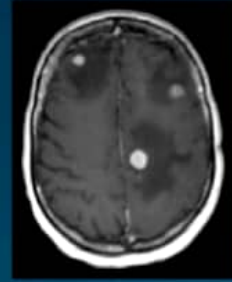


Q 3.

A. What is the most likely diagnosis?

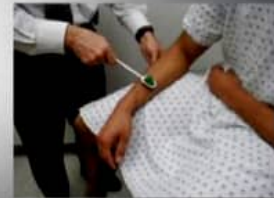

B. What is the most likely primary disease and its risk?

C. Mention 2 other possible symptoms in the patient.

Q 4 .

A. What muscle is being tested?

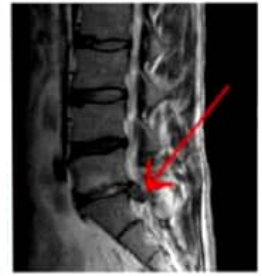

B. What nerve roots are being tested?

C. What is the corresponding action of the test?

Q 5.

A. What is the level of the pathology?

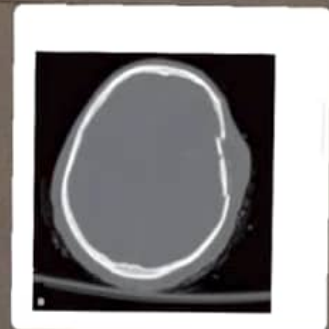


B. What spinal nerve roots most to be affected?

C. Mention 3 red flags of the pathology seen

**CONFUSED, OPEN EYES TO
Q 6. SPEECH, LOCALISIC PAIN**

A) What is the GCS of the patient?

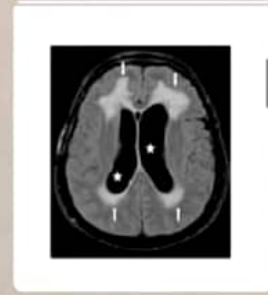

B) Describe the finding seen in the CT-scan bone window.

C) Mention 2 possible complications of this head injury.

Q 1.

A. Describe the type of imaging used.

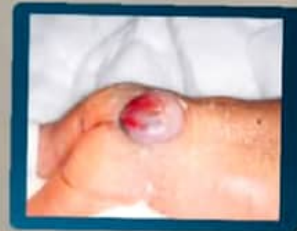

B. Name the sign indicated by white arrows.

C. What is the pathophysiology of this finding?

Q 2.

A. What the pathology seen in this patient ?



B. Mention 3 risk factors of this congenital anomaly.
