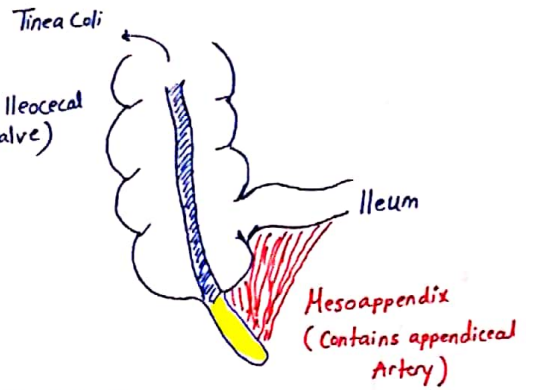


# Appendix

## # Anatomy:

- The appendix is suspended from Terminal ileum by Mesoappendix. (2cm below Ileocecal valve)
- Its length vary from 1-30cm. (most are 6-9cm)
- The Base of appendix located at McBurney's Point (2/3rds away from the umbilicus at the line from ASIS to umbilicus) - The Three Tinea Coli converge at the Base - Useful Landmark intra op -
- The tip of appendix could be:
  - 1) Retrocecal (Most Common) - 40% → Rt. iliac fossa Pain.
  - 2) Subcecal - 24% -
  - 3) Pelvic - 9% - → Pelvic Pain
  - 4) Subhepatic → Rt. upper Quadrant pain → seen in pregnancy due to enlarged uterus.
  - 5) Pre-ileal, Post ileal → present as Gastroenteritis.



## \* Blood Supply:

- SMA → Ileocecal A. → Appendiceal Artery
- End Artery so appendix is very sensitive to Ischemia.

## \* Function of Appendix:

- ① part of GALT (Gut Associated Lymphoid Tissue) → secrete IgA
- ② Site of Good Bacteria.
- ③ Useful in surgeries (in Urology)
- ④ Appendectomy → Protect against UC. No ↑ in Colon ca Risk. Don't cause Immunocompromised.

## Appendicitis

- The most common cause of Emergent Abdominal Surgery -

- Frequently seen in 2nd to 4th decades of life.
- Slight male predominance.

## # Pathophysiology:

- ① Obstruction of Lumen:
    - Caused by: ① Undigested food/seeds.
    - ② Lymphoid Hypertrophy (Peyer Patch) (Post viral infection) - childrens-
    - ③ Fecolith - Adults - (The usual Cause)
    - ④ Cecal Tumors - Elderly -
    - ⑤ Parasites (Ascaris), Carcinoid Tumor.
  - ② Visceral muscle spasm:
    - Trying to push the obstructed material.
  - ③ Distention:
    - Continuous normal secretion of appendix
    - ↑ Intra-Luminal pressure → Become more than Venous P.
    - Vascular Congestion
  - ④ Ischemia:
    - Impaired Arterial supply allowing Bacterial Invasion & Ischemia (Gangrene)
    - Polymicrobial Infection (E.coli, Bacteroids fragilis)
  - ⑤ Perforation:
    - Occur after 48 hours.
    - \* Most Common site is mid-Portion of Antimesenteric border.
    - or tip of the appendix.
    - \* 20% perforate in < 24 hours.
- lead to Closed loop Obstruction.

## # Visceral - Somatic Pain Sequence:

- Appendix distention cause Periumbilical Dull, vague pain related to Embryological origin, the after Bacterial translocation to appendix serosa it will irritate overlying peritoneal layer (Parietal layer) leading to shifting in pain to RLQ & become pin-point, localized Knife-like (Somatic pain) → After 4-6 hours.

## # Presentation: (Symptoms)

1. Periumbilical Pain shifted to RLQ. - 2nd symptom -
2. Anorexia (Nearly Always) - 1st symptom -
3. Vomiting 75% - 2ndry to Neural stimulation -
  - ↳ < 2 times (if more, think of GE, Terminal ileitis)
  - ↳ if preceded the pain, think of other DDX (GE)
4. Low Grade fever. (High Grade if Perforated)
5. Change In Bowel habits → Diarrhea → if tip irritate the rectum. Constipation → Ileus.

## # Signs:

1. Vital signs may be normal.
2. Patient lie supine with Right hip flexion
  - ↳ ↓ Irritation on Psoas muscle.
3. Signs of peritoneal Irritation:
  - start with voluntary Guarding then progress to Reflex Rigidity. (Involuntary muscle spasm)

## Signs of Appendicitis

1. Rebound Tenderness & Tenderness (Mc-Burney Point)
2. Obturator Sign → Pain on internal rotation of flexed hip & Knee. (Pelvic Appendicitis)
3. Psoas Sign → Extension hip & knee or flexion of hip against resistance (Retrocecal)
4. Rovsing's Sign → Rebound pressure on LIF & pain in RIF. (caused by colon gases)
5. Dunphy's Sign → Pain on Coughing.
6. Cutaneous Hypersthesia → By needle or picking the skin on the Right side at T10, T11, T12.

## # Laboratory findings:

- ① CBC → Leukocytosis with left shift ( $>10000$ ) - Higher levels in perforated.
- ② Urine analysis → if +ve don't R/O Appendicitis because pelvic tip can irritate ureter & Bladder
- ③ B-HCG → R/O ectopic pregnancy.

## # Imaging studies:

### ① Plain x-ray:

↳ Chest → R/O pneumonia, free air

↳ Abdomen → non-specific, fecolith seen in 5%, loss of Psoas shadow, scoliosis to the left.

### ② Ultrasound: Sensitive in 96%, specific in 98%.

- \* Signs:
- ① Thickening of wall
  - ② peri-appendiceal fluid
  - ③ Fecolith.
  - ④ Tube like structure (Blind ended loop originate from cecum)
  - ⑤ Non-compressible with AP diameter 6mm (If compressible &  $<5$  mm in diameter exclude appendicitis)

\* If Appendix not visualized → Study is Inconclusive.

### ③ CT Scan: (High Resolution Helical CT)

- Signs:
- 1- fecolith.
  - 2- Peri appendiceal fluid
  - 3- Dilated ( $>6$ mm) & thickened wall.
  - 4- Dirty fat & thickened mesoappendix
  - 5- phlegmon. (Abs)

## # Acute Appendicitis In special Groups:

- ① Childrens  $<5$  yrs → GI upset is more common. Rapid Progression to Rupture (45%) (Greater Omentum is Underdeveloped & can't contain the rupture)

- ② Elderly → Lower Incidence. Rapidly Progress to perforation.

### ③ Pregnancy

- ↳ 1 in 2000
- ↳ More in 1st 2 trimesters. (New Onset N & V)
- ↳ Abdominal Pain & tenderness, less common Guarding & Rebound tenderness (lax Abdomen)
- ↳ WBC  $>20000$
- ↳ Dx by US or laparoscopy
- ↳ Operation carry 10-15% Risk of Premature Labor
- ↳ Appendicitis fetal mortality 3-5% while in perforation 20%.

## # Complications of Perforation:

- ① Abscess formation → Percutaneous Drainage ⊕ Interval Appendectomy & Abx (After 6 weeks)
- ② Small Bowel Obstruction
- ③ Peritonitis

## DDX of Appendicitis

1. Mesenteric lymphadenitis
2. UTI
3. Ectopic pregnancy.
4. PID, Twisted Ovarian cyst
5. Meckle diverticulitis

## Alverado Score

- Symptoms
- Migration of pain to RIF (1)
  - Anorexia (1)
  - Nausea/Vomiting (1)

- Signs
- Tenderness in RIF (2)
  - Rebound Tenderness (1)
  - Elevated Temperature (1)

- Labs
- Leukocytosis (2)
  - Shift to left (1)

- 9-10 → Appendicitis (no further workup)

- 7-8 → High likelihood

- 5-6 → Confirm with CT

- 0-4 → Extremely unlikely.

## # Treatment:

- ① Hydration (IV fluid)
- ② Correct Electrolytes
- ③ Preop. Abx with Gram -ve Anaerobic coverage. ↳ for 1 day if unperforated ↳ for 3-7 days if perforated
- ④ Appendectomy

## Layers of Abdominal wall in Appendectomy

1. Skin
2. SC fat & Scarpa's fascia
3. External Oblique.
4. Internal oblique
5. Transversus muscle
6. Transversalis fascia
7. Peritoneum.

## # Differential Diagnosis of Acute Appendicitis:

### ① Acute Mesenteric Lymphadenitis:

- Recent URTI
- Diffuse pain, Generalized LN.
- No Rigidity.
- Lymphocytosis.

### ② Acute Gastroenteritis:

- Vomiting precede pain ⊕ Diarrhea (watery)
- Chills & fever
- Normal Leukocyte Count.
- Salmonella cause Localized pain & rebound tenderness.

### ③ Meckle Diverticulitis:

- within distal 2 feet from ileum.
- Require same treatment as appendicitis.

### ④ Intussusception:

- child < 2 years (Appendicitis rare in this age)
- Sudden colicky pain (Infant is well between attacks)
- Bloody Stool
- Sausage shape mass in RLQ.

### ⑤ Crohn's Disease:

- Fever, RLQ tenderness, Diarrhea.
- Infrequent Anorexia.

### ⑥ Perforated Peptic Ulcer:

- If spilled Gastroduodenal contents
- Gravitate down to cecal Area (Valentino Sign)

### ⑦ Diverticulitis or perforated cecal Tumor:

- Older patients
- Need CT scan.

### ⑧ Epiploic Appendicitis:

- Torsion that lead to infarction of cecal appendix with localized Tenderness.
- No N/V, patient don't look ill, Pain shift unusual.

### ⑨ Urinary Tract infection:

- Acute pyelonephritis → Chills, pyuria, Bacteriuria.

### ⑩ Uretric Stone:

- Simulate Retrocecal Appendicitis.
- Referred Pain to Labia, scrotum.
- Hematuria.
- CT scan without Contrast.

### ⑪ Primary peritonitis:

- Seen In nephrotic syndrome, Cirrhosis or Immunesuppression.
- Dx by peritoneal Aspiration, if only gram +ve → Primary Peritonitis → Abx if mixed flora or Gram -ve → Secondary Bacterial Peritonitis

### ⑫ Henoch-Schollen Purpura:

- Occur 3 weeks after strep. infection.
- Abdominal Pain, Joint pain, purpura & Nephritis (Hematuria)

### ⑬ Yersinosis:

- Infection with *Y. enterocolitica* or Pseudo tuberculosis from contaminated food: 1) mesenteric lymphadenitis 2) Colitis 3) Appendicitis 4) Ileitis.
- ↳ mild self limited or lead to sepsis.
- ↳ sensitive to Tetracyclin, Ampicillin.

### ⑭ Pelvic Inflammatory Disease:

- Usually Bilateral
- N/V (50%), Pain, cervical motion tenderness.

### ⑮ Ruptured Graafian follicle:

- Midpoint of MC (Mittelschmerz)
- Absent leukocytosis or fever.

### ⑯ Ruptured Ectopic Pregnancy:

- Amenorrhea, cervical motion Tenderness
- vaginal Bleeding.
- ↑ B-HCG, ↓ Hb, ↑ leukocyte count
- Culdocentesis is diagnostic.

### ⑰ Torsion of ovarian cyst:

- U/s could be diagnostic
- Emergent detorsion to prevent Necrosis

## Appendiceal Tumors

- Appendix malignancies are extremely rare. (<1% in appendectomy specimen)
- Recent studies shows that mucinous Adenocarcinoma is the most common (37%) malignant Tumor in appendix followed by Carcinoid Tumors (33%)

### # Carcinoid Tumors :

- Tumor Arise from Neuroendocrine cells ( Kulchitsky cells) & secrete serotonin. ( Yellow firm Mass)
- They occur in : 1. Appendix ( most common site) → Cause Appendicitis  
Highest rate ← 2. Ileum → Can cause SBO due to severe mesenteric fibrosis  
3. Rectum. → Rectal Bleeding, Abd. Pain. (Majority at the tip)
- Other Symptoms:
  - ① Pellagra-like symptoms (↓ Niacin Production)  
→ 3 D's → Dermatitis, Diarrhea, Dementia.
  - 10% ② Carcinoid Syndrome: B-FDR: → Medical treatment is Octreotide.  
→ Bronchospasm, Flushing, Diarrhea, Rt. sided HF (due to Tricuspid Insufficiency, Pulmonary stenosis)
- \* Treatment : ( Malignant Potential related to size)
- If tumor < 1cm → Appendectomy.
- If tumor 1cm & extending to meso appendix or > 1.5 → Right Hemicolectomy.

### # Adenocarcinoma :

- Rare Tumor.
- Has 3 Subtypes : ① Mucinous Adenocarcinoma  
② Colonic Adenoca.  
③ Adenocarcinoid.
- The most common presentation is Appendicitis & early perforation. ; could present with mass or Ascites.
- Treatment: Right Hemicolectomy.

### # Mucocele :

- Progressive enlargement of appendix from Intraluminal Accumulation of mucoid substances.
- Histological subtypes :
  - ① Retention Cyst
  - ② Mucosal Hyperplasia
  - ③ Cyst adenoma.
  - ④ Cyst Adenocarcinoma } Benign Mucocele treated with Appendectomy.