ovaries

ovarian cysts

Premenopausal Women

- complex cyst
  - septations
  - Ascites
  - metastases
  - Bilateral lesions
  - papillary projections \ solid components
- simple cyst
  - Approx 10% of women will have surgery for an ovarian cyst
  - Tend to be benign in young women
  - More difficult to pre-operatively decide if benign or malignant
  - The underlying management rationale is to minimise patient morbidity by:
    - conservative management where possible
    - use of laparoscopic techniques where appropriate, thus avoiding laparotomy where possible
    - referral to a gynaecological oncologist where appropriate
- Types of ovarian cysts in young women
  - Benign
    - ovarian
      - functional cyst
      - Endometriomas
      - cystadenoma
        - Serous
        - Mucinous
      - Mature Teratoma
    - cyst
      - paratubal
    - Non-ovarian
      - Pseudocyst
        - peritoneal
      - Abscess
        - Tubo-ovarian
        - Appendiceal
        - Diverticular
      - pelvic kidney
  - Malignant
    - Germ-cell tumours
    - primary
      - Epithelial carcinoma
      - Sex-cord tumour
    - secondary
      - Breast carcinoma
      - Gastrointestinal carcinoma
- Tumour markers in young women
  - Lactate dehydrogenase (LDH)
  - Alpha FP
  - bHCG
  - should be measured in all women under age 40 with a COMPLEX ovarian mass because of the possibility of germ cell tumours
- Symptoms
  - Asymptomatic.
  - Pain
  - Pressure symptoms — bloating, urinary frequency, bowel symptoms
  - Symptoms of endometriosis
  - Sinister features
- Imaging
  - A pelvic ultrasound is the single most effective way of evaluating an ovarian cyst
  - Transvaginal USS is preferatable due to its increased sensitivity over transabdominal USS.
  - MRI may aid diagnosis
  - An estimation of the risk of malignancy is essential in the assessment of an ovarian mass — RMI = U x M x CA-125 — Risk of Malignancy Index (RMI)
    - (1)Menopausal Status
    - (2)Ultrasound findings

Benign (B-rules)	Malignant (M rules)
Unilocular cyst	Irregular solid tumor
Presence of solid components where the largest solid component <7 mm	Ascites
Presence of anacoustic shadowing	At least four papillary structures
Bilateral multilocular tumour with largest diameter <7 cm	Irregular multilocular solid tumour with largest diameter >7 cm
No blood flow	Very good blood flow

    - (3)CA-125 levels
      - CA-125 is unreliable in premenopausal women, high rate of false positives and reduced specificity.
      - CA-125 may be raised in numerous conditions including :
      - A raised serum CA-125 should be interpreted cautiously.
      - is primarily a marker for epithelial ovarian carcinoma and is only raised in 50% of early stage disease
      - Causes of elevated CA-125
        - Malignant
          - Gynecological
            - Gynecologic Cancers
            - Epithelial ovarian cancer
            - Some germ cell tumors
            - Some stromal tumors
            - Fallopian tube cancers
            - Endometrial cancer
            - Endocervical cancer
          - Non-gynecological
            - Pancreatic cancer
            - Lung cancer
            - Colon cancer
        - Benign
          - Gynecological
            - Endometriosis
            - Leiomyomata uteri
            - Ectopic pregnancy
            - Normal pregnancy
            - Pelvic inflammatory disease
            - Menses
          - Non-gynecological
            - Pancreatitis
            - Cholecystitis
            - Cirrhosis
            - Peritonitis
            - Peritoneal tuberculosis
            - Peritoneal sarcoidosis
            - Recent laparotomy

CALCULATION OF THE RMI I

The RMI I combines three preoprgial features. It is a product of the serum CAs125 level (u/ml), the menopausal status (M), and an ultrasound score (U) as follows.

RMI = U x M x CA125

- The ultrasound result is scored 1 point for each of the following characteristics: multilocular cysts, solid areas, metastases, ascites and bilateral lesions.
  - U = 0 for an ultrasound score of 0
  - U = 1 for an ultrasound score of 1)
  - U = 3 for an ultrasound score of 2-5
- The menopausal status is scored as:
  - 1 = premenopausal
  - 3 = postmenopausal
  - This guideline is directed at postmenopausal women and therefore all will be allocated the same score of 3 for menopausal status.
- Serum CAs125 is measured in u/ml and can vary between zero and hundreds or even thousands of units.

- Referral to a gynaecological oncologist:
  - serum CA-125 of more than 200 units/ml.
  - ascites.
  - evidence of abdominal or distant metastasis.
  - a first-degree relative with breast or ovarian cancer.
- Management: - Simple ovarian cysts
  - < 50 mm diameter — Do not require followup as, very likely to be physiological and almost always resolve within 3 menstrual cycles.
  - 50–70 mm in diameter — should have yearly ultrasound follow-up.
  - Larger simple cysts — should be considered for either further imaging (MRI) or surgical intervention; difficulties in examining the entire cyst adequately at time of ultrasound.
- Treatment
  - Ovarian cysts that persist or increase in size are unlikely to be functional and warrant surgical management.
  - The use of the combined oral contraceptive pill does not promote the resolution of functional ovarian cysts.
  - Aspiration of ovarian cysts, is less effective and is associated with a high rate of recurrence
  - Laparoscopic management of presumed benign ovarian cysts should be undertaken
    - There is consensus on the size above which surgical management should be considered. Most studies have used maximum diameter of 50-60 mm among their inclusion criteria to offer conservative management
  - Spillage of cyst contents should be avoided where possible
- NON-FUNCTIONAL OVARIAN CYST — Endometriomas (chocolate cysts) — Should be removed if
  - >5cm
  - causing symptoms or issues with fertility

Postmenopausal Women

Cyst in a post menopausal woman is a tumour until proven otherwise

- Symptoms:
  - **Bloating**
  - **Early satiety**
  - **Abdominal Distension/Pain**
  - **Toilet – Urinary frequency**
  - Incidence is approx between 6 – 17%
  - Can be detected incidentally
- History
- Full examination inc pelvic
- USS
- Bloods – CA 125
- CT TAP/MRI

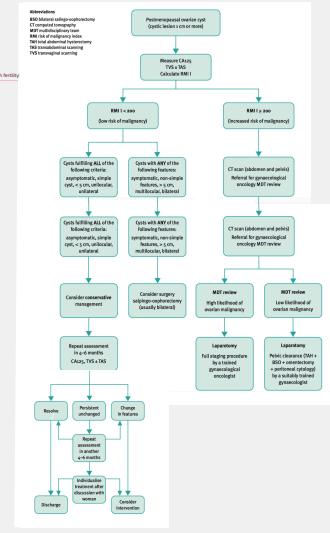

Ovarian Cancer

- Background
  - 4th most common cancer for women
  - ~679 new cases a year
  - General risk to age 74 : 1.4%
  - ~10% familial BRCA / Lynch / Tothers
  - 80% post menopausal
- Stage Vs Grade
  - Grade = Characteristics generally consistent with tumour behaviour / Differentiation
  - Stage = Anatomical distribution
- Pathology of Ovarian Cancer
  - Epithelial Tumours (90%)
    - Serous - 75% of all ovarian ca.
      - HGSC Vs LGSC – tubal differentiation
      - HGSC 70%, LGSC 5% of all ovarian malignancies
      - Fimbrial STIC exfoliation
      - Post menop. / raised ca125 / advanced stage
      - Variable size / cystic / solid
      - IHC
        - Borderline variant
    - Endometrioid – 15%
      - Asc. with endometriosis (42%), endometrial ca (20%), Lynch
      - Rarely borderline, usually low grade
      - 30% bilateral
      - IHC / MMR genes
    - Clear cell – 7%
      - Asc. Endometriosis (60-70%), Lynch
      - Solid nodule in chocolate cyst / solid / cystic / unilocular
      - IHC / MMR genes
    - Mucinous – 5%
      - Majority of mucinous tumours are metastatic from GI – especially if bilateral/ surface lesions
      - 5% of ovarian malignancies
      - Largest ovarian tumours / unilateral / multi-loculated
      - Intestinal / endocervical types
      - Ca 19.9 , CEA, modest Ca 125
      - Borderline type
    - Carcinosarcoma – rare / aggressive/ advanced stage / poor prognosis
    - Mixed Mullerian Tumours
  - See cord - stromal tumours (<2%) – gonadal stroma – endocrine
    - Granulosa cell T. – low grade/ indolent /late recurrence/ inhibin (juvenile version recurs sooner)
      - follicular cells, produce oestrogen/inhibin, difficult to predict based on grade
    - Sertoli leydig cell T. – combo cell types / grade + behaviour
      - combination cell types / granulular/mesenchymal
    - Steroid cell T. – uncommonly malignant
    - Thecoma / Fibroma group – usually benign, except fibrosarcoma
  - Germ cell tumours (<3%) – undifferentiated pluripotial germ cells
    - Commonest type is the mature cystic teratoma – dermoid cyst – vast, vast majority benign.
    - Rare
      - Yolk sac tumour
    - Children/adolescents
      - Dysgerminoma
    - aggressive/excellent respons
      - Embryonal carcinoma
    - AFP/HCG
      - Choriocarcinoma
    - Teratoma
  - Metastatic pathways
    - Transcoelomic
    - Lymphatic
    - Haematogenous
- Risk factors
  - Age
  - Nulliparity
  - Late age at first birth
  - Early menarche
  - Late menopause
  - Ovarian stimulation
  - Ionising radiation
  - Obesity
  - Family history
- Genetic Risk
  - Background Risk : 1.4%
  - BRCA 1 40% 72% – Breast
  - BRCA 2 27% 49% – Breast
  - Lynch syndrome - varies.. 4- 20% 40-80% CRC, 40% Endometrial
  - 1 x 1st degree relative : 4%
  - 2 x first degree relatives : 12%
- Protective factors
  - Increasing parity
  - OCP
  - Breastfeeding
  - Tubal ligation
- Presenting Symptoms
  - Bloating
  - Eating less – early satiety/anorexia
  - Abdominal / pelvic pain
  - Urinary symptoms
  - Dyspareunia
  - Abnormal uterine bleeding
  - Weight loss
  - New IBS Sx in >40yo.
  - BEAT
    - B – bloating that is persistent
    - E – eating less and feeling fuller
    - A – abdominal pain
    - T – trouble with your bladder
- Work up
  - Imaging – CT TAP/ MRI Pelvis
  - Histology/cytology
  - Optimisation of co-morbidities
  - MDT
- Ovarian Cancer Staging
  - Stage I — **Tumour confined to ovaries or fallopian tube(s) SY5**
    - IA Tumour limited to within one ovary (capsule intact) or fallopian tube 85%
    - IB Tumour limited to within both ovaries (capsules intact) or fallopian tubes 85%
    - IC Tumour limited to one or both ovaries or fallopian tubes, with any of the 80% following:
      - IC1 Surgical spill intraoperatively
      - IC2 Capsule ruptured before surgery or tumour on ovarian or fallopian tube surface
      - IC3 Malignant cells in the ascites or peritoneal washings
  - Stage 2 — **Tumour involves one or both ovaries or fallopian tubes with pelvic extension (below pelvic brim) or primary peritoneal cancer SY5 – 70%**
    - IIA Extension and/or implants on the uterus and/or fallopian tubes/and/or ovaries
    - IIB Extension to other pelvic intraperitoneal tissues
  - Stage 3 — **Pathologically confirmed spread to the peritoneum outside the pelvis and/or metastasis to the retroperitoneal lymph nodes SY5 – 40%**
    - IIIA1 Positive retroperitoneal lymph nodes only
      - (i) Metastasis ≤ 10 mm in greatest dimension
      - (ii) Metastasis > 10 mm in greatest dimension
    - IIIA2 Microscopic extra-pelvic (above the pelvic brim) peritoneal involvement with or without positive retroperitoneal lymph nodes
    - IIIB Macroscopic peritoneal metastases beyond the pelvic brim ≤2 cms in greatest dimension, with or without metastasis to the retroperitoneal lymph nodes
    - IIIC Macroscopic peritoneal metastases beyond the pelvic brim >2 cms in greatest dimension, with or without metastases to the retroperitoneal nodes. (Includes extension of tumour to capsule of liver and spleen without parenchymal involvement of either organ)
  - Stage 4 — **Distant metastasis excluding peritoneal metastases SY5 – 10%**
    - (Including inguinal lymph nodes and lymph nodes outside of abdominal cavity and parenchymal mets)
    - IVA: Pleural effusion with positive cytology
    - IVB: Metastases to extra-abdominal organs
- Management
  - MDT – always, always, always ...
    - Gynaecological Oncologists
    - Radiation Oncologist
    - Medical oncologist
    - Pathologist
    - Radiologist
    - Specialist nurses
    - Admin staff
  - Primary cytoreduction
  - Neoadjuvant chemotherapy – usually 3-4K carbo/taxol
  - Adjuvant chemotherapy – Usually 6K carbo/taxol
  - PARPi
  - Fertility sparing treatment?

OVARIAN TORSION

- Sudden onset of sharp and usually unilateral lower abdominal pain
- O/E Tender +/- guarding
- Raised WCC & CRP
- 70% of cases accompanied by nausea and vomiting
- USS findings
  - Doppler
    - Absent arterial flow
    - Absent or reversed diastolic flow
    - commonly seen
      - Little or no intra-ovarian venous flow.
  - other USS features include:
    - 1. Enlarged hypoechogenic or hyperechogenic ovary
    - 2. Peripherally displaced ovarian follicles
    - 3. Free pelvic fluid. This may be seen in more than 80% of cases
    - 4. Whirlpool sign of twisted vascular pedicle
    - 5. Underlying ovarian lesion can often be found
    - 6. Uterus may be slightly deviated towards the torted ovary.

The ovary twists on itself stops it's blood supply. If untreated the patient goes septic/black and died

- Treatment
  - ABCDE
  - Analgesia
  - Laparoscopy to uncoil the torted ovary
  - Possibly oophoropexy to fixate the ovary which is likely to twist again
  - Where blood flow is cut off to the ovary for an extended period of time, necrosis of the ovary can occur
    - So progress oophorectomy

Presented with xmind