

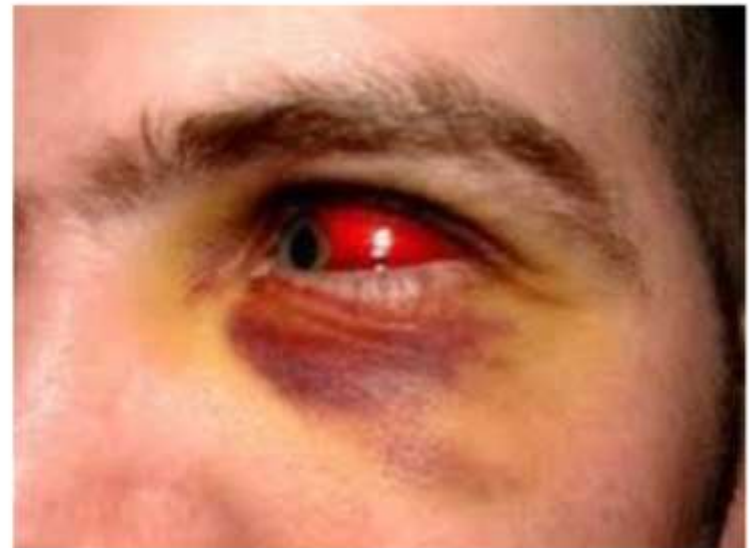4 MARKS

Pt presented with blunt trauma


- What can you see in the pic?
Restricted vertical movement
Subconjunctival hemorrhage
Swollen lid
Loss of sensation over upper cheek
Periorbital ecchymoses

Ttt?

Three guide line



3 MARKS



5 MARKS

1- What is the name of this test ?

Optical coherence tomography (OCT)

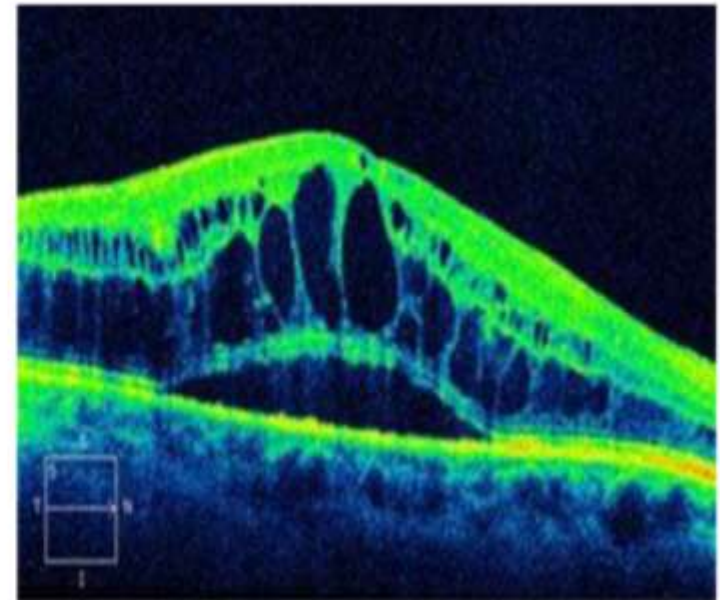
2- What is the finding in this image ?

loss of foveal depression and fluid
under macula (subretinal fluid just under macula)
that reflect macular edema

3- Give two differential diagnosis ?

Diabetic retinopathy (maculopathy) Central retinal
vein occlusion (CRVO)

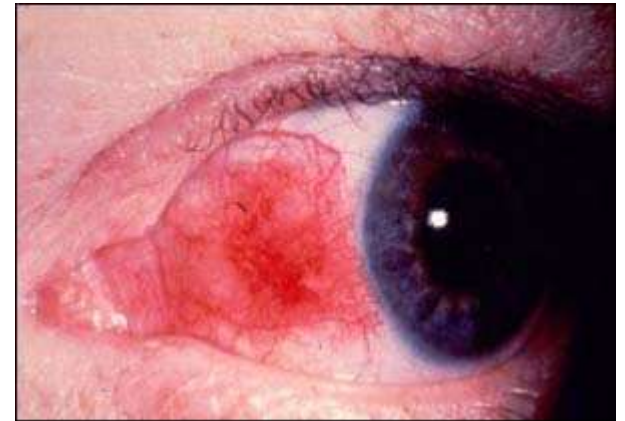Wet Age-related macular degeneration (Wet AMD)



Patient have a painless red eye

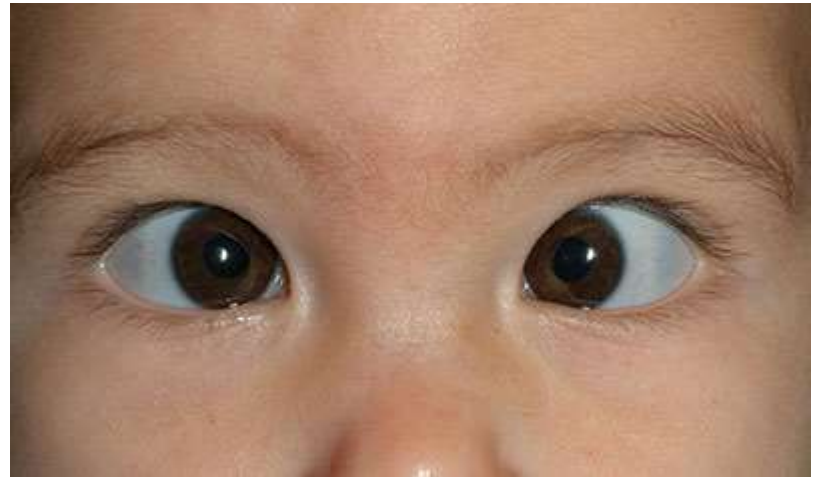3 marks

1. what is the diagnosis ? •
2. give 2 topical drops that used in the treatment? •



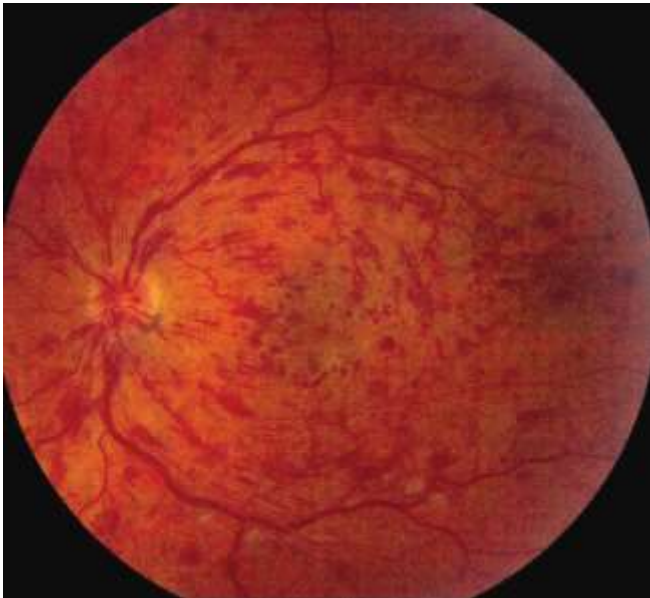5 Marks

1. what is the diagnosis ? (2marks) •
- 2.give 3 guideline to treat the patient? •
(3marks)



5 marks

1. what is the diagnosis ? (1 mark) Ischemic type of central retinal vein occlusion •
What is the risk factor for this case ? (2marks) Age more than 60-70, •
Hypertension,DM,pregnancy,glucoma •
What is the serious complication of this patient?(2 marks) (Cystoid •
macular edema neovascularization ,



Optic disc (4 MARKS)
some says it's cupping , some says it's swelling

- 1. what is the sign (1 mark) •
- What is the test to confirm the diagnosis ? (2 •
marks)
- What is the diagnosis ? (1 mark) •

6 MARKS

Mention three types of refractory errors and •
the type of lens to correct each one ?