

# CLINICAL SKILLS LAB

**NAME :** Raghad Hamed

**LECTURE NUMBER :**



الفريق العلمي - لجنة الطب البشري

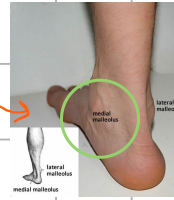


## ⑥ Posterior tibial artery felt right down behind the medial malleolus.

Again, obesity or edema may prevent successful detection of the pulse at the location.

وذمة Edema

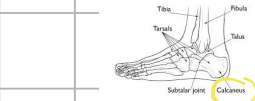
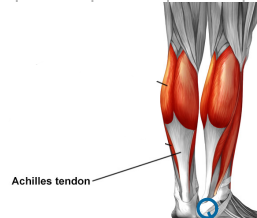
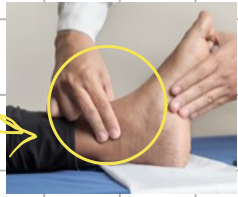هي تورم سببه احتباس كمية زائدة من السوائل داخل أنسجة الجسم



It can be felt most readily by curling the fingers of the examining hand anteriorly around the ankle, indenting the soft tissues in the space between the medial malleolus and the Achilles tendon, above the calcaneus.

أنا فحيت إنيك تحط  
لربها ملك عالبرحة  
الثانية من الكامل

The thumb is applied to the opposite side of the ankle in a grasping fashion to provide stability.



عظمة calcaneus

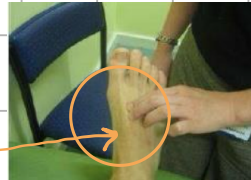## ⑦ Dorsalis pedis artery

Is examined with the patient in the recumbent position and the ankle relaxed.

يعني وضعية  
المريض يكون  
متقدم ومريح  
رجله عامة

The examiner stands at the foot of the examining table and places the fingertips transversely across the dorsum of the forefoot near the ankle.

وضعية الطبيب



The dorsum of foot refers to the upper surface of the foot, where

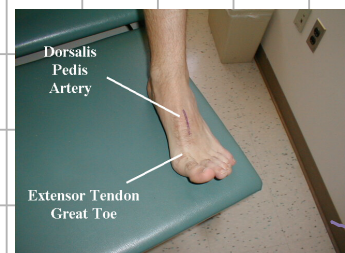
هي المنطقة  
Dorsum

The artery usually lies near the center of the long axis of the foot, lateral to the extensor hallucis tendon but it may be aberrant in location and often, requires some searching.

ويت مكانه؟

يعني مش دايما

متلاقية بسهولة



This pulse is congenitally absent in approximately 10% of individuals.

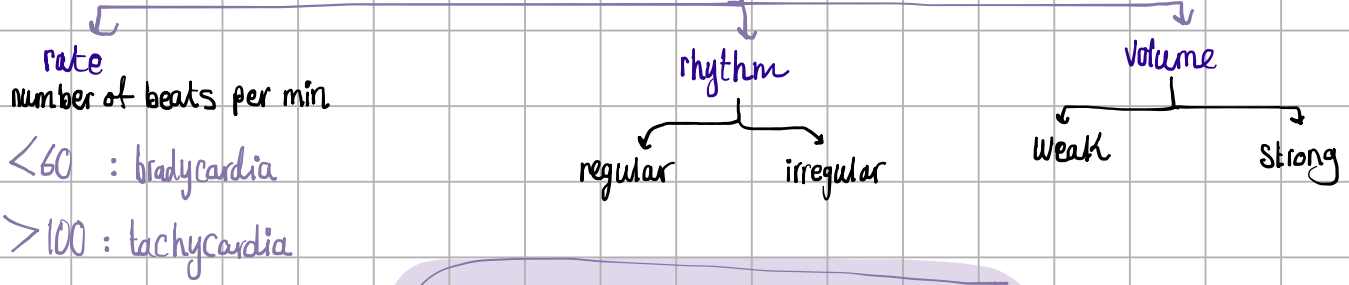
in a way that has existed since or before birth

Dorsalis pedis artery: felt between the heads of the first and second metatarsals.



مفكرت خلصنا؟

## ٣ أشياء بدنا نلاحظها من النبض



Normal pulse rate: 60 - 100  
beats per minute,  
regular rhythm



بعد كل نبض احكي بدي اشيك على الجهة الثانية

"I will check the other side"

بالإمتحان تشيكش

عجد (نفس وقت)

بست مهم تكتب

Record the pulse on to the observation chart and  
report any abnormal results to the doctor / nurse in  
charge