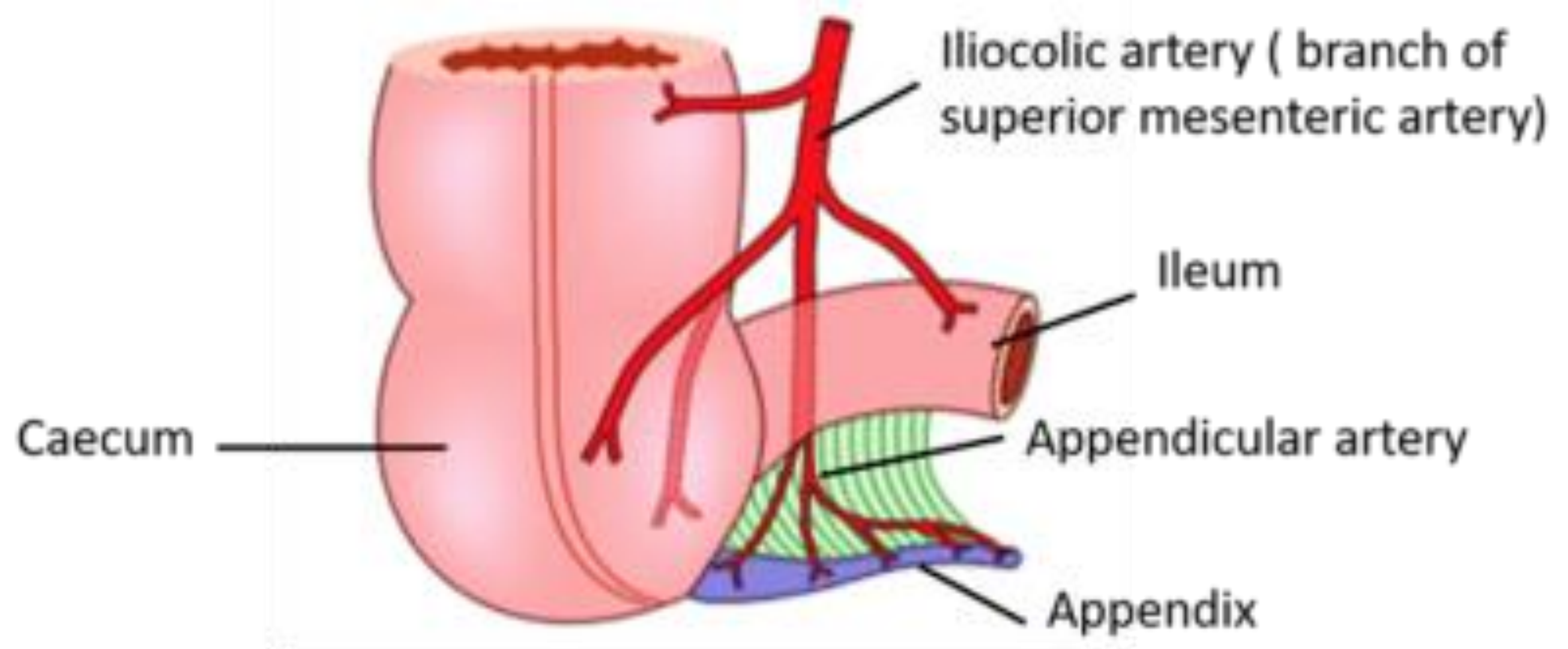


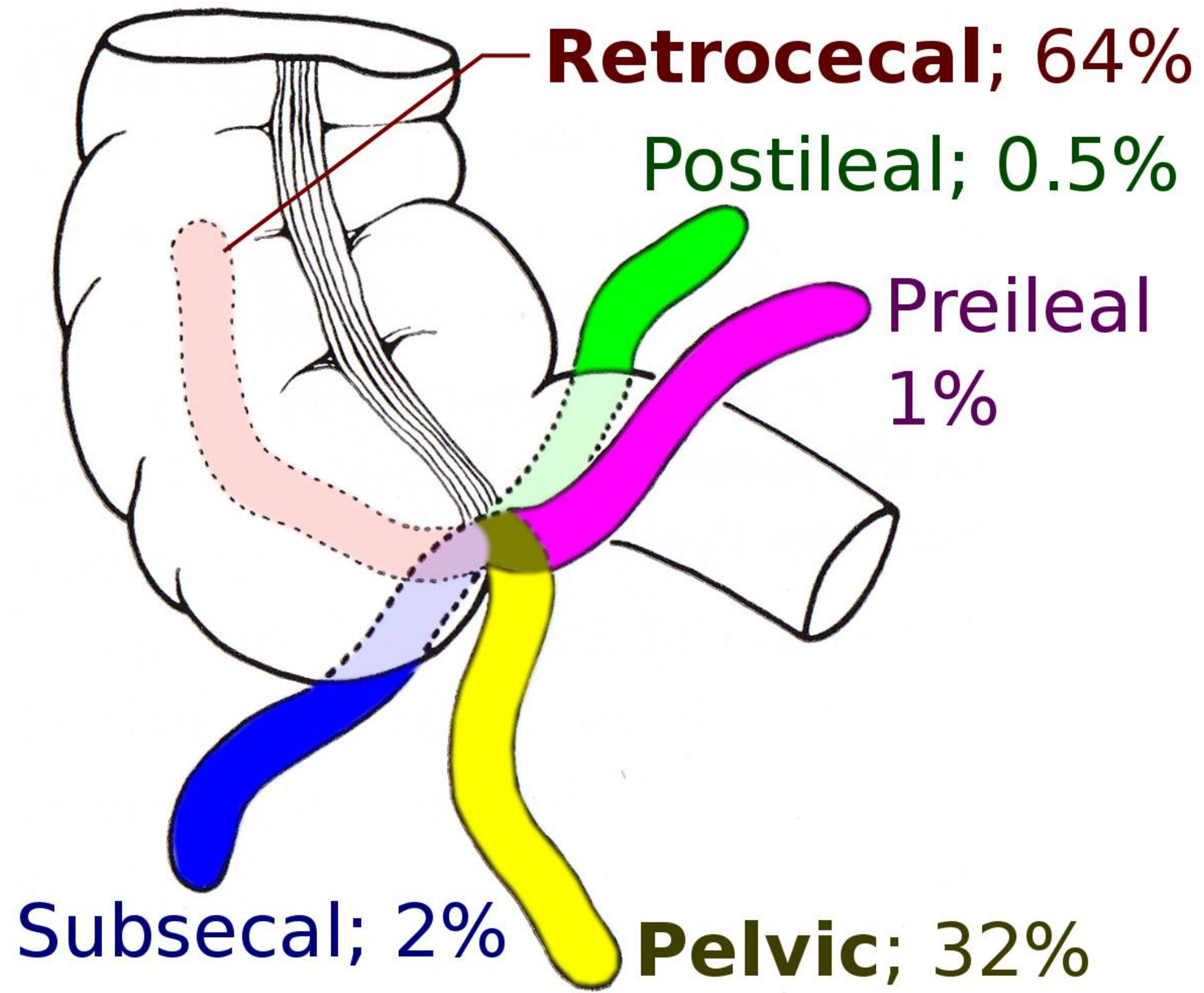
APPENDICITIS

Epidemiology

Pathophysiology



Presentation



Physical Examination

McBurney point

Obturator sign

Psoas sign

Rovsing sign

Laboratory Evaluation

Imaging

Treatment

Carcinoid Tumor
Appendiceal Mucinous Neoplasms
Adenocarcinoma