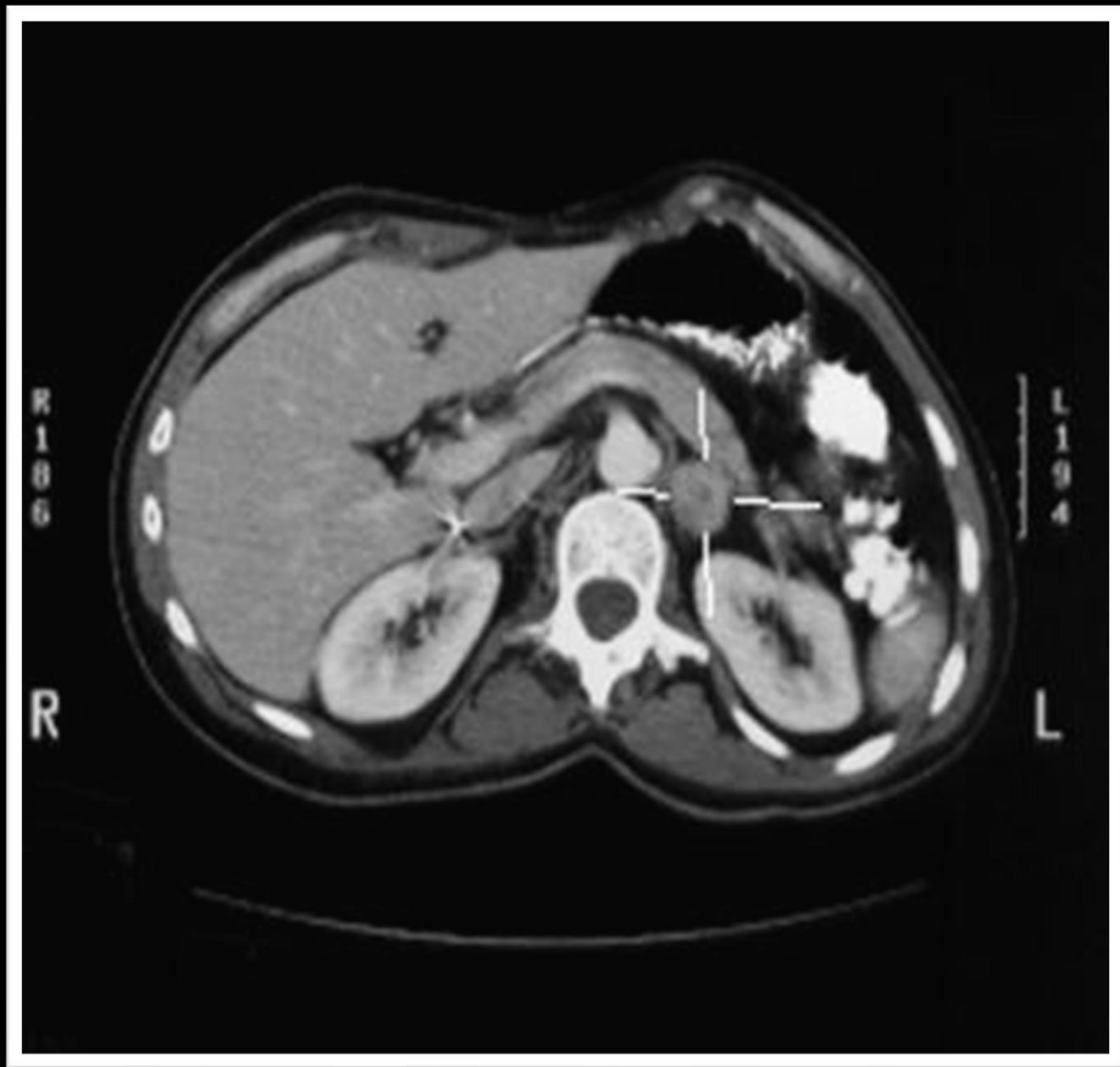


Adrenal Mass

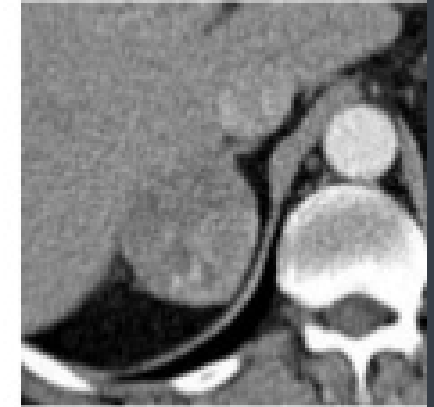
Dr Sohail Bakkar MD, Ph D

Asst. Prof. Endocrine & General Surgery (Hashemite University)



Adrenal Mass

incidental adrenal mass is detected on cross-sectional imaging (rarely on ultrasound)



✓ No known neoplasm (CT is performed for other reasons e.g. vascular, trauma)

→ **Incidentaloma**

Imaging can not distinguish between functioning and nonfunctioning adrenal mass

INCIDENTALOMA

#The most common presentation of adrenal masses is incidental observation on cross-sectional imaging performed for other reasons.

Differential Diagnosis of Adrenal Incidentaloma:

- Adenoma
- Metastasis
- Lymphoma
- Pheochromocytoma
- Neuroblastoma
- Adrenocortical carcinoma
- Hematoma
- Myelolipoma
- Adrenal hyperplasia
- Adrenal cyst
- Granulomatous disease.

#systematic approach is required to differentiate functional adrenal masses that deserve removal and those lesions with a significant risk of carcinoma from the more common benign nonfunctional adenoma.

Incidental adrenal mass

Plasma fractionated metanephrines
1 mg dexamethasone suppression
Potassium, PRA/PAC measurement (if HTN present)
Adrenal CT
Adrenal MRI

