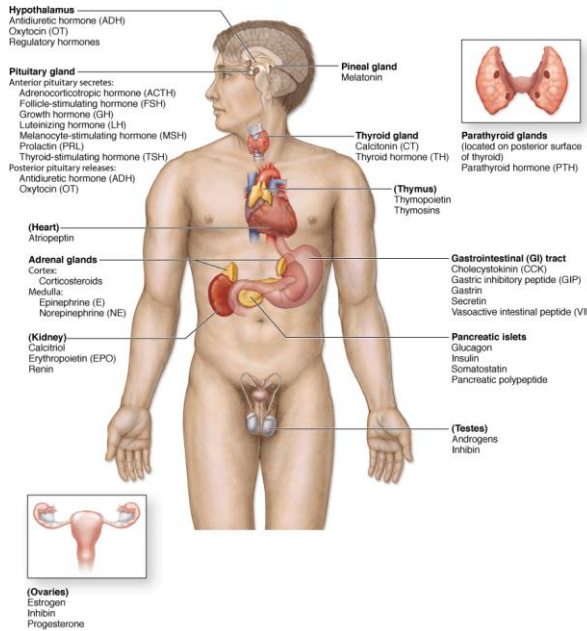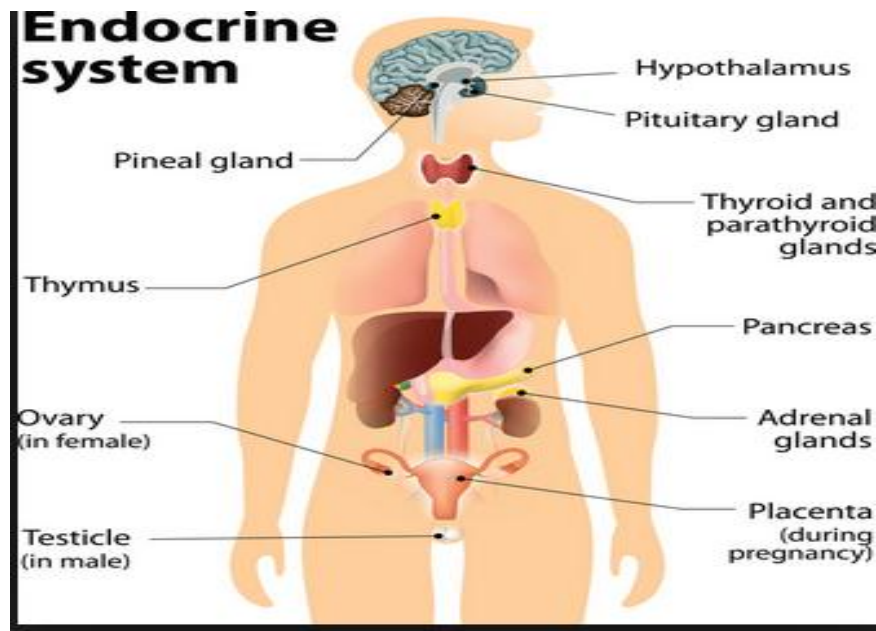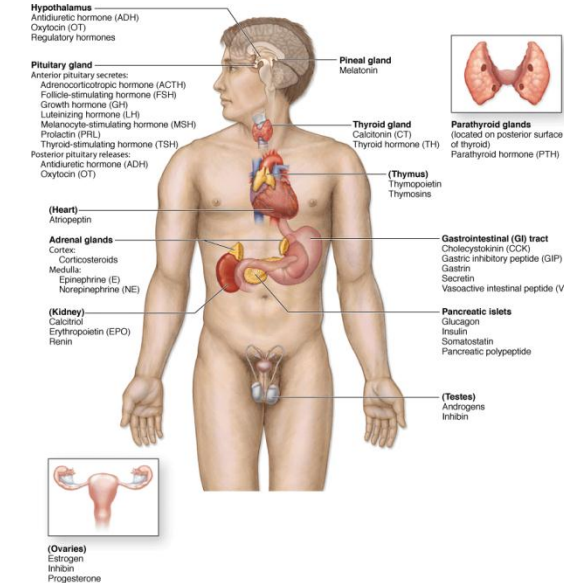


Source: Meander AL, Junqueira's Basic Histology: Text and Atlas, 2nd Edition. <http://www.accessmedicine.com>  
Copyright © The McGraw-Hill Companies, Inc. All rights reserved.



Source: Meander AL, Junqueira's Basic Histology: Text and Atlas, 2nd Edition. <http://www.accessmedicine.com>  
Copyright © The McGraw-Hill Companies, Inc. All rights reserved.

# The Endocrine System

## Anatomy Lectures 1 & 2

### Hypothalamus & pituitary gland & pineal body

# Dr. Mohamed Fathi

## Ass. Professor of Anatomy & Embryology

# **By the end of these lectures you must know:**

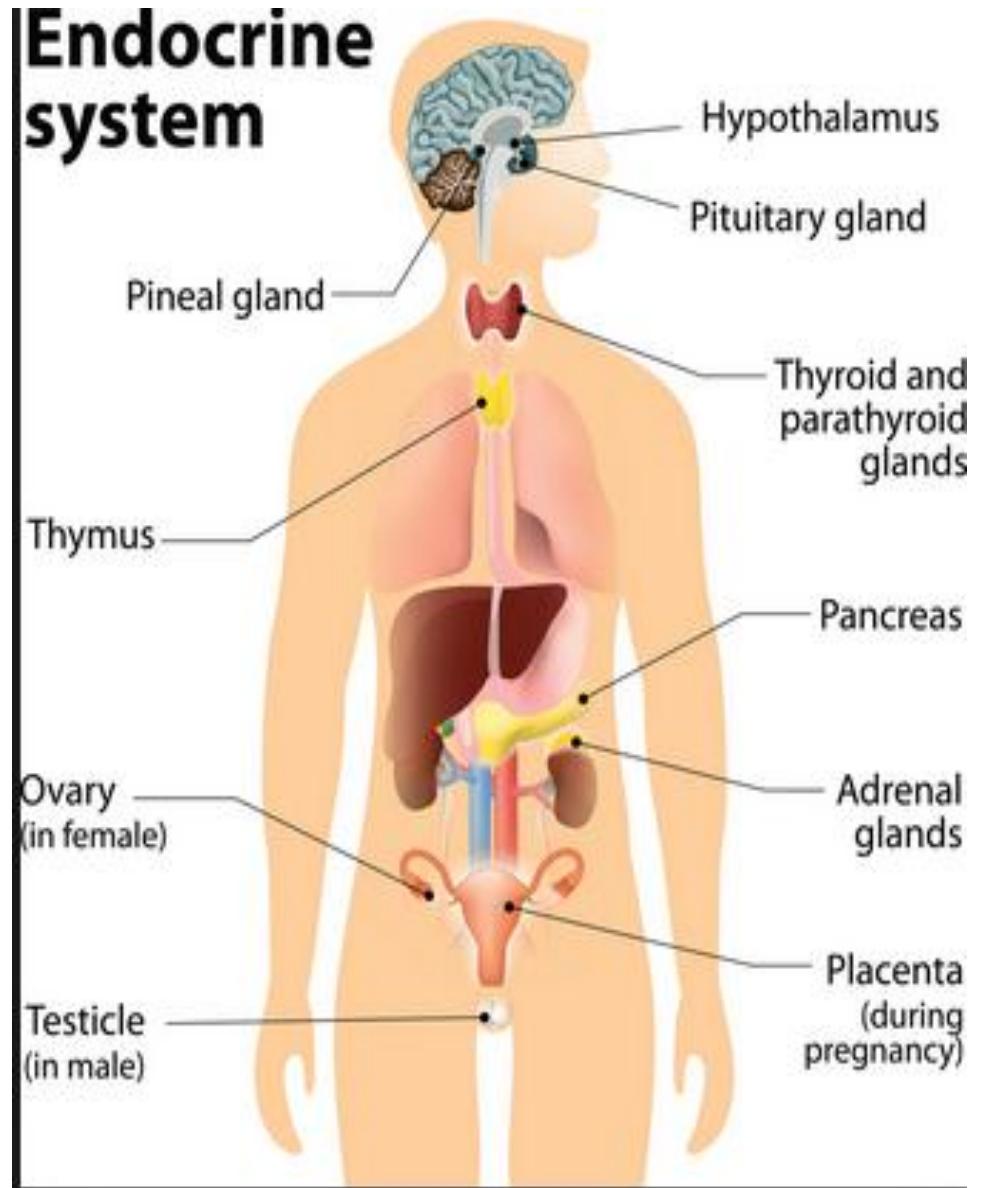
- **Overview of endocrine system.**
- **Feedback mechanism of endocrine system.**
- **Anatomical features of hypothalamus and its development.**
- **Anatomical features of pituitary gland.**
- **Histology of pituitary gland.**
- **Development of pituitary gland.**
- **Pineal gland (Anatomy, histology & function).**

# An Overview of the Endocrine System

\* **The endocrine system** is a group of specialized organs and body tissues that produce, store and secrete chemical substances known as **hormones** which regulate growth, metabolism and sexual development and function.

\* **The endocrine system** is made up of several endocrine glands:

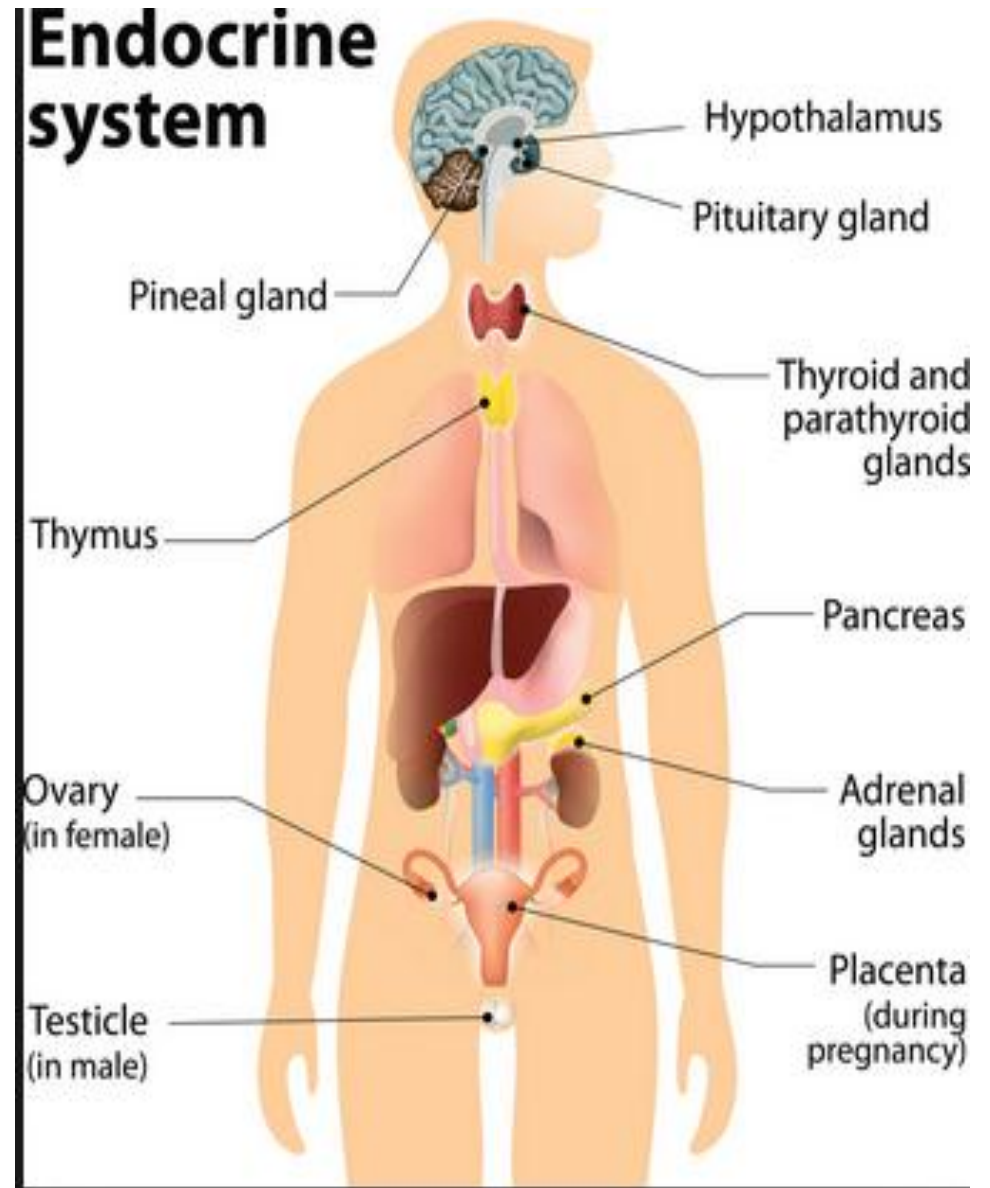
1. The pituitary gland (hypophysis cerebri) & the pineal gland.
2. The thyroid gland, the parathyroid glands & the thymus gland.
3. The suprarenal glands & the islets of Langerhans of the pancreas.
4. The testes of the male, the ovaries of the female, and the placenta (if present).



# An Overview of the Endocrine System

\* The endocrine glands differ from the exocrine glands in that they are **ductless glands**. Their secretions (**hormones**) are released directly into the blood stream and **may affect one or several organs** throughout the body.

\* **Hormones are chemical messengers** created by the body. They transfer information from one set of cells to another to coordinate the functions of different parts of the body.

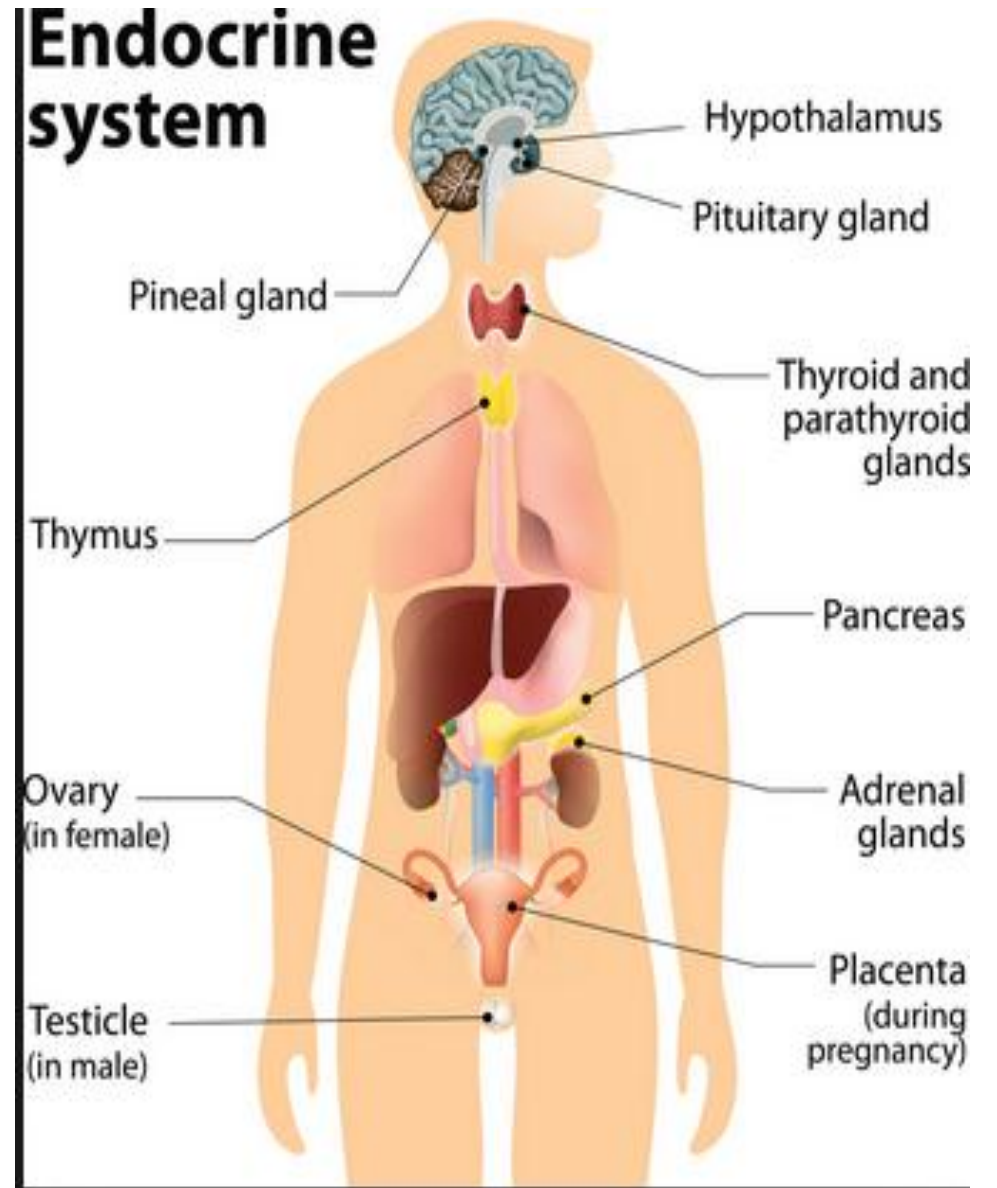




# Regulation of the Endocrine System

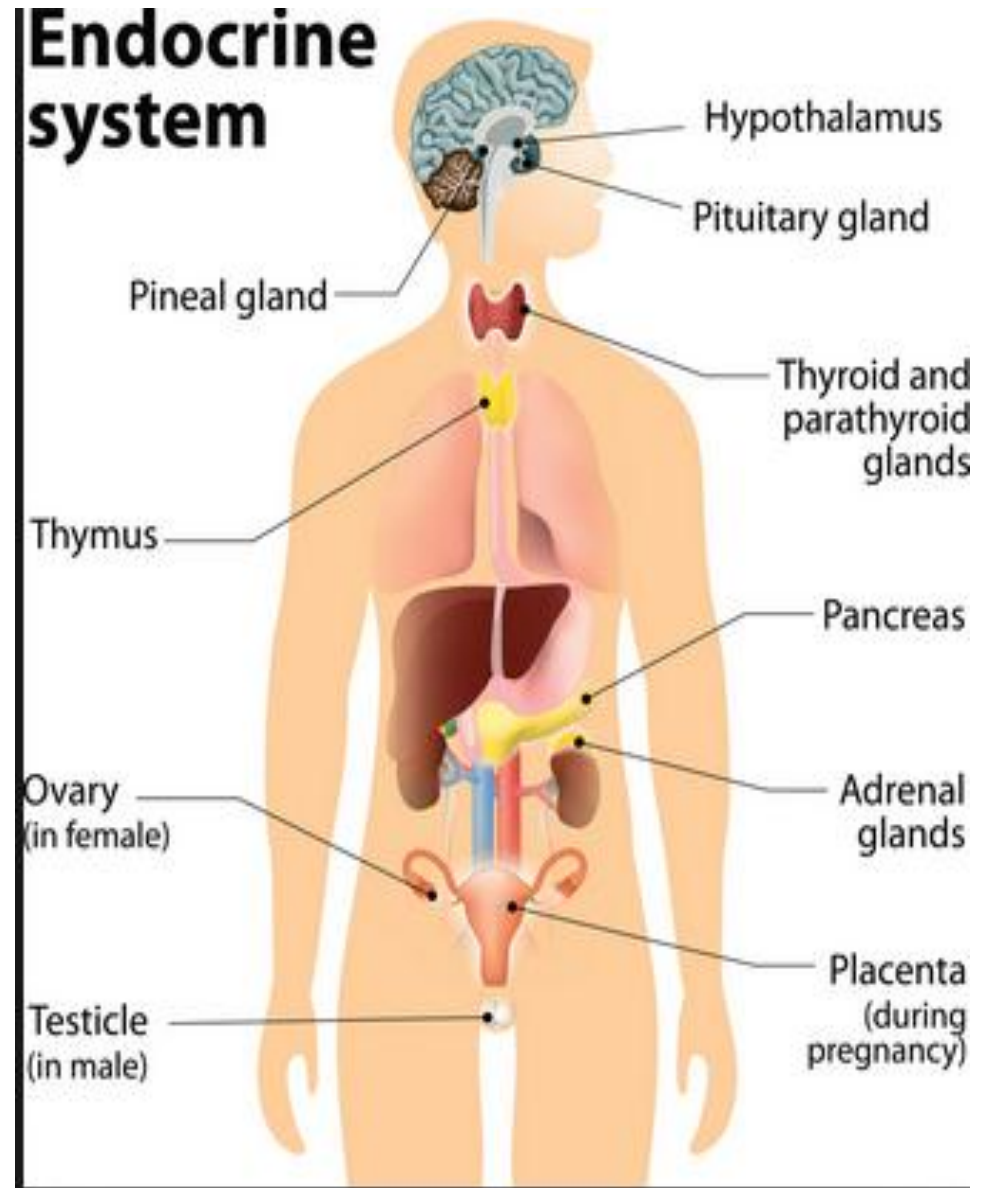
\* The endocrine system is regulated by a **feedback mechanism** which is similar to the action of the **thermostat** that regulates the temperature in a room.

\* For the hormones that are regulated by the **pituitary gland**, a signal is sent from the **hypothalamus** to the pituitary gland in the form of a **"releasing hormone"** which stimulates the pituitary to secrete a **"stimulating hormone"** into the circulation.



# Regulation of the Endocrine System

- \* The stimulating hormone then signaling the **target gland** to secrete its **hormone**.
- \* As the level of this hormone rises in the circulation, the **hypothalamus and the pituitary gland** shut down the secretion of the releasing hormone and the stimulating hormone, which in turn slows the secretion by the target gland.
- \* This system results in stable blood concentrations of the hormones that are regulated by the pituitary gland.



**Hypothalamus**

**Thyroid Stimulating Hormone (TSH) releasing factor**

**Thyroid Stimulating Hormone (TSH) inhibiting factor**

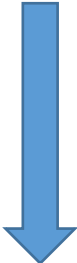
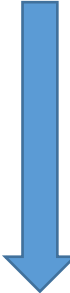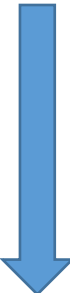**Pituitary Gland**

**Pituitary Gland**

**Thyroid Stimulating Hormone (TSH)**

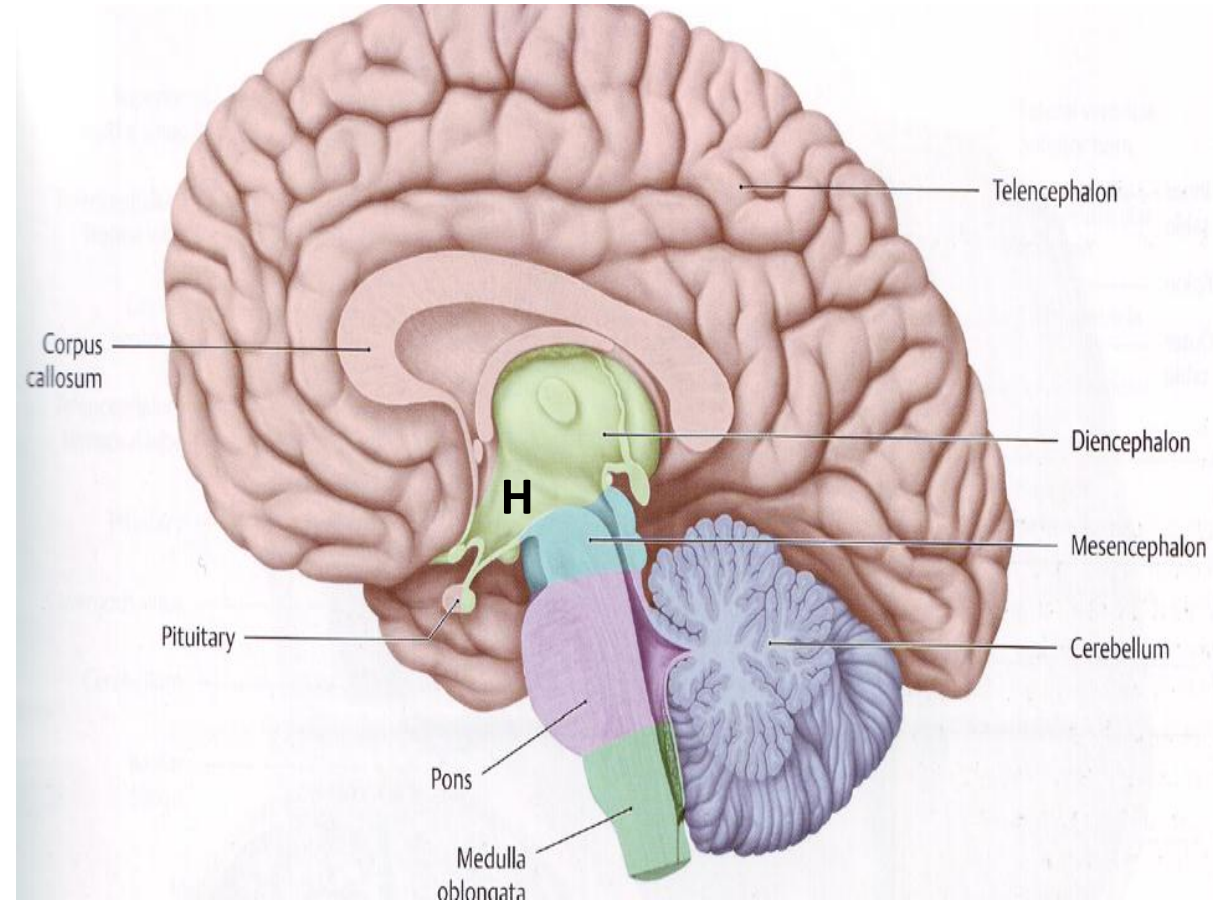
**Thyroid Gland**

**Thyroid Hormones**



# The Hypothalamus

- The hypothalamus is a small part in the brain ( part of diencephalon), located inferior to the thalamus, in the lower central part of the brain.
- Functions:
  1. Regulation of satiety, metabolism & body temperature.
  2. Secretion of hormones that stimulate or suppress the release of the hormones of the pituitary gland.

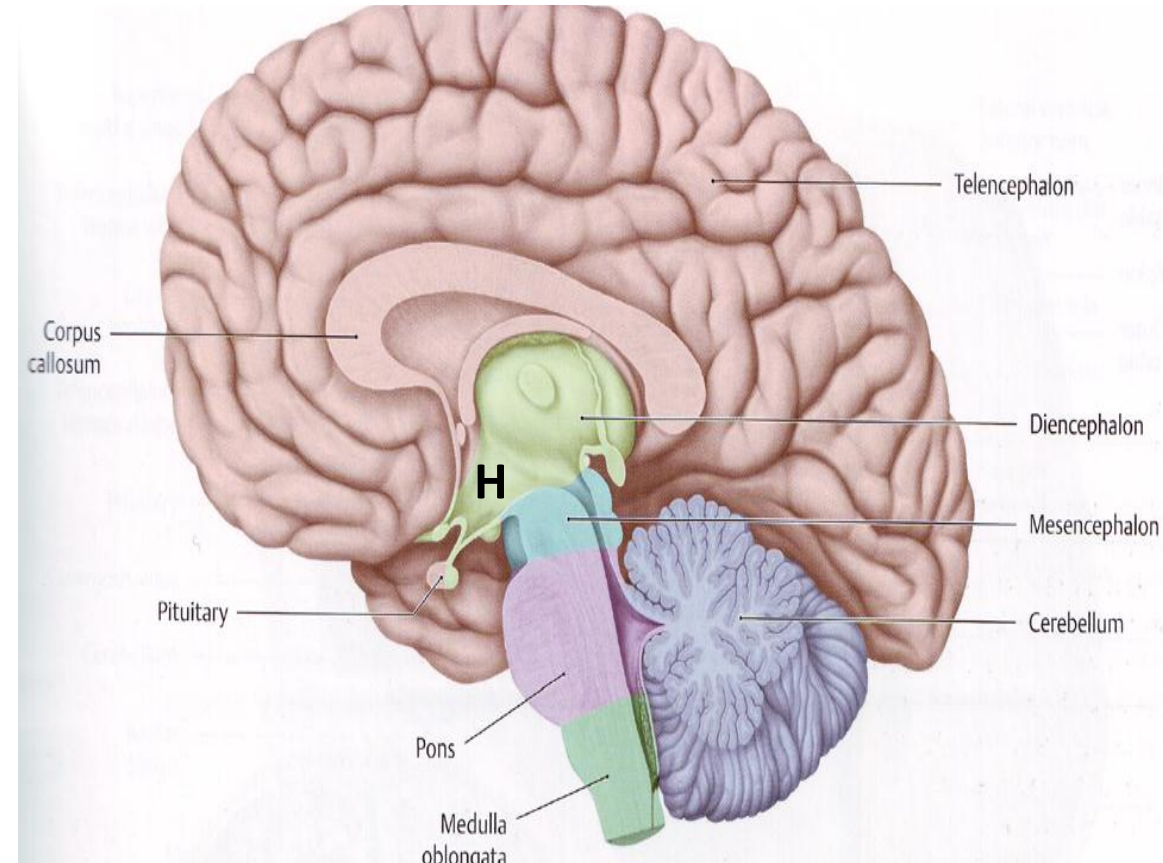




# The Hypothalamus

- Many of these hormones are releasing hormones, which are secreted into an artery (the hypophyseal portal system) that carries them directly to the pituitary gland.
- In the pituitary gland, these releasing hormones signal secretion of stimulating hormones.

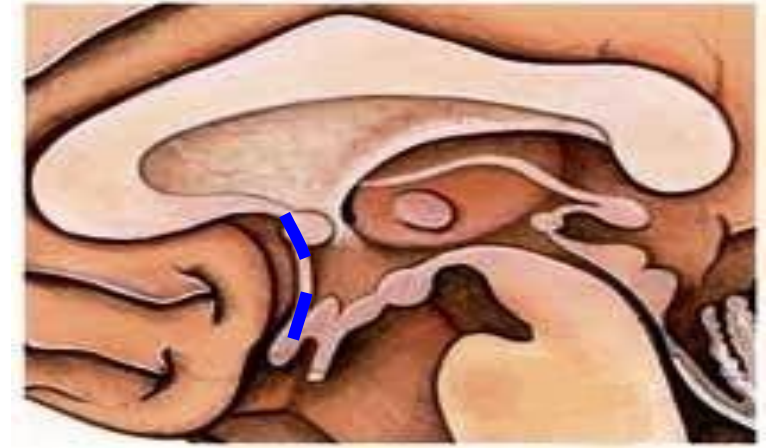
**3. The activities of the endocrine system and the autonomic nervous system on the target organ (the specific structure acted on by a hormone) are integrated and coordinated by the hypothalamus.**



# HYPOTHALAMUS

## Extent

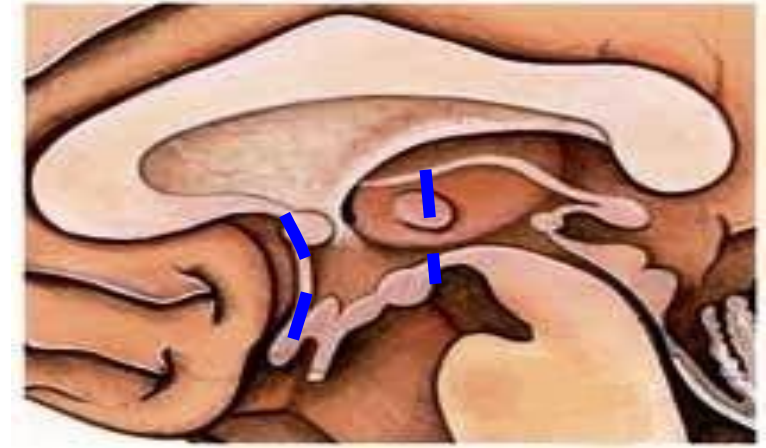
- **Ant:** lamina terminalis



# HYPOTHALAMUS

## Extent

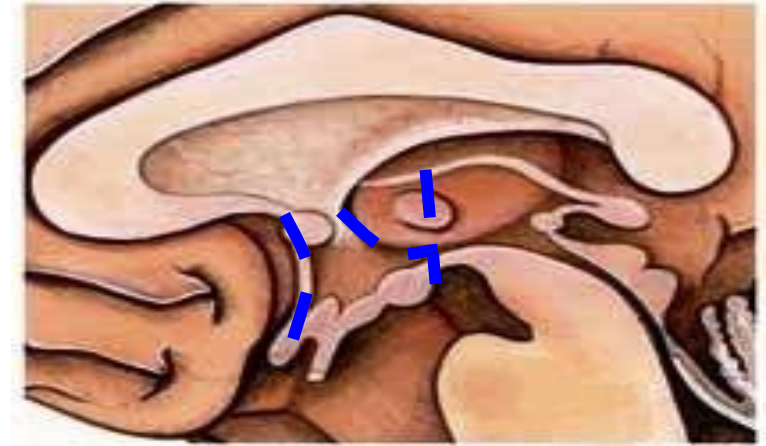
- **Ant:** lamina terminalis
- **Post:** plane post to mammillary bodies



# HYPOTHALAMUS

## Extent

- **Ant:** lamina terminalis
- **Post:** plane post to mammillary bodies
- **Sup:** hypothalamic sulcus.

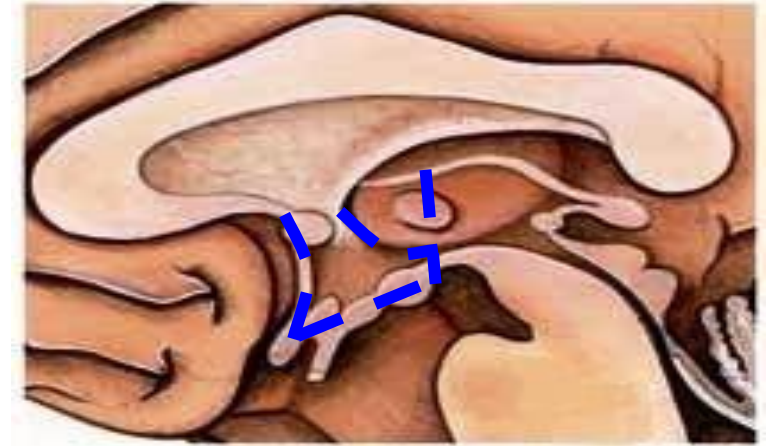



# HYPOTHALAMUS

## Extent

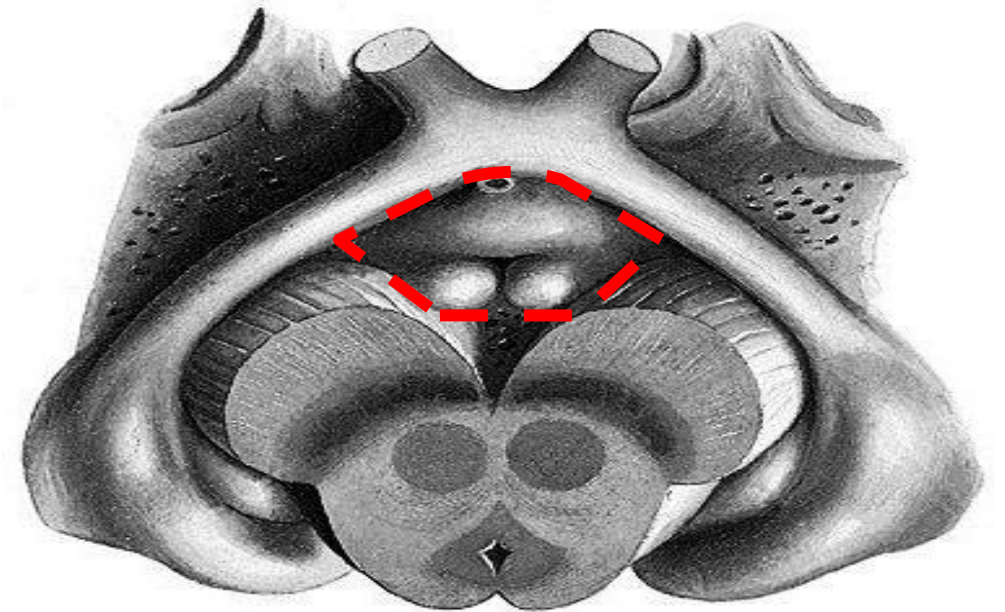
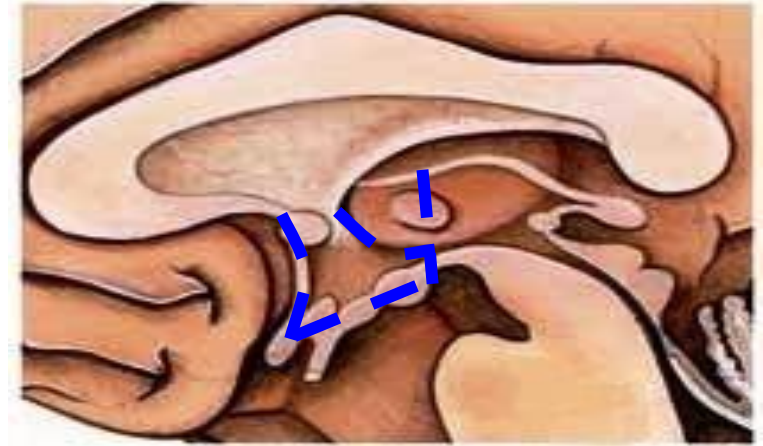
- **Ant:** lamina terminalis
- **Post:** plane post to mammillary bodies
- **Sup:** hypothalamic sulcus.
- **Inf:**
  - floor of 3<sup>rd</sup> ventricle



# HYPOTHALAMUS

## Extent

- **Ant:** lamina terminalis
- **Post:** plane post to mammillary bodies
- **Sup:** hypothalamic sulcus.
- **Inf:**
  - floor of 3<sup>rd</sup> ventricle
  - interpeduncular fossa

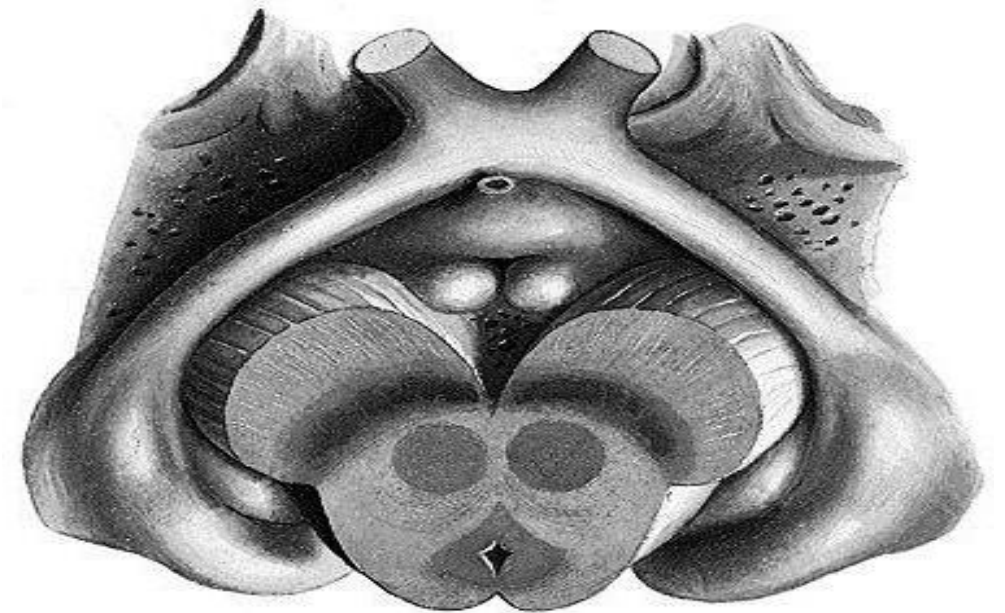
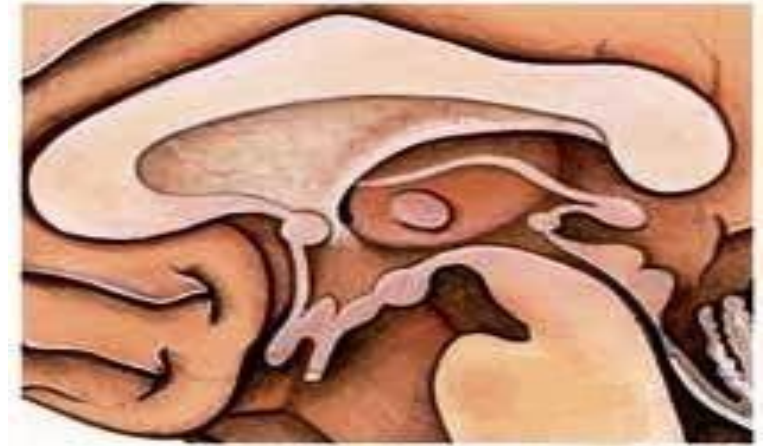

# HYPOTHALAMUS

## Extent

- **Ant:** lamina terminalis
- **Post:** plane post to mammillary bodies
- **Sup:** hypothalamic sulcus.
- **Inf:**
  - floor of 3<sup>rd</sup> ventricle
  - interpeduncular fossa

**3 parts** (anteroposteriorly)



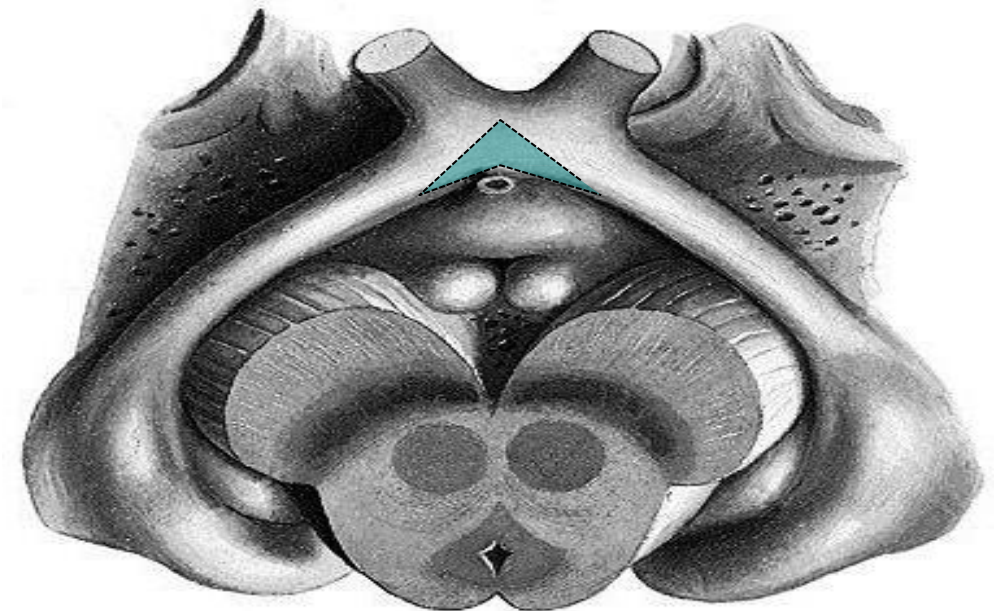
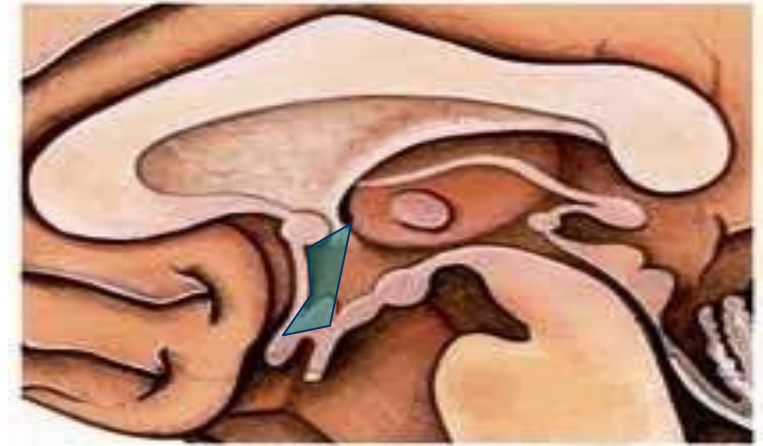# HYPOTHALAMUS

## Extent

- **Ant:** lamina terminalis
- **Post:** plane post to mammillary bodies
- **Sup:** hypothalamic sulcus.
- **Inf:**
  - floor of 3<sup>rd</sup> ventricle
  - interpeduncular fossa

## 3 parts (anteroposteriorly)

- Optic part





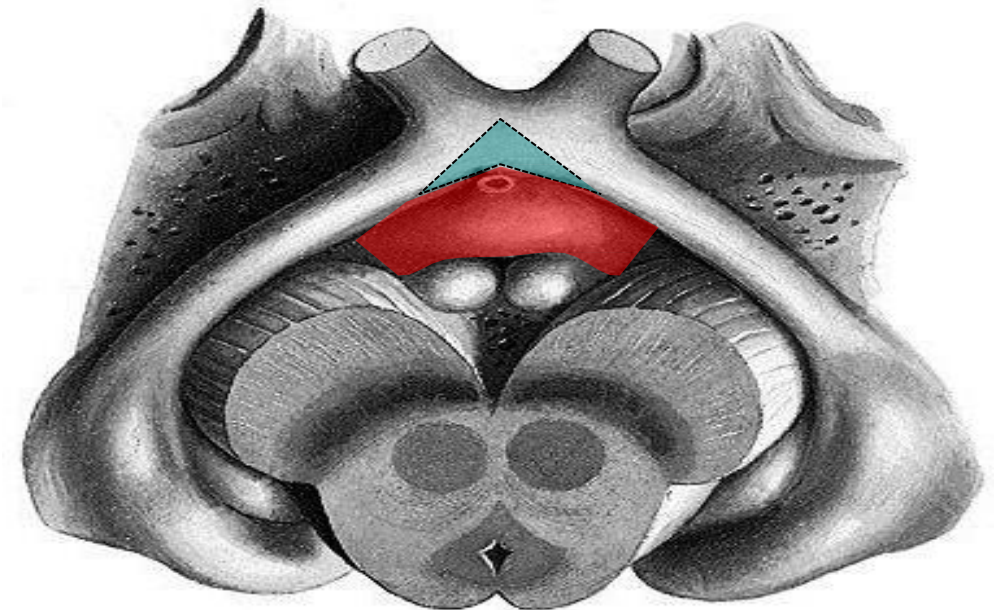
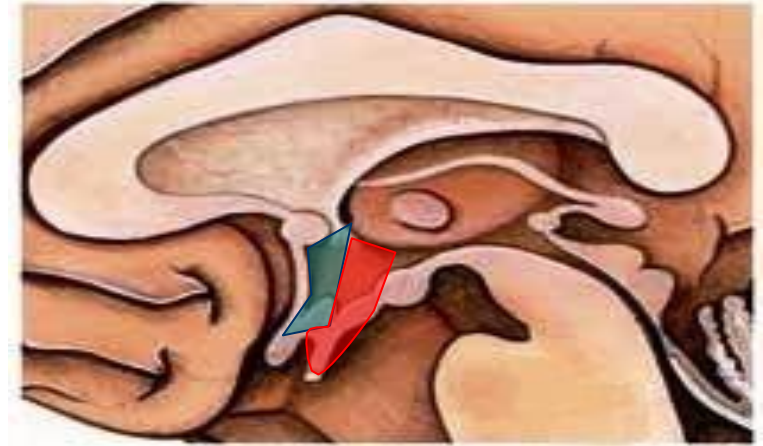# HYPOTHALAMUS

## Extent

- **Ant:** lamina terminalis
- **Post:** plane post to mammillary bodies
- **Sup:** hypothalamic sulcus.
- **Inf:**
  - floor of 3<sup>rd</sup> ventricle
  - interpeduncular fossa

## 3 parts (anteroposteriorly)

- Optic part
- Tuberal part



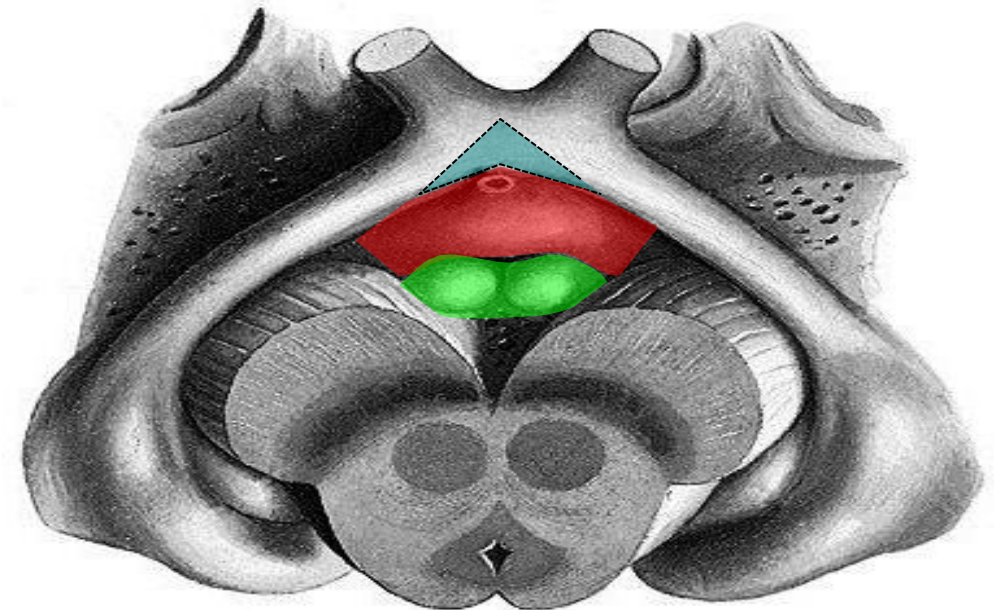
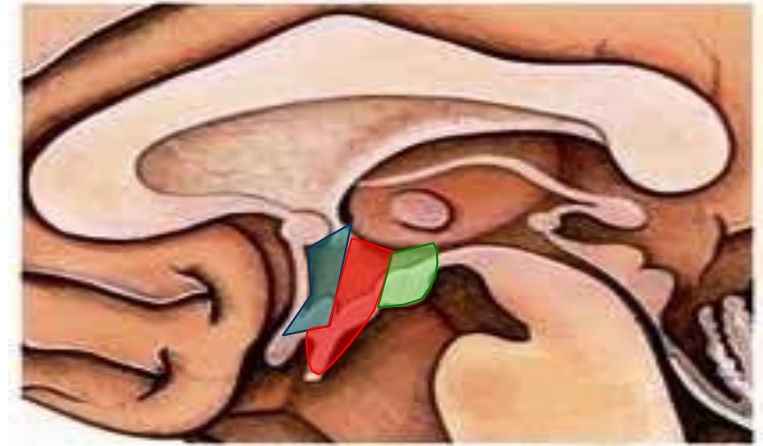# HYPOTHALAMUS

## Extent

- **Ant:** lamina terminalis
- **Post:** plane post to mammillary bodies
- **Sup:** hypothalamic sulcus.
- **Inf:**
  - floor of 3<sup>rd</sup> ventricle
  - interpeduncular fossa

## 3 parts (anteroposteriorly)

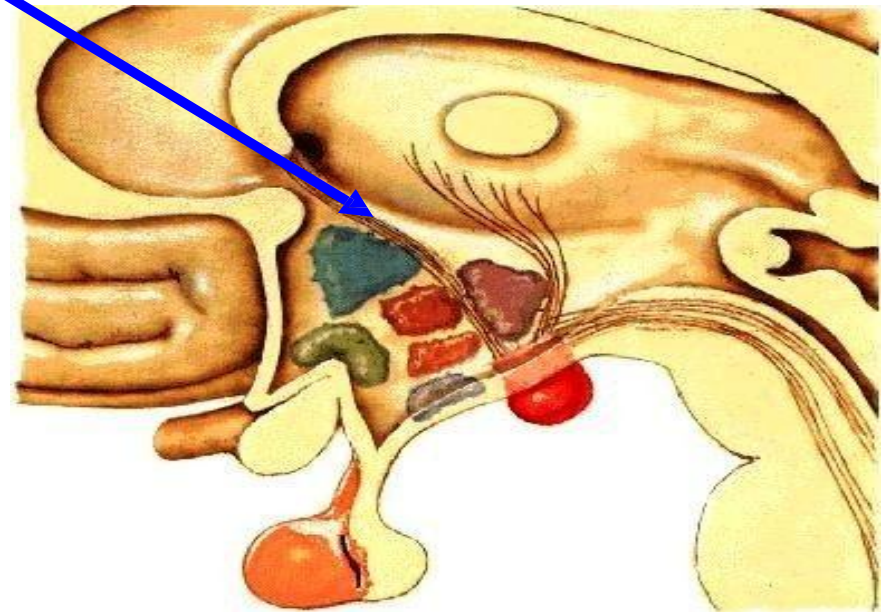
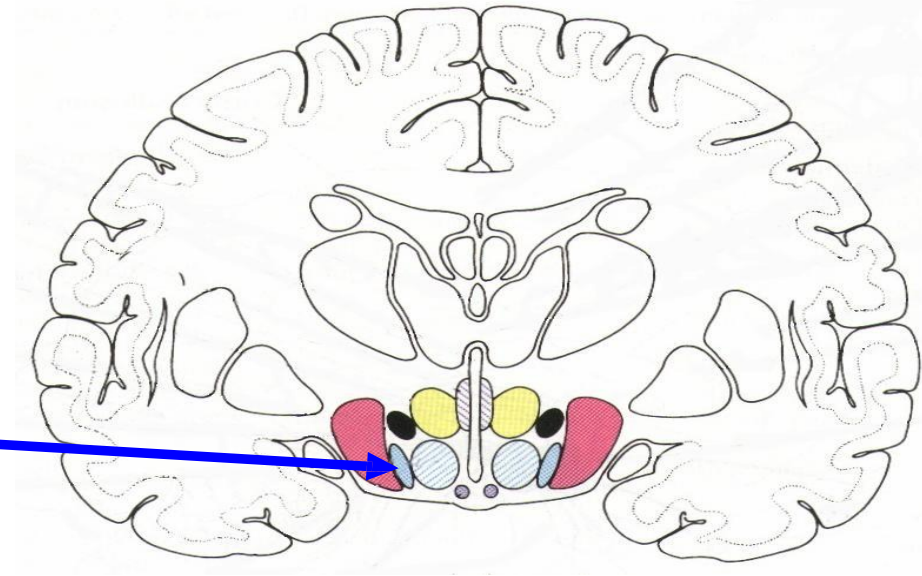
- Optic part
- Tuberal part
- Mammillary part



3 zones

**3 zones**

column of fornix traversing

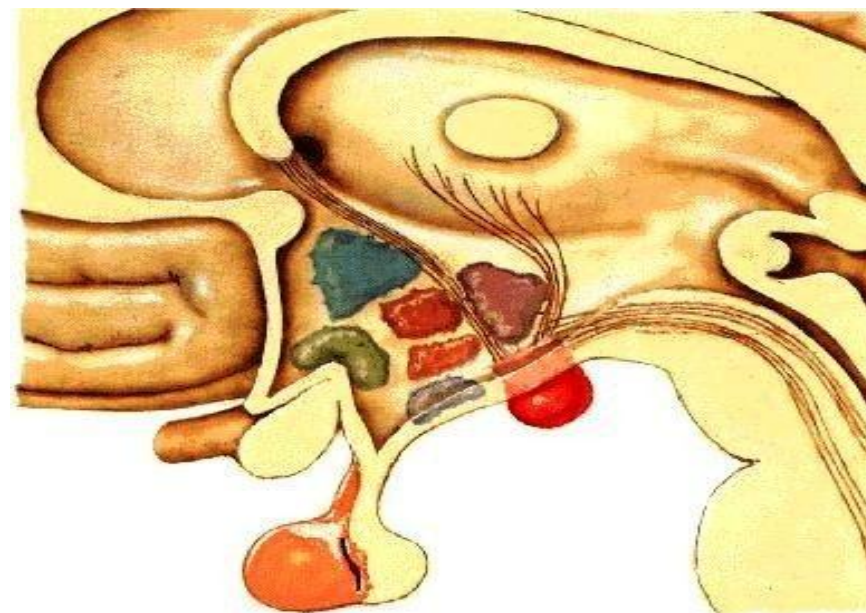
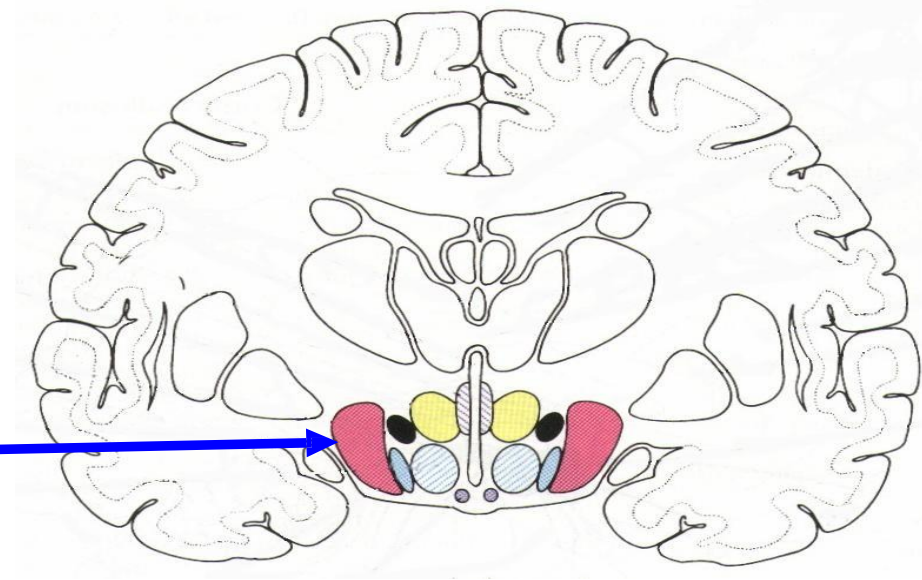




## 3 zones

column of fornix traversing

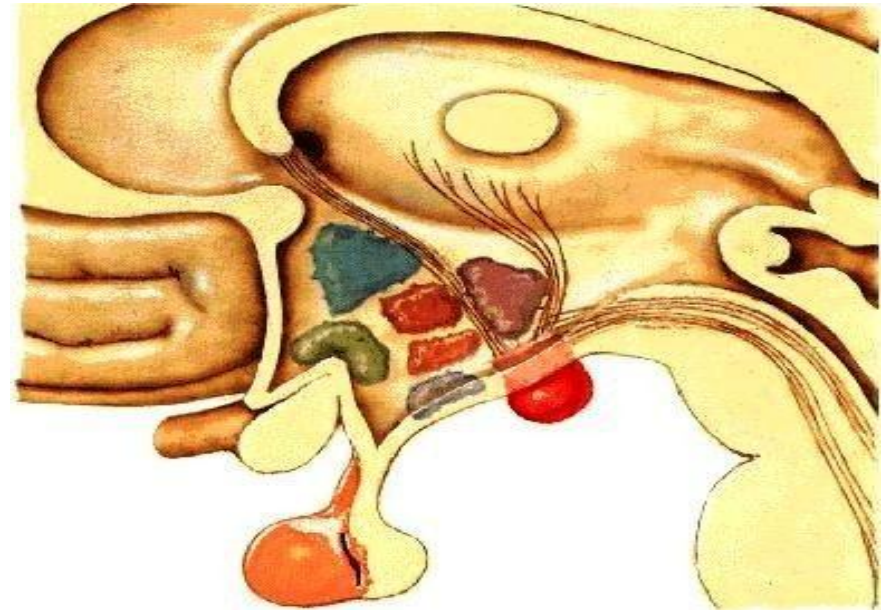
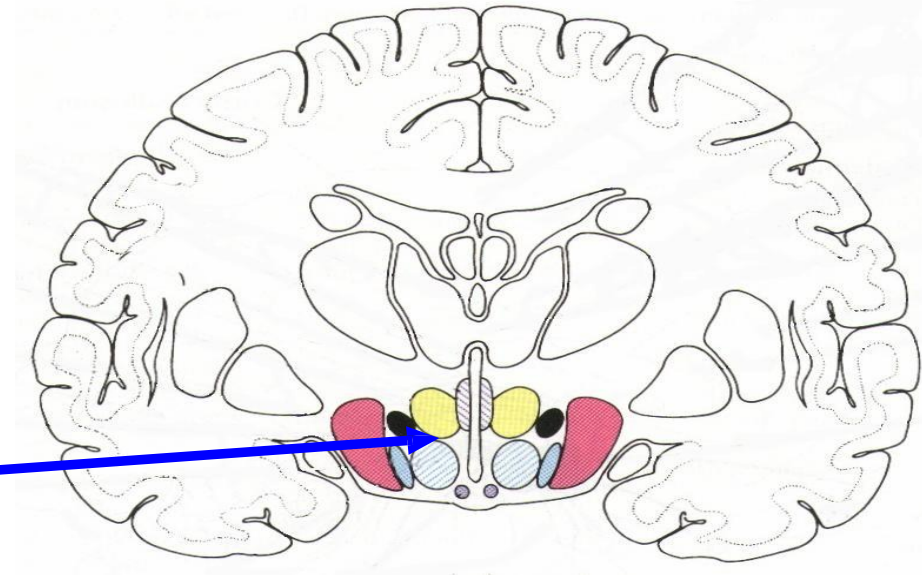
- lat zone



## 3 zones

column of fornix traversing

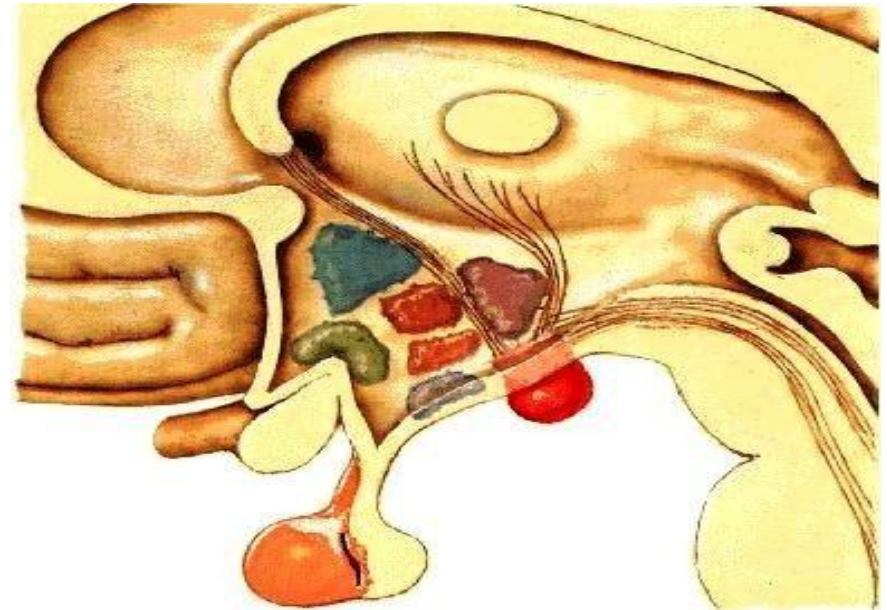
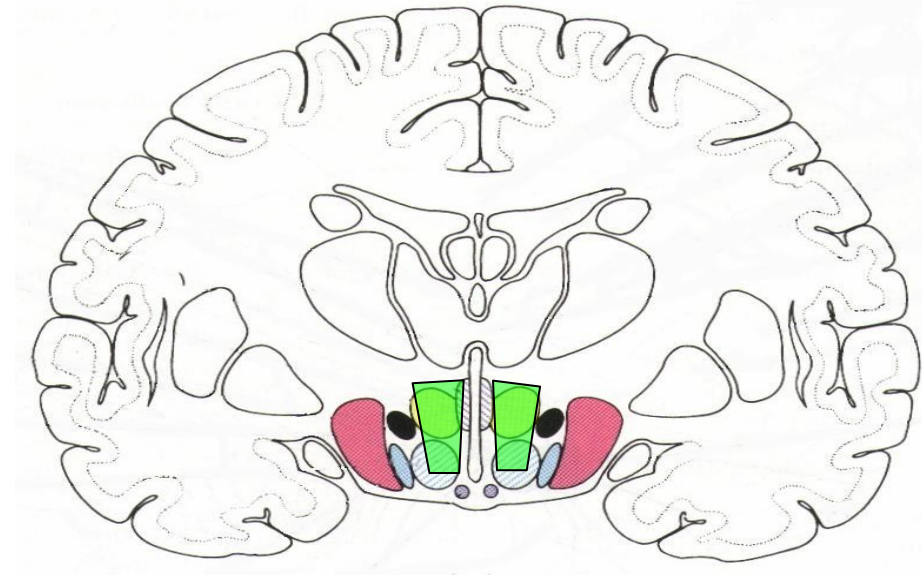
- lat zone
- med zone



## 3 zones

column of fornix traversing

- lat zone
- med zone
  - periventricular zone

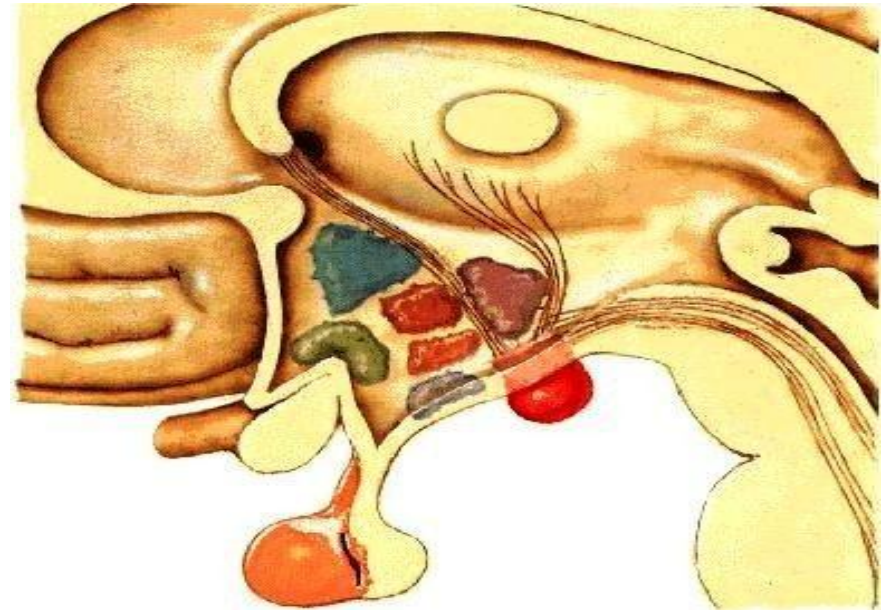
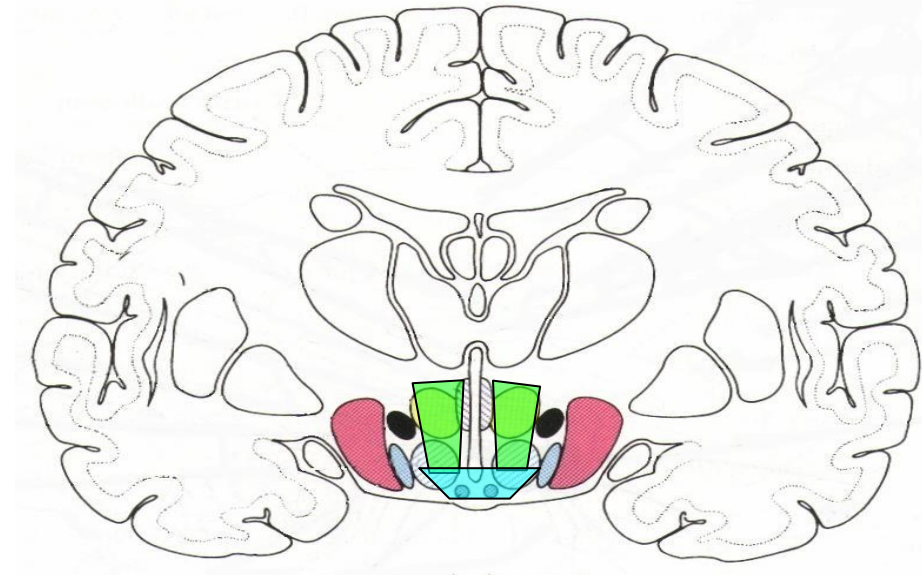




## 3 zones

column of fornix traversing

- lat zone
- med zone
  - periventricular zone
  - intermediate zone



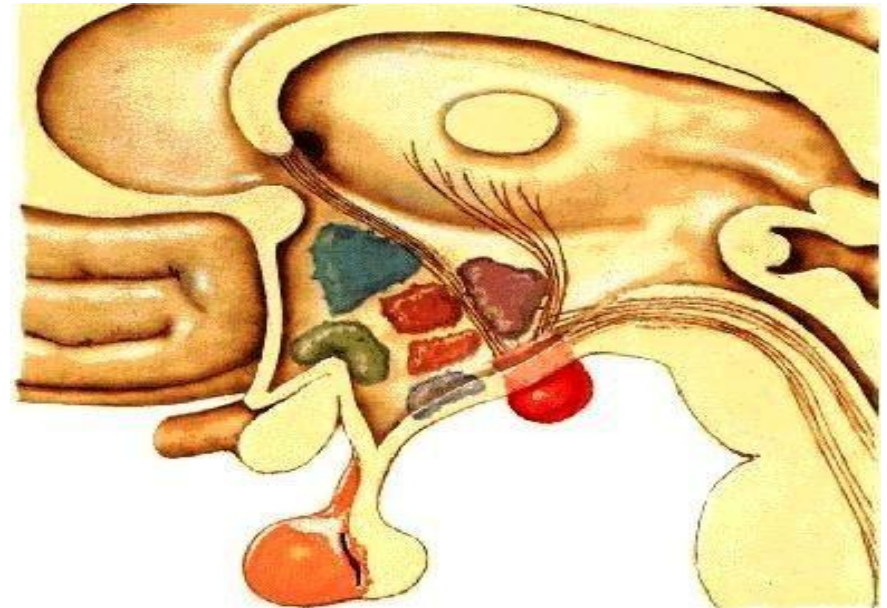
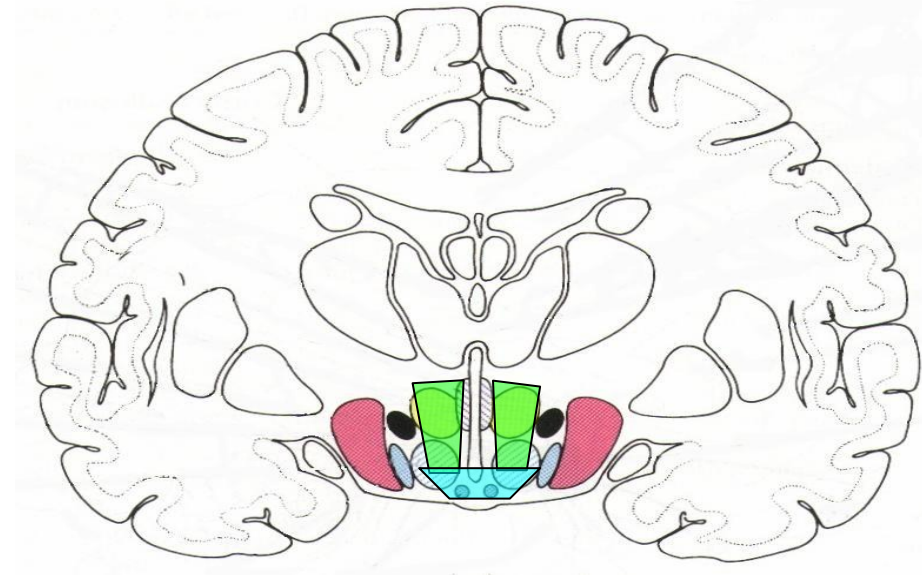


## 3 zones

column of fornix traversing

- lat zone
- med zone
  - periventricular zone
  - intermediate zone

## important nuclei



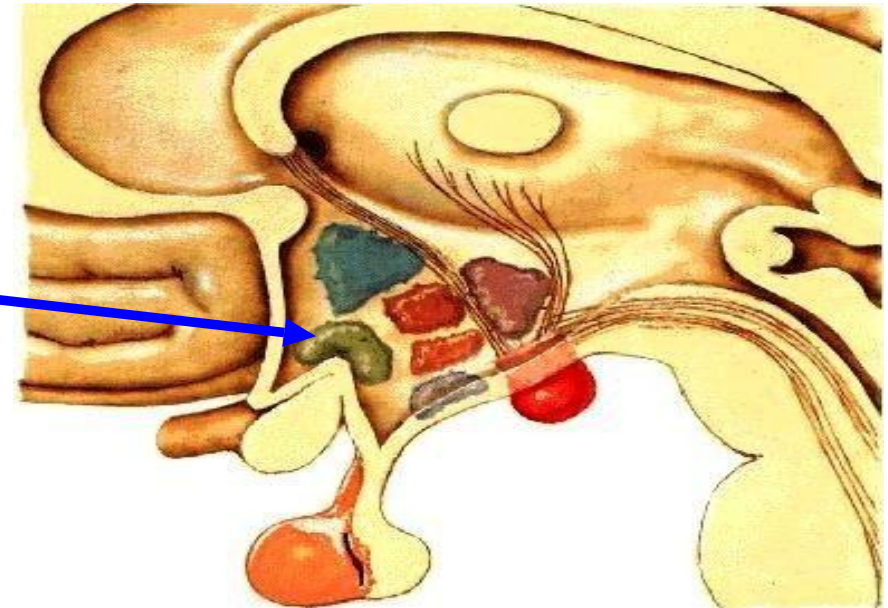
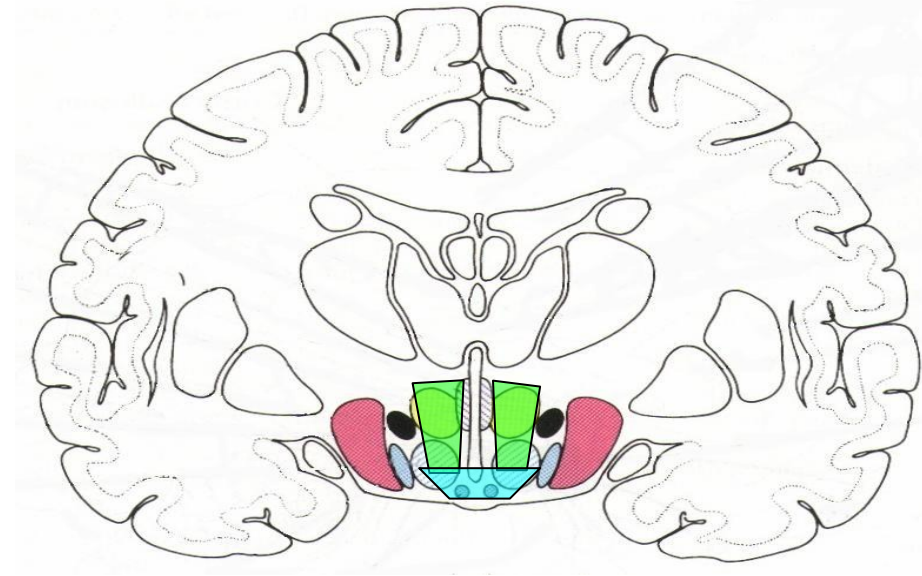
## 3 zones

column of fornix traversing

- lat zone
- med zone
  - periventricular zone
  - intermediate zone

## important nuclei

- supraoptic



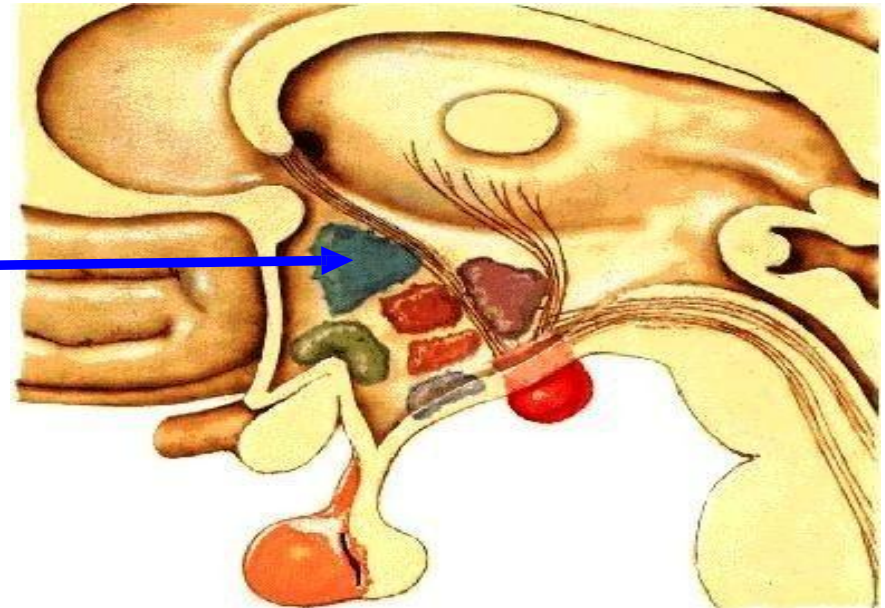
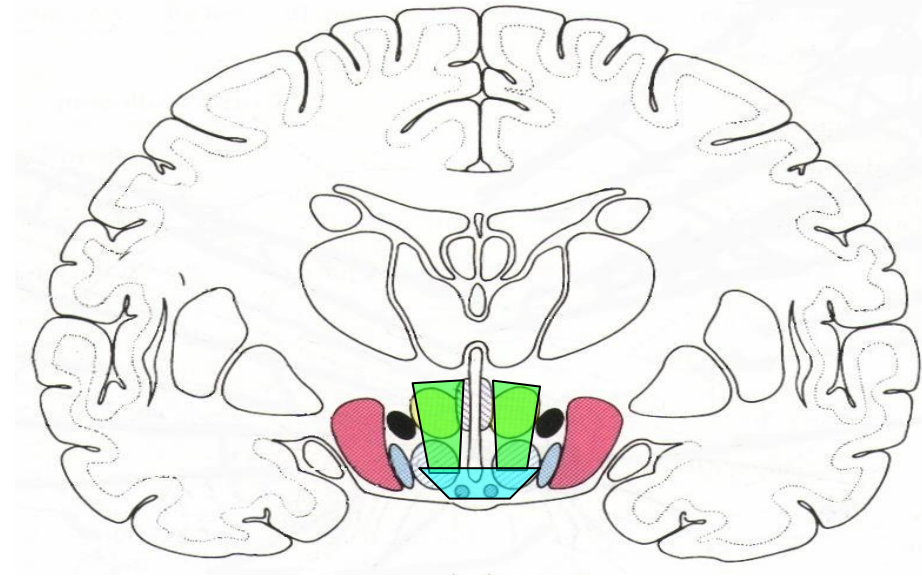
## 3 zones

column of fornix traversing

- lat zone
- med zone
  - periventricular zone
  - intermediate zone

## important nuclei

- supraoptic
- paraventricular





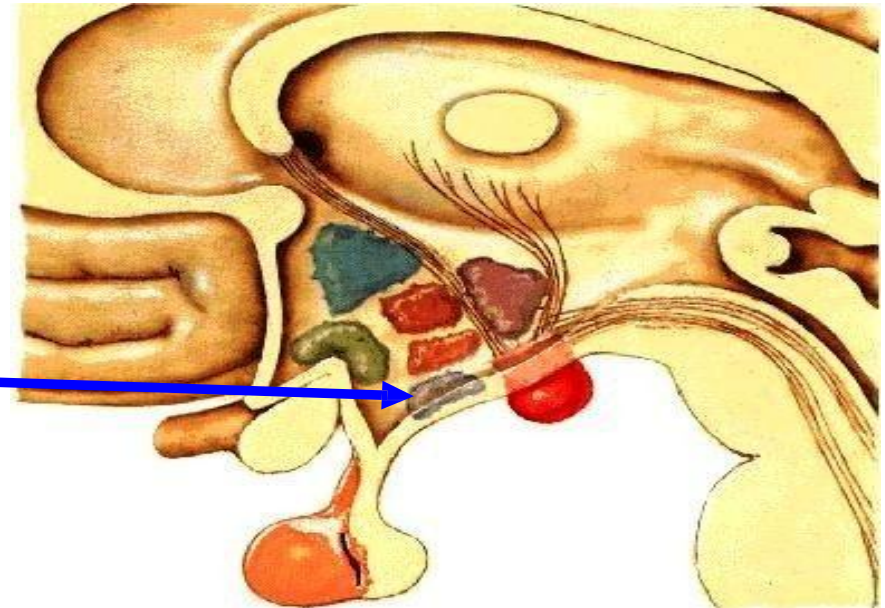
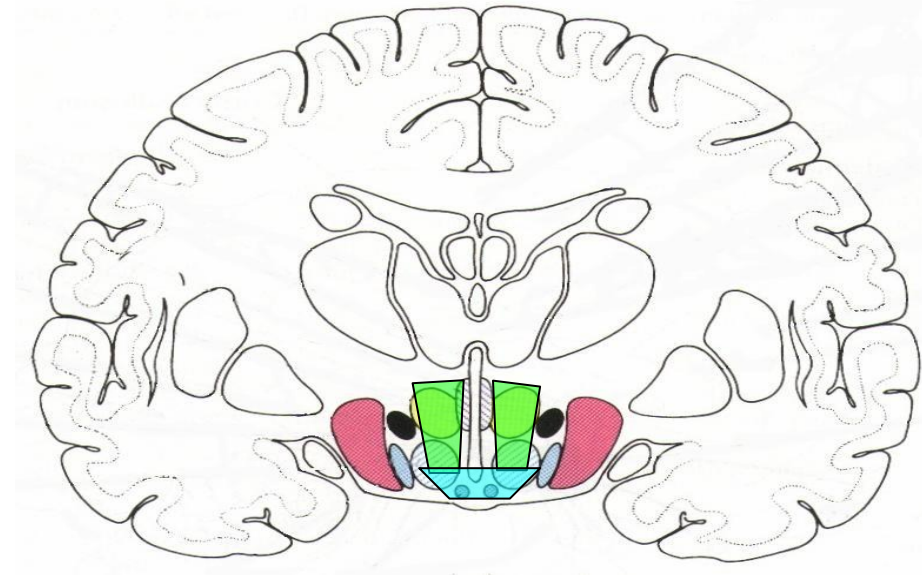
## 3 zones

column of fornix traversing

- lat zone
- med zone
  - periventricular zone
  - intermediate zone

## important nuclei

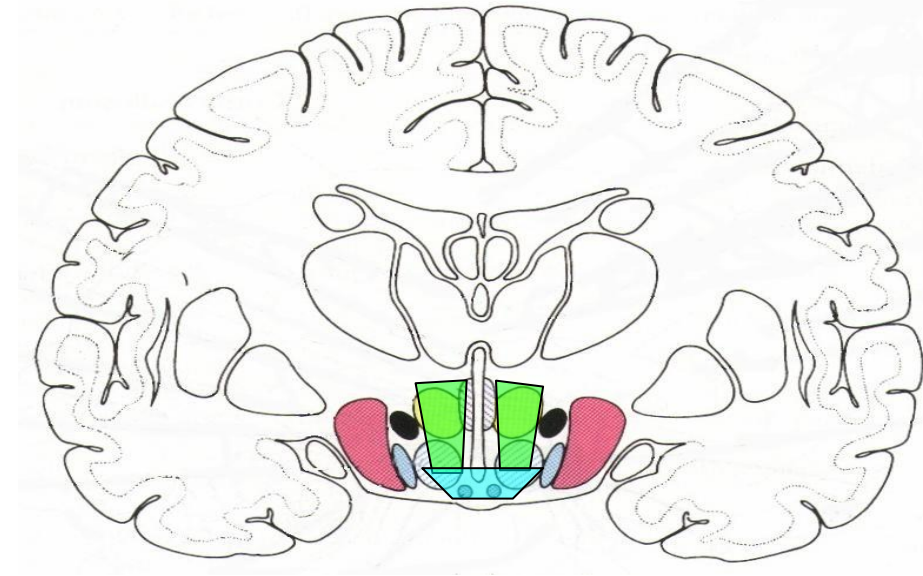
- supraoptic
- paraventricular
- arcuate



## 3 zones

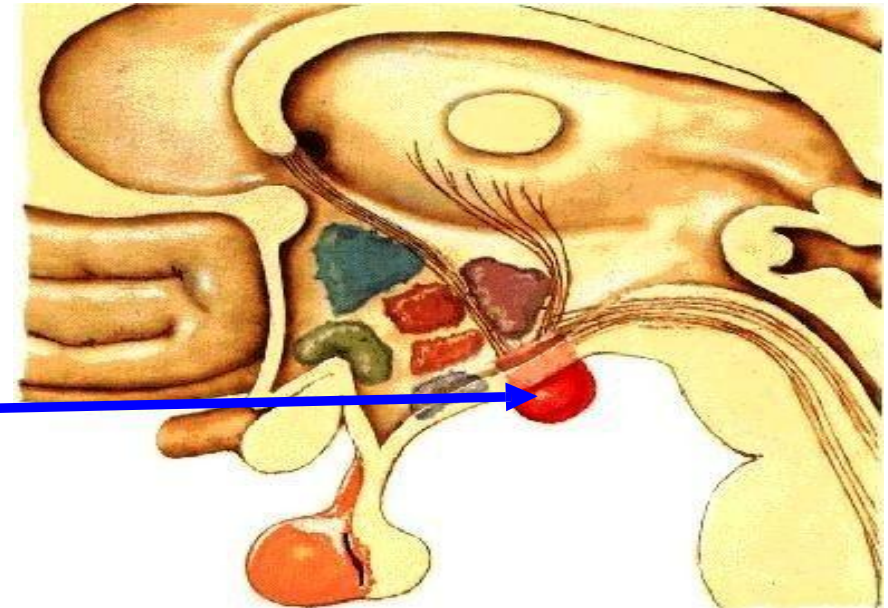
column of fornix traversing

- lat zone
- med zone
  - periventricular zone
  - intermediate zone



## important nuclei

- supraoptic
- paraventricular
- arcuate
- mammillary

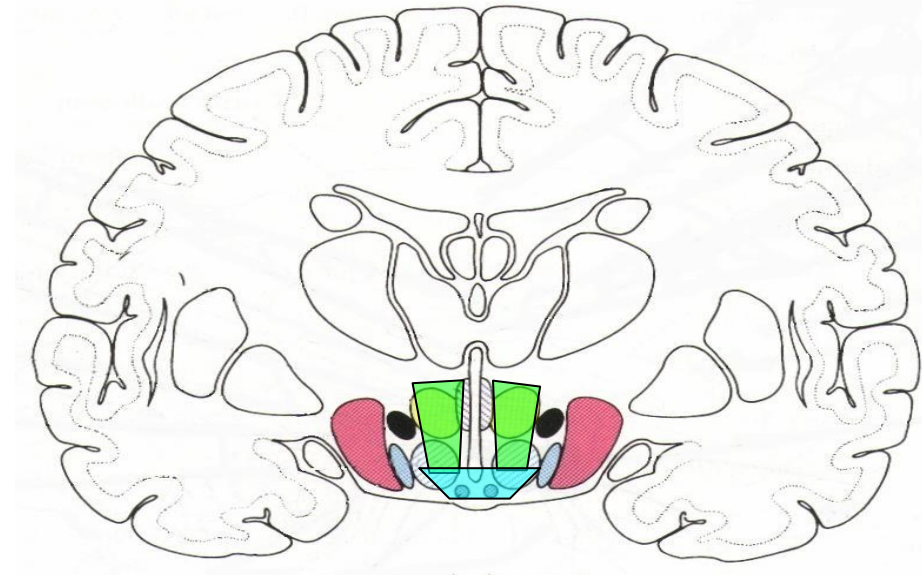




## 3 zones

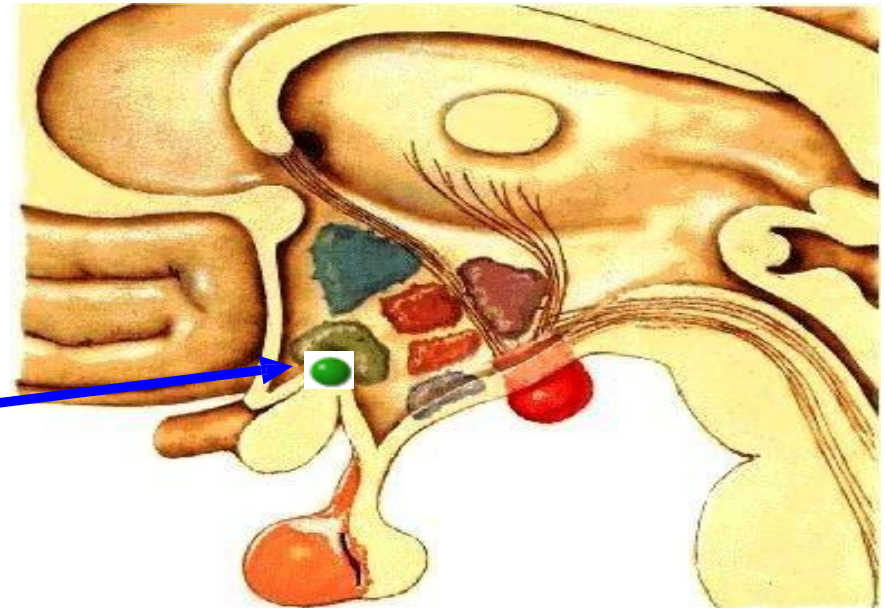
column of fornix traversing

- lat zone
- med zone
  - periventricular zone
  - intermediate zone

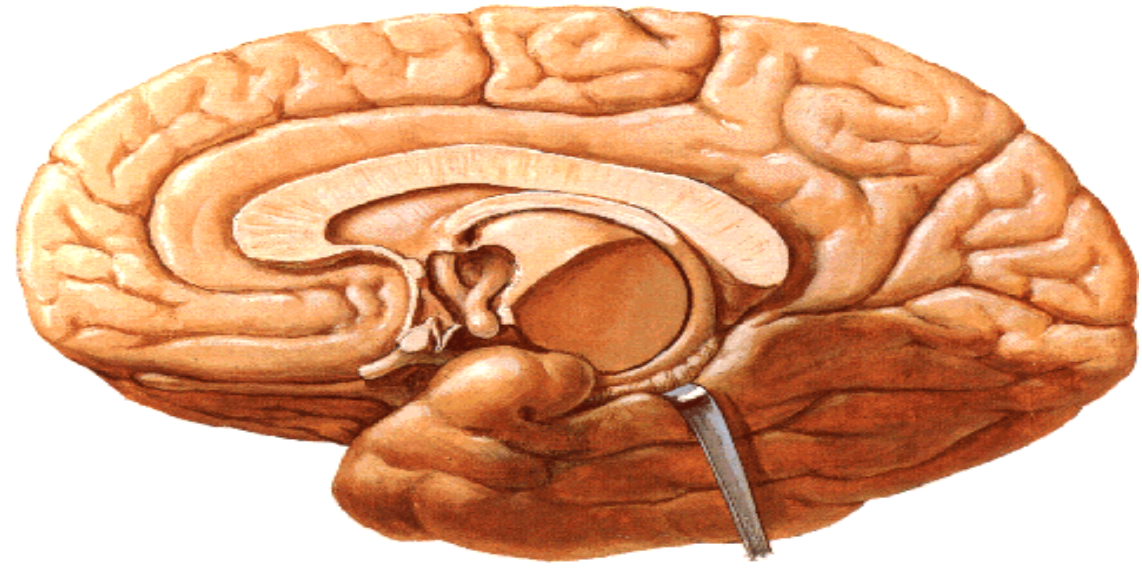


## important nuclei

- supraoptic
- paraventricular
- arcuate
- mammillary
- suprachiasmatic



# Connections



# Connections

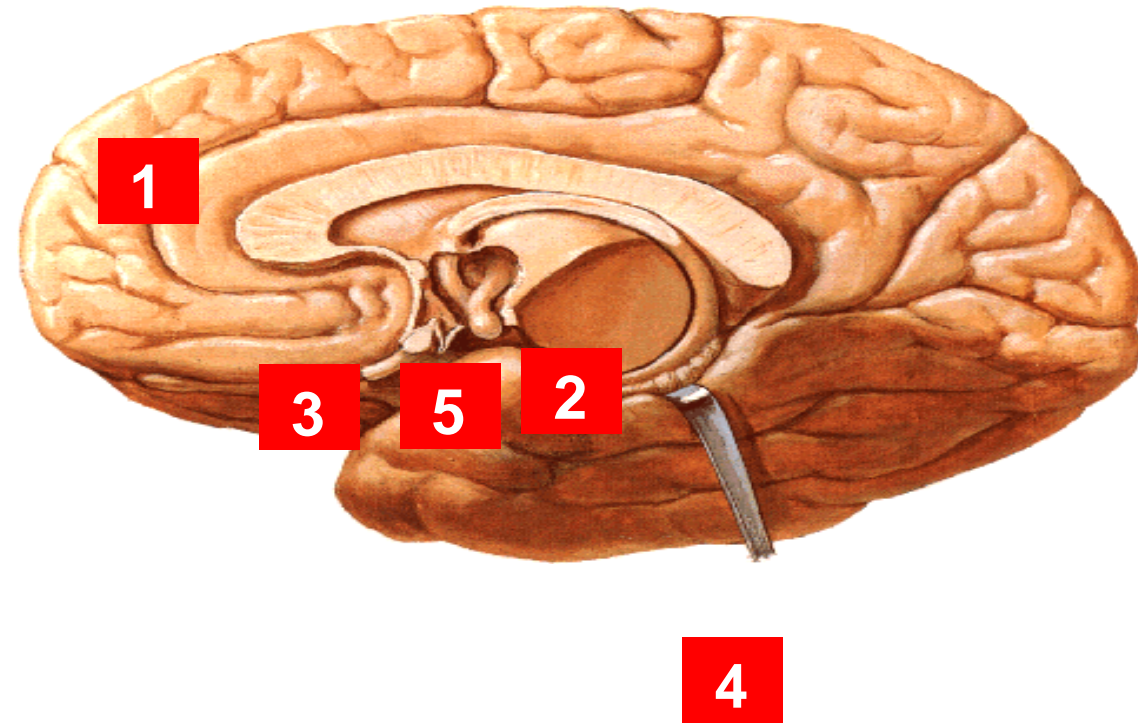
1. **Cortical**

2. **Limbic**

3. **Retinal**

4. **Lower centers**

5. **Pituitary**





# Connections

## 1. Cortical

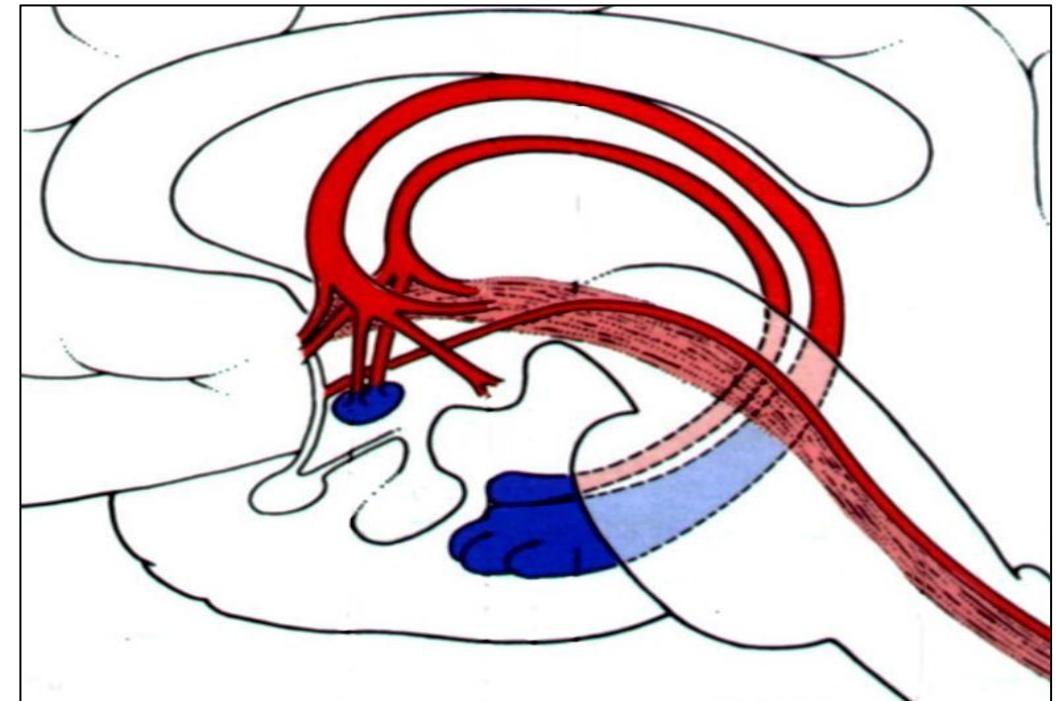
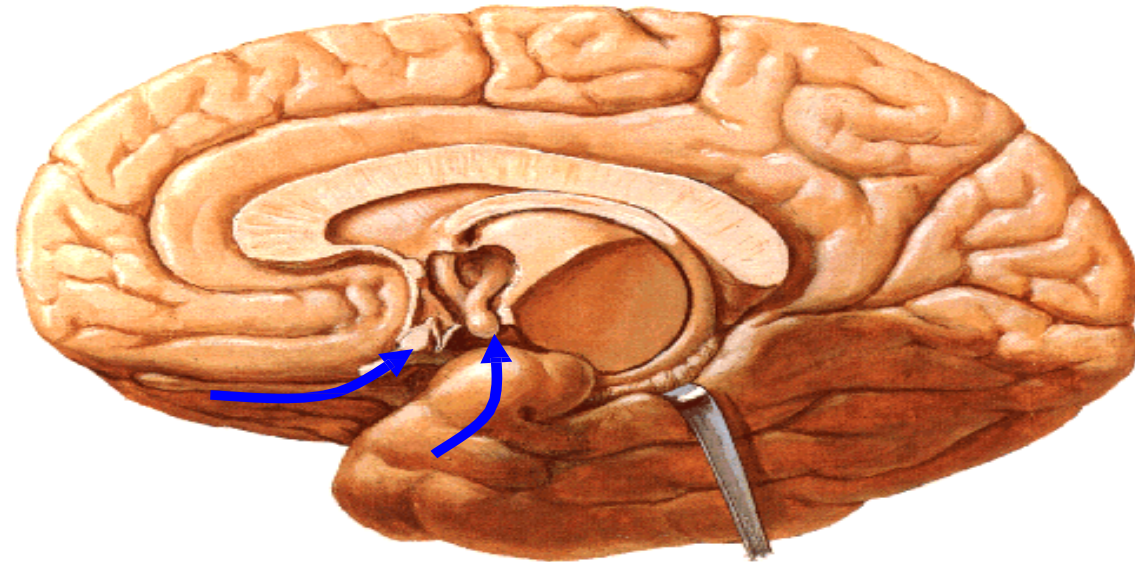
- visceral & olfactory areas  
→autonomic response (past experience)

## 2. Limbic

## 3. Retinal

## 4. Lower centers

## 5. Pituitary





# Connections

## 1. Cortical

- **visceral & olfactory** areas  
→ autonomic response (past experience)

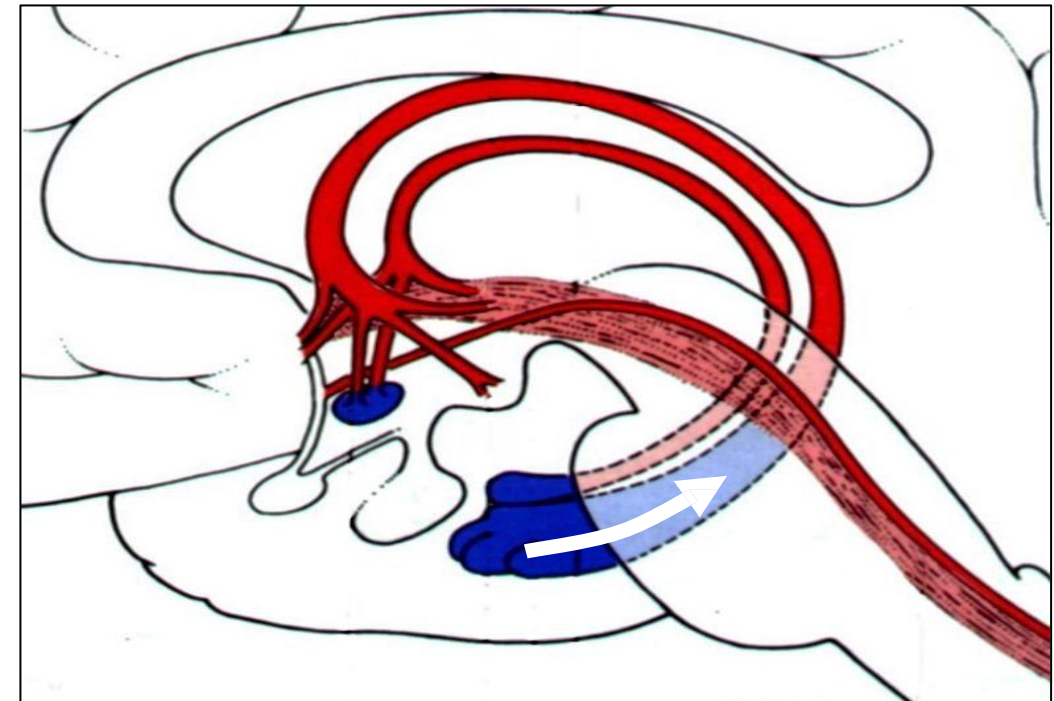
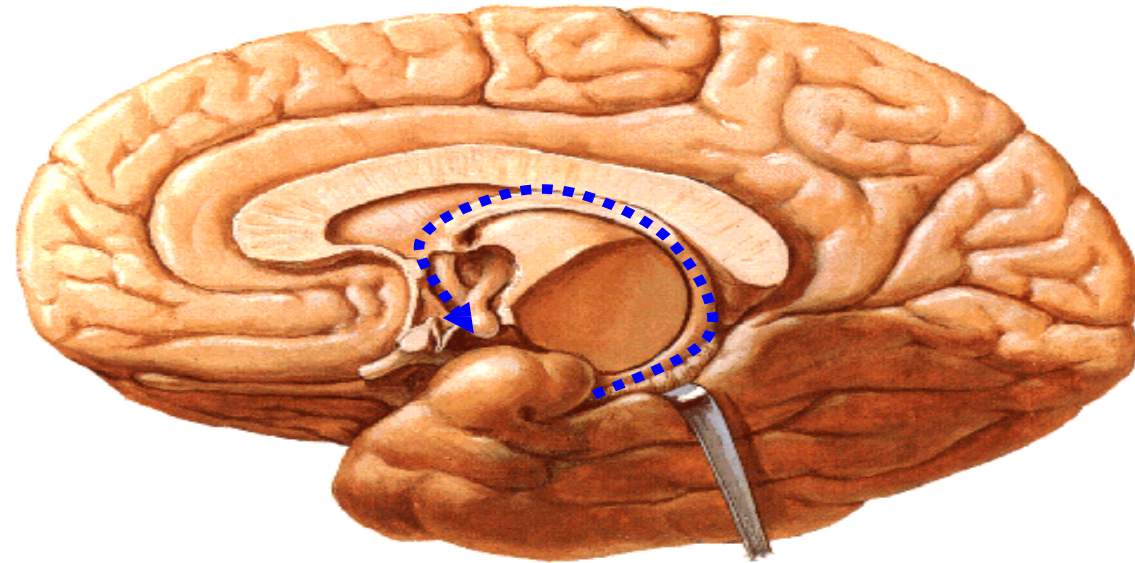
## 2. Limbic

- **Hippocampus** via fornix (Papez circuit)  
→ memory consolidation

## 3. Retinal

## 4. Lower centers

## 5. Pituitary



# Connections

## 1. Cortical

- **visceral & olfactory** areas  
→autonomic response (past experience)

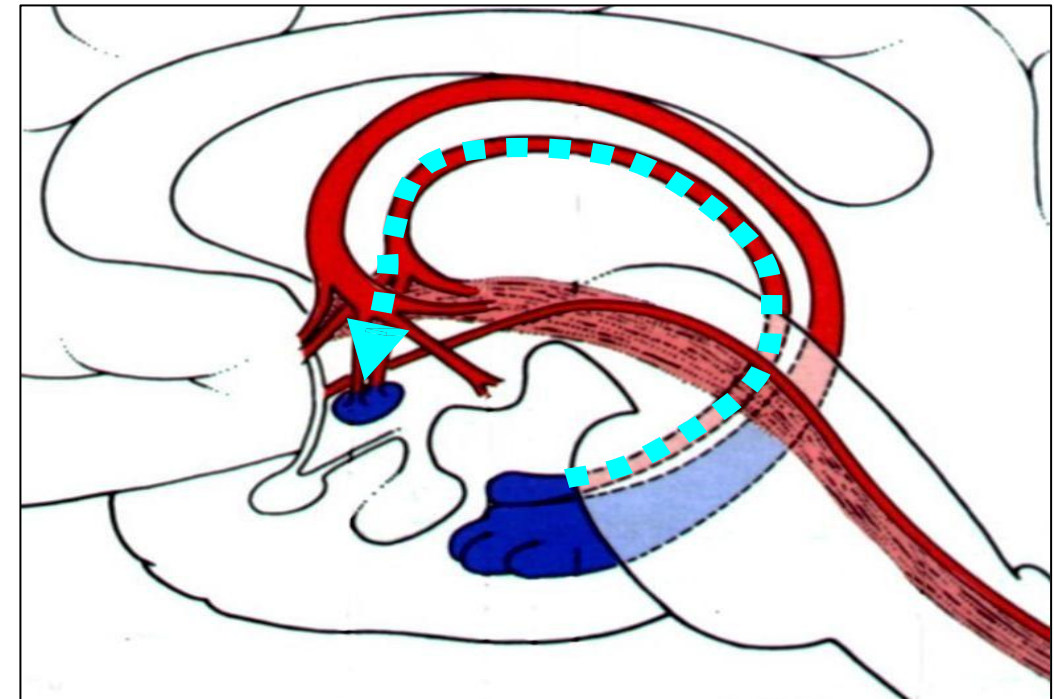
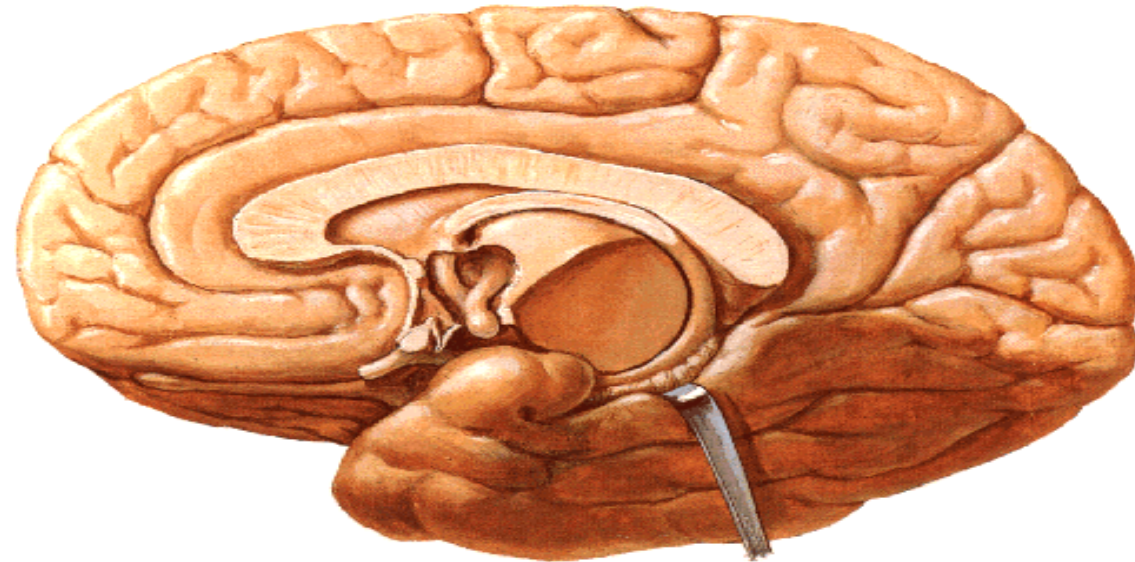
## 2. Limbic

- **Hippocampus** via fornix (Papez circuit)  
→ memory consolidation
- **Amygdala & Septal areas**  
emotions → autonomic reactions

## 3. Retinal

## 4. Lower centers

## 5. Pituitary





# Connections

## 1. Cortical

- **visceral & olfactory** areas  
→autonomic response (past experience)

## 2. Limbic

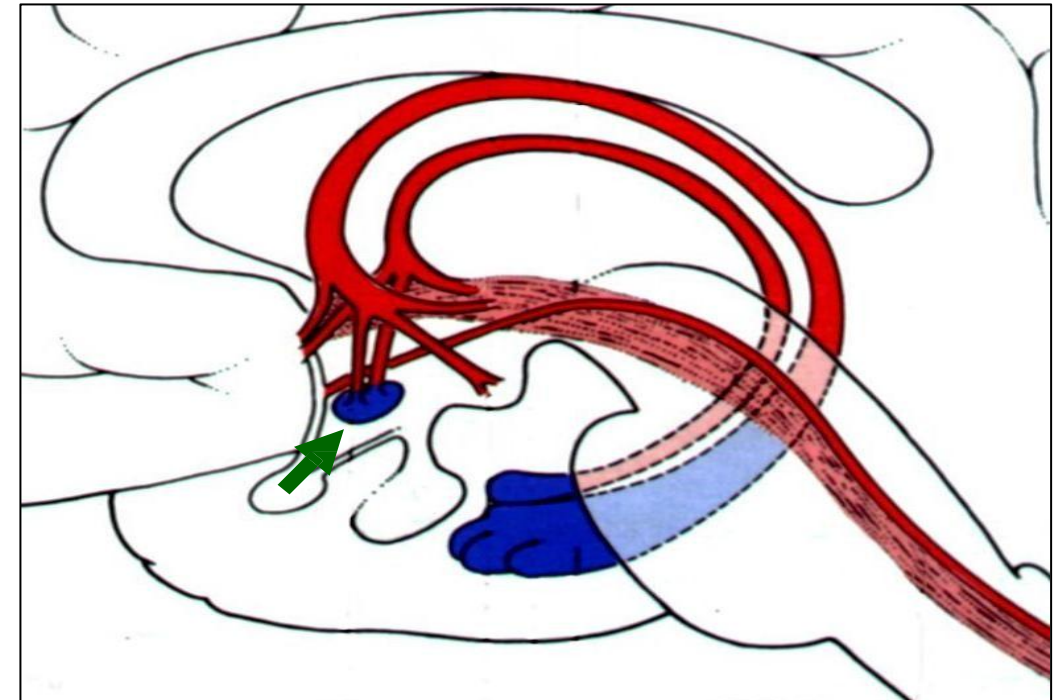
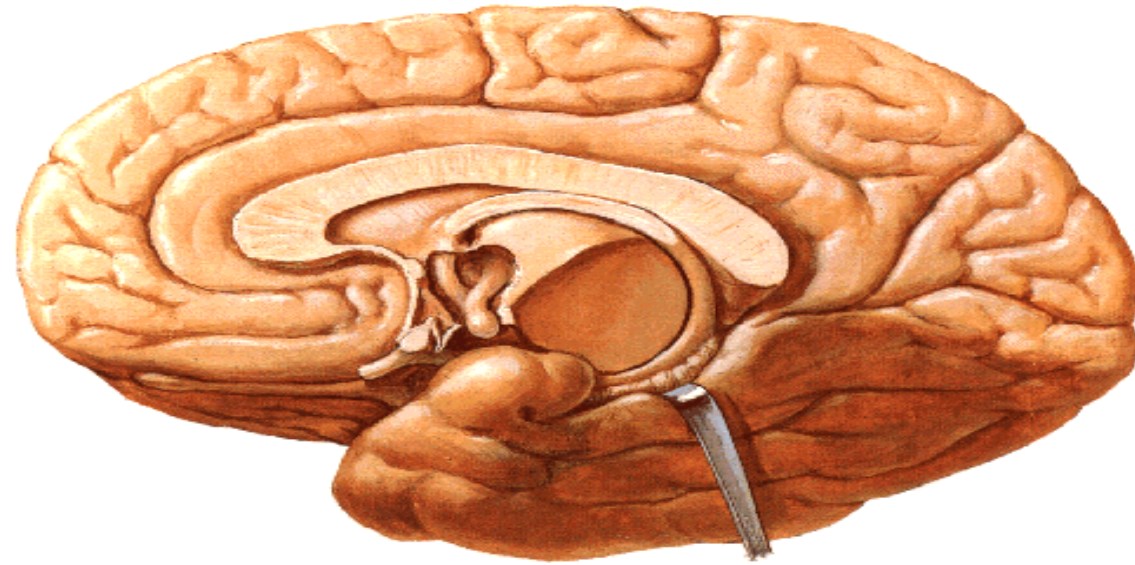
- **Hippocampus** via fornix (Papez circuit)  
→ memory consolidation
- **Amygdala & Septal areas**  
emotions → autonomic reactions

## 3. Retinal

light → suprachiasmatic nc → biological clock

## 4. Lower centers

## 5. Pituitary



# Connections

## 1. Cortical

- **visceral & olfactory** areas  
→autonomic response (past experience)

## 2. Limbic

- **Hippocampus** via fornix (Papez circuit)  
→ memory consolidation
- **Amygdala & Septal areas**  
emotions → autonomic reactions

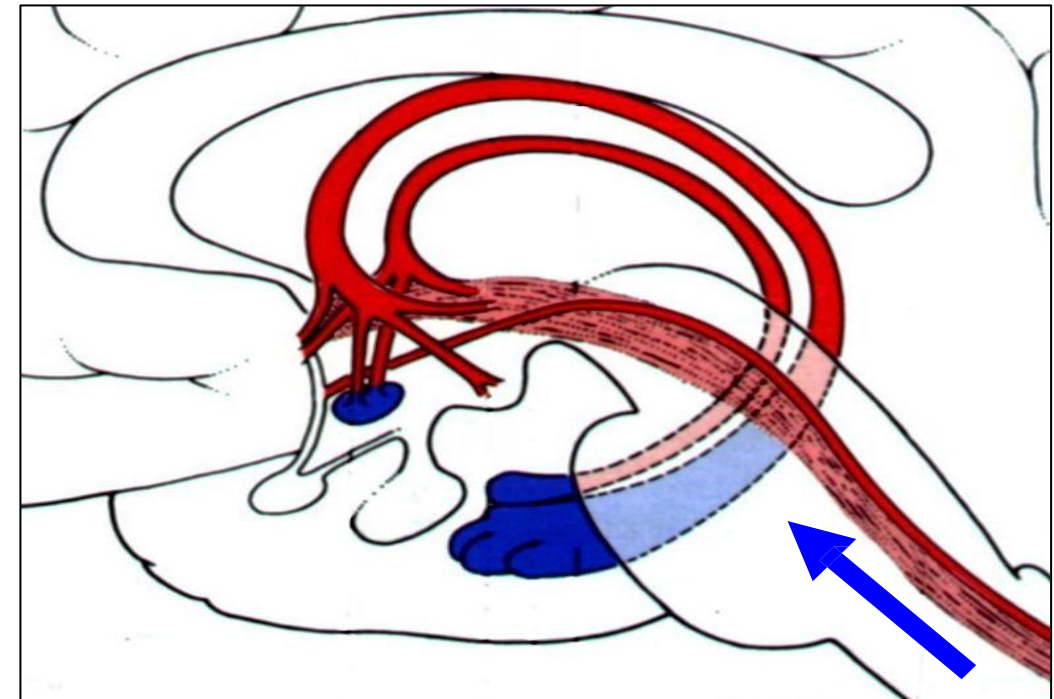
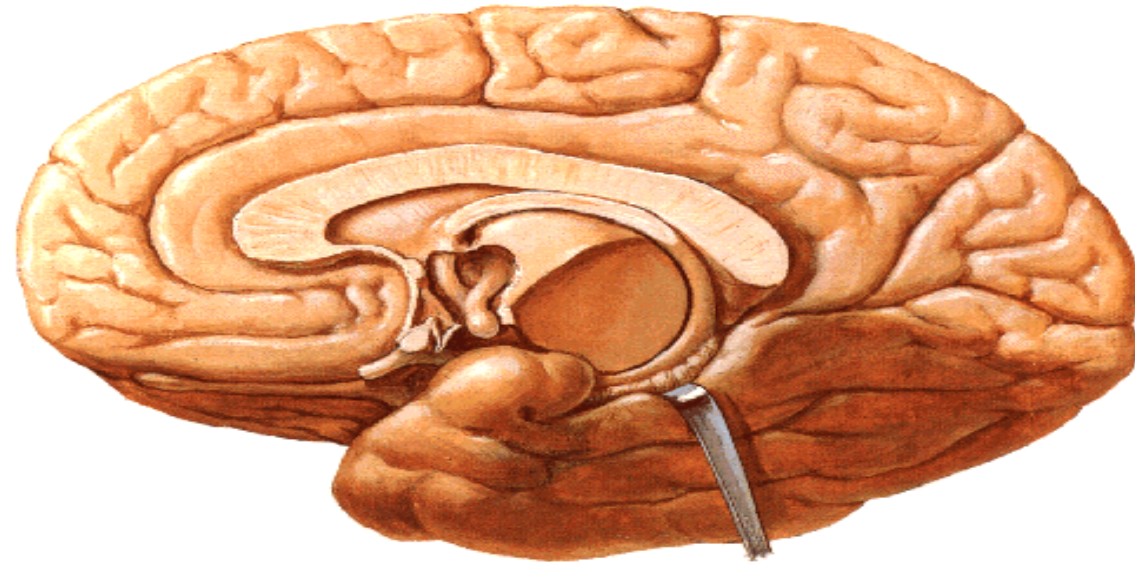
## 3. Retinal

light → suprachiasmatic nc → biological clock

## 4. Lower centers

- **Ascending**
  - **Visceral** (general & taste)
  - **Somatic** (temp. - nipple - genitalia)

## 5. Pituitary





# Connections

## 1. Cortical

- **visceral & olfactory** areas  
→ autonomic response (past experience)

## 2. Limbic

- **Hippocampus** via fornix (Papez circuit)  
→ memory consolidation
- **Amygdala & Septal areas**  
emotions → autonomic reactions

## 3. Retinal

light → suprachiasmatic nc → biological clock

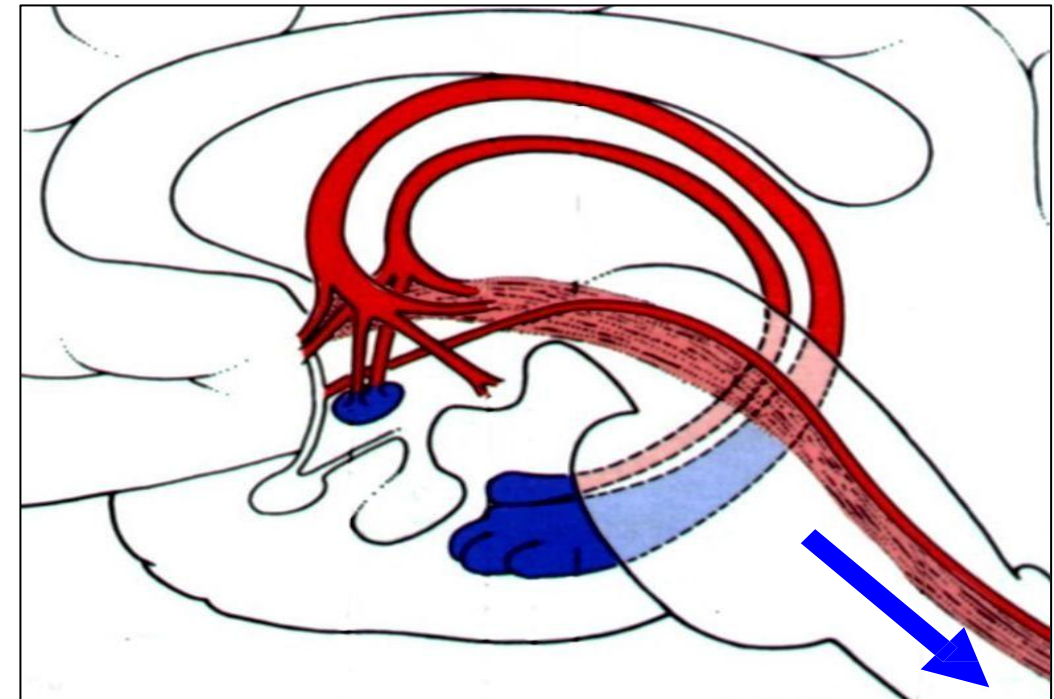
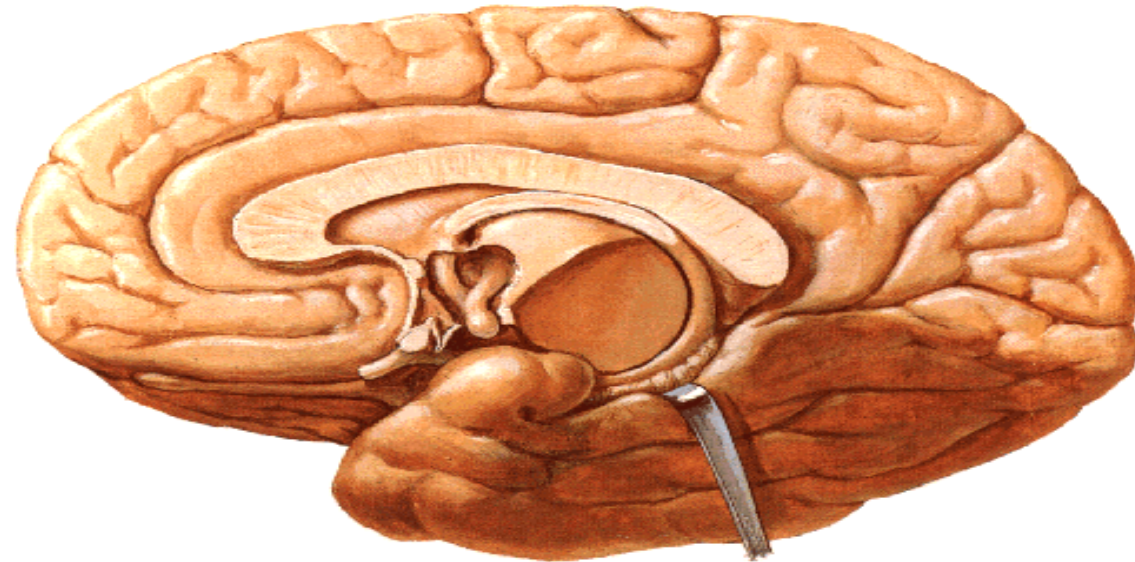
## 4. Lower centers

### – Ascending

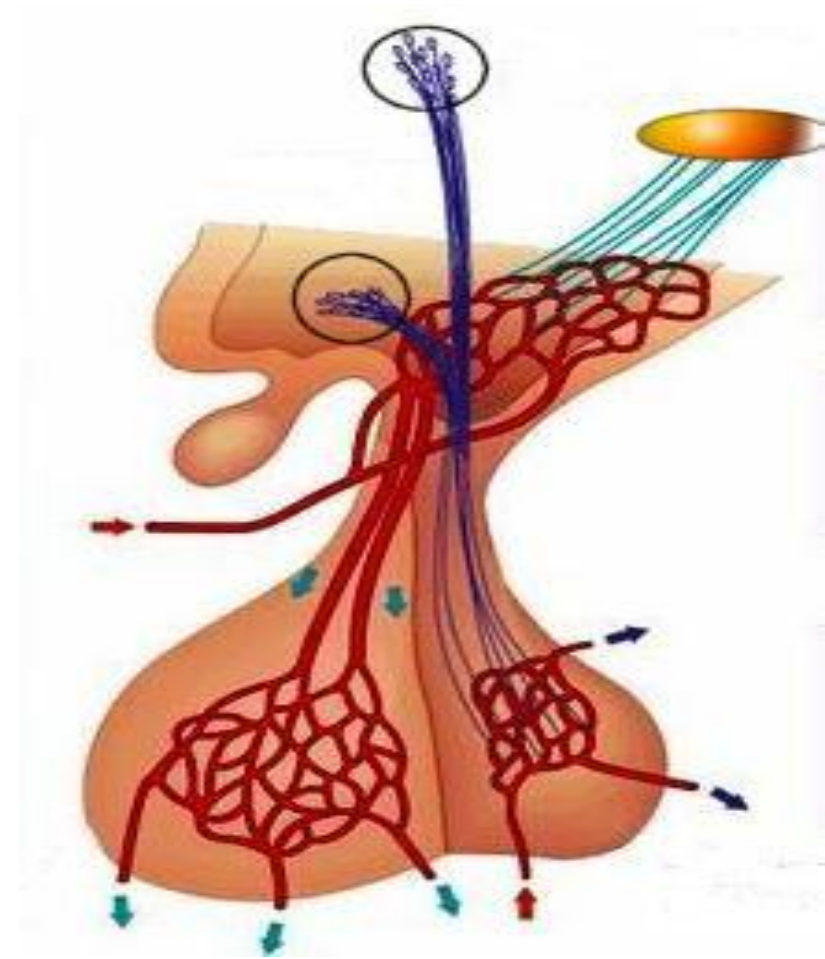
- **Visceral** (general & taste)
- **Somatic** (temp. - nipple - genitalia)

### – Descending

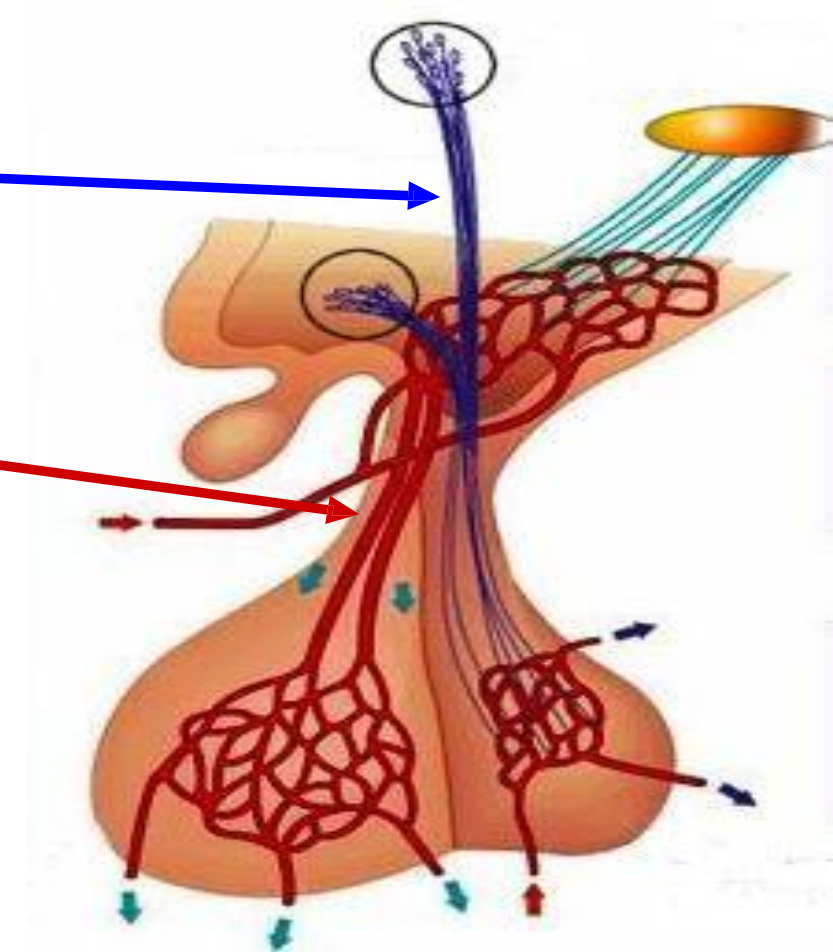
- **Cranial** (III, VII, IX, X)
- **Spinal** (via reticulospinal T.) →
  - **LHCs** → symp & parasymp
  - **AHCs** → Shivering



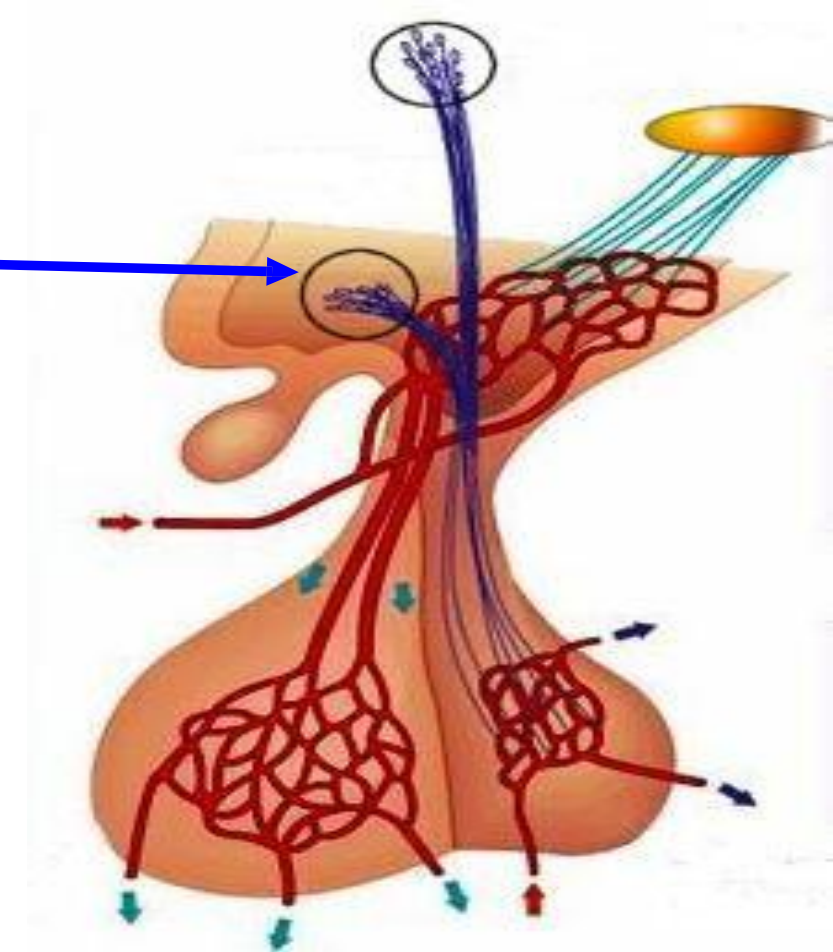
# 5-Pituitary



- **Nervous connection** with post lobe  
(Hypothalamo-hypophyseal tract)
- **Vascular connection** with ant lobe  
(Hypothalamo-hypophyseal portal circulation)

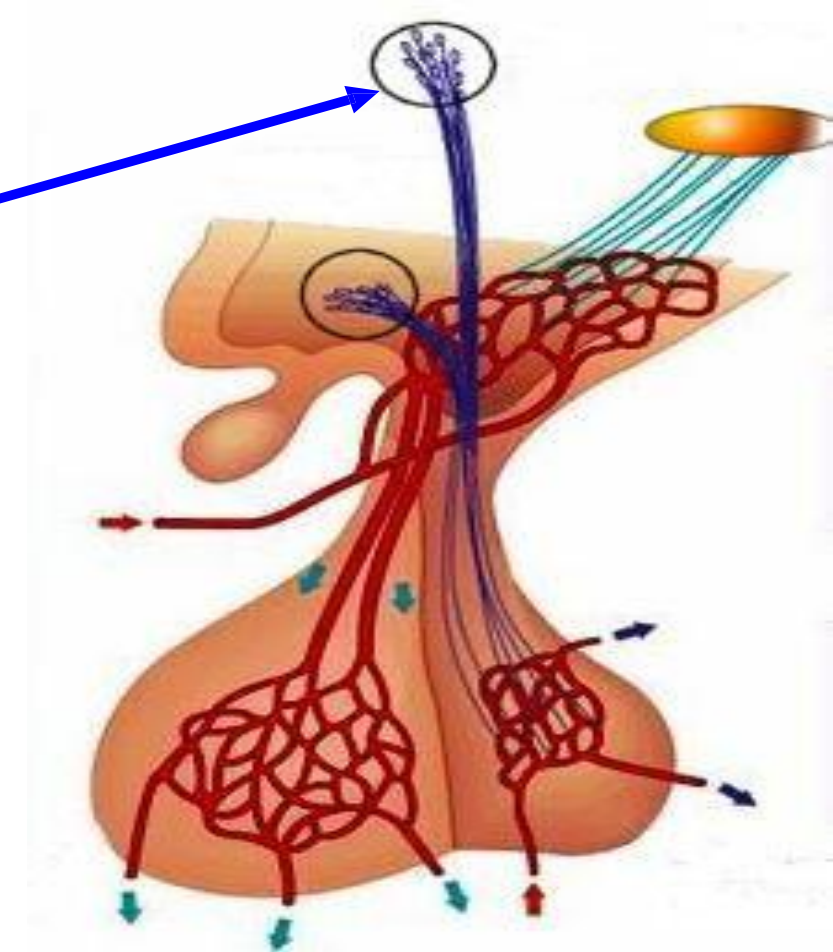


- **Nervous connection** with post lobe  
(Hypothalamo-hypophyseal tract)
  - Supraoptic nc → vasopressin
- **Vascular connection** with ant lobe  
(Hypothalamo-hypophyseal portal circulation)





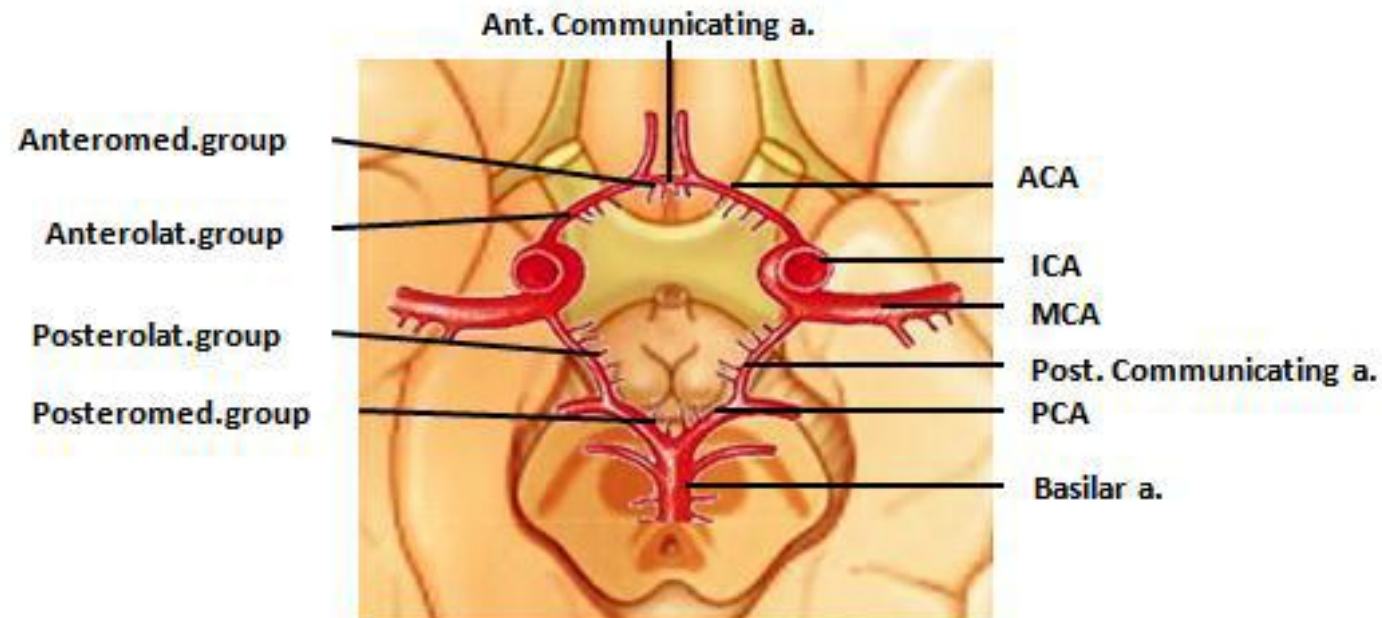
- **Nervous connection** with post lobe  
(Hypothalamo-hypophyseal tract)
  - Supraoptic nc → vasopressin
  - Paraventricular nc → oxytocin
- **Vascular connection** with ant lobe  
(Hypothalamo-hypophyseal portal circulation)



# Blood supply of hypothalamus:

- Arterial supply :

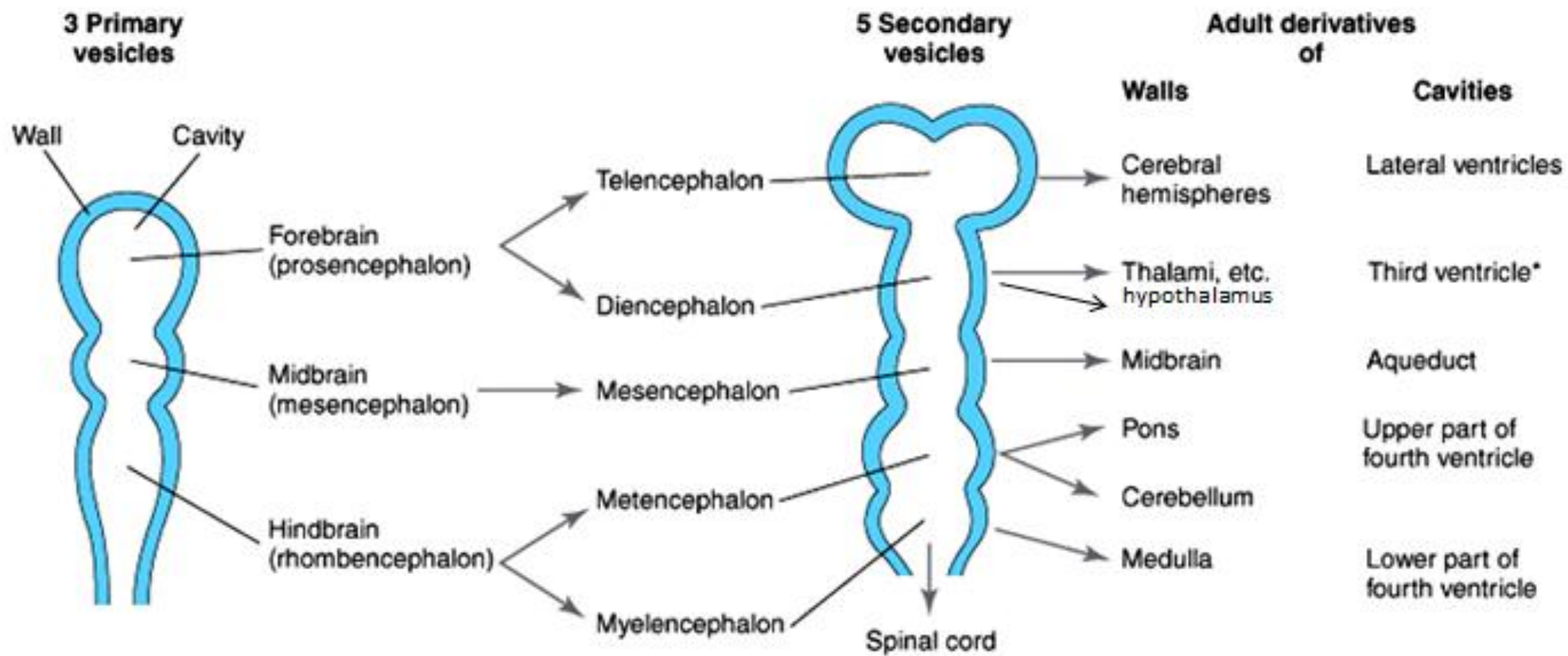
**Posteromedial group of Posterior cerebral artery ( one of the central brs of circle of willis.**



# Development of hypothalamus

- **The brain** is derived from the cranial part of the neural tube (ectodermal in origin).
- Brain vesicles arised : *3 primary brain vesicles develop which give 5 secondary vesicles which give the adult derivatives:*

1ry vesicles	2ry vesicles	Derivatives	Cavity
Forebrain (prosencephalon)	telencephalon	cerebral hemispheres	lateral ventricles
	diencephalon	thalamus, hypothalamus, epithalamus, subthalamus	third ventricle
Midbrain (mesencephalon)	mesencephalon	midbrain	cerebral aqueduct
Hindbrain (Rhombencephalon)	Metencephalon	Pons	fourth ventricle
	myelencephalon	medulla oblongata	





# Pituitary Gland (Hypophysis Cerebri)

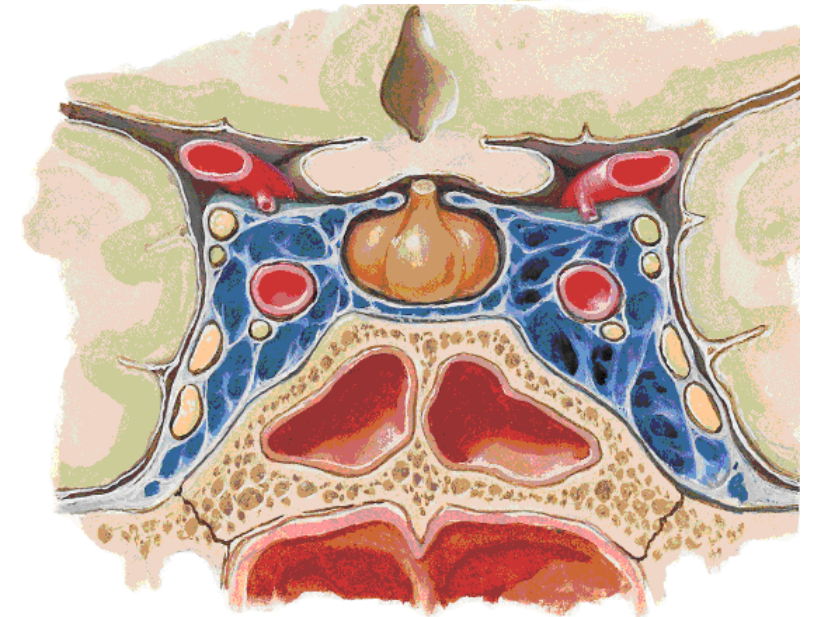
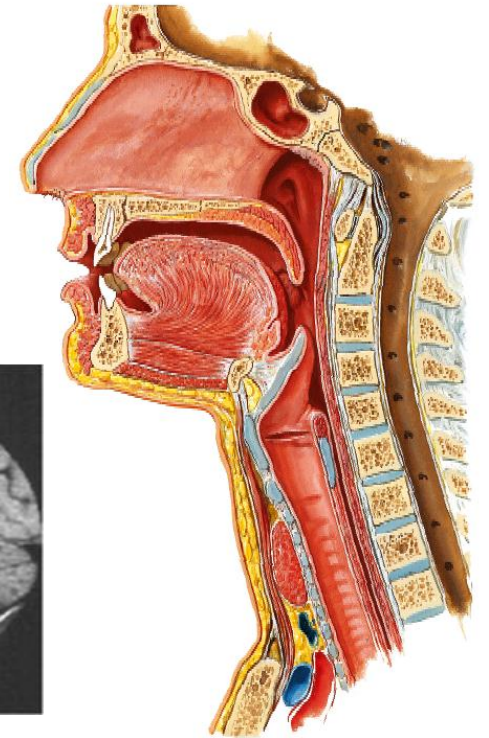
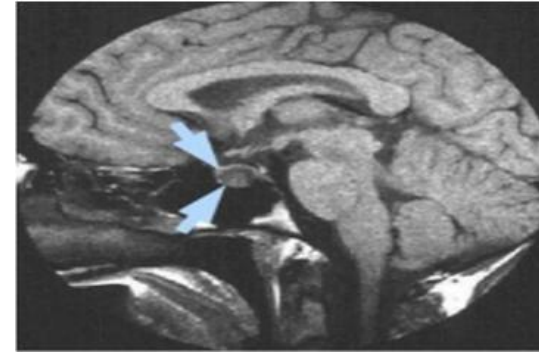
- \* Position :

- \* It lies at the base of the brain in the hypophyseal fossa (sella turcica).

- \* It is roofed by **diaphragma sellae** (a dural fold) that is pierced by the infundibulum connecting the pituitary gland to the hypothalamus.

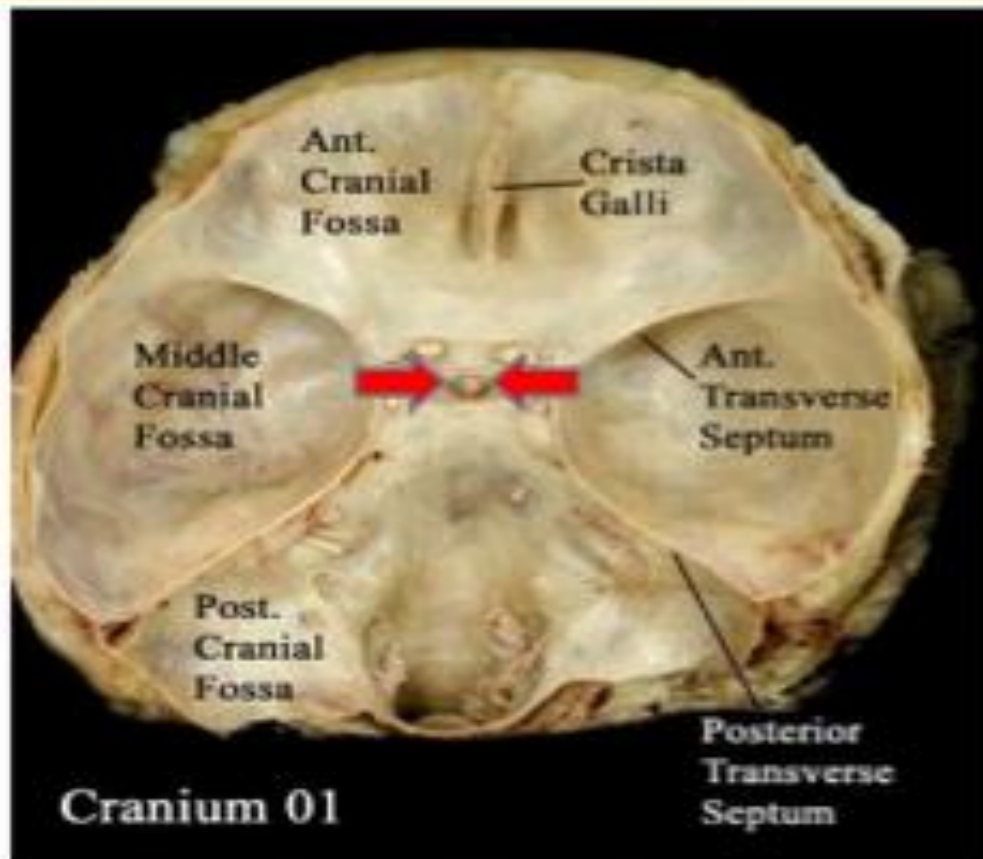
- \* Shape : oval shaped gland.

- \* Size : 12 mms transversely, 8 mms antero-posterior & 6 mms in height.

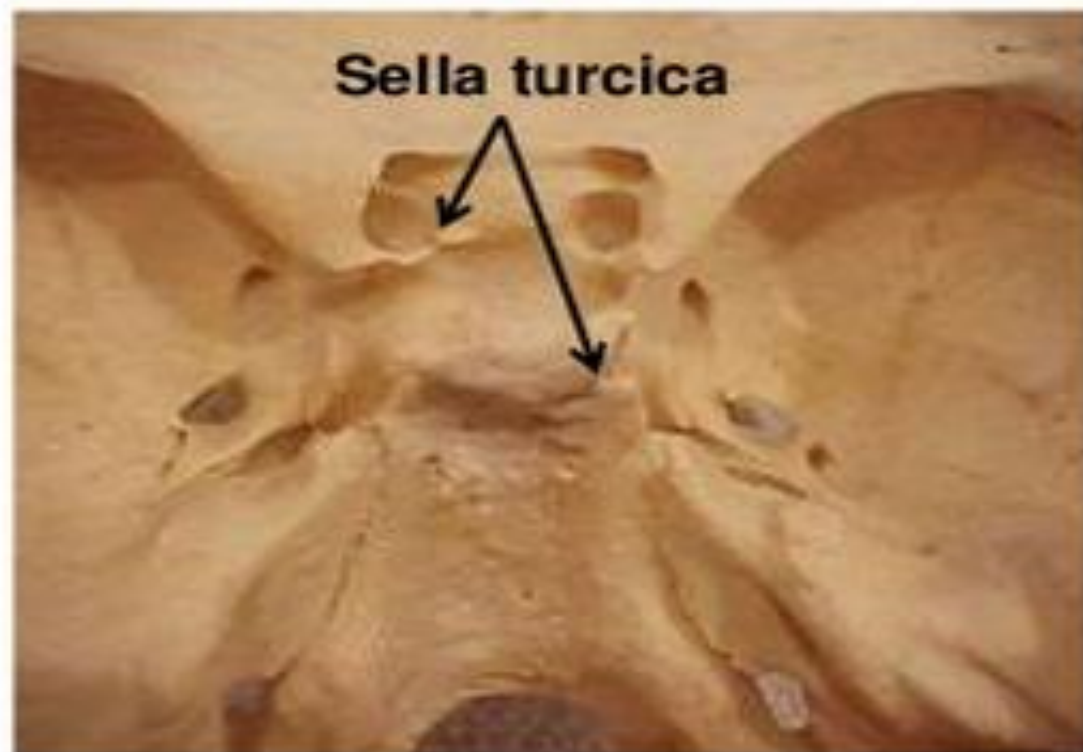

# PITUITARY GLAND (POSITION)

It lies in the middle cranial fossa

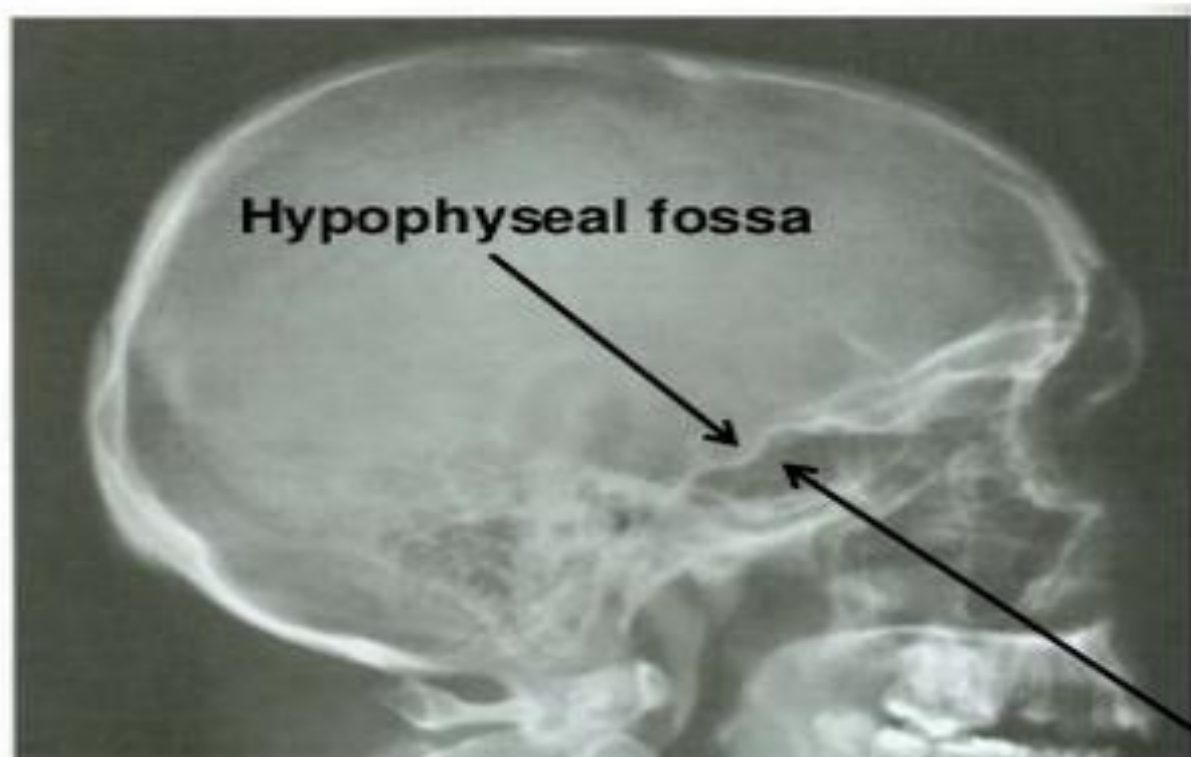


It is well protected in sella turcica of body of sphenoid

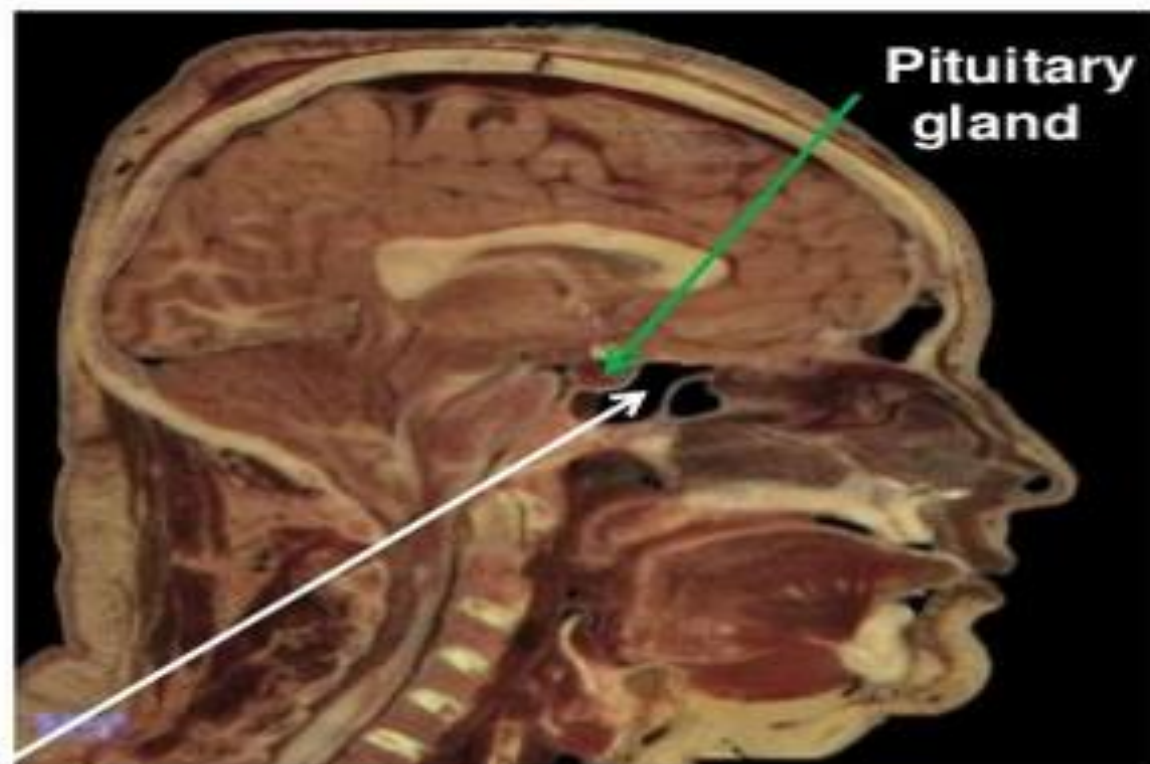




## X-RAY SKULL: LATERAL VIEW



## SAGITTAL SECTION OF HEAD & NECK

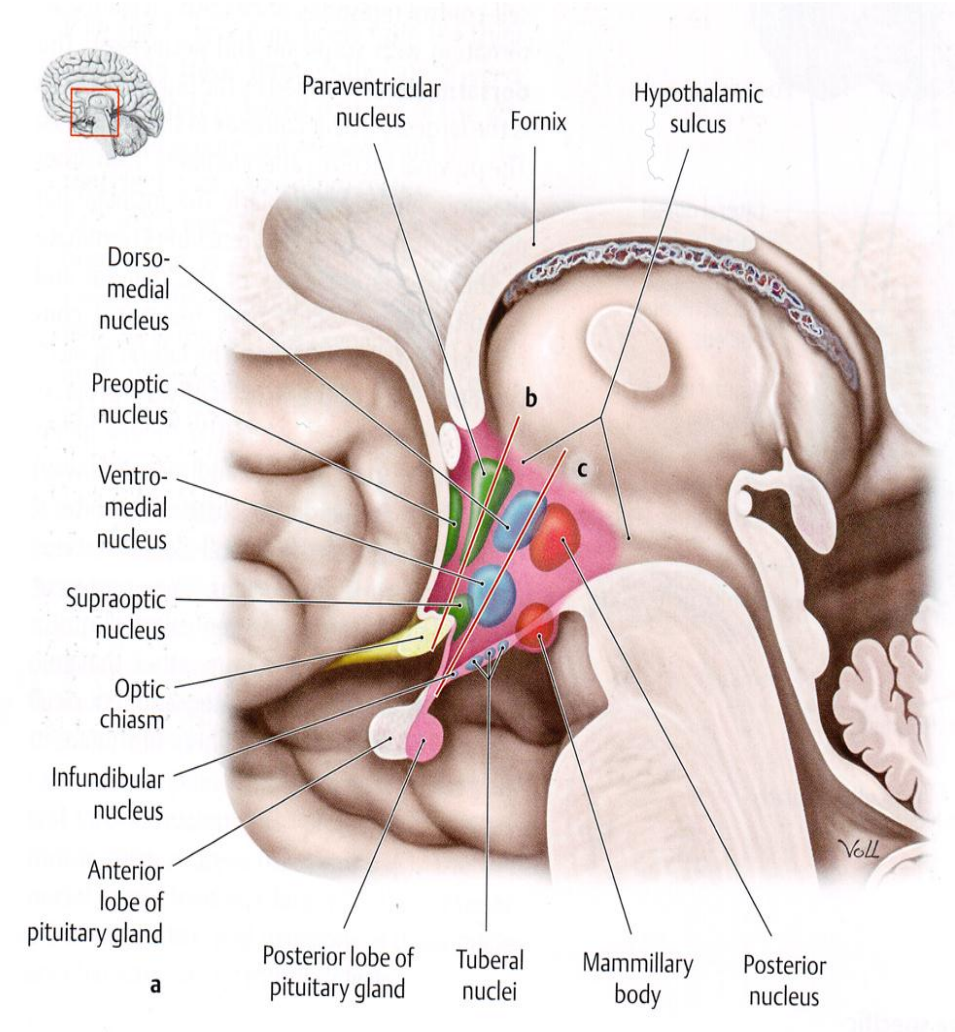


Sphenoidal air sinus

# Pituitary Gland (Hypophysis Cerebri)

\* For many years the pituitary gland was called the “**master endocrine gland**” because it secretes several hormones that control other endocrine glands.

\* We now know that the pituitary gland itself has a master, which is the **hypothalamus**.





# Pituitary Gland (Hypophysis Cerebri)

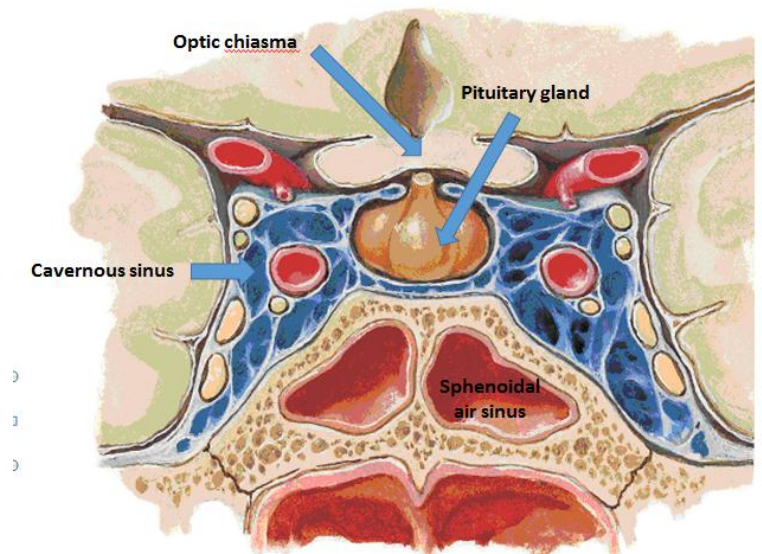
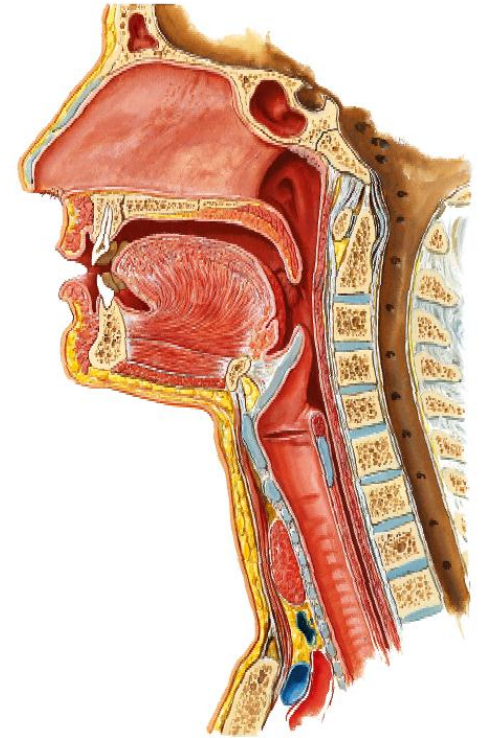
## \* Relations :

### \*\* Superiorly :

1. diaphragma sellae (separating the gland from the hypothalamus).
2. Optic chiasma.

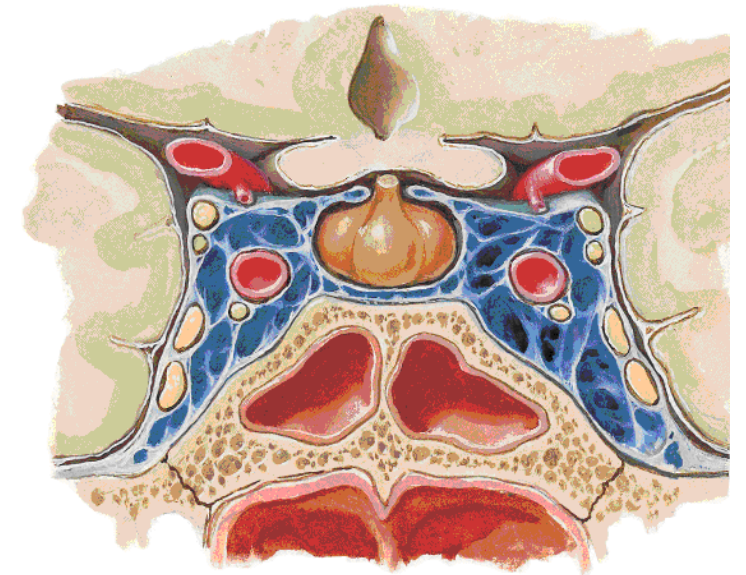
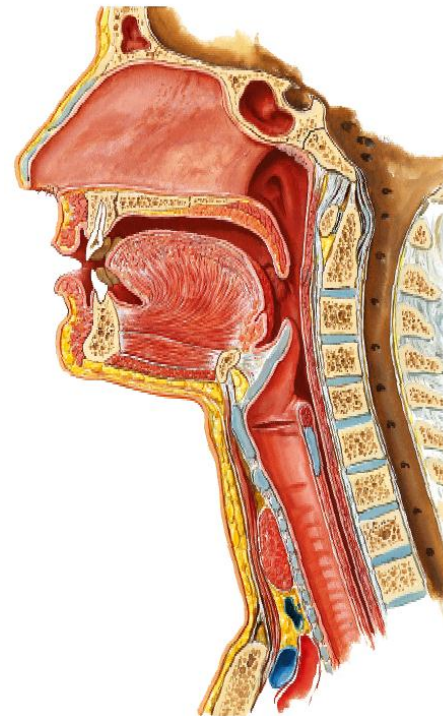
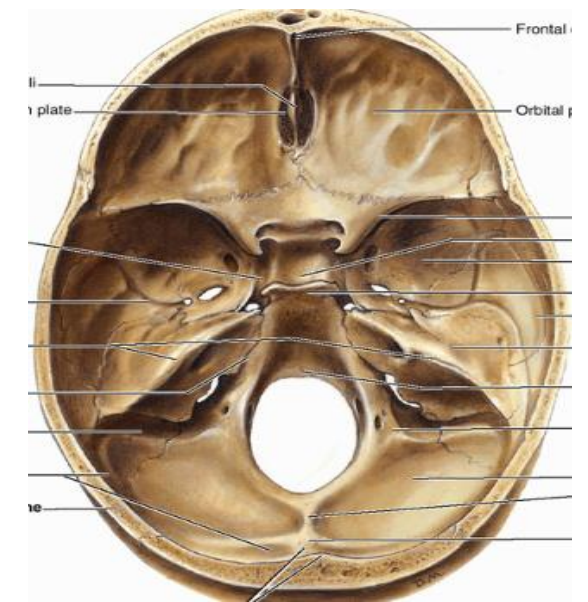
### \*\* Inferiorly :

1. Middle Intercavernous sinus .
2. Body of sphenoid and sphenoid air sinus (separating it from nasopharynx).



# Pituitary Gland (cont)

- \*\*Anteriorly** : 1. Tuberculum sellae.  
2. Sphenoidal air sinus (separating it from nose).
- \*\*Posteriorly** : Dorsum sellae (separating it from pons).
- \*\*On each side** : Cavernous sinus (with the structures inside it (ICA & abducent nerve) & the nerves embedded in its lat. wall (OTOM = Oculomotor, trochlear, Ophthalmic & maxillary nerves).
- \* Blood supply :**
  - a. Arterial** : Sup. and inf. hypophyseal branches of Internal Carotid artery (ICA).
  - b. Venous** : A venous plexus which ends in cavernous sinus.





# Parts of Pituitary Gland

\* The pituitary gland comprises a larger **anterior lobe (or adenohypophysis)** and a smaller **posterior lobe (or neurohypophysis)**.

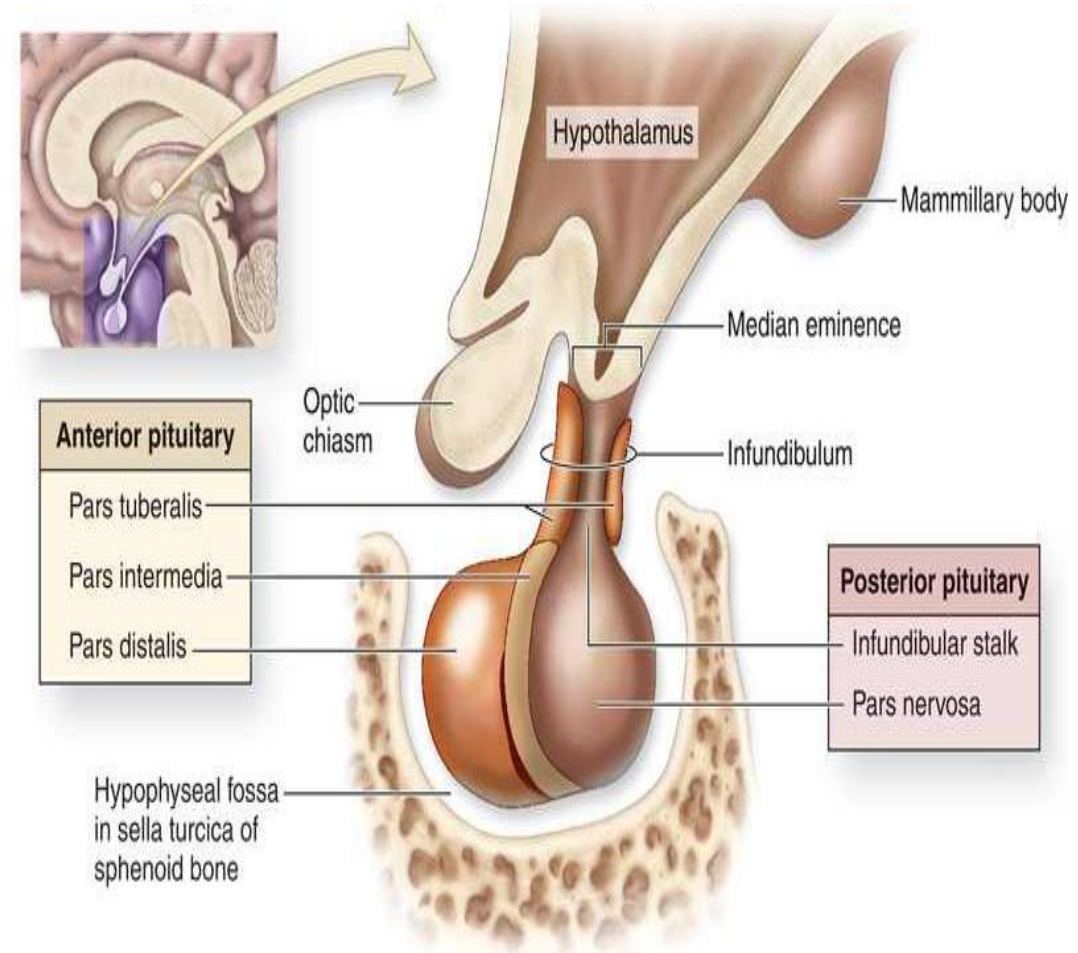
\* **The anterior pituitary** regulates several physiological processes including stress, growth, reproduction and lactation.

\* **The anterior lobe** is subdivided into:

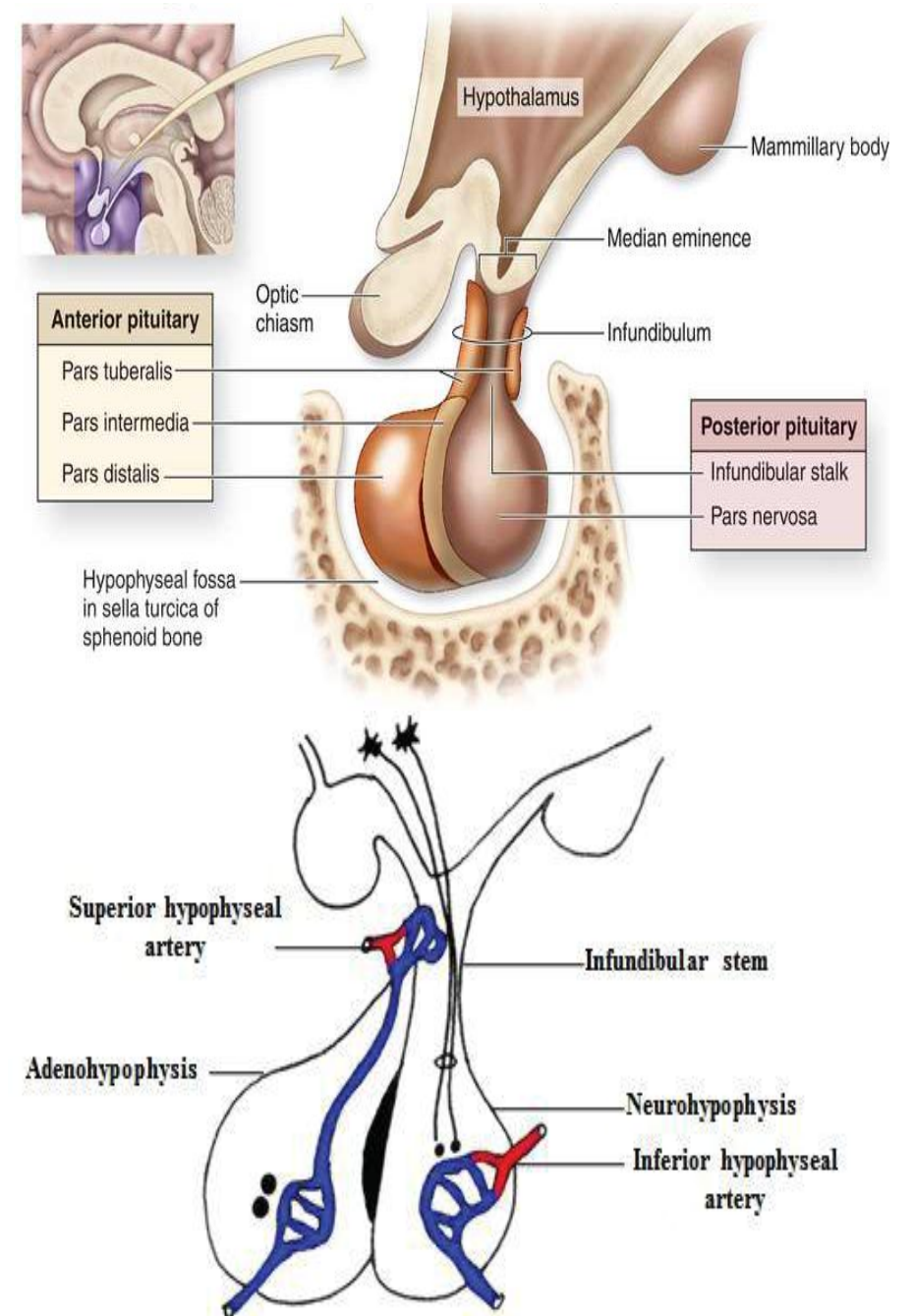
A. **The pars anterior (pars distalis)**

B. **The pars intermedia**, which may be separated by a cleft from the pars distalis

C. Extending up along the anterior and lateral surfaces of the pituitary stalk from the pars anterior there is a projection called the **pars tuberalis**.



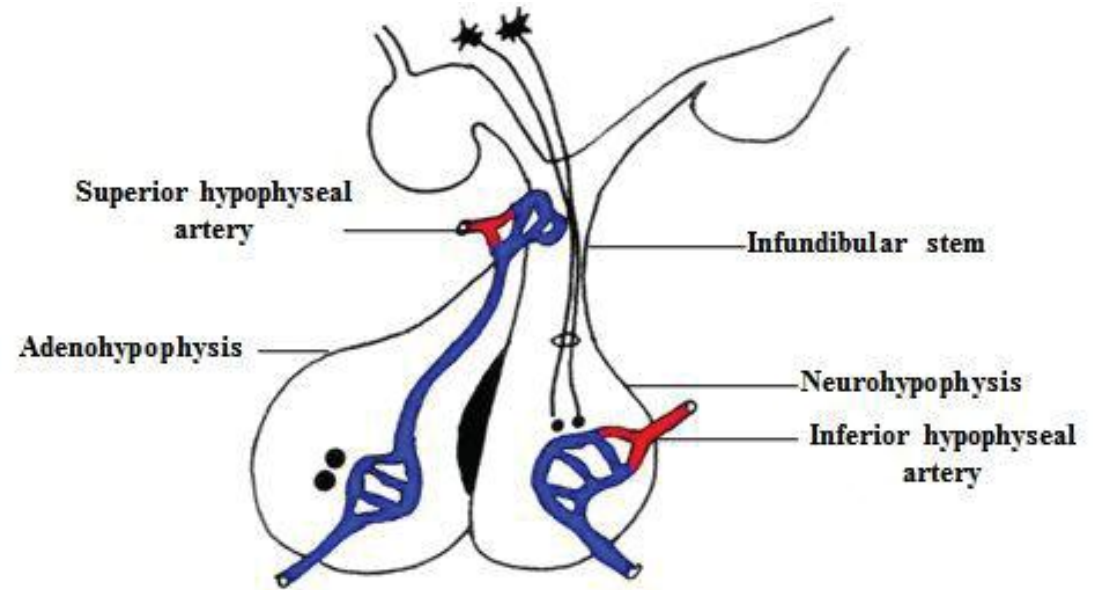
**\* The posterior pituitary (neurohypophysis or pars nervosa) is not glandular as the anterior pituitary. Instead, it is largely a collection of axonal projections from the hypothalamus that terminate behind the anterior pituitary, and acts as a store for the neurohypophysial hormones (oxytocin and antidiuretic hormones) which are produced by the hypothalamus.**





# Hypophyseal Portal Circulation

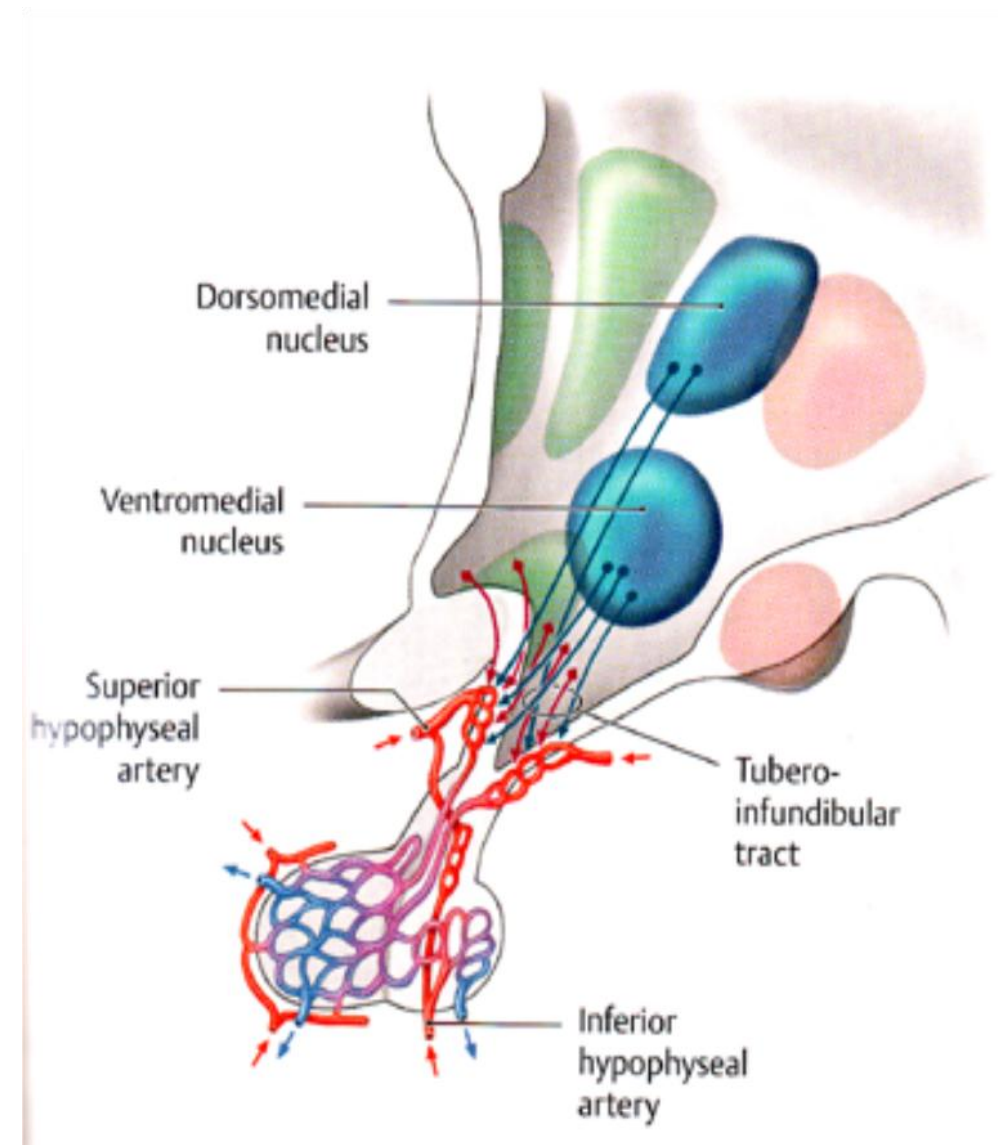
- \* The **hypophyseal portal circulation** is a general term denoting the circulation of blood through larger vessels from the capillaries of one organ to those of another.
- \* It is named after the portal circulation of the liver.



# Hypophyseal Portal Circulation & connections of the hypothalamic nuclei to the anterior pituitary lobe

\* The superior hypophyseal arteries → form a vascular plexus around the infundibulum (pituitary stalk).

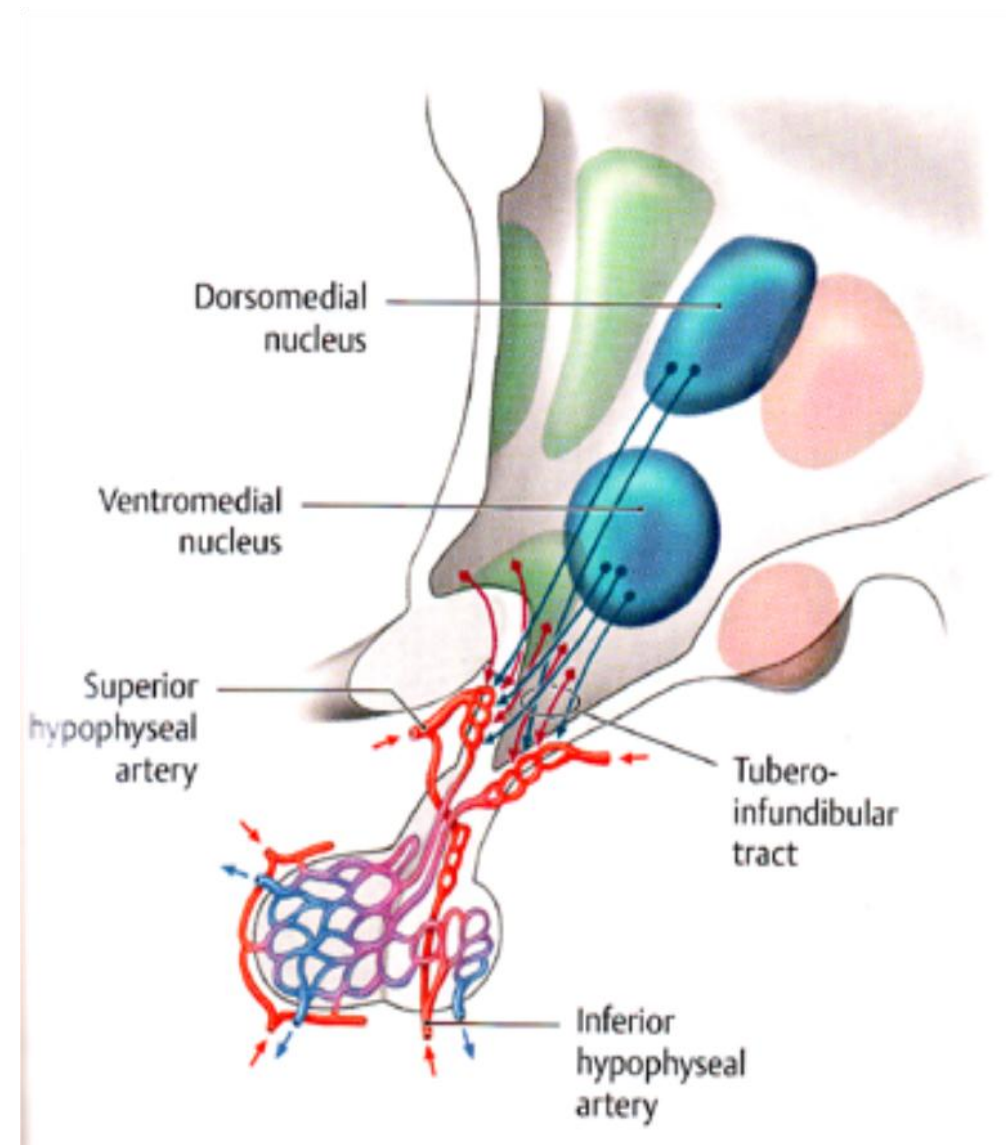
\* The axons from the neurons of hypothalamic nuclei (dark red & dark blue arrows) terminate at this plexus & secrete hormones that have been produced in the neurons of the hypothalamus.



# Hypophyseal Portal Circulation & connections of the hypothalamic nuclei to the anterior pituitary lobe

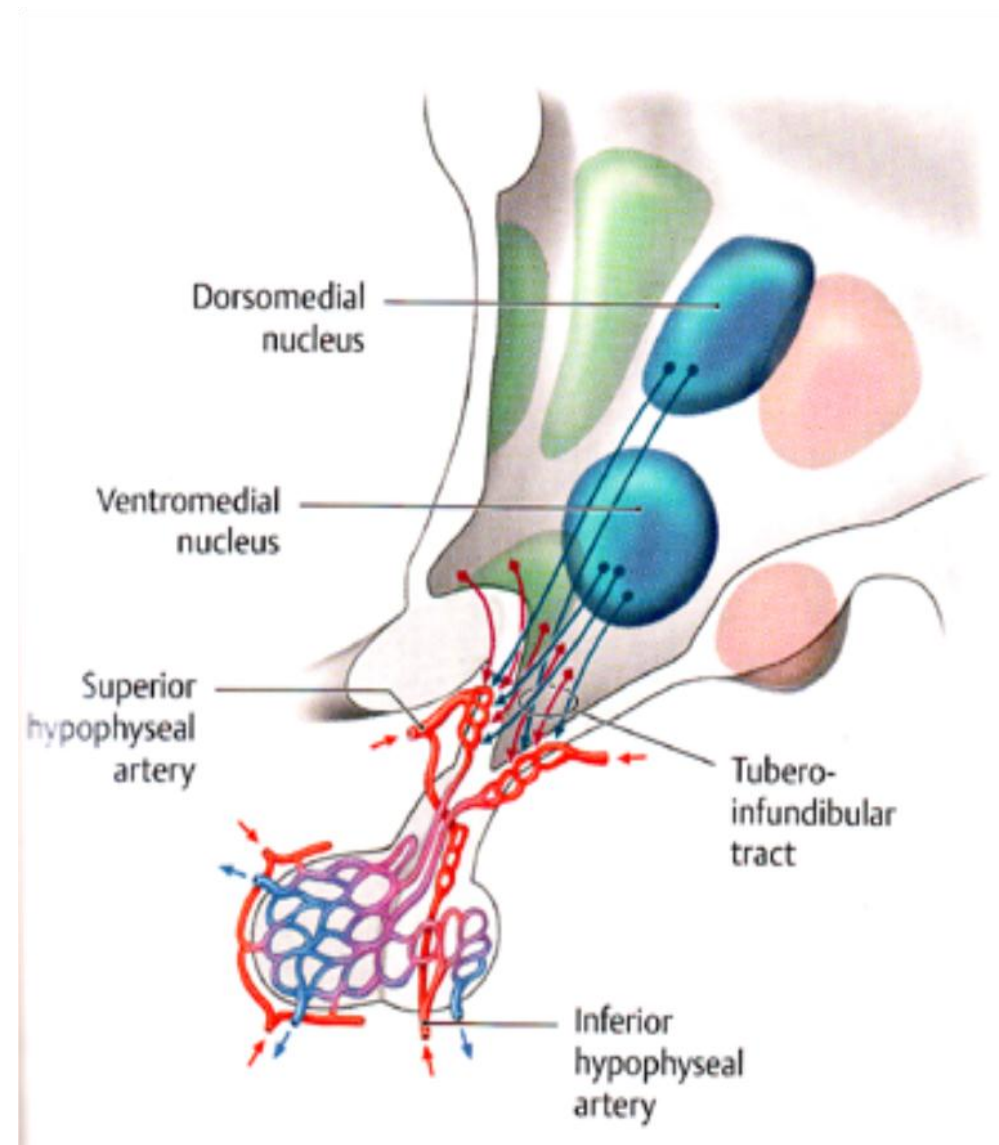
**\* The secreted hypothalamic hormones are of 2 types:**

- 1. Releasing stimulating factors which stimulate hormone release from cells of the anterior pituitary lobe.**
- 2. Release-inhibiting factors which inhibit the release from these cells.**



# Hypophyseal Portal Circulation & connections of the hypothalamic nuclei to the anterior pituitary lobe

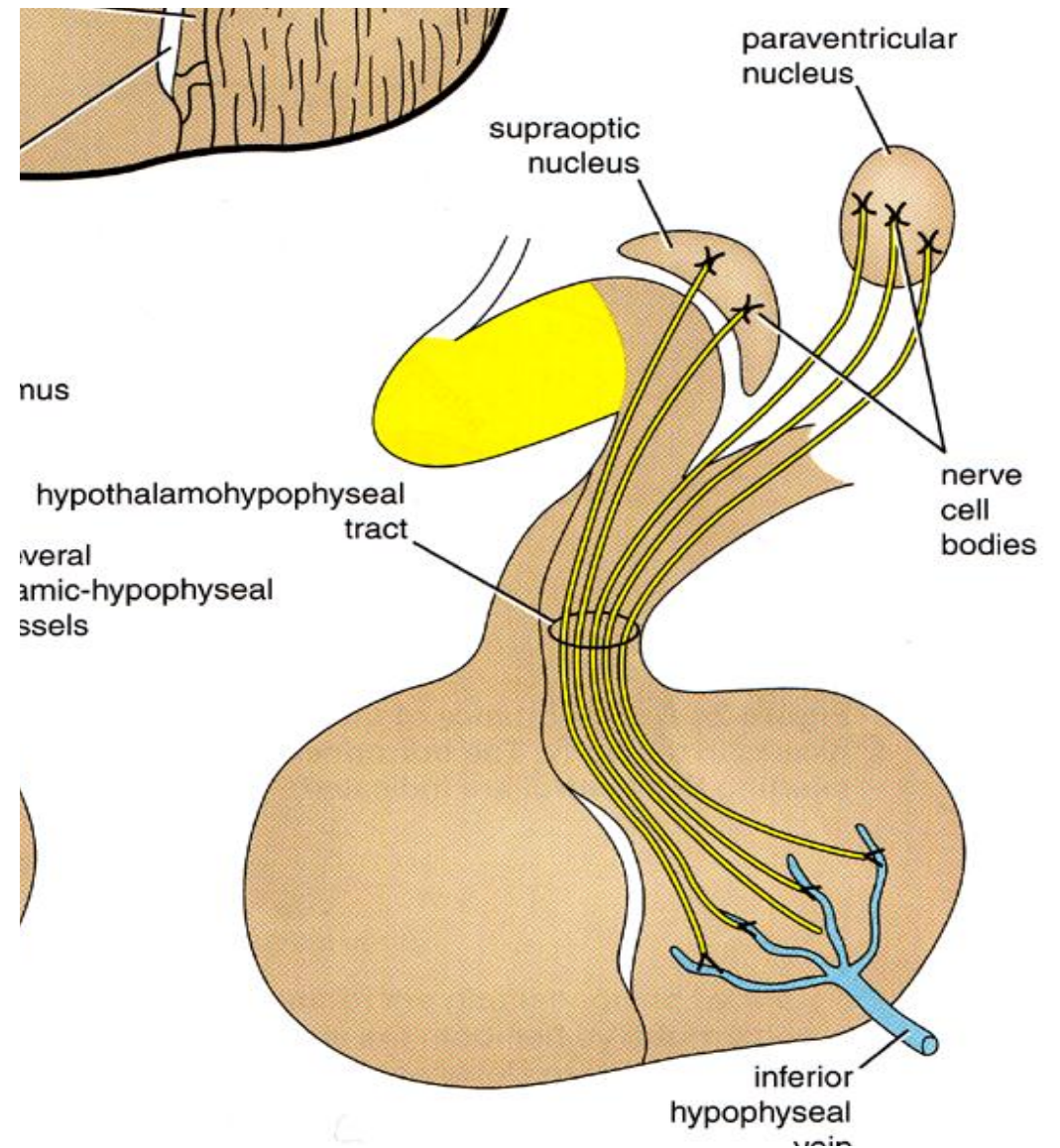
\* These hormones are carried by the **hypophyseal portal venous system** to capillaries in the anterior lobe, establishing communication between the hypothalamus & the endocrine cells of the anterior pituitary.





# Hypothalamo-hypophyseal Tract

- **Pituitary hormones** are not synthesized in the posterior pituitary lobe itself.
- They are synthesized in the **hypothalamic neurons**.
- The **paraventricular nucleus** secretes **oxytocin hormone** & the **supraoptic nucleus** secretes the **vasopressin or antidiuretic hormone**.
- They are then transported by axons of the **hypothalamic-hypophyseal tract** to the **neurohypophysis** where they are stored and released when needed.



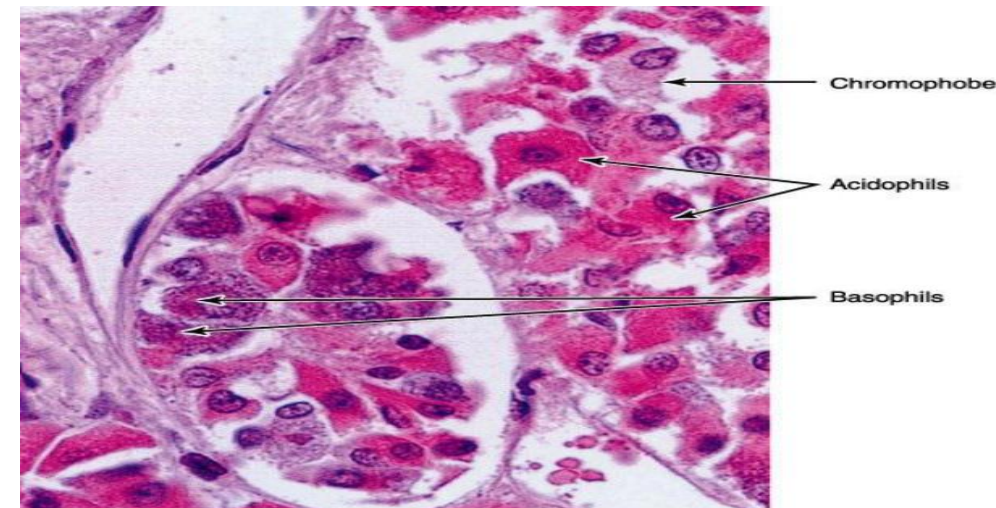
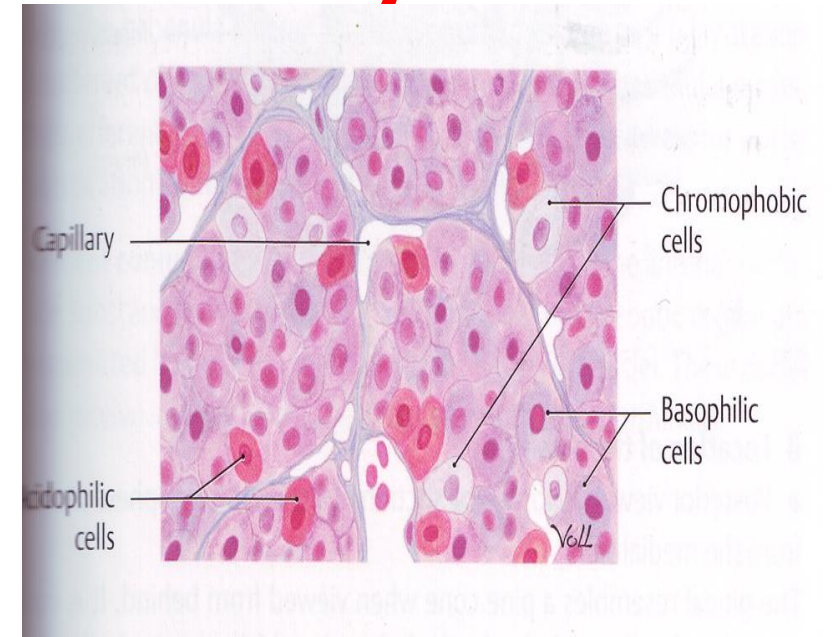
\* Three types of cells can be distinguished in the anterior lobe of the pituitary gland (pars distalis) according to their staining reactions:

**(a) Acidophils or alpha cells** (somatotrophs and lactotrophs) → make up about 35% of the cells. They stain **red** with acidic dyes and contain secretory granules.

**(b) Basophils or beta cells** (thyrotrophs, gonadotrophs and corticotrophs) → make up about 15% of the cells. They stain **blue** with basic dyes and contain secretory granules.

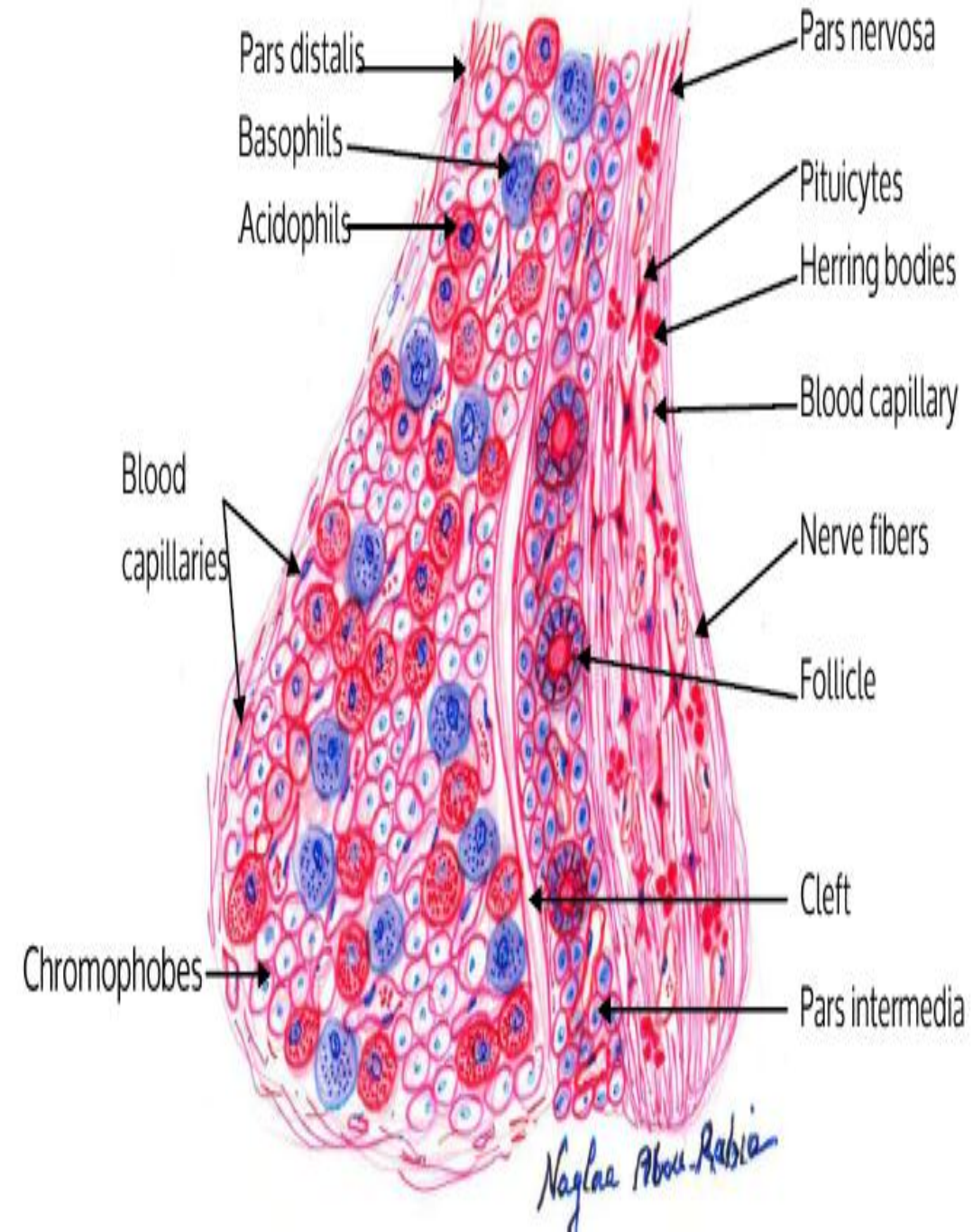
\* Both acidophils and basophils are referred to as **chromophils cells**.

## Histology of Pituitary Gland





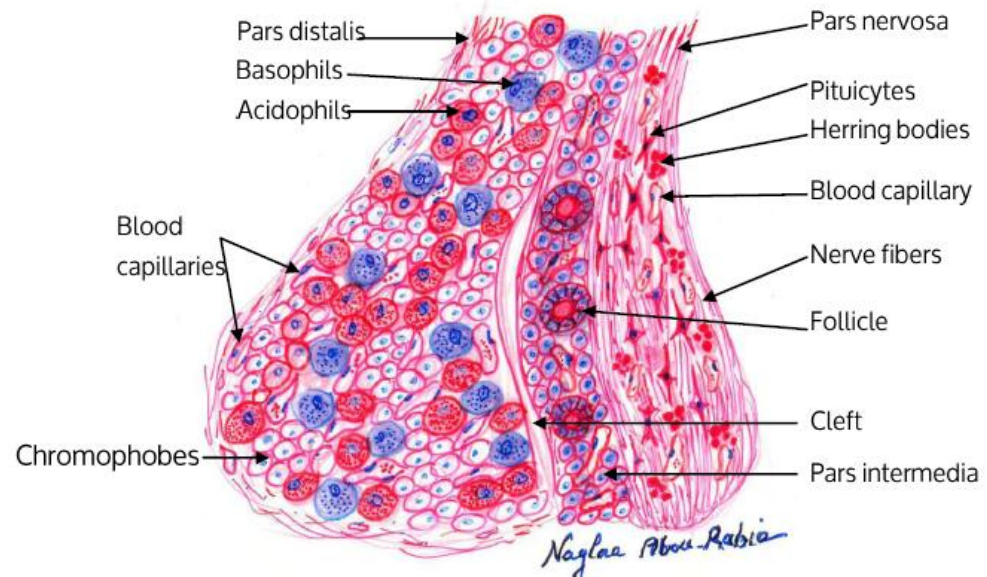
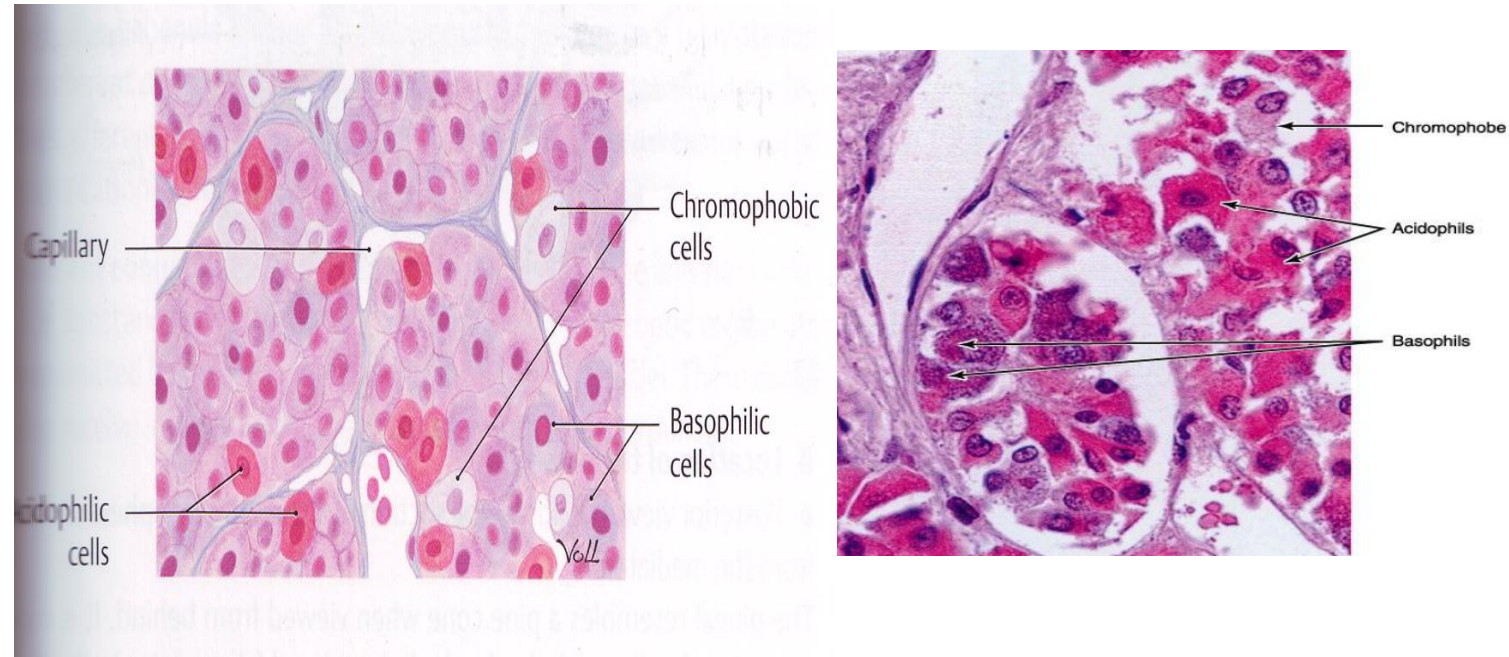
	Acidophils		Basophils		
	Somatotrophs	Mammotrophs	Thyrotrophs	Gonadotrophs	Corticotrophs
Shape	spherical or ovoid	small fusiform or polygonal	Typically angular	Fusiform	Spherical or oval
Stains	stained orange by "Orange G stain"	stained red by erythrocin and azocarmine	Granules are PAS positive and Ald.F positive	They are PAS positive and Ald.F negative	They are PAS negative and Ald.F negative
Granules Size	300-400nm	200nm	120-200nm	200-400nm	100-250nm
Function	Secrete Growth hormone (GH) or (STH)	Secrete Prolactin (PRL) Lactogenic (LTH)	Secrete Thyroid stimulating hormone (TSH)	Secrete Follicular stimulating hormone (FSH) & Luteinizing hormone (LH)	Secrete Adrenocortico trophic hormone (ACTH) & Melanocyte stimulating hormone (MSH)



# Histology of the Pituitary Gland

**(c) Chromophobes** make up about 50% of the cells and have little affinity for basic or acidic dyes. They have no secretory granules and do not secrete hormones.

**\* The posterior lobe (pars nervosa)** is made up of pituicytes, fenestrated blood capillaries and acidophilic bodies called (herring bodies).



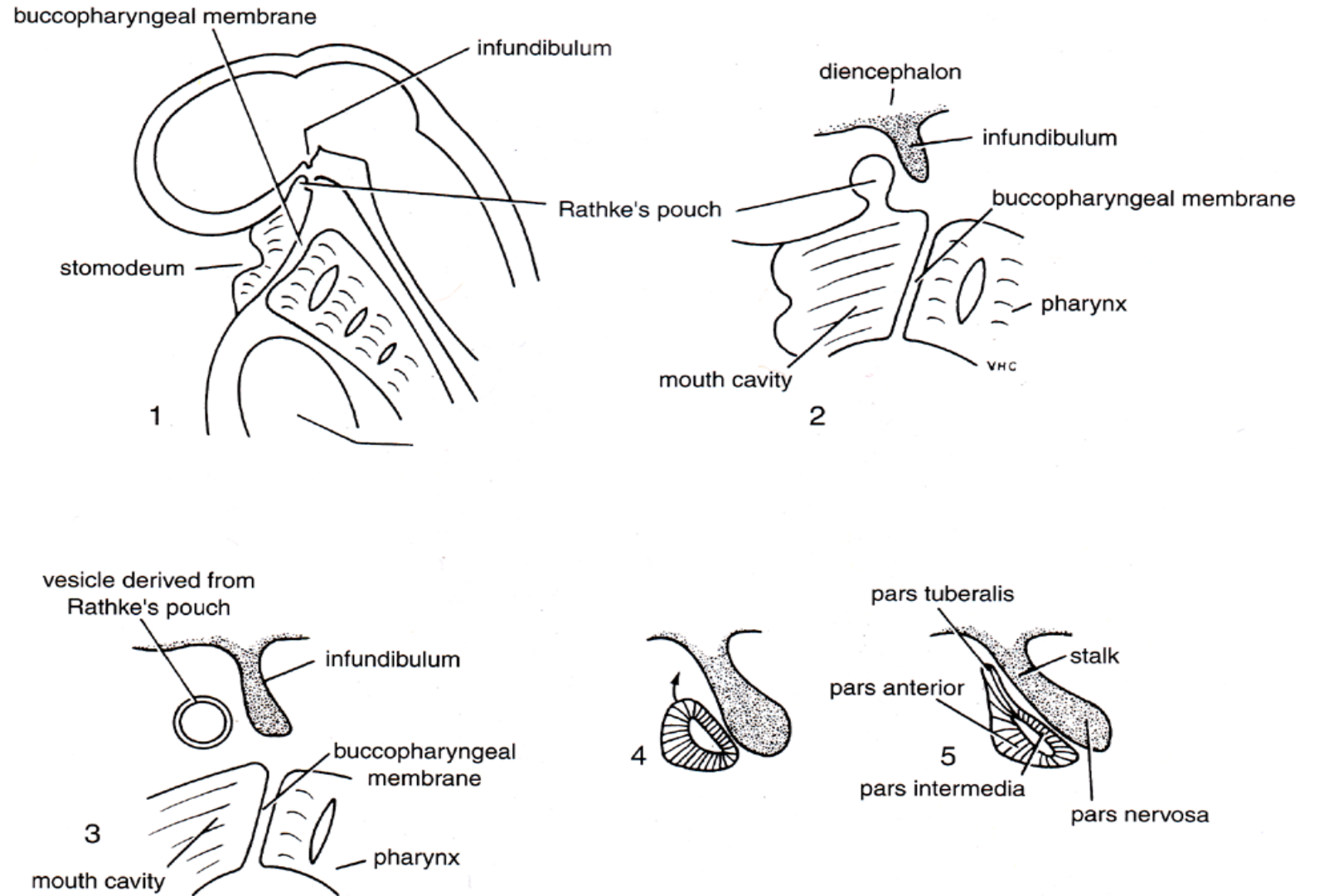


# Development of the Pituitary Gland

\* The pituitary gland develops from two sources:

**A. The posterior lobe:** develops as a small ectodermal diverticulum (the infundibular process) from the floor of the diencephalon of the brain.

\* The infundibulum eventually develops into the **stalk and pars nervosa** of the pituitary gland.

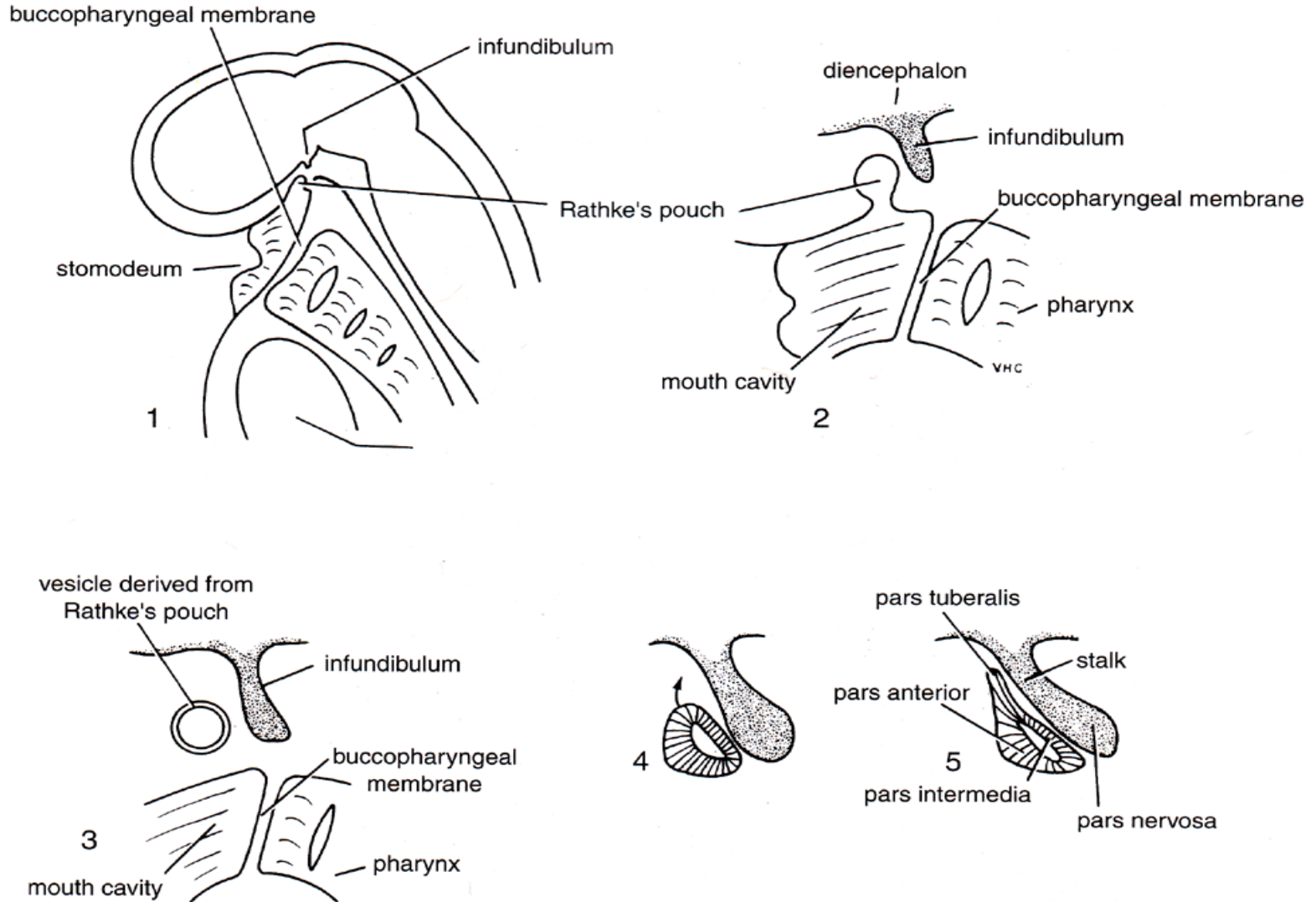


**Figure 24-8** The different stages in the development of the pituitary gland shown in sagittal sections.

# Development of the Pituitary Gland

## B. The anterior lobe and the pars intermedia:

develop from **Rathke's pouch** (which grows superiorly from the roof of the stomodeum immediately anterior to the buccopharyngeal membrane).



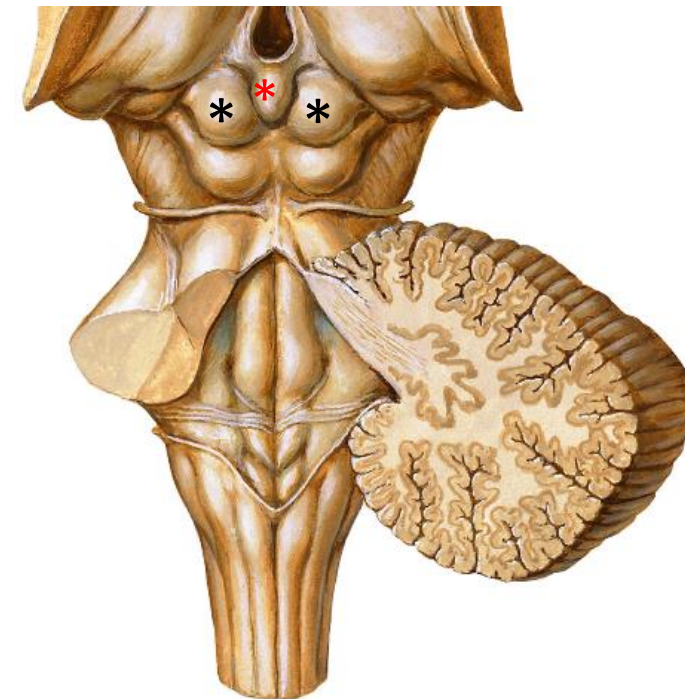
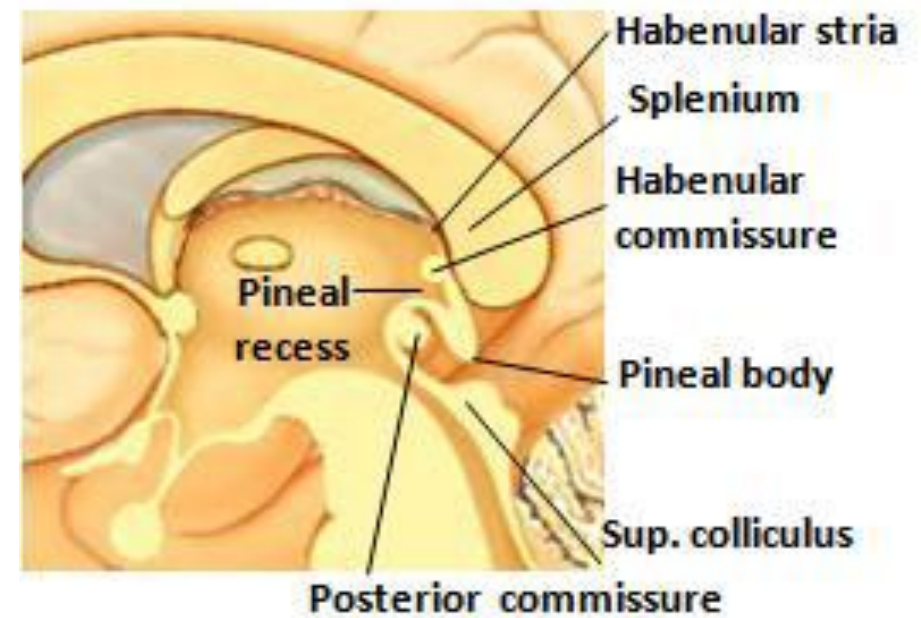
**Figure 24-8** The different stages in the development of the pituitary gland shown in sagittal sections.

# Anomalies

- 1. **Ectopic gland** present along the course of Rathke's pouch.
- 2. **Craniopharyngeal canal** is sometimes present in the sphenoid bone, marking the original course of the stalk of Rathke's pouch.

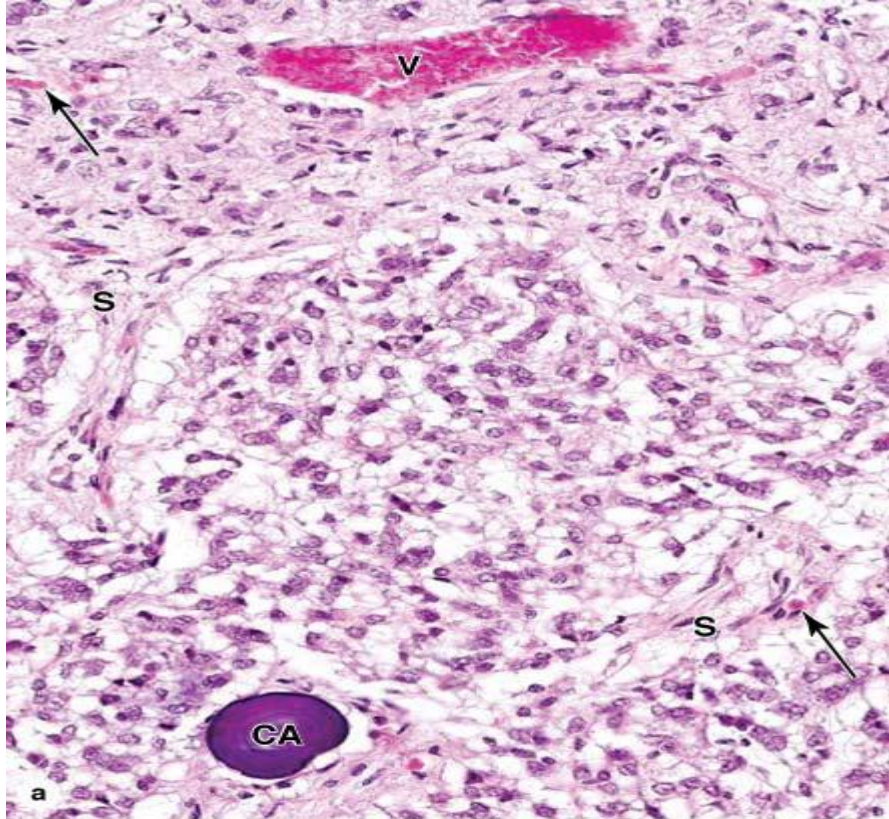
# PINEAL GLAND

- It is a very small, pine cone-shaped organ in the brain
- **Site:** in the roof of the diencephalon and is found in the posterior of the third ventricle, between the superior colliculi of brain stem.
- **Measurements:** 5–8 mm in length and 3–5 mm in width and weighing about 150 mg. The pineal develops with the brain from neuroectoderm.
- **Histologically,** the pineal gland is covered by connective tissue of the pia mater, from which emerge septa containing small blood vessels and subdividing various sized groups of secretory cells as lobules. The prominent and abundant secretory cells are the **pinealocytes**, which have slightly **basophilic cytoplasm** and **large, irregular nuclei and nucleoli** .
- **Function:** It is an endocrine gland that inhibits the pituitary gland, pancreas, parathyroids, adrenal cortex and gonads. It is active in the dark secreting **melatonin** hormone by its pinealocytes. After puberty, it becomes calcified forming the brain sand which is a landmark in skull x-rays.

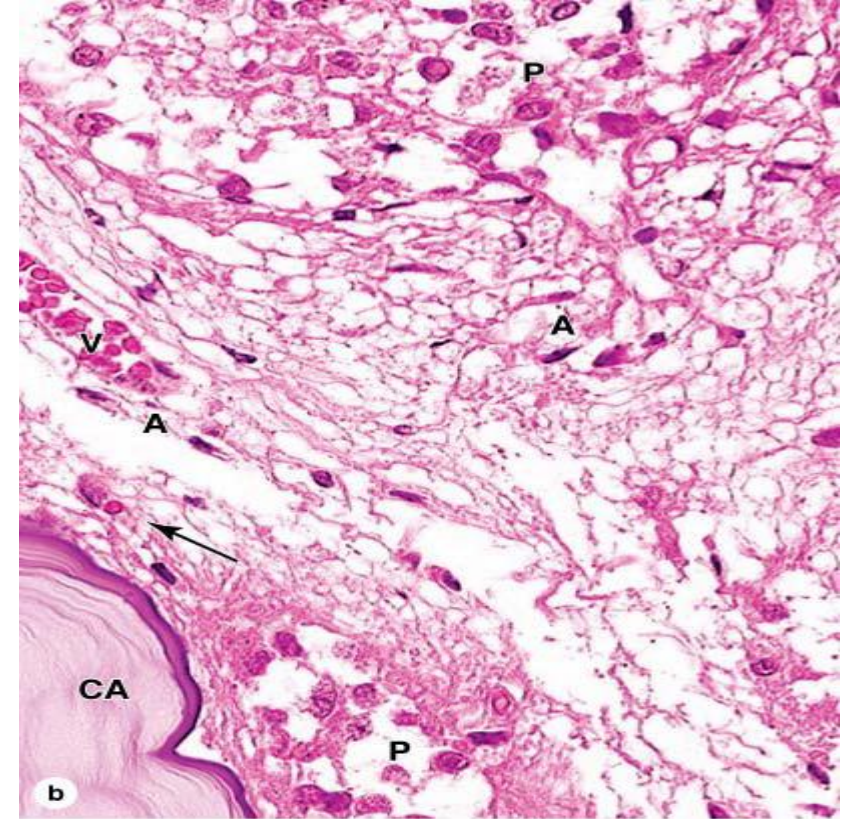


**\* = pineal body**  
**\* = superior colliculus**





Source: Mescher AL: *Junqueira's Basic Histology: Text and Atlas, 12th Edition*: <http://www.accessmedicine.com>  
 Copyright © The McGraw-Hill Companies, Inc. All rights reserved.



Source: Mescher AL: *Junqueira's Basic Histology: Text and Atlas, 12th Edition*: <http://www.accessmedicine.com>  
 Copyright © The McGraw-Hill Companies, Inc. All rights reserved.

The pineal gland is a very small neuroendocrine gland attached to the brain in the roof of the third ventricle. It is covered by the pia mater, which sends septa of connective tissue into the glands, subdividing groups of parenchymal cells called pinealocytes. (a): The micrograph shows a group of pinealocytes surrounded by septa (S) containing venules (V) and capillaries (arrows). Also seen is an extracellular mineral deposit called a corpus arenaceum (CA) of unknown physiological significance but an excellent marker for the pineal. X40. H&E.

(b): At higher magnification the numerous large pinealocytes (P) with euchromatic nuclei can be compared to the relatively few astrocytes (A) which have darker, more elongated nuclei. Astrocytes are located mainly within septa and near small blood vessels (V). Capillaries (arrow) are not nearly as numerous as in other endocrine glands. At the lower left is a part of a very large corpus arenaceum (CA), the calcified structures also known as brain sand. Along the septa run unmyelinated tracts of sympathetic fibers, associated indirectly with photoreceptive neurons in the retinas and running to the pinealocytes to stimulate melatonin release in periods of darkness. Levels of circulating melatonin are one factor determining the diurnal rhythms of hormone release and physiological activities throughout the body. X100. H&E.

***THANK YOU***

