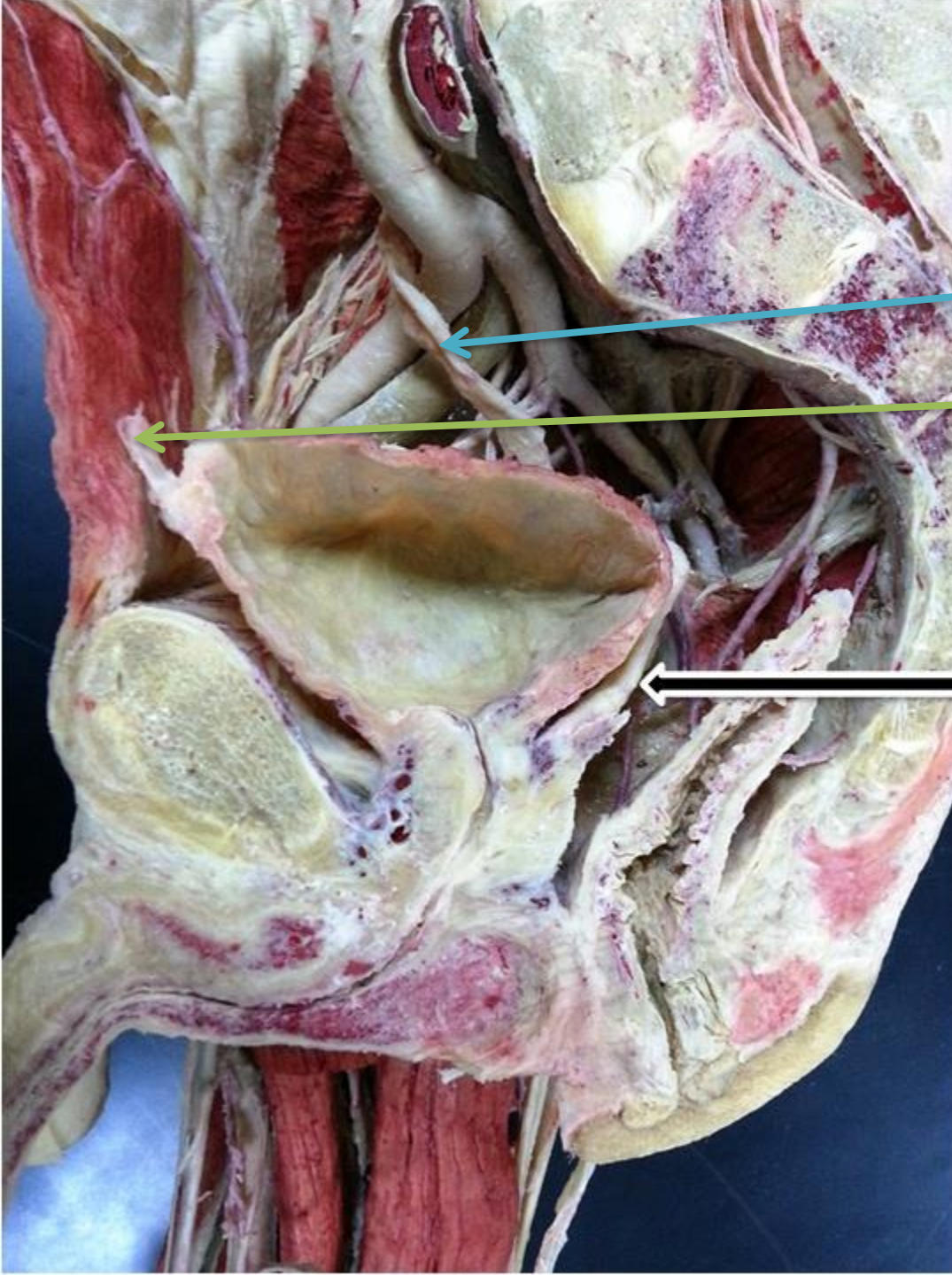


UGS Lab 2

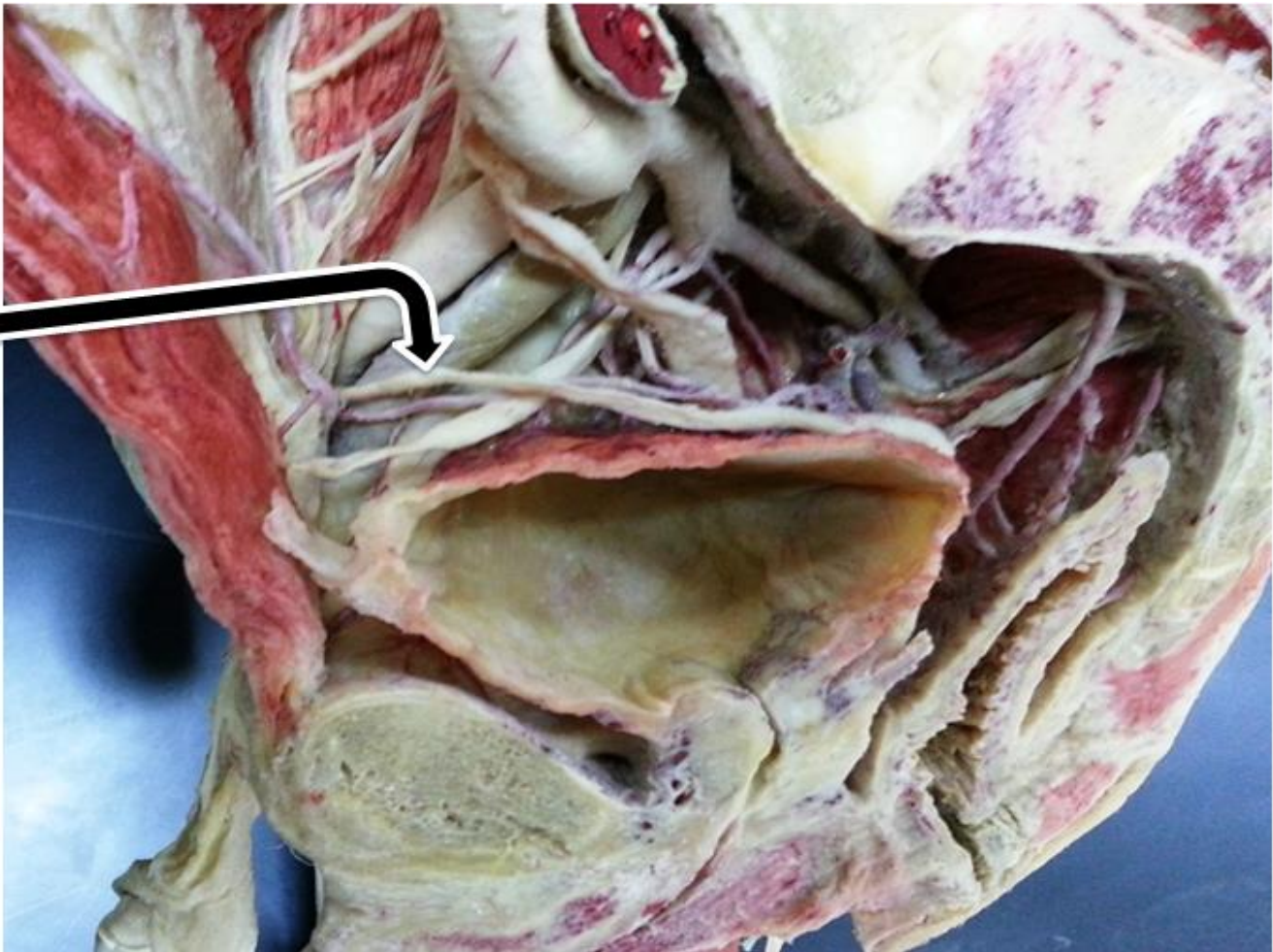


Ureter

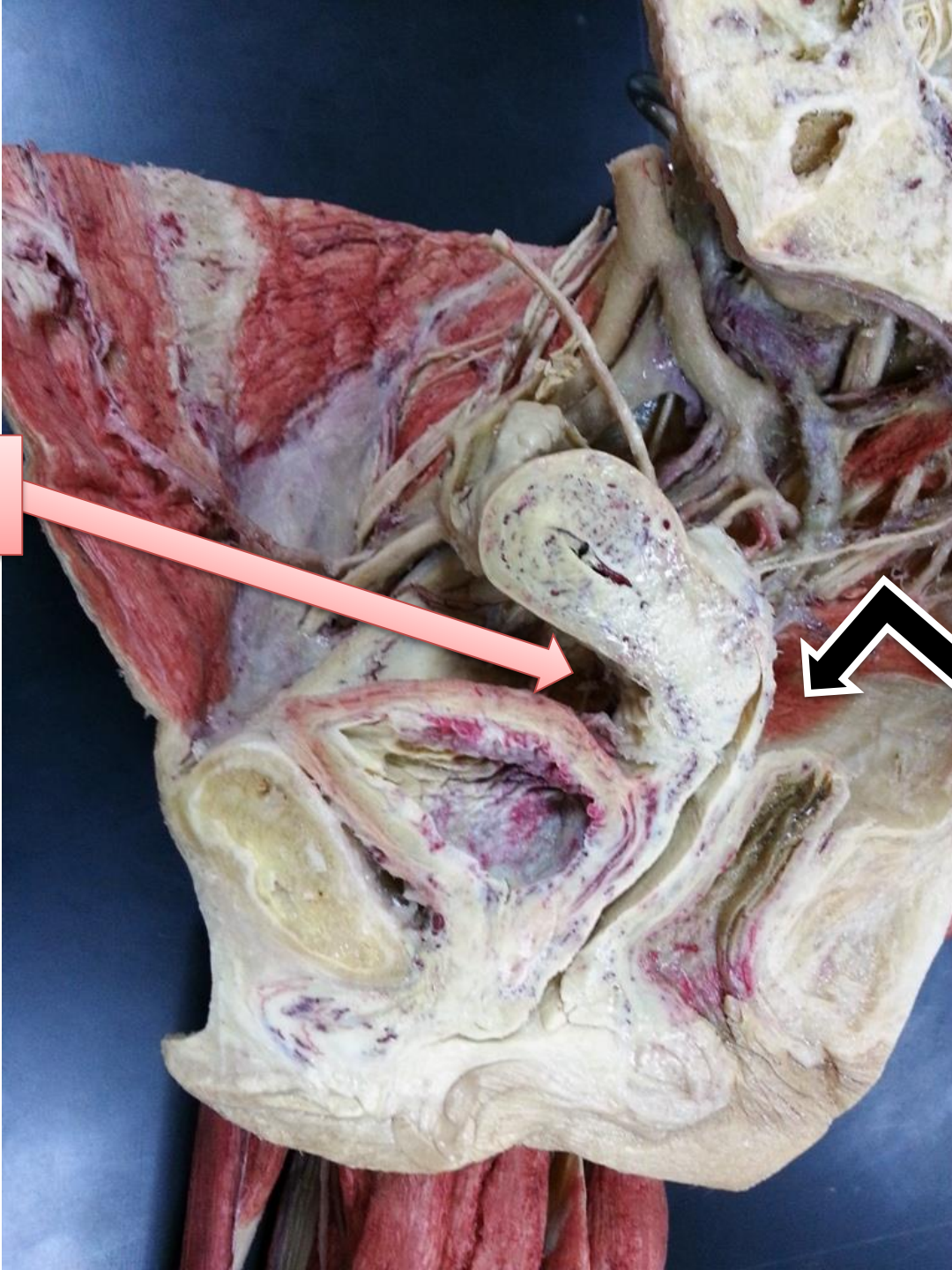
Median umbilical ligament

Vas deferens

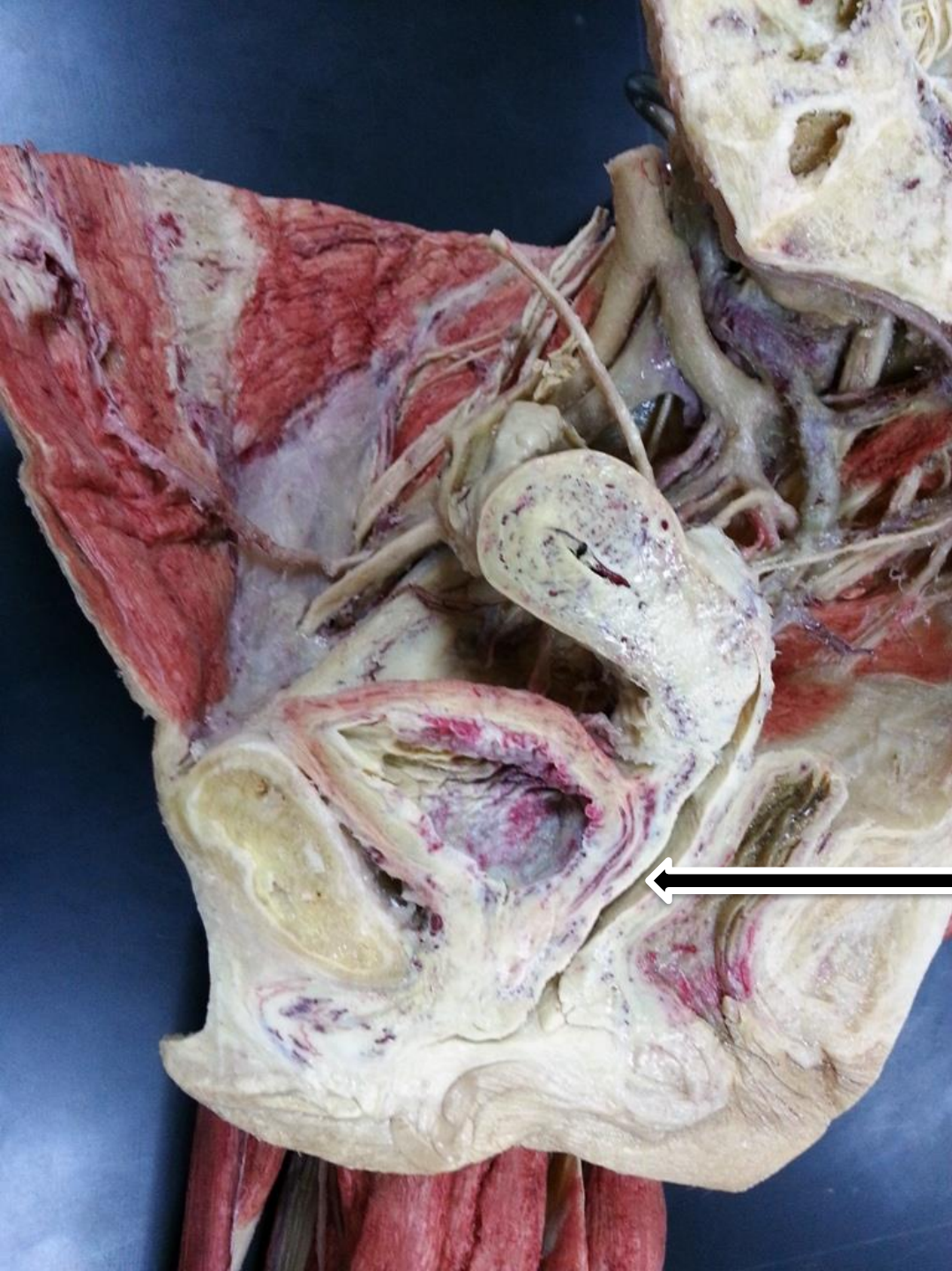
Vas deferens



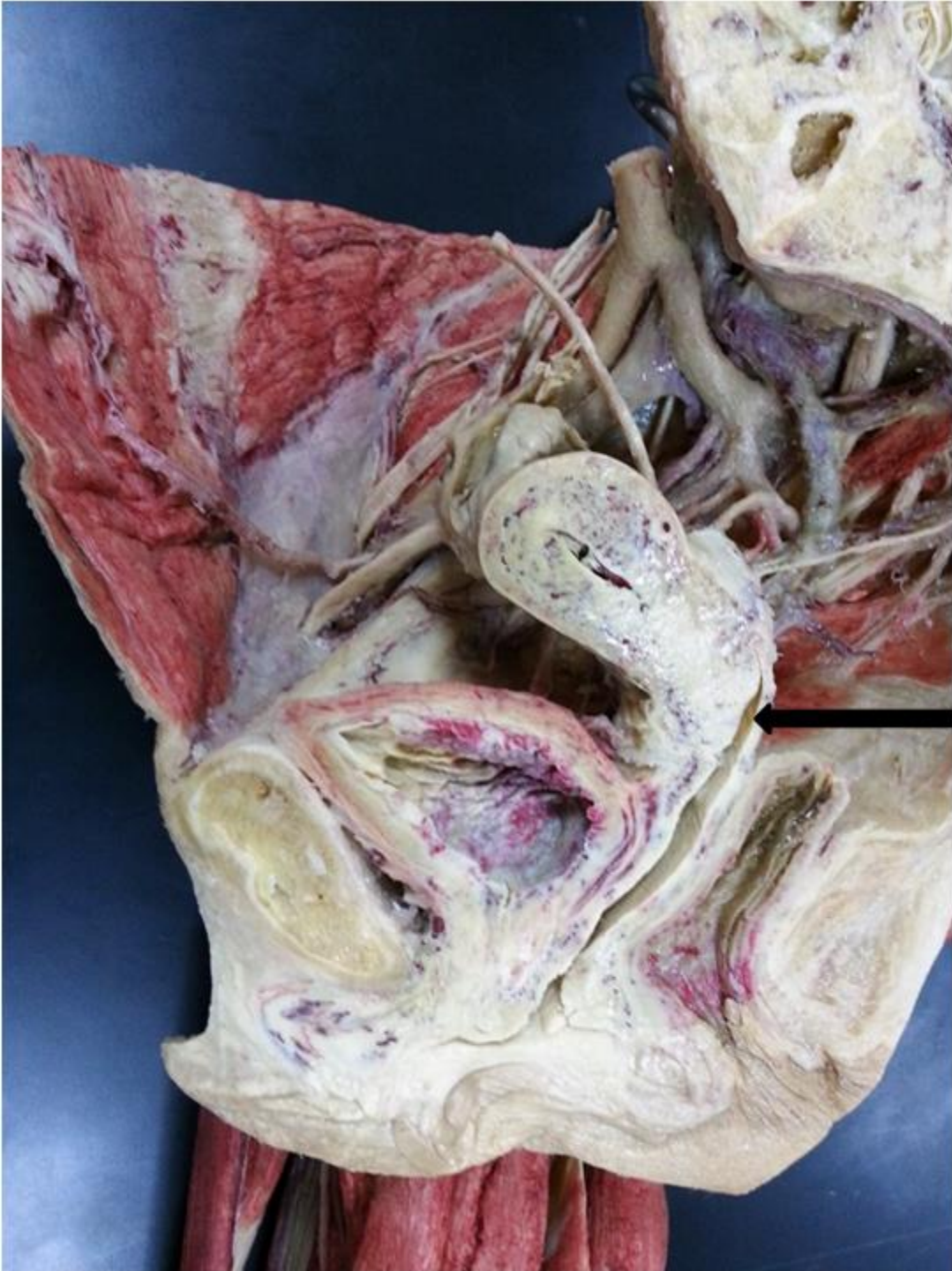**Uterovesical
pouch**



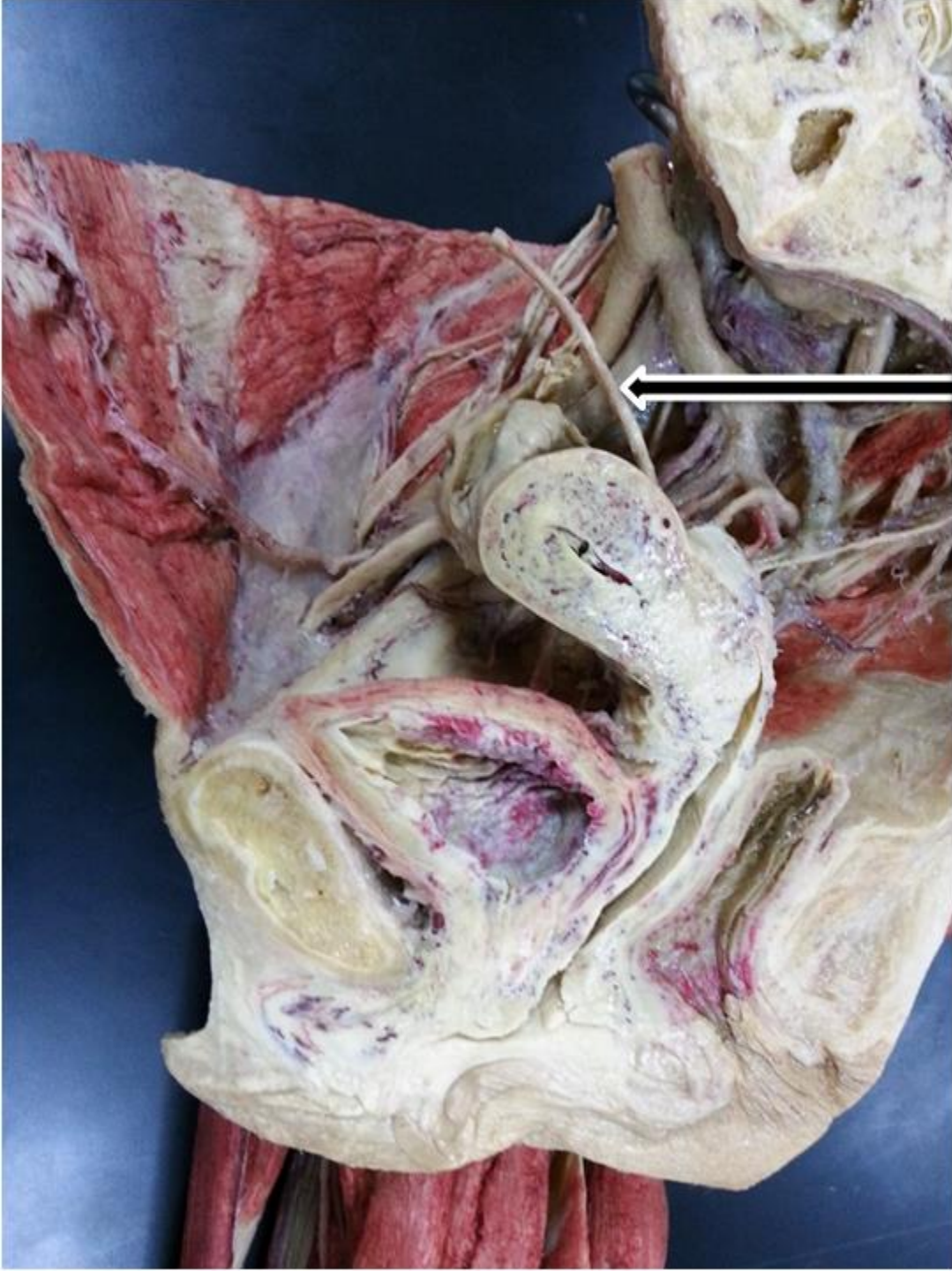
Pouch of Douglas



Vagina

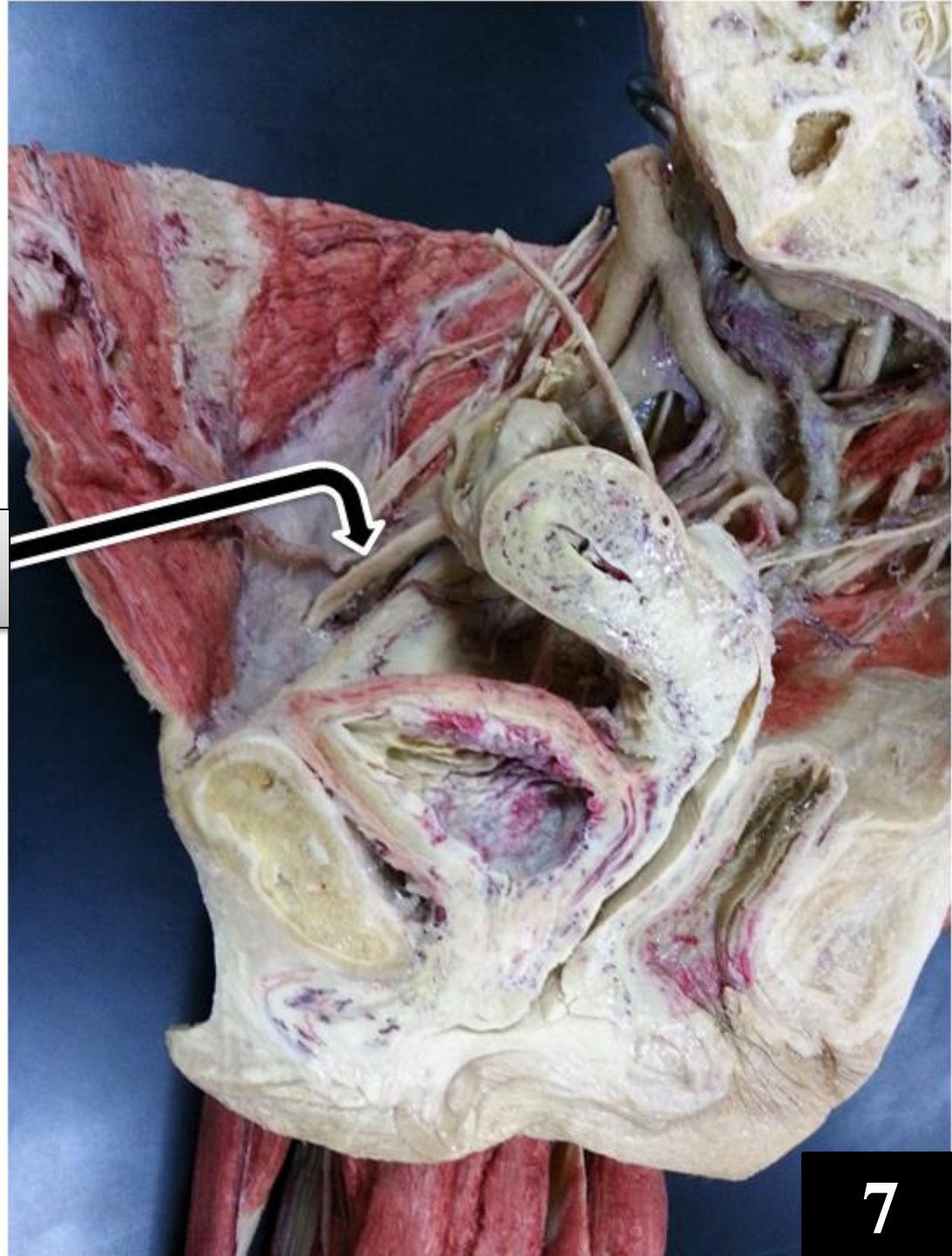


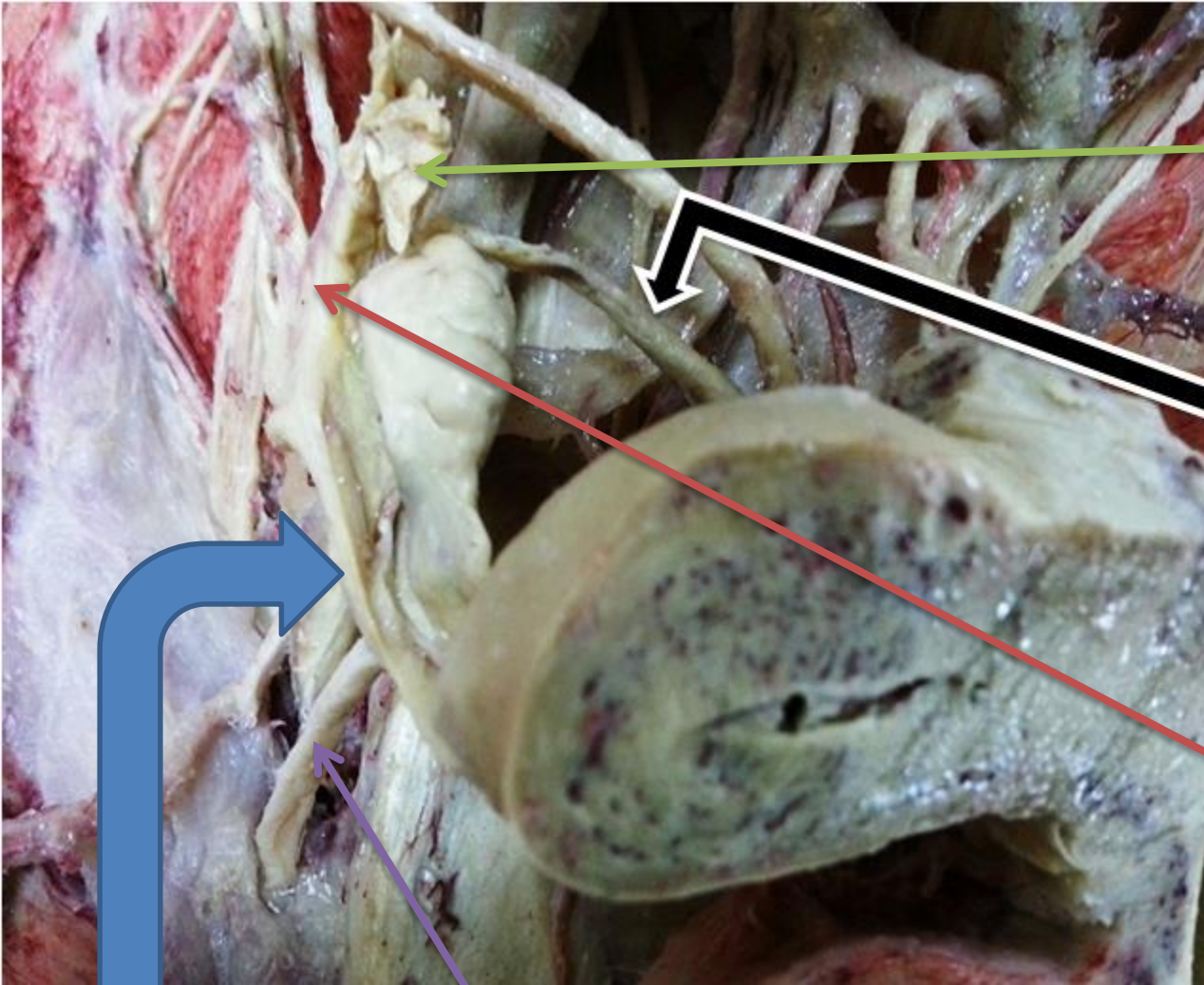
Posterior vaginal fornix



Ureter

**Round ligament of
uterus**





Fimbria of infundibulum

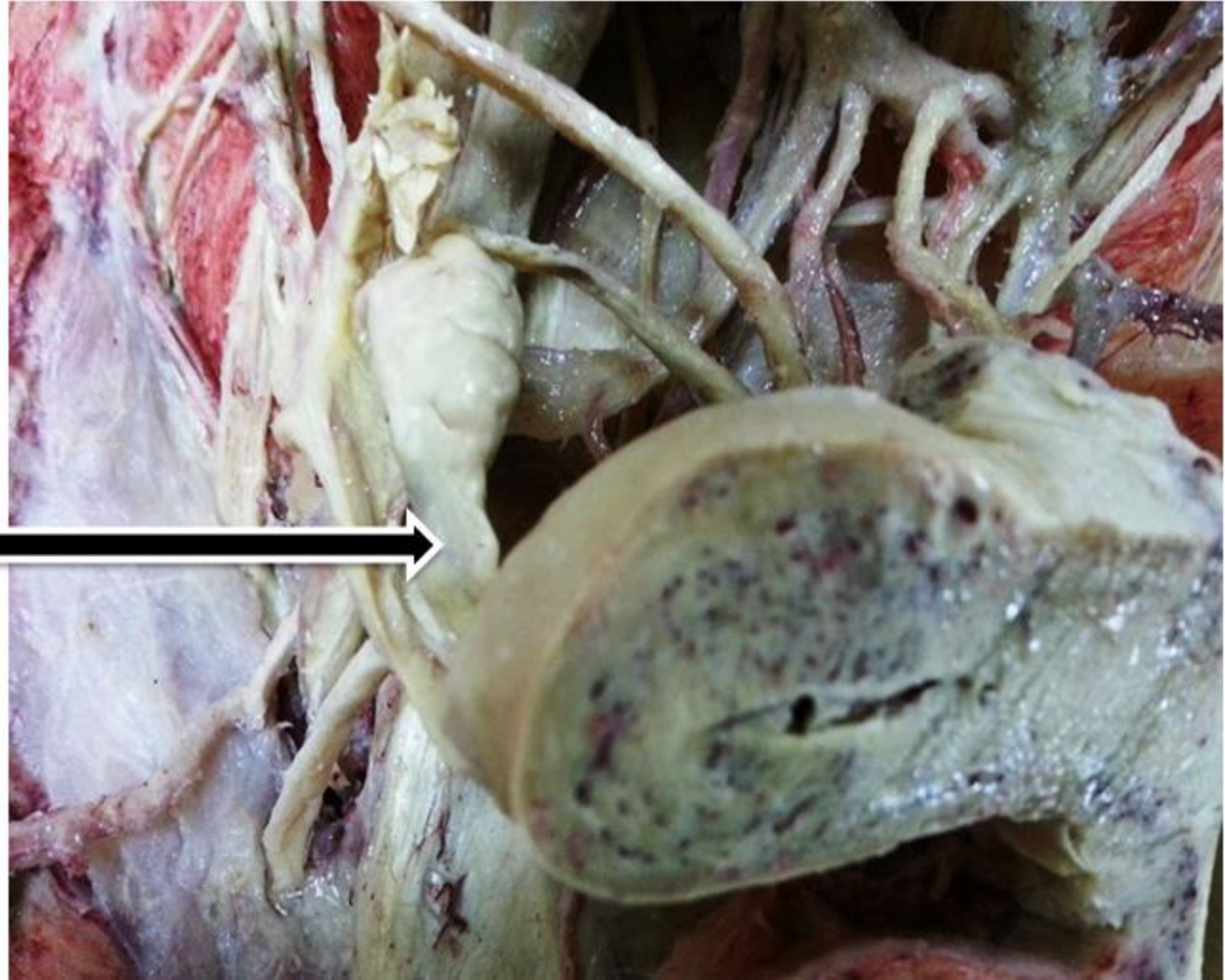Ovarian ligament

Ampula of uterine tube

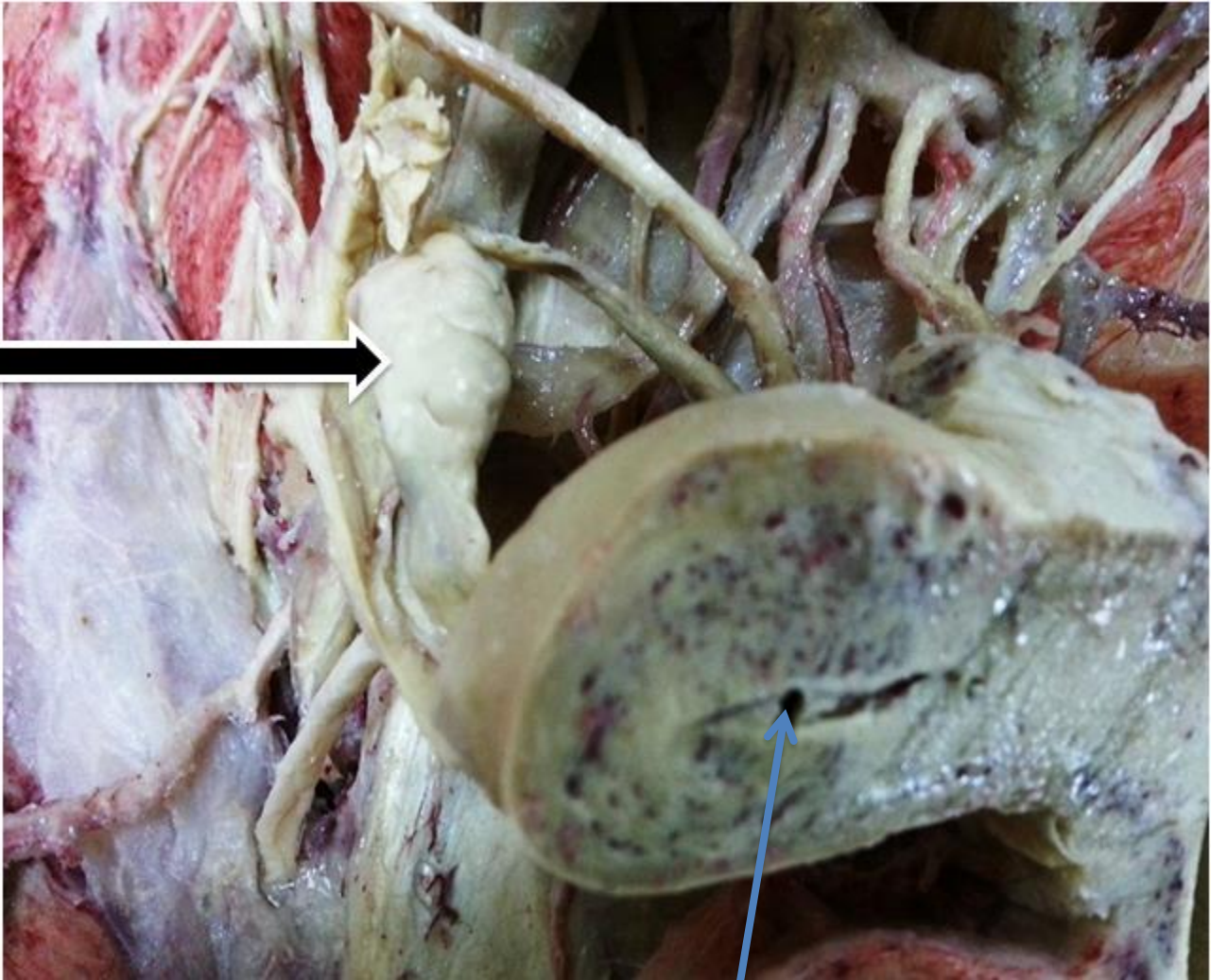
Round ligament of uterus

Isthmus part of uterine tube

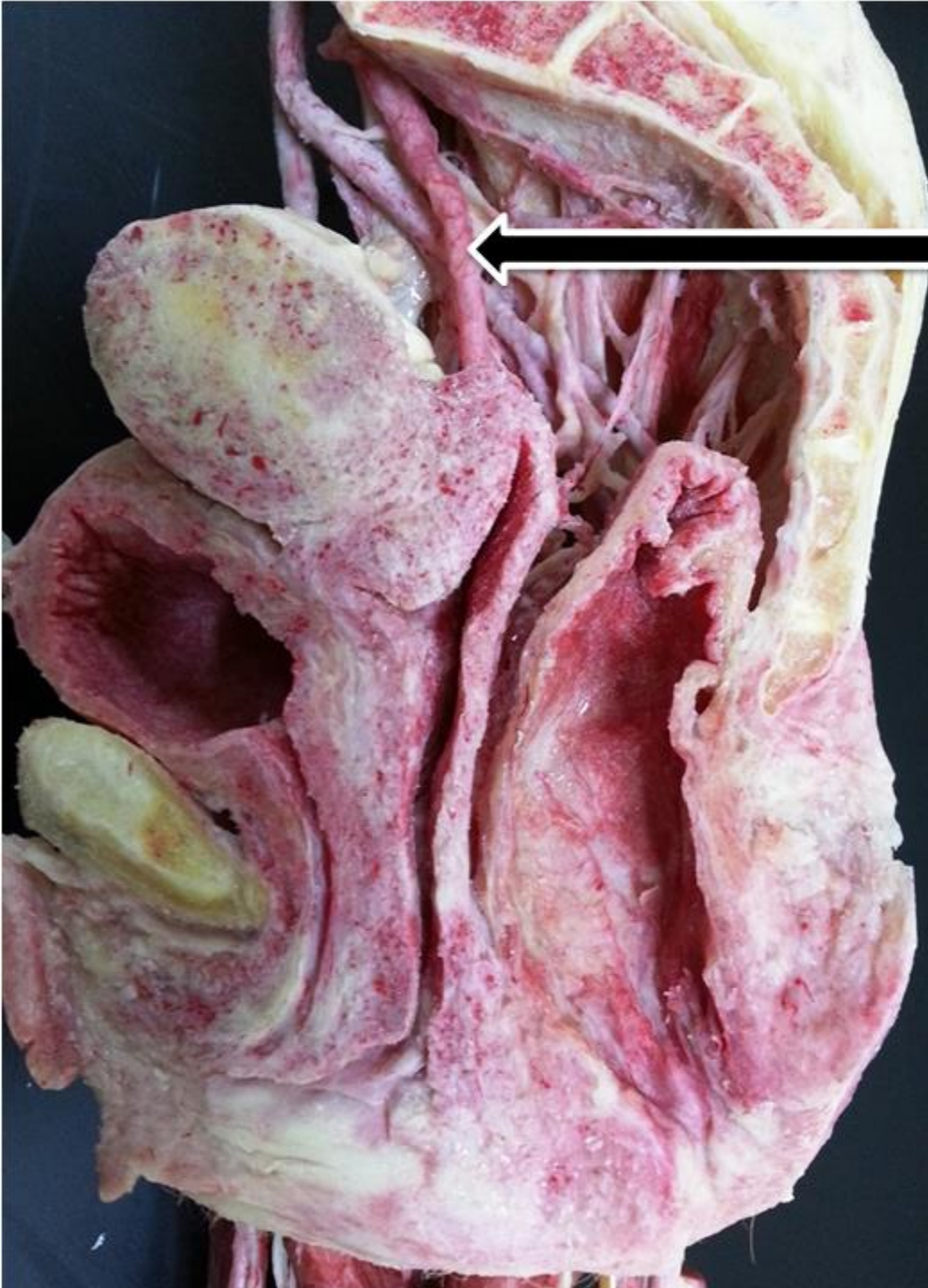
**Suspensory ligament
of ovary**



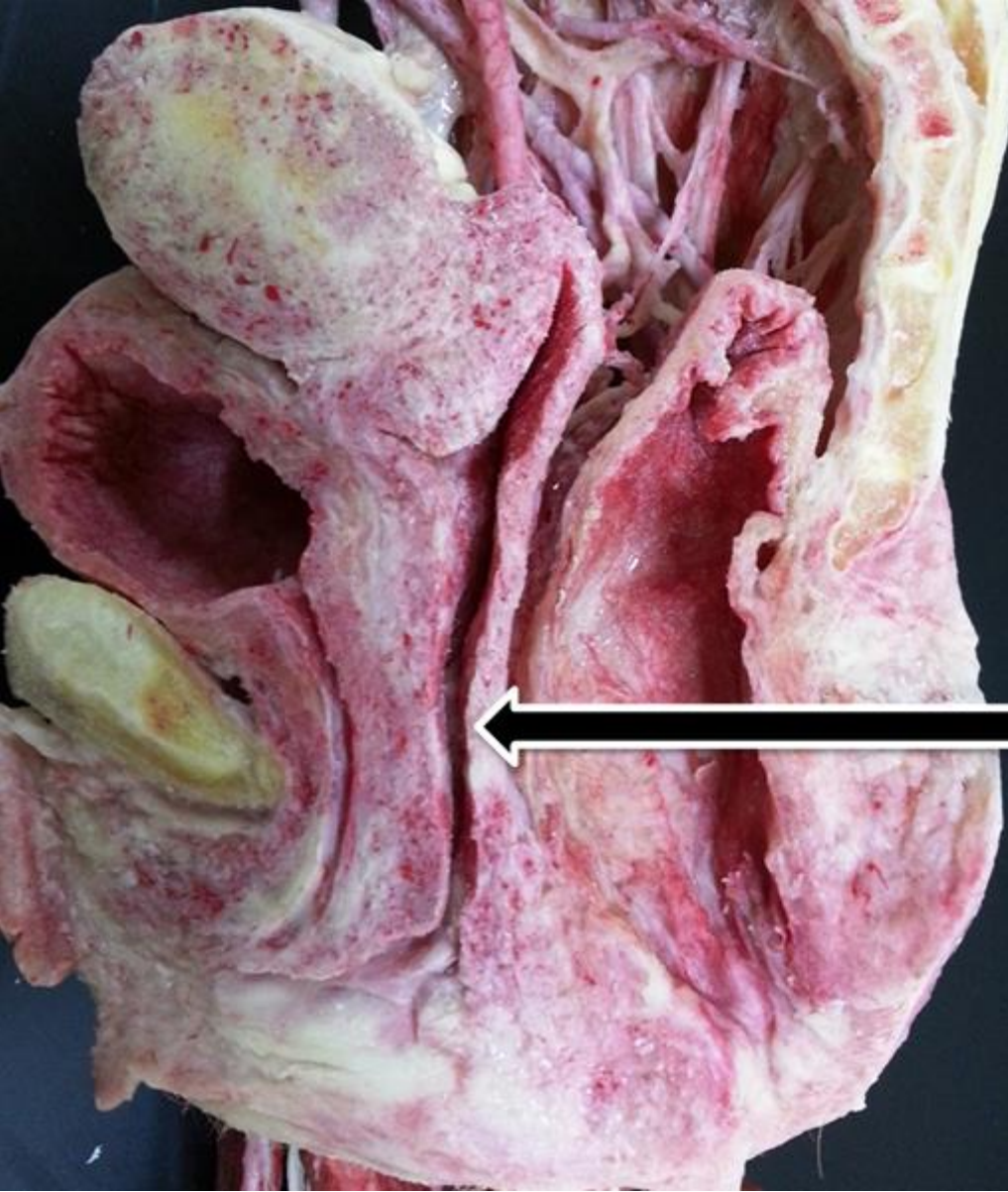
Ovary



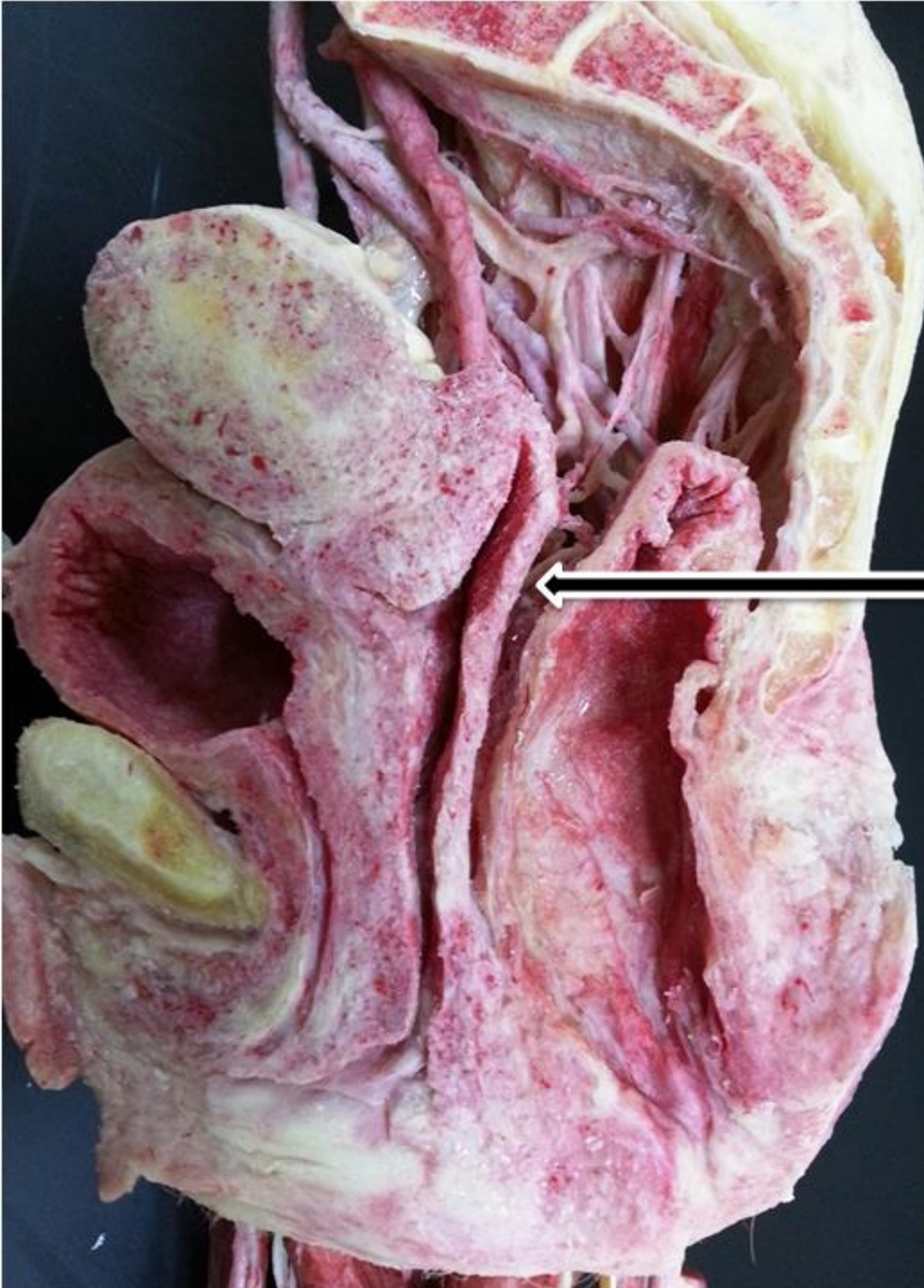
Uterine cavity



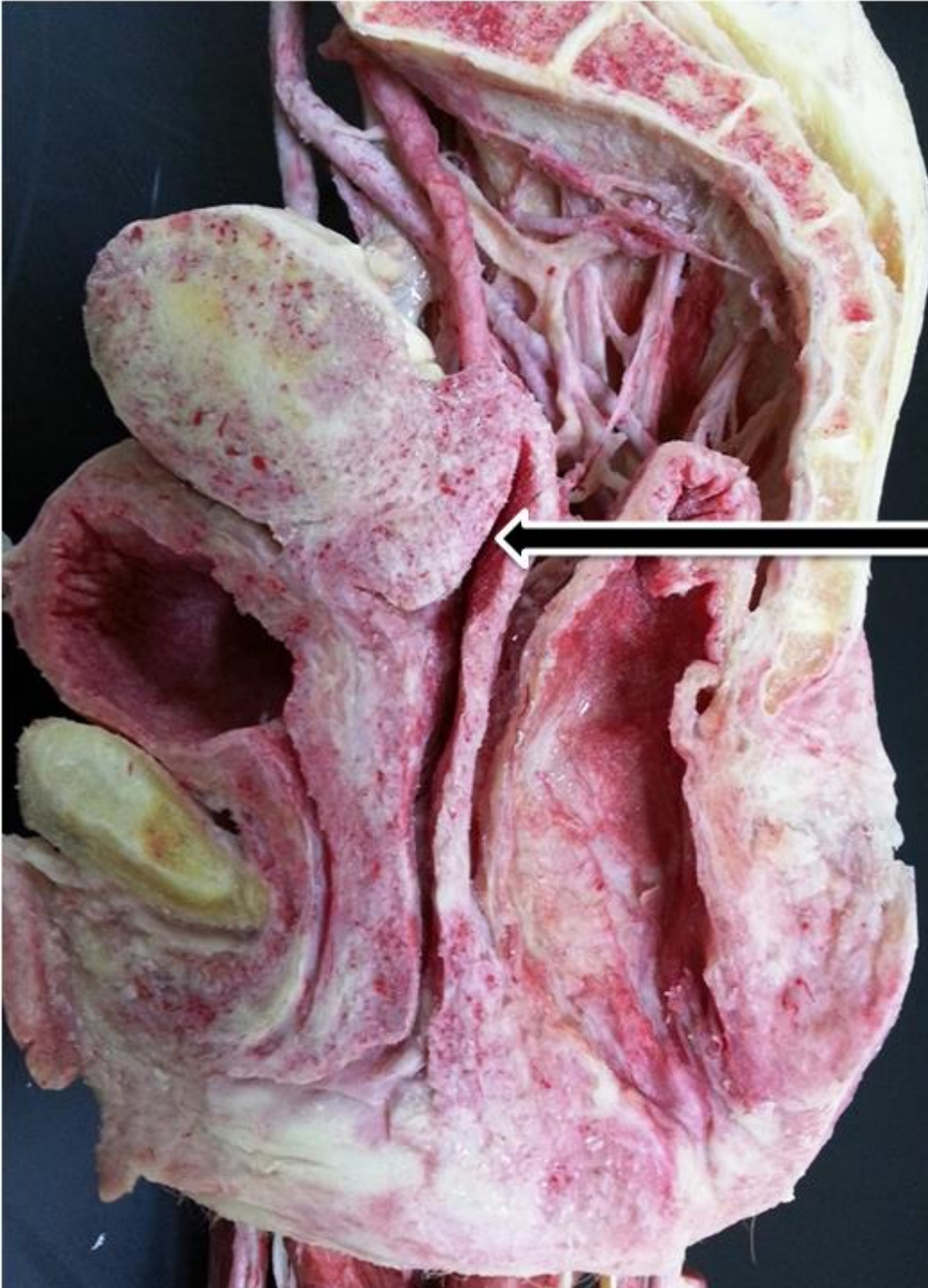Round ligament of uterus



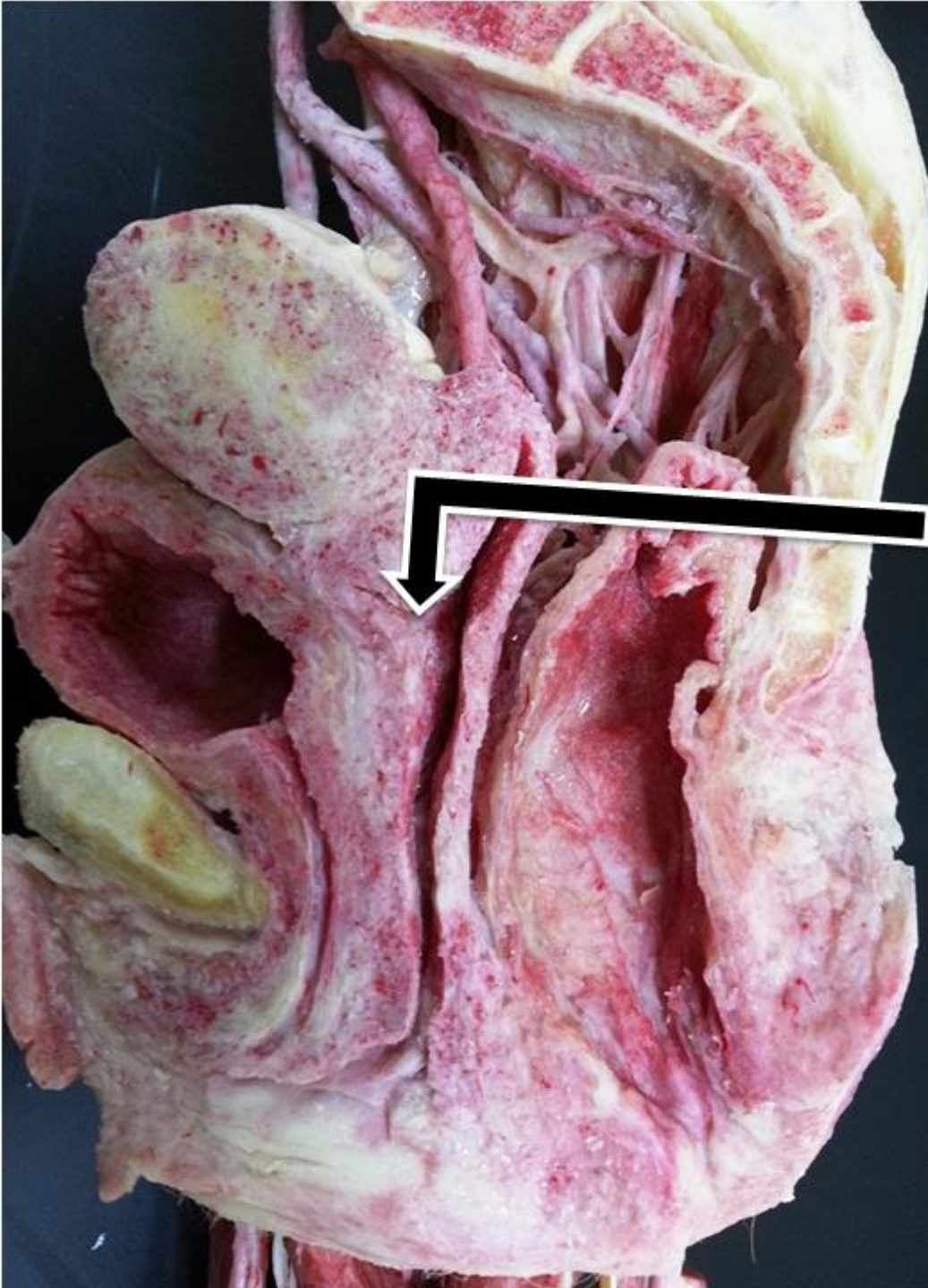Vagina



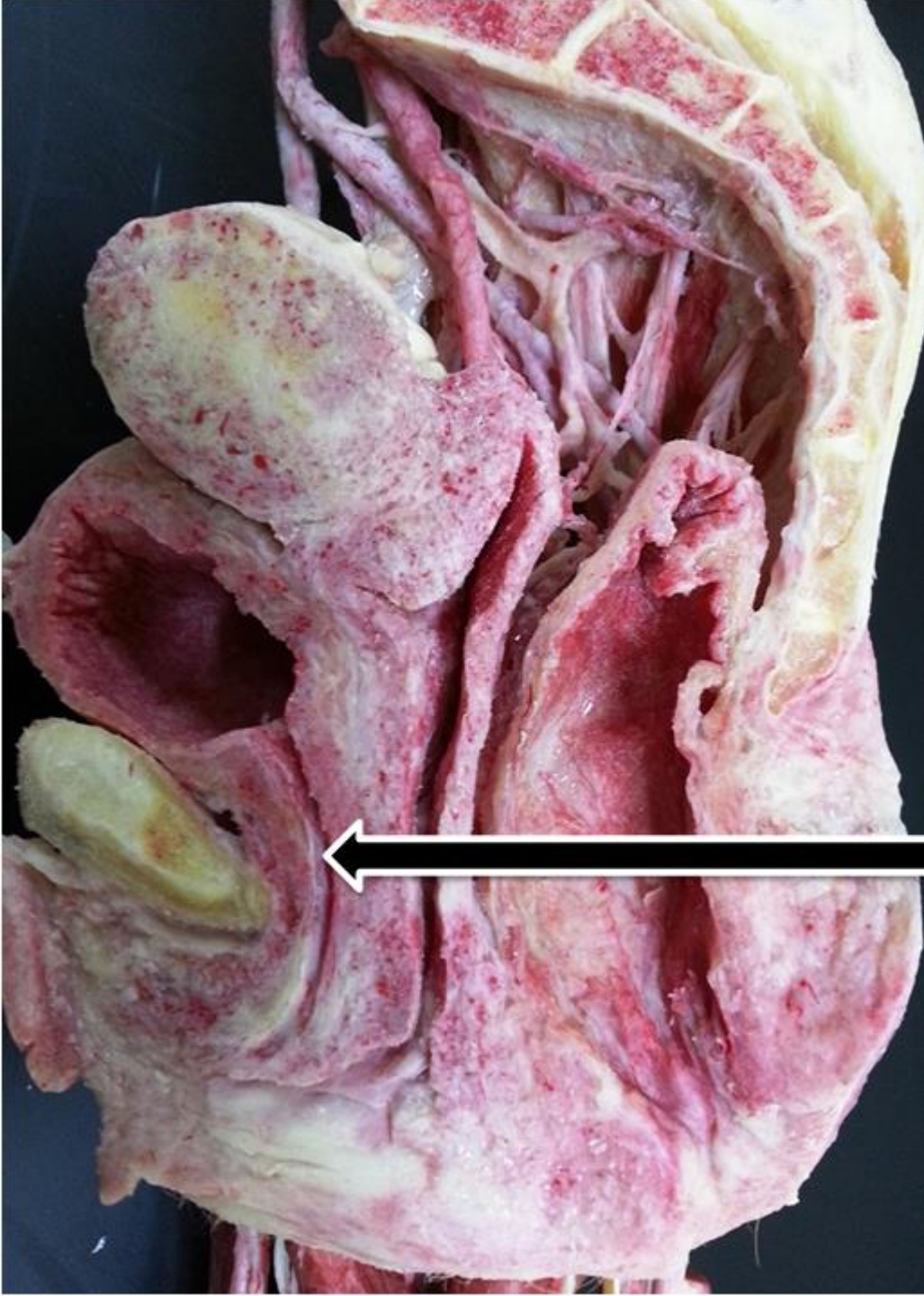Pouch of Douglas



Posterior vaginal fornix

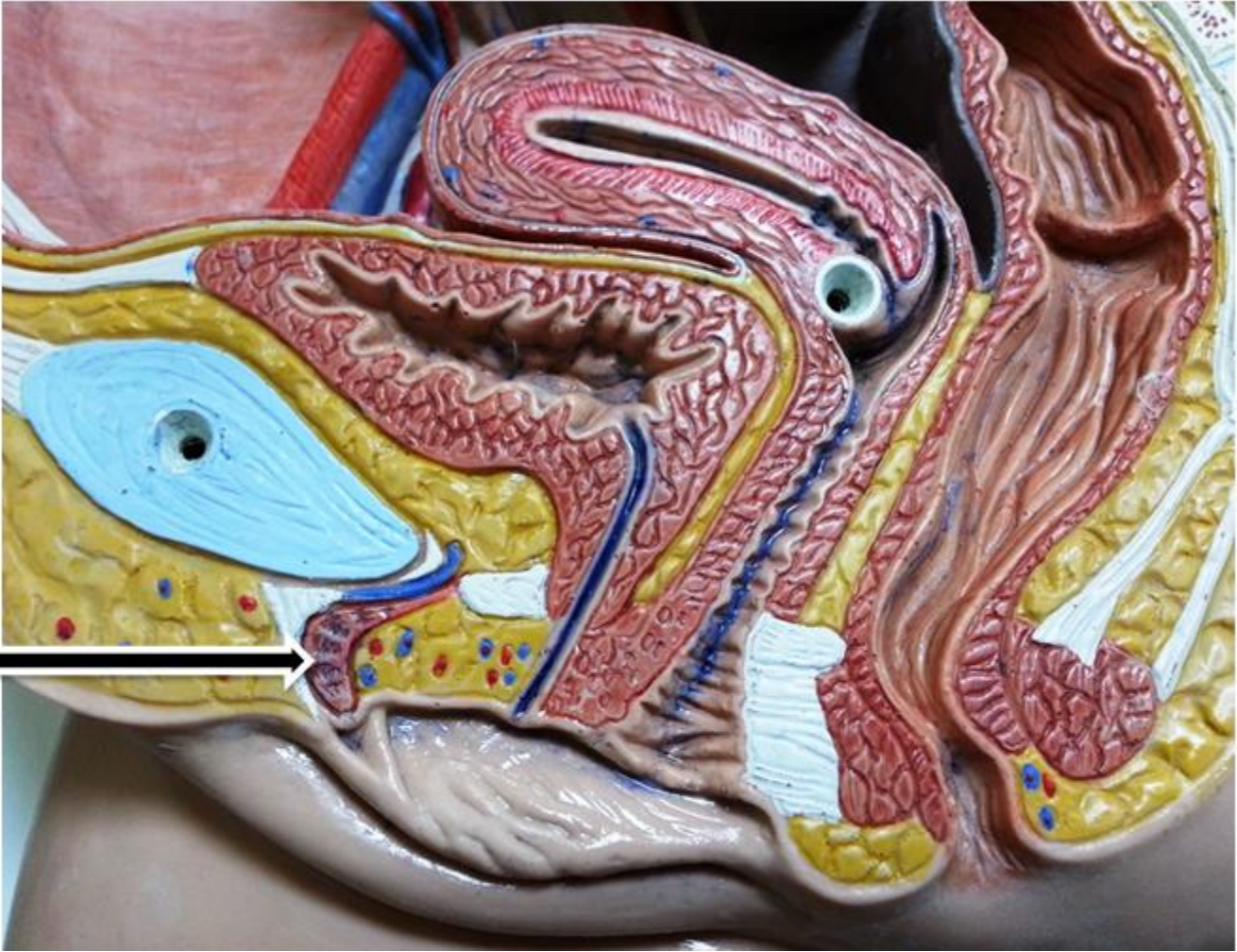

**Anterior vaginal
fornix.**

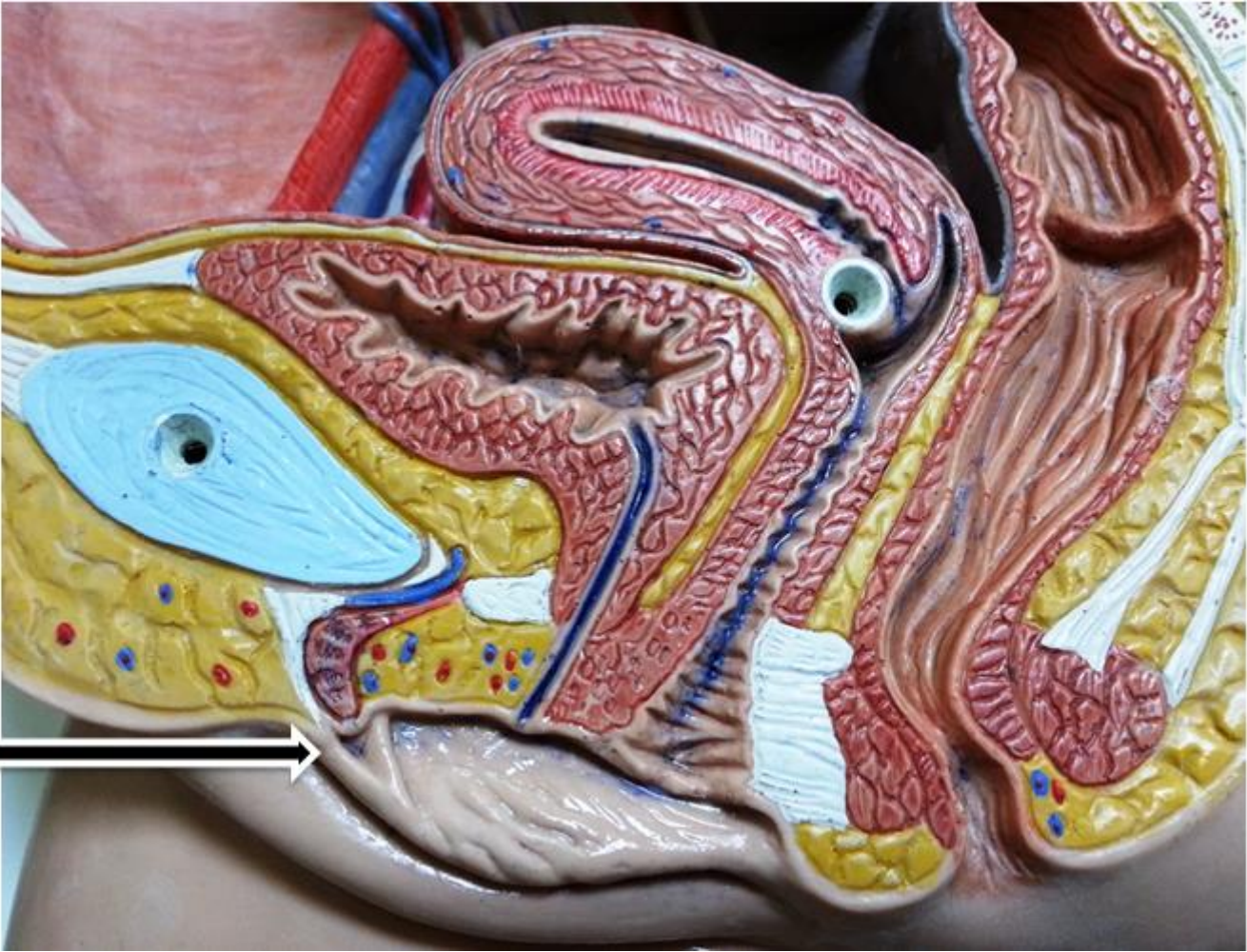

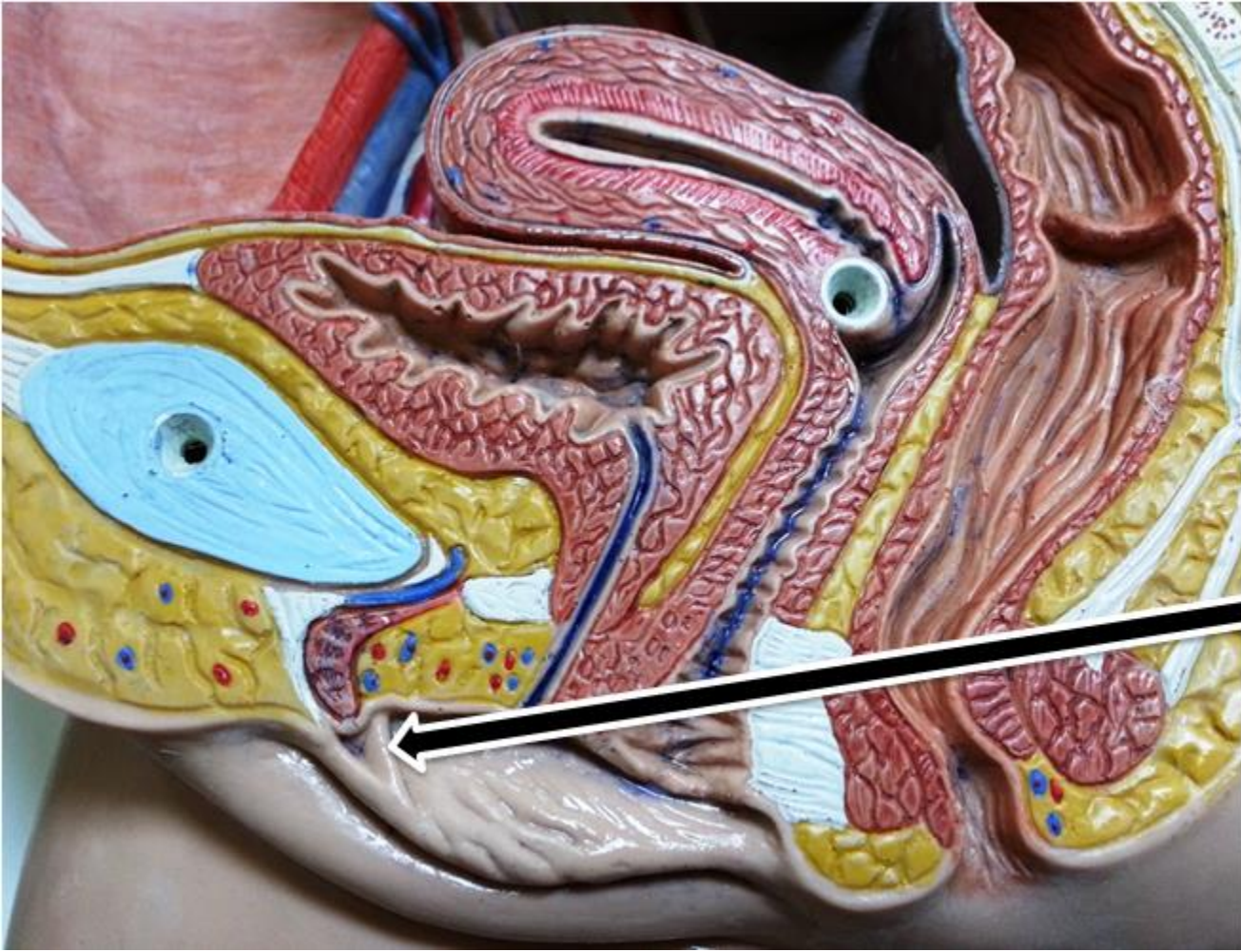
Female Urethra

Clitoris

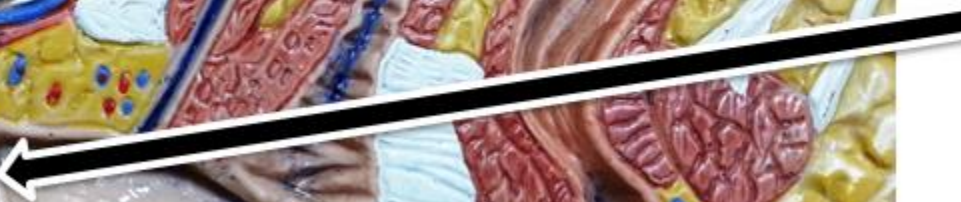

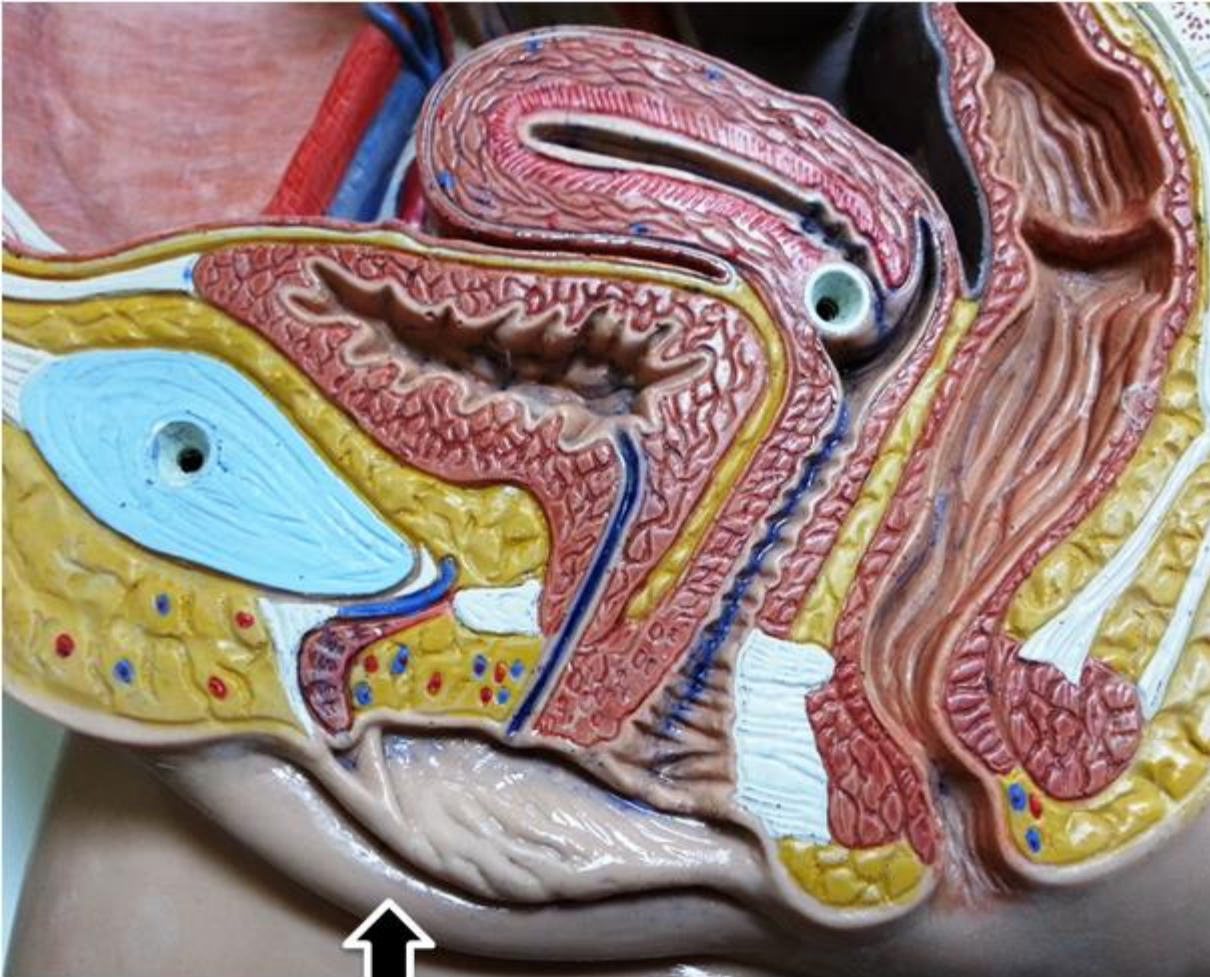Prepuce



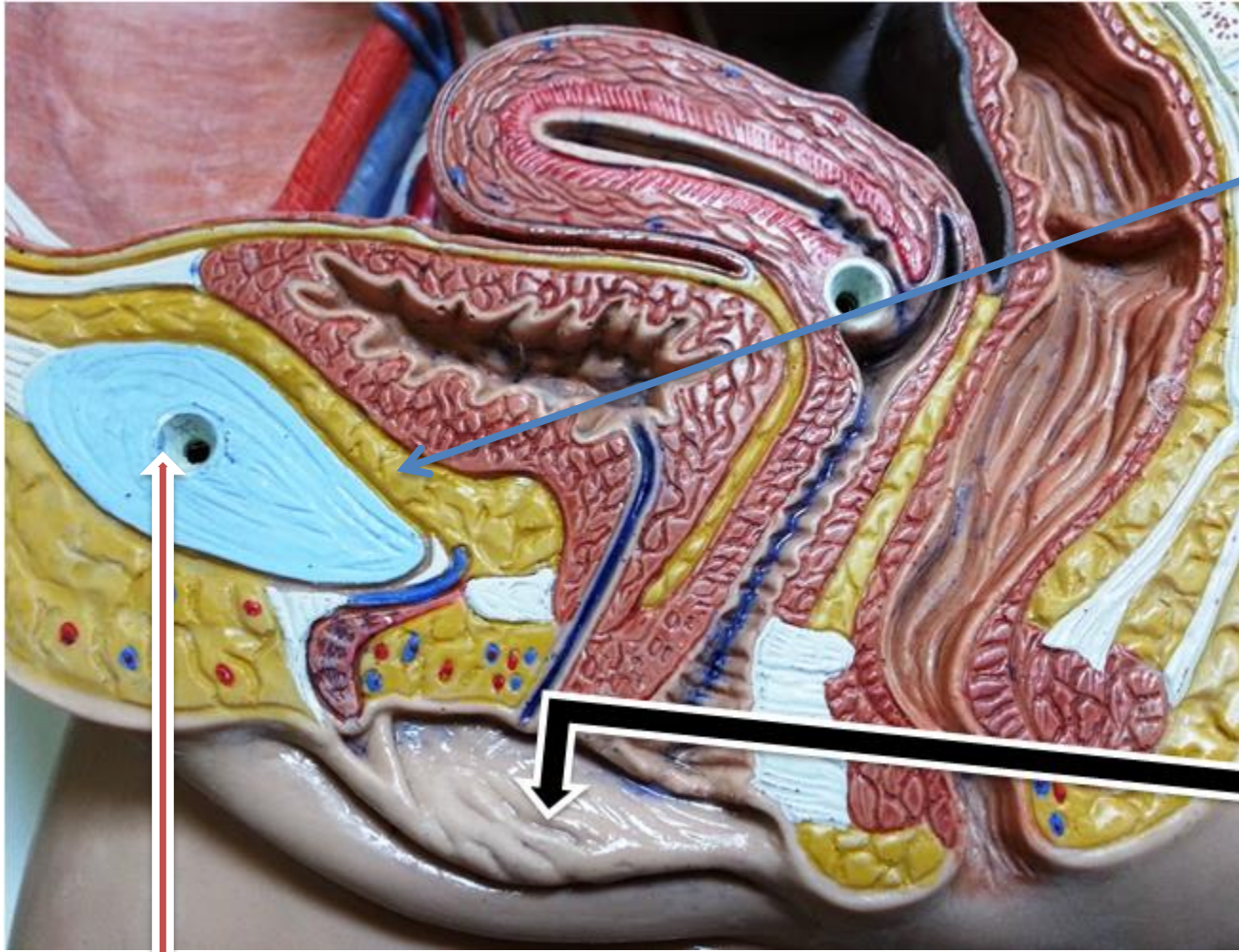


Frenulum





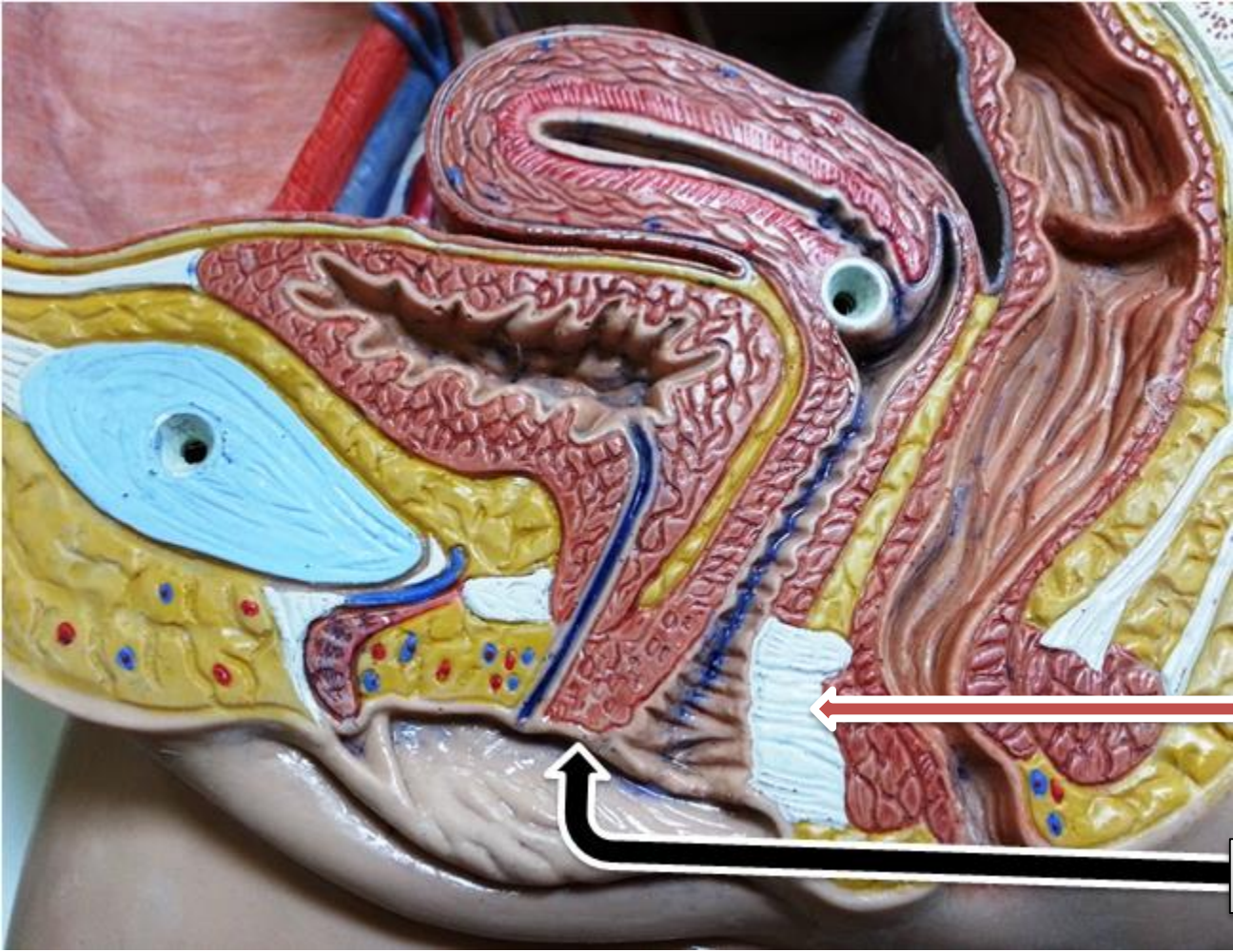
Labia majora



Retropubic pad of fat

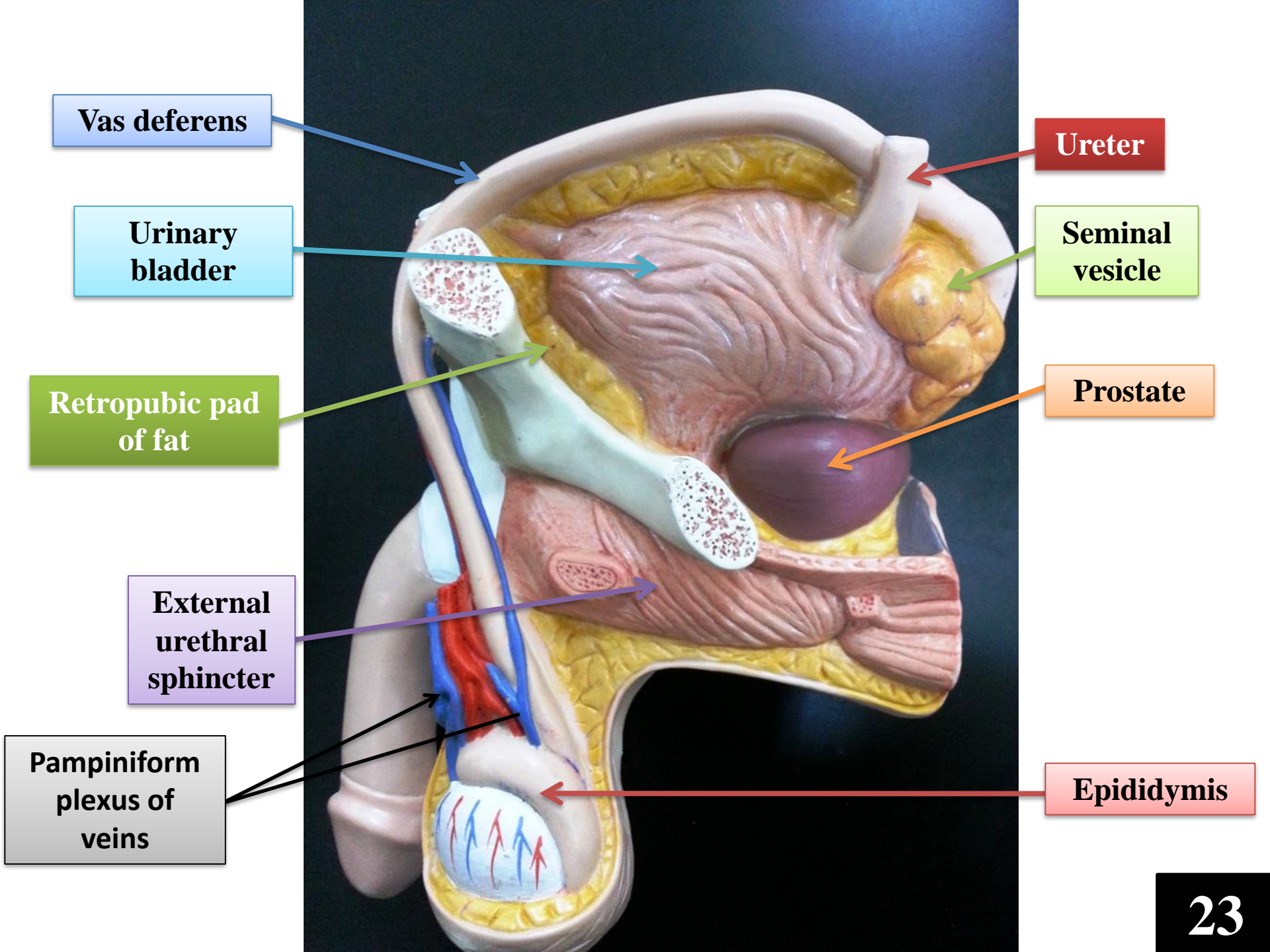
Labia minora

Pubic bone



Perineal body

vestibule



Vas deferens

Urinary bladder

Retropubic pad of fat

External urethral sphincter

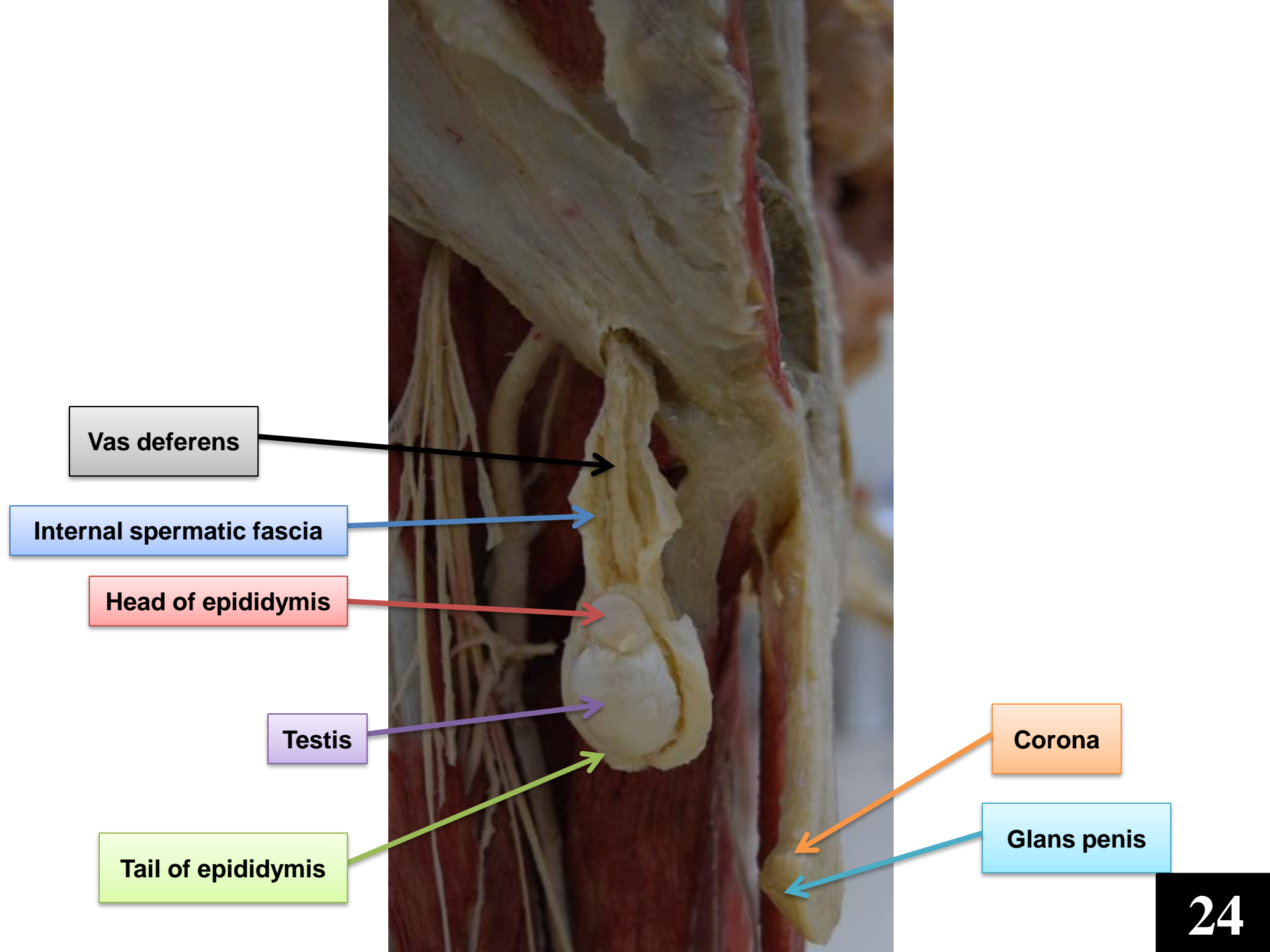
Pampiniform plexus of veins

Ureter

Seminal vesicle

Prostate

Epididymis



Vas deferens

Internal spermatic fascia

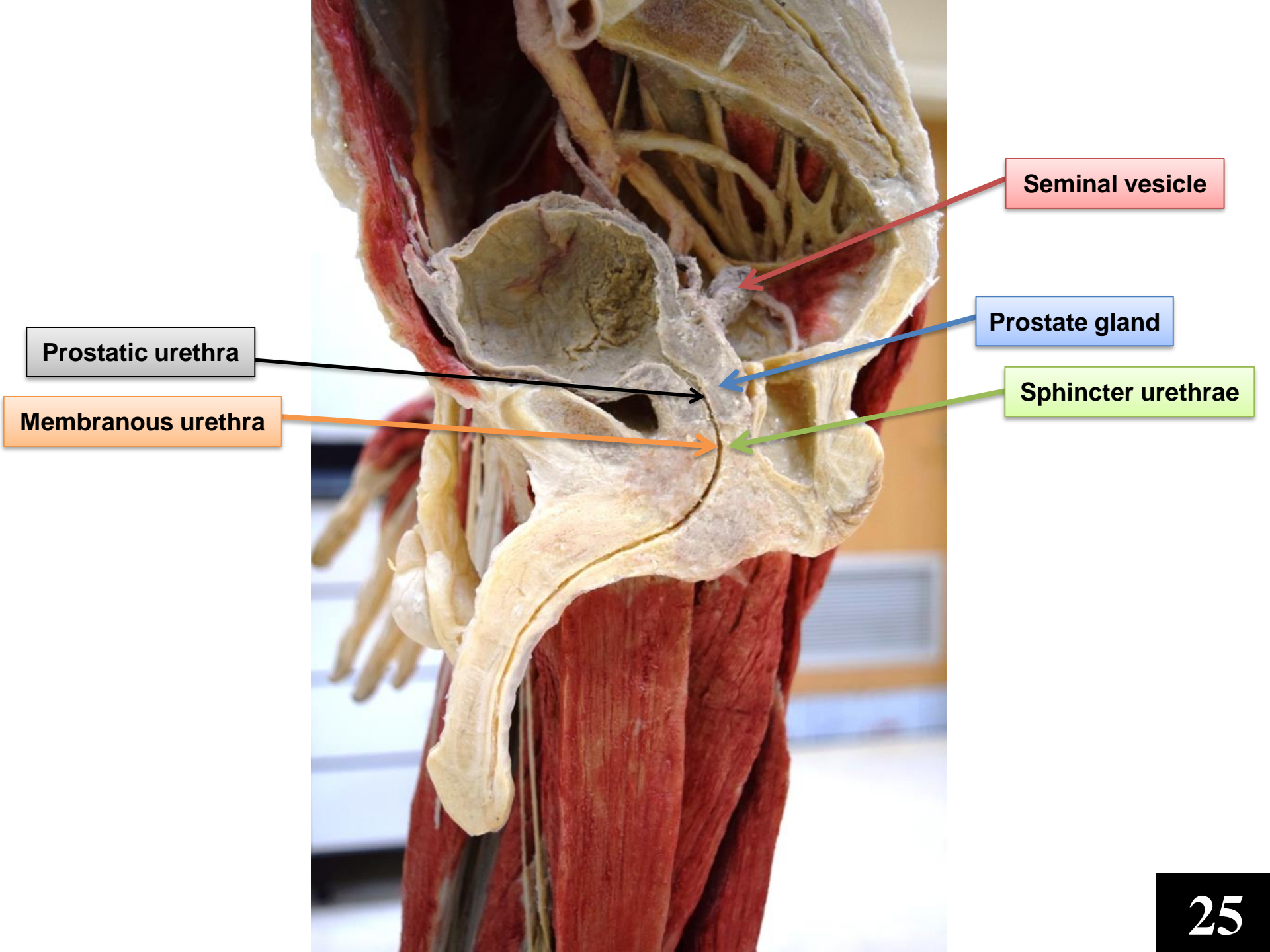
Head of epididymis

Testis

Tail of epididymis

Corona

Glans penis



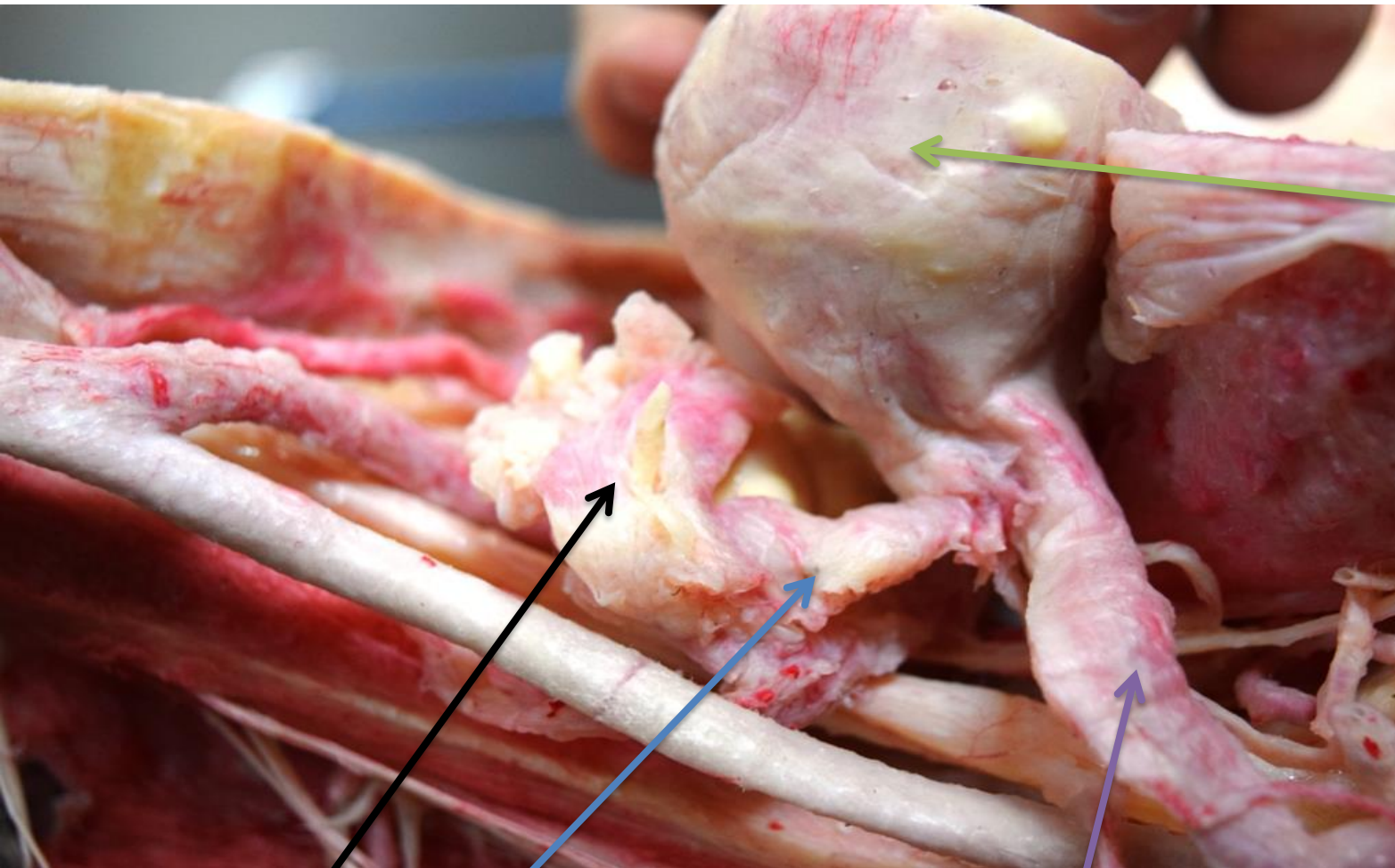
Prostatic urethra

Membranous urethra

Seminal vesicle

Prostate gland

Sphincter urethrae

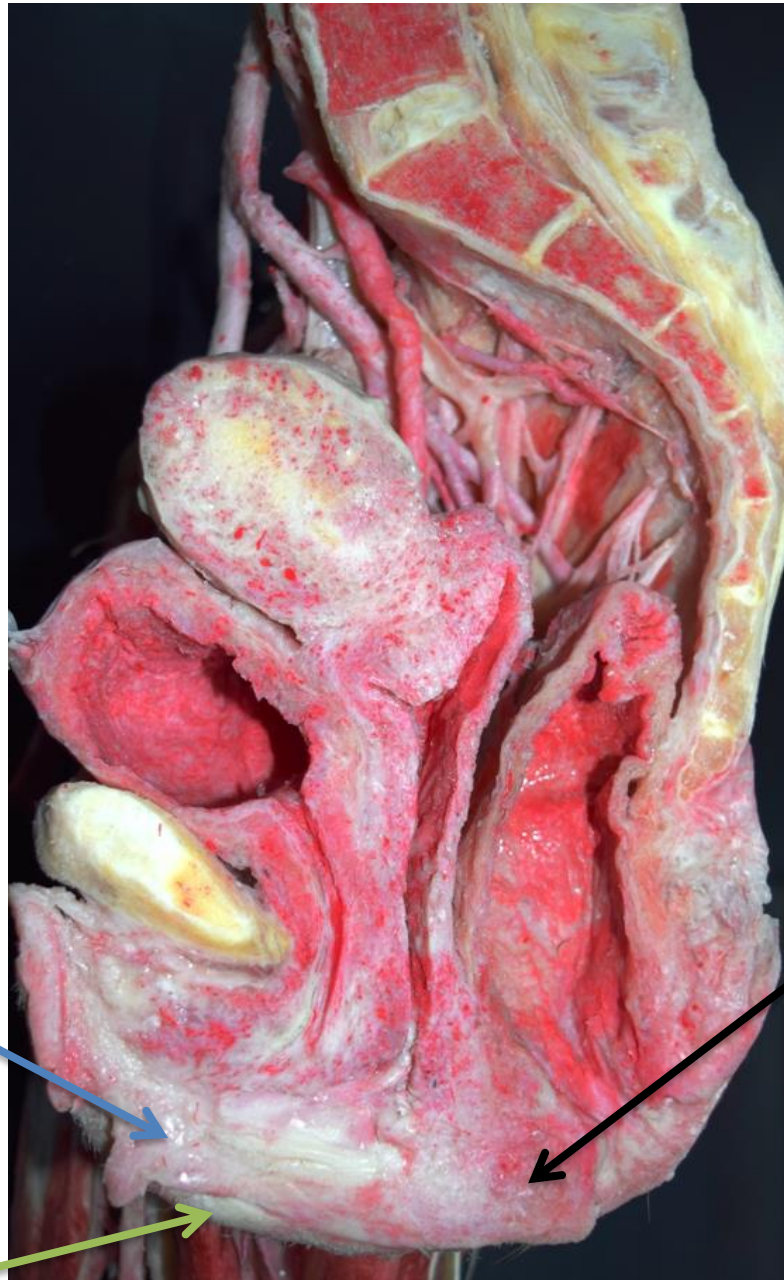

Fundus of uterus

Uterine tube

Infundibulum of uterine tube

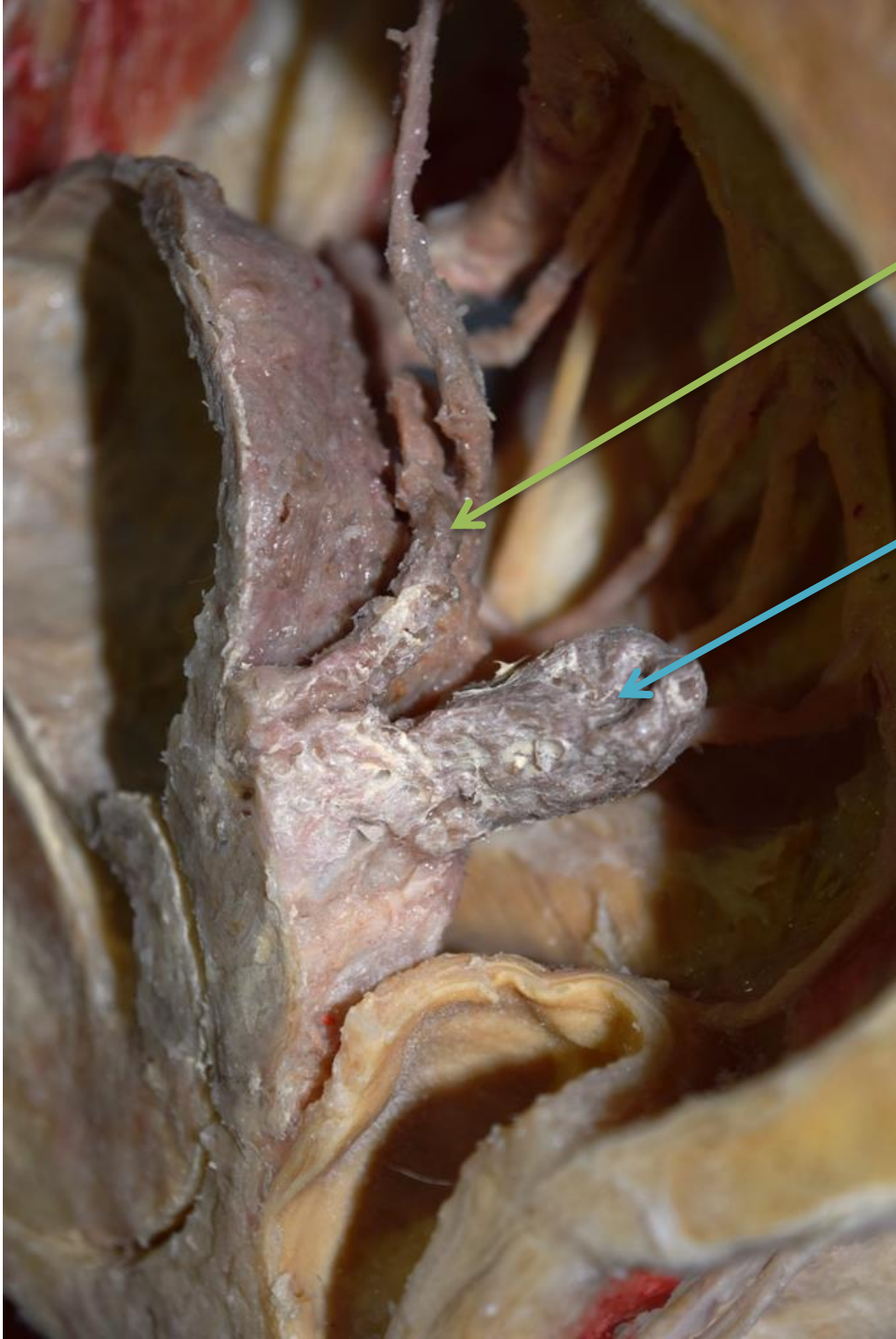
Round ligament of uterus



Labia minora

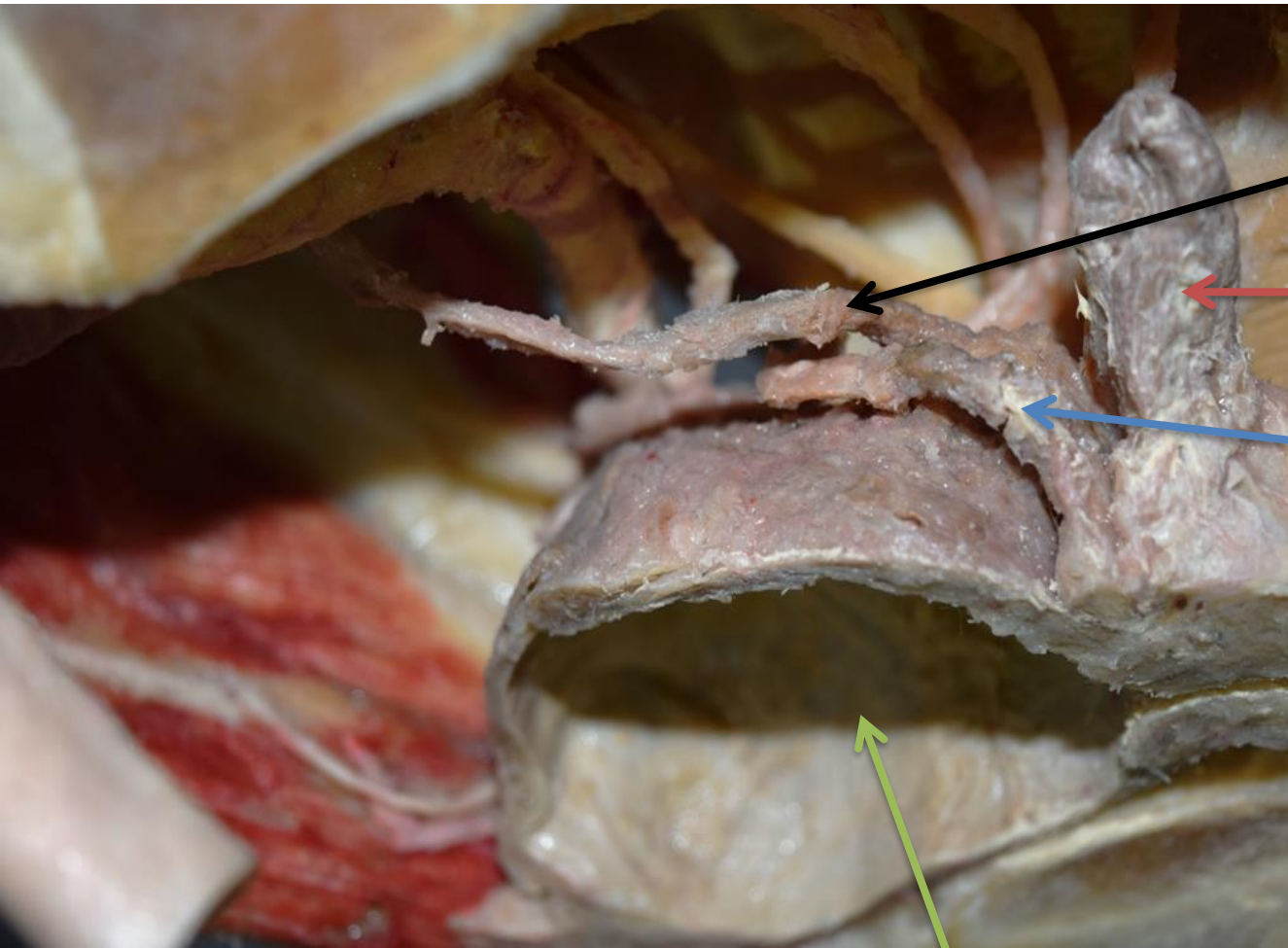
Peineal body

Labia majora



Vas
deferens

Seminal
vesicle



Ureter

Seminal vesicle

Vas deferens

Urinary bladder

**External urethral
sphincter (sphincter
urethrae)**

