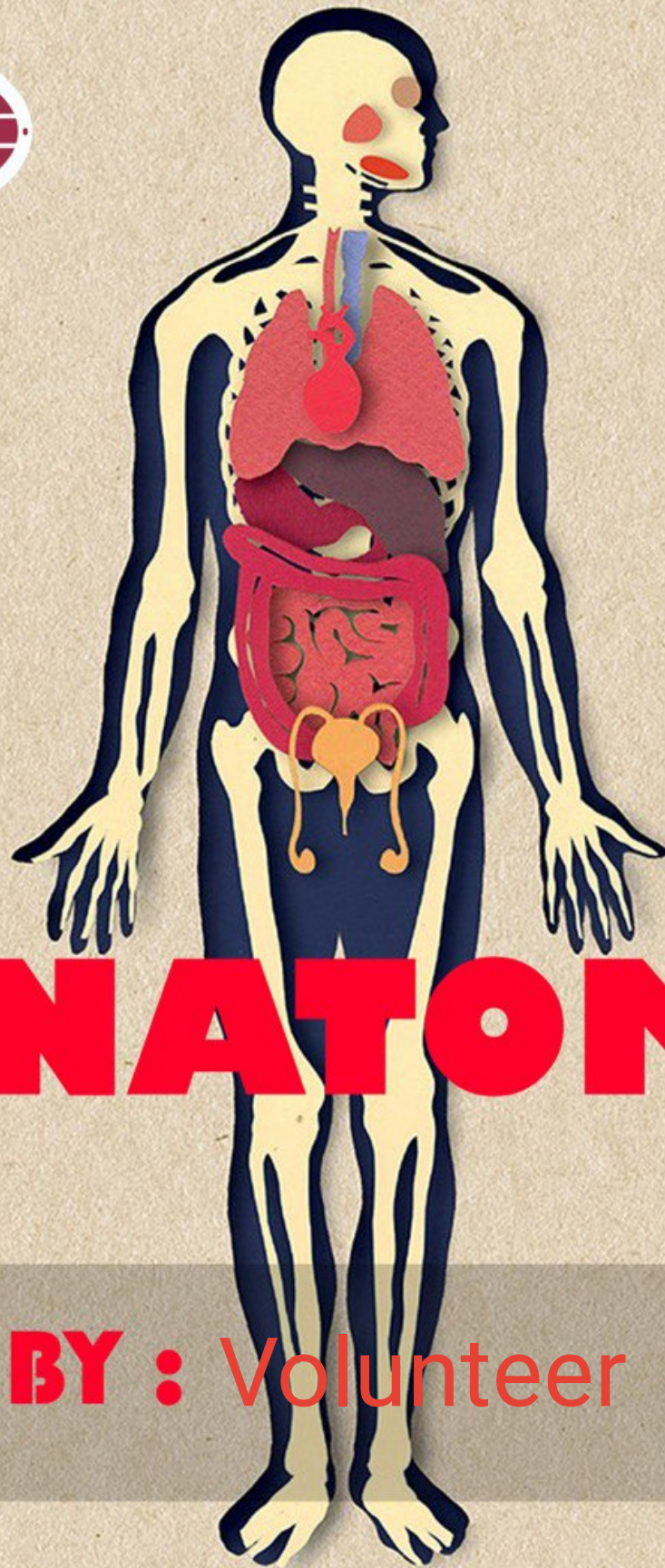


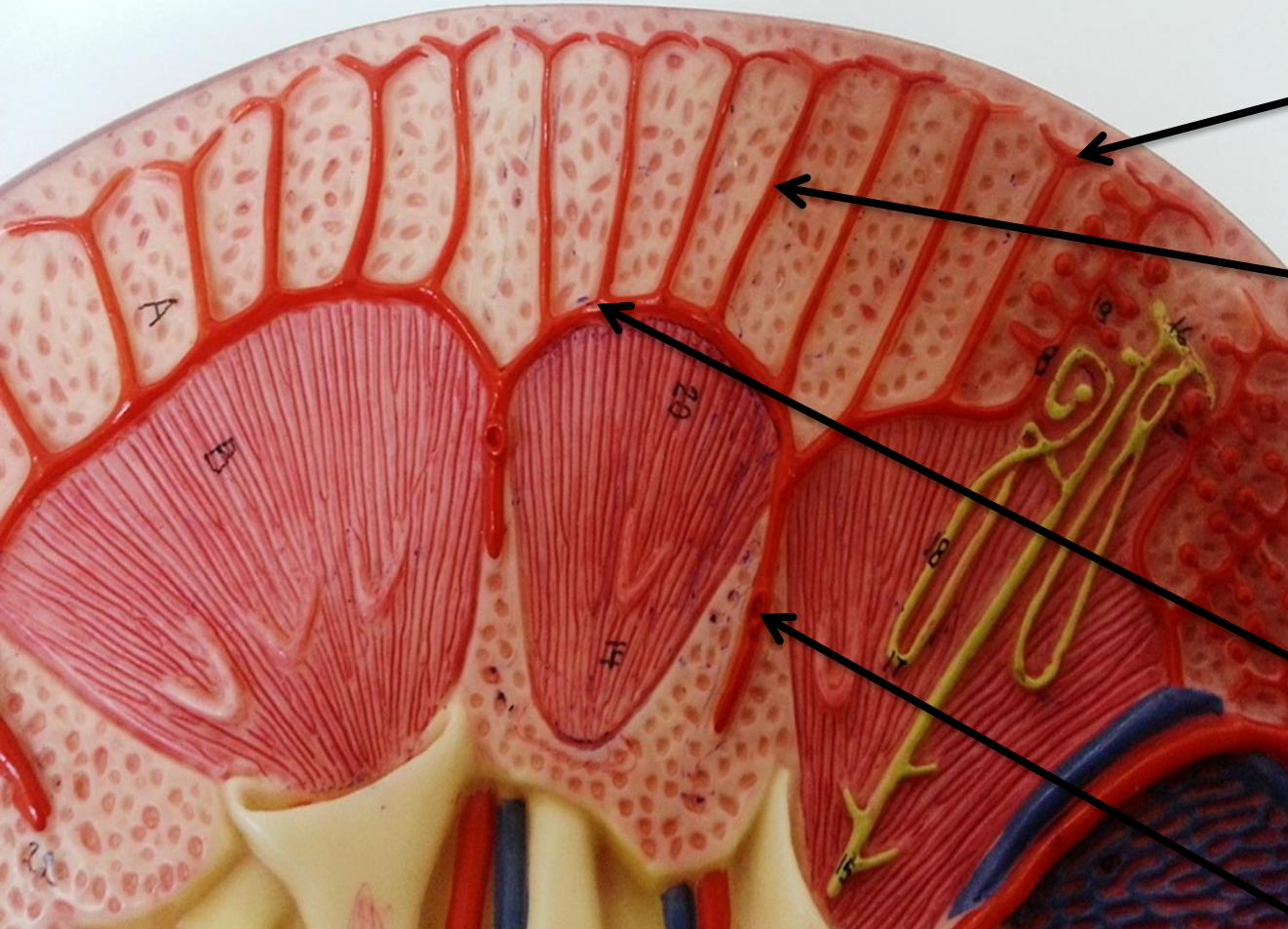
ANATOMY

DONE BY : Volunteer

UGS Lab 1

تم إضافة اشارة بجانب الصور المهمة





Afferent arteriole

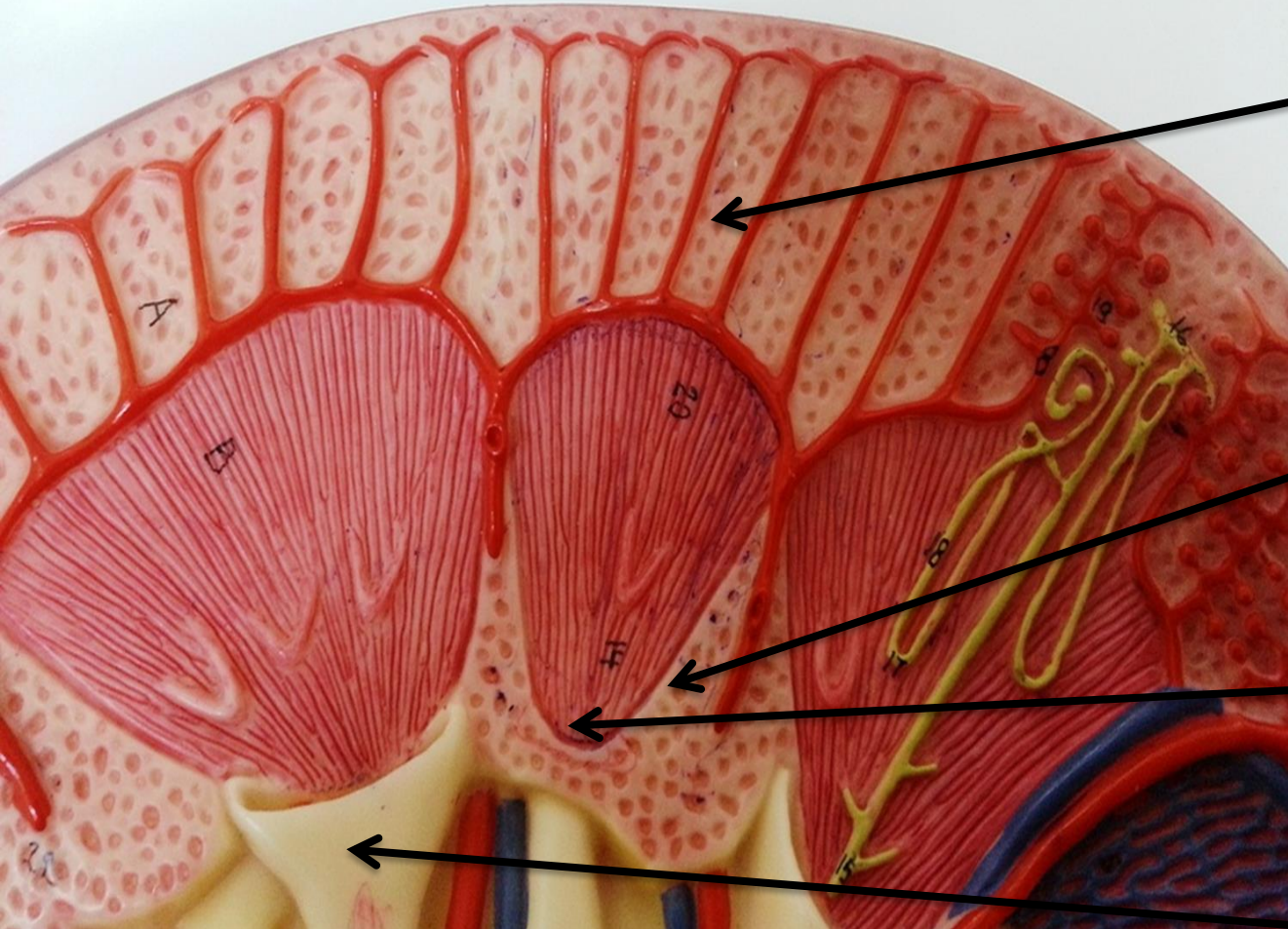
Interlobular artery

Arcuate artery

Interlobar artery

1

Sagittal Section of Kidney



Cortical arch

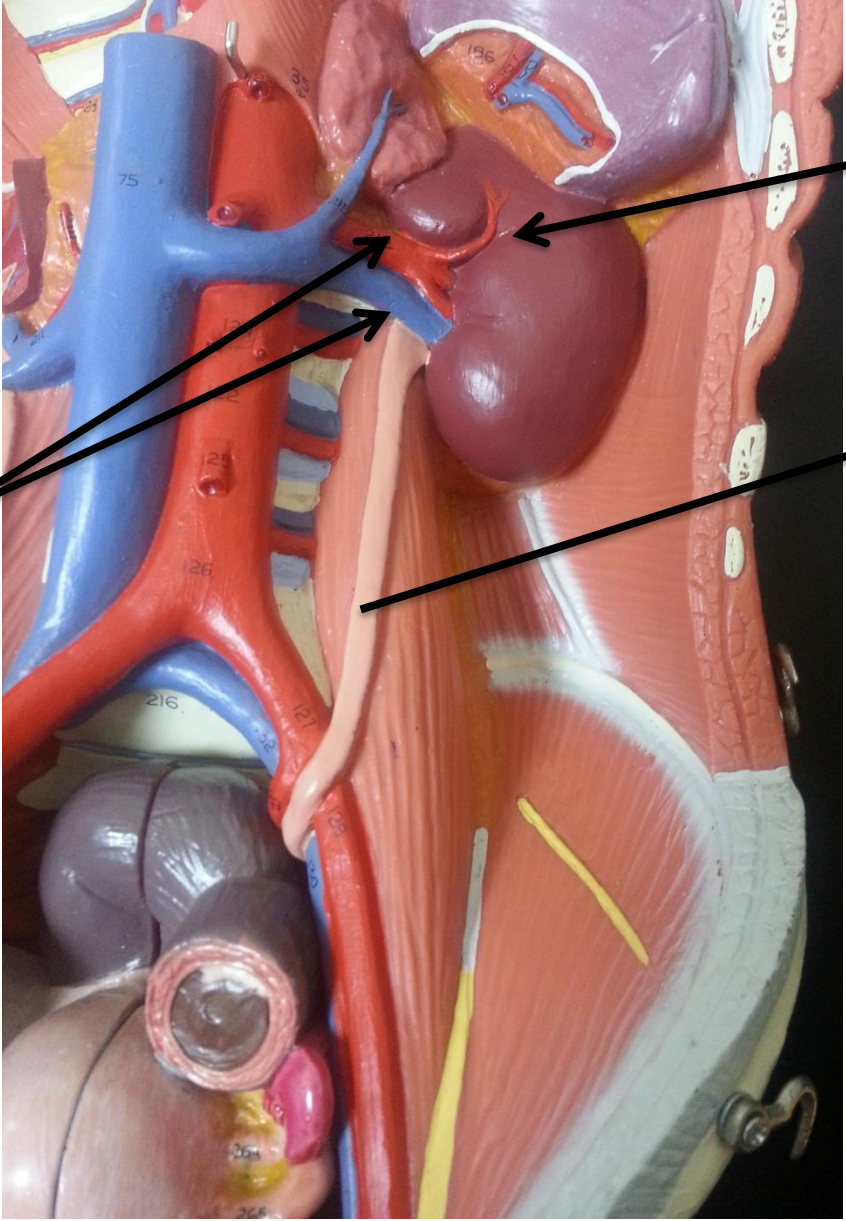
Cortical (renal) column

Renal papilla

Minor calyx

Sagittal Section of Kidney

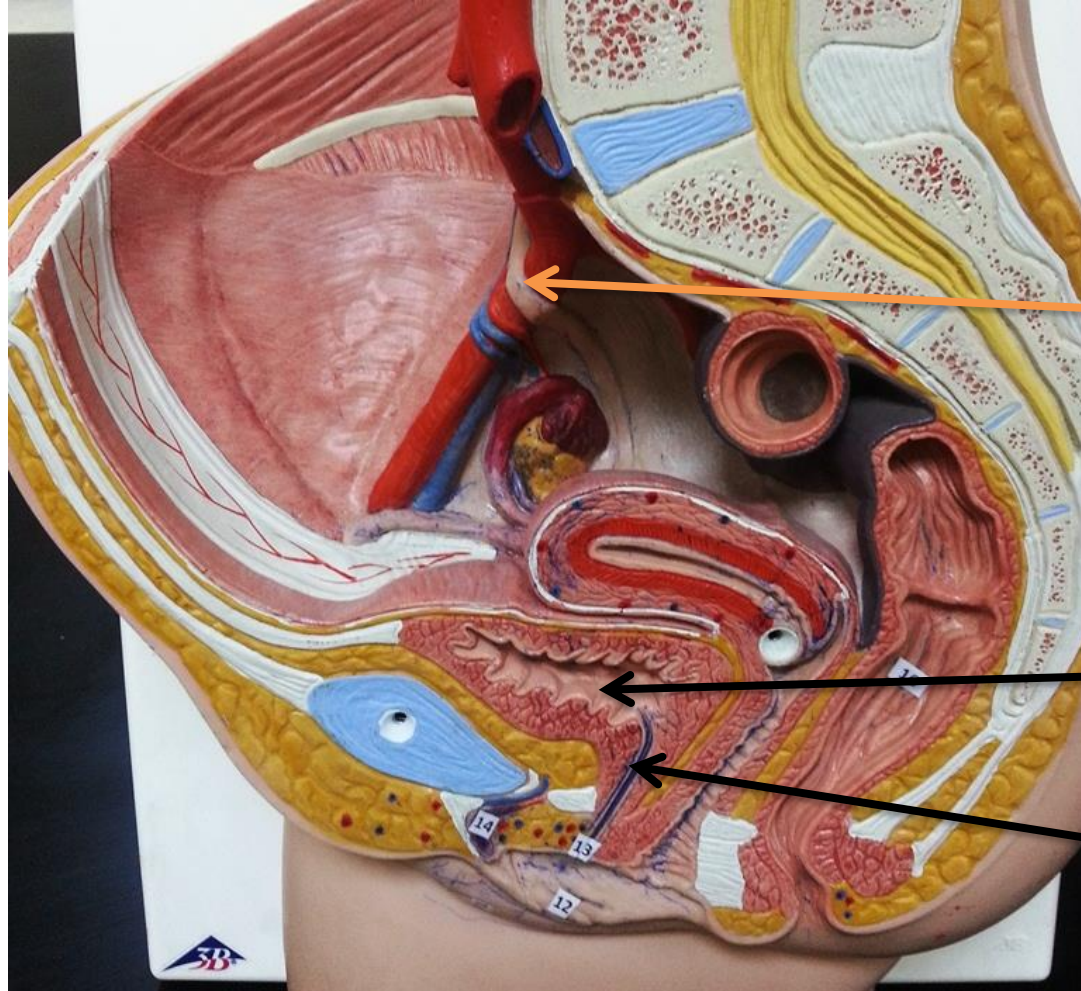
**Left renal
artery and
vein**



Left kidney

Left ureter

Left Kidney and Ureter

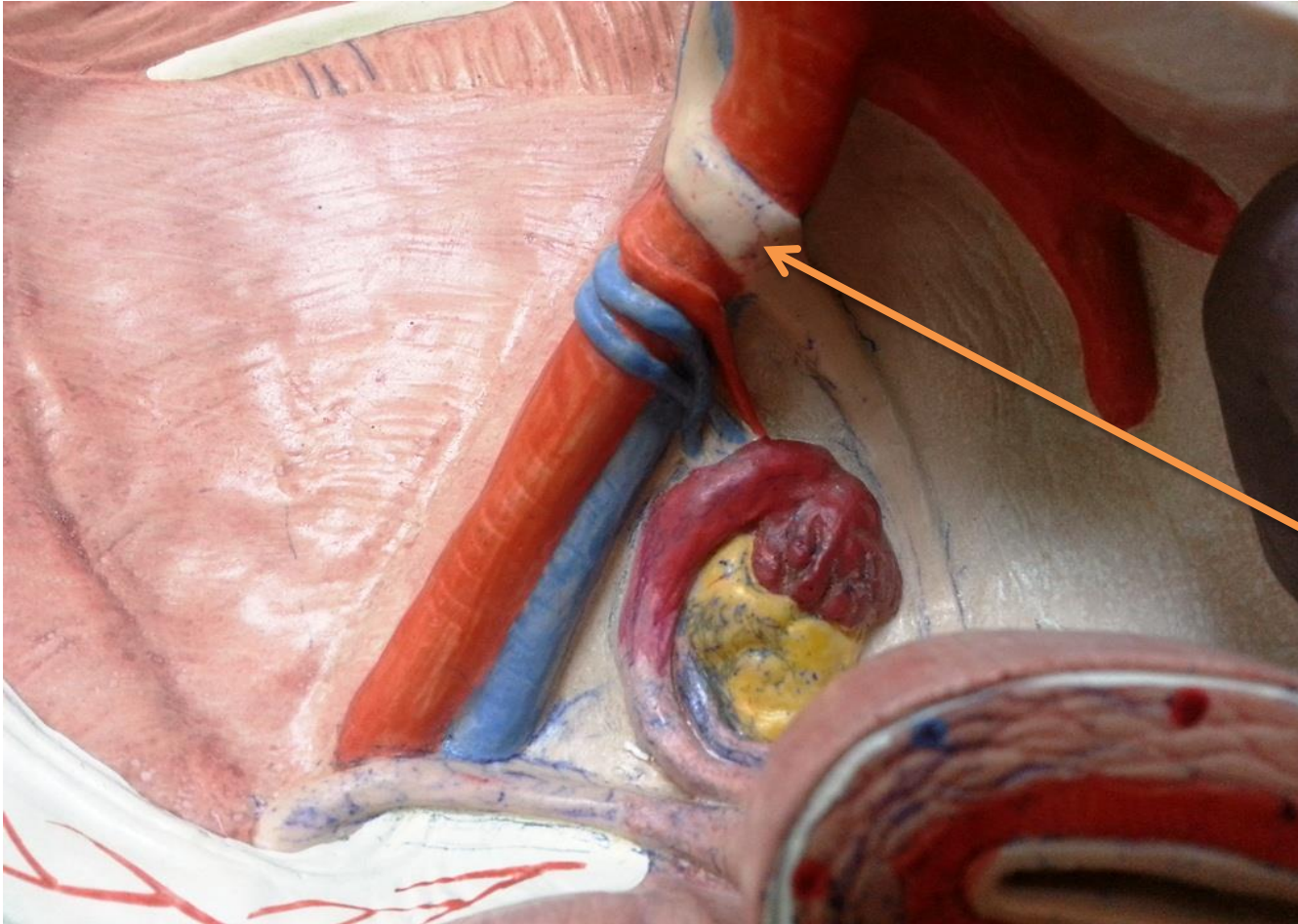


Right ureter

Urinary bladder

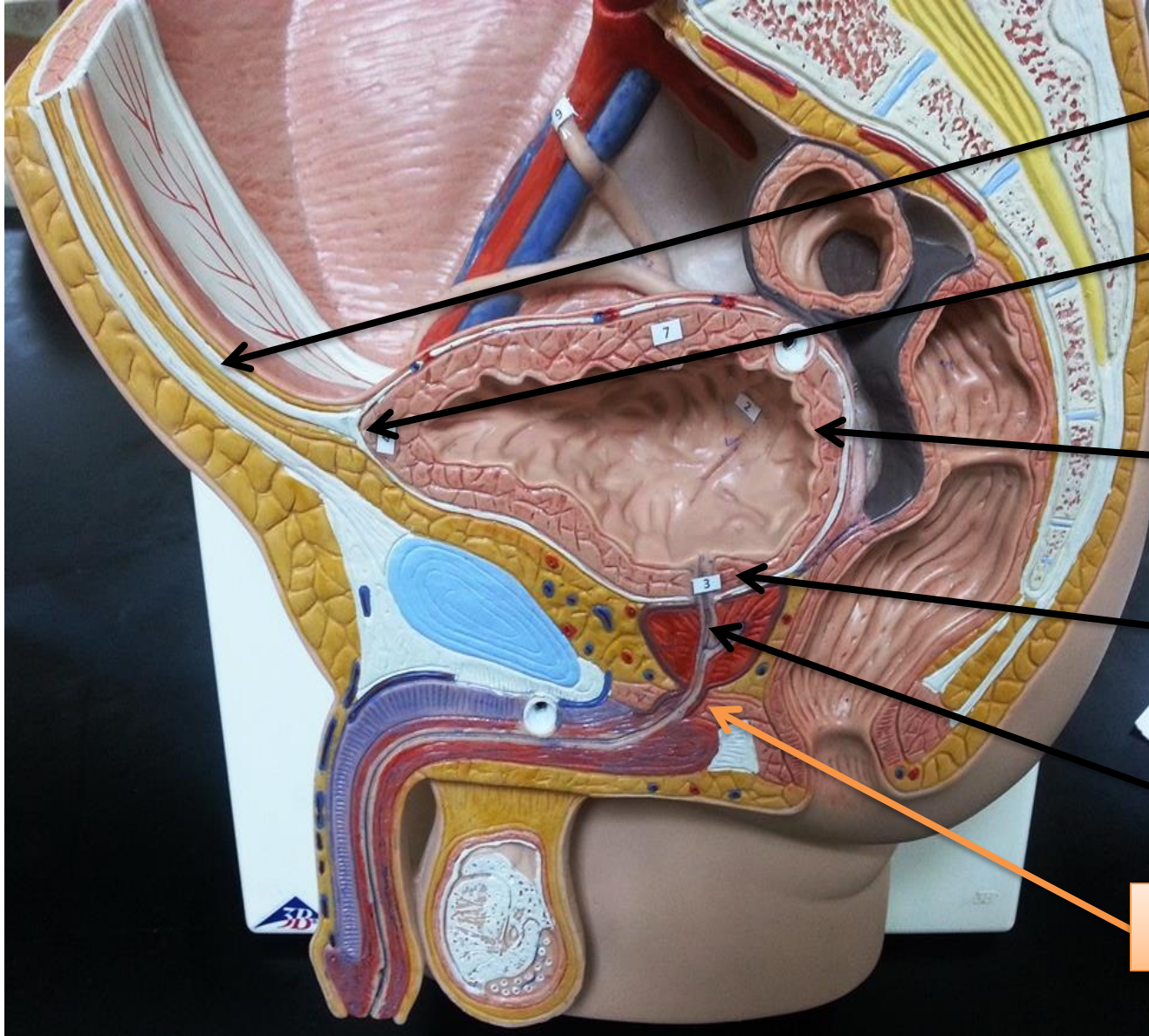
Urethra

Right Ureter, Bladder, and Urethra



Right ureter

Right Ureter



Umbilical ligament

Apex of urinary bladder

Base of urinary bladder

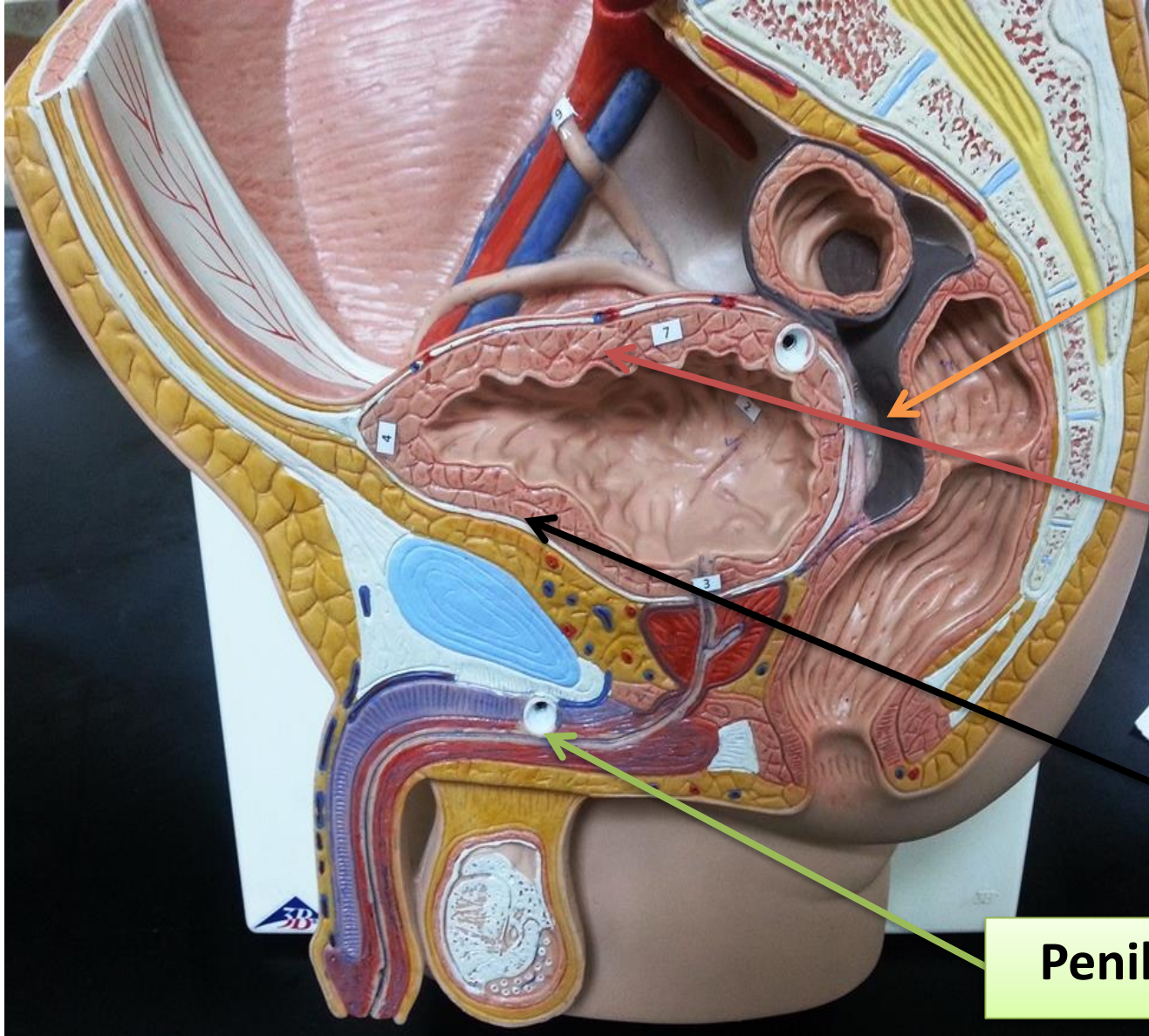
Neck of urinary bladder

Prostatic urethra

Membranous urethra

6

Urinary Bladder and Urethra



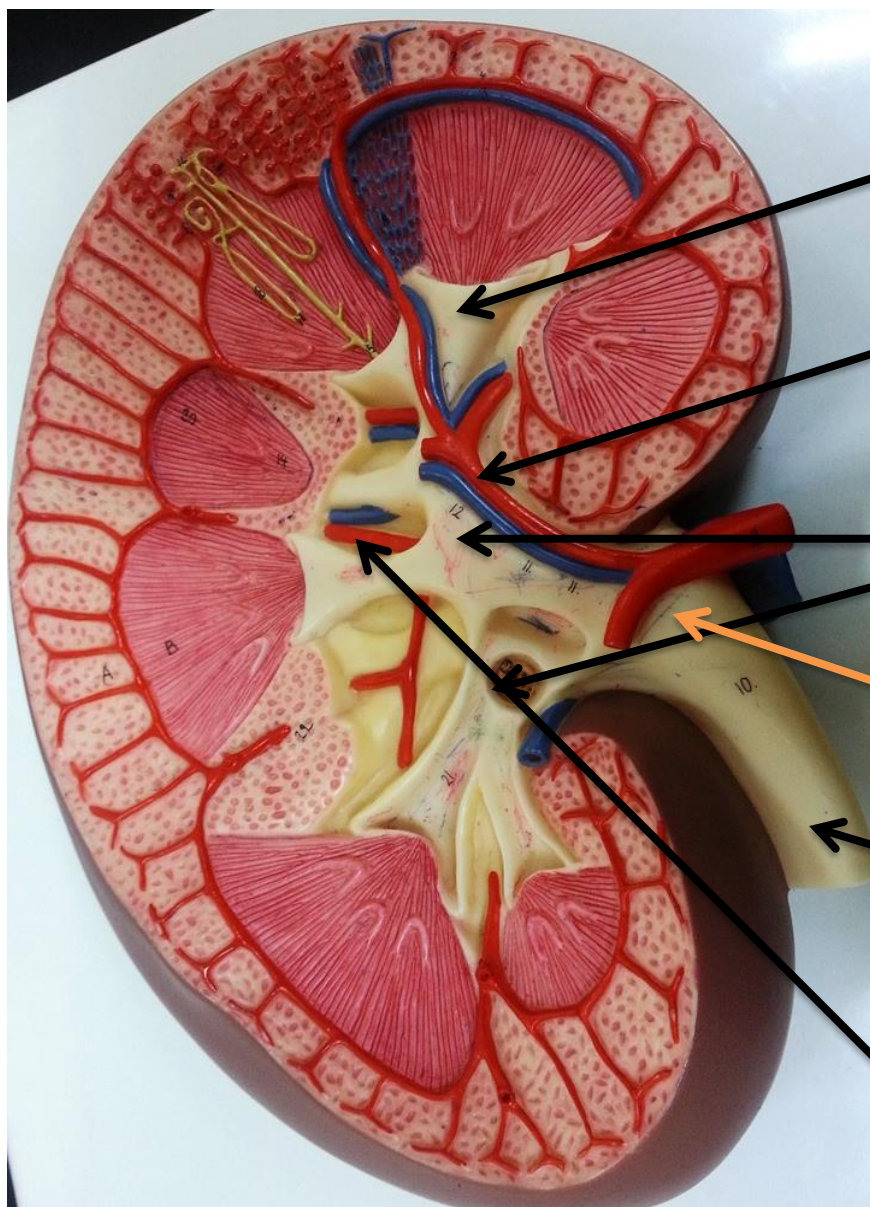
Rectovesical pouch

Superior wall of urinary bladder

Inferolateral wall of urinary bladder

Penile (spongy) urethra

Urinary Bladder and Urethra



Minor calyx


Segmental artery

Major calyx

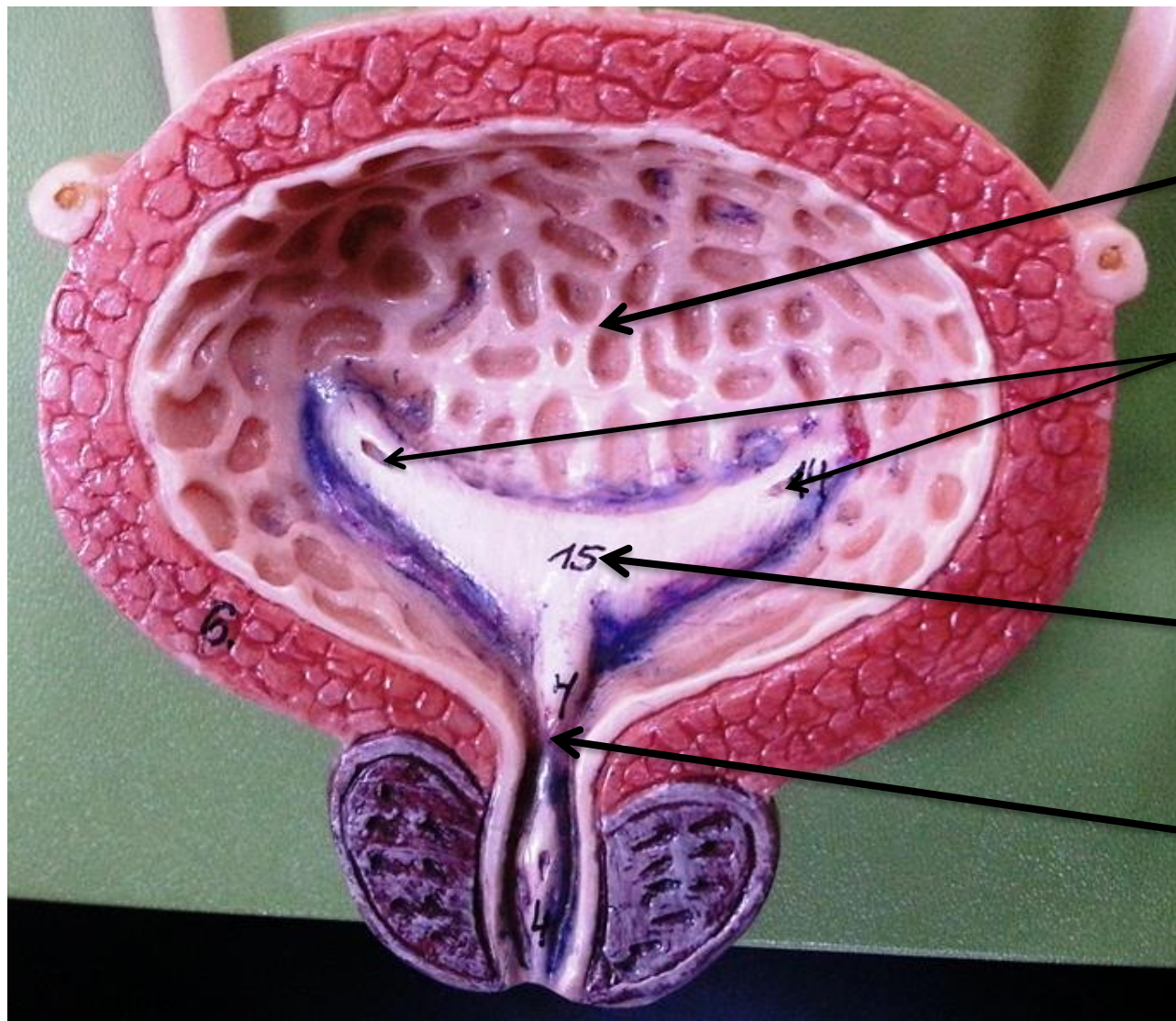
Renal pelvis

Ureter

Lobar artery



Sagittal Section Through the Kidney

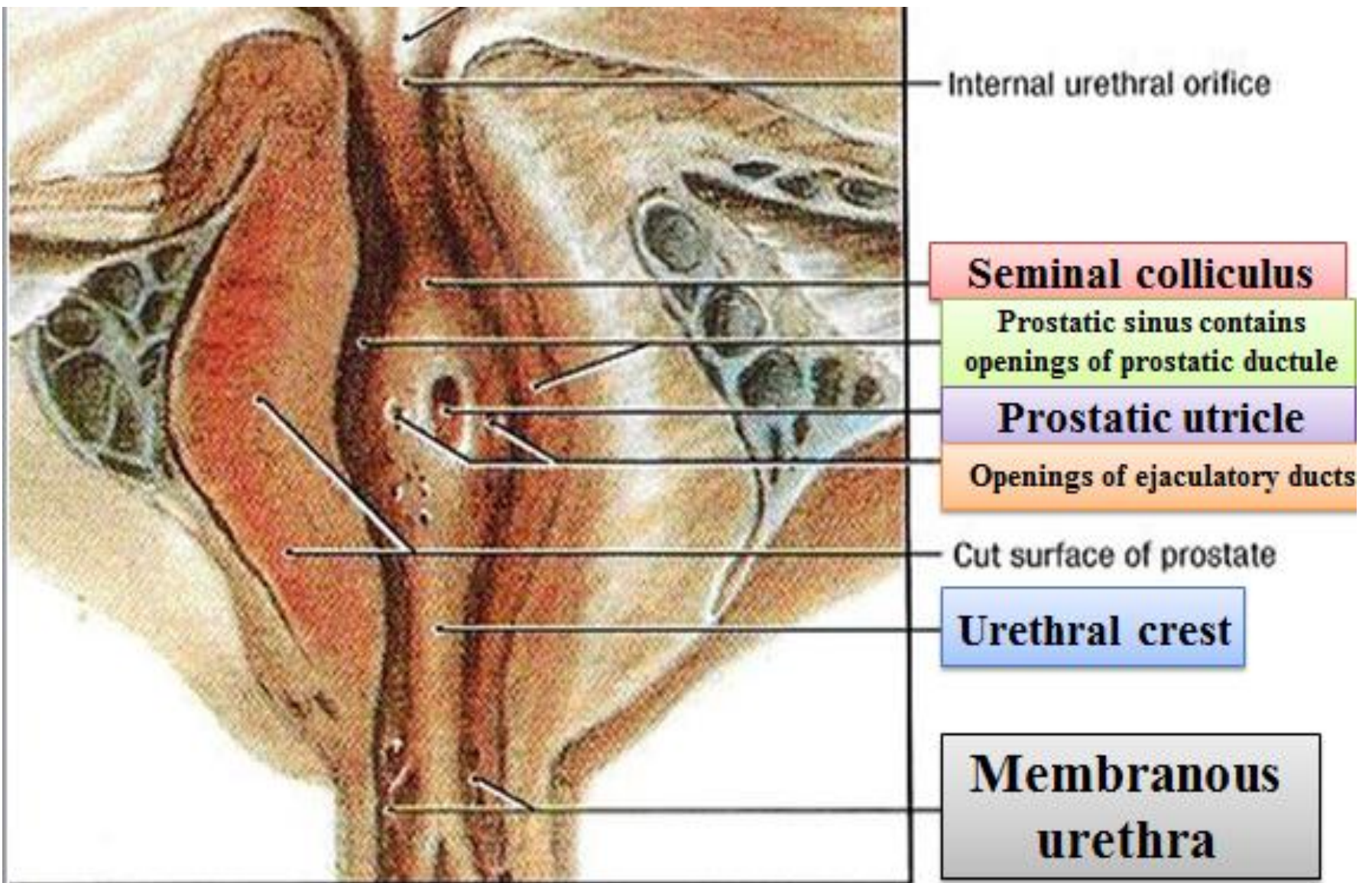


Rugae

Ureteric orifices

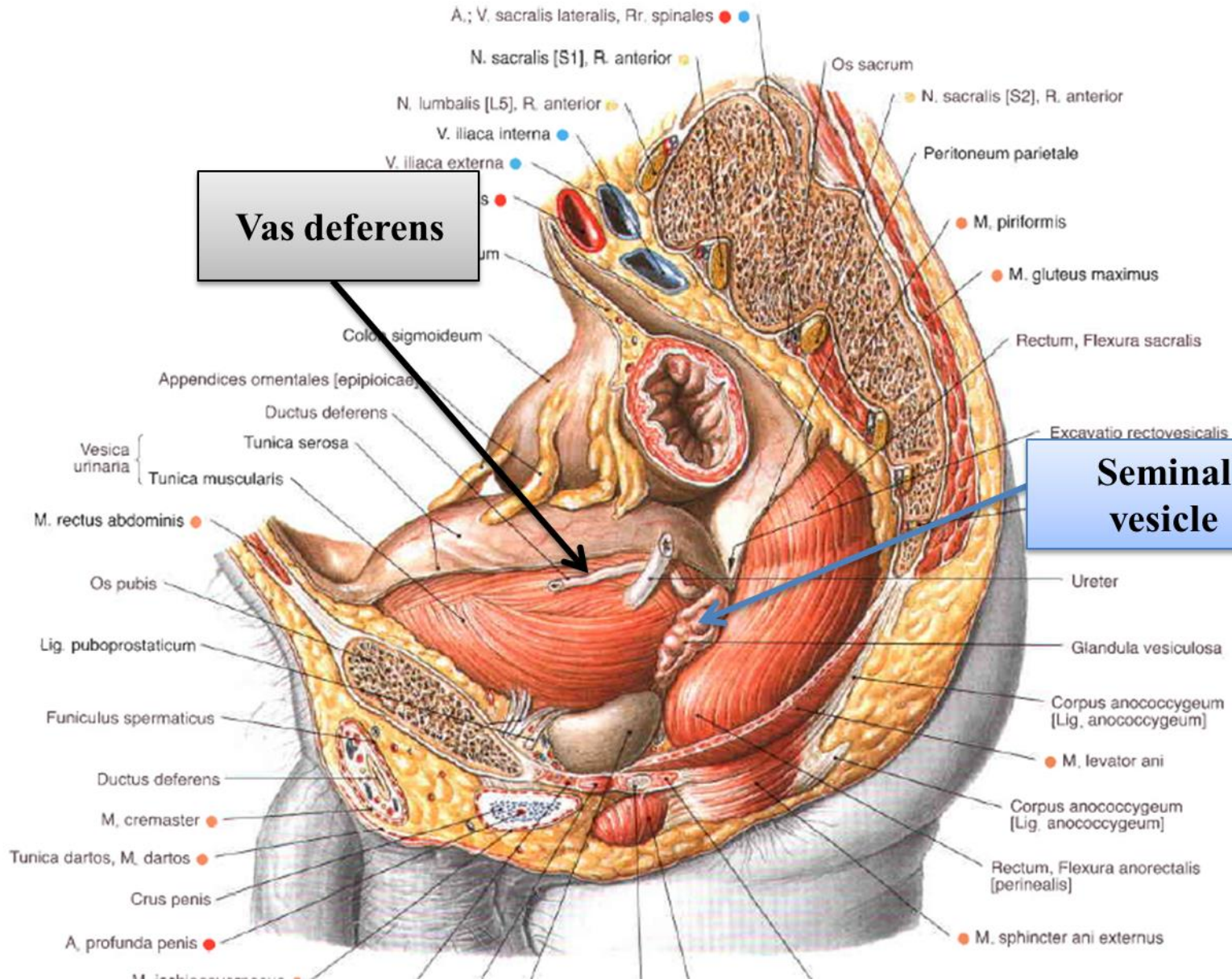
Trigone of urinary bladder

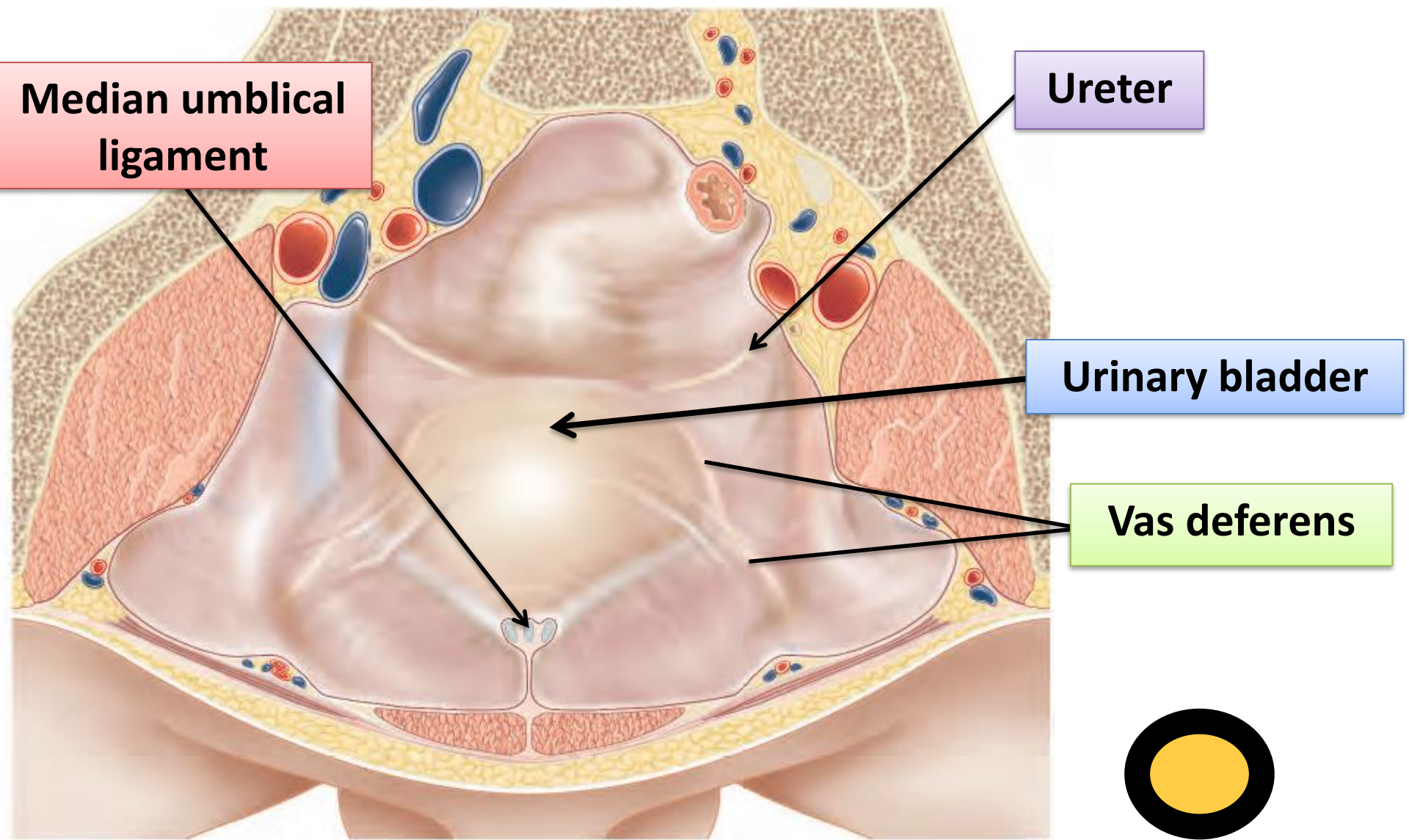
Internal urethral meatus



10A

Prostatic Urethra






Median umbilical ligament

Ureter

Urinary bladder

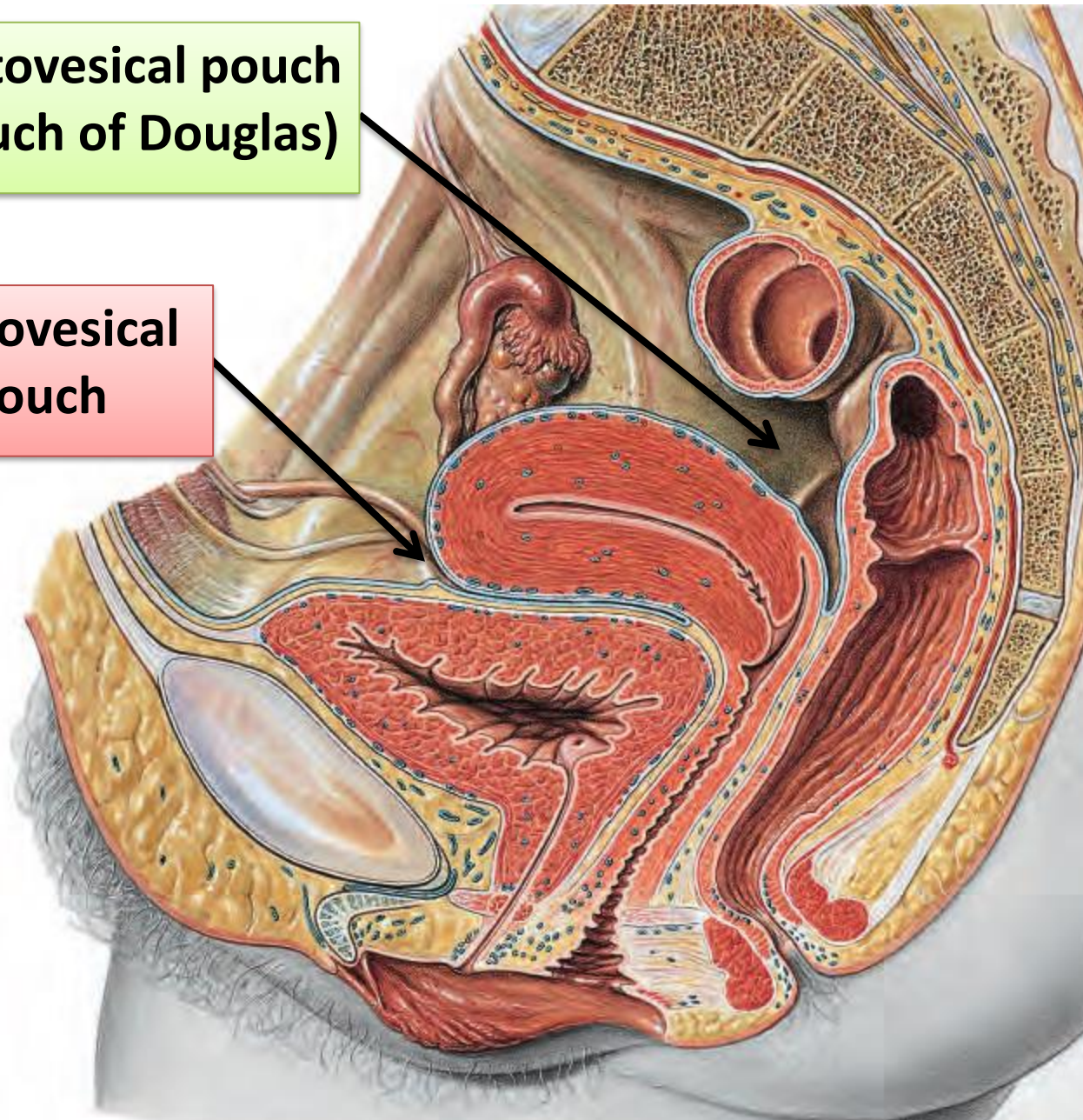
Vas deferens

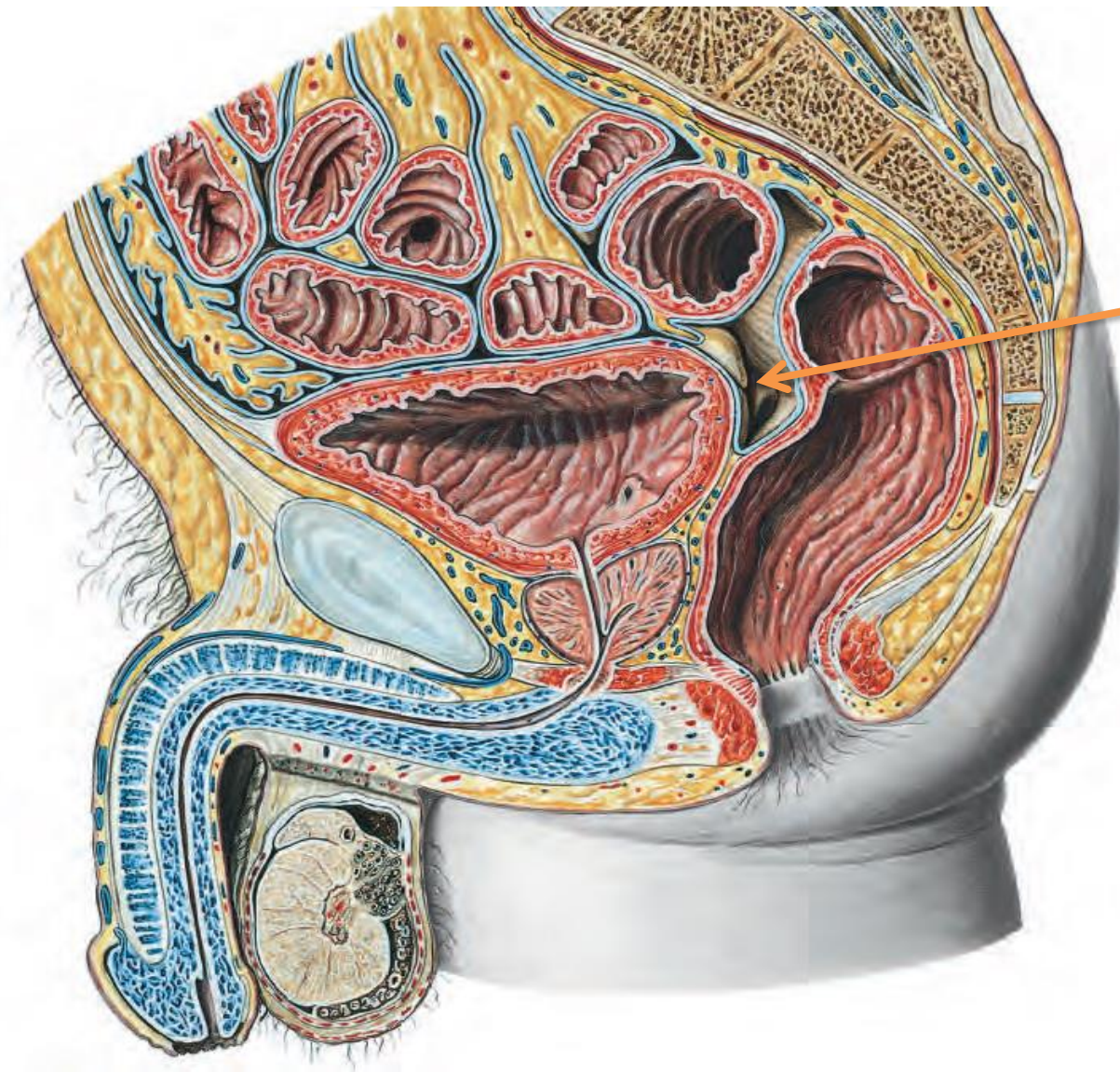


Urinary Bladder

**Rectovesical pouch
(pouch of Douglas)**

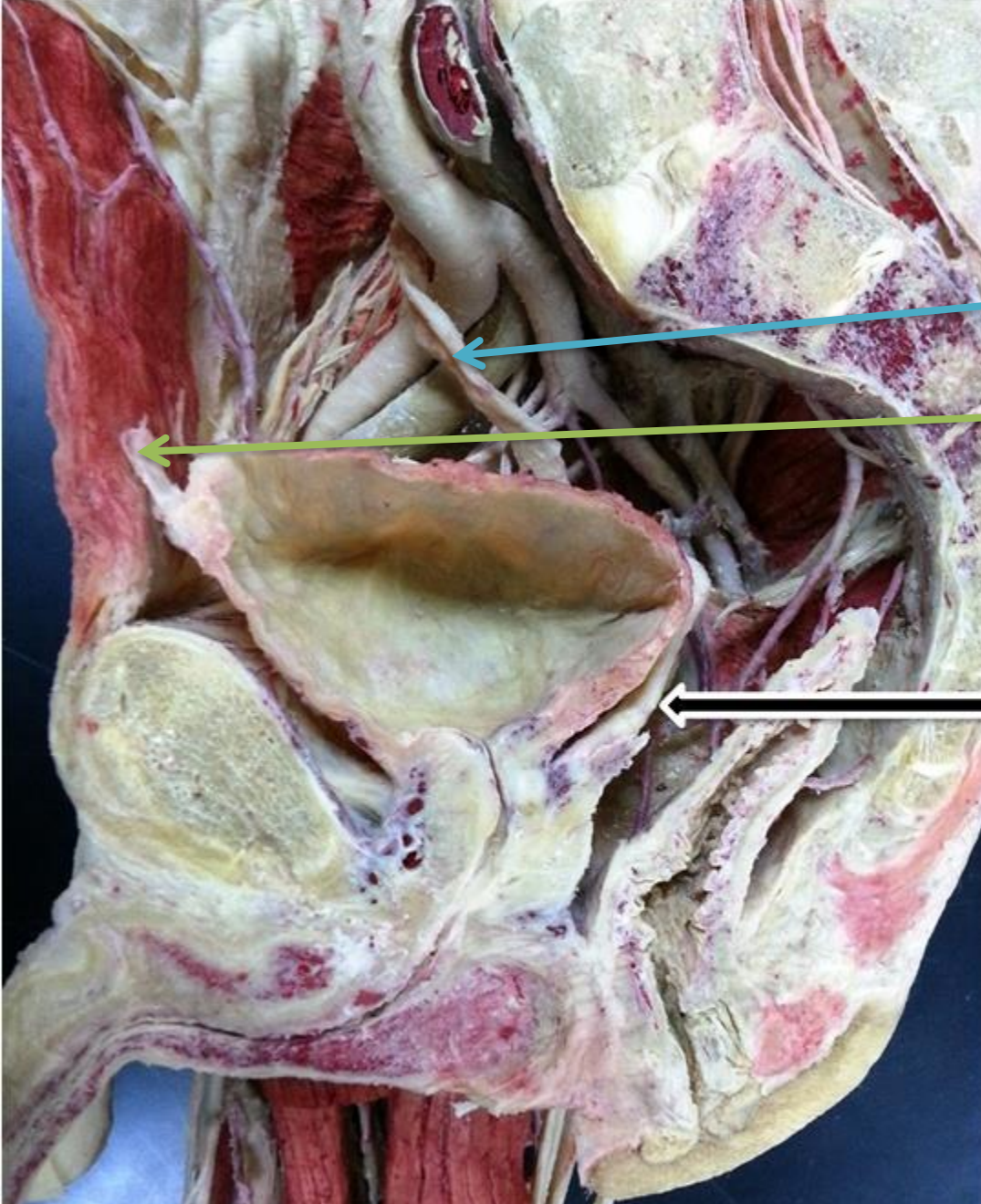
**Uterovesical
pouch**





**Rectovesical
pouch**

Peritoneal Recesses



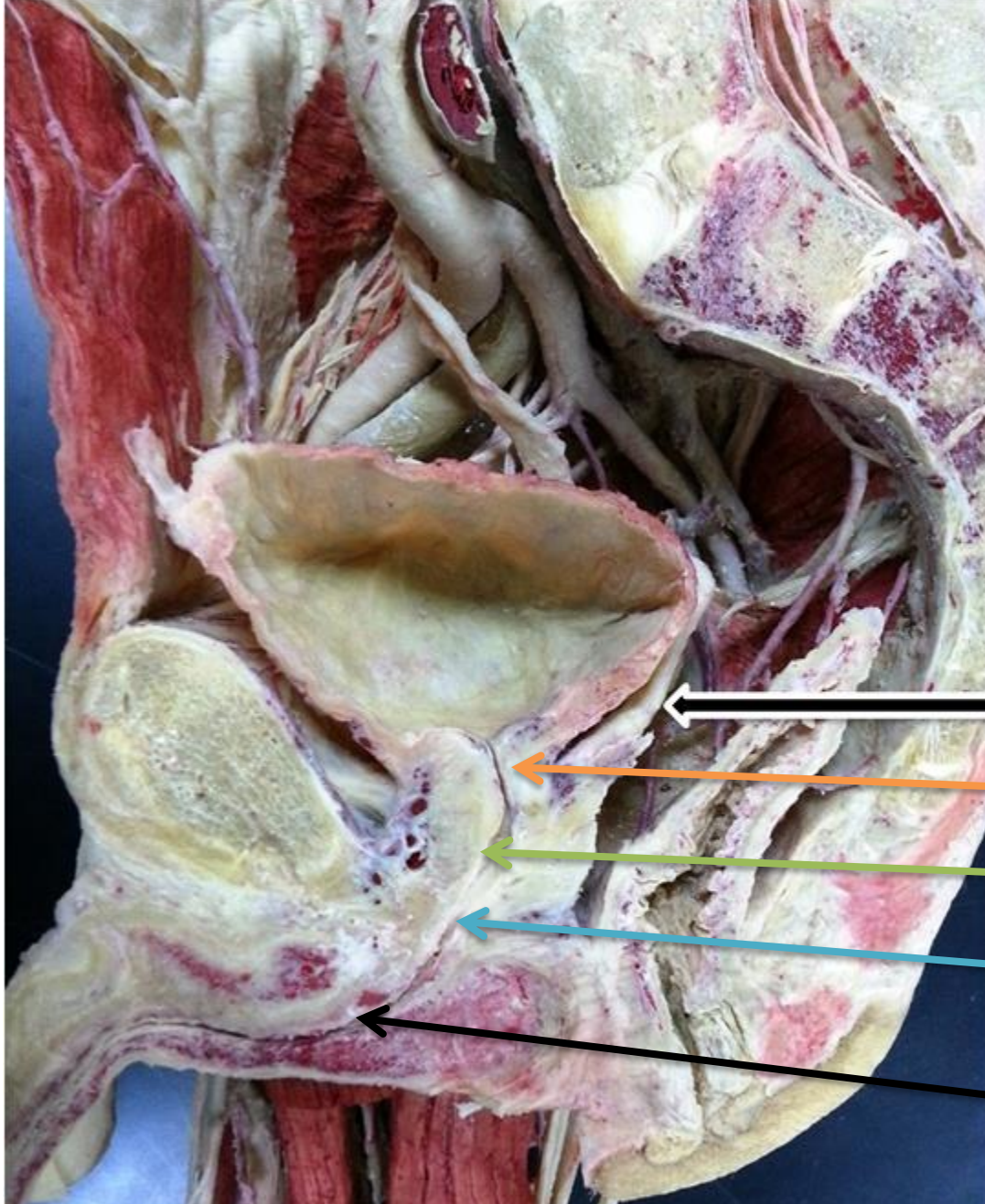
Ureter

Median umbilical ligament

Vas deferens

14

Ureter, Urinary bladder, and vas deferens



Vas deferens

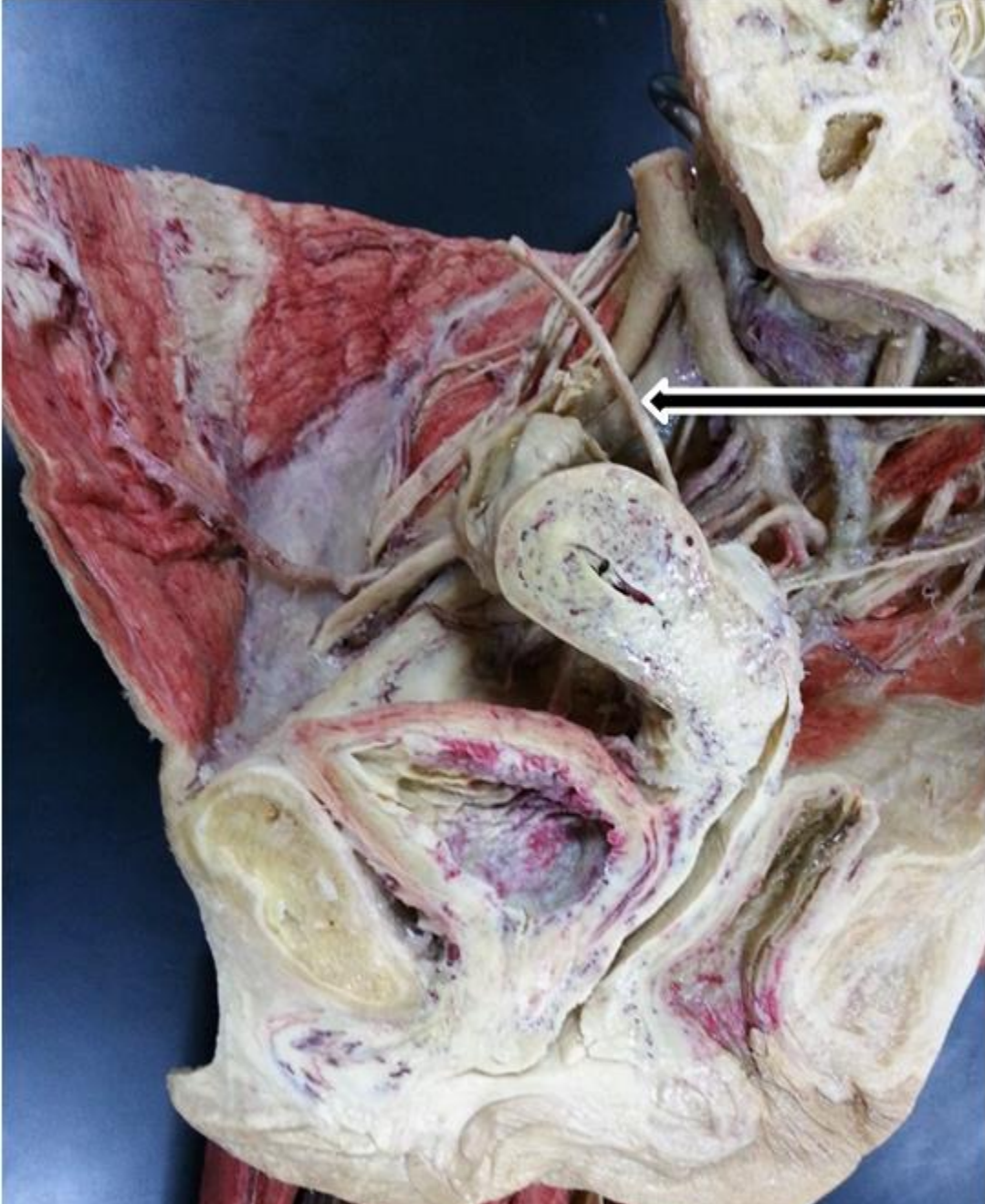
Neck of urinary bladder

Prostatic urethra

Membranous urethra

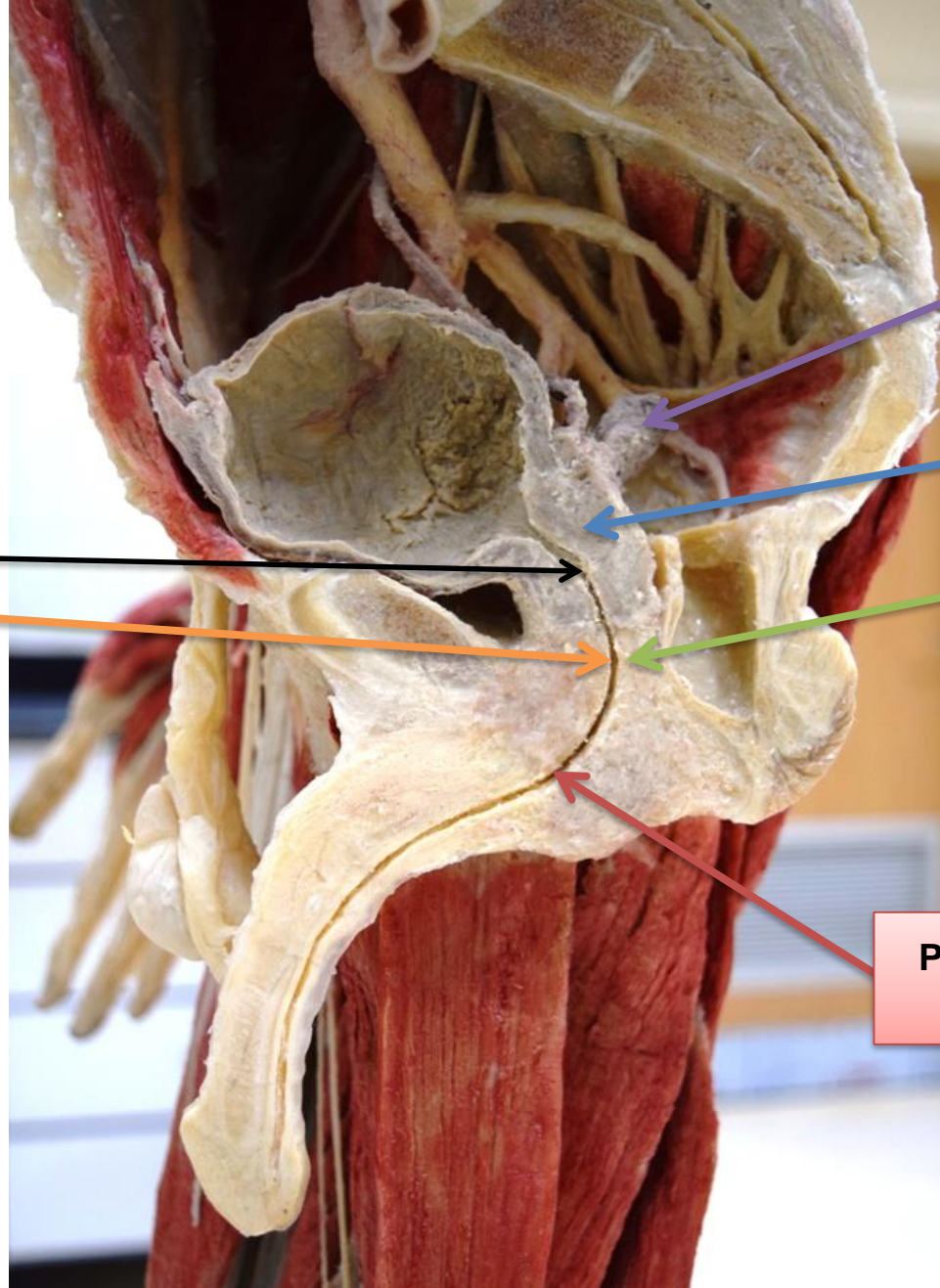
Penile urethra

Parts of Male Urethra



Ureter.

Ureter



Seminal vesicle

Prostate gland

Sphincter urethrae

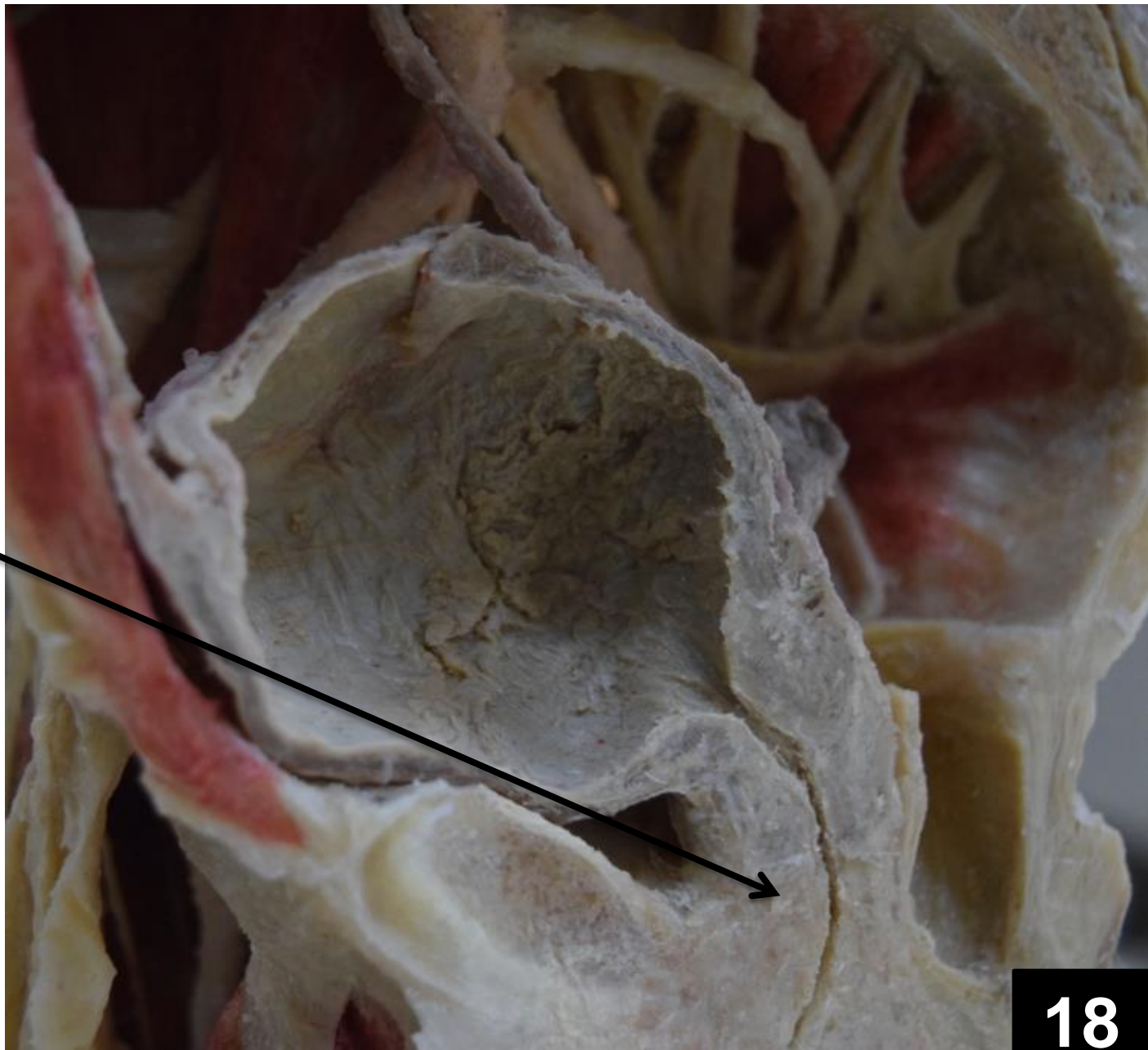
Penile (spongy) urethra

Prostatic urethra

Membranous urethra

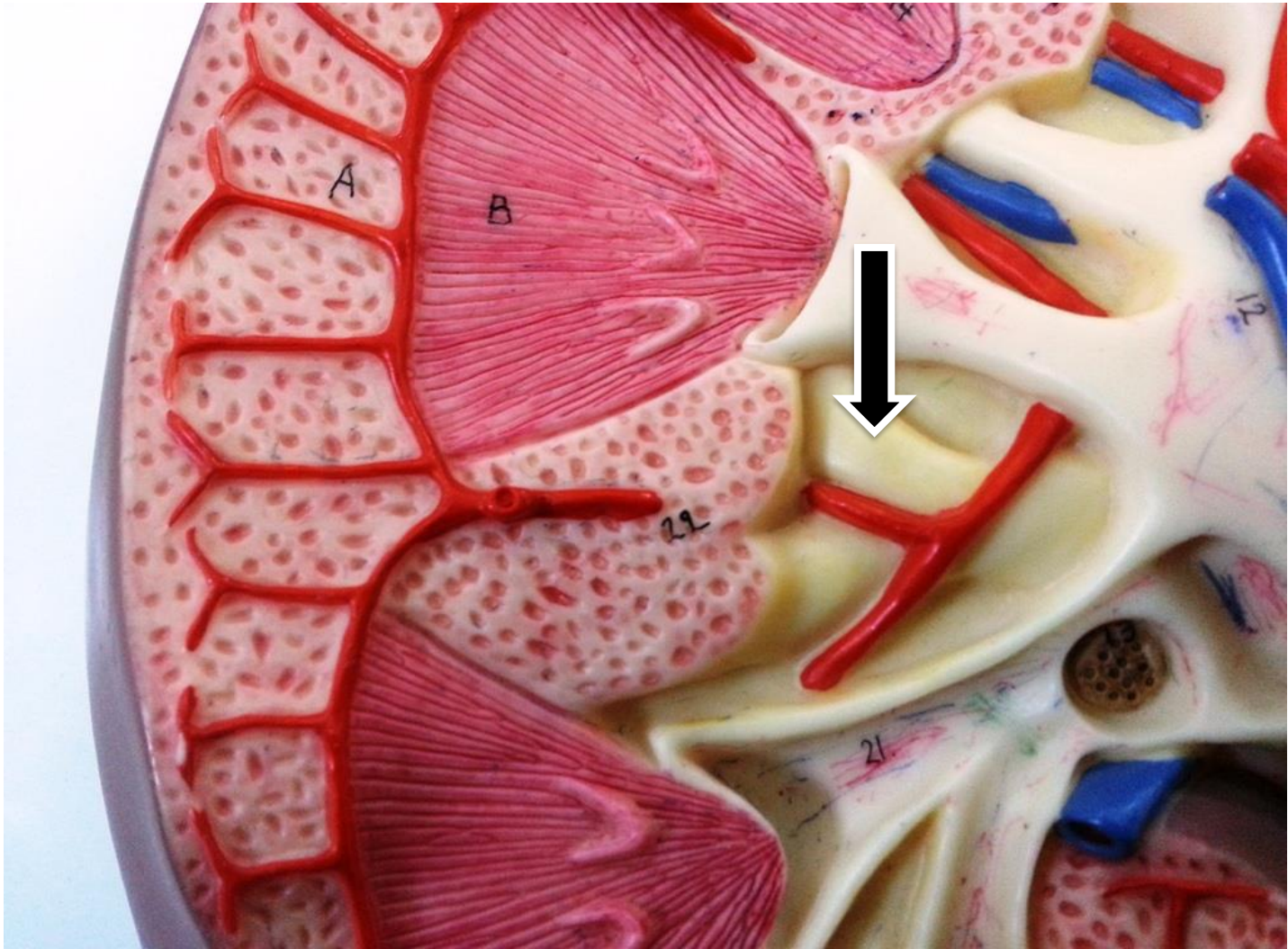
Parts of Male Urethra

**External urethral
sphincter (sphincter
urethrae)**

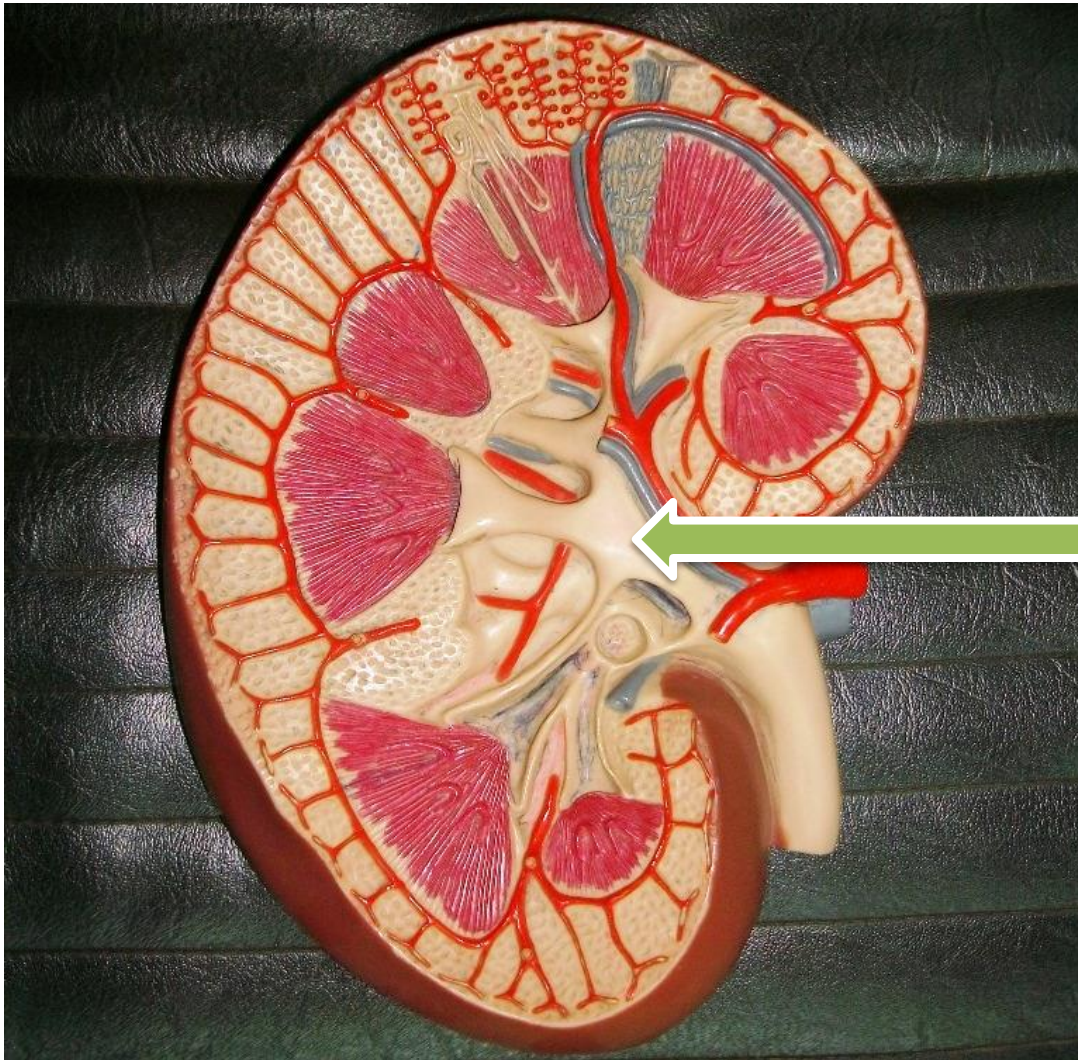


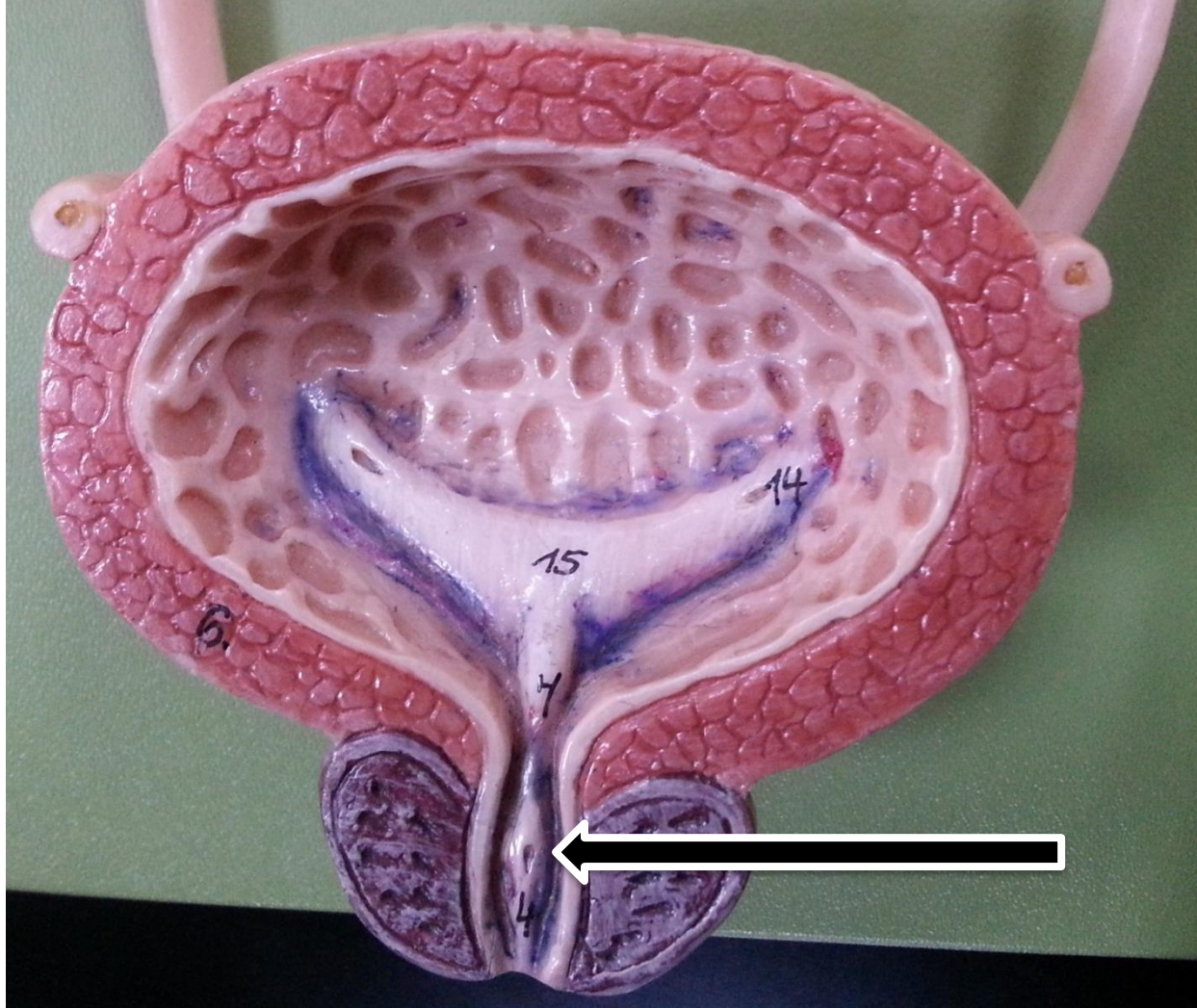
18

The External Urethral Sphincter

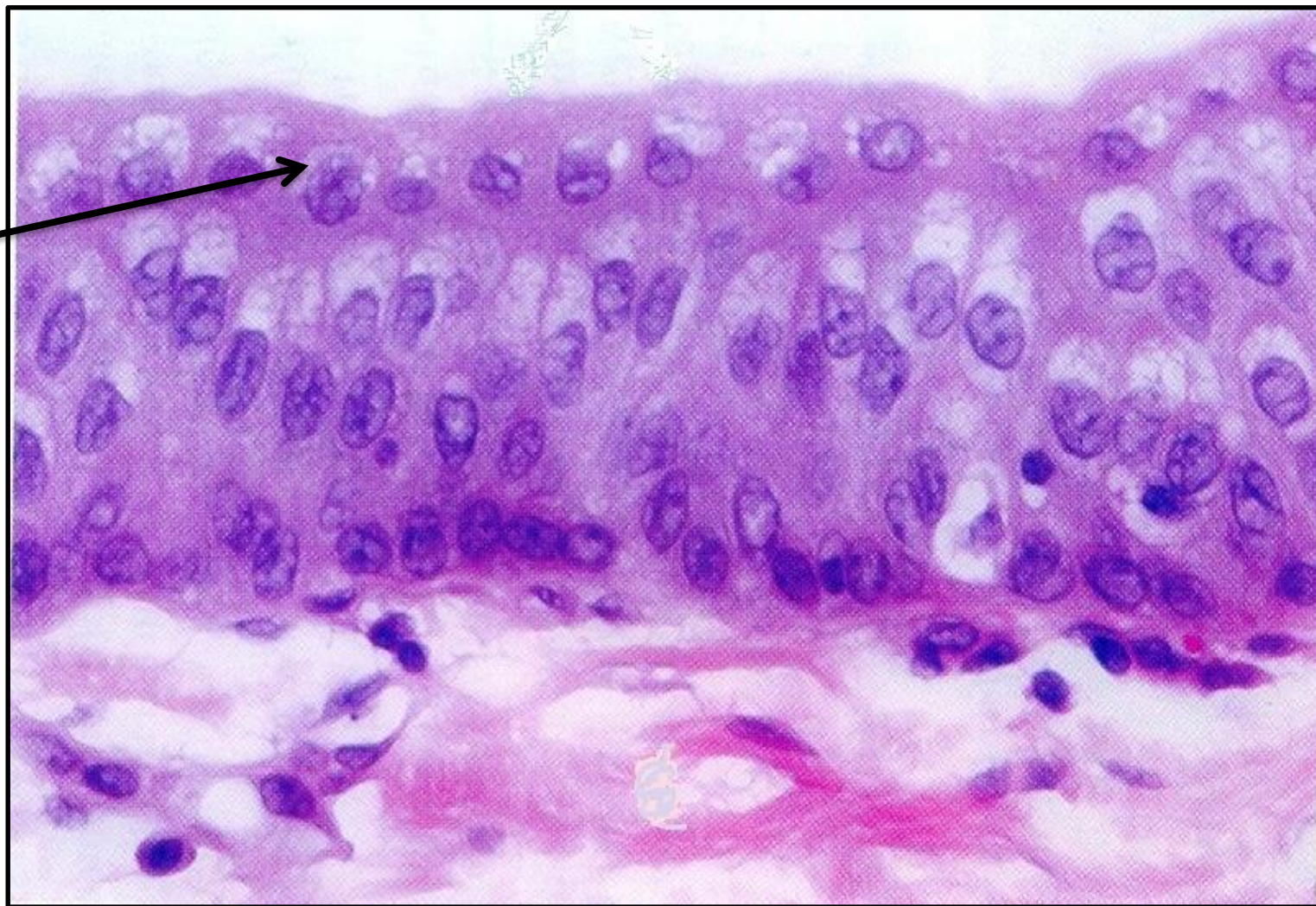


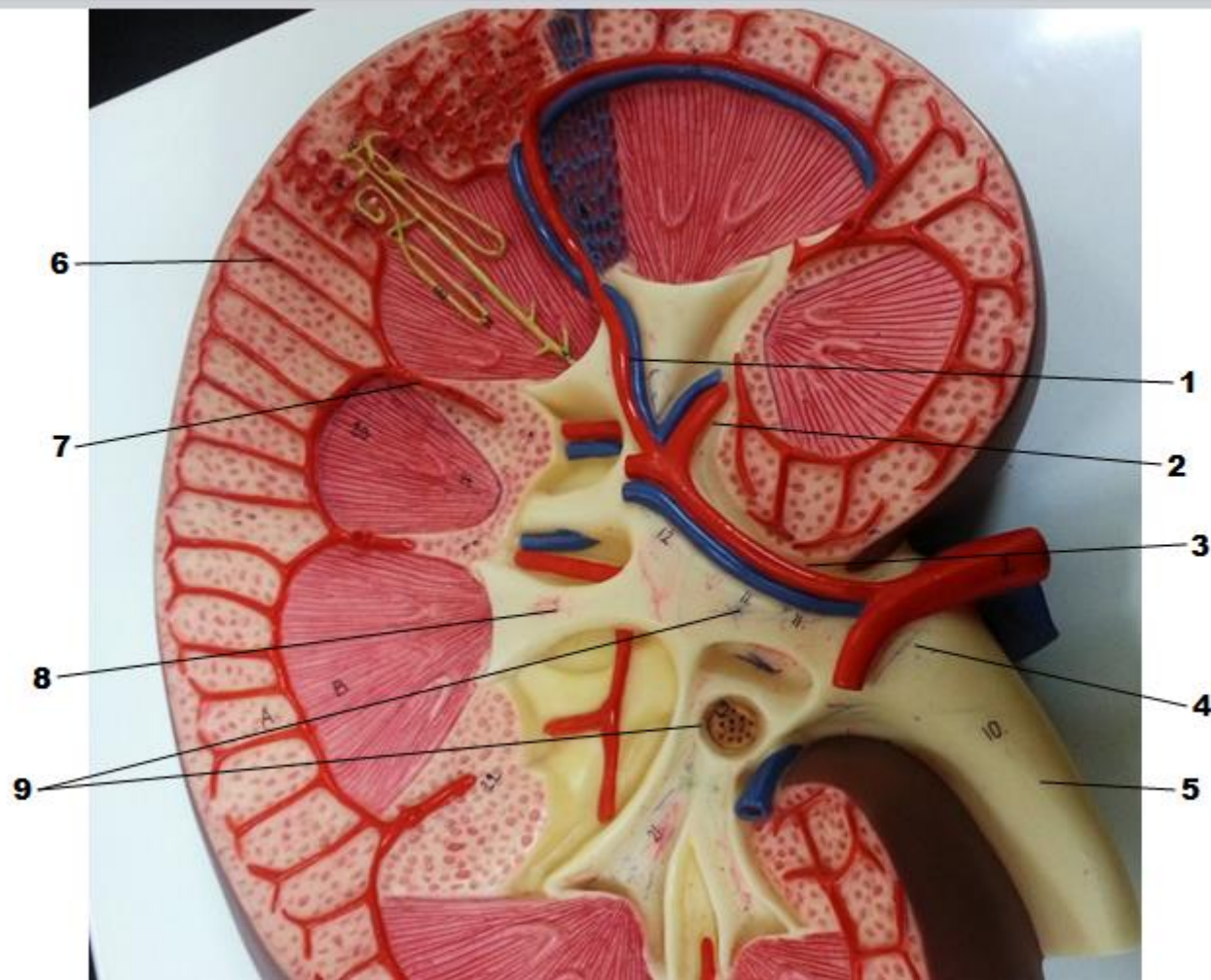
Interlobar artery



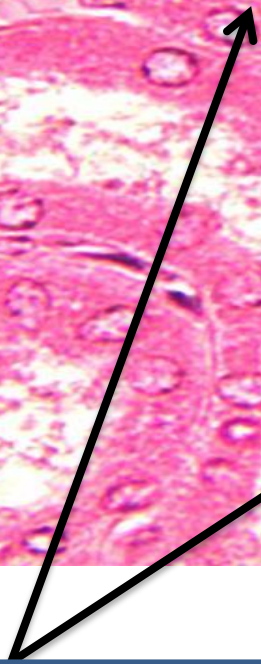
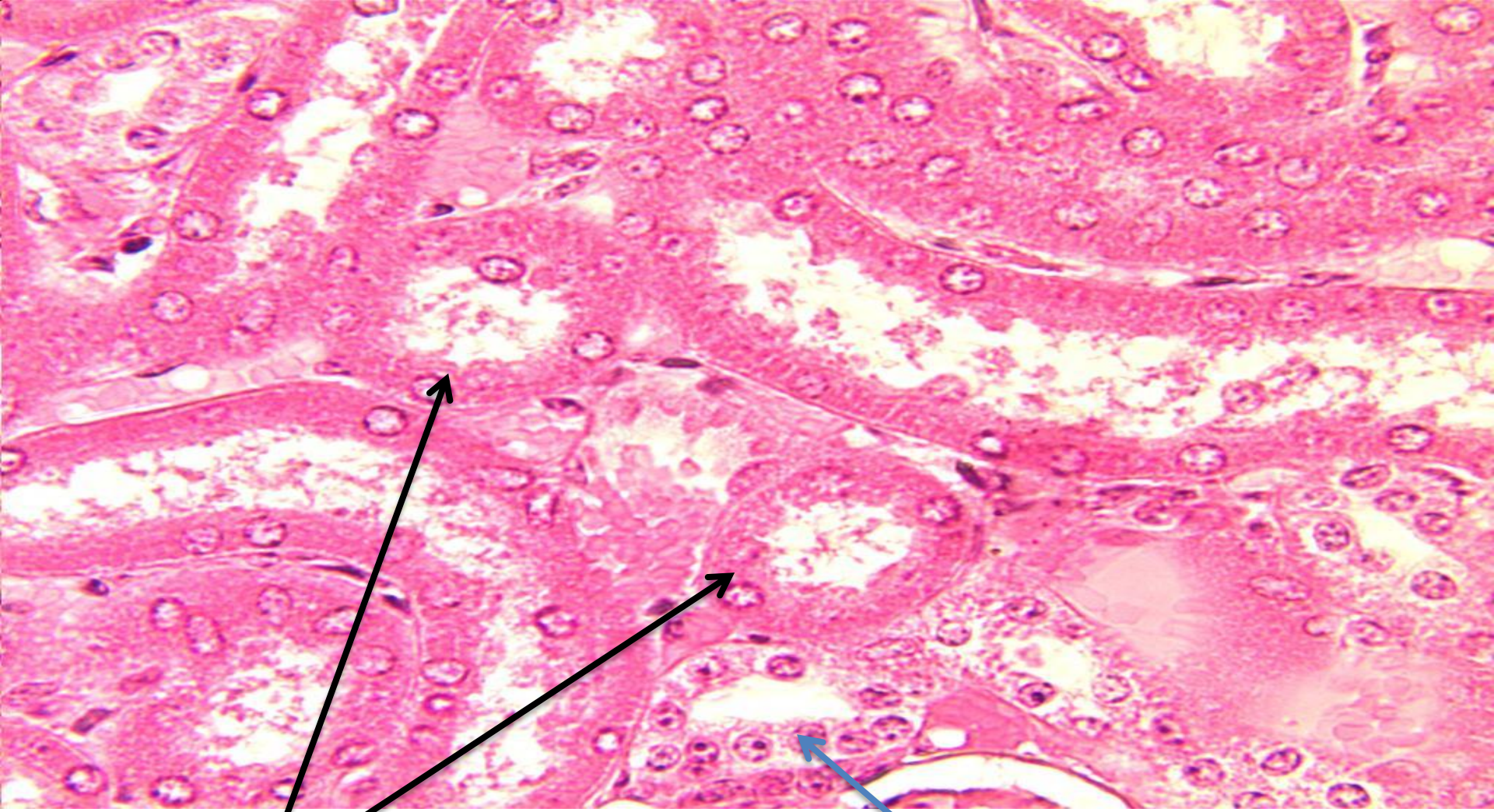


Dome cell.

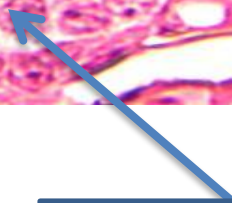




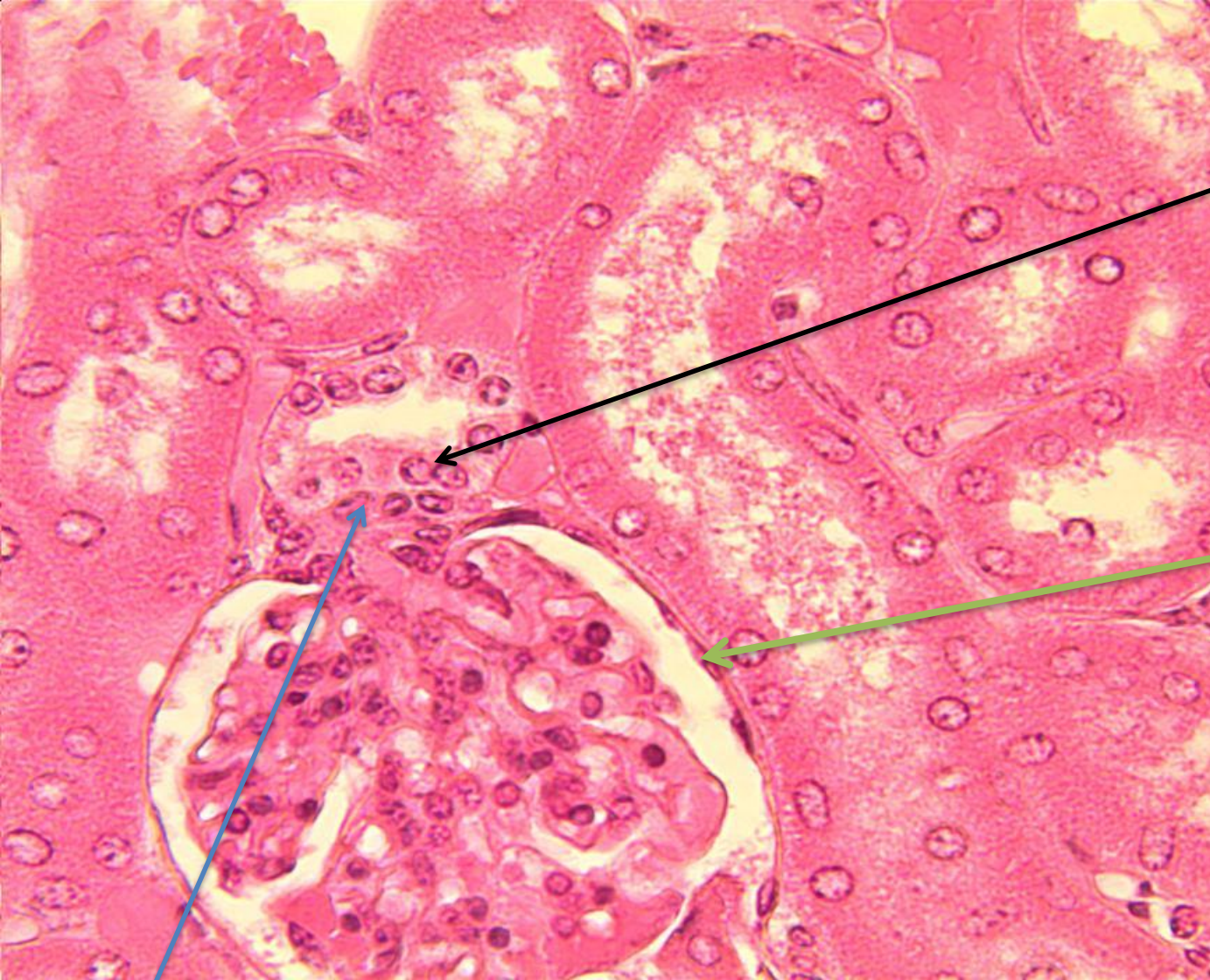
1. Interlobar artery; 2. Lobar artery; 3. Segmental artery; 4. Renal pelvis; 5. Ureter; 6. Interlobular artery; 7. Interlobar artery; Minor calyx; and 9. Major calyx.



Proximal convoluted tubules



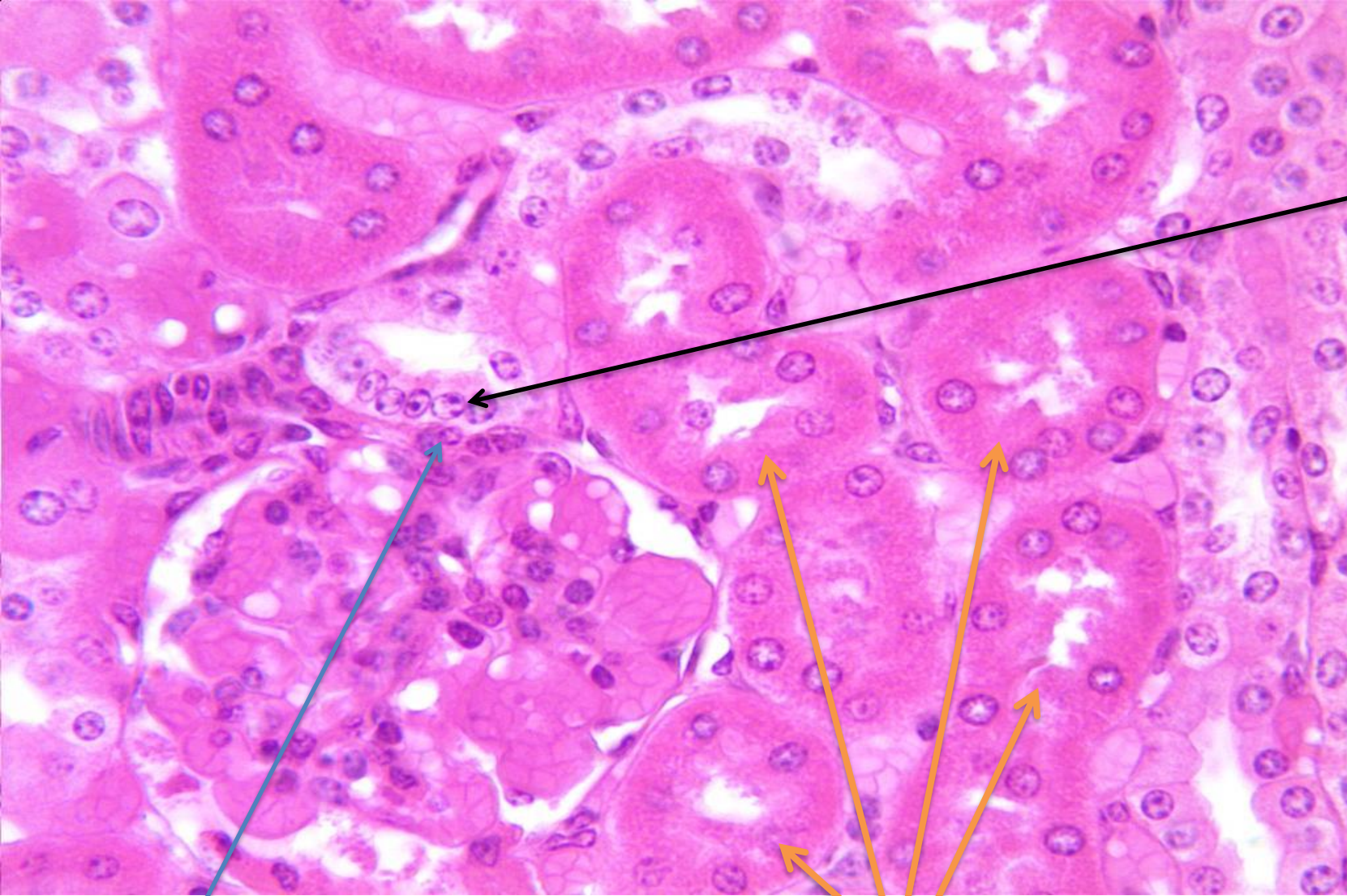
Distal convoluted tube



Macula densa

**Parietal layer
of glomerular
capsule**

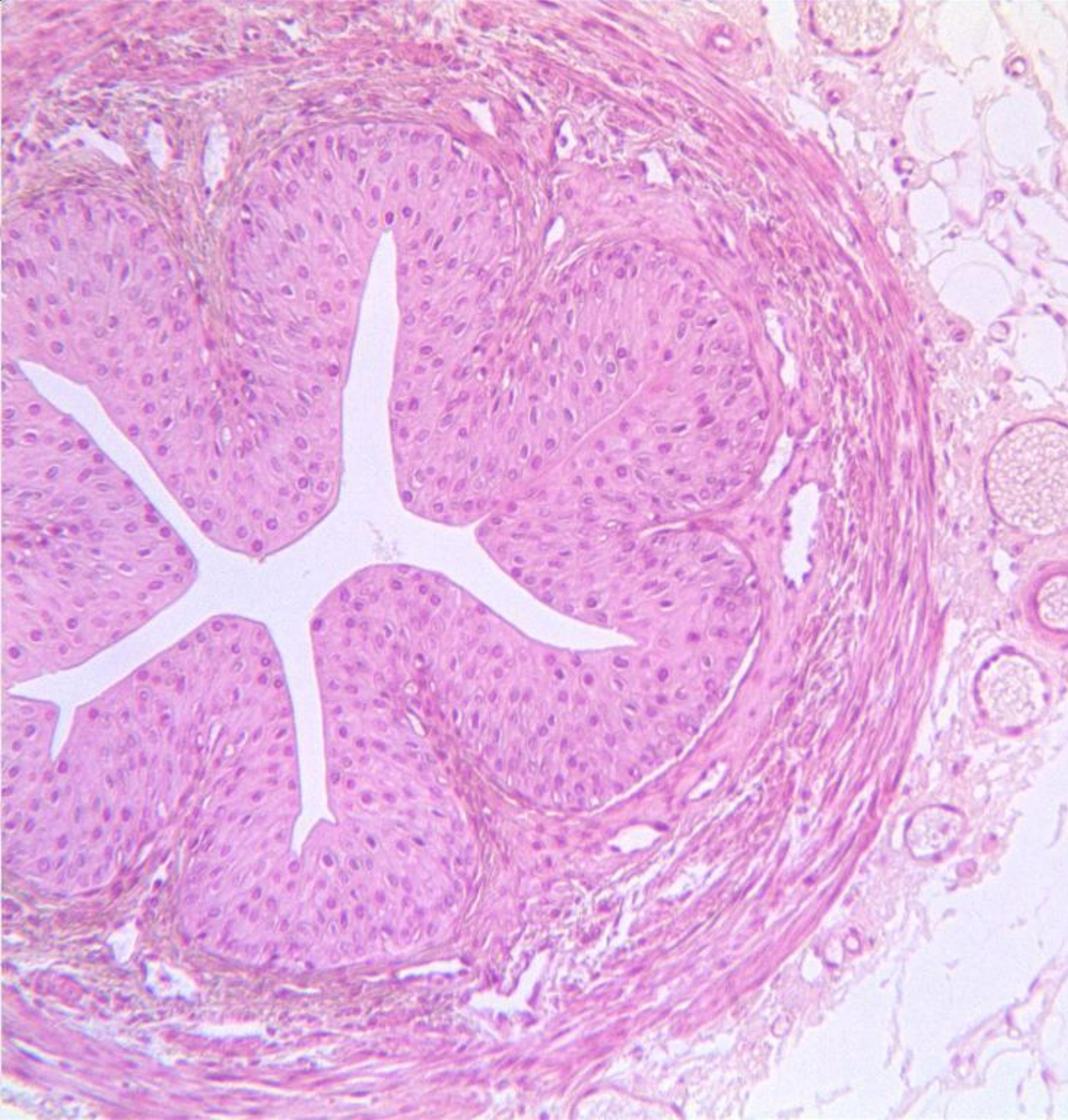Juxta glomerular cells



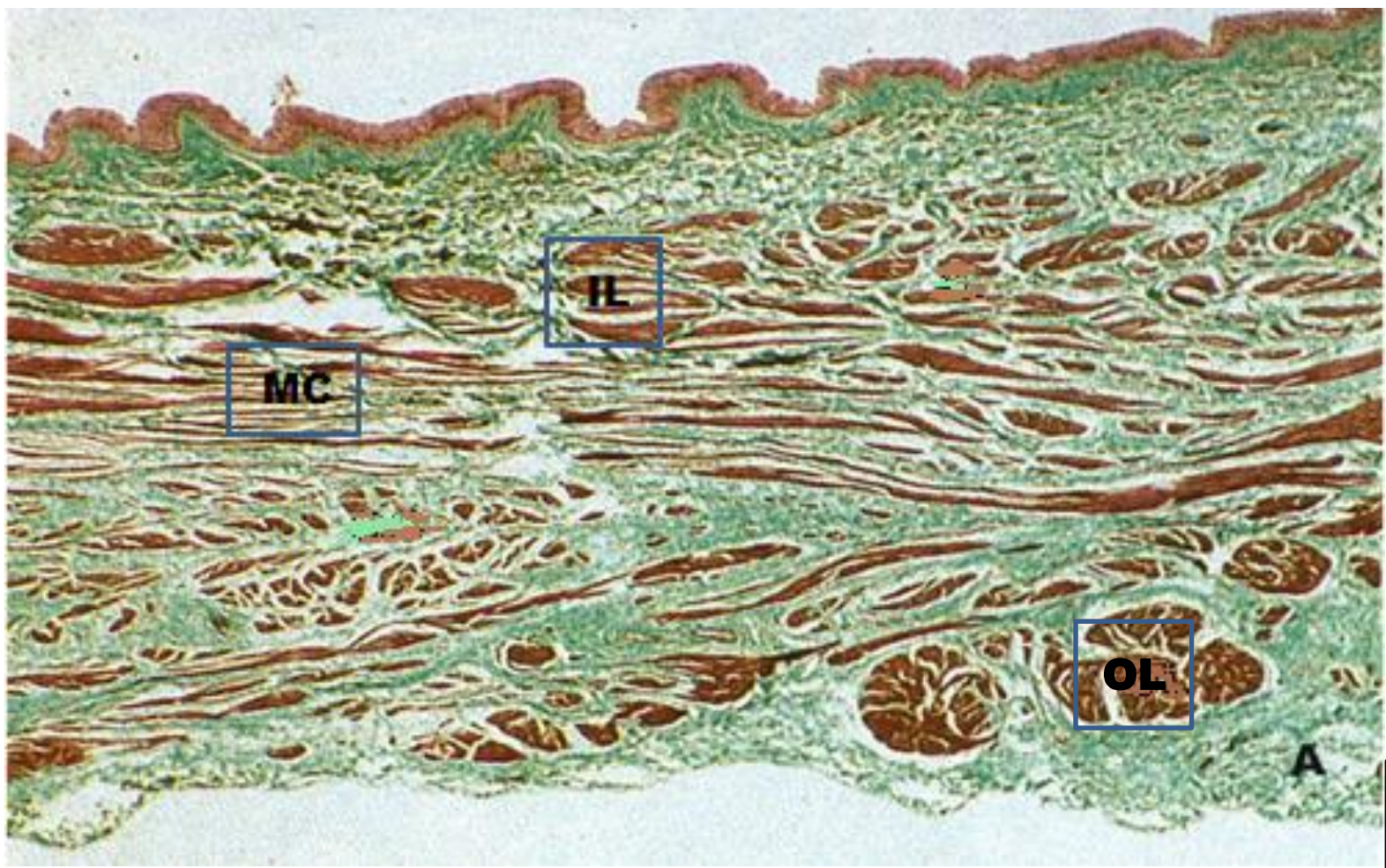
**Macula
densa**

Juxta glomerular cells

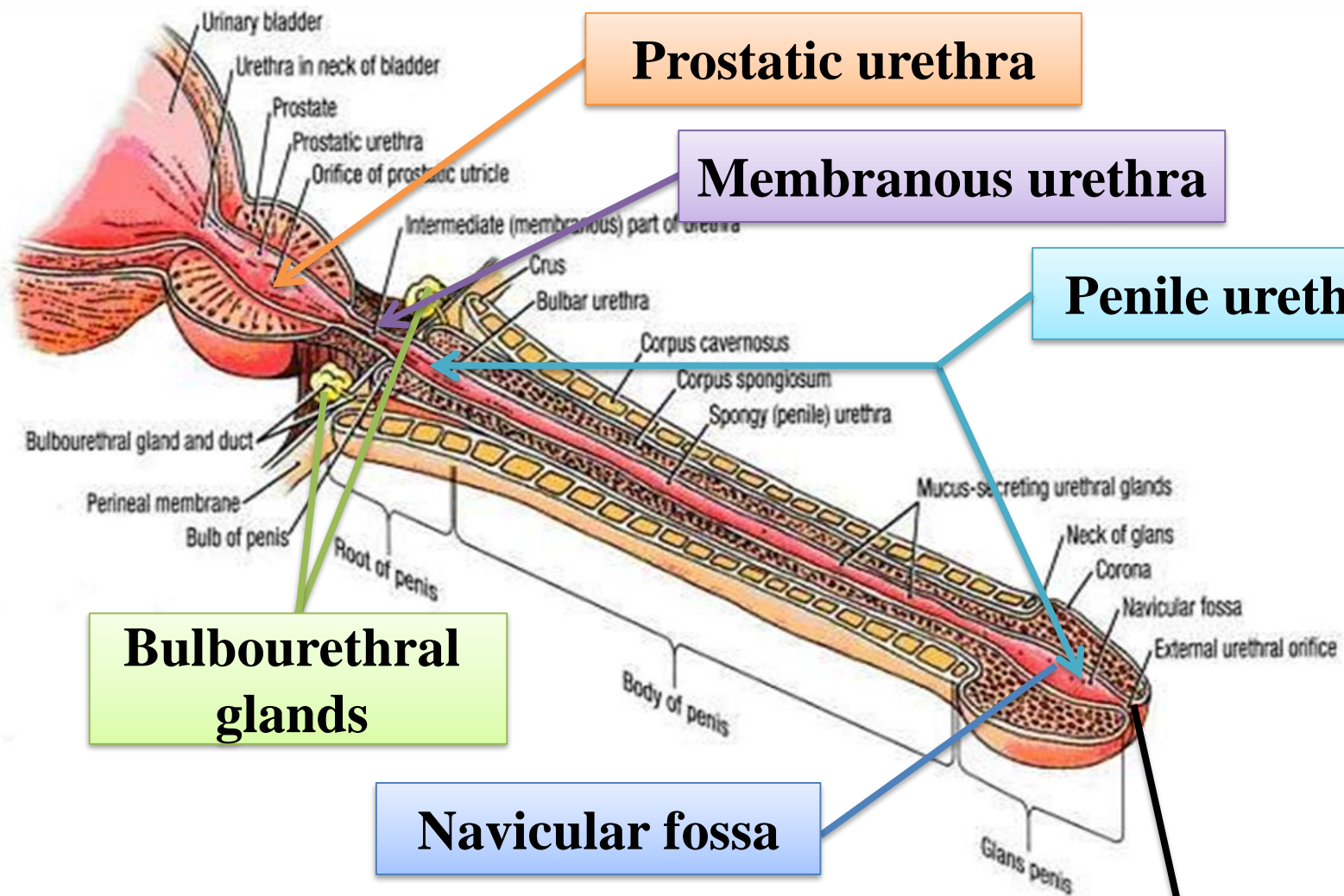
Proximal convoluted tubules



**Section
through
ureter**



The wall of the bladder: Note the three muscular layers: Outer longitudinal (OL; middle circular (MC), and Inner longitudinal (IL); and the adventitia layer (A).



Prostatic urethra

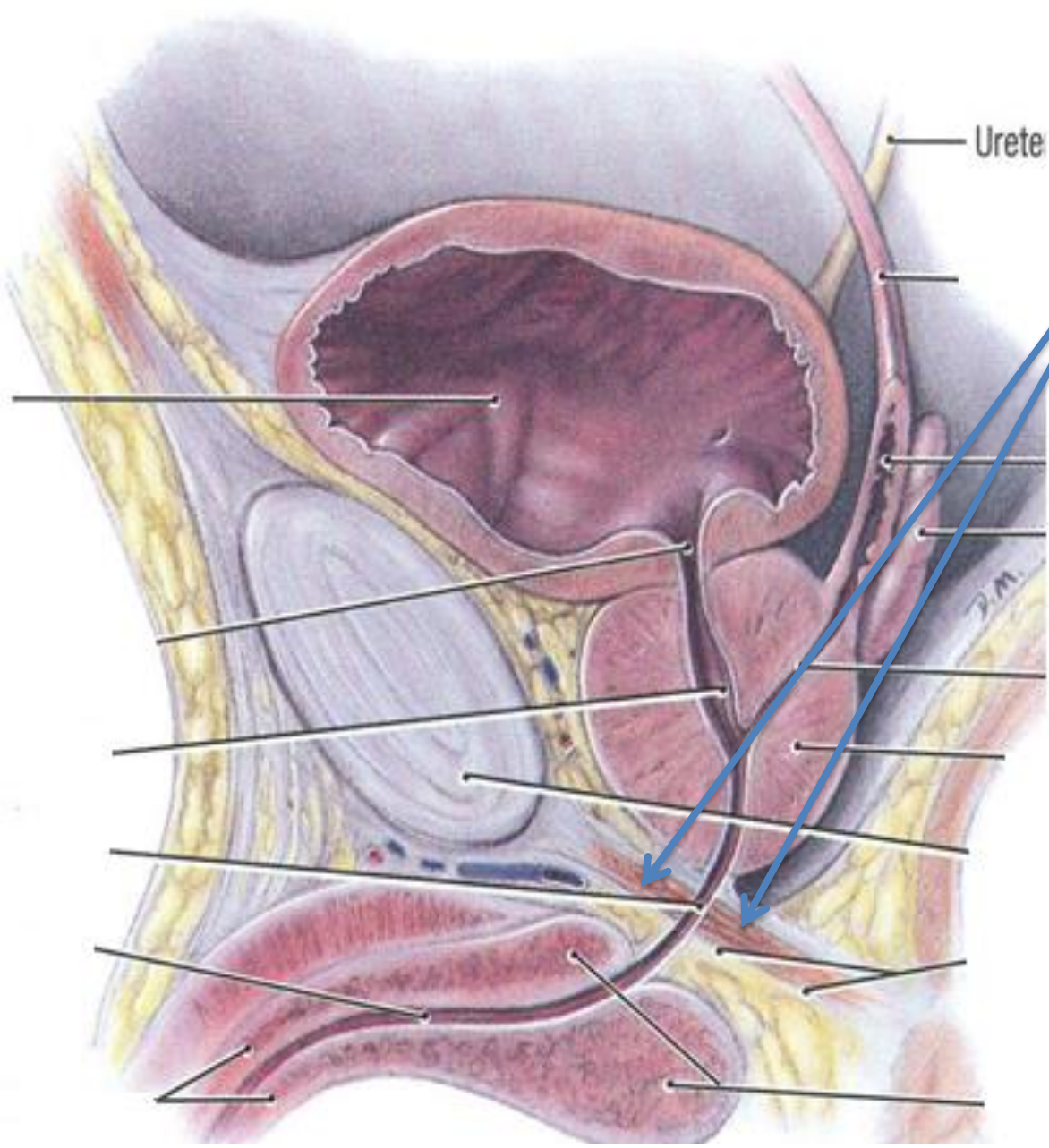
Membranous urethra

Penile urethra

Bulbourethral glands

Navicular fossa

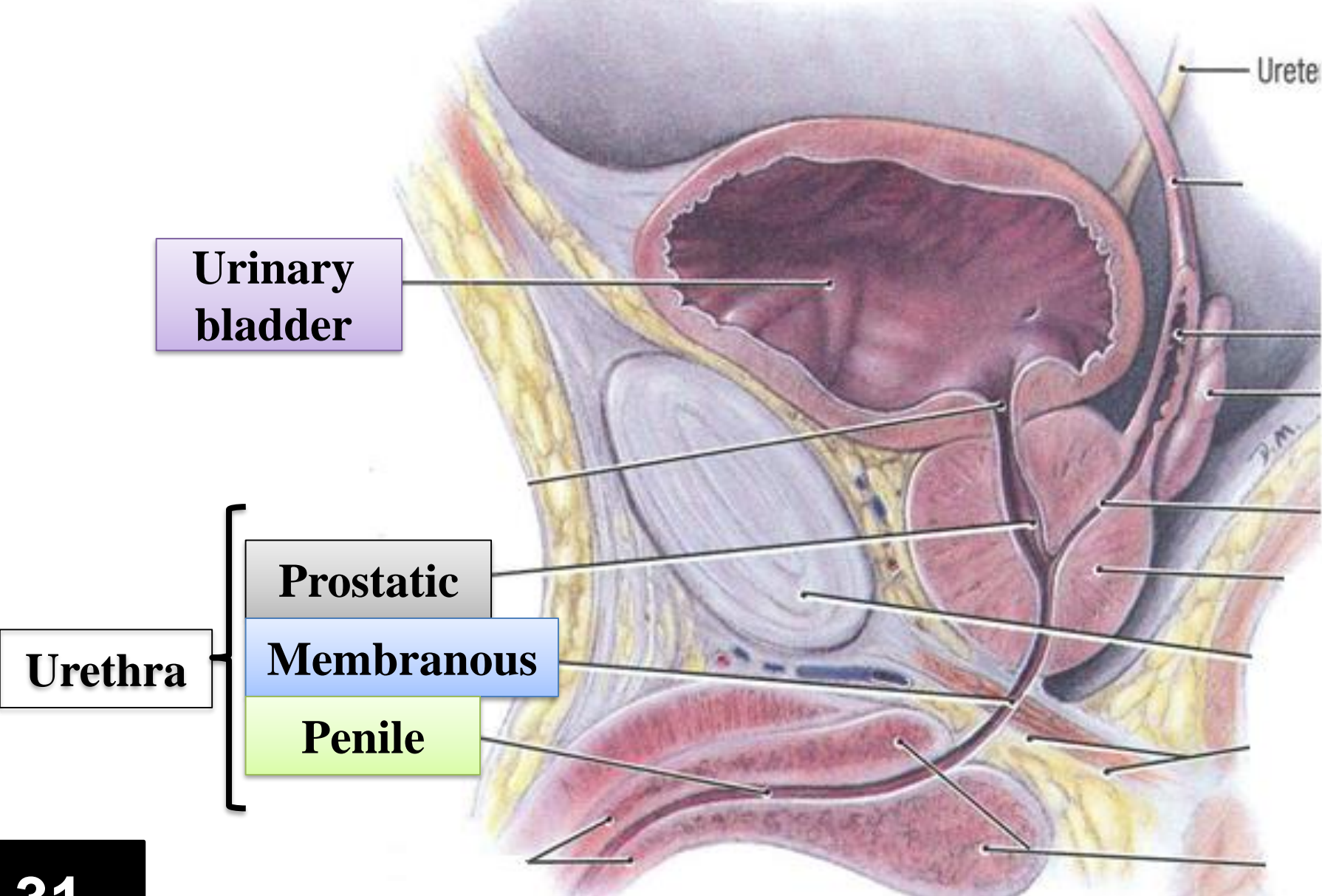
External urethral orifice

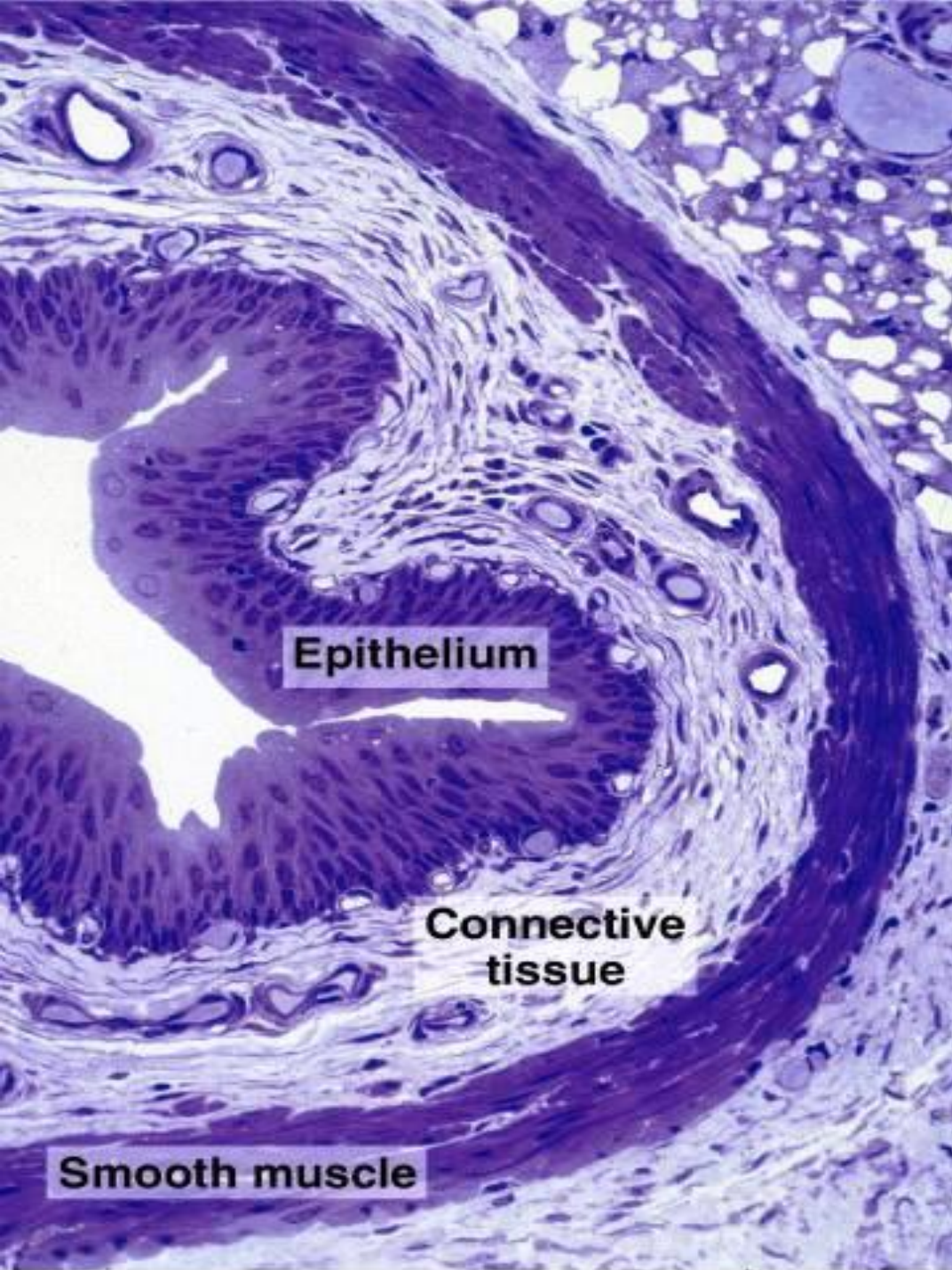


Urete


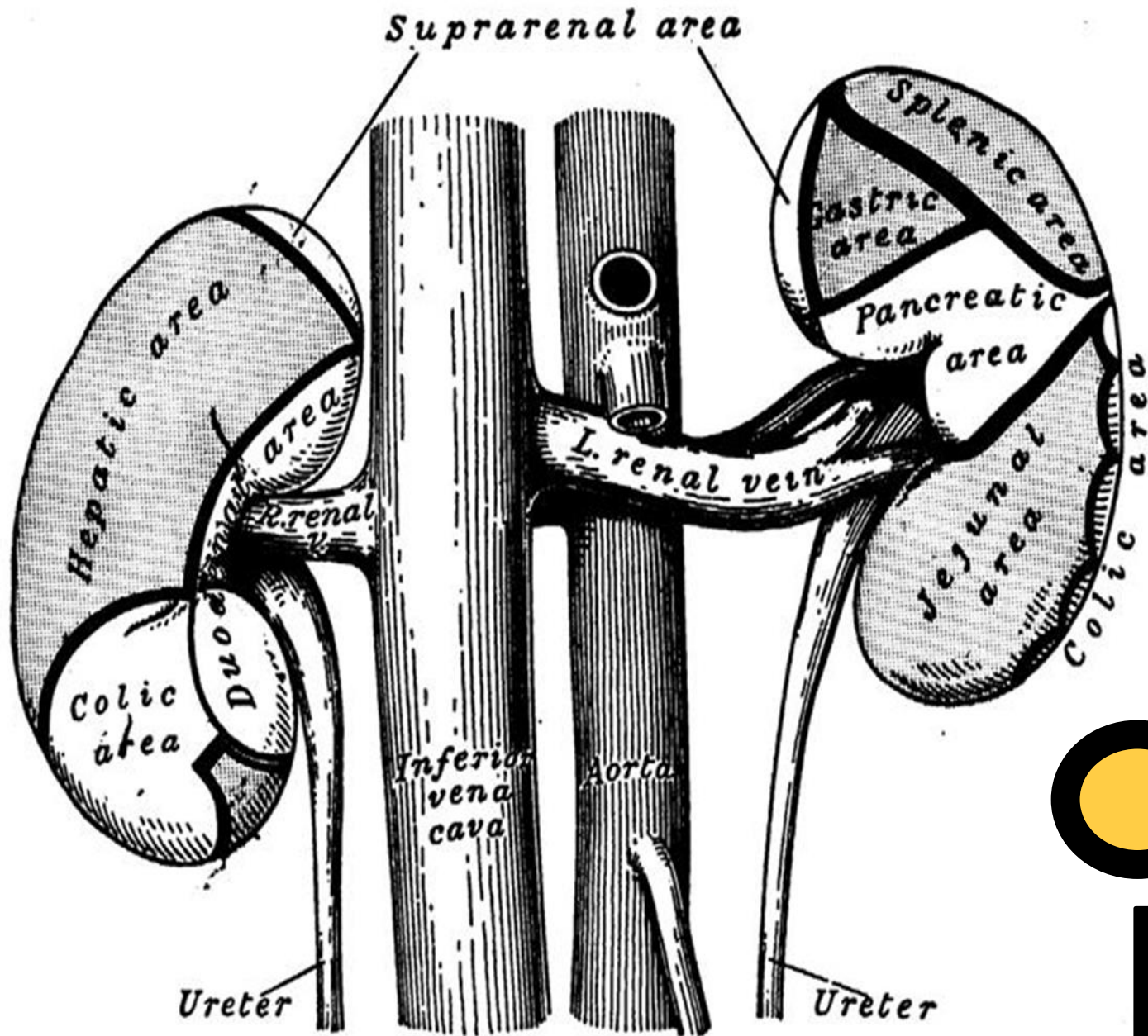
**Sphincter urethrae
(external urethral
sphincter)**

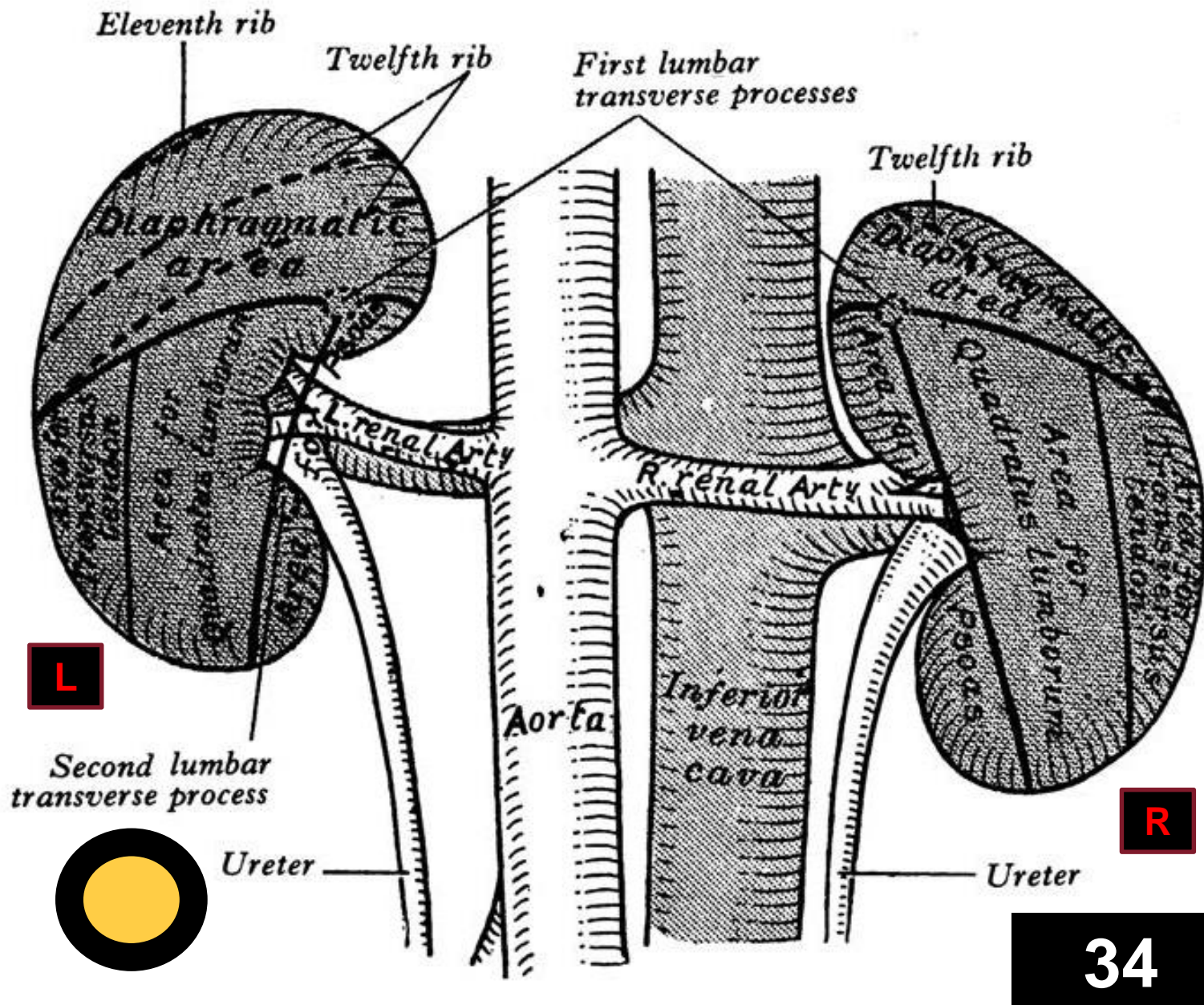
Male Urethra



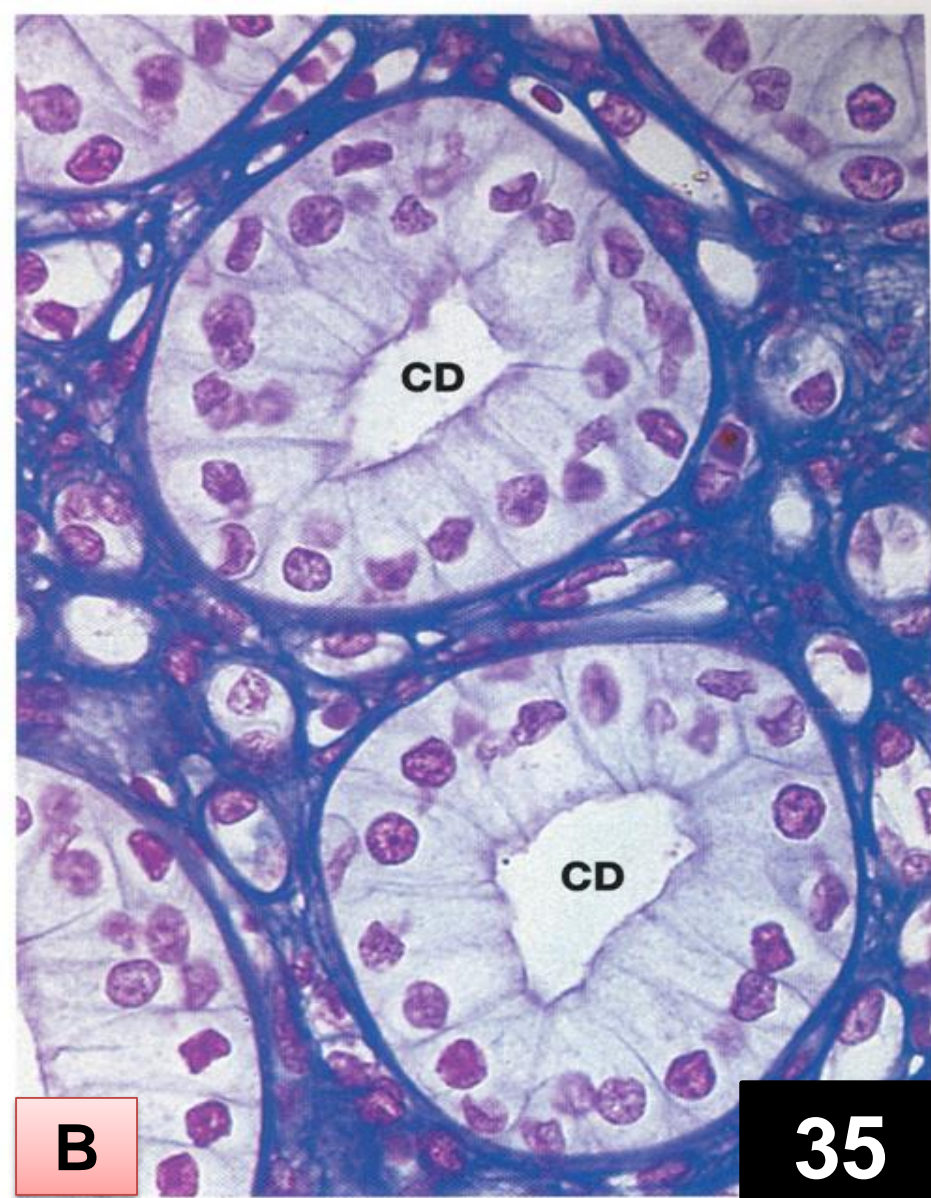
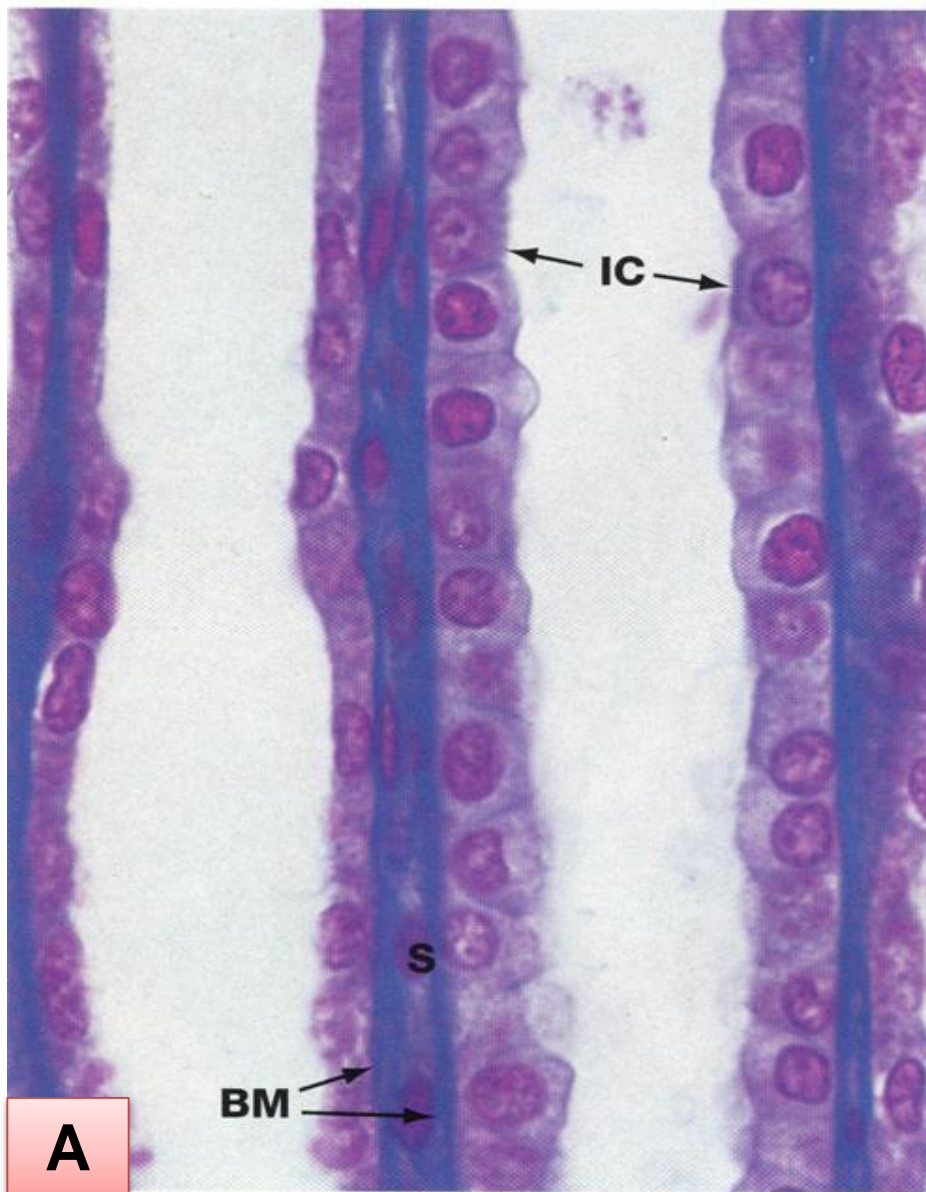


Section through ureter





Posterior relations of the kidneys



35

Section through renal medulla, showing A. Collecting tubules; and B. Collecting ducts (CD)

Ampulla part of uterine tube

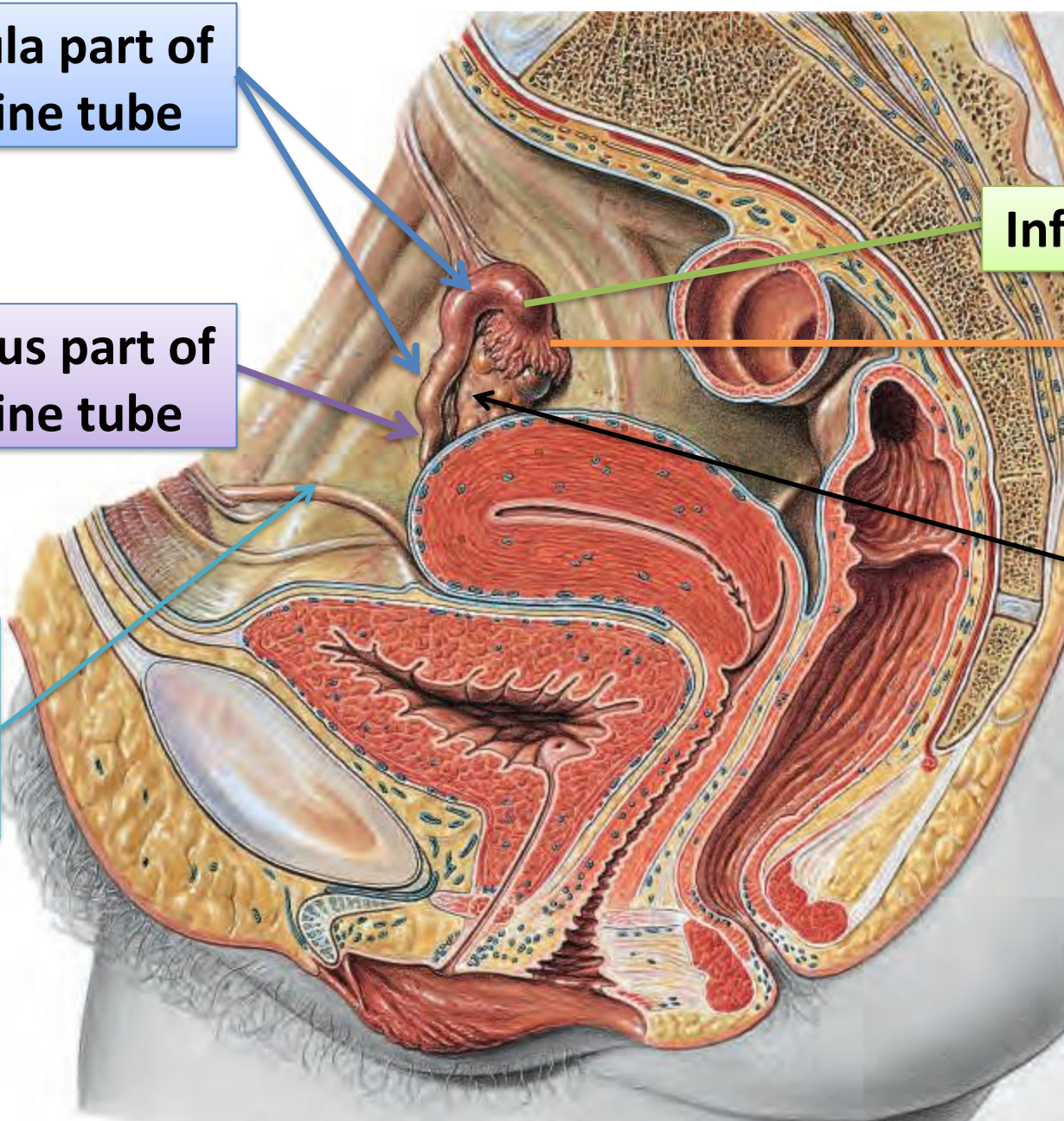
Isthmus part of uterine tube

Round ligament of uterus

Infundibulum

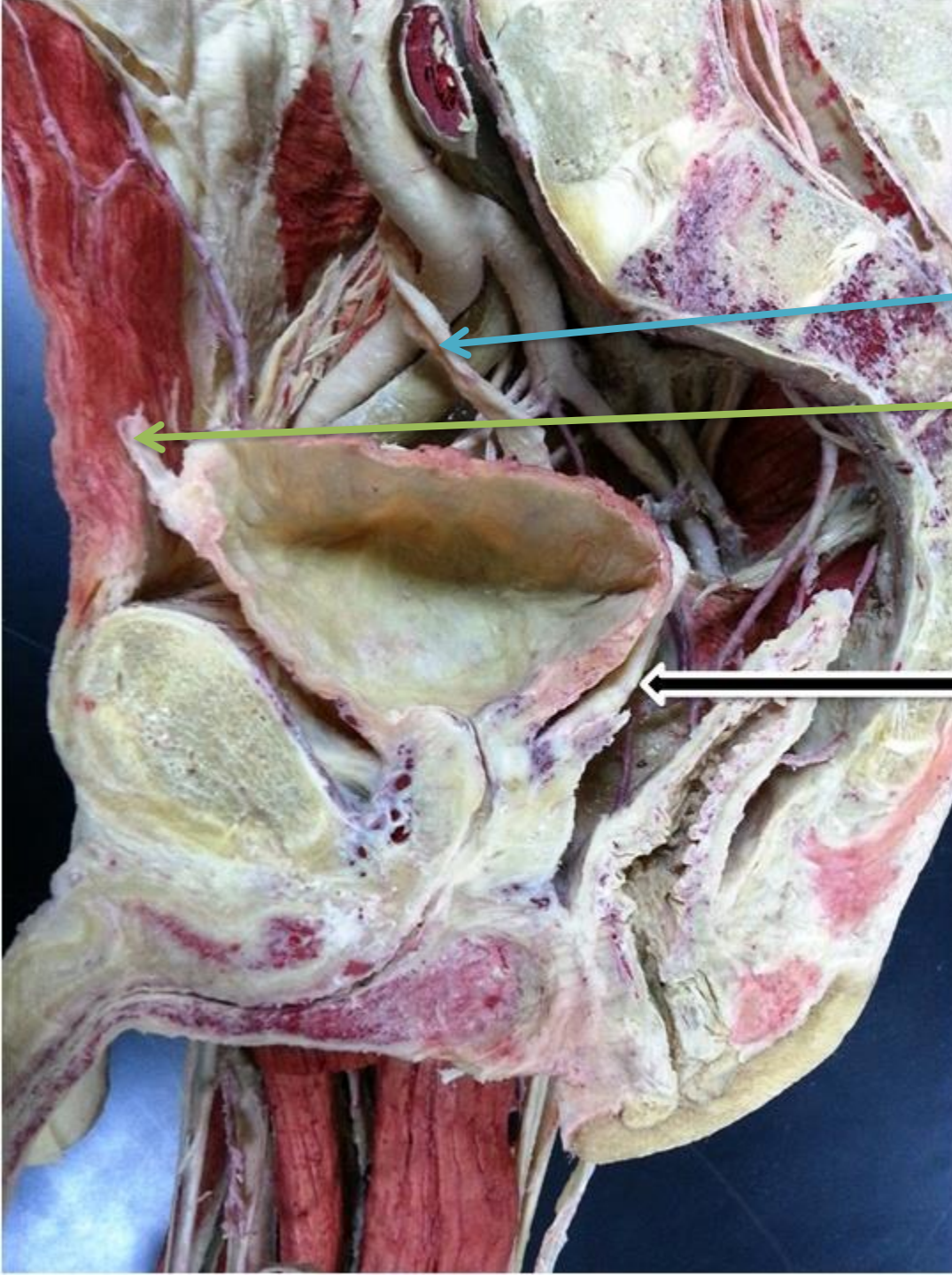
Fimbriae

Ovary



Right Ovary and Parts of Uterine Tube

UGS Lab 2

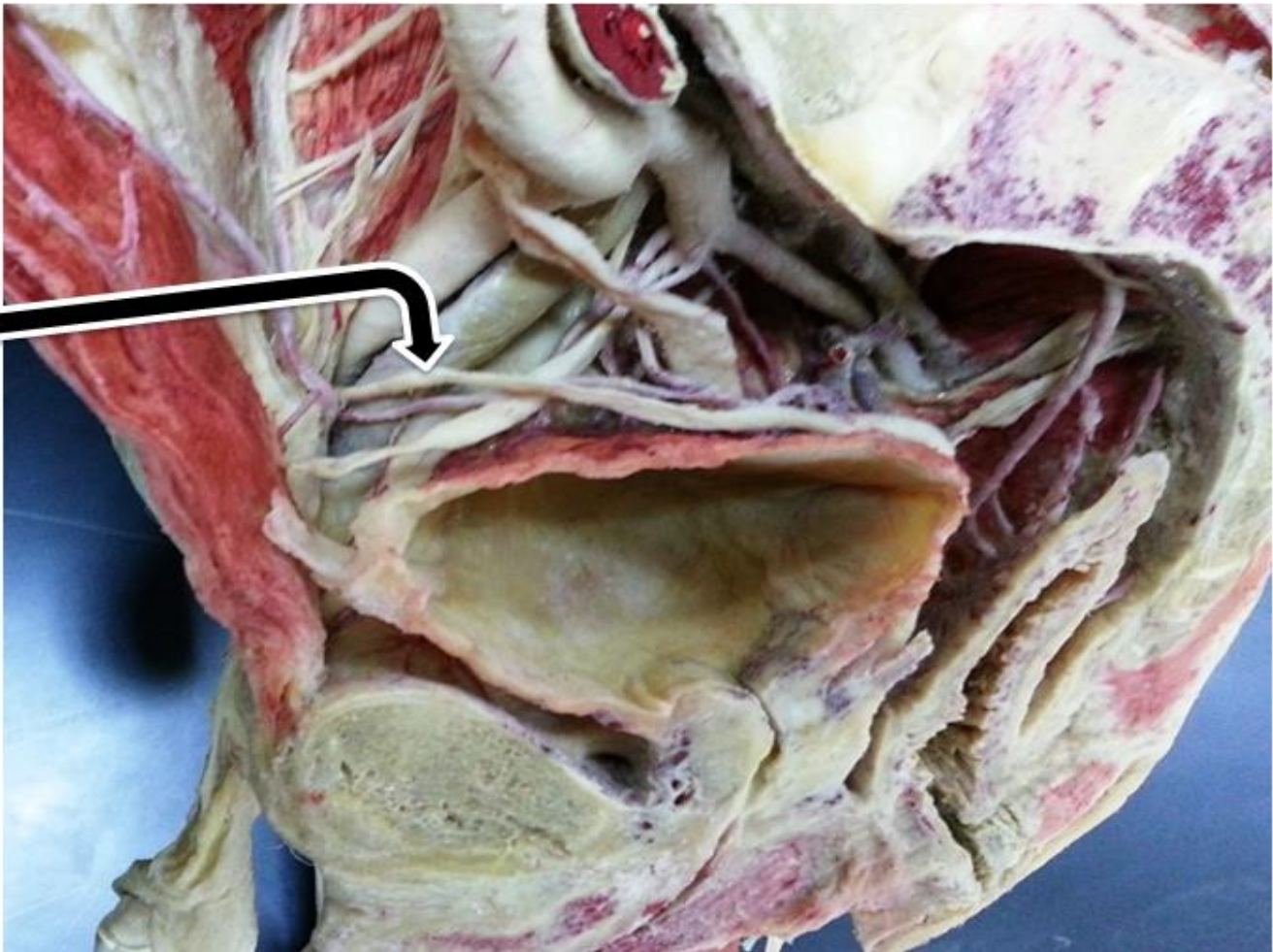


Ureter

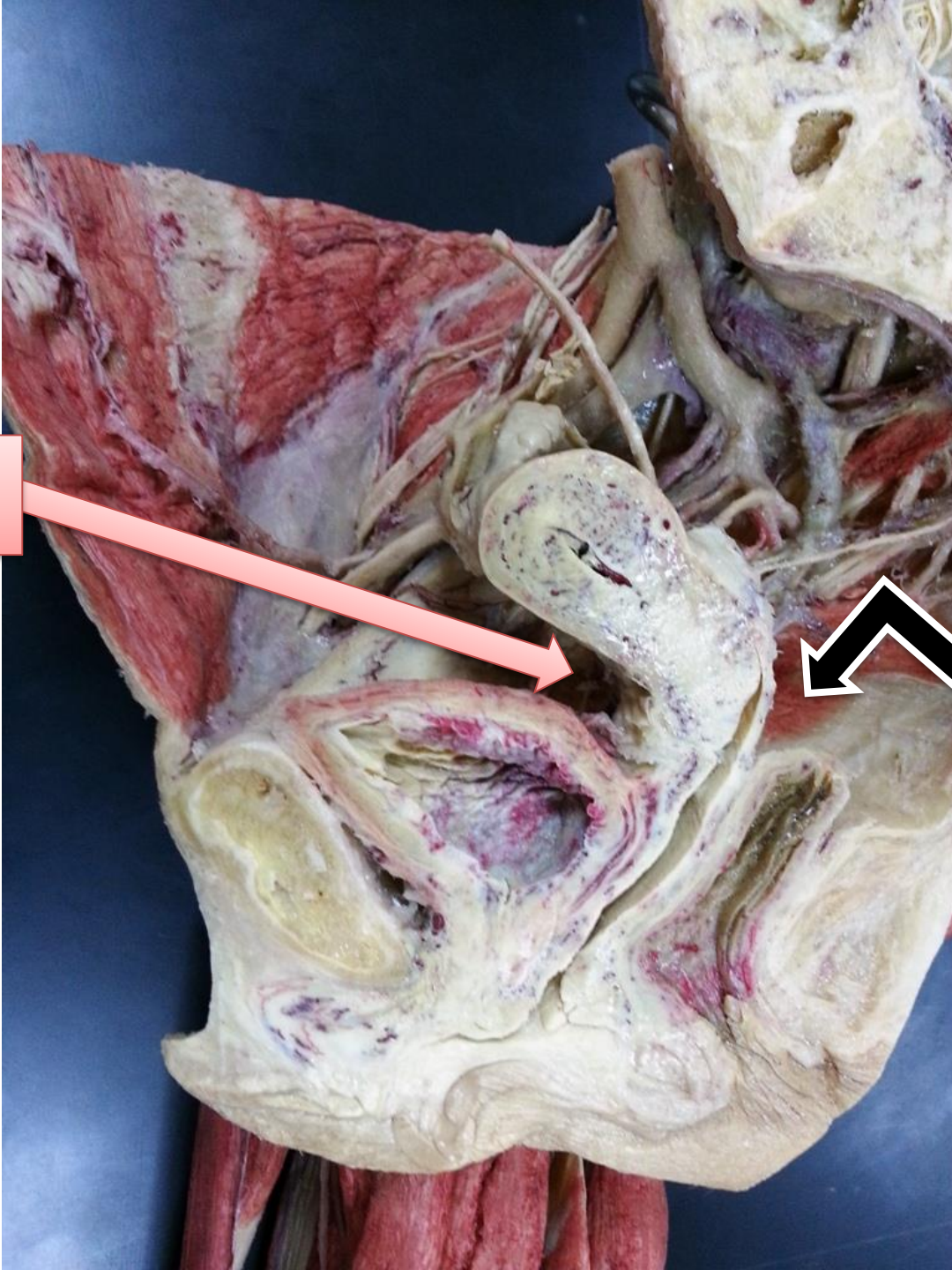
Median umbilical ligament

Vas deferens

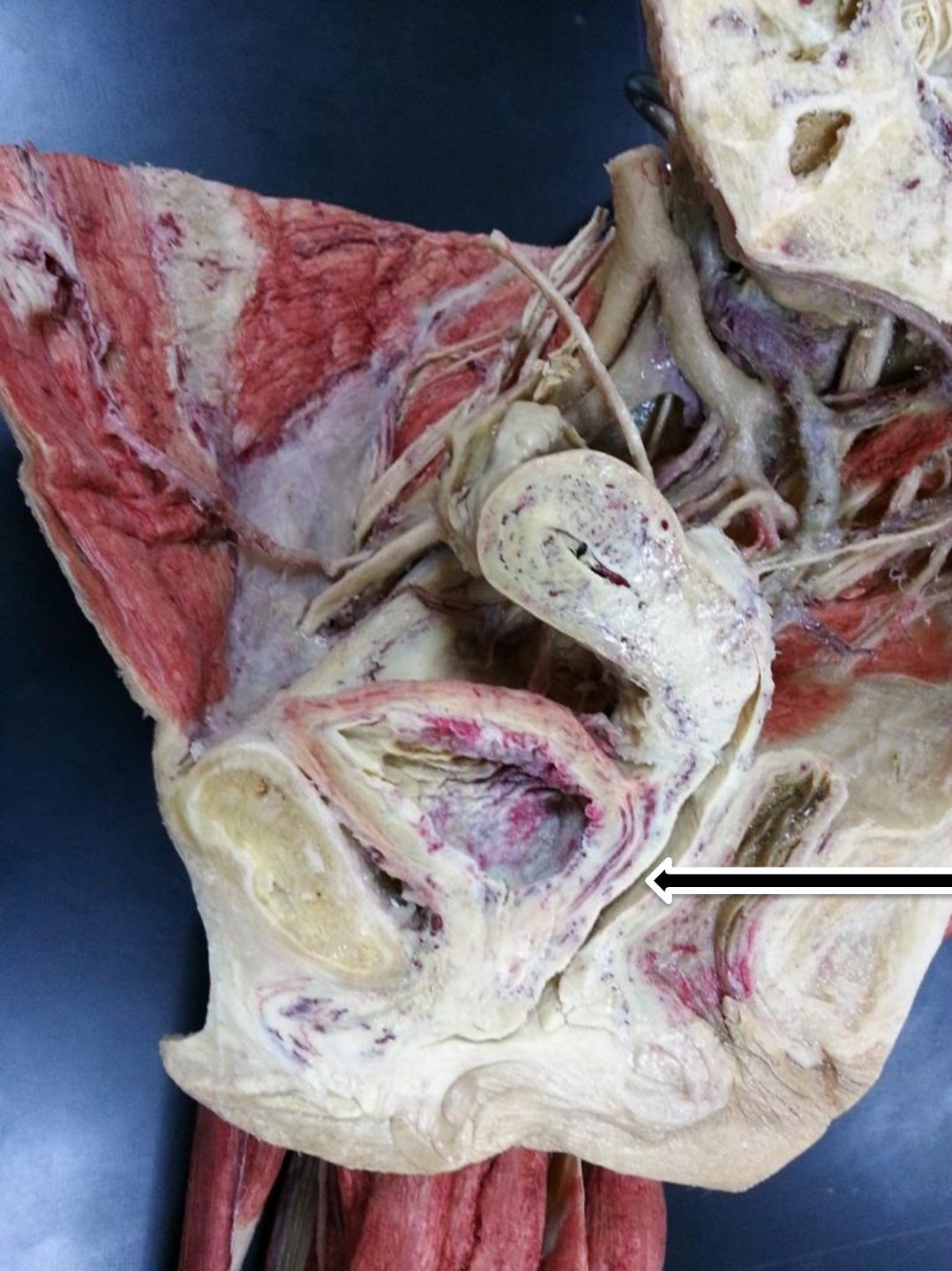
Vas deferens



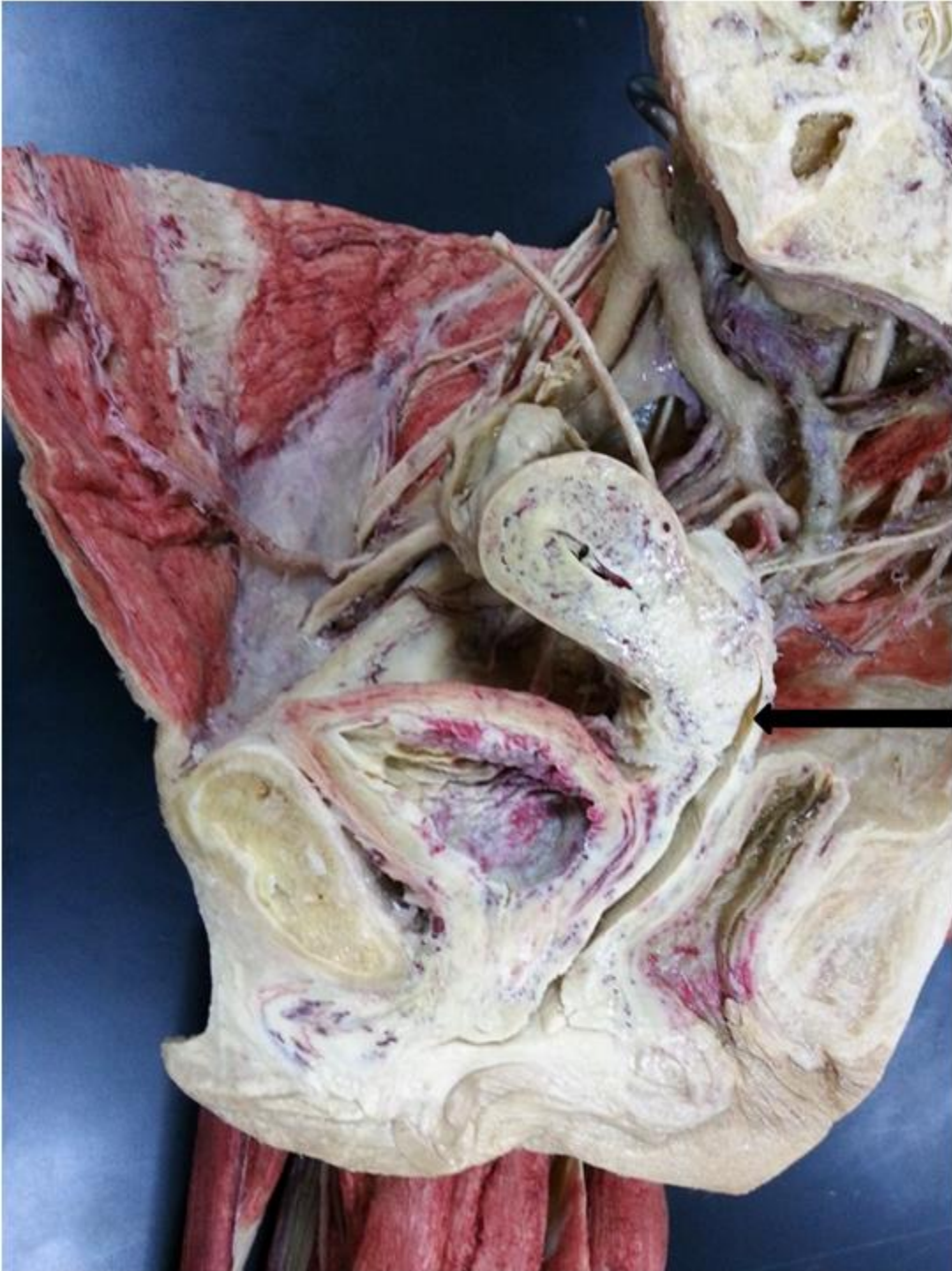**Uterovesical
pouch**



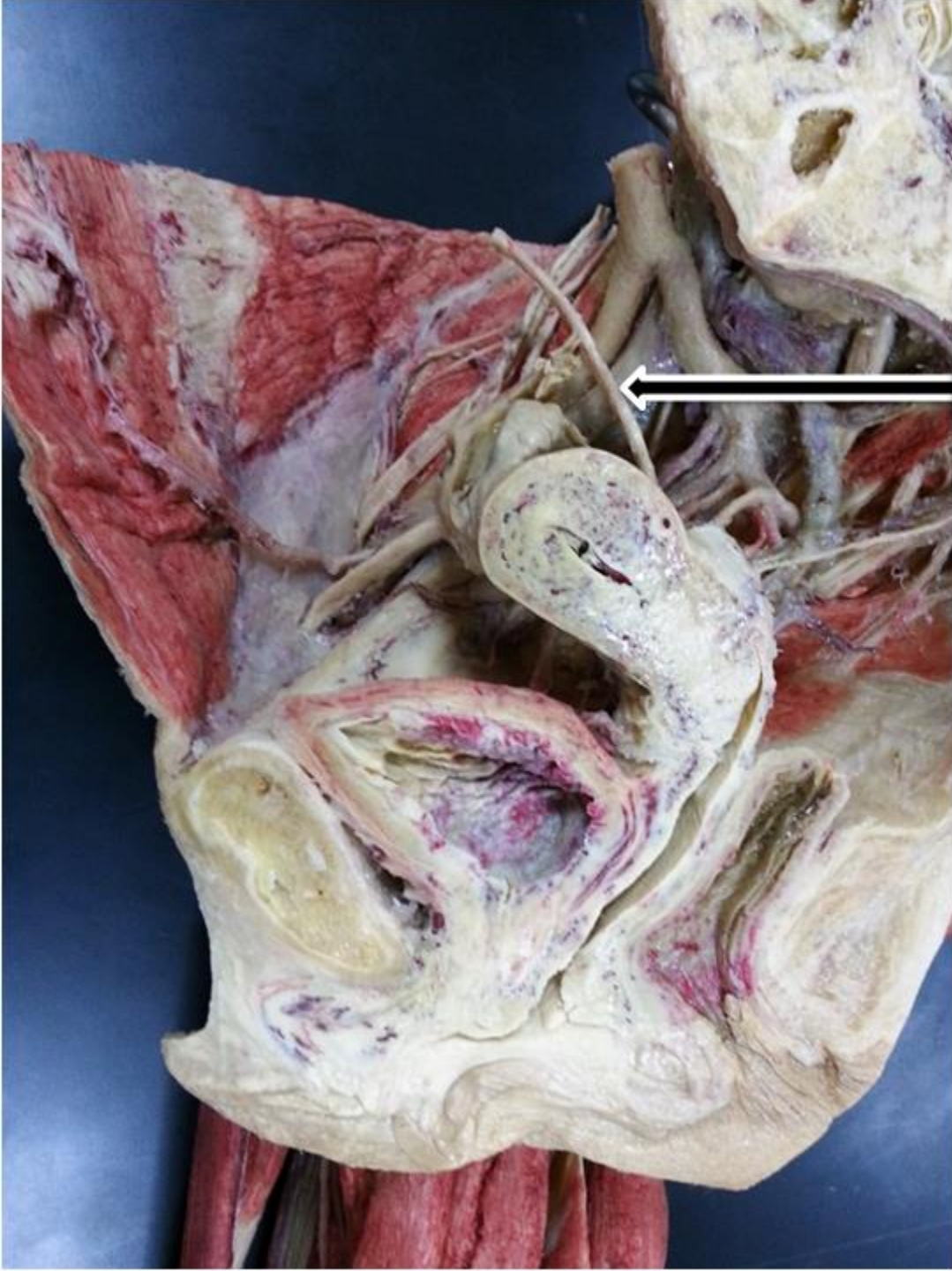
Pouch of Douglas



Vagina

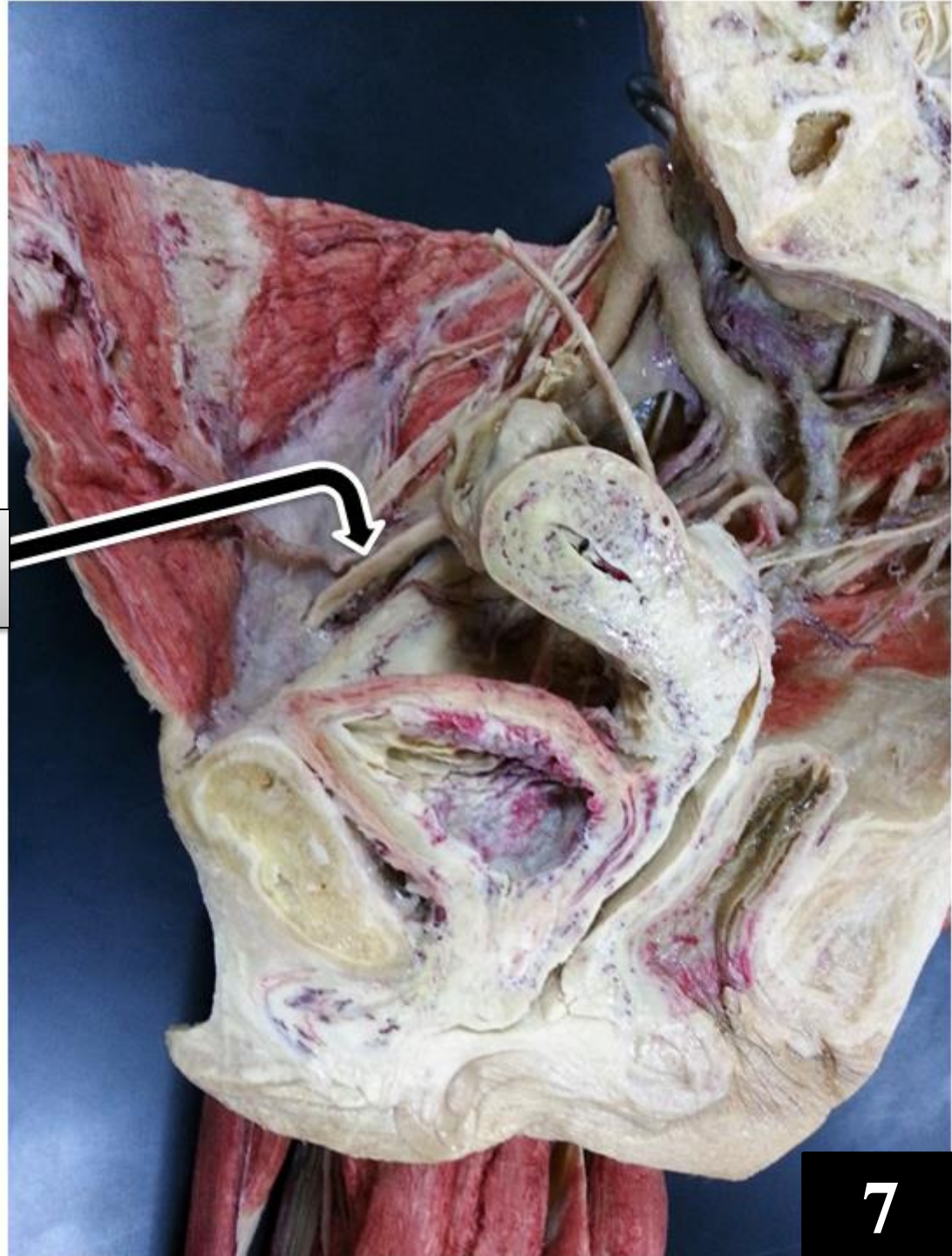


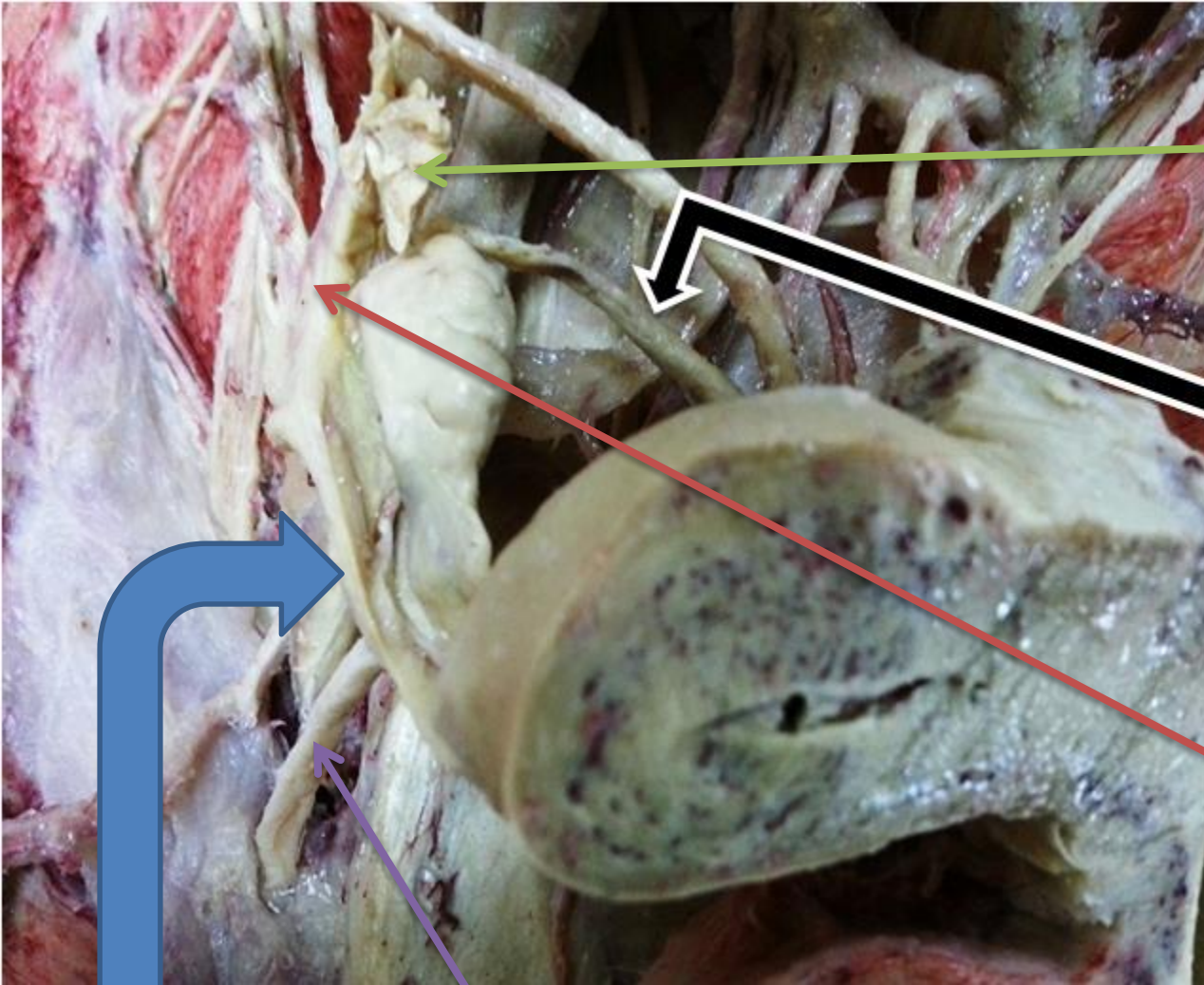
Posterior vaginal fornix



Ureter

**Round ligament of
uterus**





Fimbria of infundibulum

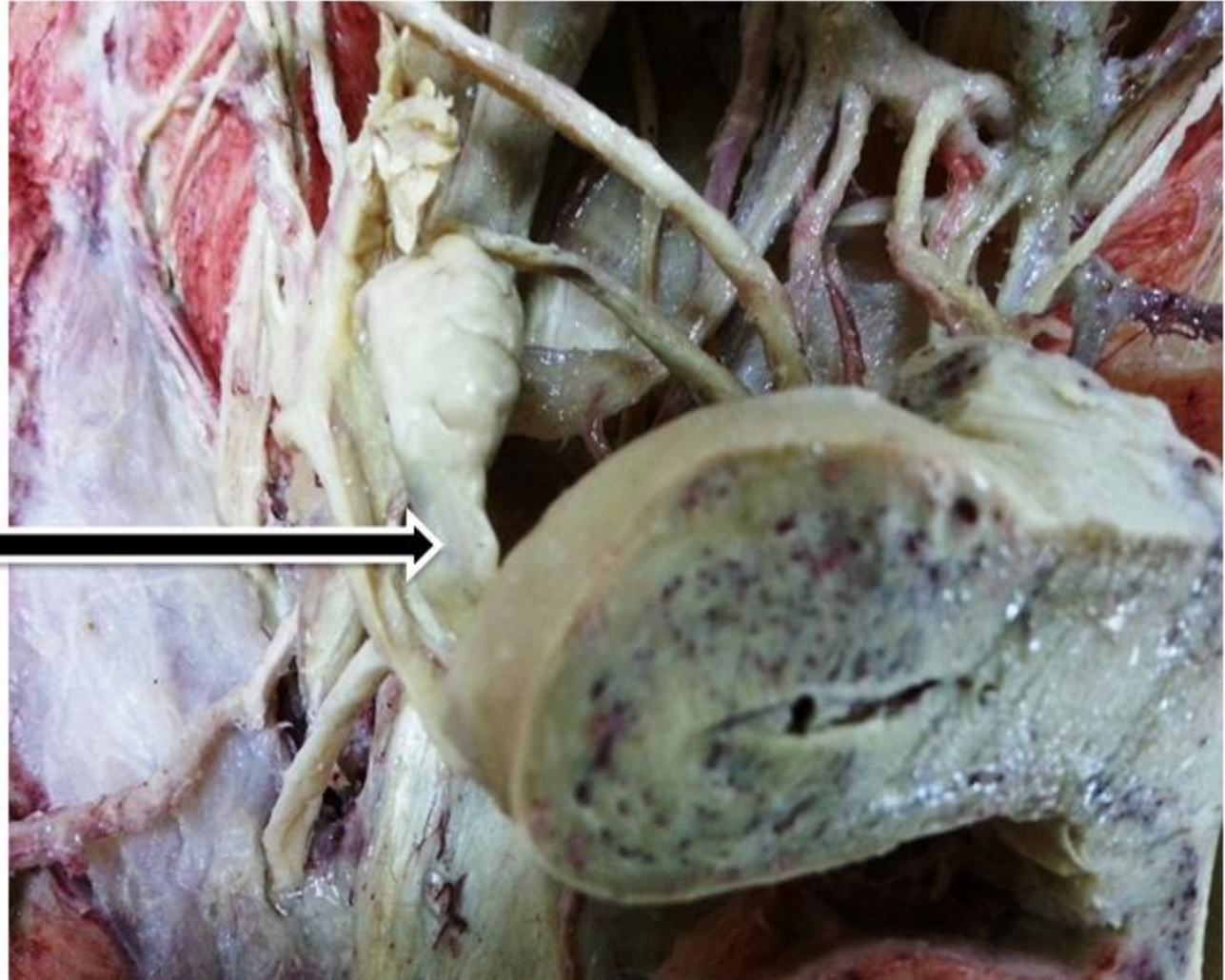Ovarian ligament

Ampula of uterine tube

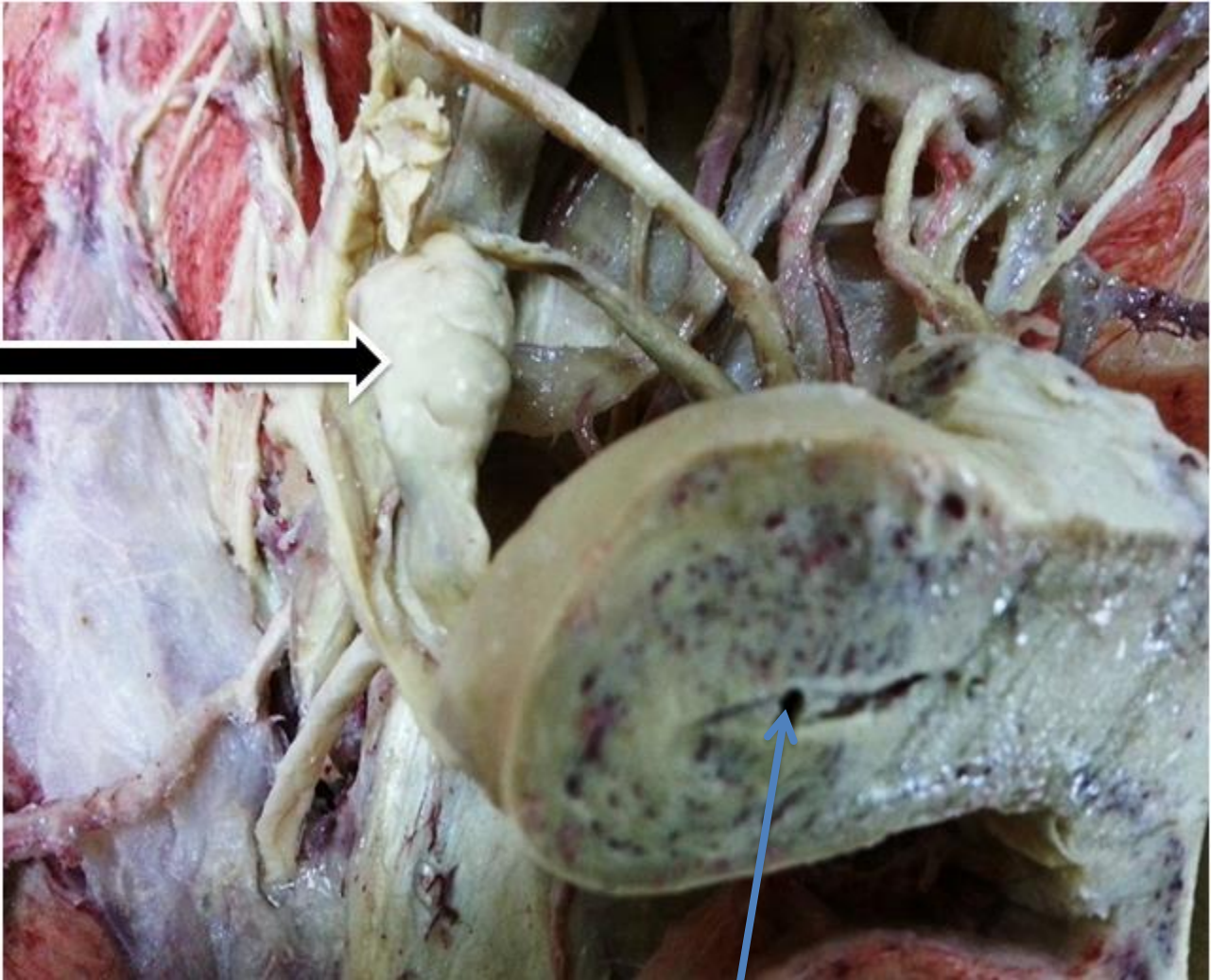
Round ligament of uterus

Isthmus part of uterine tube

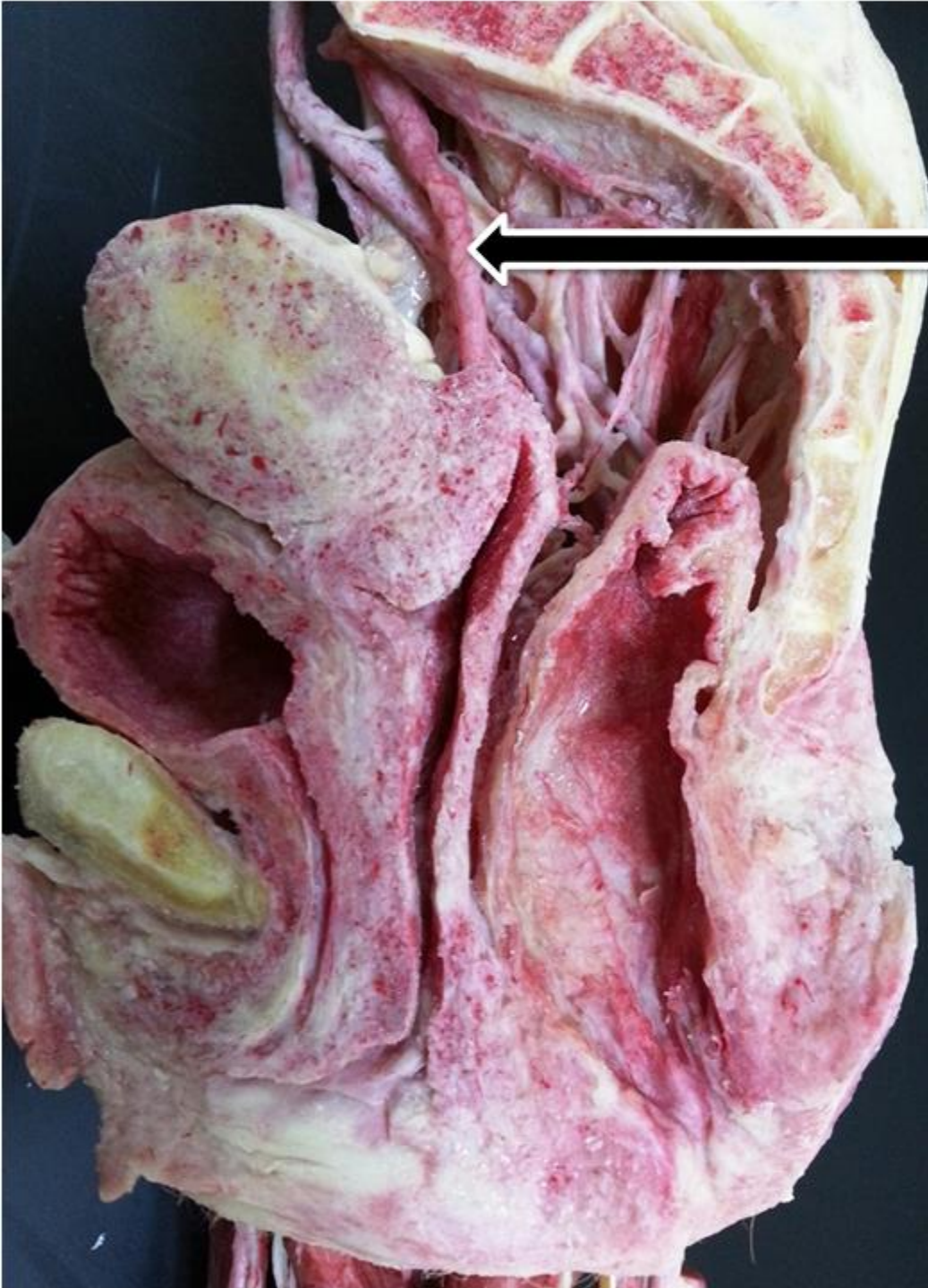
**Suspensory ligament
of ovary**



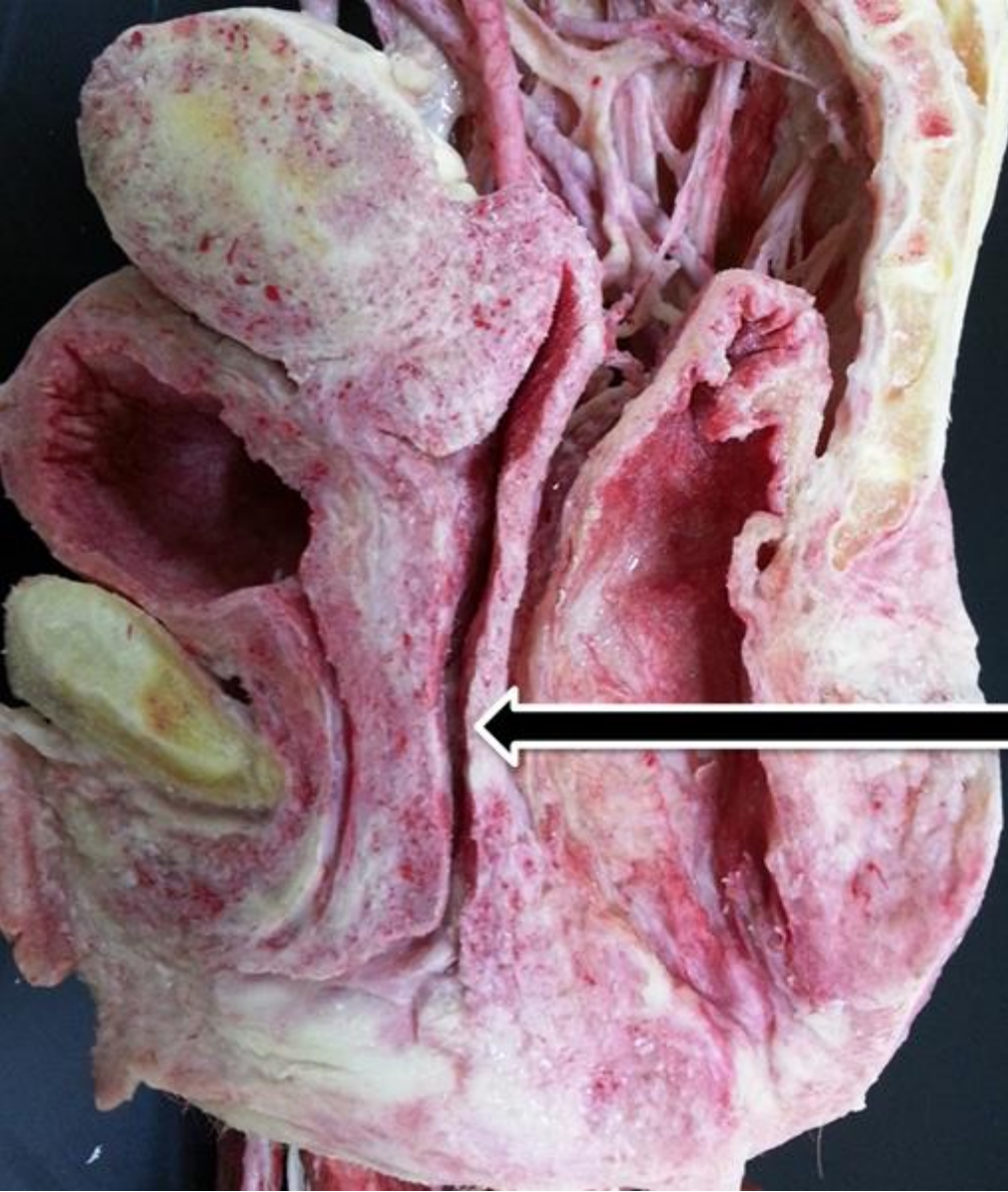
Ovary



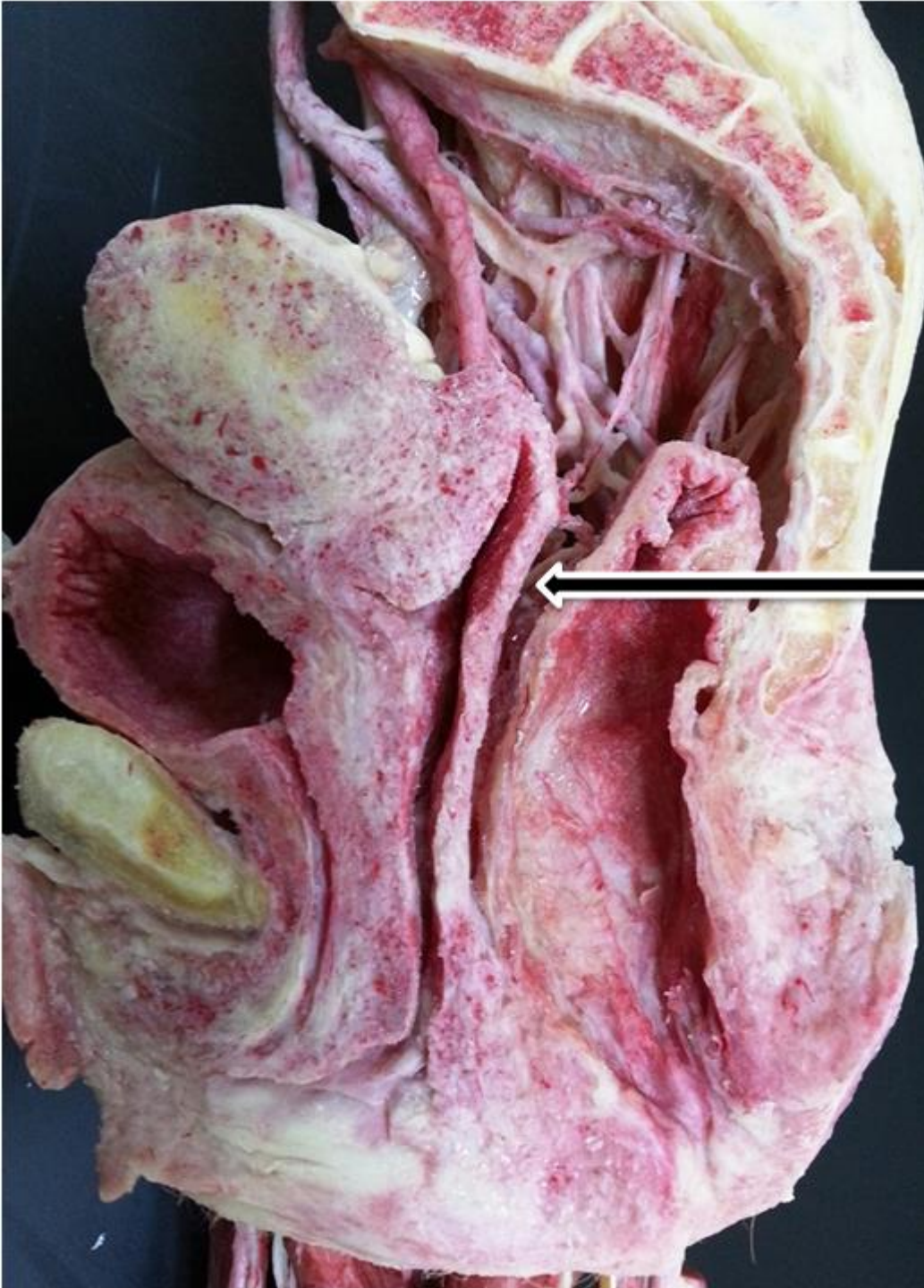
Uterine cavity



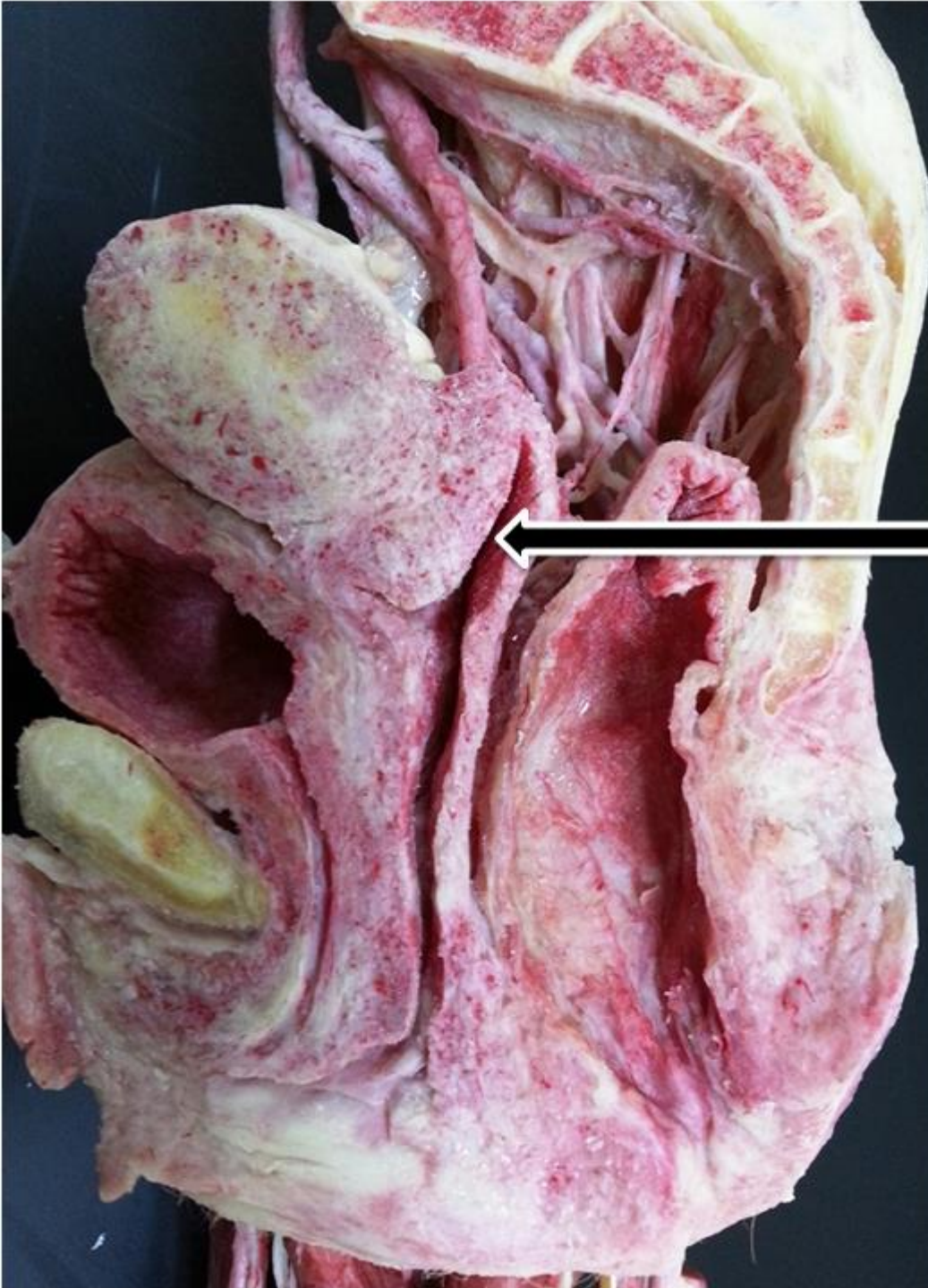Round ligament of uterus




Vagina

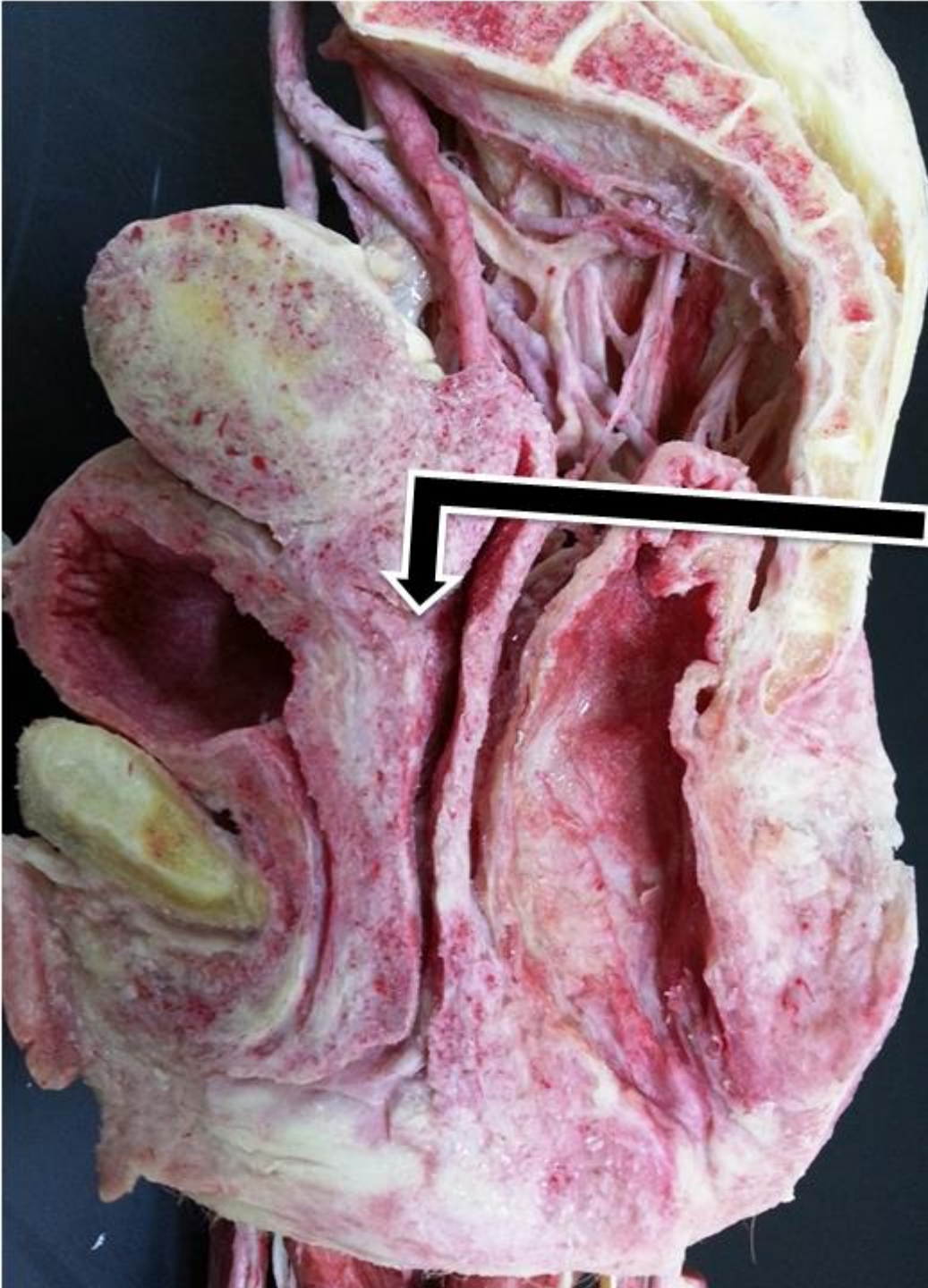

Pouch of Douglas

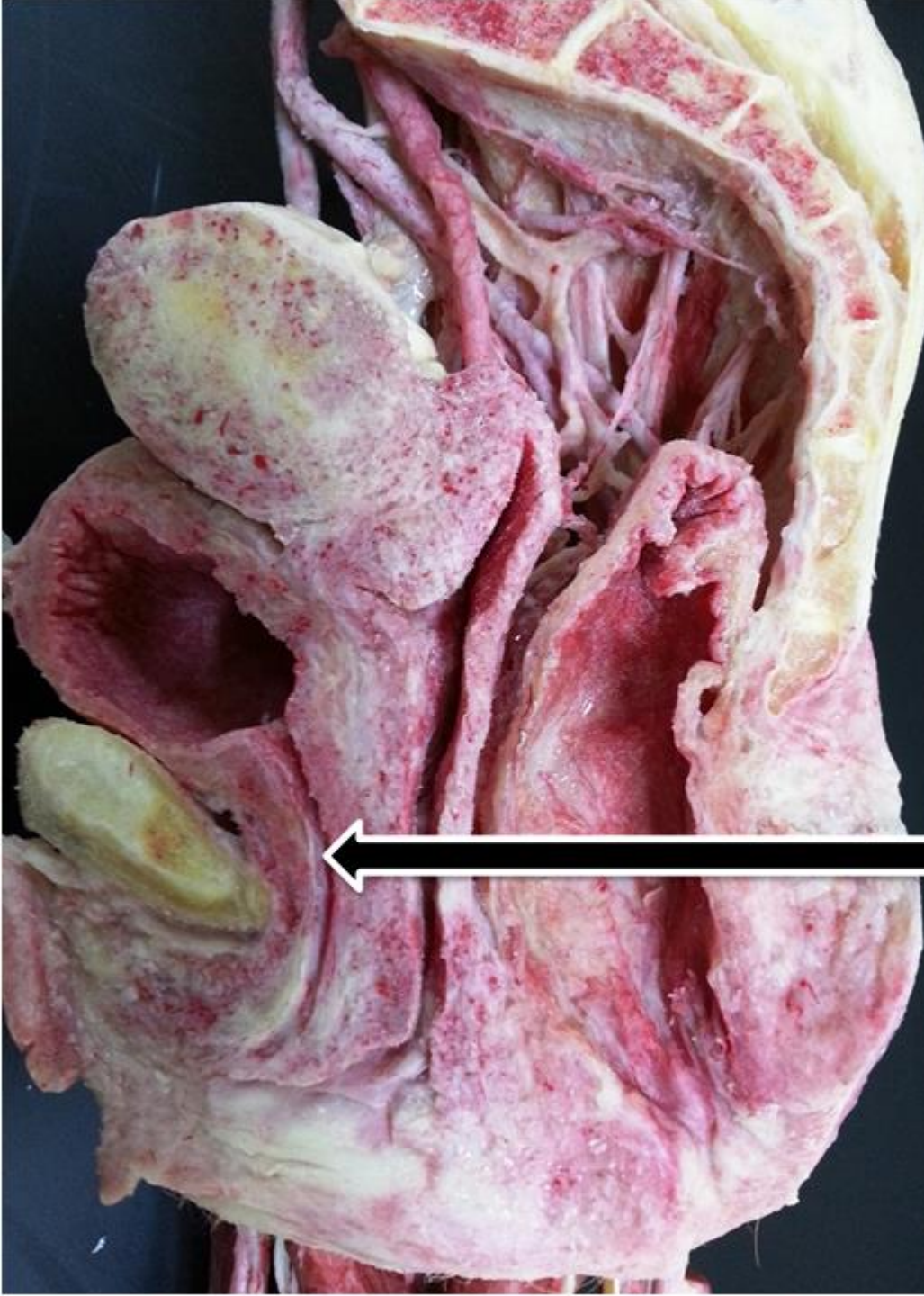

Posterior vaginal fornix

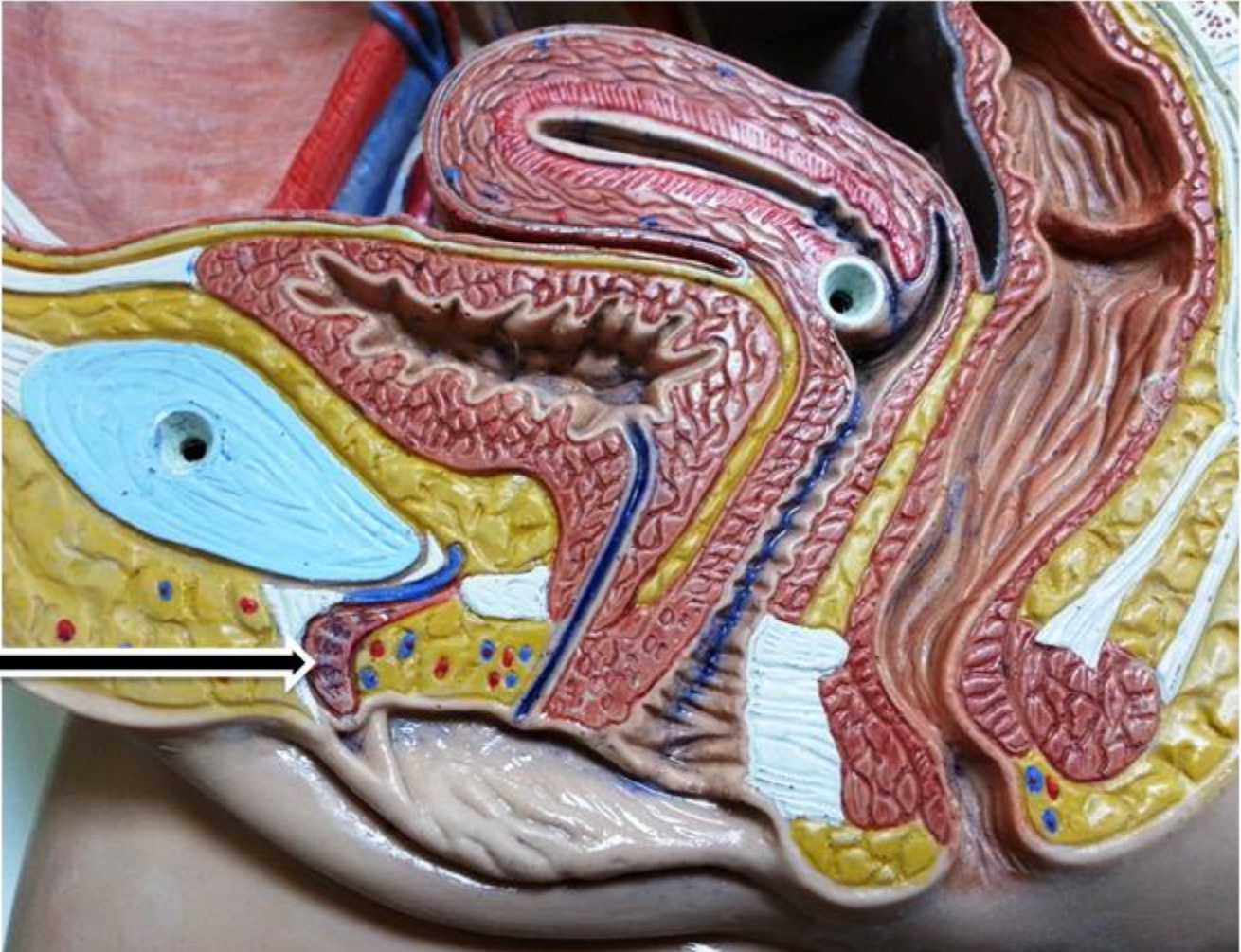




**Anterior vaginal
fornix.**



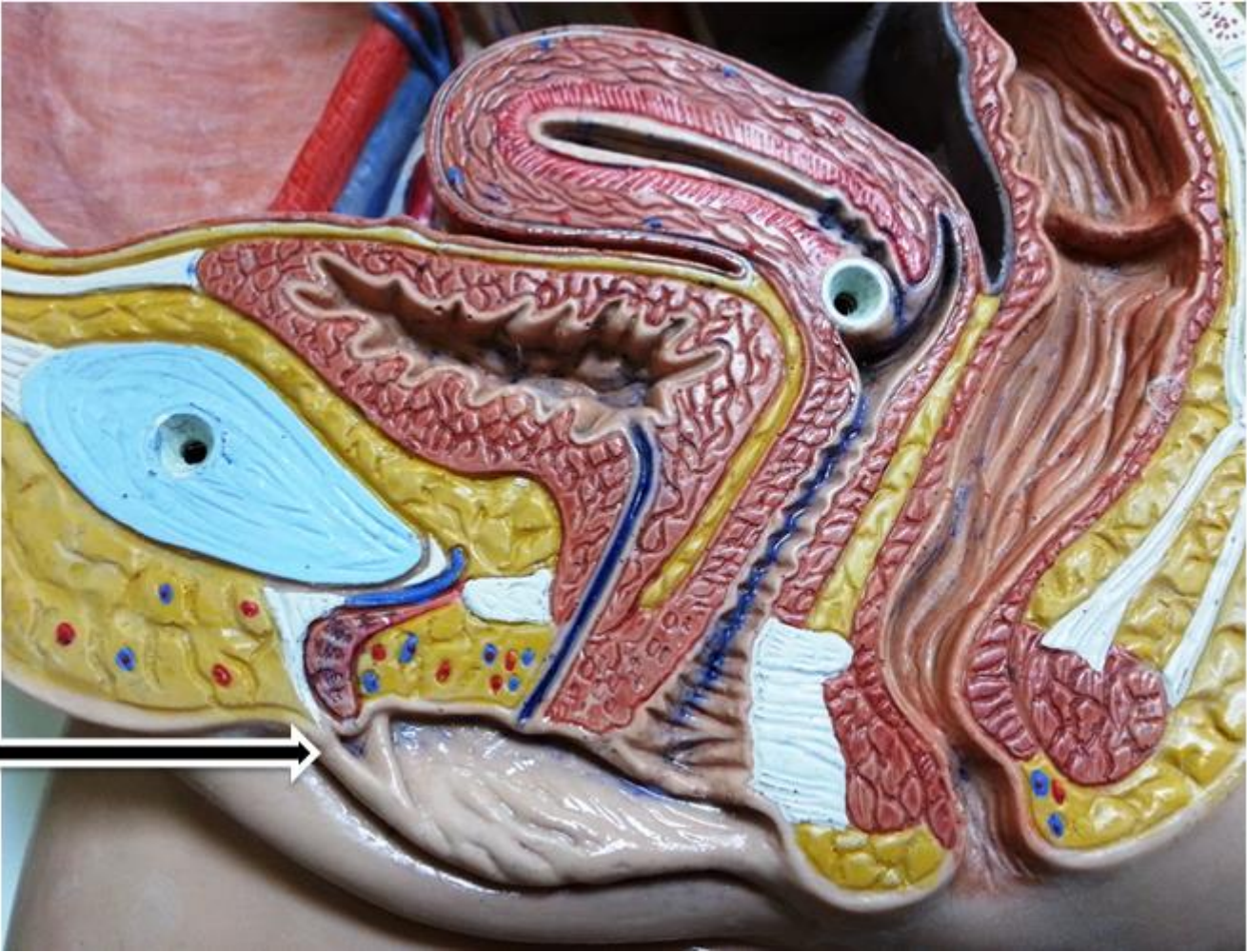
Female Urethra

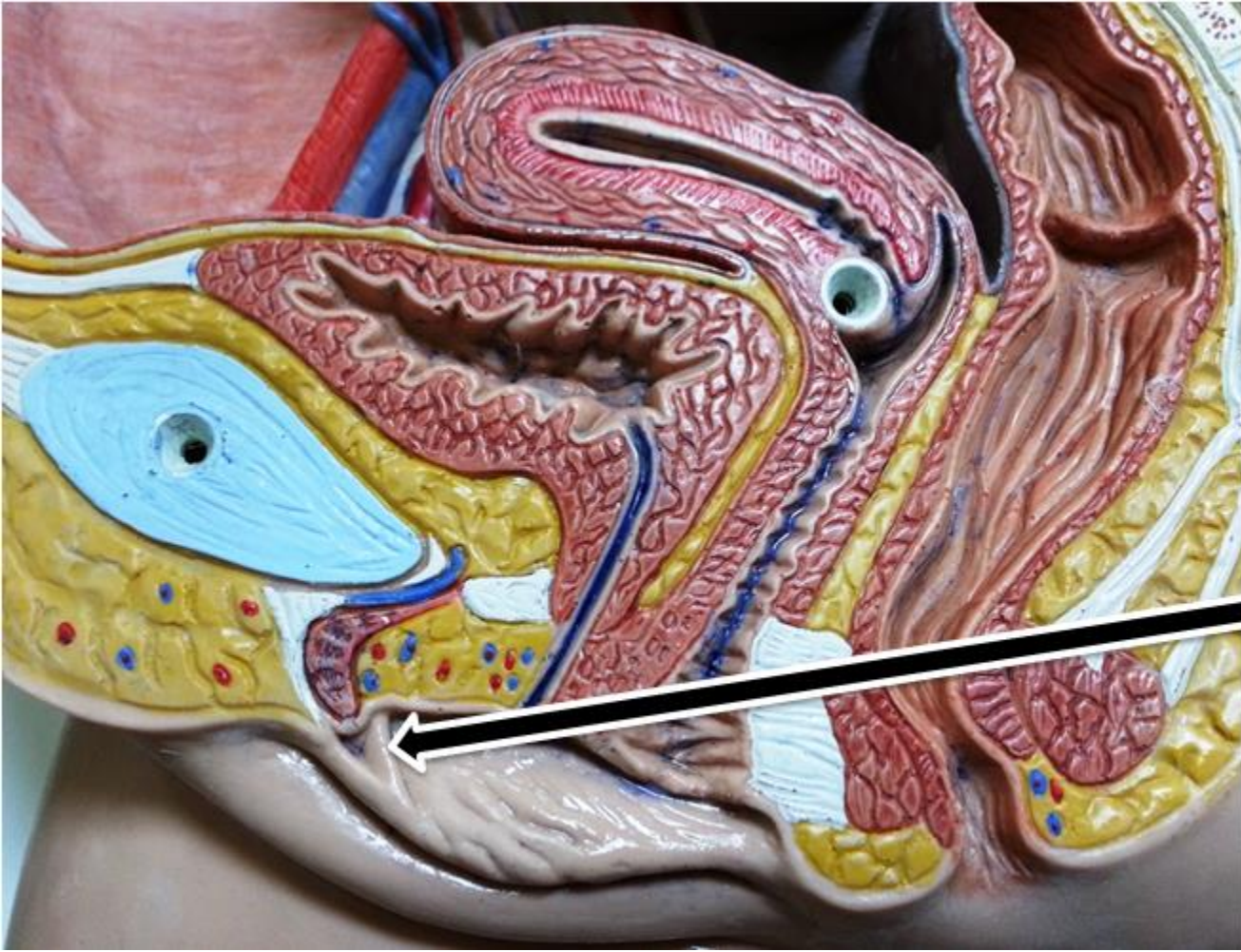


Clitoris

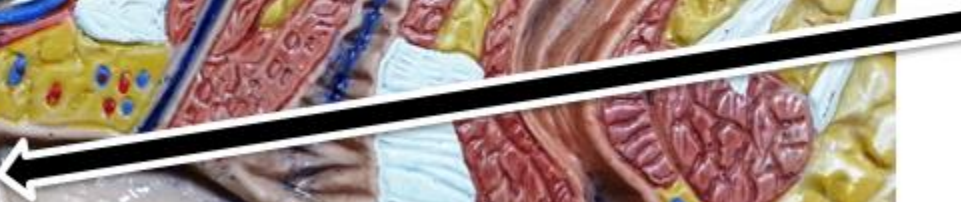

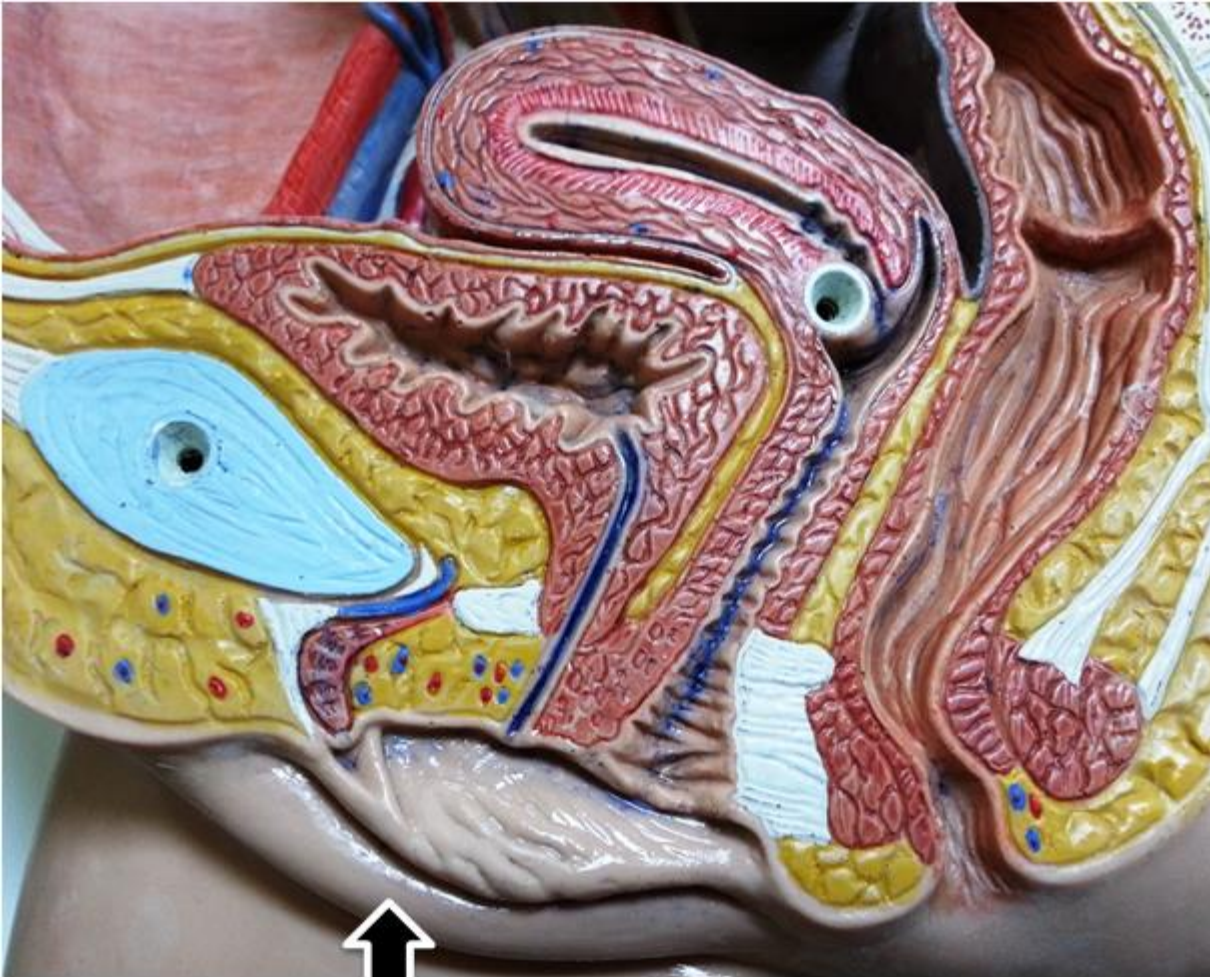Prepuce



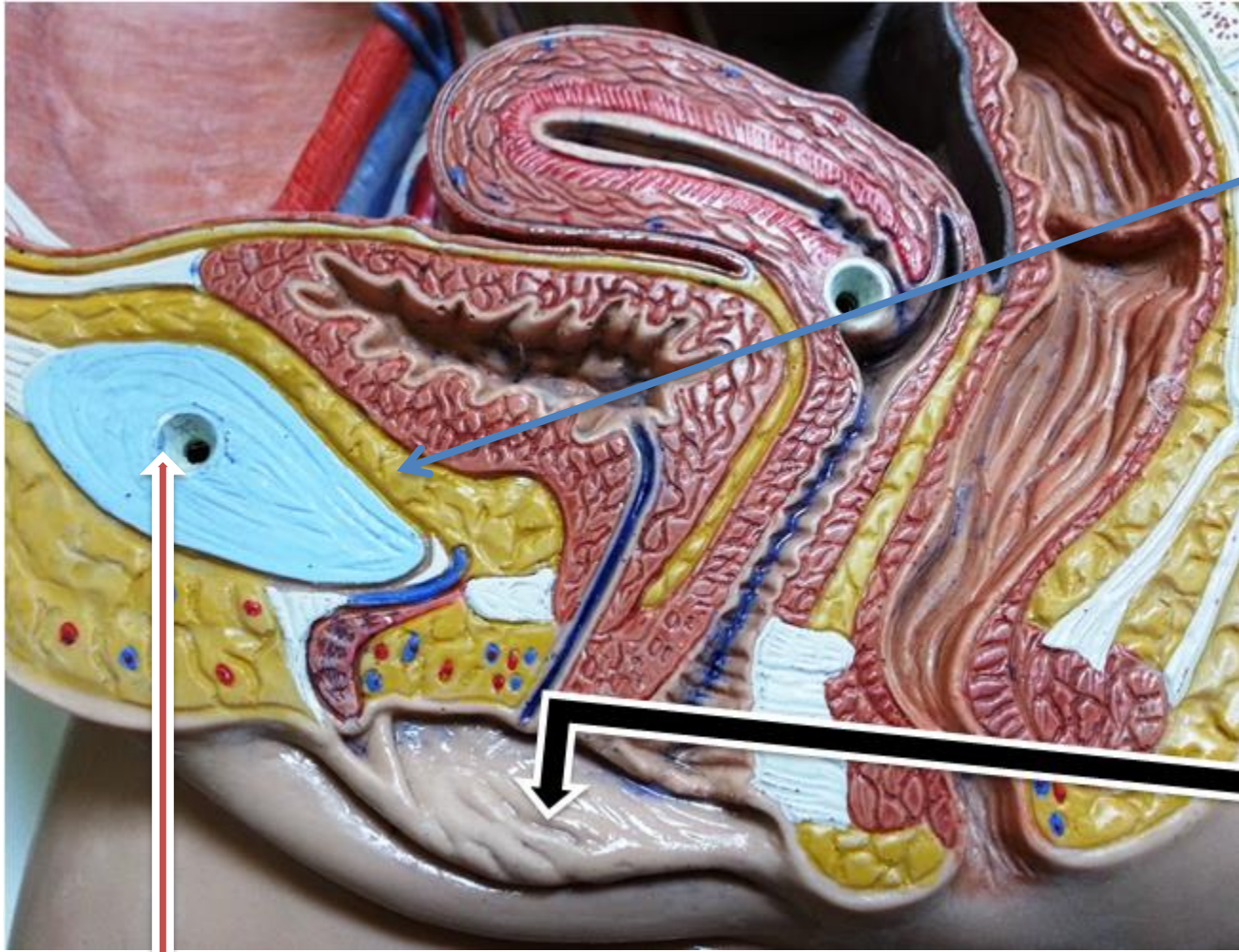


Frenulum





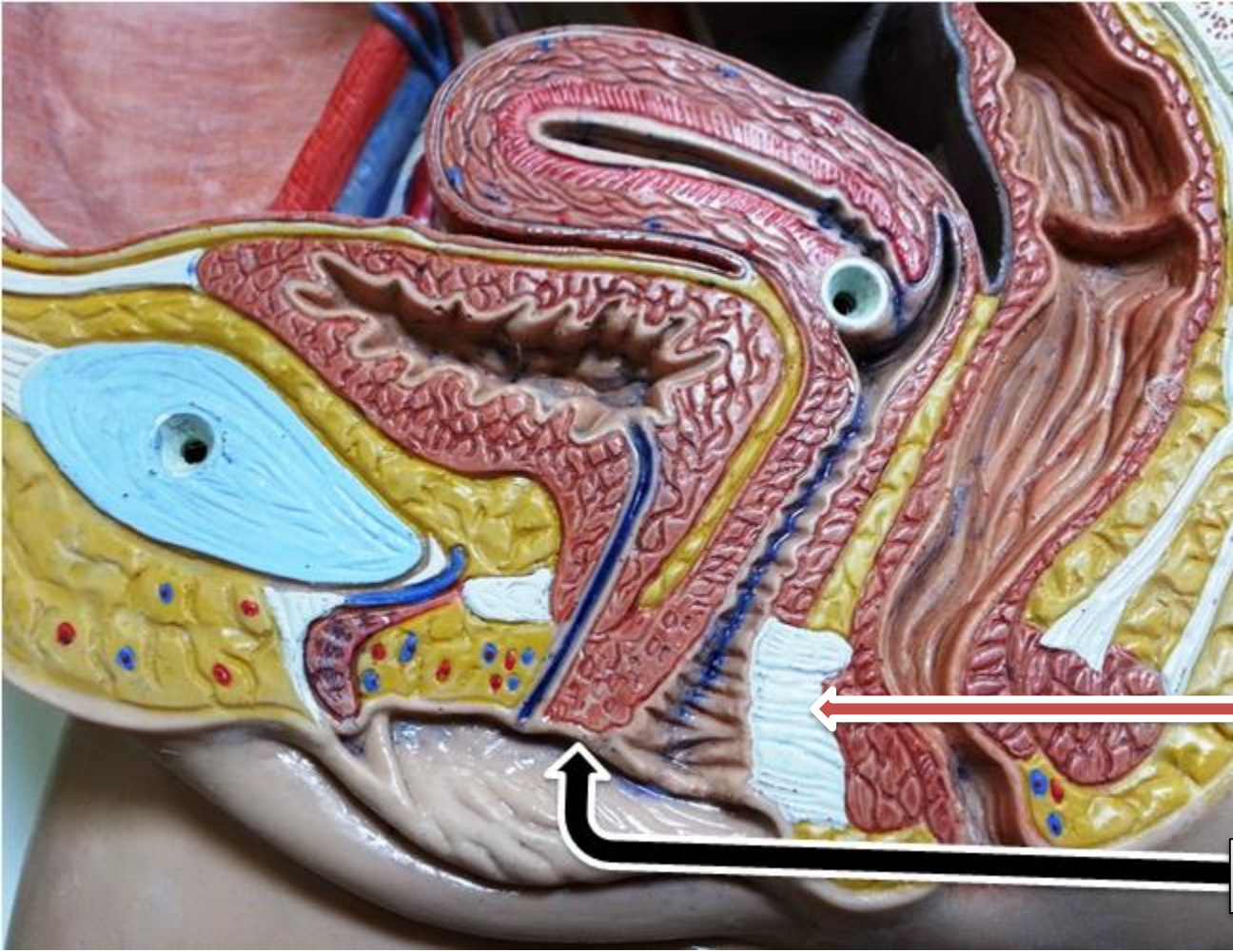
Labia majora



Retropubic pad of fat

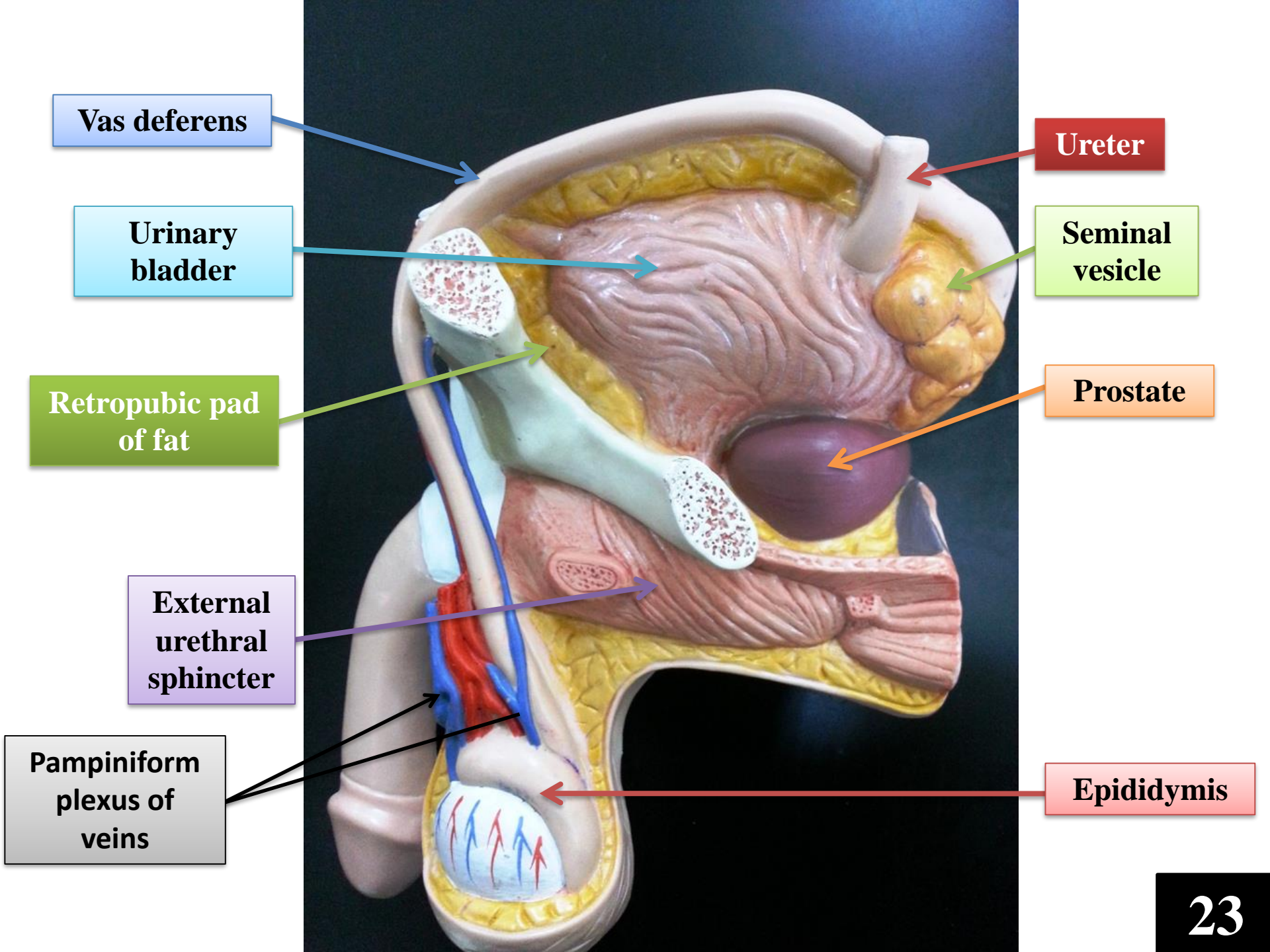
Labia minora

Pubic bone



Perineal body

vestibule



Vas deferens

Urinary bladder

Retropubic pad of fat

External urethral sphincter

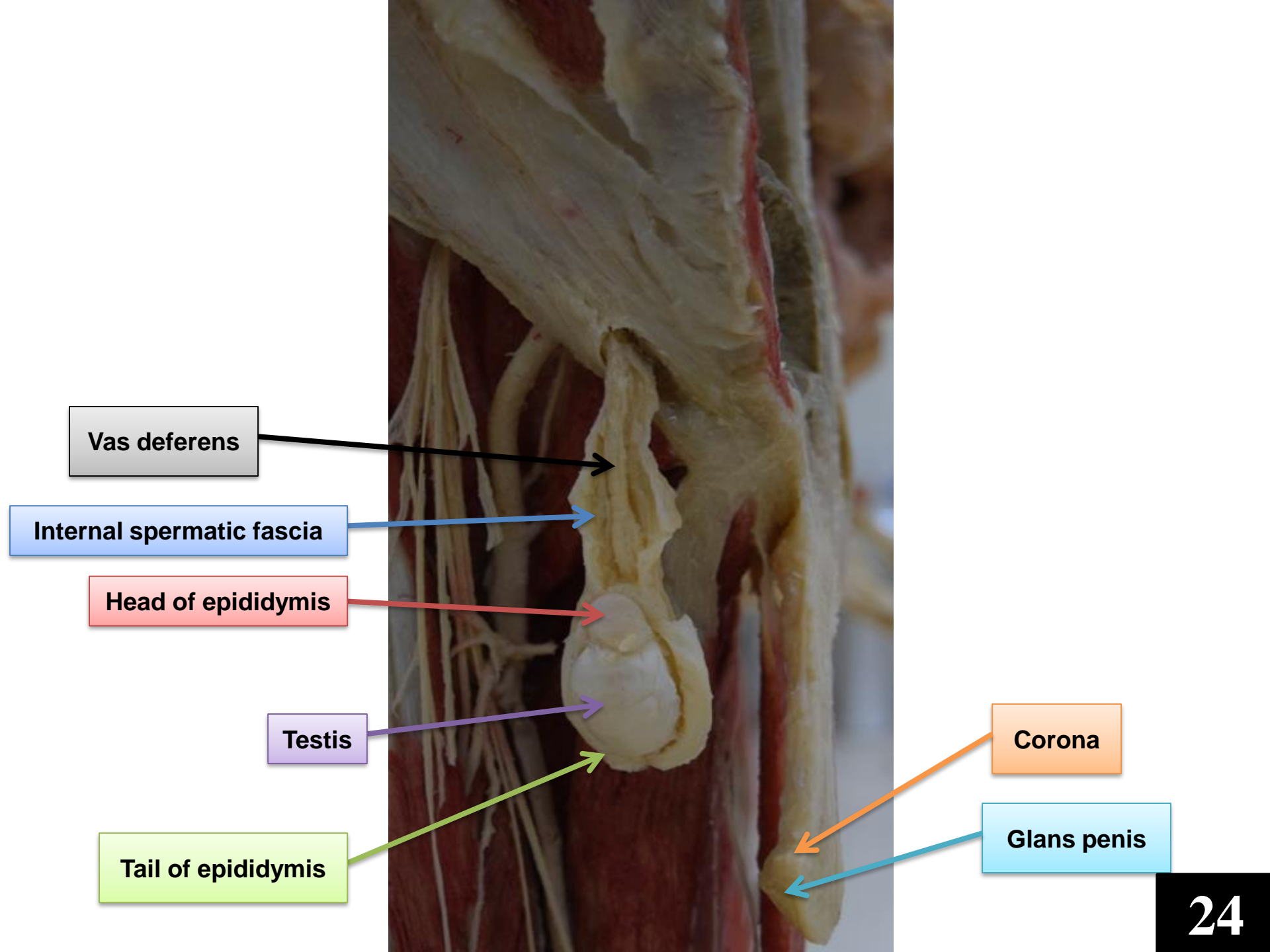
Pampiniform plexus of veins

Ureter

Seminal vesicle

Prostate

Epididymis



Vas deferens

Internal spermatic fascia

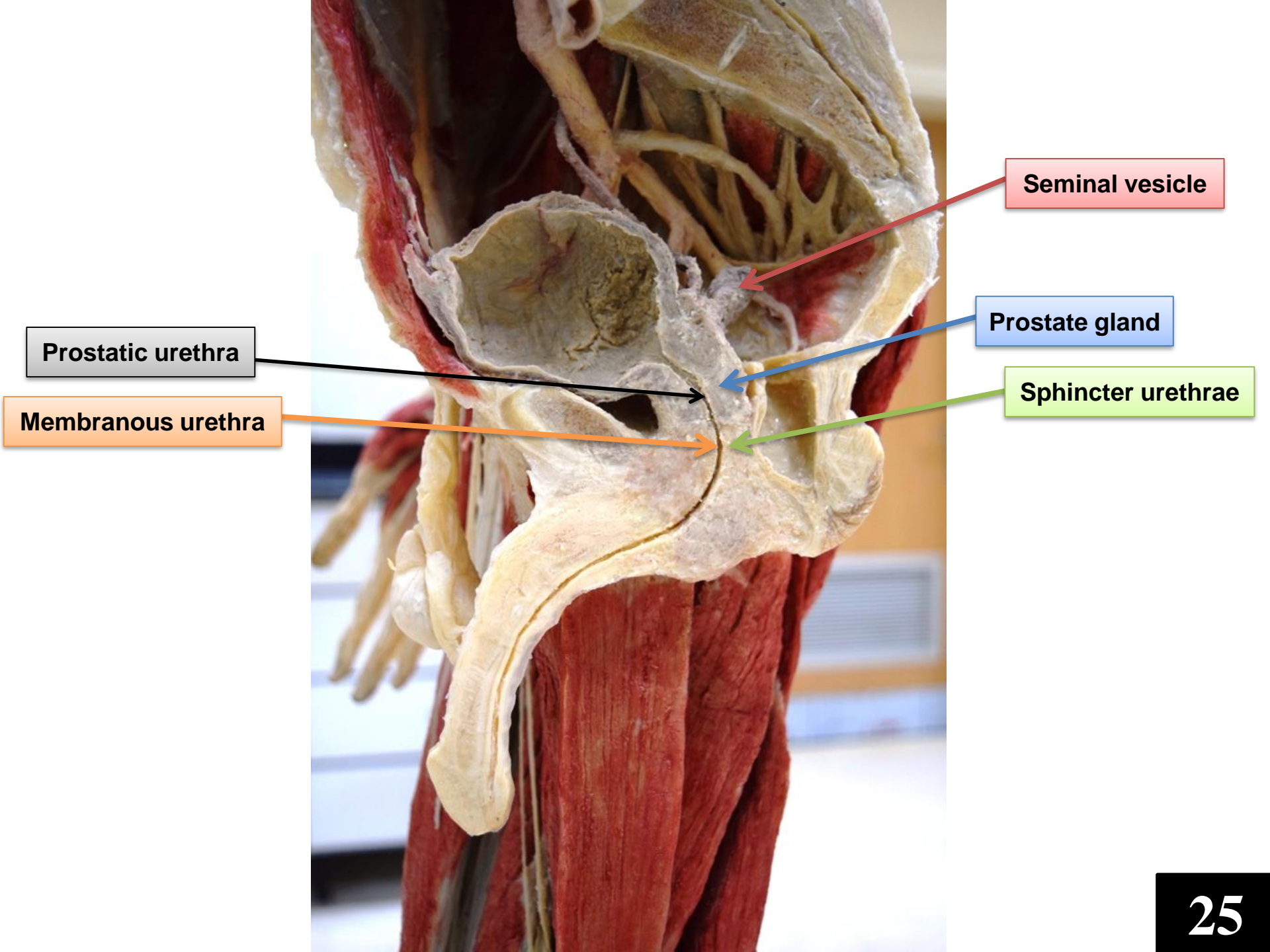
Head of epididymis

Testis

Tail of epididymis

Corona

Glans penis



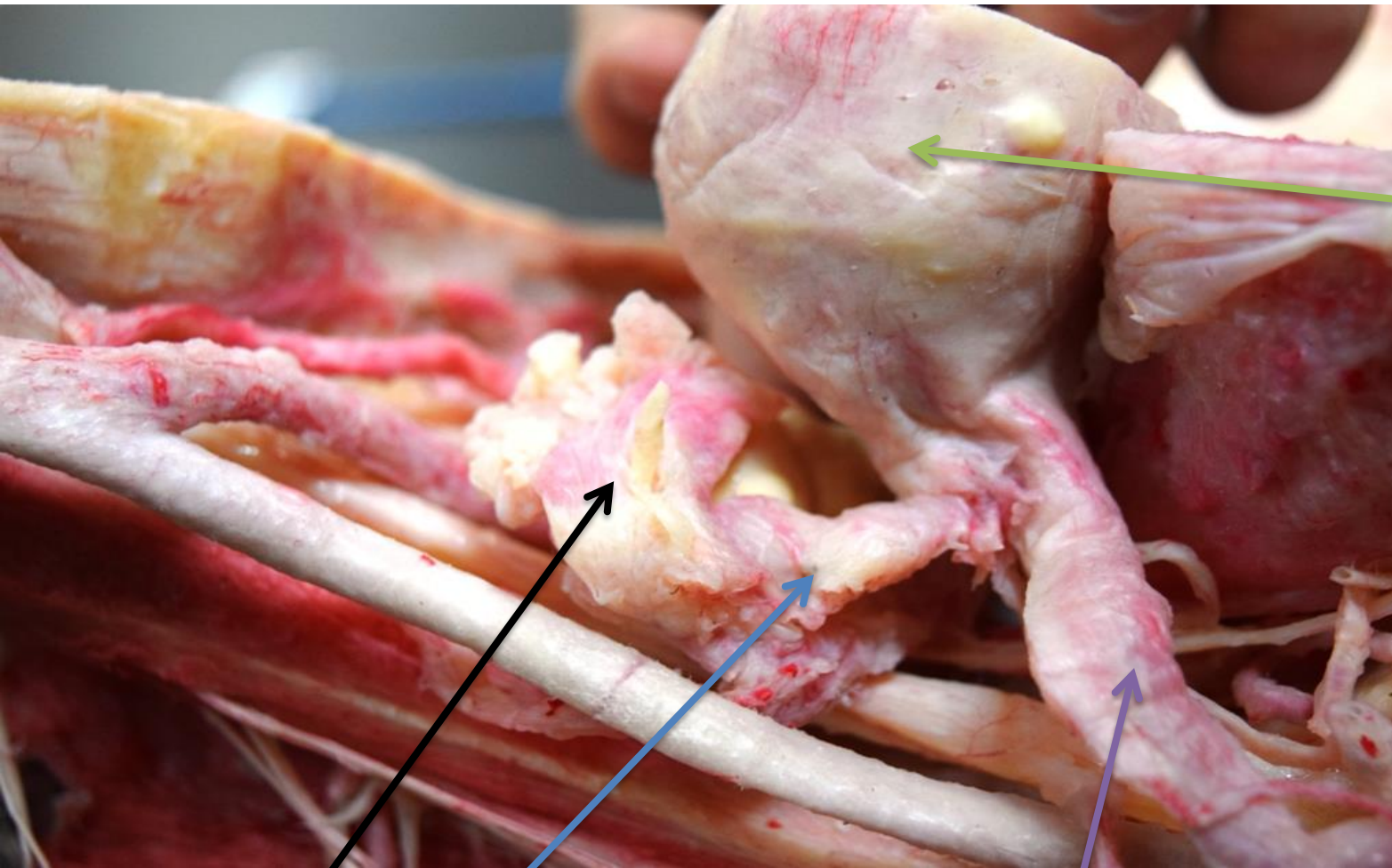
Seminal vesicle

Prostate gland

Sphincter urethrae

Prostatic urethra

Membranous urethra

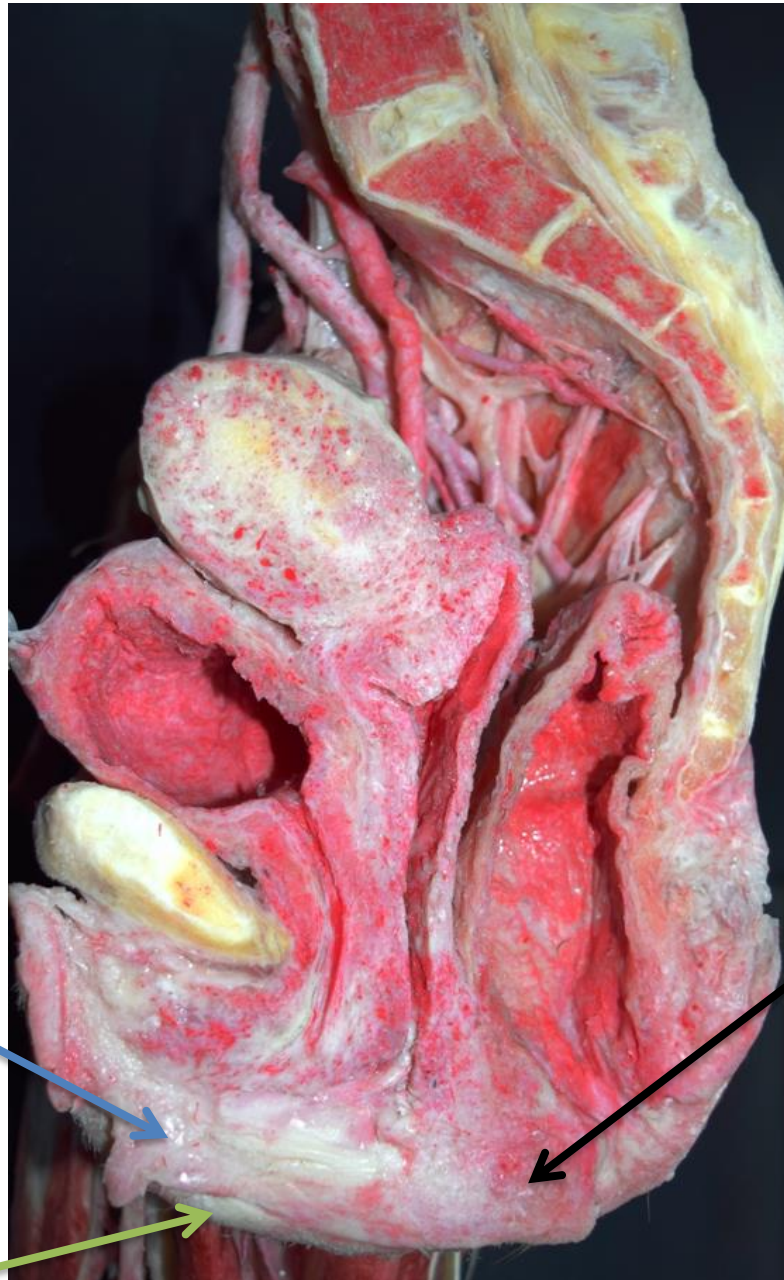

Fundus of uterus

Uterine tube

Infundibulum of uterine tube


Round ligament of uterus

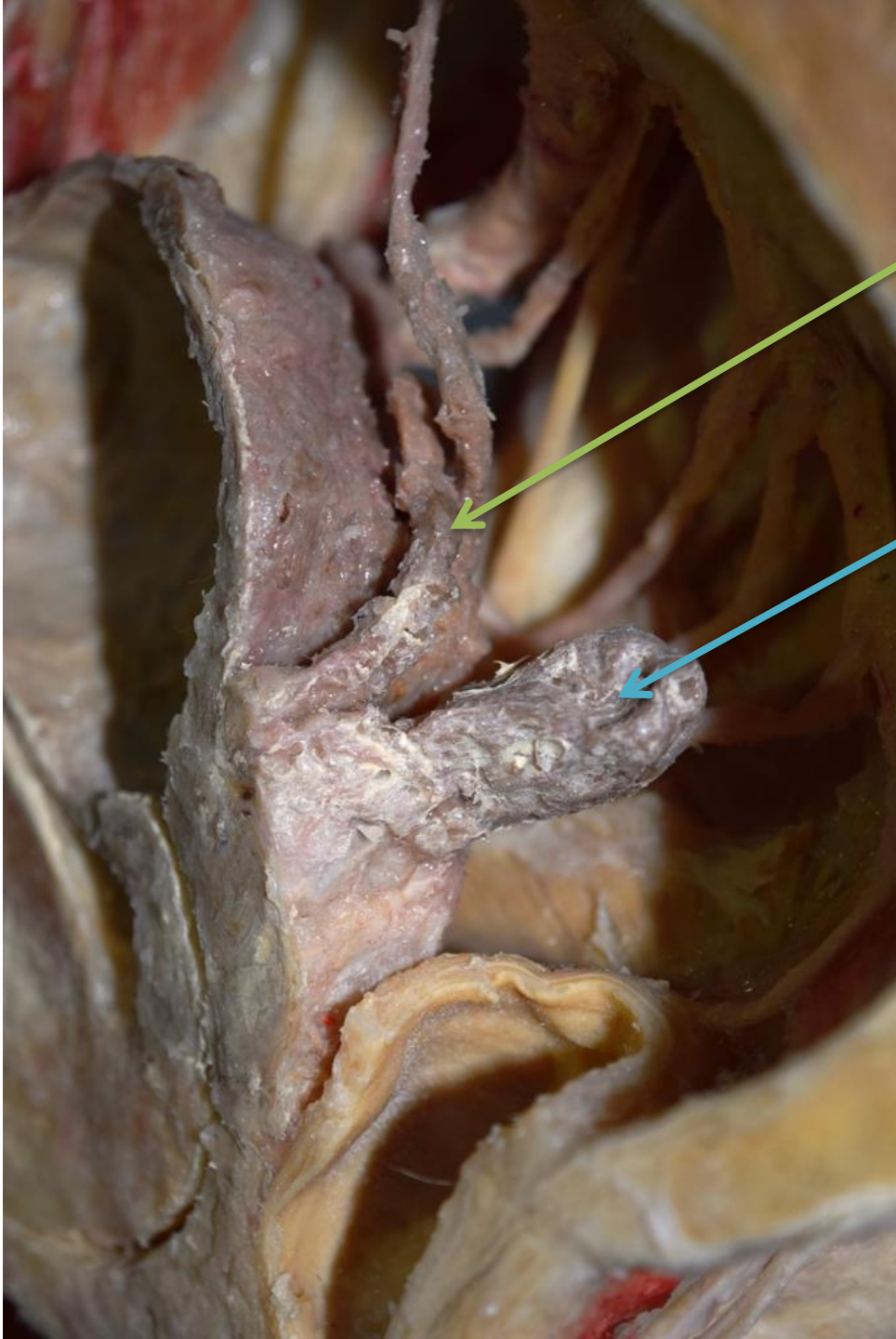


Labia minora

Labia majora


Peineal body

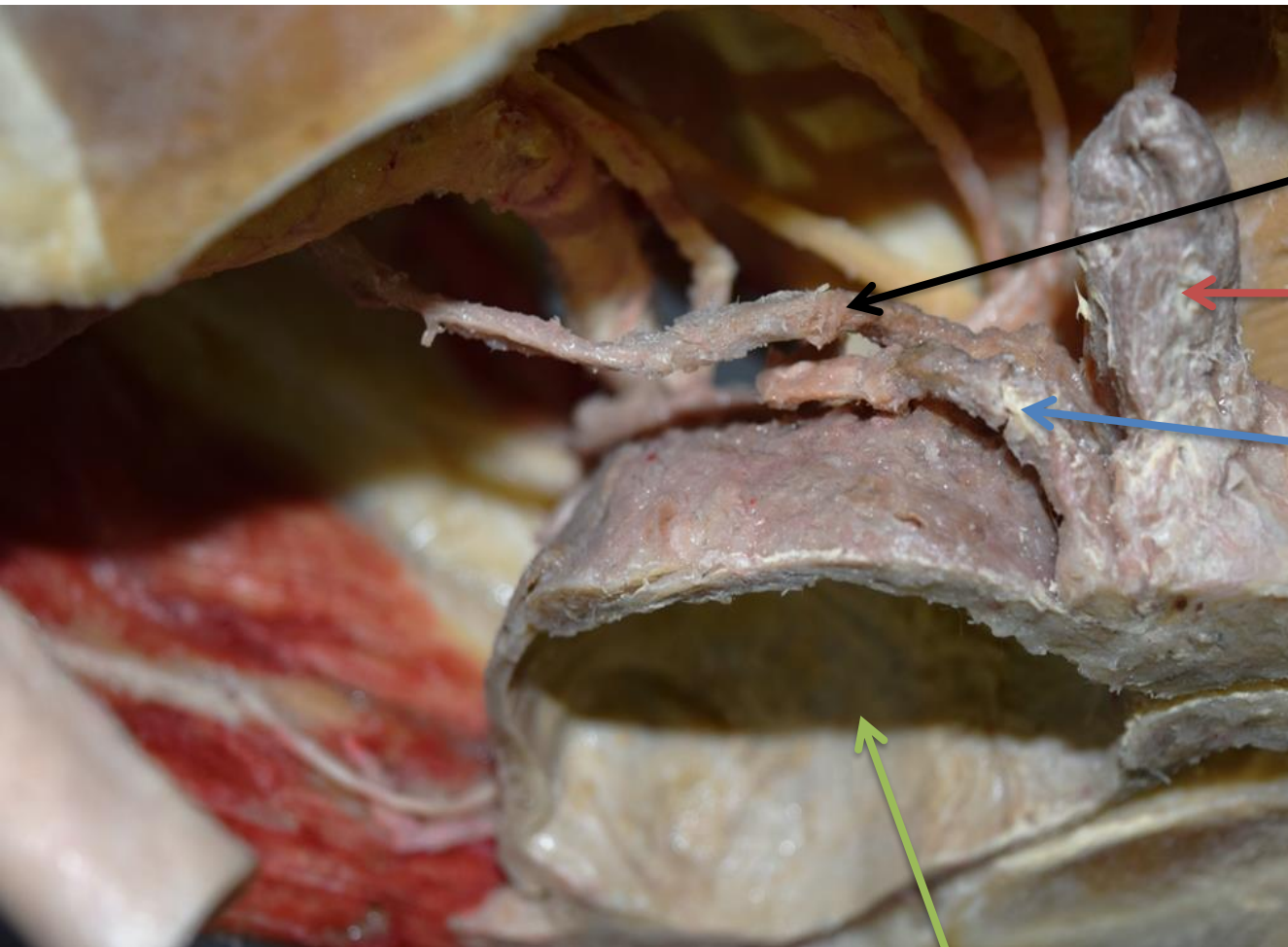




Vas
deferens

Seminal
vesicle





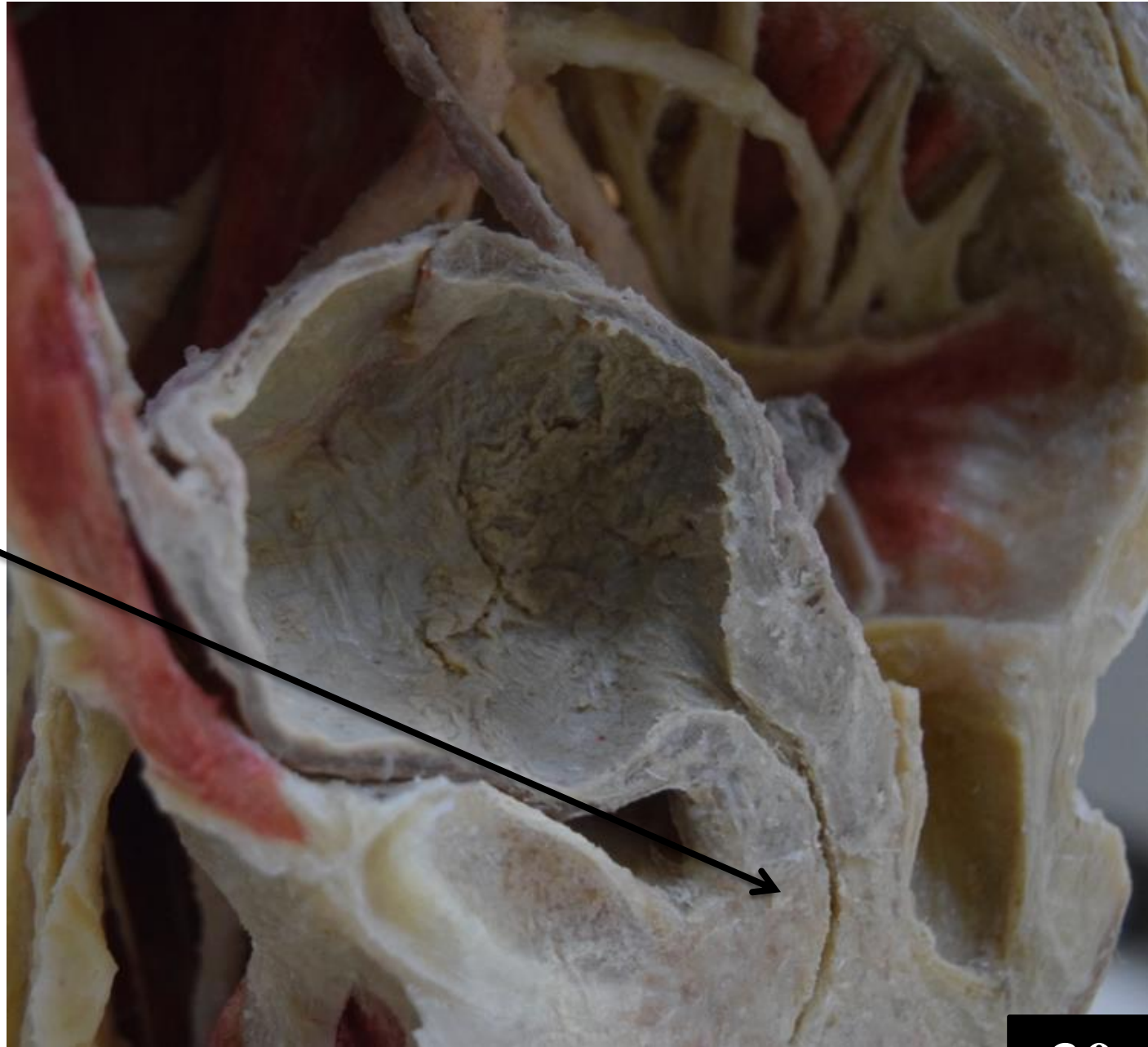
Ureter

Seminal vesicle

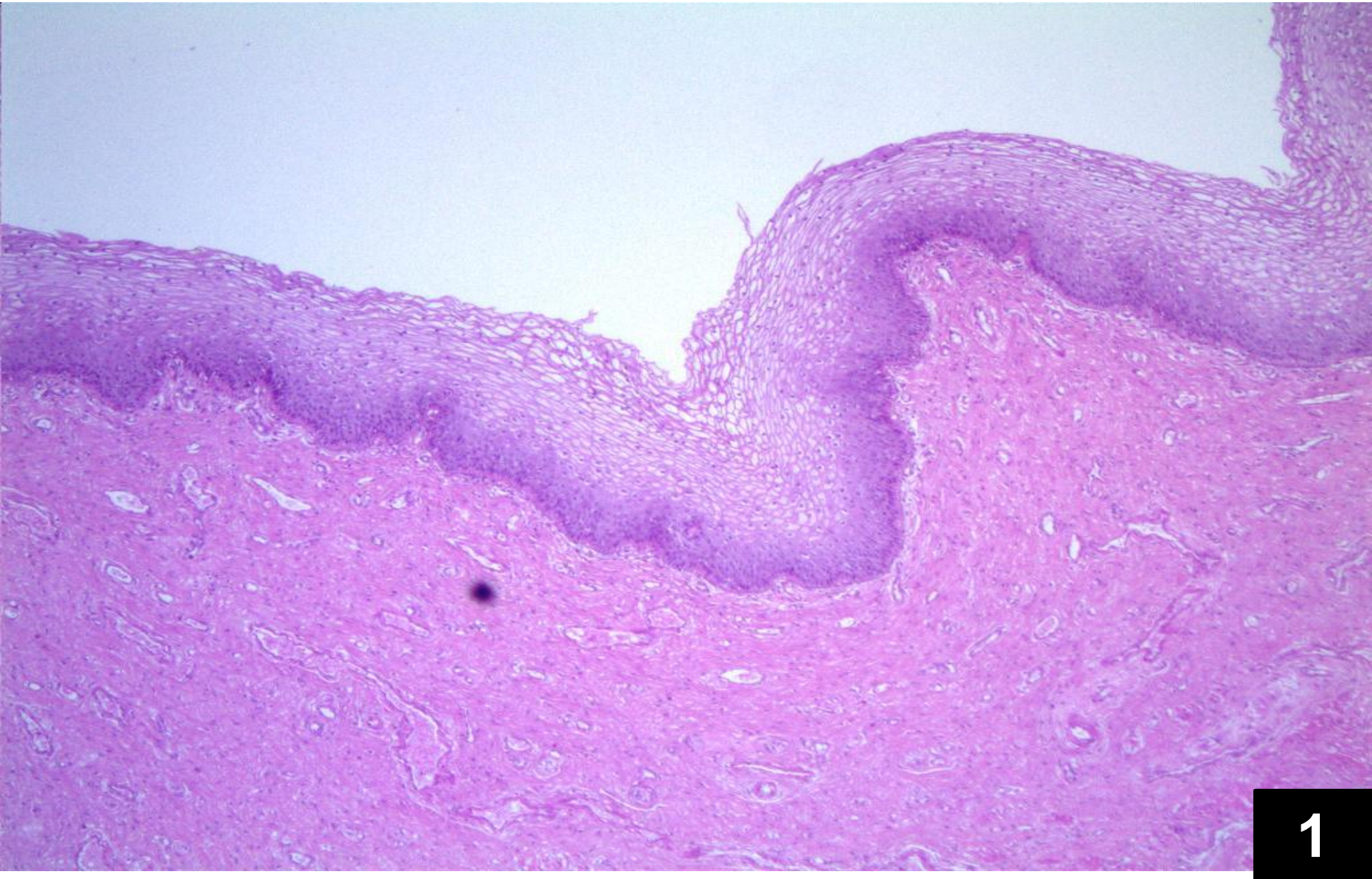
Vas deferens

Urinary bladder

**External urethral
sphincter (sphincter
urethrae)**

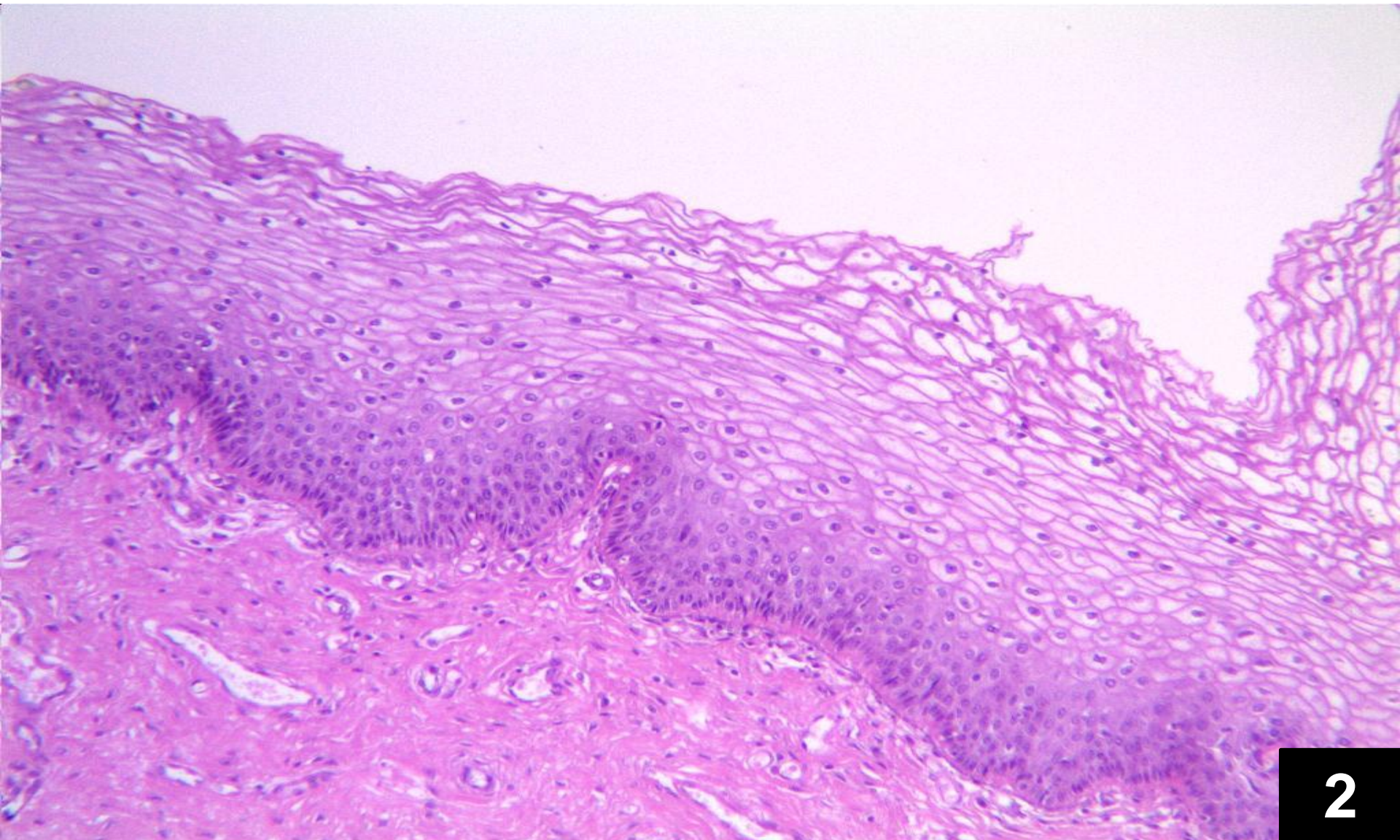


UGS Lab 3



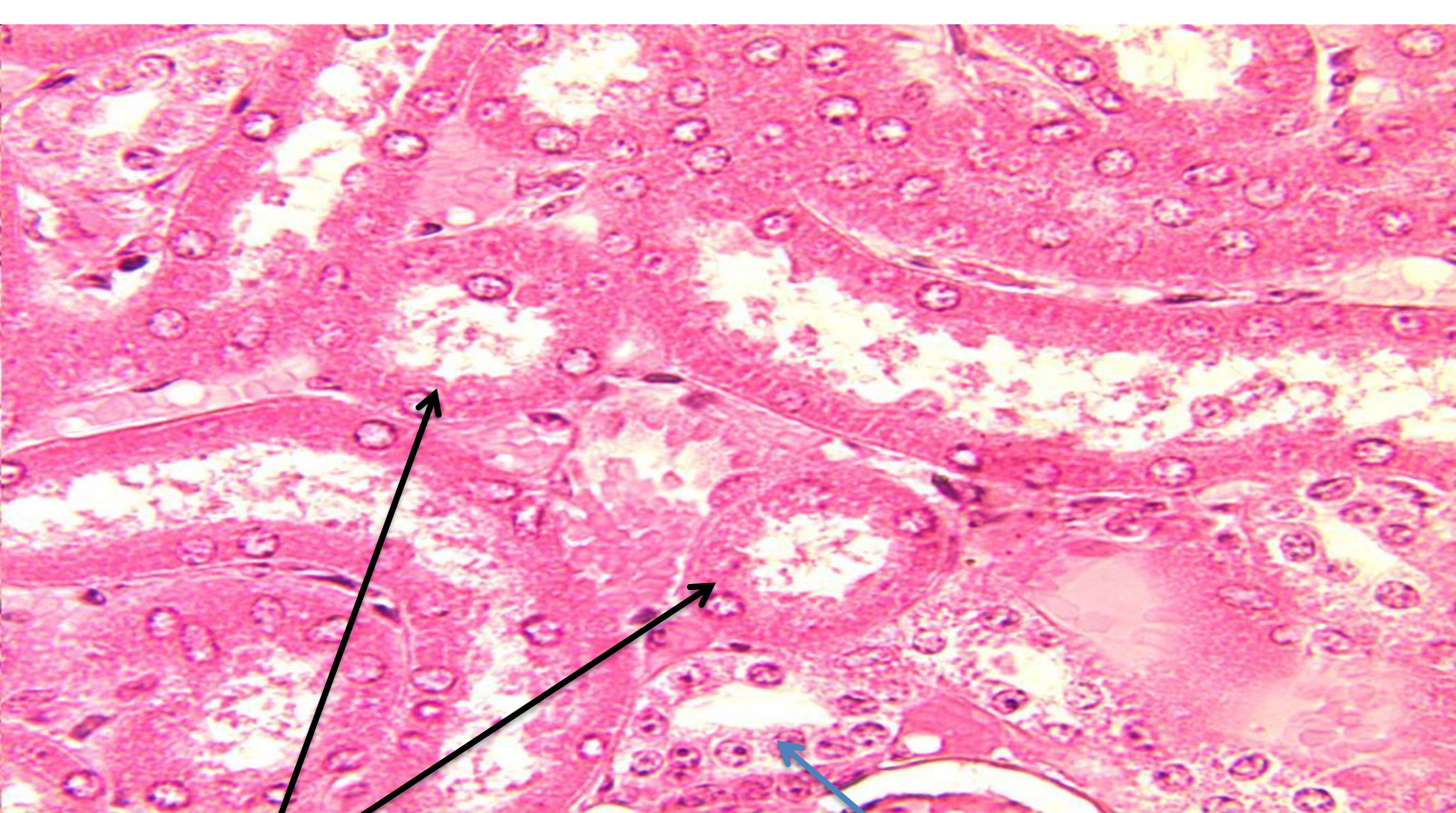
1

Section Through the Vagina (Medium Power)



2

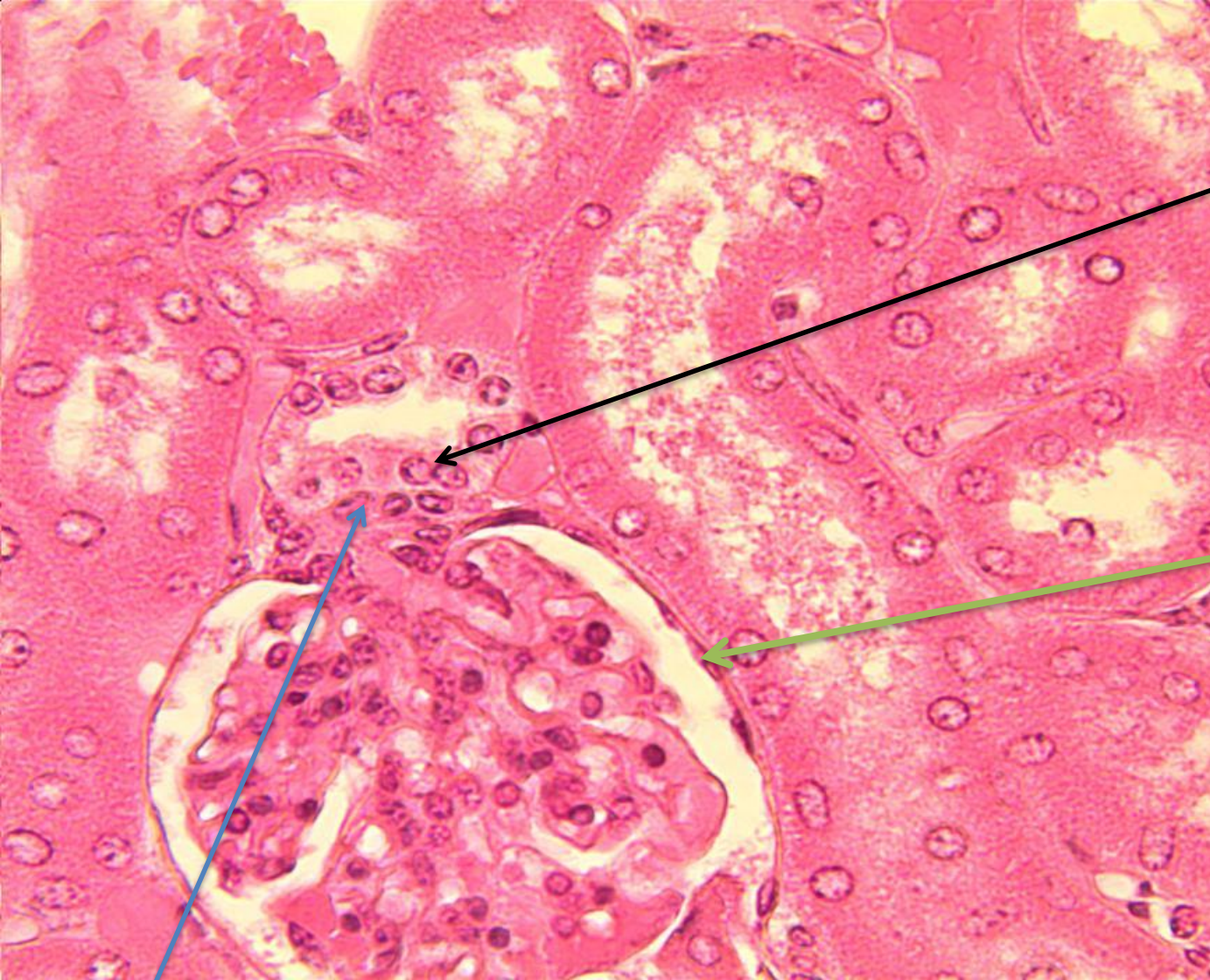
Section through vagina (high Power)



Proximal convoluted tubules

Distal convoluted tube

Section Through the Kidney

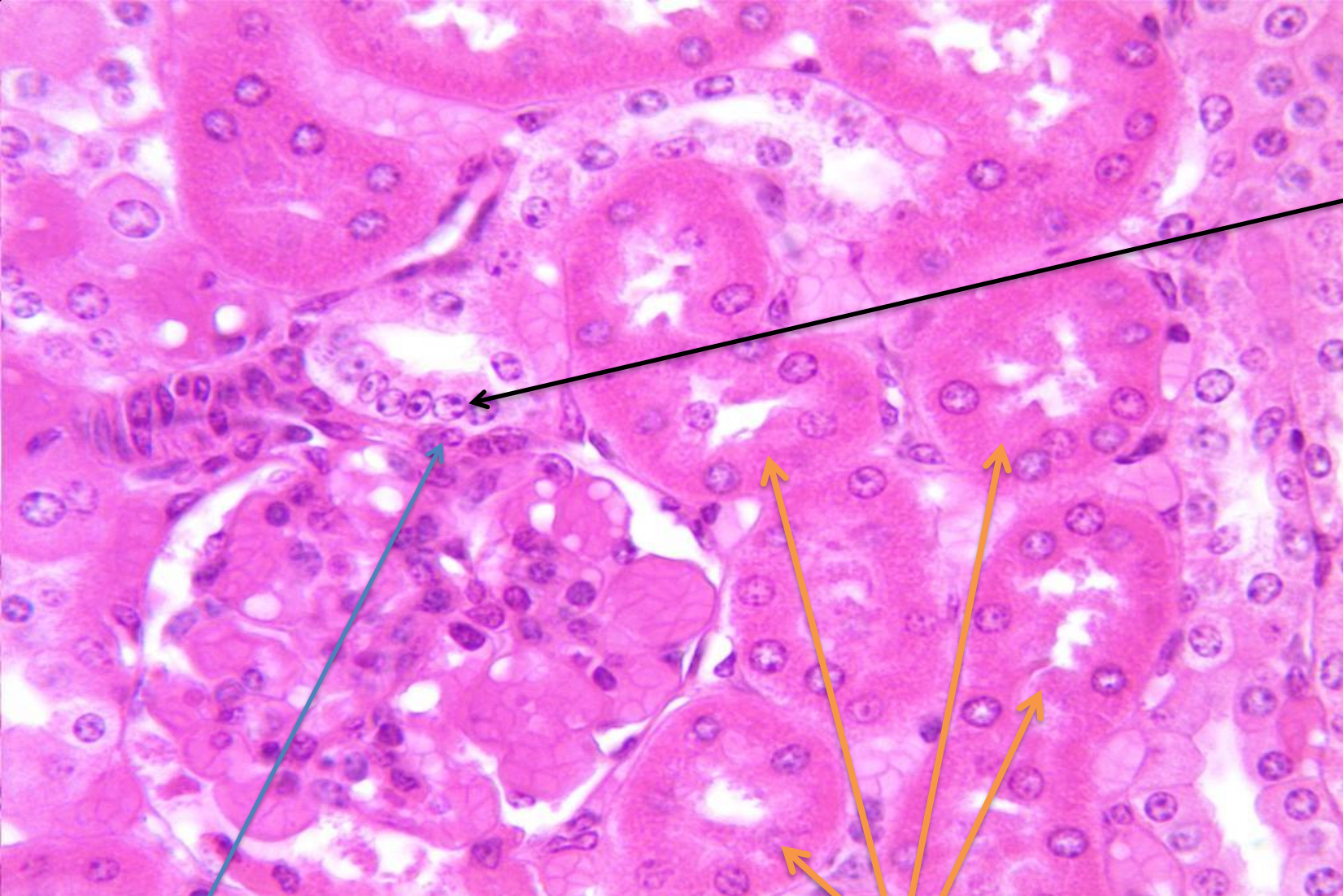


Macula densa

Parietal layer of glomerular capsule

Juxta glomerular cells

Section Through the Kidney

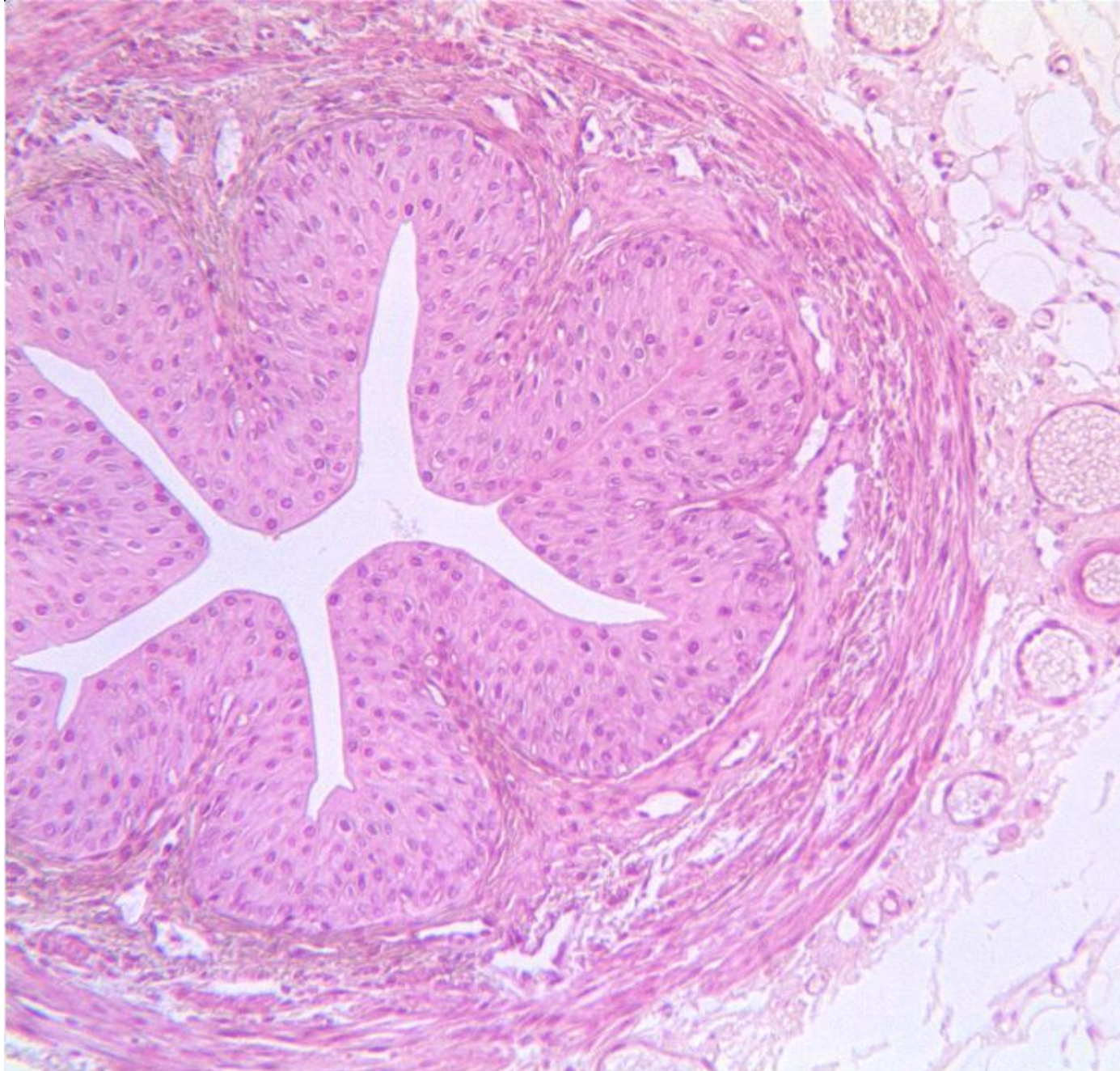

Macula densa

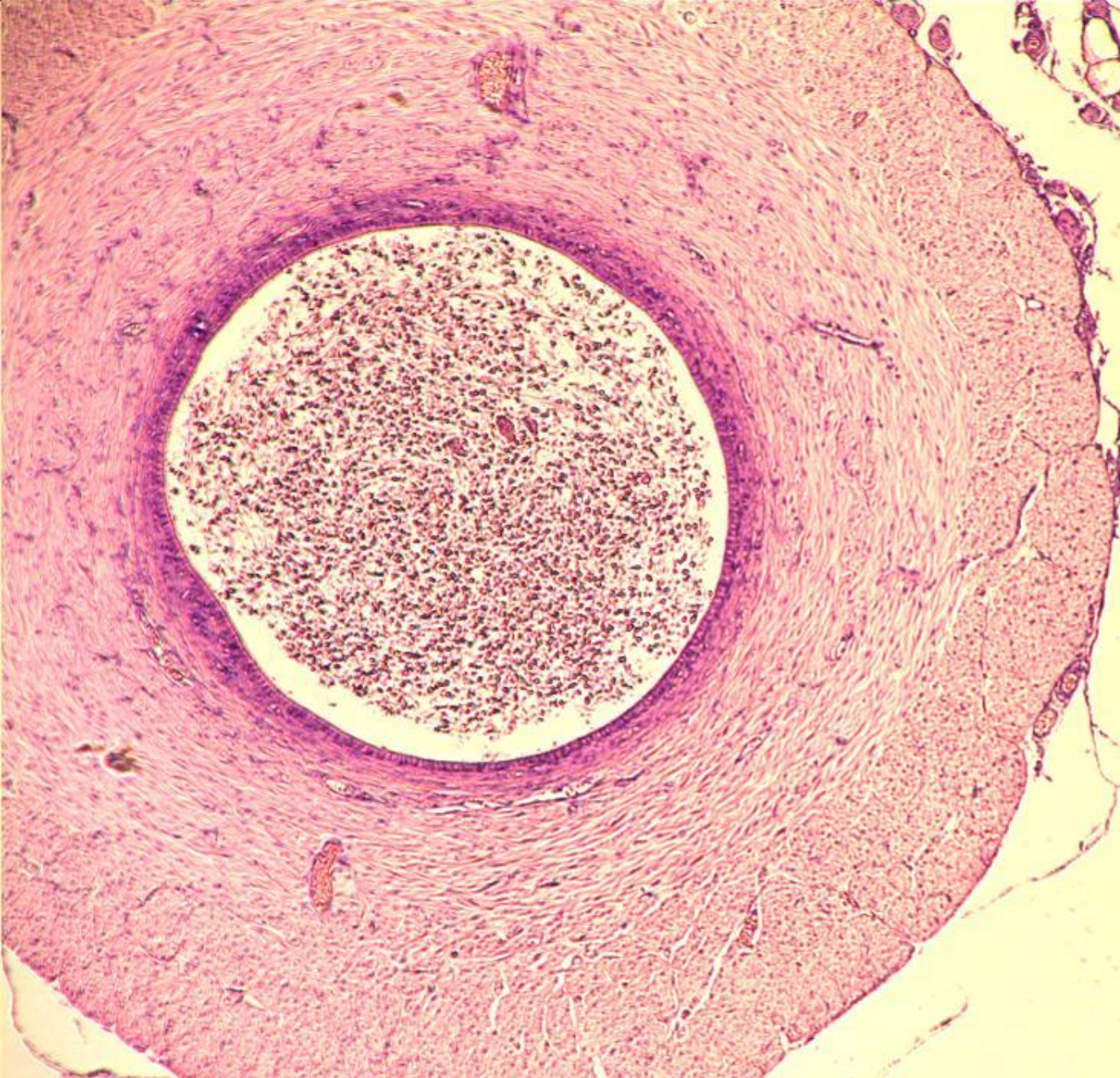
Juxta glomerular cells

Proximal convoluted tubules

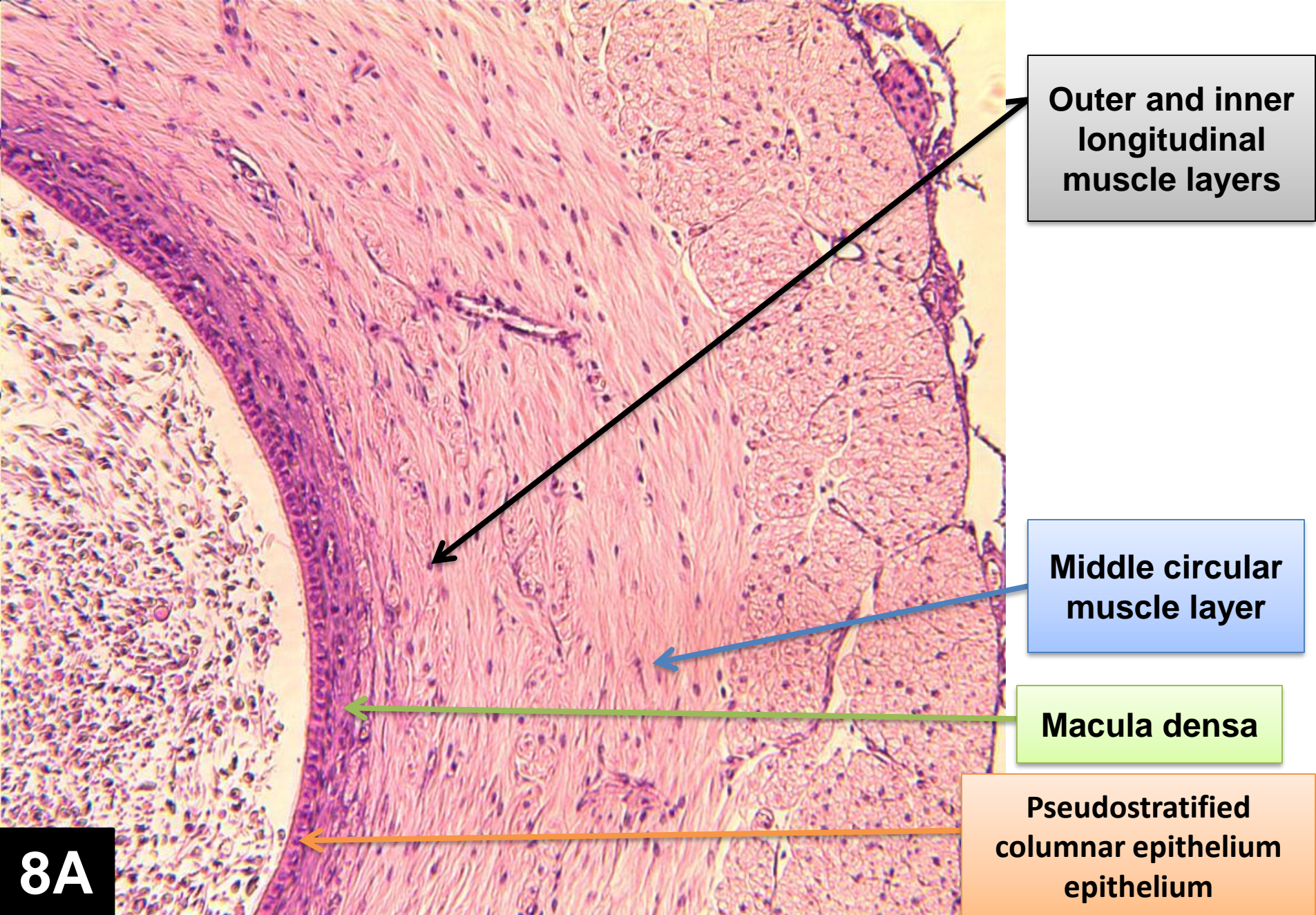
Section Through the Kidney



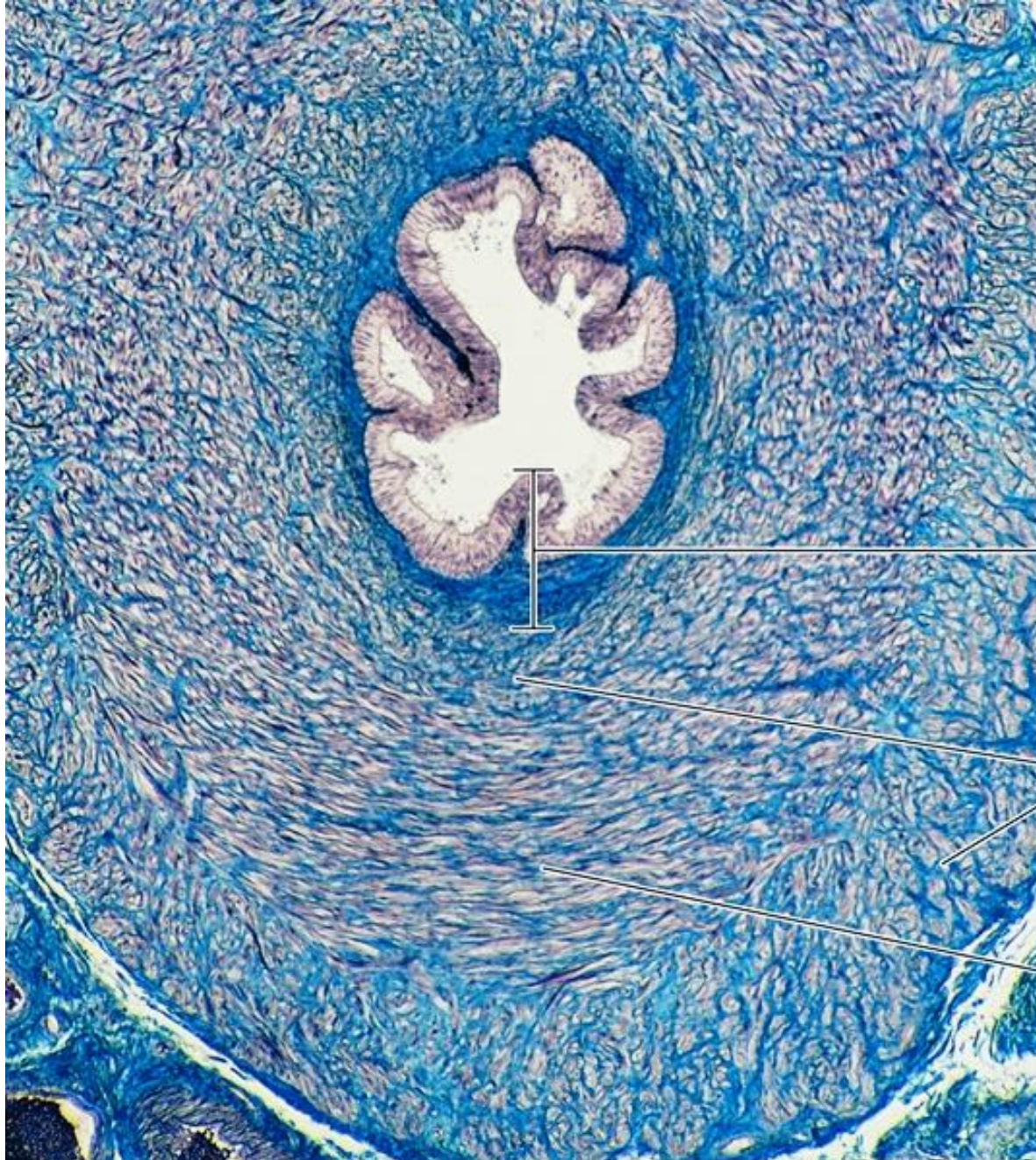
Section Through the Ureter



Section Through the Vas deferens (Low power)



Section Through the Vas deferens (High power)



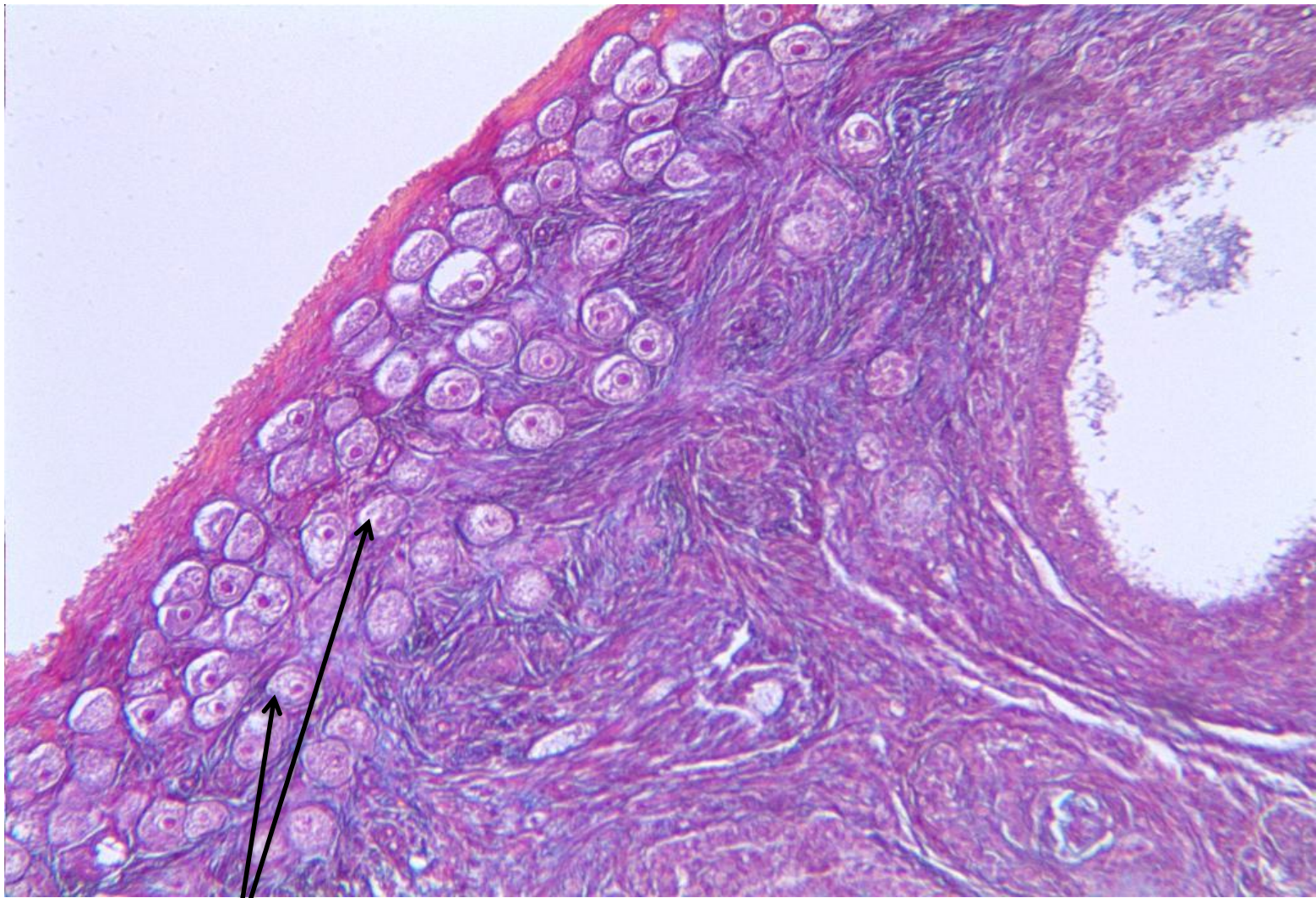
Mucosa

Longitudinal
smooth muscle
layer

Circular
smooth muscle
layer

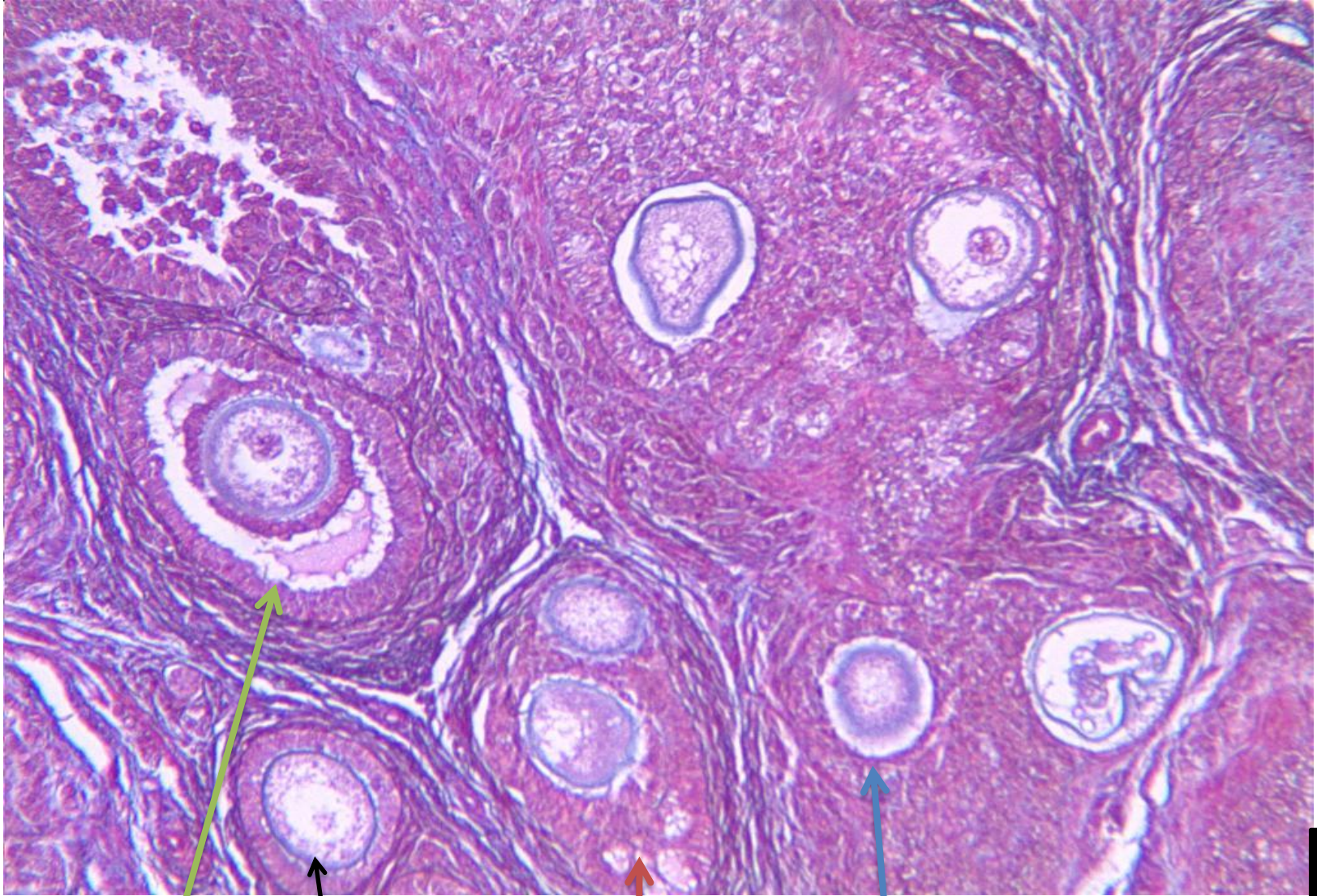
8B

Section Through the Vas deferens (High power)



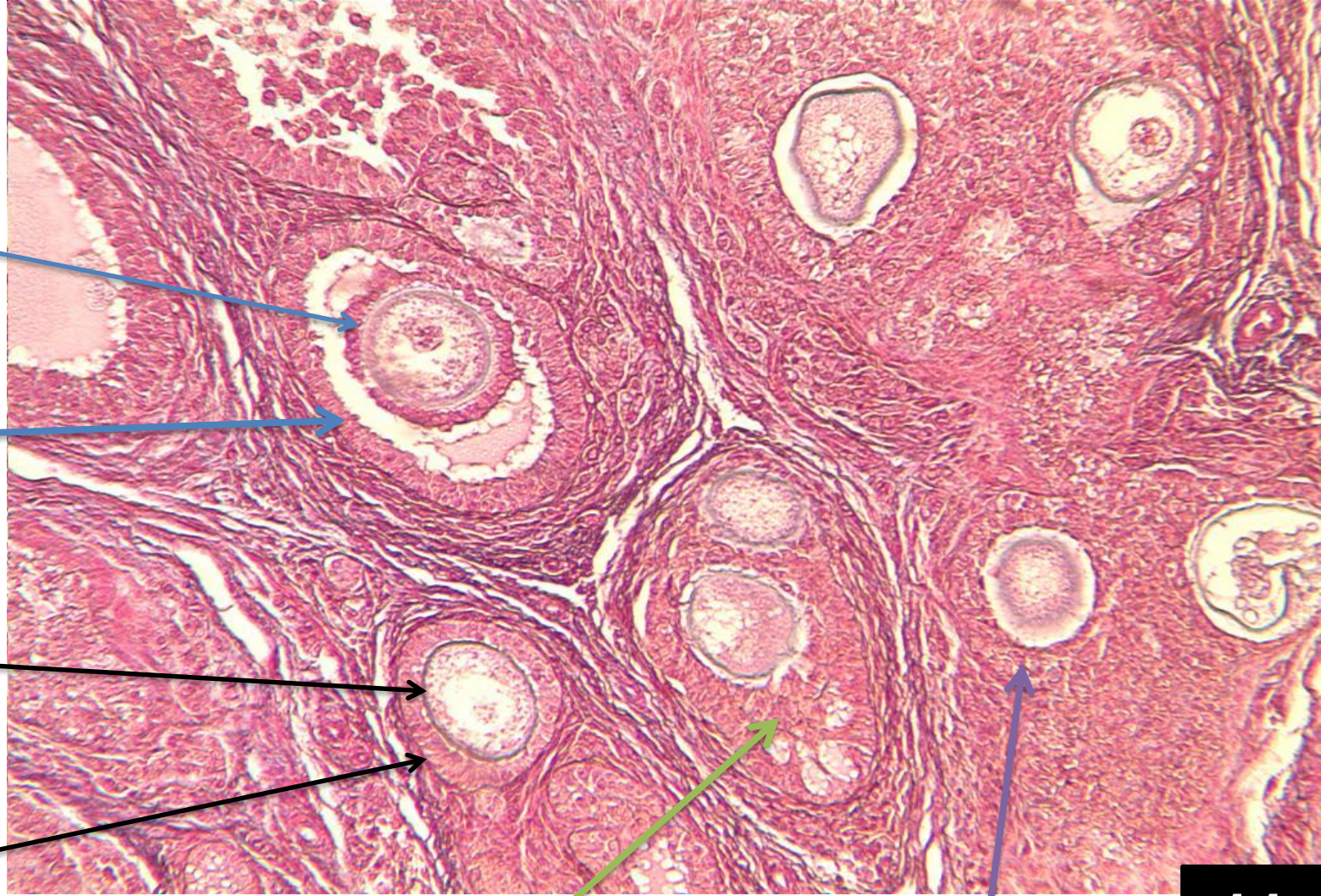Primordial follicles

Section Through Ovary

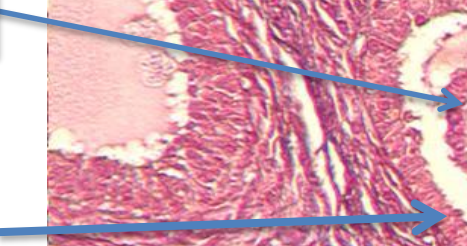


10

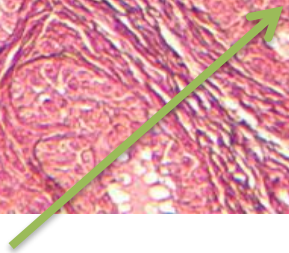
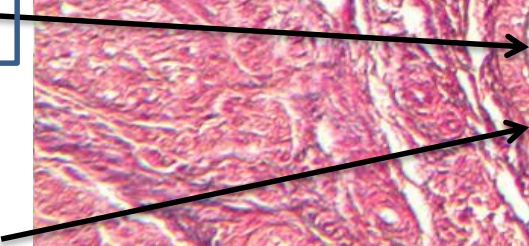
Mature follicle (Green arrow); Unilaminar primary follicle (black arrow); Multilaminar primary follicle (Blue arrow); and Antral follicle (pink arrow)



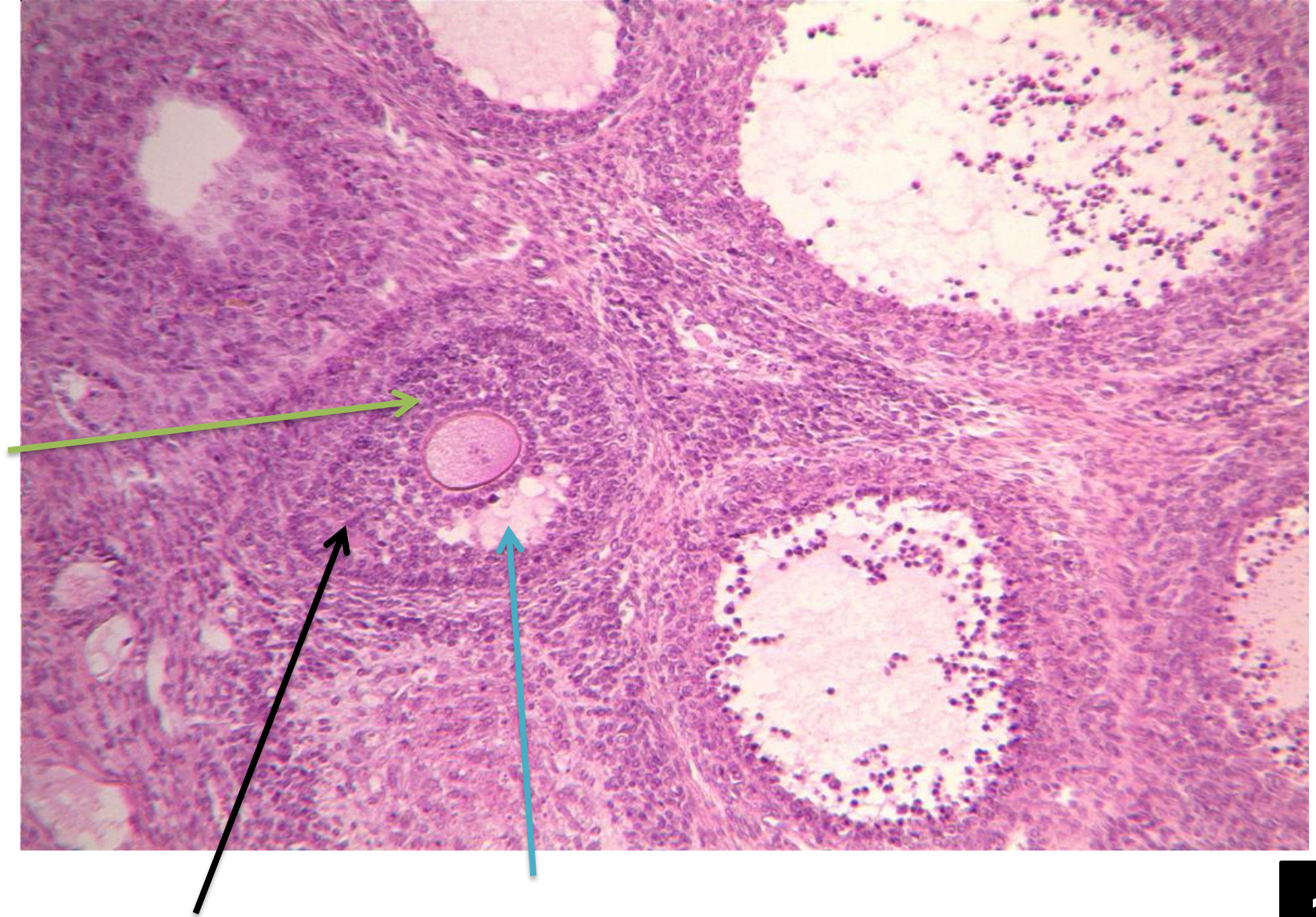
Corona radiata



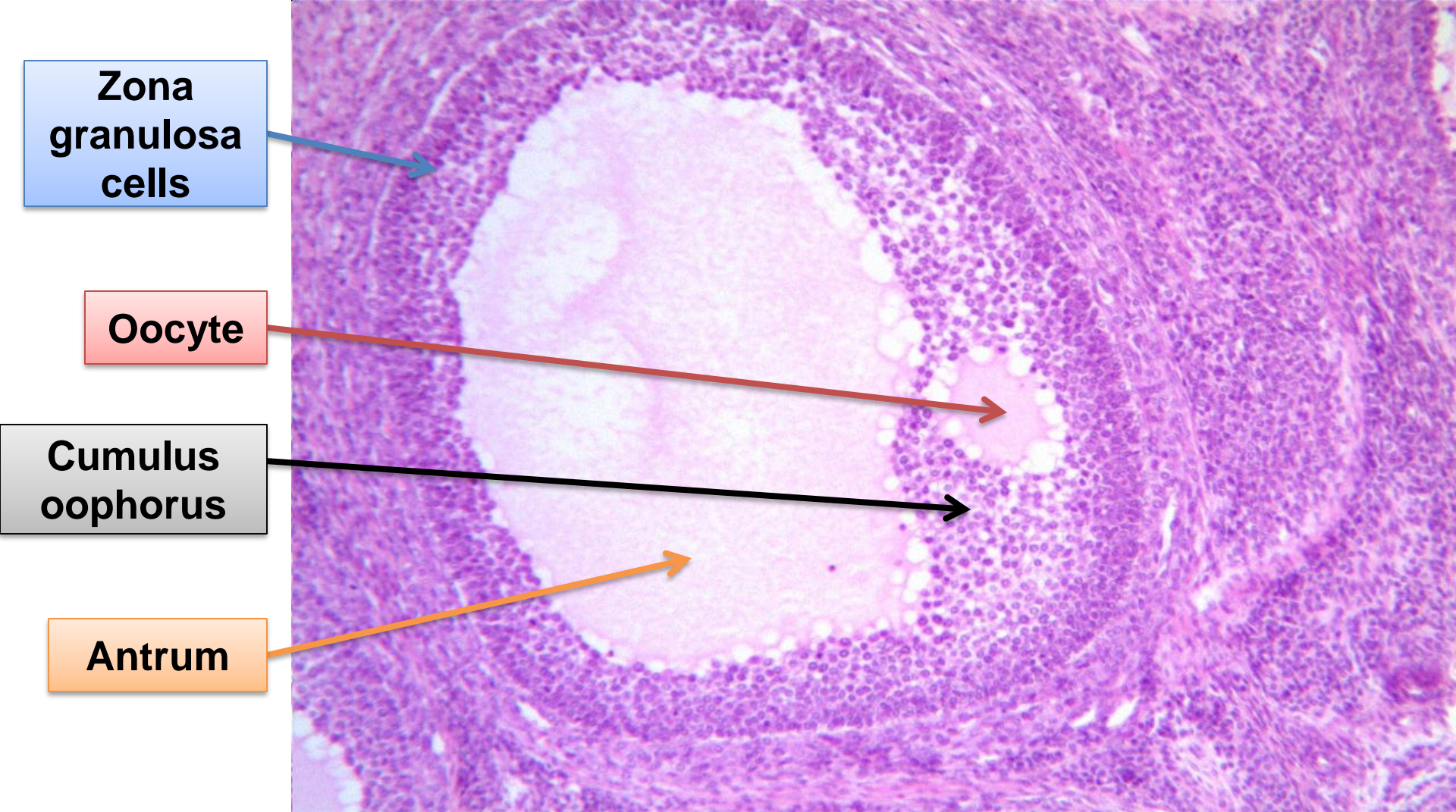
Zona pellucida



Mature follicle (blue arrow); Unilaminar primary follicle (black arrow); Multilaminar primary follicle (purple arrow); and Secondary or Antral follicle (green arrow)



Gumulus oophorus (Green arrow); Antrum (Blue arrow); and Antral or secondary follicle (Black arrow).

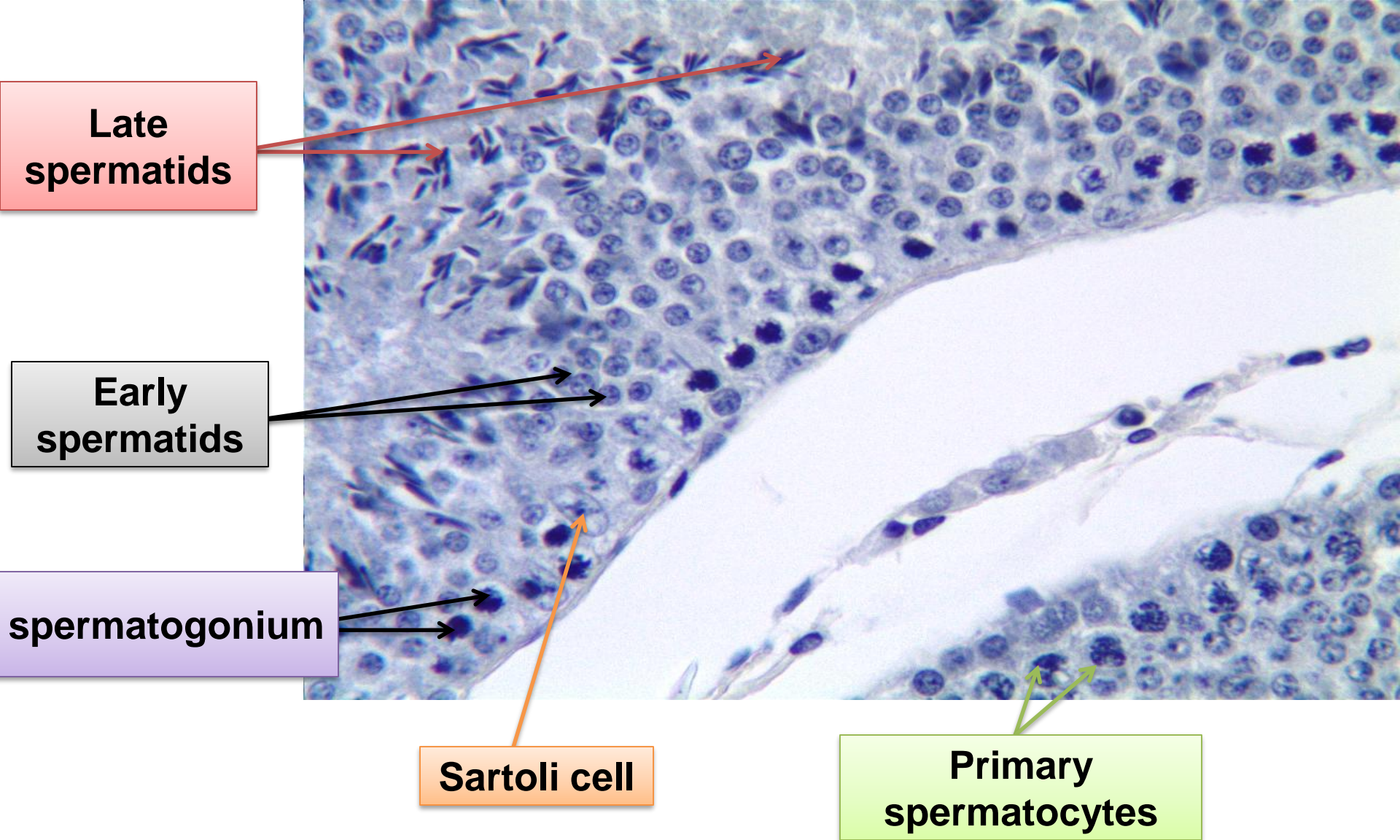


Zona granulosa cells

Oocyte

Cumulus oophorus

Antrum



Late spermatids

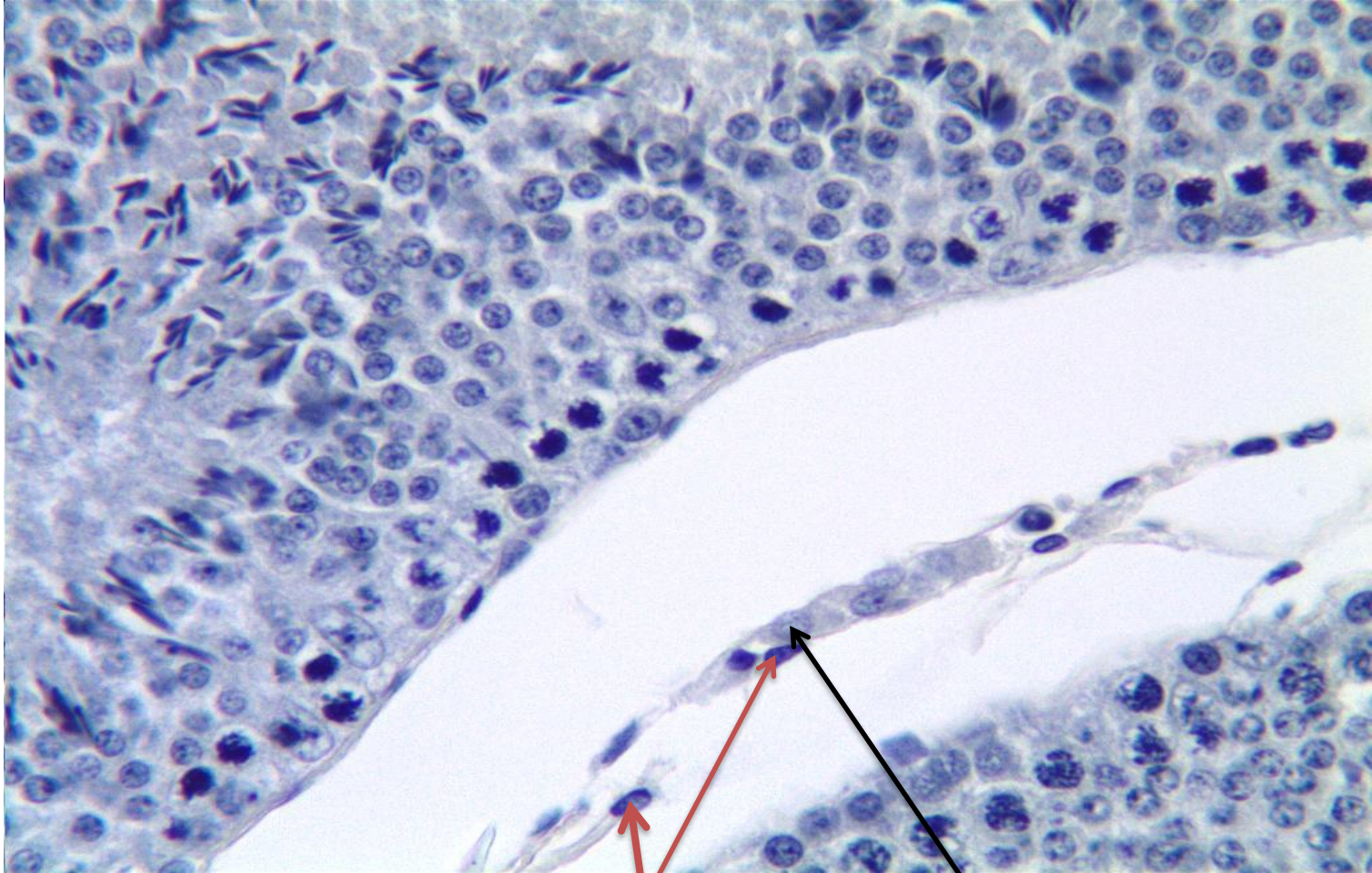
Early spermatids

spermatogonium

Sertoli cell

Primary spermatocytes

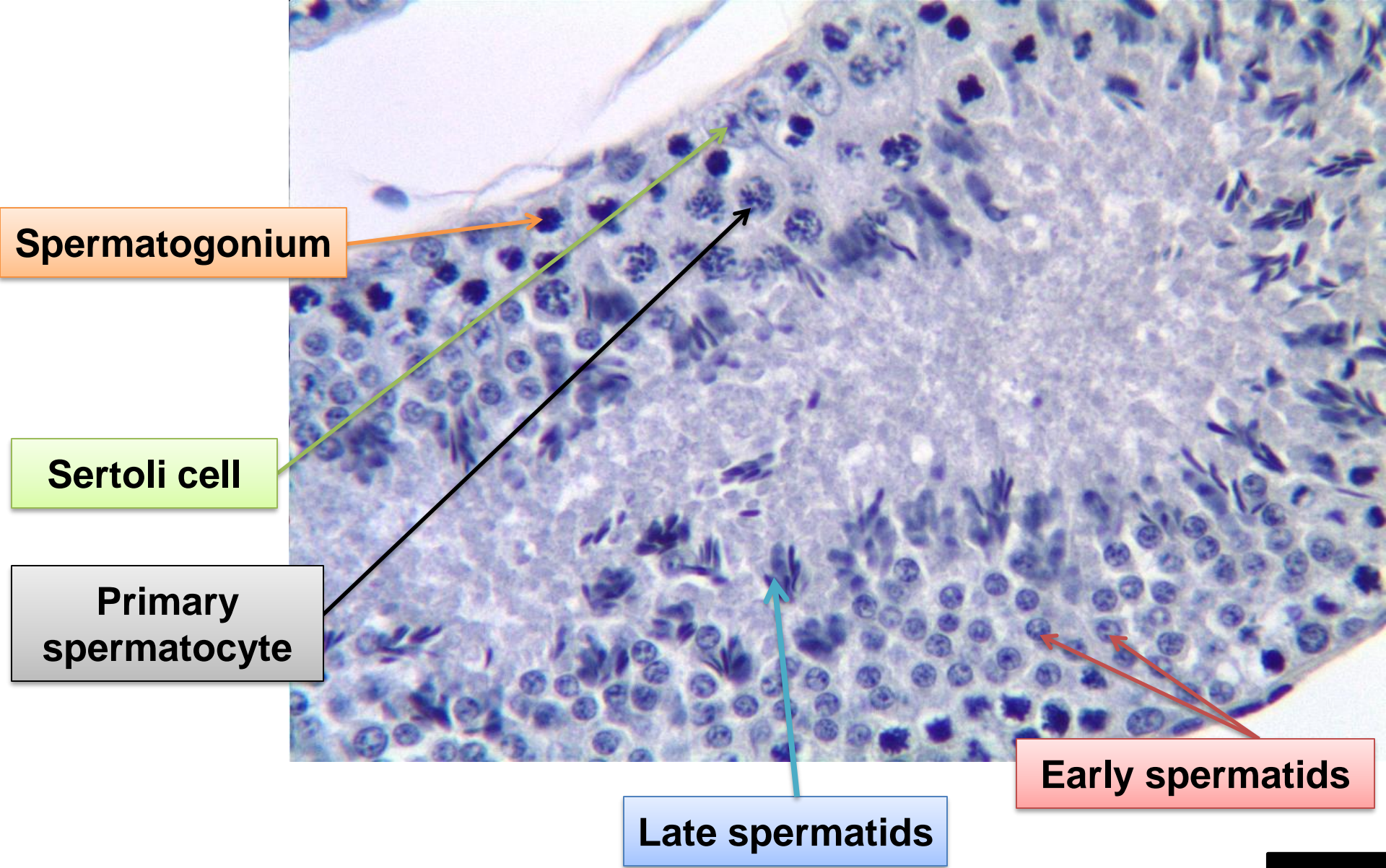
Seminiferous Tubules



Fibroblasts

Lydig cell

Seminiferous Tubules



Spermatogonium

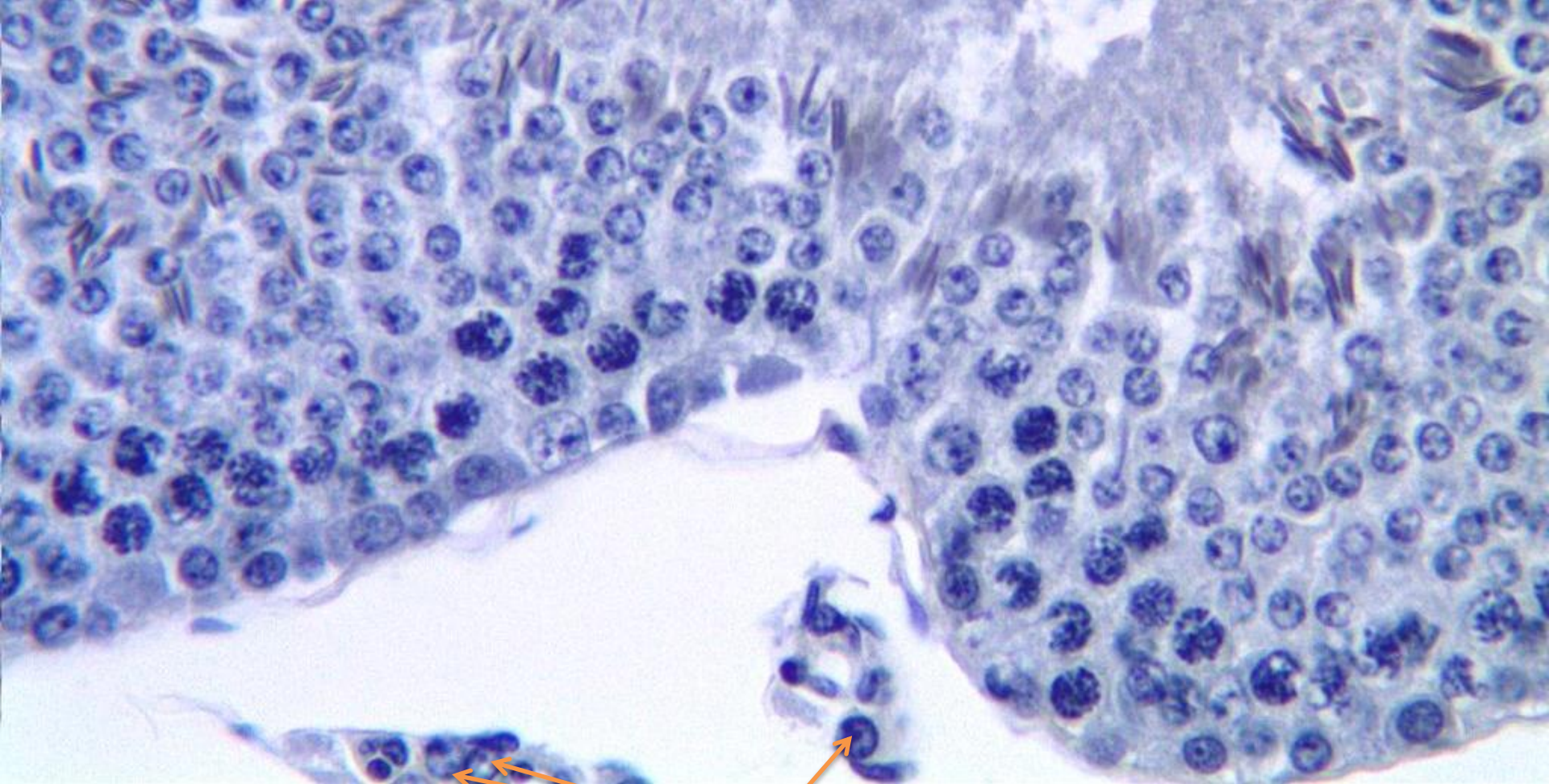
Sertoli cell

Primary spermatocyte

Late spermatids

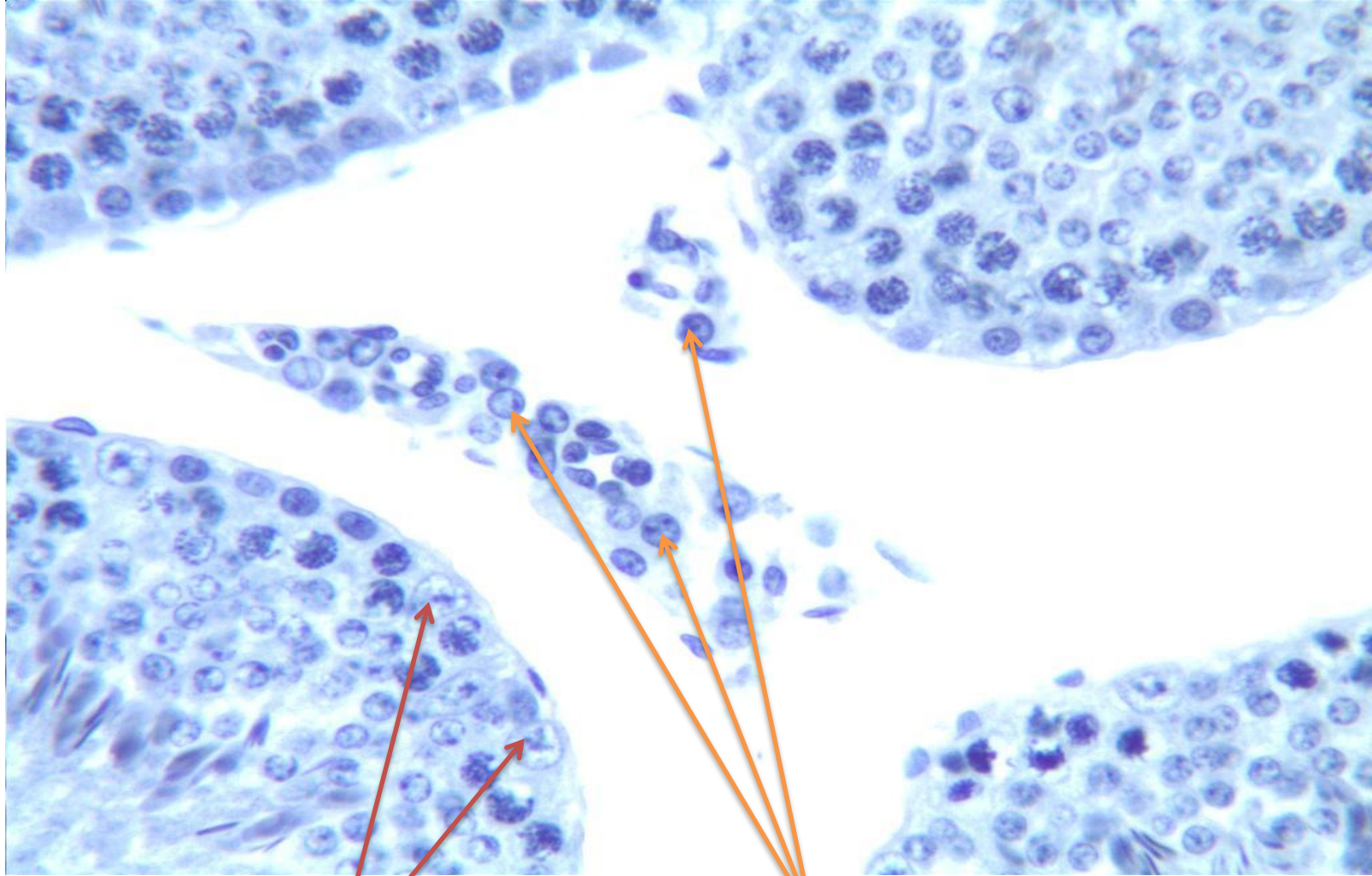
Early spermatids

Seminiferous Tubules



Lydig cells

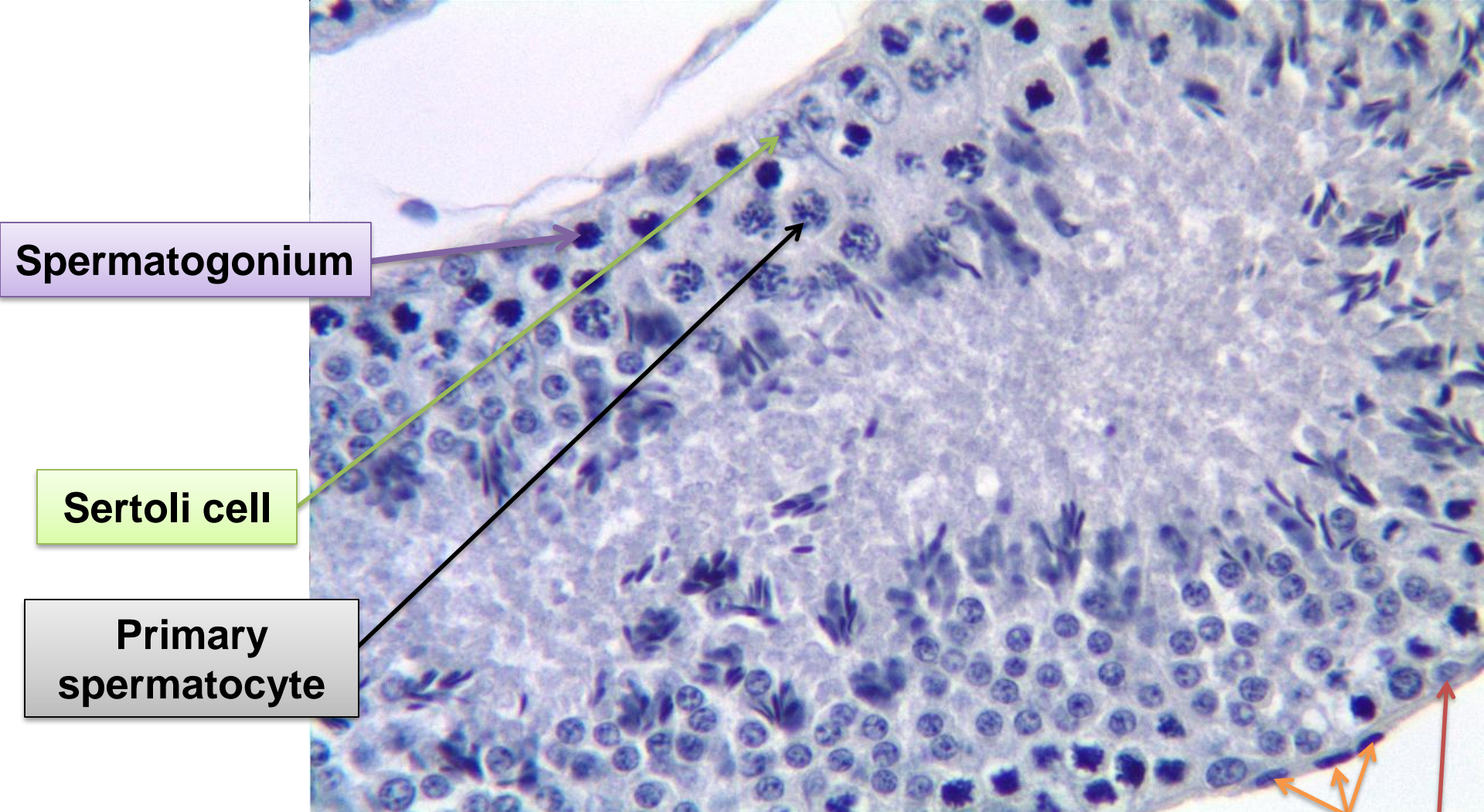
Seminiferous Tubules



Sertoli cells

Leydig cells

Seminiferous Tubules



Spermatogonium

Sertoli cell

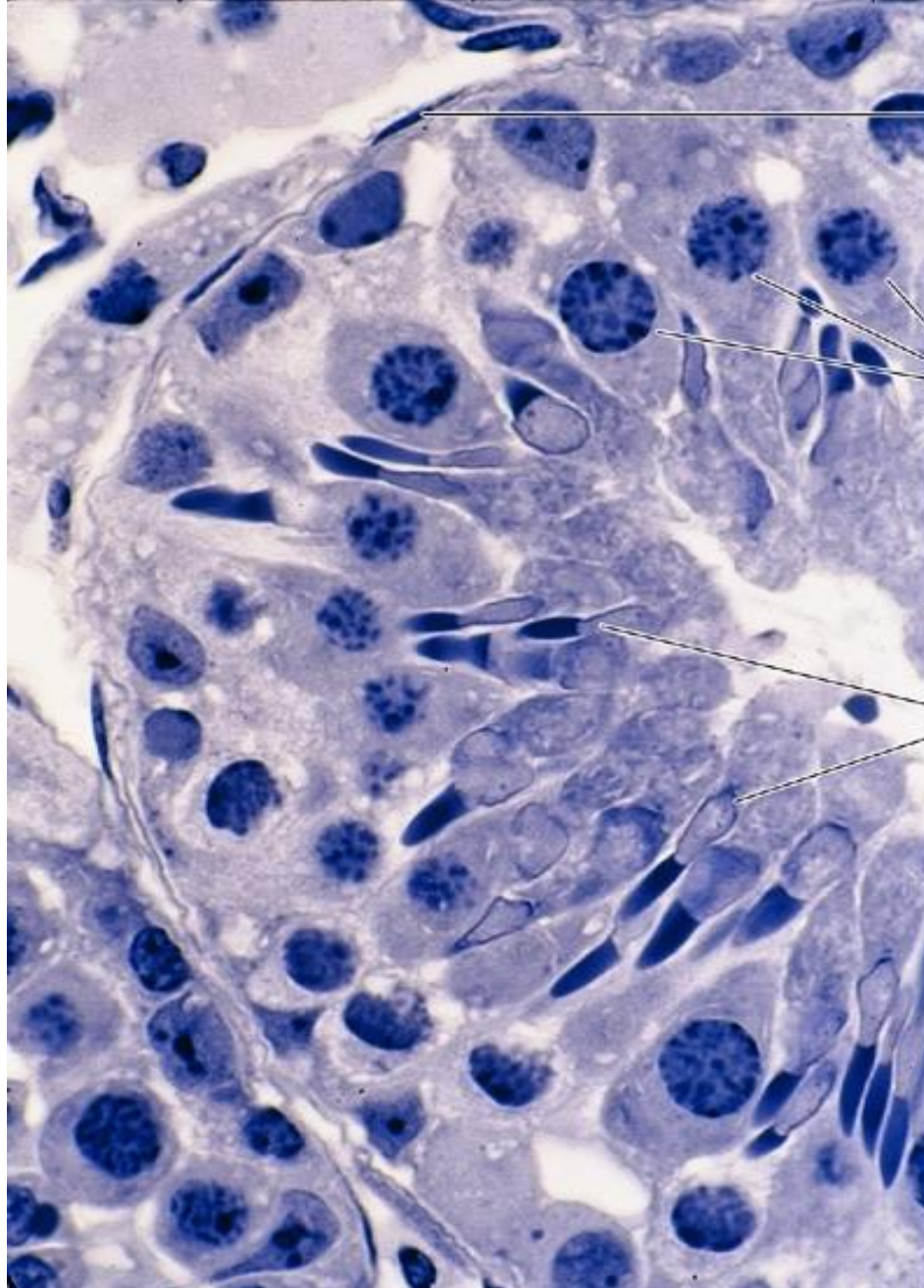
Primary spermatocyte

Myoid cells

Basal cell

19A

Seminiferous Tubules



Myoid cells

**Primary
spermatocyte**

Late spermatids

19B

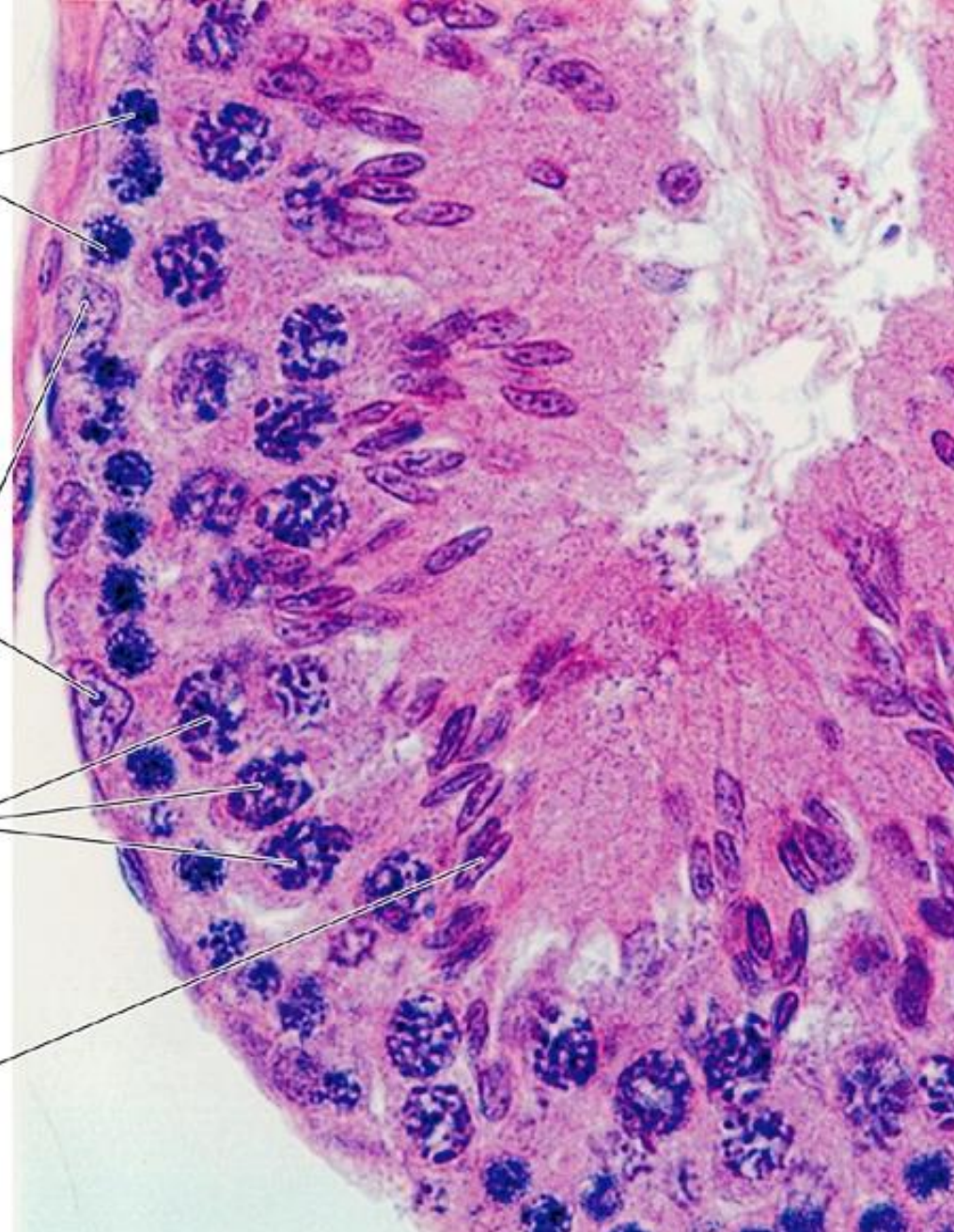
Seminiferous Tubules

Spermatogonia

Sertoli cells

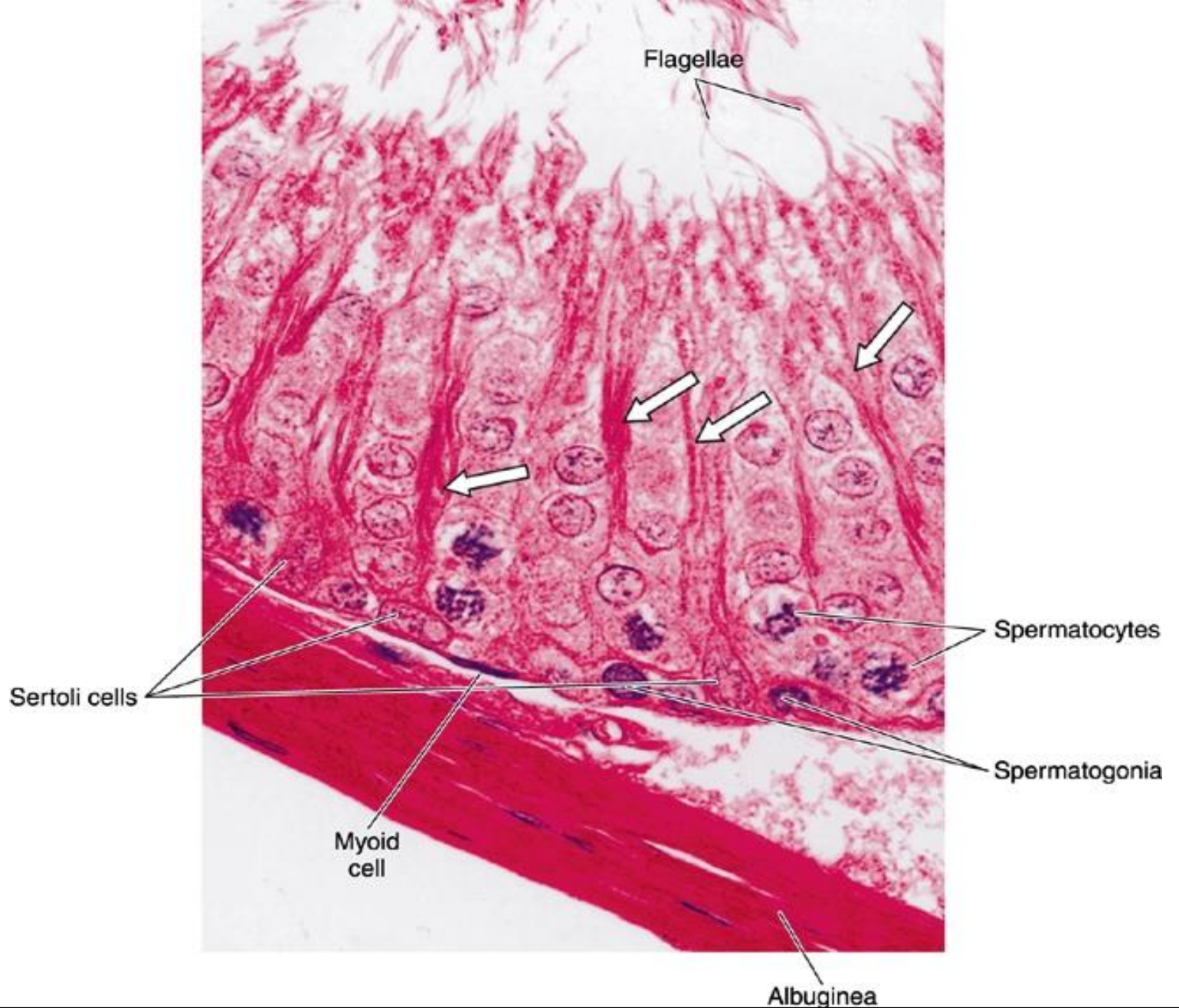
Spermatocytes

Spermatids



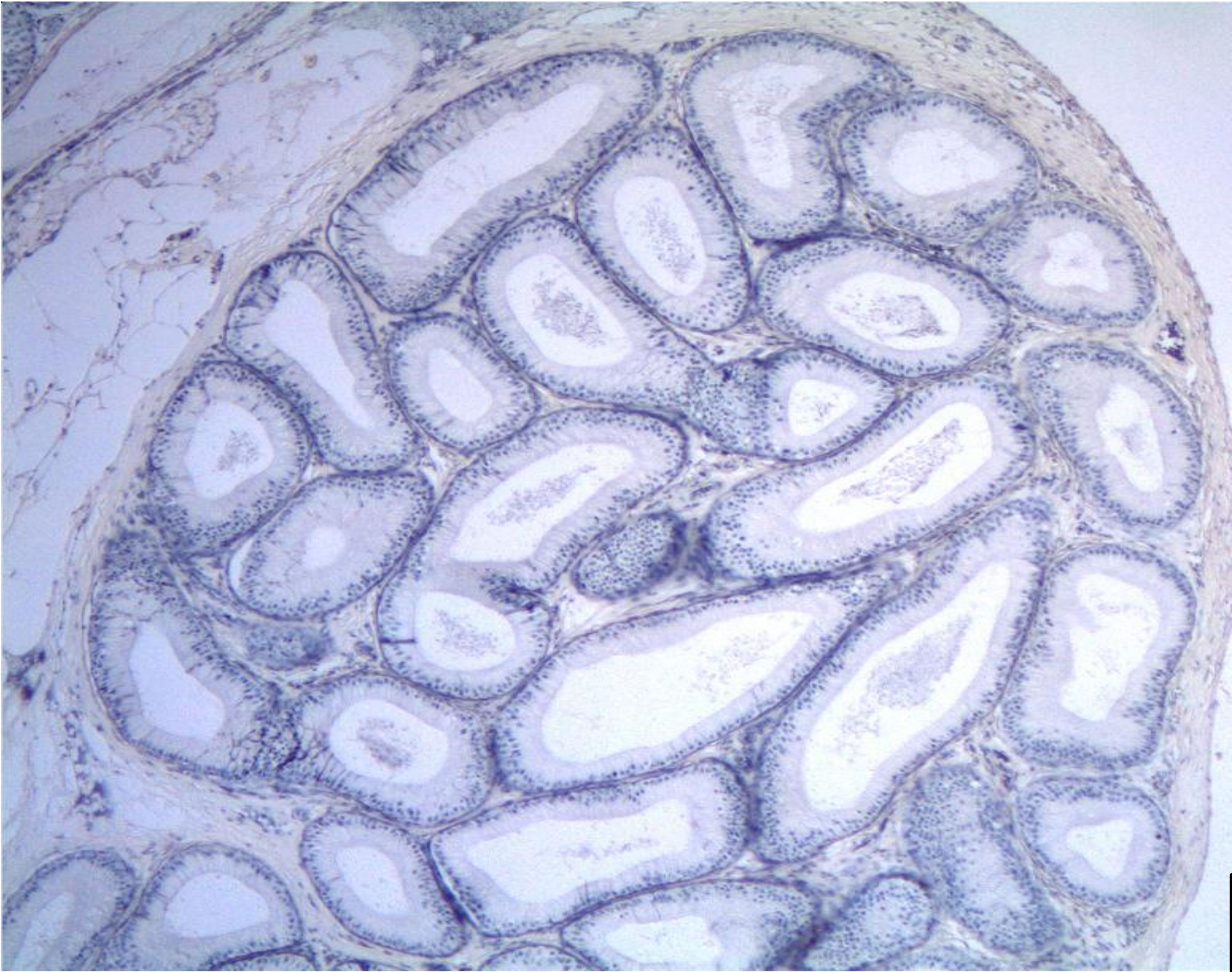19C

Seminiferous Tubules

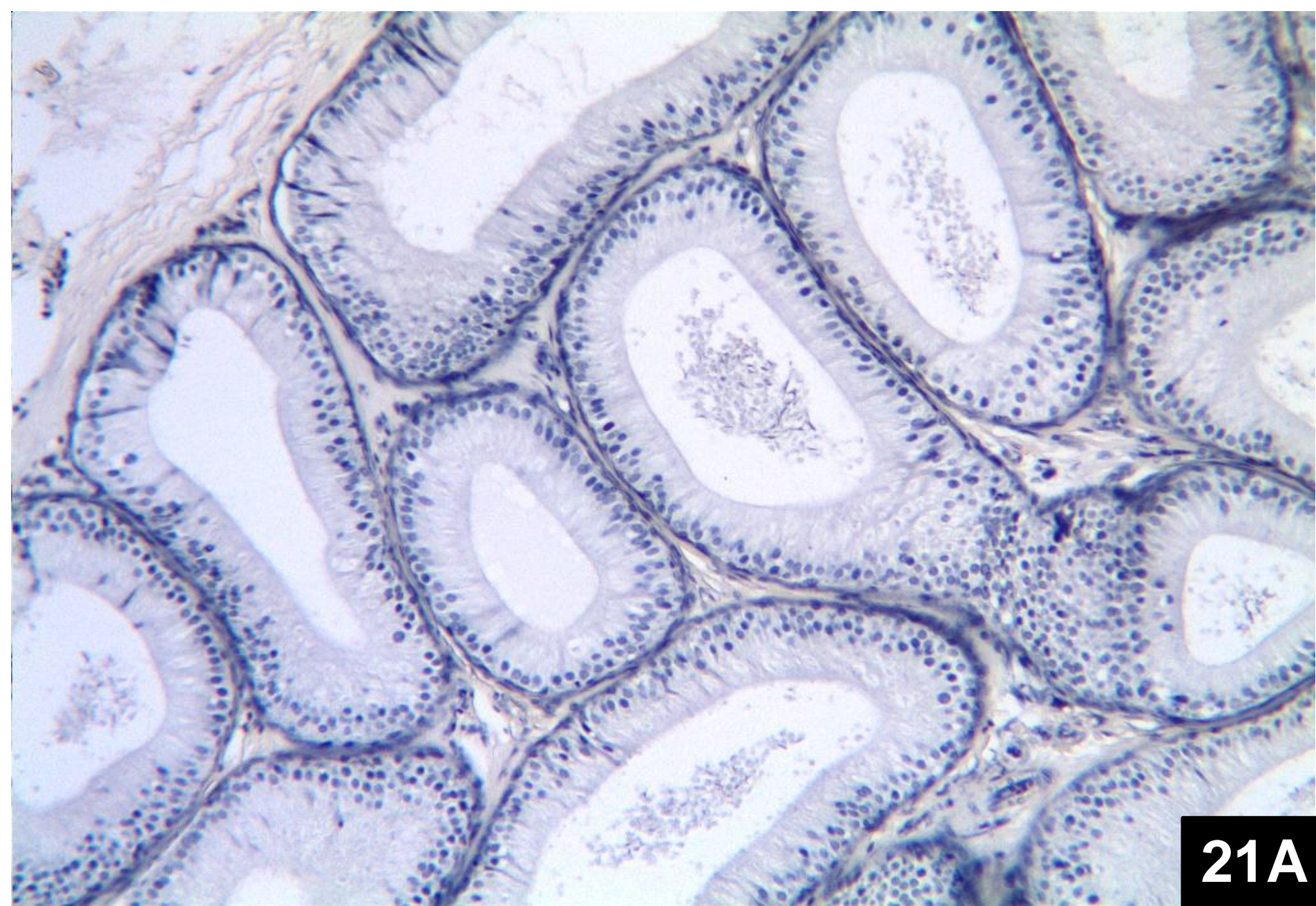


19D

Seminiferous Tubules

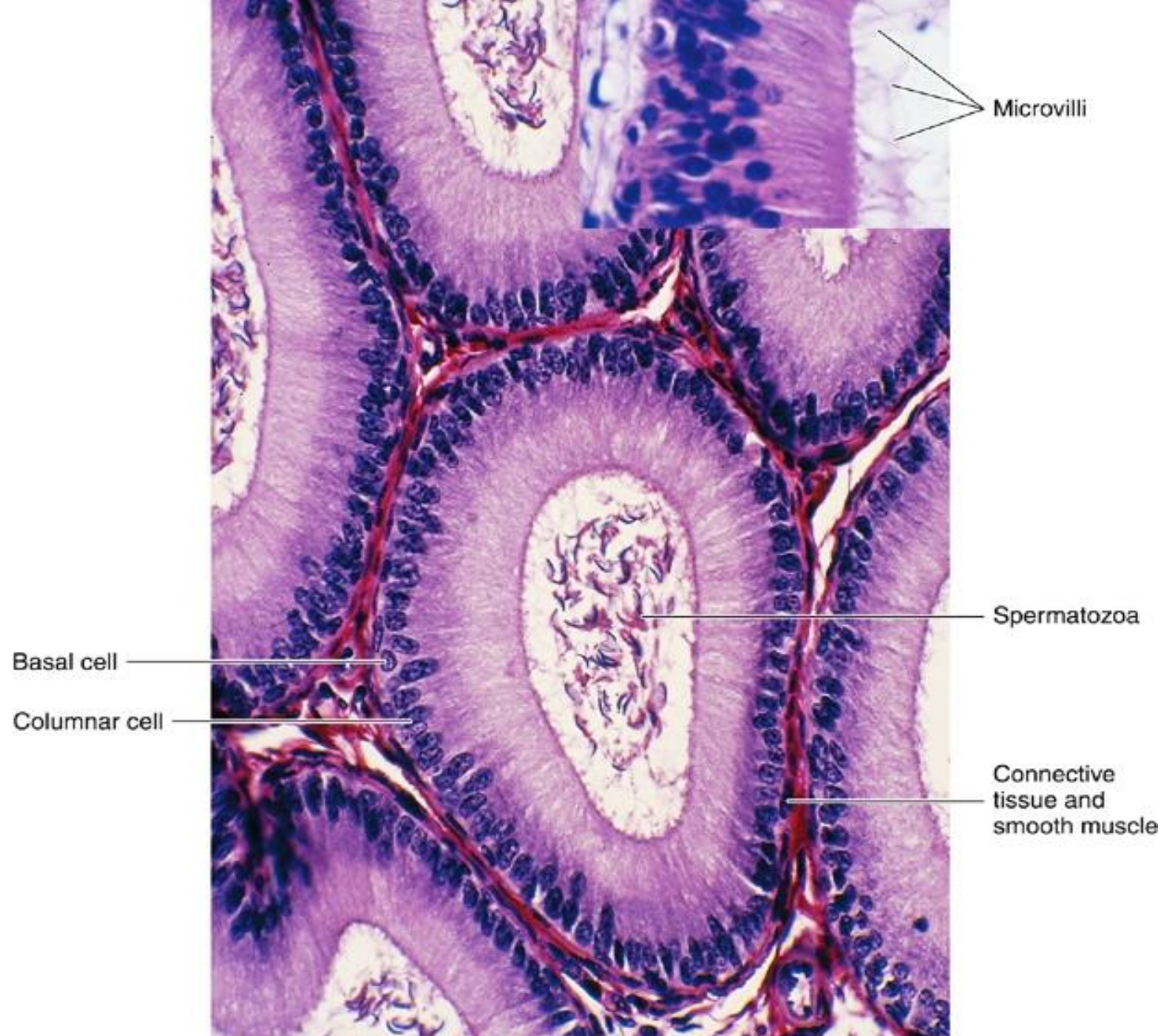


Section Through Epididymis (Low Power)



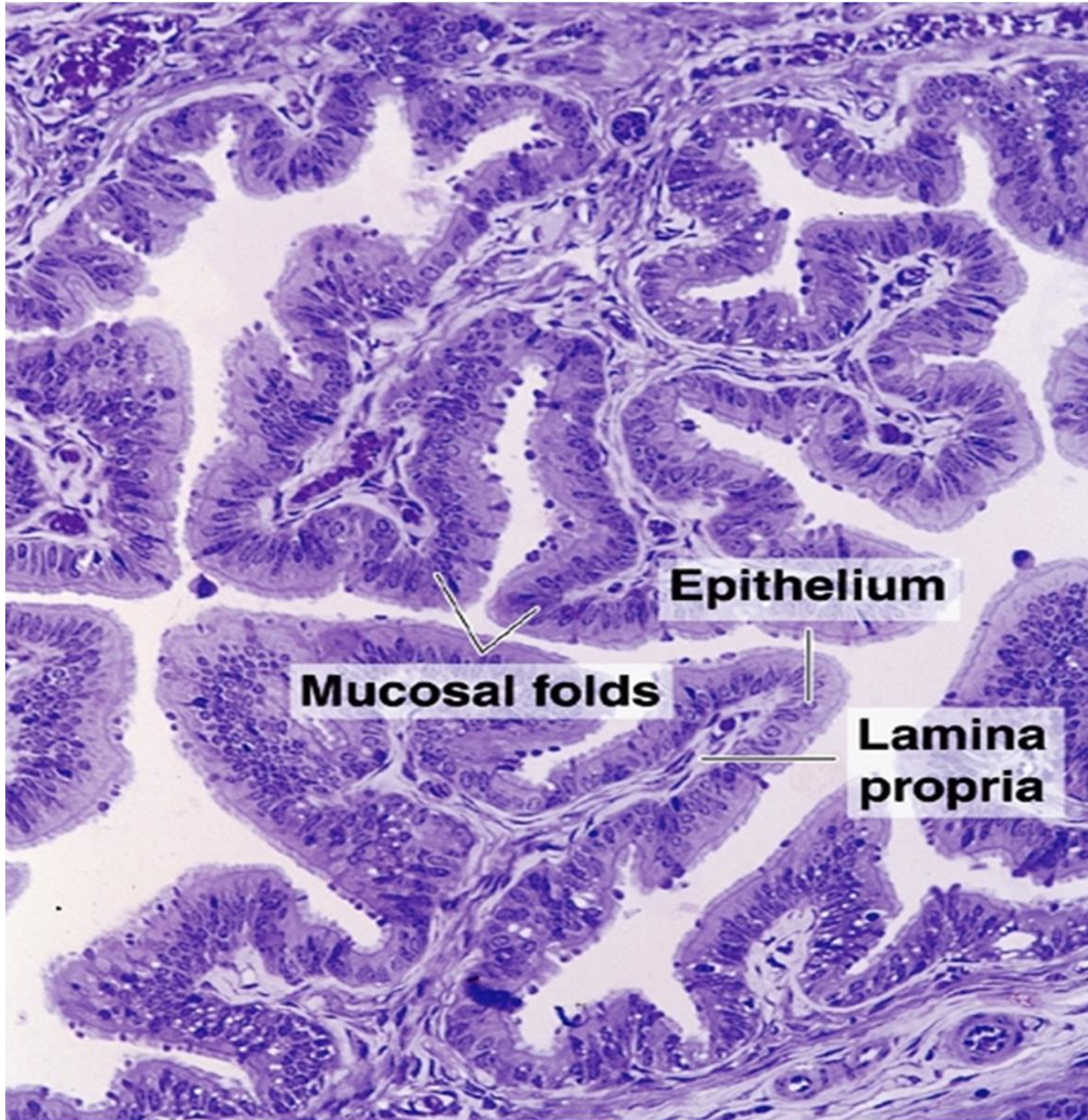
21A

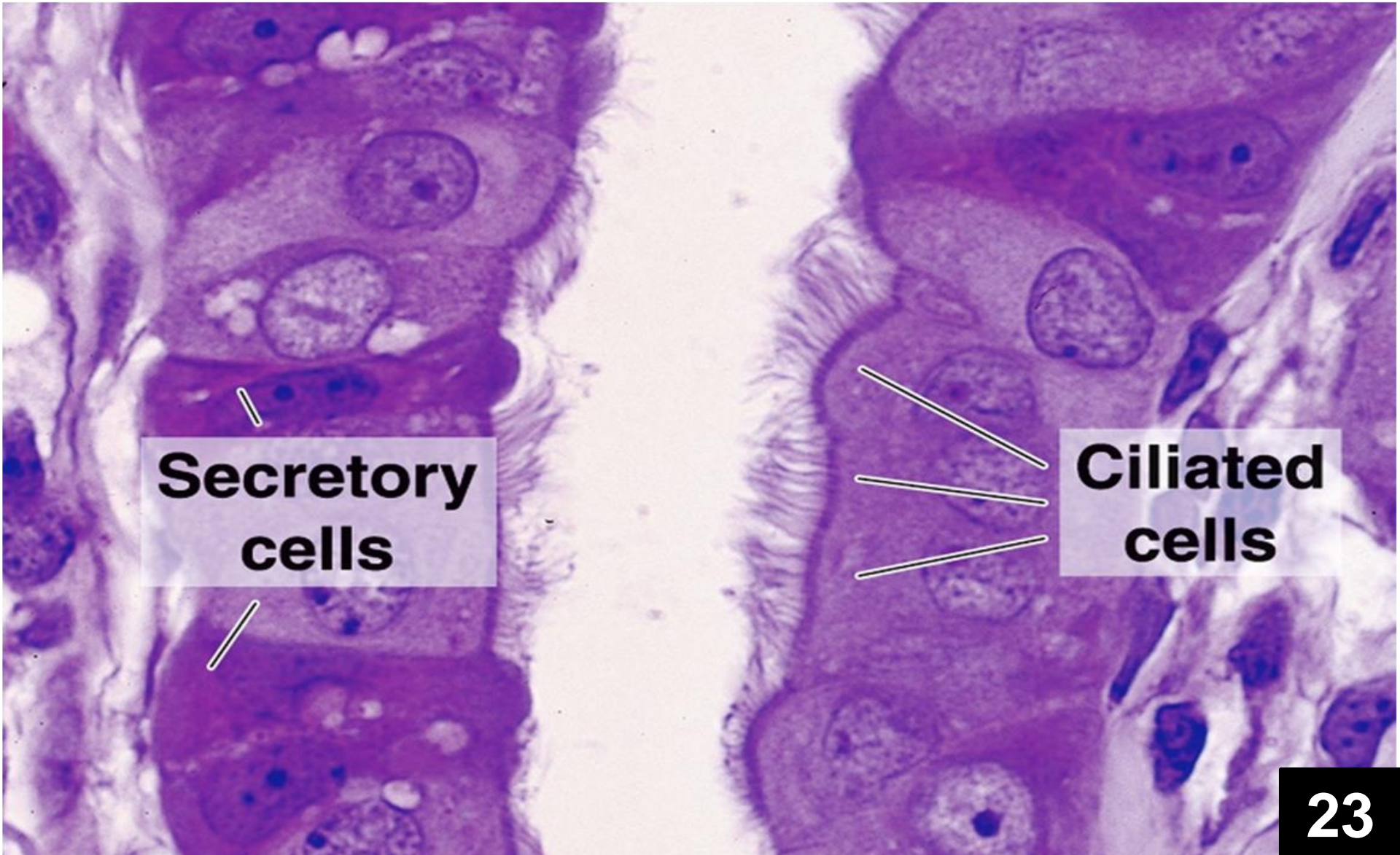
Section Through Epididymis (High Power)



21B

Section Through Epididymis (High Power)

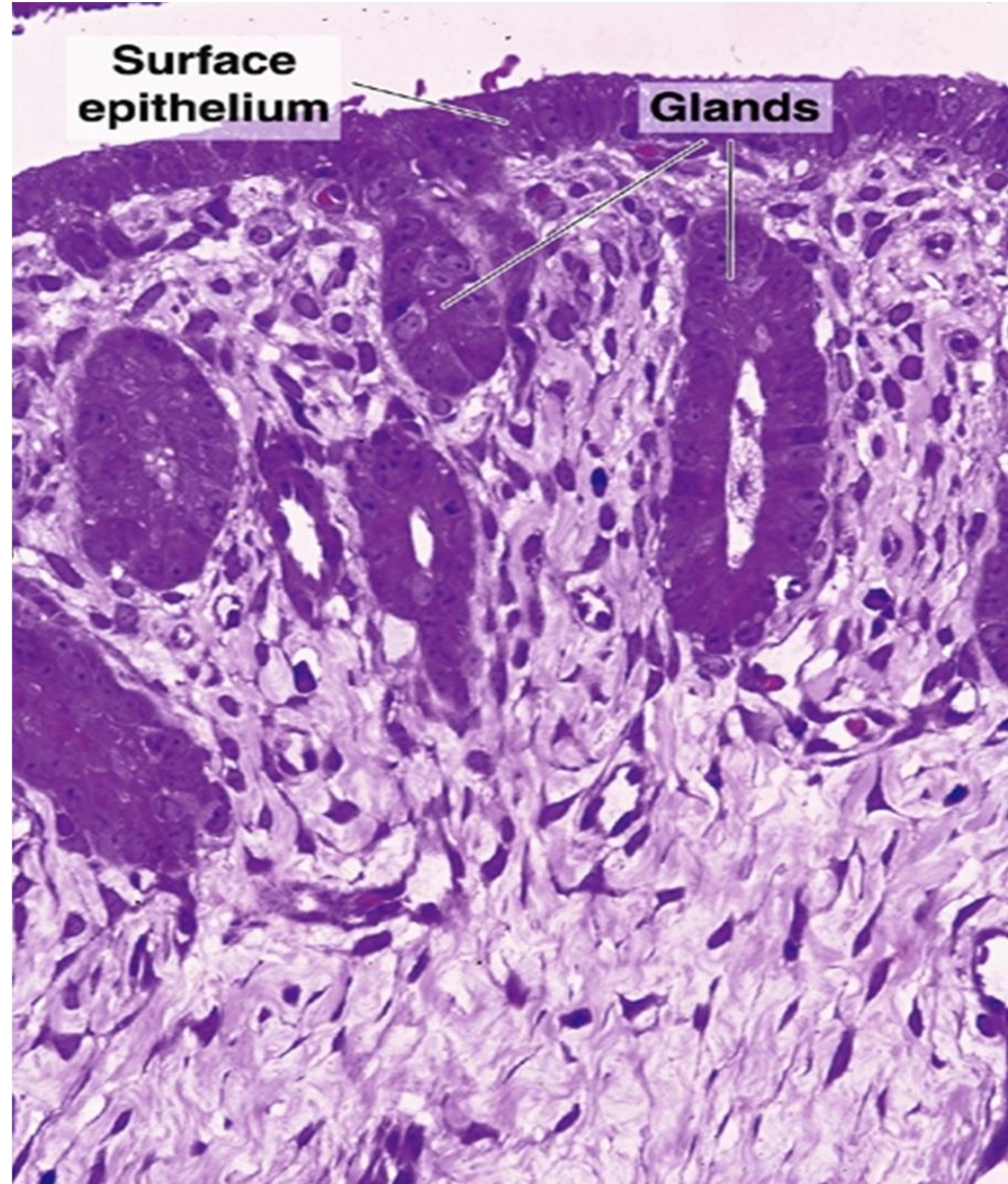




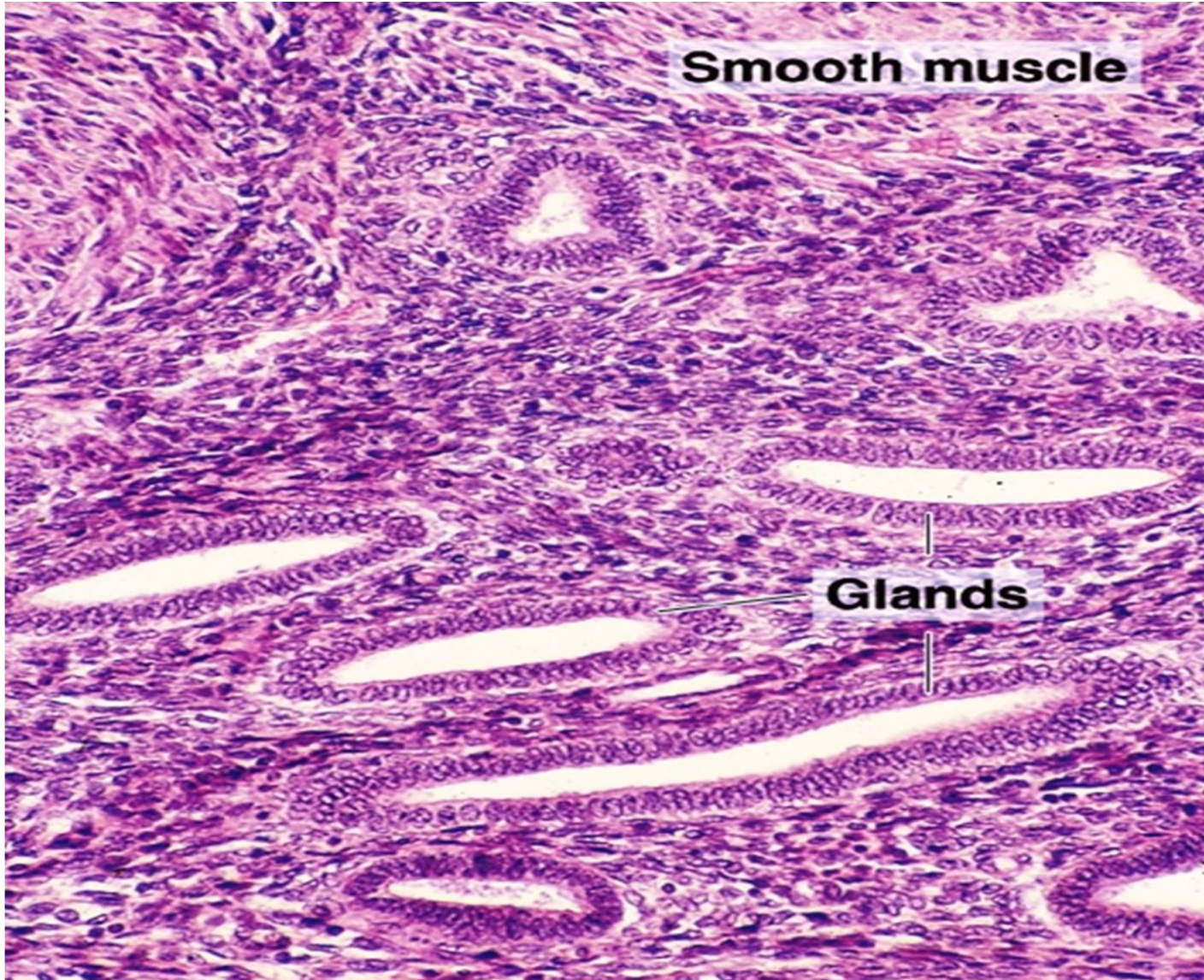
Secretory cells

Ciliated cells

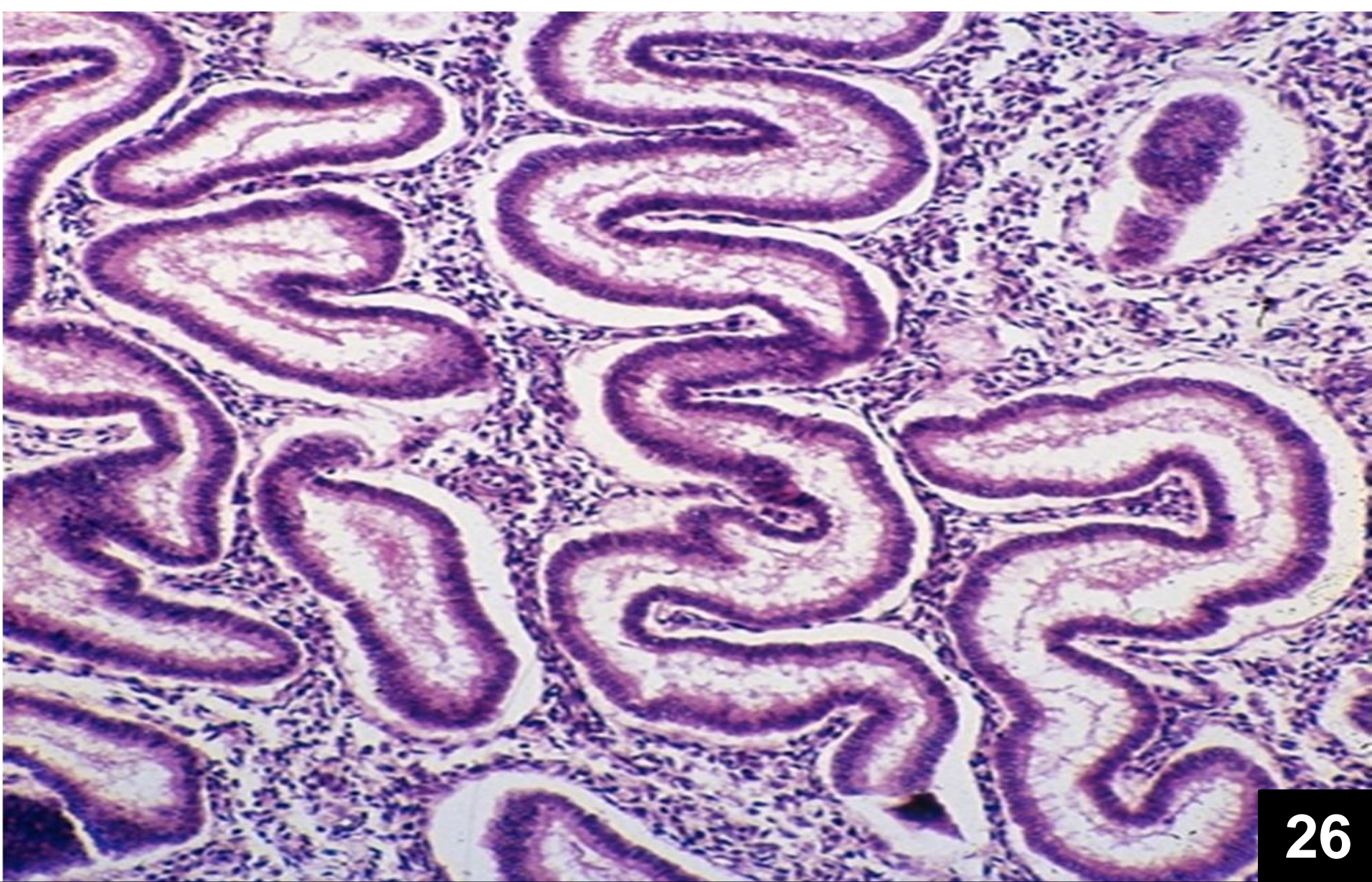
Lining epithelium of uterine tube (high power)



**Section Through Endometrium of Uterus
(Medium Power)**

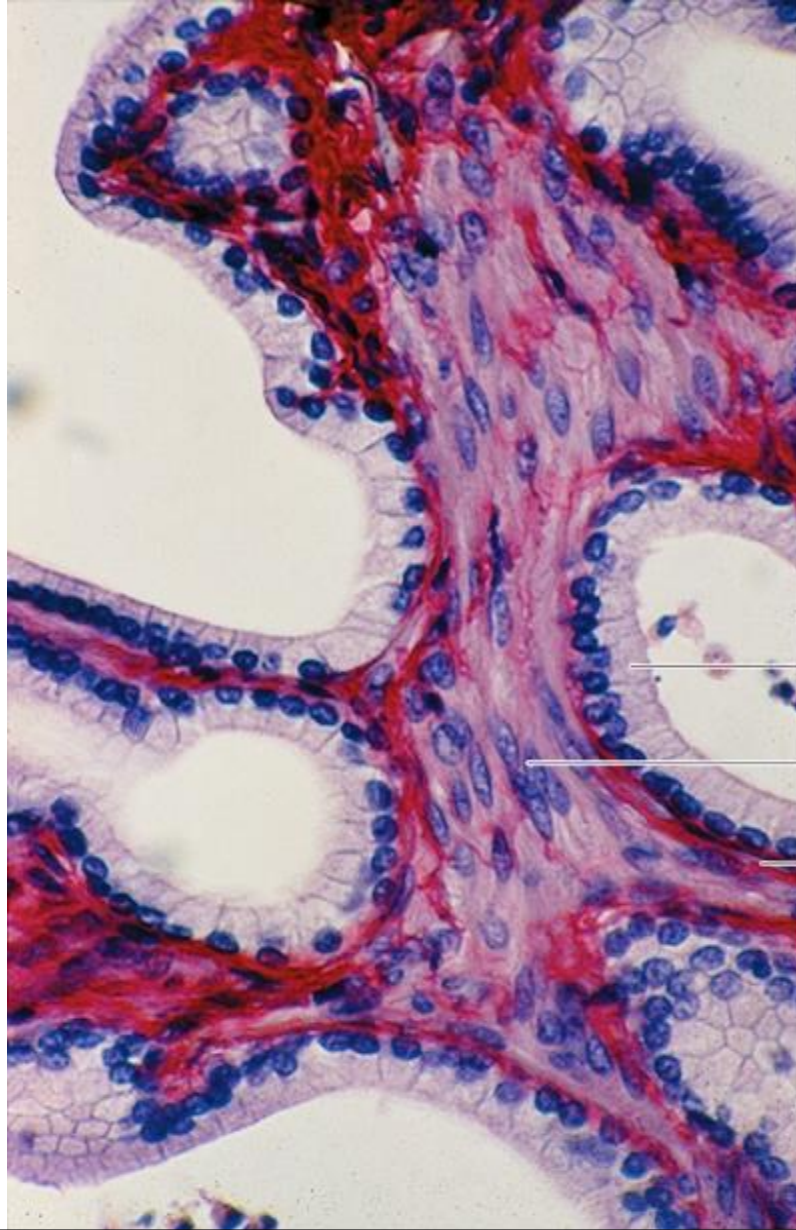


Endometrium of uterus during the proliferative phase (medium power)



26

Endometrium of uterus during the secretory phase (medium power)



Epithelium

Smooth muscle

Lamina propria

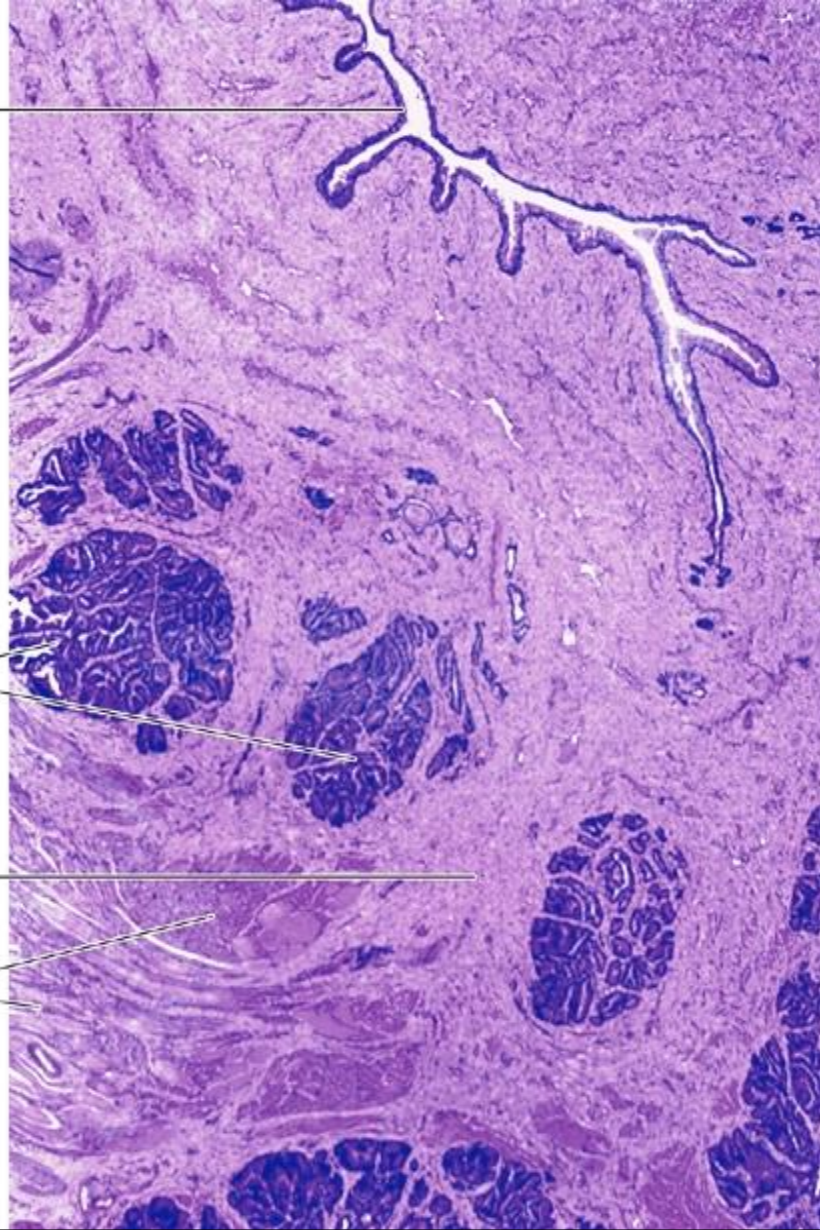
Section Through the Seminiferous Tubule

Prostatic urethra

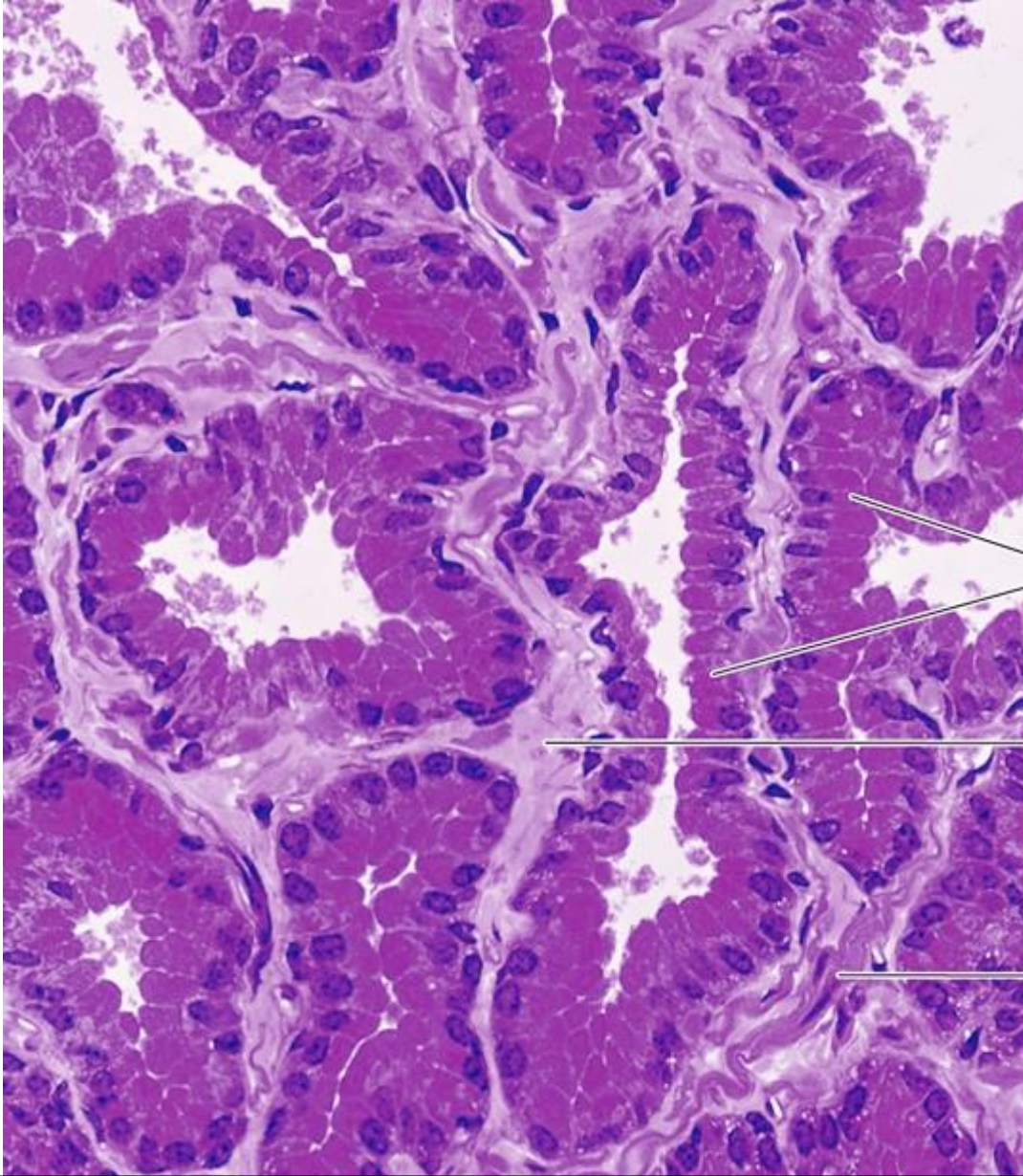
Glands

Connective tissue

Smooth muscle



The Prostatic Gland (Low Magnification)

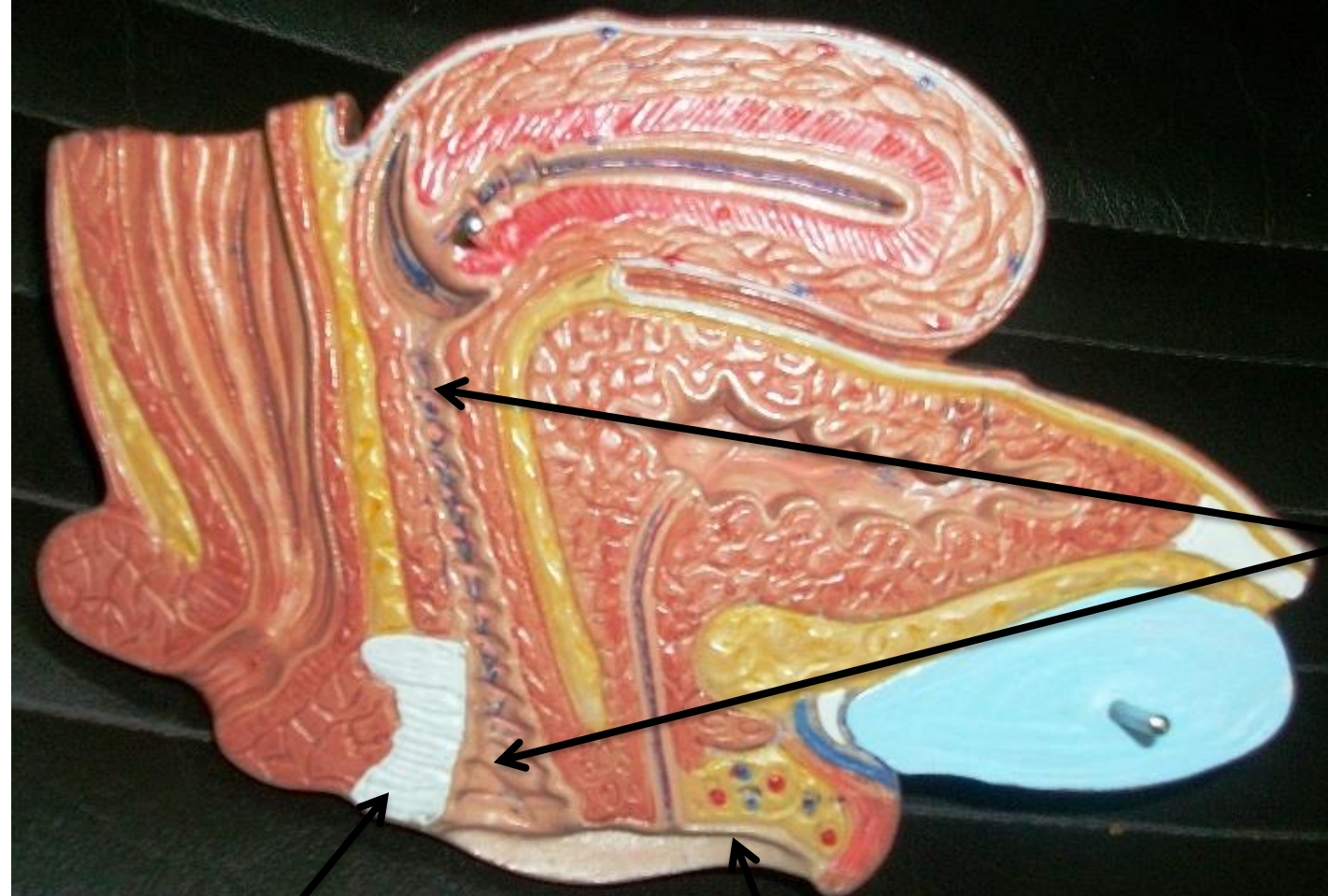


Glandular
epithelium

Connective
tissue

Smooth
muscle

The Prostatic Gland (Medium Magnification)



Vagina

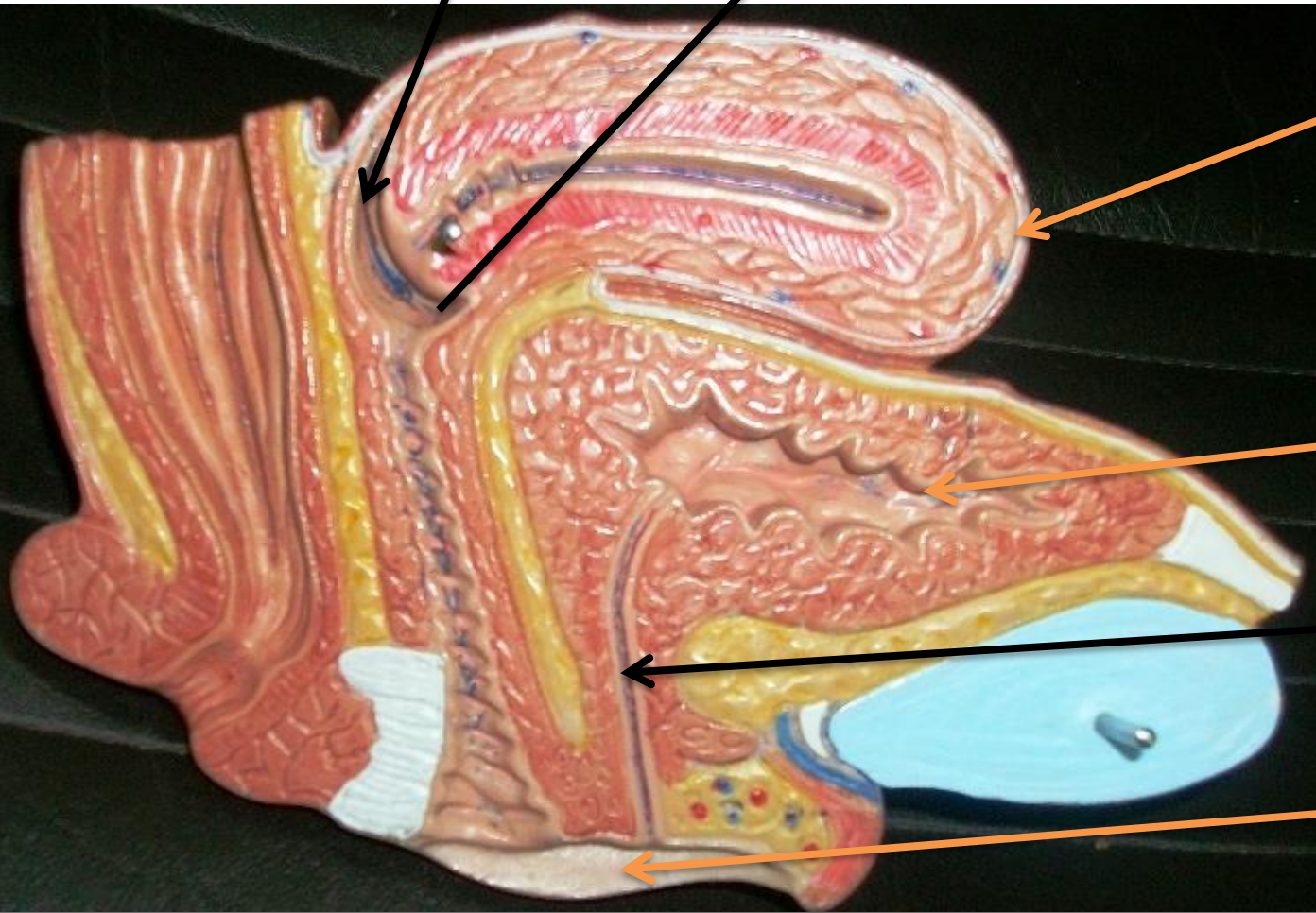

Perineal membrane

Vestibule

Female Genital Organs

Posterior vaginal fornix

Anterior vaginal fornix



Fundus part of uterus

Urinary bladder

Urethra

Labia minora

Female Genital Organs

Rectouterine pouch

Isthmus part of uterus

Body of uterus

Uterovesical pouch

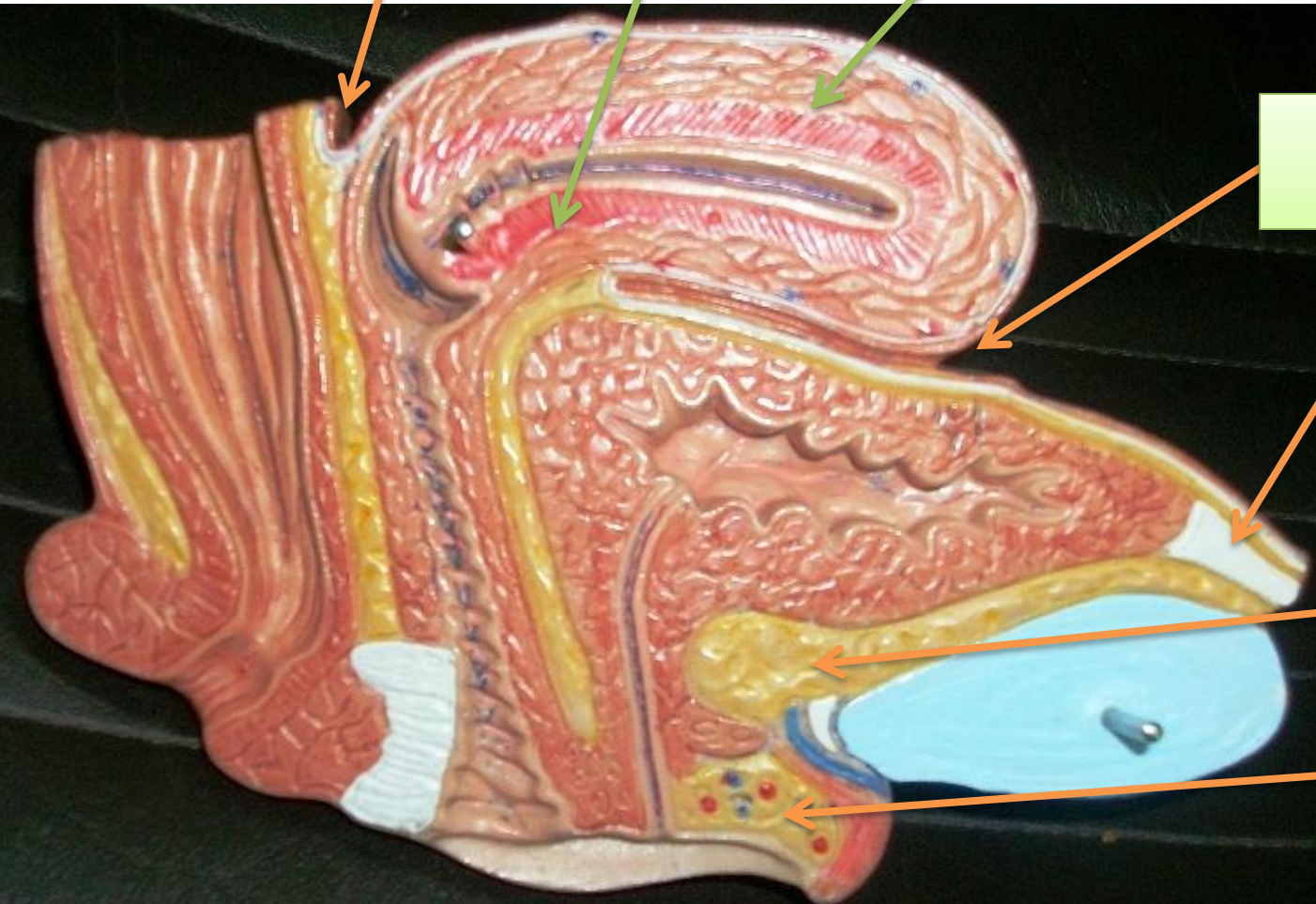
Median umbilical ligament

Retropubic pad of fat

Clitoris

32

Female Genital Organs



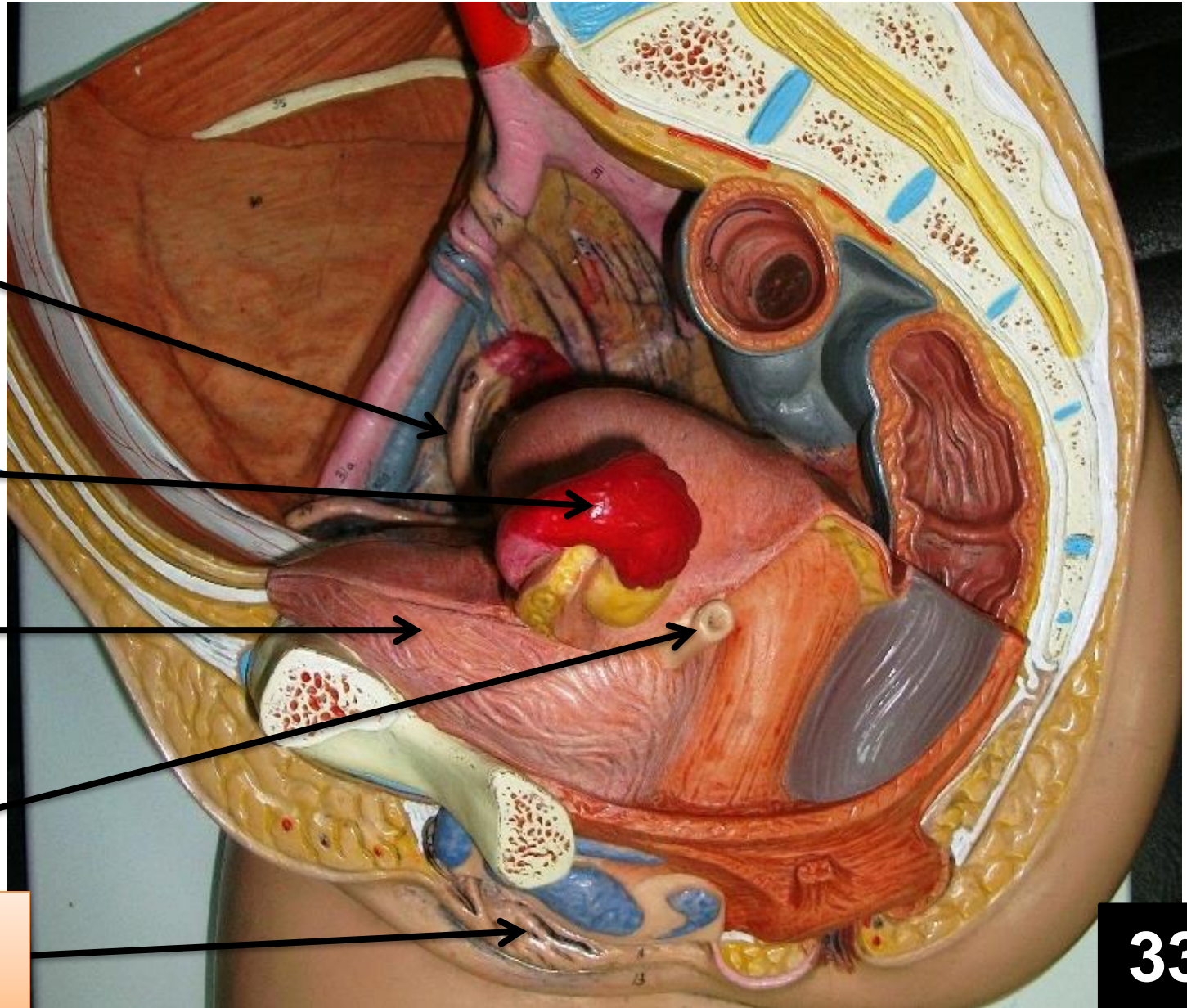
Uterine tube

Ovary

Urinary bladder

Ureter

Labia minora

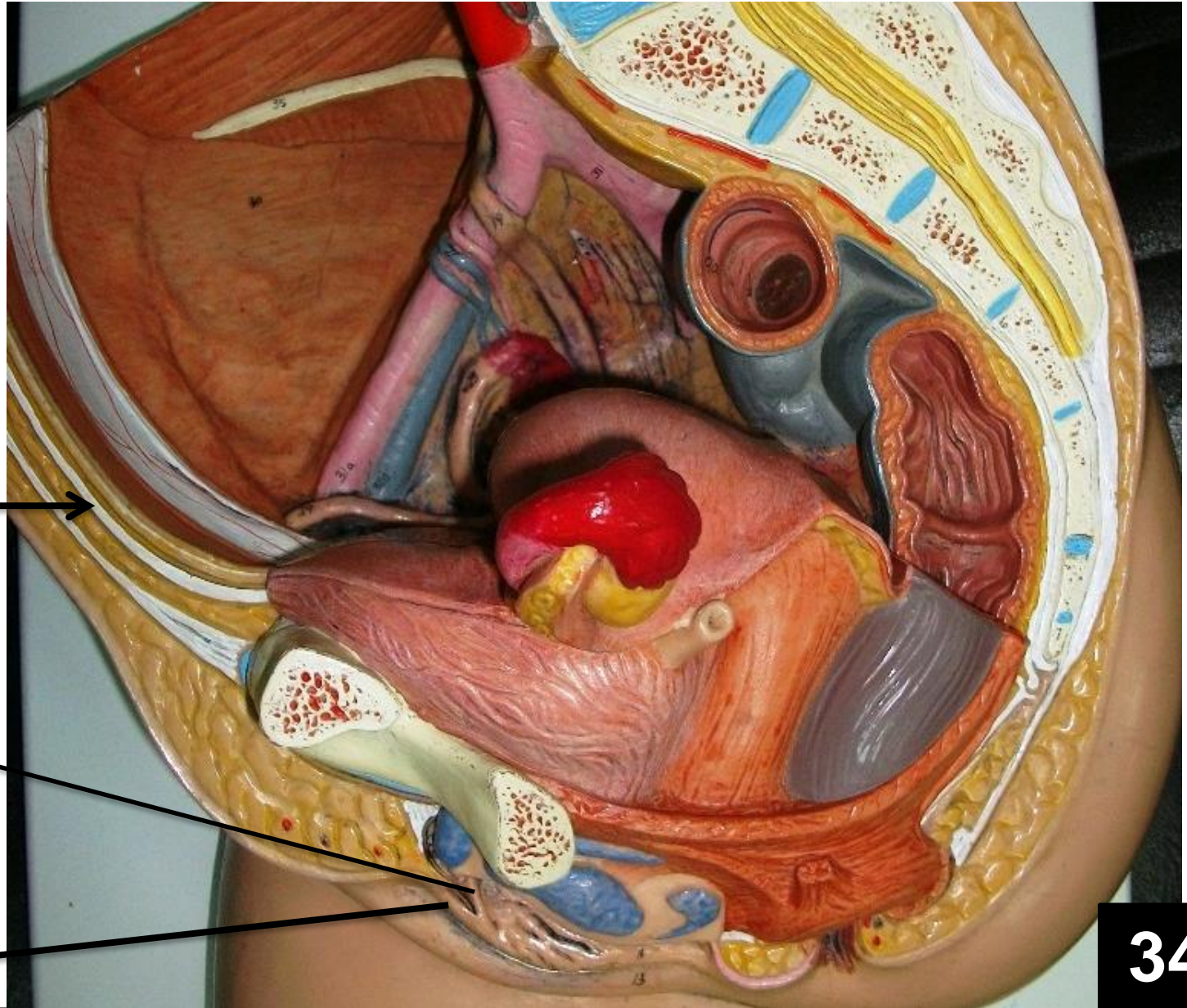


Female Genital Organs

**Median
umbilical
ligament**

Frenulum

Prepuce



Female Genital Organs

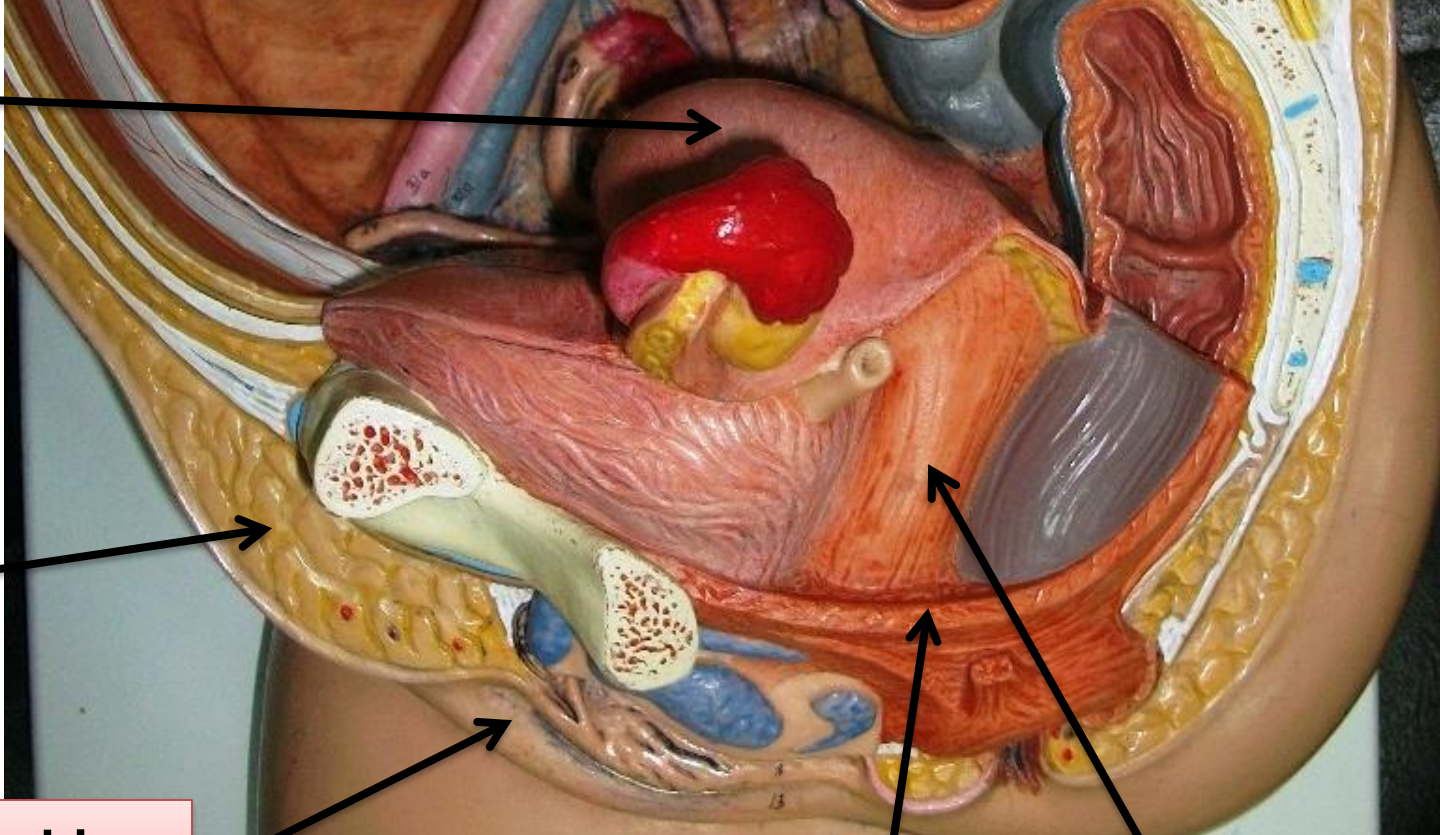
Uterus

Retropubic
pad of fat

Labia
majora

Pelvic
diaphragm
(levator ani)

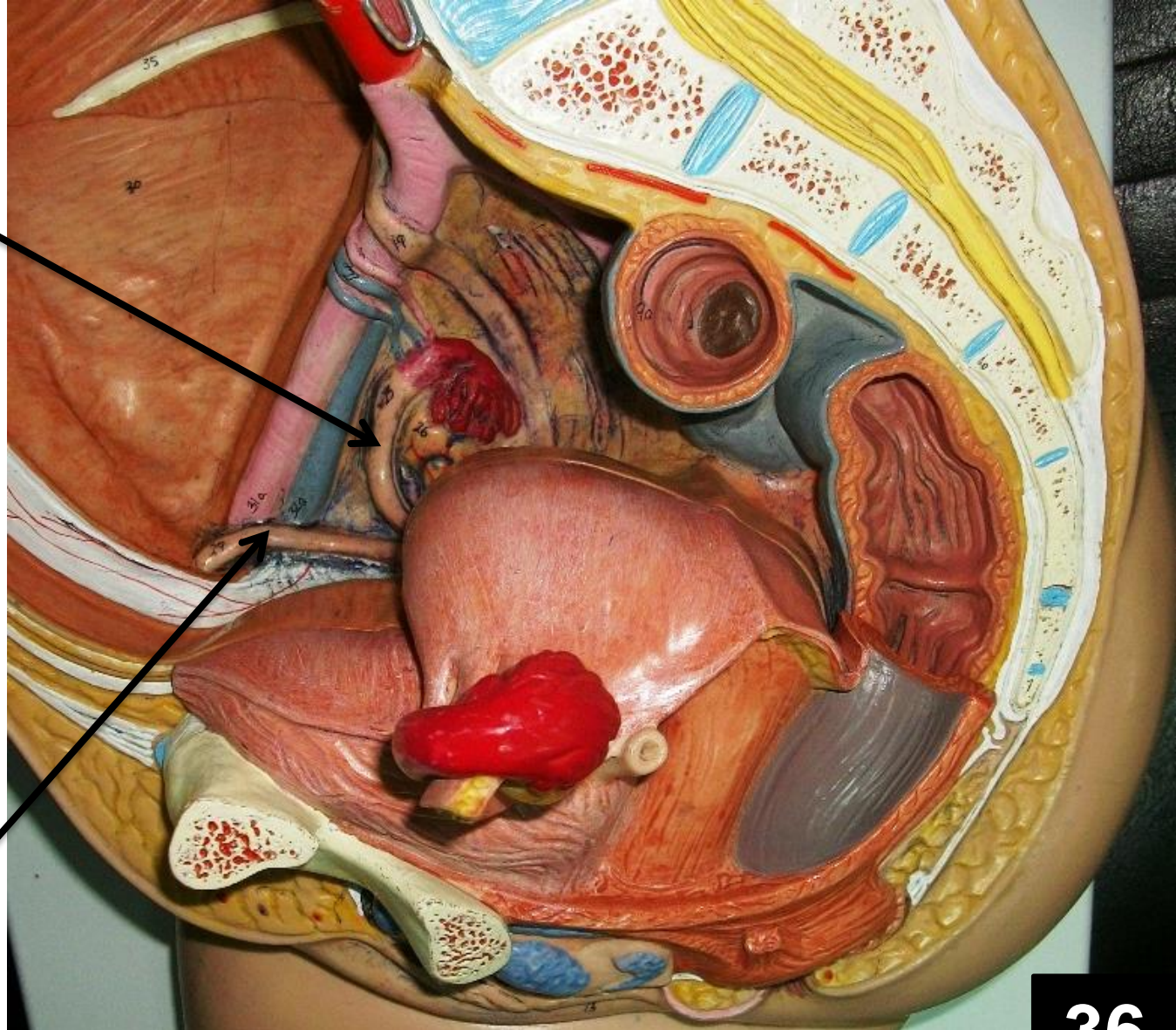
Vagina



Female Genital Organs

Uterine tube

**Round
ligament of
uterus**



36

Female Genital Organs



Infundibulum
part of
Uterine tube

Fimbriae

Ampula part
of Uterine
tube

vaginal part of
cervix

Supravaginal
part of cervix

Female Genital Organs

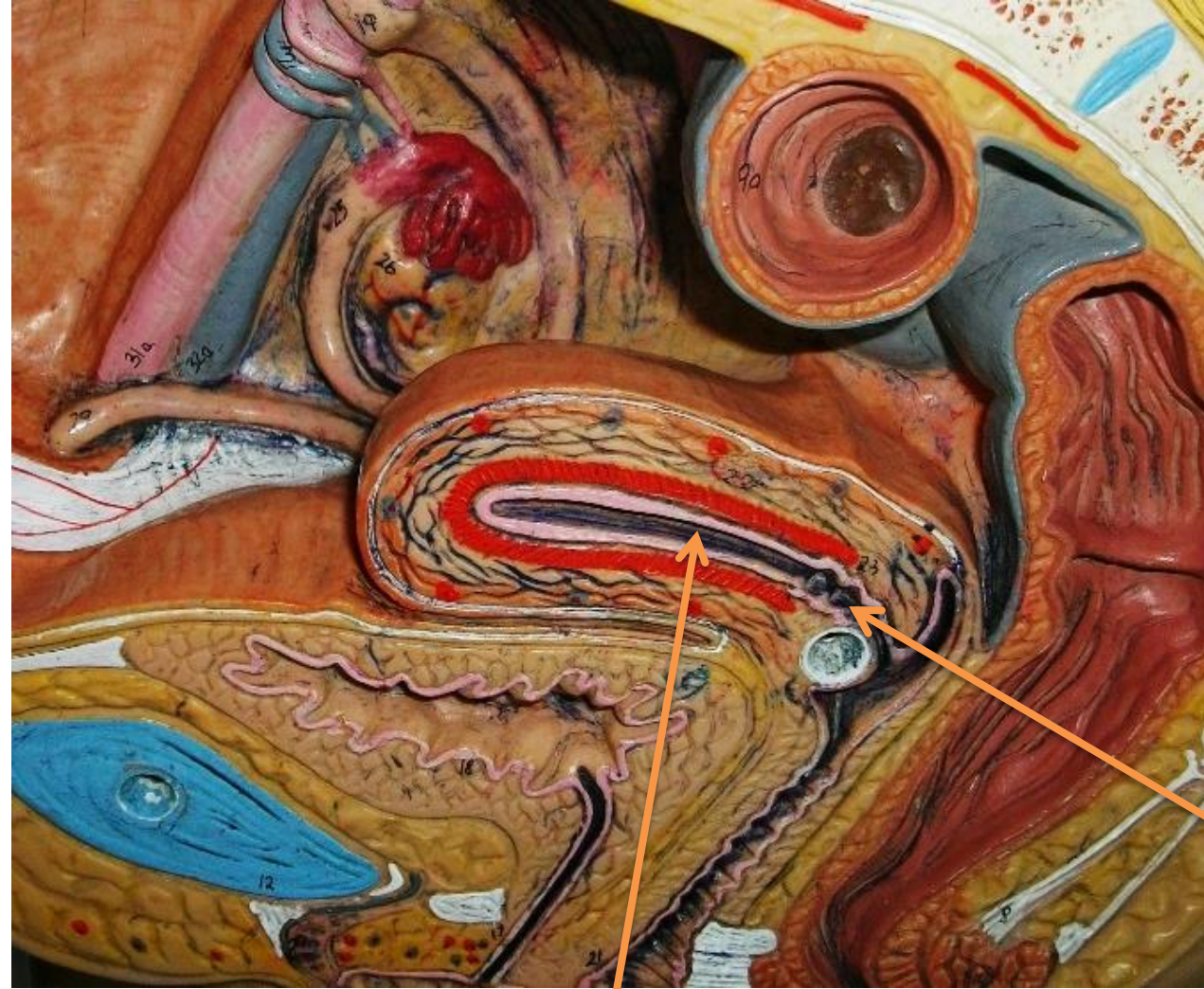**Infundibulum
part of
Uterine tube**

Cervical canal

Uterine cavity

38

Female Genital Organs



Urinary bladder

Prostatic urethra

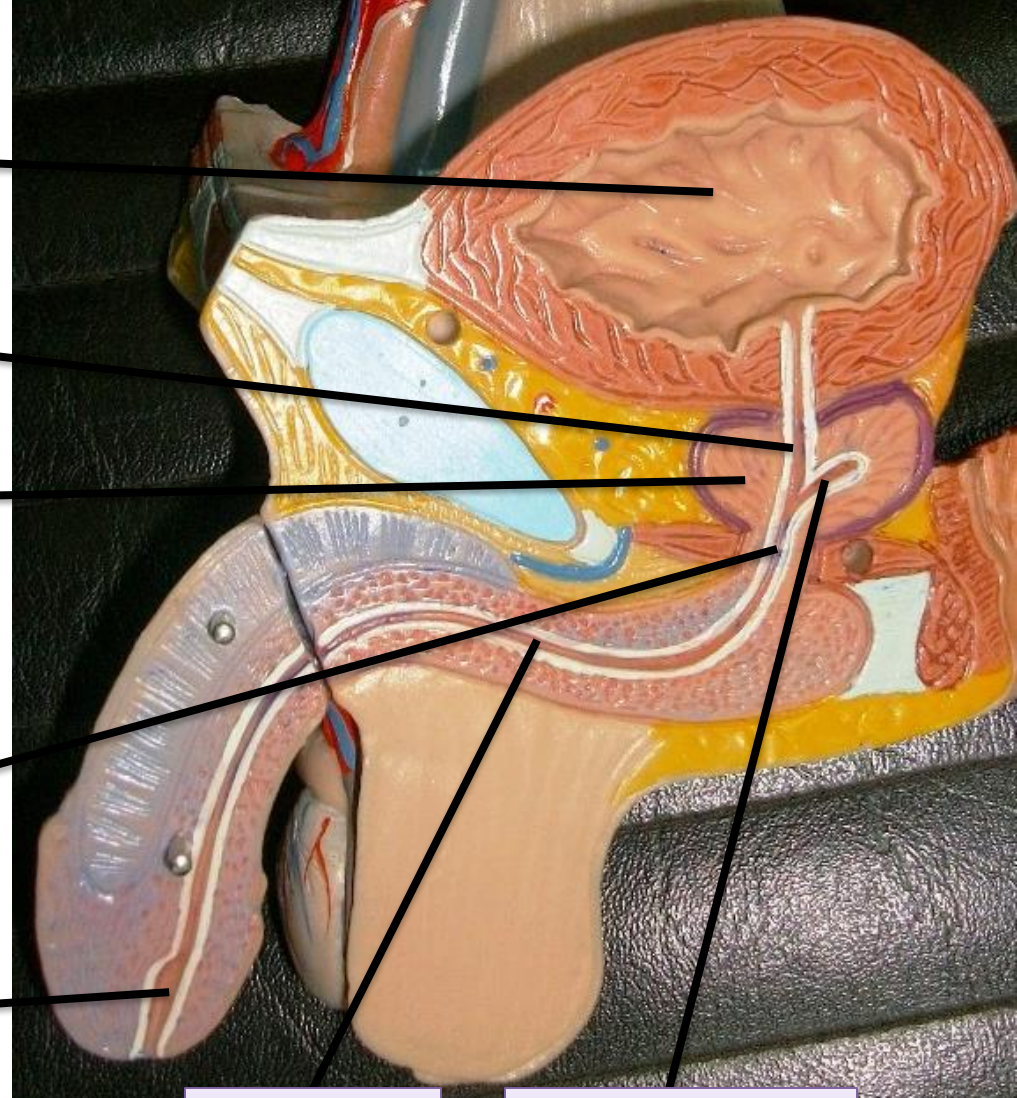
Prostate gland

Membranous urethra

**Navicular fossa
(fossa terminalis)**

**Penile
urethra**

**Ejaculatory
duct**

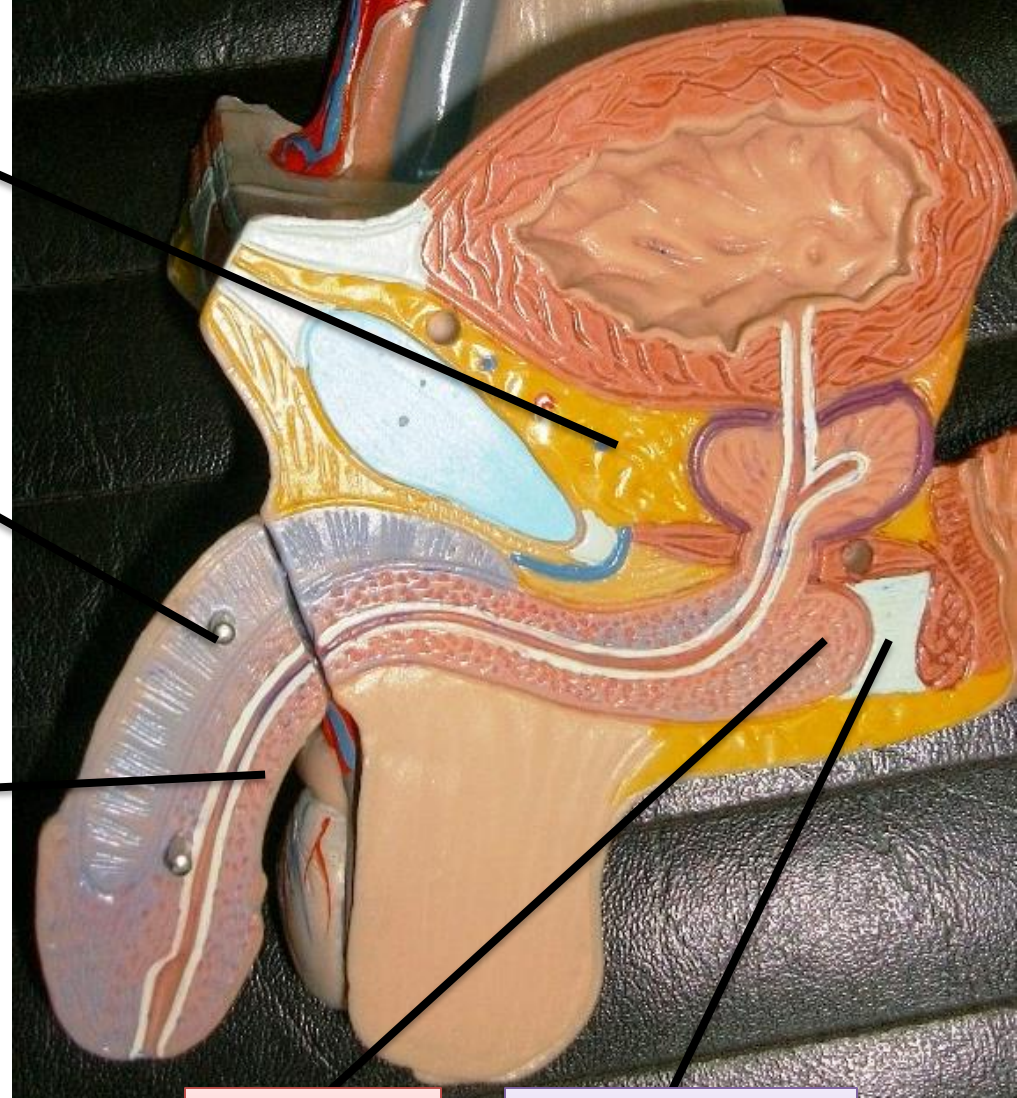


Male Genital Organs

Retropubic pad of fat

**Corpus
Cavernosum**

Corpus spongiosum

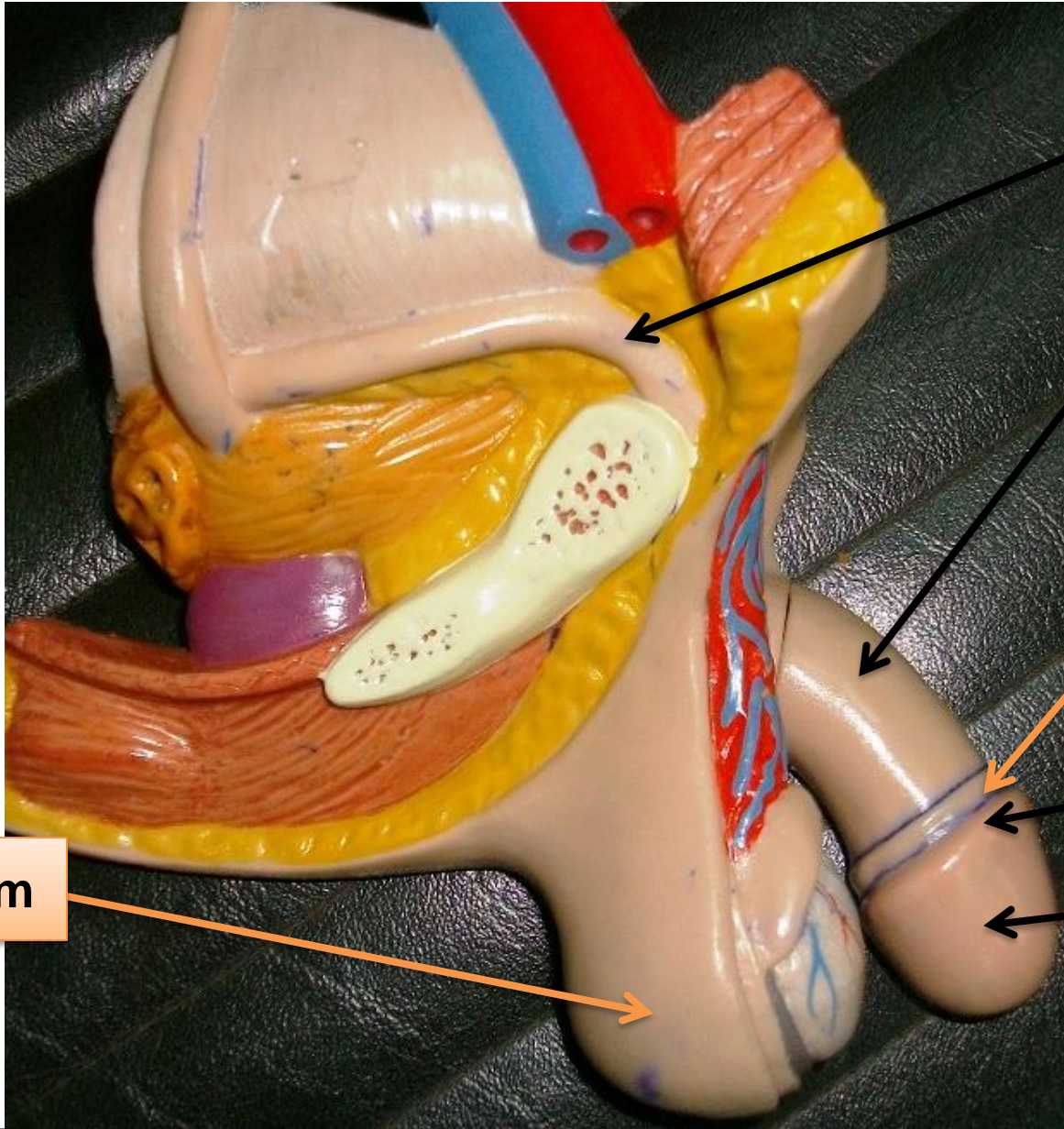


**Bulb of
penis**

**Perineal
body**

40

Male Genital Organs



Vas deferens

Body of penis

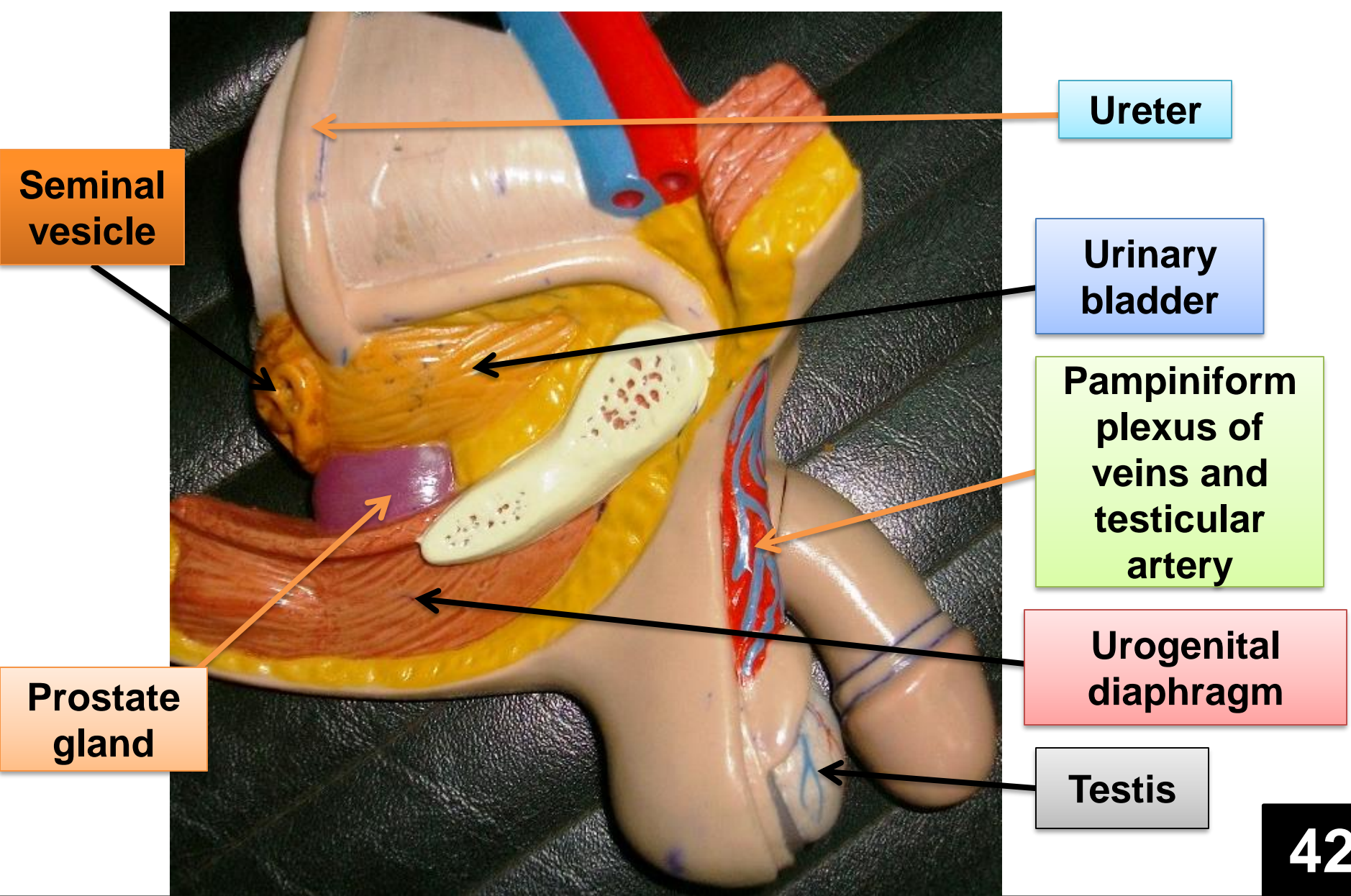
Neck of penis

Corona of penis

Glans penis

Scrotum

Male Genital Organs



Male Genital Organs

Obturator internus muscle and fascia

Tendinous arch
for insertion of
Levator ani

Periformis

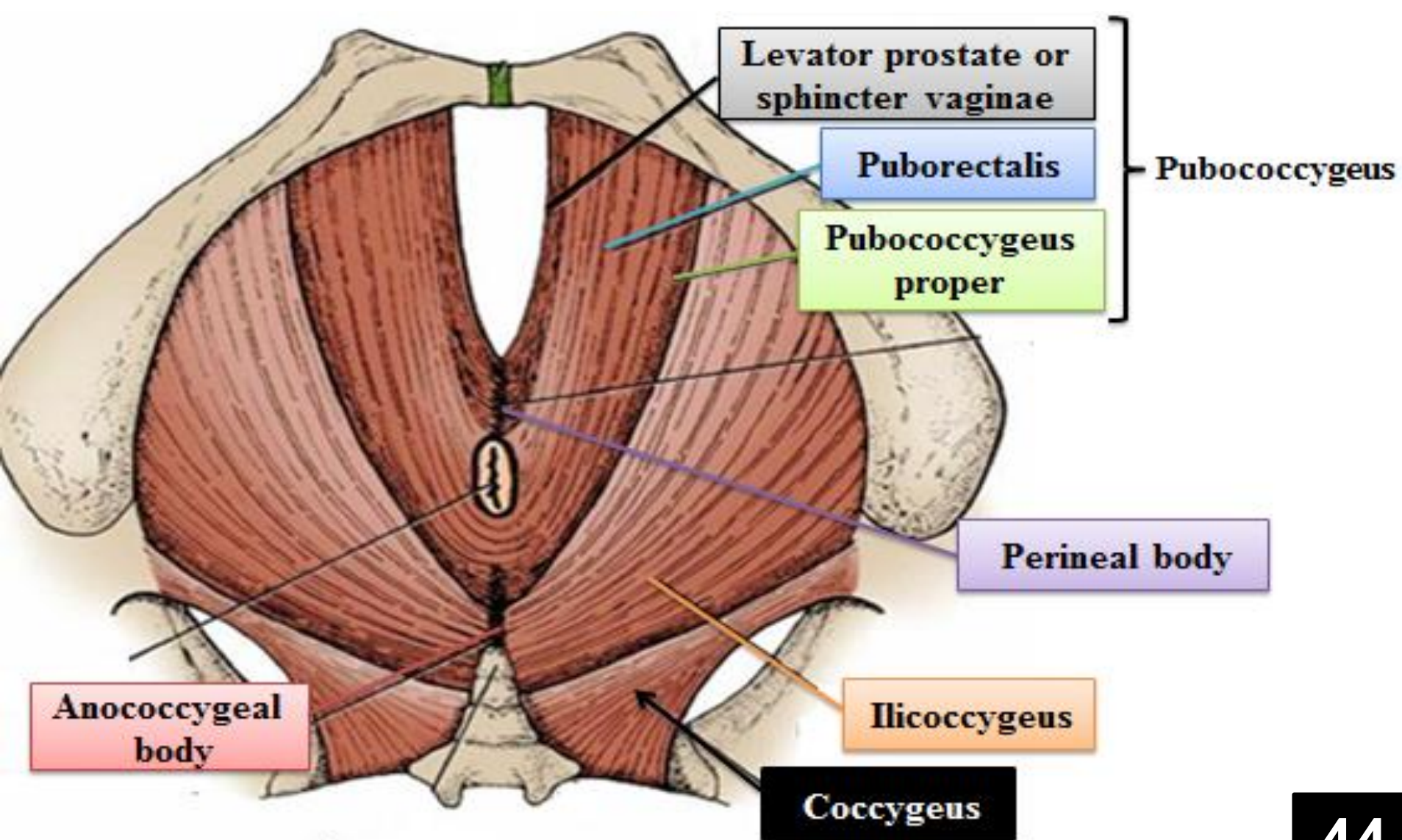
Coccygeus

Levator ani

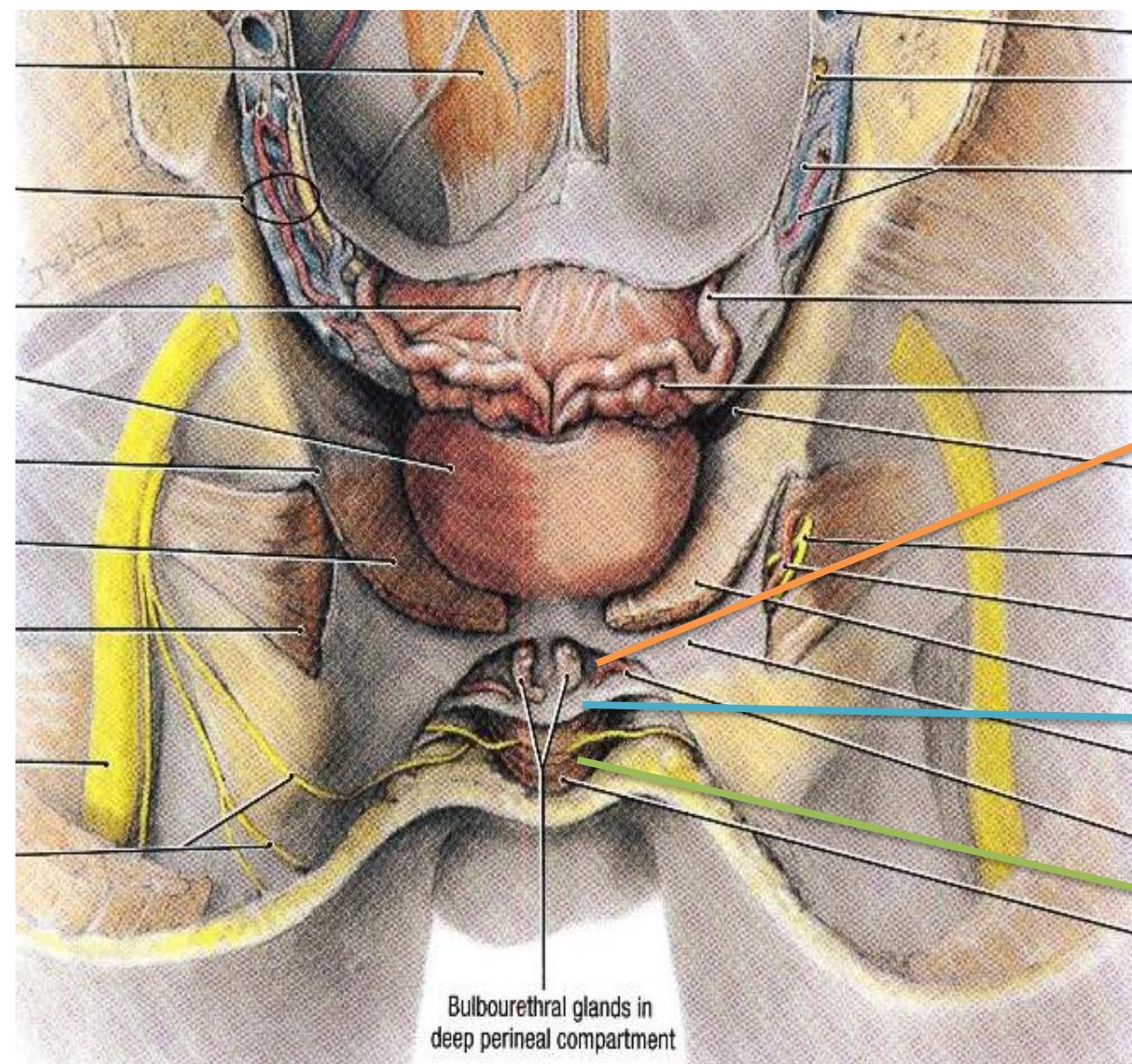
Superior and inferior fascia
of urogenital diaphragm

43

Muscular Wall of Pelvic Cavity



Muscles of the Floor of Pelvic Cavity Pelvic Diaphragm



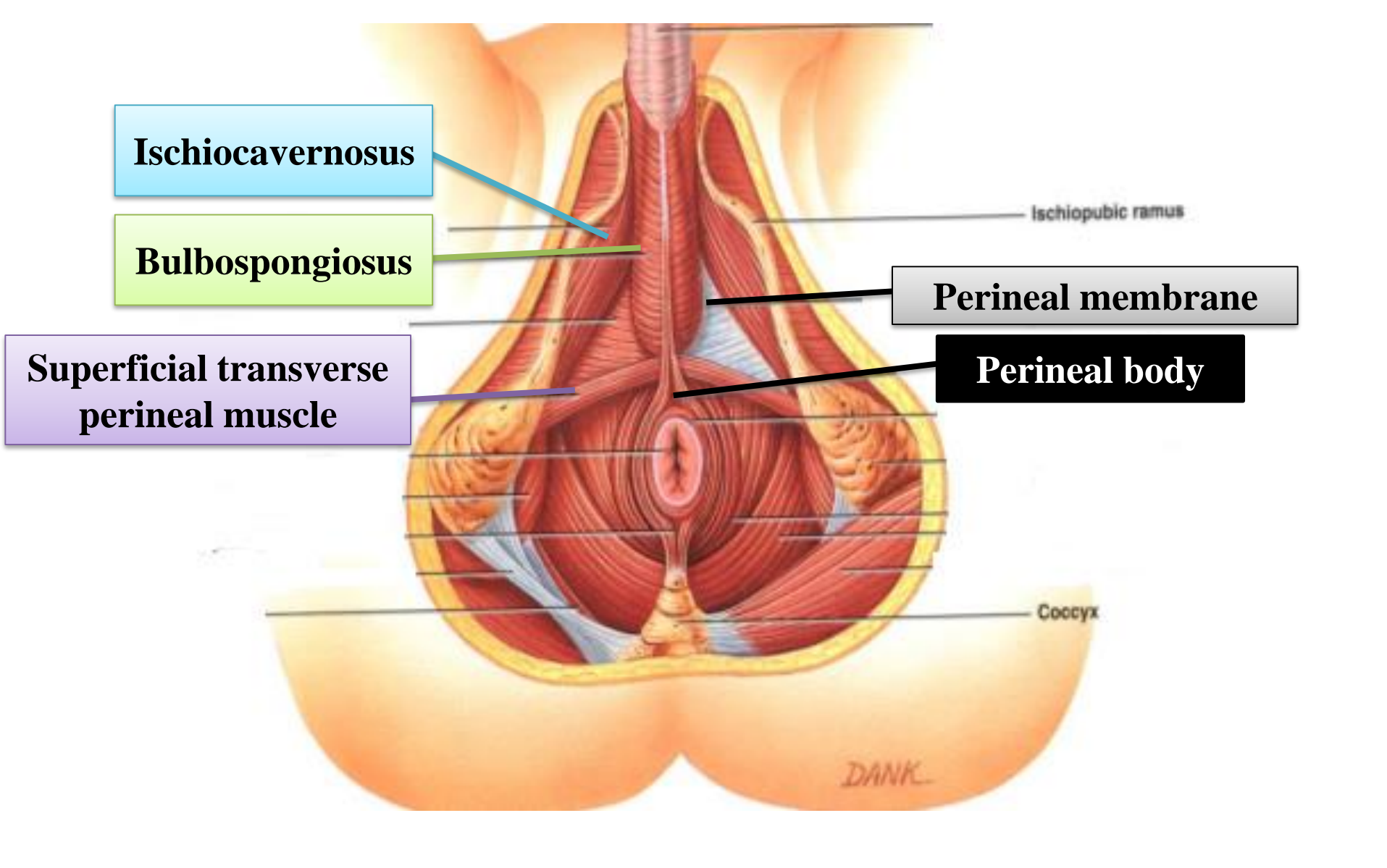
Bulbourethral glands in deep perineal compartment

Deep perineal pouch

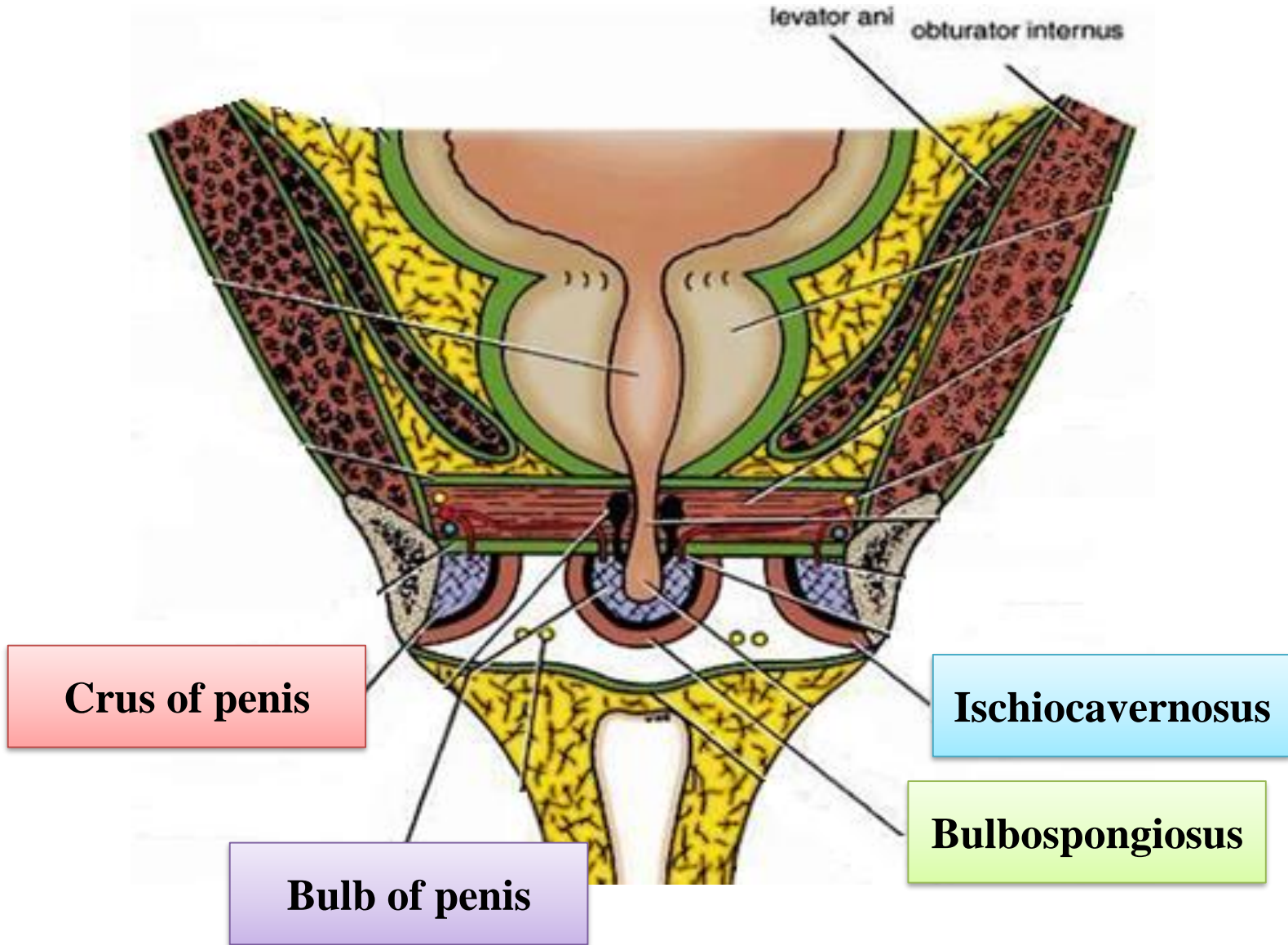
perineal membrane

Superficial perineal pouch

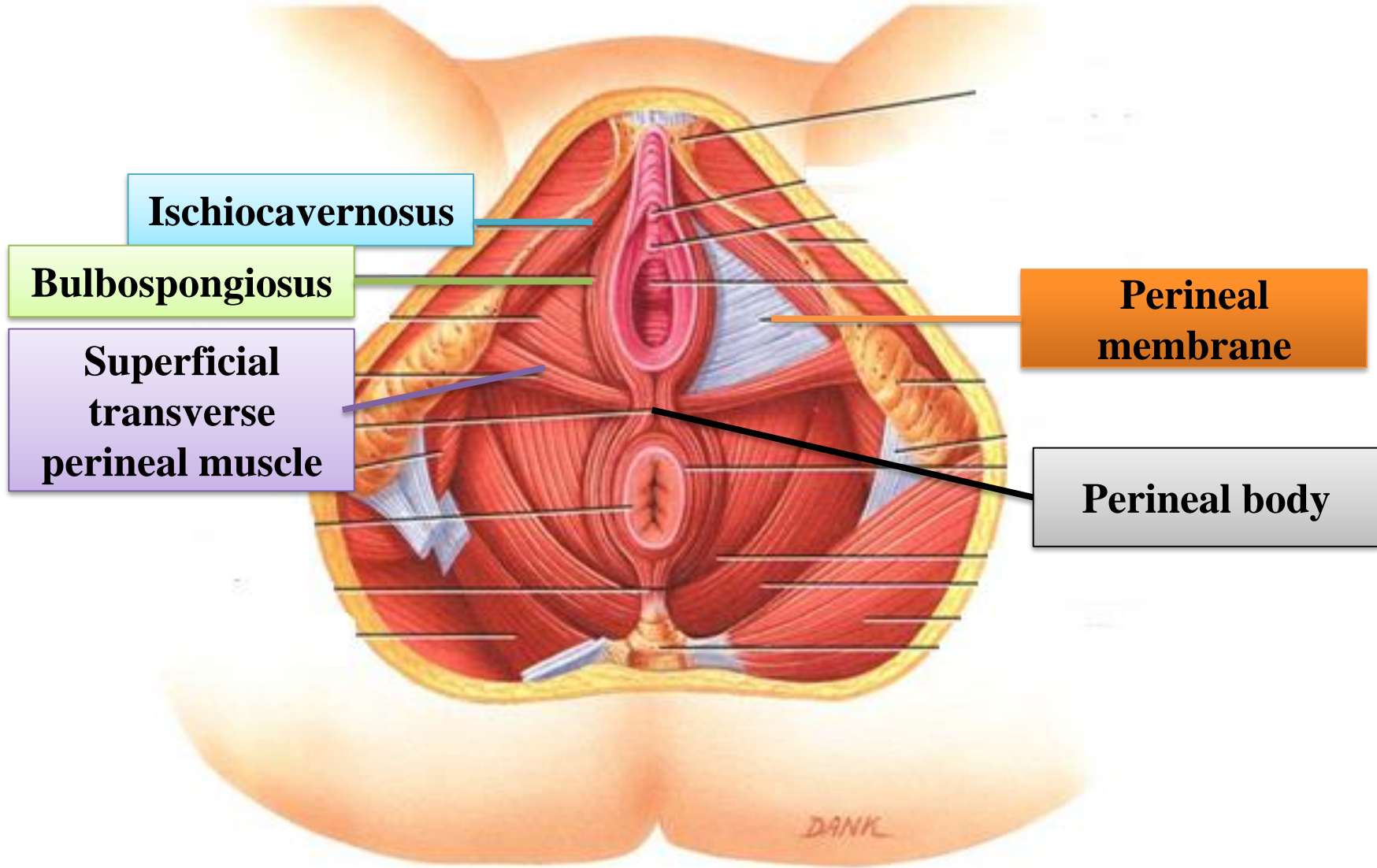
The superficial and deep perineal pouch



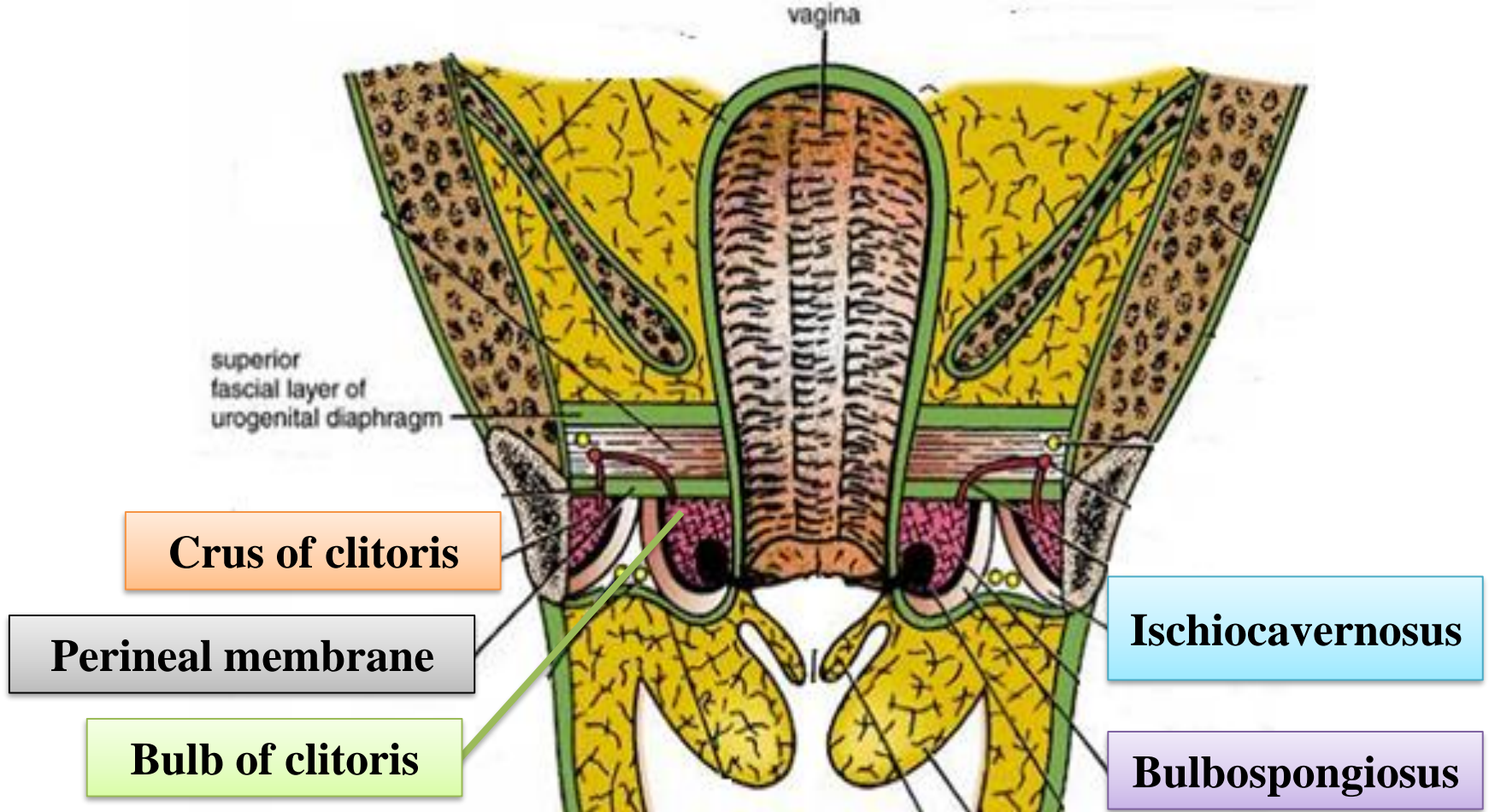
Superficial perineal pouch – Male



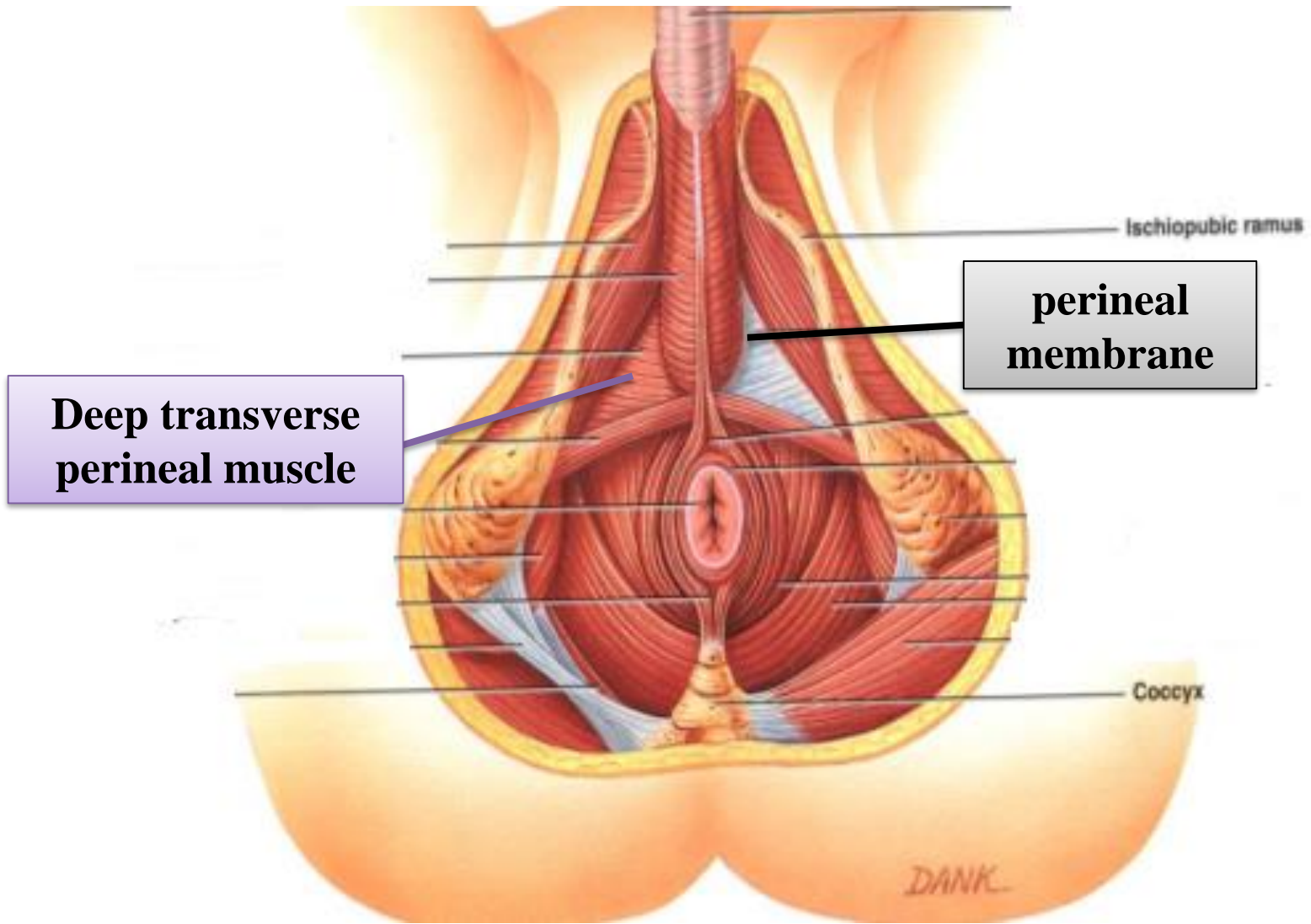
Superficial perineal pouch – Male



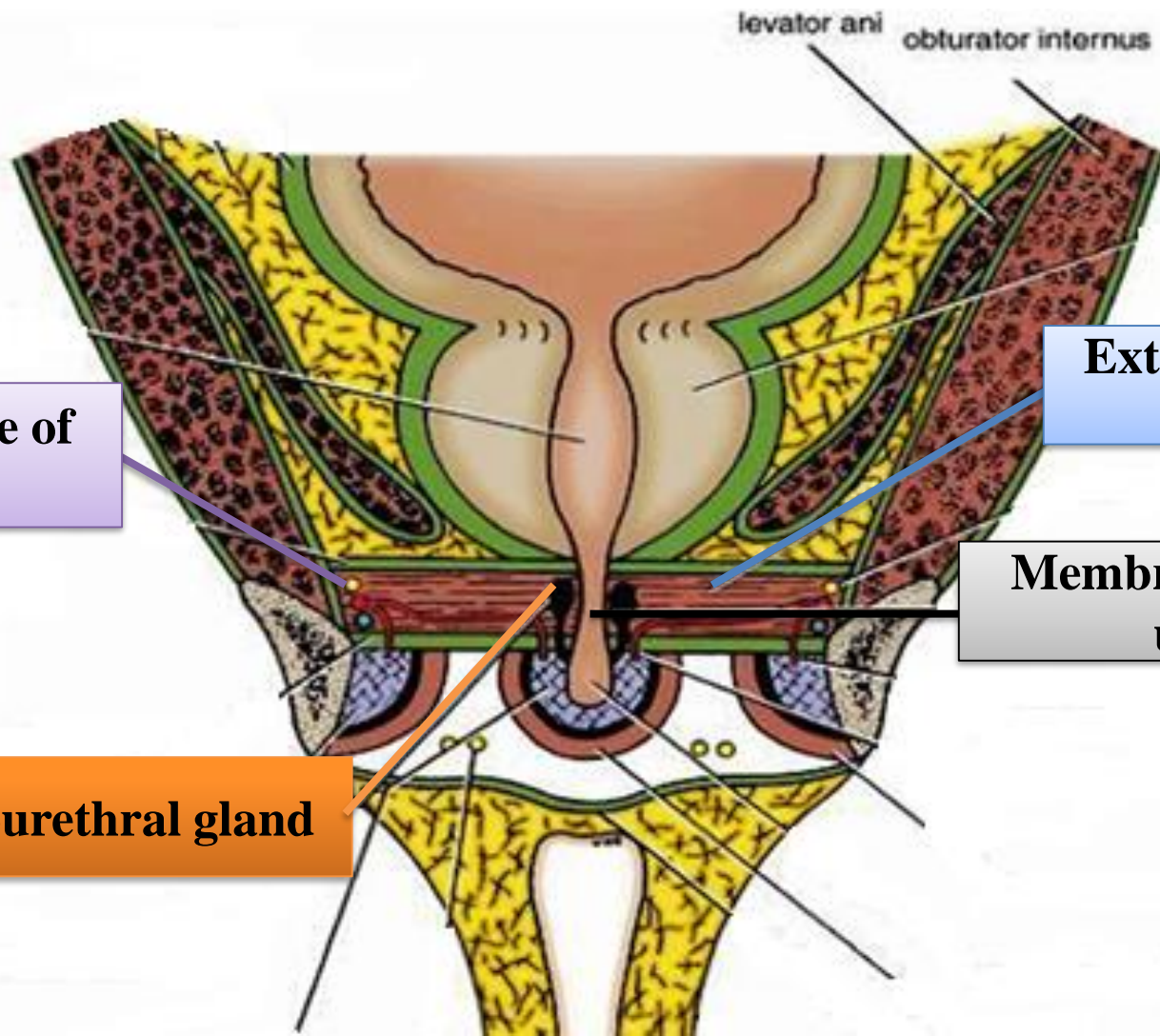
Superficial perineal pouch – Female



Superficial perineal pouch – Female



Deep perineal pouch – Male



levator ani obturator internus

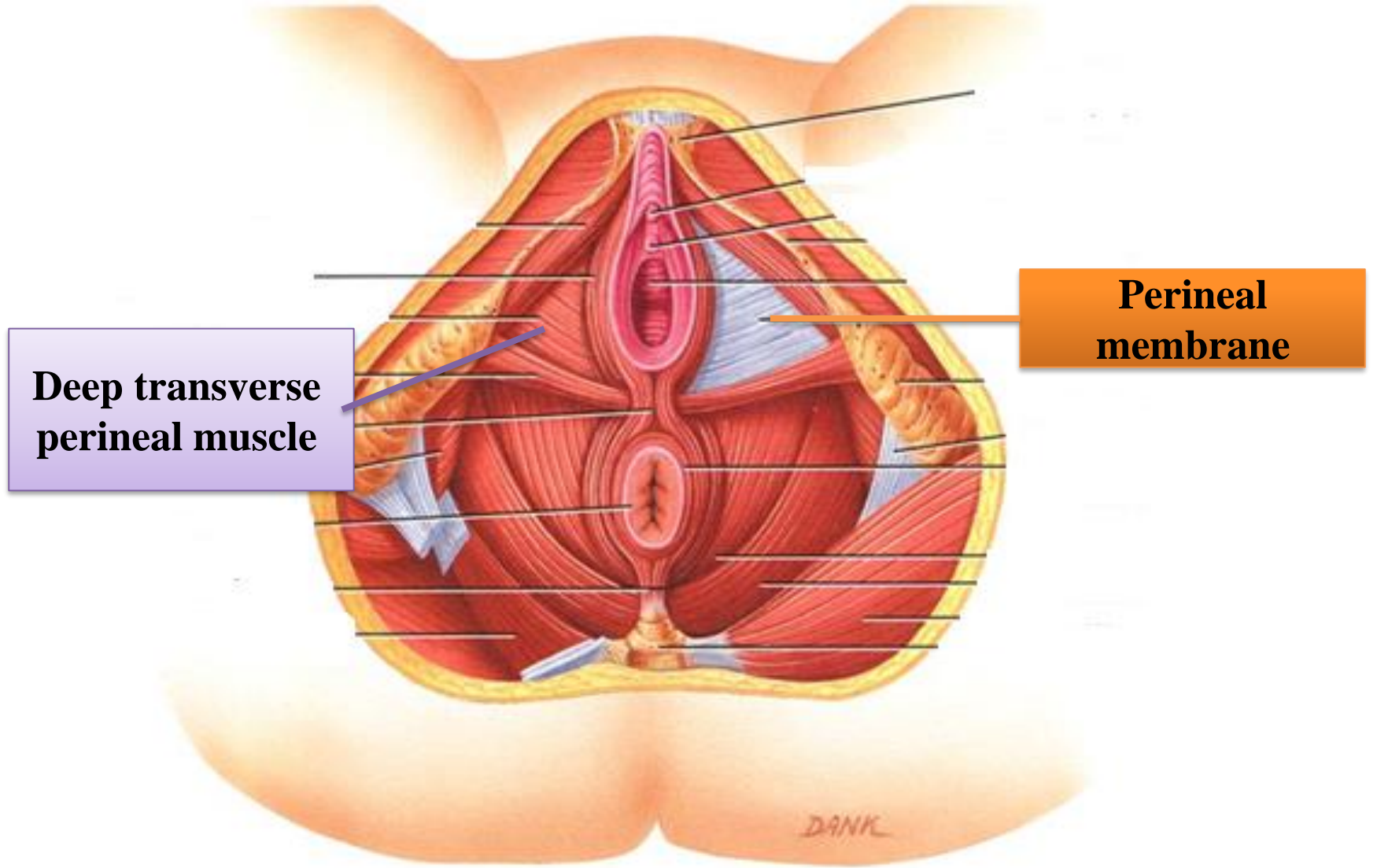
Dorsal nerve of penis

External urethral sphincter

Membranous part of urethra

Bulbourethral gland

Deep perineal pouch – Male



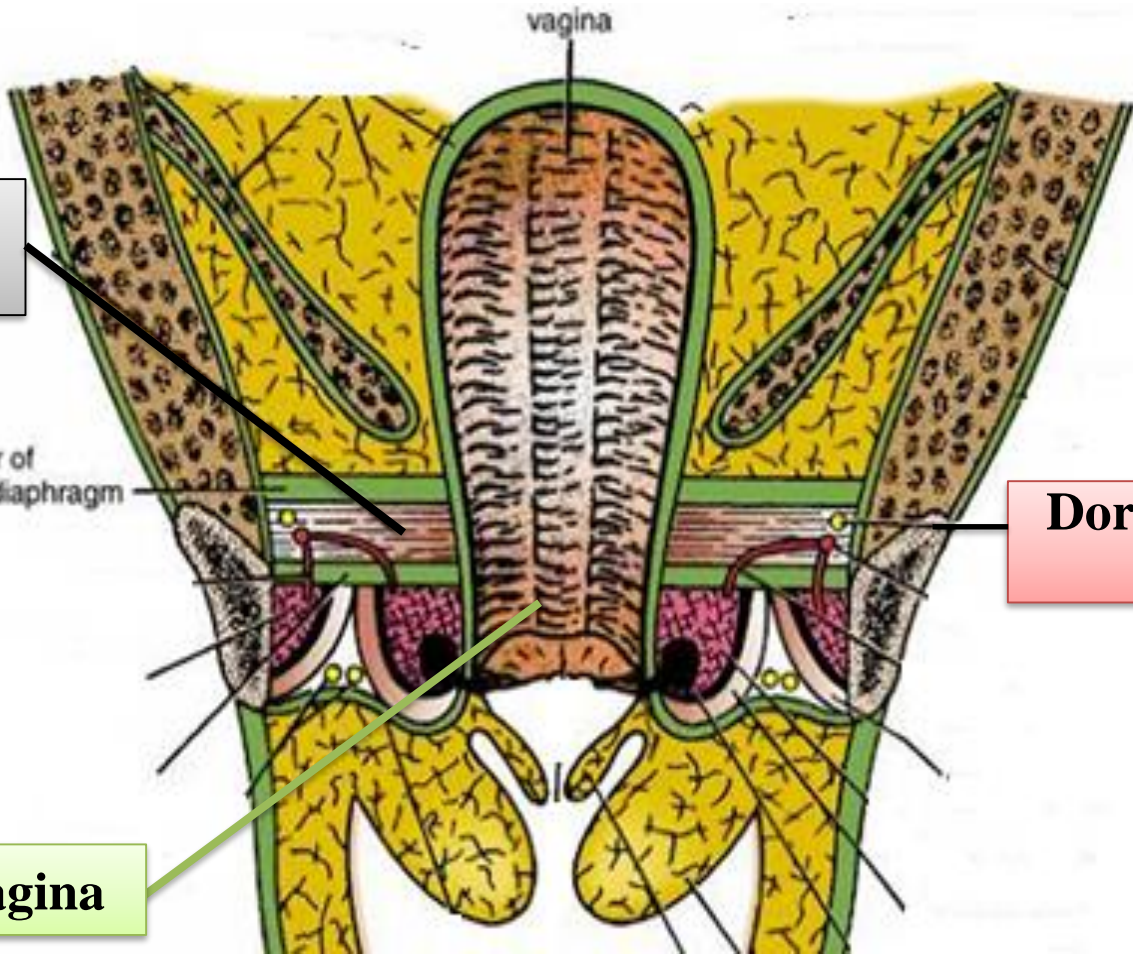
Deep perineal pouch – Female

External urethral sphincter

superior fascial layer of urogenital diaphragm

Dorsal nerve of clitoris

Vagina



Deep perineal pouch – Female