



لجنة الأطباء البشريين
رؤية تنير دروب تميزكم

Hope academic team

CS4-Med exam

CLINICAL LAB IV

past paper Soul batch

1) Which of the following is a case of infertility:

- A) They were married since 8 years and the husband works in Dubai, comes two weeks every year to his wife, they don't take contraception.
- B) They were married since 8 months.
- C) They were married since 3 years and had a child recently (3 months old baby).
- D) They were married two years from now, try to have a baby with no contraception and regular intercourses

Answer: D

2) Which of the following is a case of infertility:

- A) They are married since 5 years or so and have a child whom is 4 years old, trying to have a baby with no contraception.
- B) They were married since 8 years and the husband works in dubai, comes two weeks every year to his wife, they don't take contraception.
- C) They were married since 8 months.
- D) They were married since 3 years and had a child recently (3 months old baby).

Answer: A

3) If you wanted to tell your male patient that he has STD, you should start like:

- A) Are you currently in a relationship. **

4) A pregnant woman had her first day of the last menstrual cycle on April 20, 2018 expected baby birth is:

- A) January 20, 2019
- B) January 27, 2019
- C) April 20, 2019
- D) April 27, 2019

Answer: B

5) A patient with suspected UTI has which of the following test results:

- A) Nitrite and leukocyte esterase positive.
- B) Nitrite negative and leukocyte esterase positive.
- C) Nitrite positive and leukocyte esterase negative.

Answer: A

6) 18 YO female presents to you with dehydration in ER, her urine specific gravity is most likely to be:

- A) 1.25 **

7) To measure and estimate kidney function we calculate:

- A) Estimated GFR. **

8) We had an x-ray for a patient with right flank pain with history of stones, where do you look to search for any abnormalities:

- A) Along the course of right spinal processes.
- B) Along course of left spinous processes.

Answer: A

9) menstrual cycle defined as:

- A) Time between the first day of cycle and the first day of the next cycle. **

10) A patient came with urine analysis showing proteinuria and specific gravity of 1.025 , you would ask the patient to:

- A) Hydrate well and re do the test.
- B) Ask for culture.
- C) Obtain 24 h's urine.

11) Female with vaginal discharge which is pus charging and turbid , she may have:

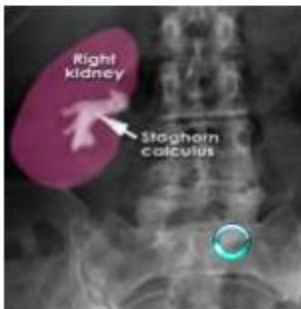
- A) STD
- B) UTI

Answer: A

Ihsan batch

1) Case to female pt. Came to hospital with spastic pain, On X-ray the kidney appeared like this pic, what is the diagnosis:

- A) Aluminium and Magnisium stones



2) lab results show: Creatinine =2, Urea=20, and no urine retention for a day, What is most likely the cause of this:

- A) Stone
- B) Hypotension
- C) Hemorrhage
- D) Dehydration

Answer: A

3) Which one is correct:

- A) PAS is diagnostic in cancer
- B) Urate increase with chronic renal failure

Answer: B

4) RBC + RBC cast + protein + turbidity are found in a urine sample. Your diagnosis:

- A) Glomerulonephritis
- B) Nephritic syndrome
- C) Urinary tract infection
- D) Renal stones

Answer: A

5) Which of the following is the correct answer:

- A) Bicarbonate reduced in chronic renal failure

6) not to ask about sexual history:

- A) Are you in relationship?
- B) Is it sexual relationship?
- C) Have you ever had STD?
- D) Are you homosexual?

Answer: D

7) In female pt, what is the most important pathological finding:

- A) Menstrual periods 27 days in length
- B) Menstrual bleeding 6 days in length
- C) Menarche after the age of 16

Answer: C

8) female pt, what is the most important pathological finding:

A) Heavy bleeding one year after menopause

9) Pt. suffers from sharp sever intermittent pain at the side of abdomen, it seems to have stones stretching the ureter , another most related findings:

A) Fever

B) Hematuria

C) Urgency

D) Frequency

Answer: B

10) A pt. with hesitancy and urgency the most likely cause is:

A) UTI

11) Benign tumor in the Breast differ from the malignant one by:

A) Asymmetrical change

B) Symmetrical change

C) Change in shape

D) Pull nipple to side

Answer: B

12) the most true statement you should know about breast from the Following:

A) Benign breast adenoma is much common than malignant

13) Case of a pt. With Proteinuria, he will come to the clinic suffering from:

A) No symptoms (Asymptomatic pt.)

14) pt. with chronic kidney disease, one of most important Q. you should ask about his family history is:

A) Hypertension

15) Pt with urinary leakage on coughing, sneezing, it is embarrassing to her....
your diagnosis is:

- A) Urge incontinence
- B) Stress incontinence
- C) Mixed

Answer: B

Healing Batch

1) Menarche is:

- A) Age of first period

2) 22 old female came to clinic with dysuria , frequency of urination and UTI ,
when doing urine analysis , she'll have :-

- A) Nitrite positive , leukocyte esterase negative .
- B) Nitrite negative ,leukocyte esterase positive .
- C) Nitrate positive , leukocyte esterase positive

Answer: C

3) 'Case' with fever, vomiting, nausea.....:

- A) Pyelonephritis

4) We use catheter in all , except :

- A) UTI treatment

5) Polycystic kidney disease is related to:

- A) Hypertension

6) which of the following radiates to groin , scrotum:

- A) Unilateral kidney stones

7) PSA=5 , in 60 -year old:

- A) Low
- B) Intermediate increase, biopsy not required
- C) Intermediate and require biopsy
- D) High and require biopsy

Answer: B

8) Patient with chronic kidney failure, which of the following tests you'll do to estimate the kidney function:

- A) Estimated GFR
- B) Creatinine clearance

Answer: A

9) Acute kidney disease 'pt. In certain age' :

- A) Prerenal
- B) Intrarenal
- C) Postrenal
- D) All of the above

Answer: D

10) Male patient with PSA=11.1:

- A) Take prostate biopsy

11) Woman with dehydration because she works in summer. Her specific gravity is:

- B) 1.030

12) All are related to UTI , except:

A) having one kidney

13) Not related to UTI:

A) Nausea and vomiting

PULSE BATCH

1) Which of the following might lead to embarrassment:

A) A physical examination of a private body area.

2) Which of the following is correct regarding prostate cancer:

A) Symptoms similar to BPH when advanced

3) Causative agent of UTI is:

A) E.Coli

4) A case of a patient, he has fever, dysuria, nausea and abdominal pain radiating to the back:

A) Pyelonephritis

5) Which of the following is a correct management of kidney stones:

A) Watch and wait

B) Analgesia

C) Shock wave lithotripsy

D) Surgery

E) All of the above

Answer: E

6) Most common type of stone is:

A) Calcium oxalate

7) Painful red breast lump:

A) Mastitis Abscess

8) Un painful breast lump in a 20 year old female:

A) Fibro adenoma

9) Which of the following is not an important question in menstrual systems review:

A) When did you get married?

10) All of the following is part of the menstrual system review except:

A) Dysuria

11) Menorrhagia is:

A) More than 80mls blood loss per cycle

12) Which of the following is a no pathology cause of menorrhagia:

A) Dysfunctional uterine bleeding

13) What is the meaning of primary causes of amenorrhea:

A) Never had menstrual cycle.

14) Which of the following is correct:

A) Peripheral zone 70-80% prostate cancer.

15) Which of the following is correct:

A) Transition zone benign prostatic hyperplasia.

16) Best method of breast examination:

A) Concentric circles

17) All of the following is correct regarding breast examination:

A) Ask patient to lock hands together.

18) Which of the following describes a breast cancer lump:

A) Discharge blood.

19) In per vaginal examination we place a finger either side of the cervix, push it from side to side this is called:

A) Cervical excitation

20) Which of the following is wrong:

A) In triple assessment we take ultrasound and mammography if patient is younger than 35

21) Which of the following is correct:

A) Make sure to have a close contact between baby and mother.

22) All of the following is correct regarding breast examination except:

A) Don't give patient privacy to change his/her clothes.