

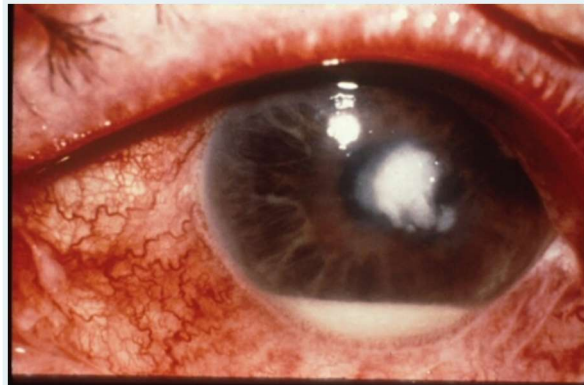
ack

 Computer Mo

End Rotation Mini-OSCE

Section

3

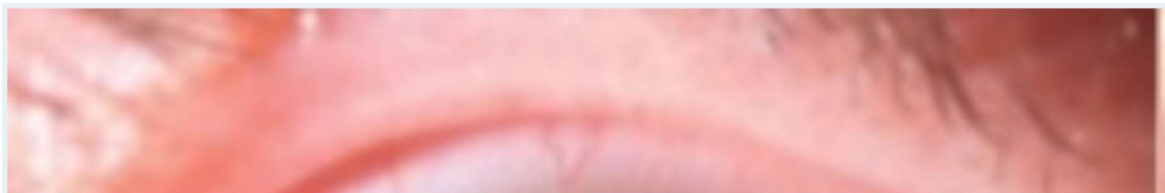

The diagnosis of the disease shown in this picture?
(2 Points)

- ☐ retinal detachment
- ☐ keratitis
- ☐ conjunctivitis
- ☐ hyphema
- ☐ iritis

4

Q4: A 7 y old boy presented with pain and loss of vision after being hit by a ball on his right eye. Examination showed visual acuity of CF at 2 m, and this is his anterior segment picture. Your diagnosis is:
(2 Points)

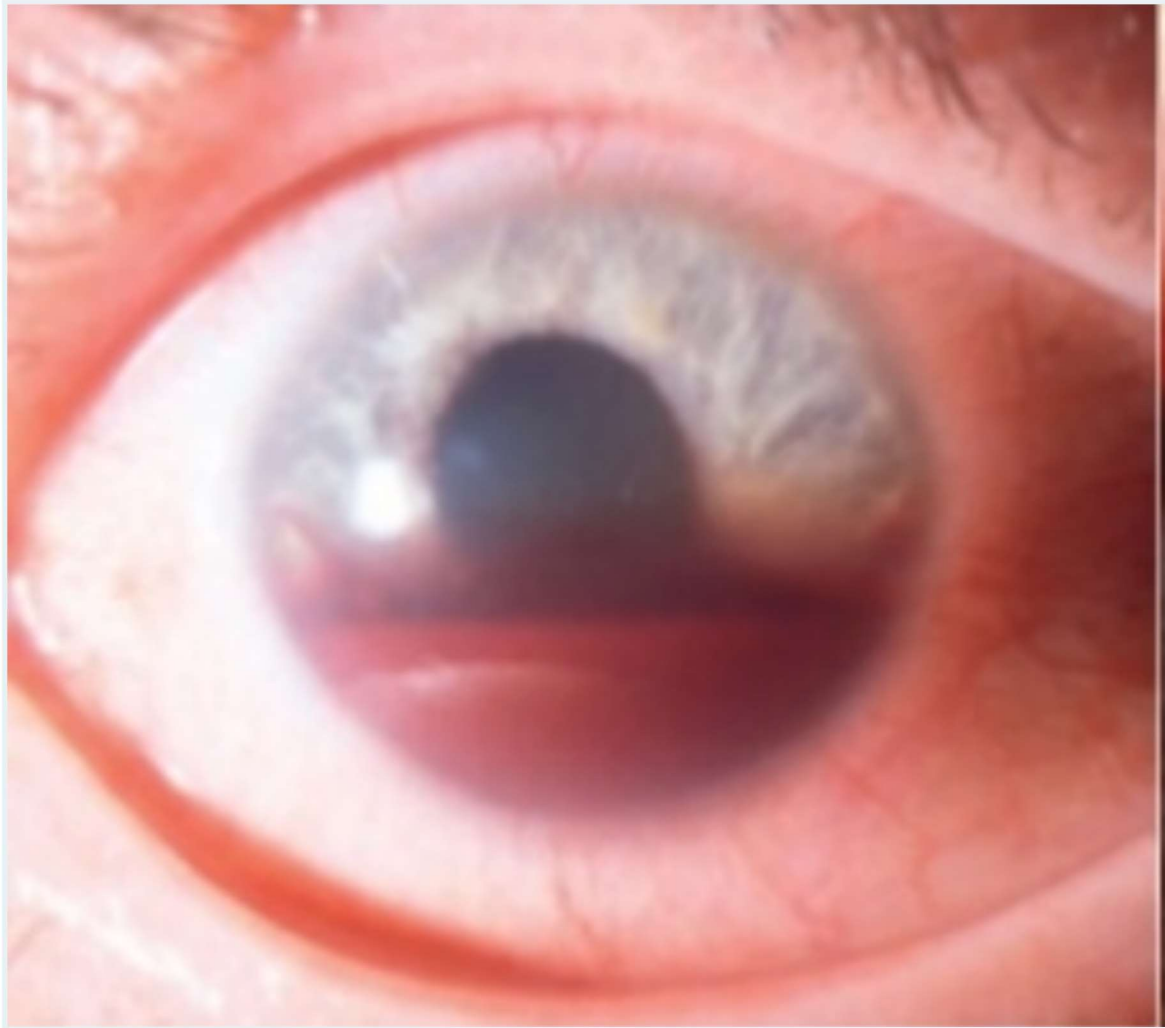


ack

 Computer Mo

4

Q4: A 7 y old boy presented with pain and loss of vision after being hit by a ball on his right eye. Examination showed visual acuity of CF at 2 m, and this is his anterior segment picture. Your diagnosis is:
(2 Points)



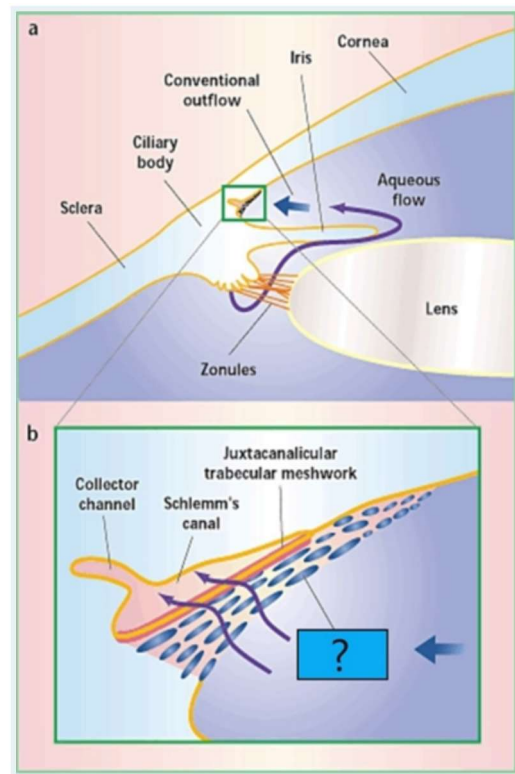
- ☐ cataract
- ☐ subconjunctival hemorrhage
- ☐ rupture of globe
- ☐ hyphema
- ☐ keratitis

ack

Computer

Mo

6




Q1: The structure marked by question mark (?) is:
(2 Points)

- ☐ canal of schlem
- ☐ trabecular meshwork
- ☐ sclera
- ☐ iris
- ☐ cornea

7

This device is used to?
(2 Points)




ack

 Computer Mo

7


This device is used to?
(2 Points)



- ☐ Inspection of the iridocorneal angle
- ☐ Measure the central corneal thickness
- ☐ Measure the density of cataract
- ☐ Measure the IOP
- ☐ Measure the cup/disc ratio

8

What is lens pathology seen in this picture:
(2 Points)



ack

 Computer Mo

- ☐ Keratoconus
- ☐ Diabetic retinopathy
- ☐ Senile cataract
- ☐ Central retinal artery occlusion
- ☐ Open Angle Glaucoma

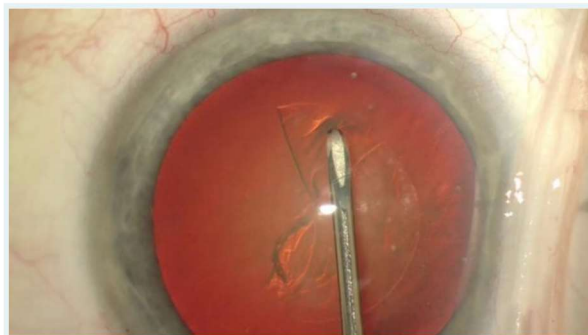
9

Causes of presenile cataract. One is not true?
(2 Points)

- ☐ Can occur in children
- ☐ It is a major cause of cataract in the elderly
- ☐ Occurs in patients taking steroids
- ☐ Occur in young individuals
- ☐ Trauma is a recognized cause

10

This step in surgery is?
(2 Points)



- ☐ Can-opener capsulotomy in ECCE
- ☐ Part of intravitreal injection of ant-VEGF

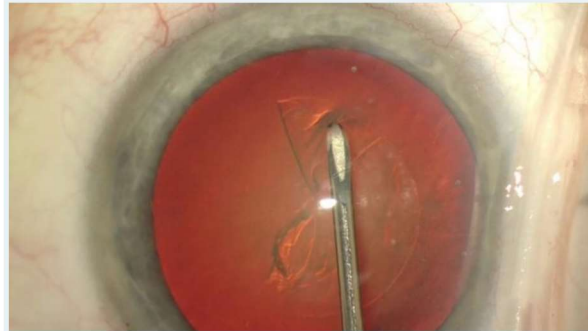
ack

 Computer Mo

- ☐ Trauma is a recognized cause

10

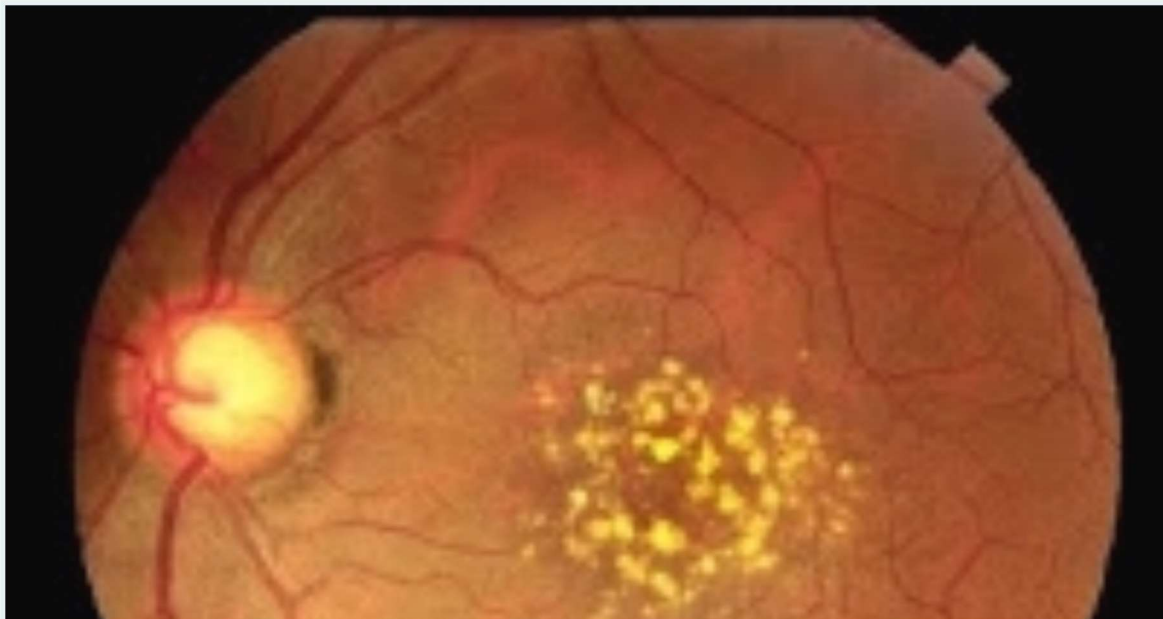This step in surgery is?
(2 Points)



- ☐ Can-opener capsulotomy in ECCE
- ☐ Part of intravitreal injection of anti-VEGF
- ☐ Capsulorrhexis step in phacoemulsification
- ☐ Implantation of IOL in phacoemulsification
- ☐ Injection of silicone oil in vitrectomy

11

Regarding the white dots on the picture, which one is true?
(2 Points)



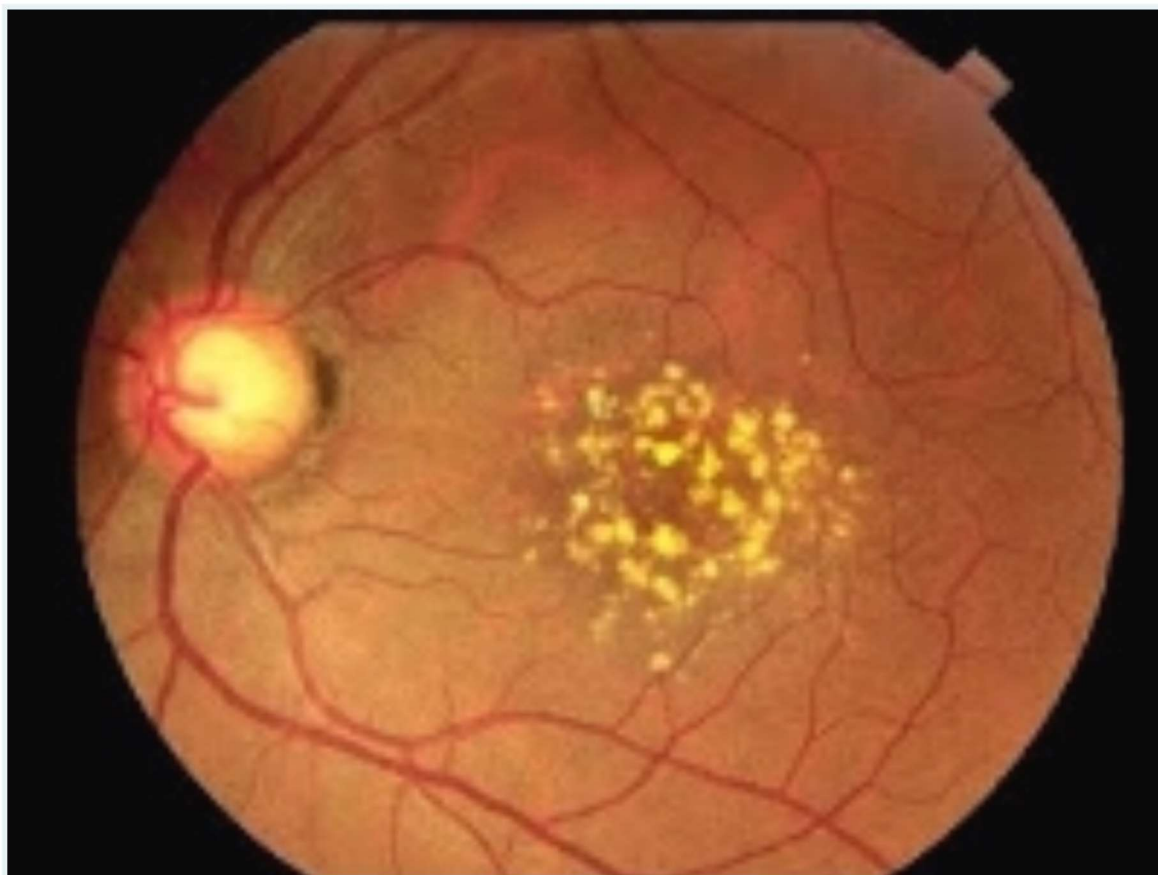ack

 Computer Mo

- ☐ Can-opener capsulotomy in ECCE
- ☐ Part of intravitreal injection of anti-VEGF
- ☐ Capsulorrhexis step in phacoemulsification
- ☐ Implantation of IOL in phacoemulsification
- ☐ Injection of silicone oil in vitrectomy

11

Regarding the white dots on the picture, which one is true?
(2 Points)



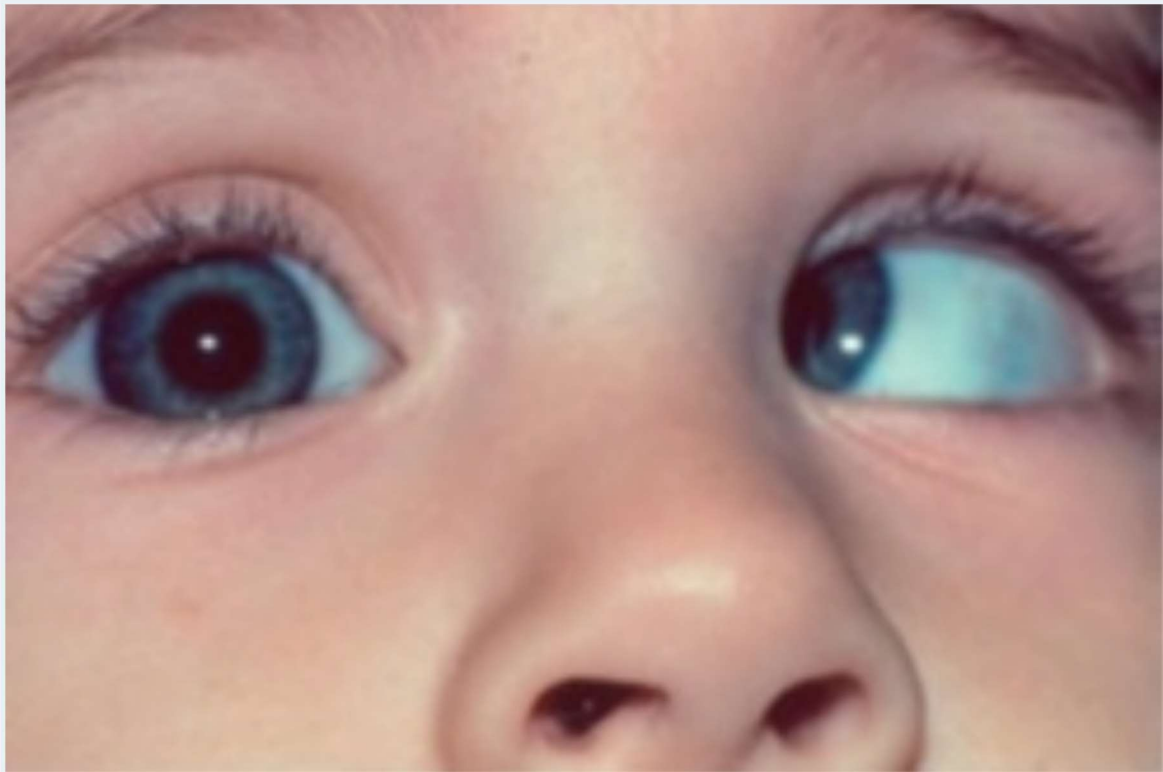- ☐ Anti-VEGF plays an important role in the treatment
- ☐ Examination of other family members is important
- ☐ Usually carries good prognosis
- ☐ Treatment include good control of blood sugar

ack

 Computer Mo

12

This 8 month old baby was brought by his mother because of inward deviation of his left eye. Your diagnosis is:
(2 Points)



- ☐ Retinal detachment
- ☐ cavernous sinus thrombosis
- ☐ infantile esotropia
- ☐ Optic atrophy
- ☐ third nerve palsy

13

The pathology shown in this image is:
(2 Points)

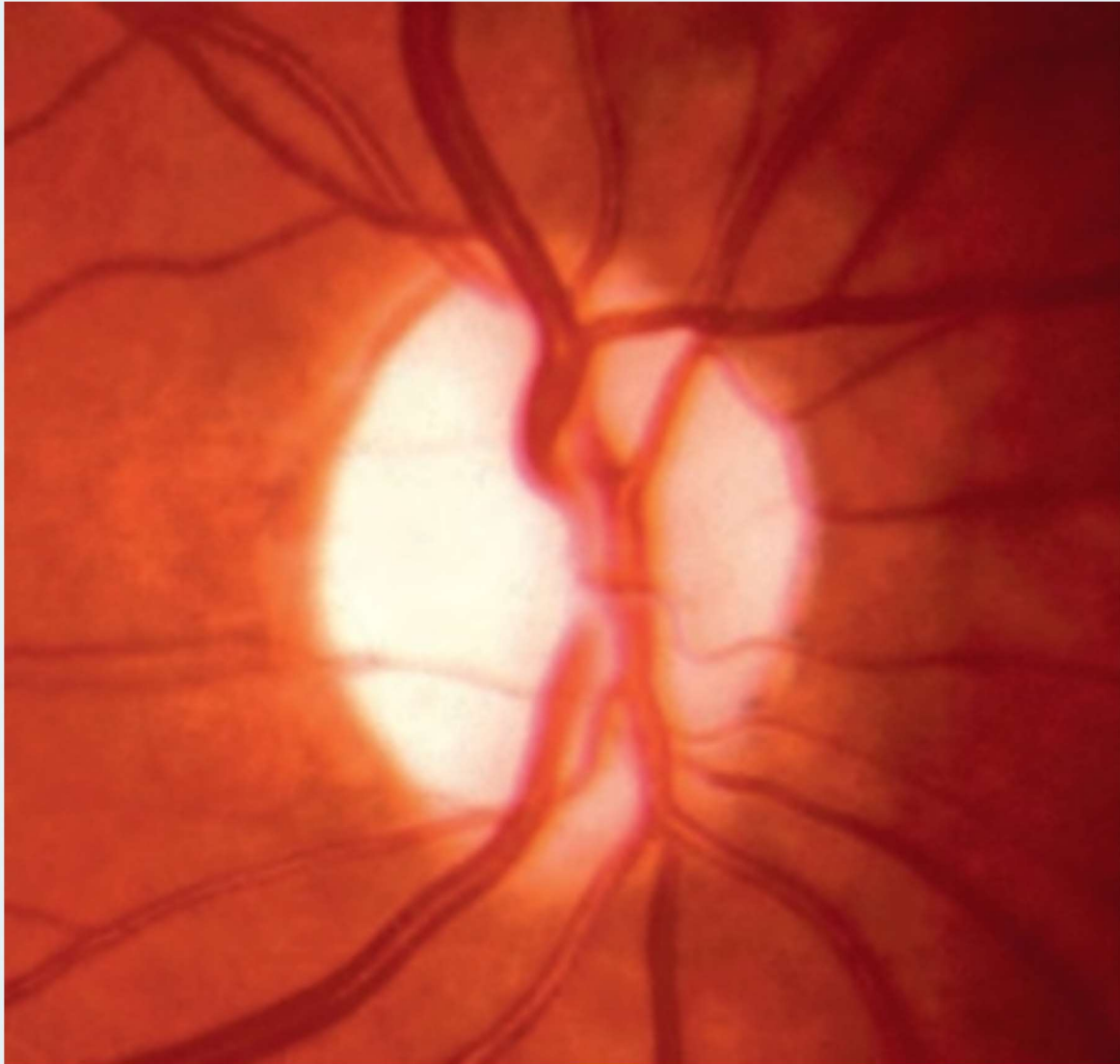


ack

 Computer Mo

13

The pathology shown in this image is:
(2 Points)

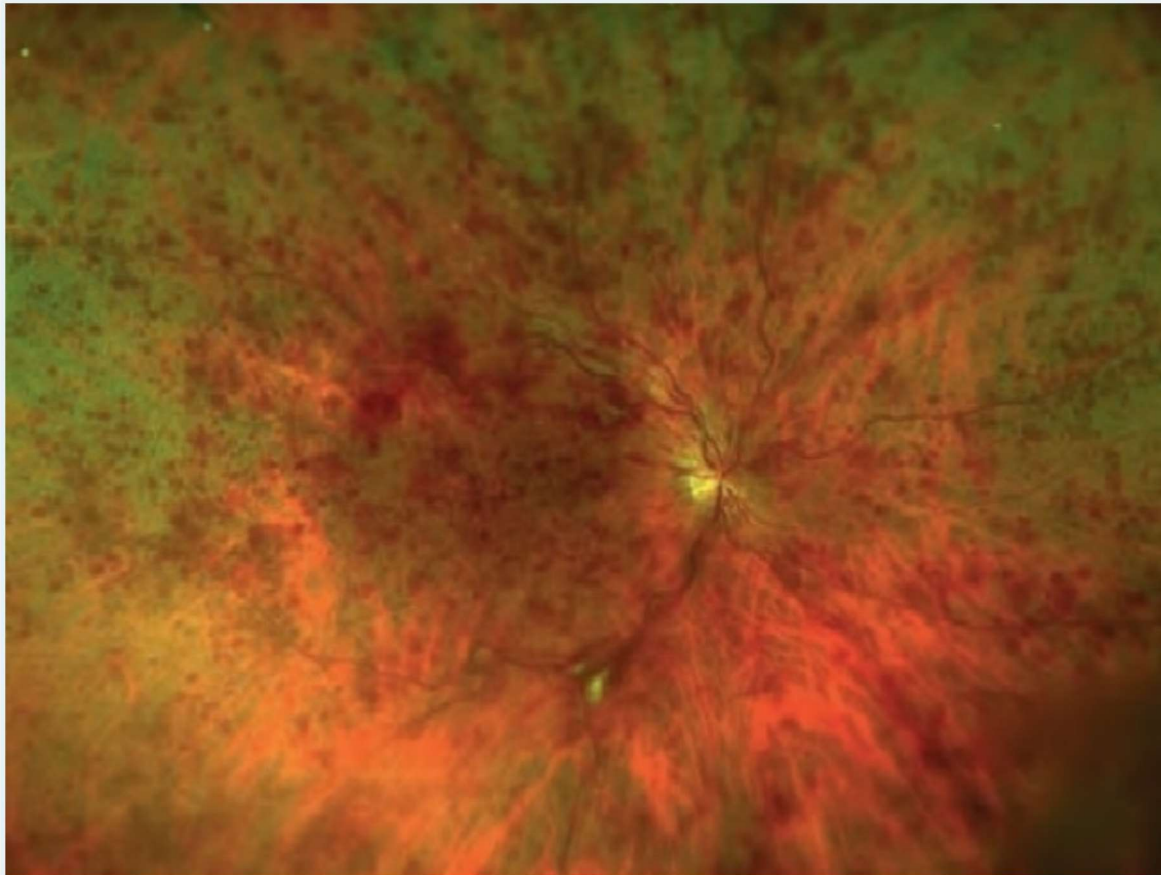


- ☐ NVD
- ☐ papilledema
- ☐ optic neuritis
- ☐ optic nerve head drusen
- ☐ optic atrophy

ack

 Computer Mo

A 65 y old man presented with sudden loss of vision in his right eye. Examination showed visual acuity of HM, with positive RAPD. and this is his fundus picture. Your diagnosis is:
(2 Points)



- ☐ central retinal artery occlusion
- ☐ ischemic central retinal vein occlusion
- ☐ non-ischemic central retinal vein occlusion
- ☐ proliferative diabetic retinopathy
- ☐ retinal detachment

15

A 49 y old man presented with sudden loss of vision in his right eye. He is myope. Examination showed visual acuity of HM, and this is his fundus picture. Your diagnosis is:
(2 Points)

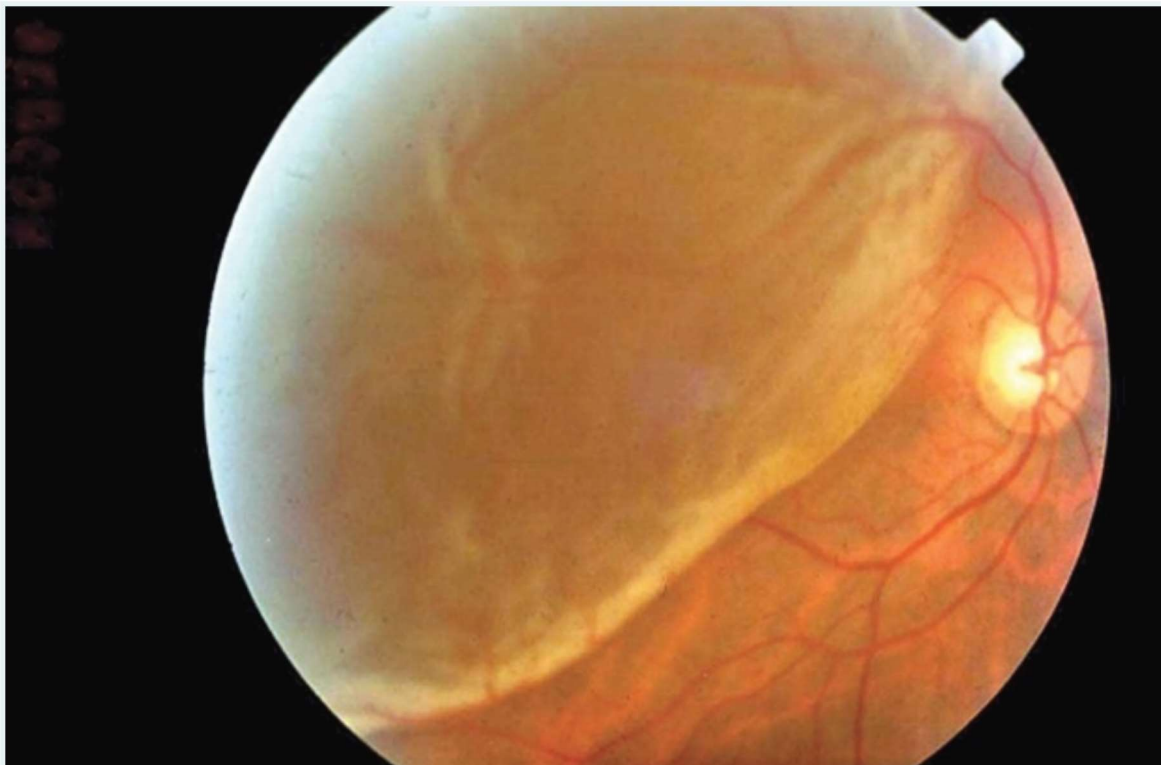
ack

 Computer Mo

- ☐ central retinal artery occlusion
- ☐ ischemic central retinal vein occlusion
- ☐ non-ischemic central retinal vein occlusion
- ☐ proliferative diabetic retinopathy
- ☐ retinal detachment

15

A 49 y old man presented with sudden loss of vision in his right eye. He is myope. Examination showed visual acuity of HM, and this is his fundus picture. Your diagnosis is:
(2 Points)



- ☐ tractional retinal detachment
- ☐ choroidal detachment
- ☐ retinoschisis

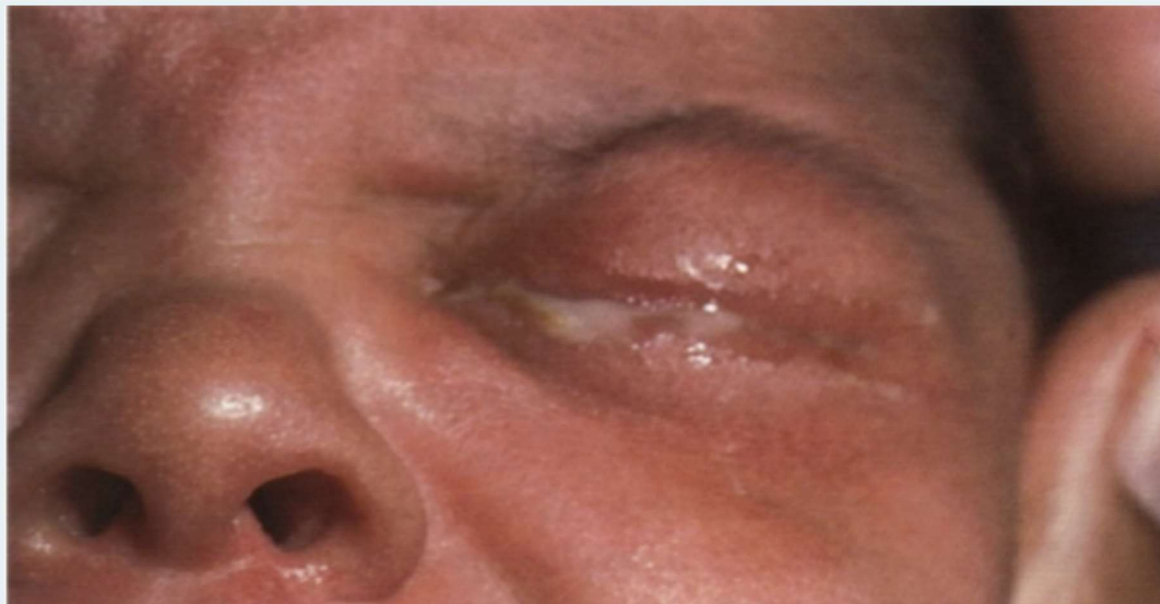ack

 Computer Mo

- ☐ tractional retinal detachment
- ☐ choroidal detachment
- ☐ retinoschisis
- ☐ exudative retinal detachment
- ☐ rhegmatogenous retinal detachment

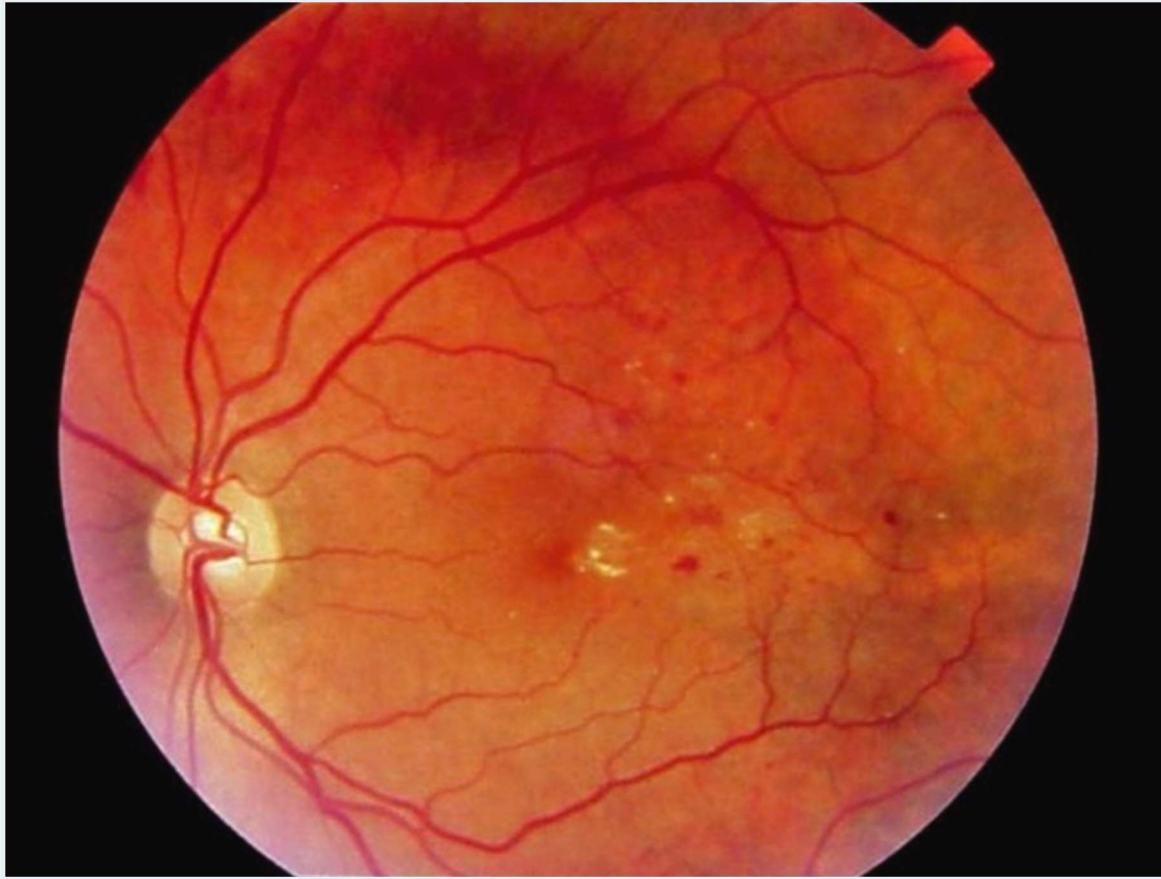
16

This is a newly born infant, presented with this picture 5 days after delivery.
This image shows:
(2 Points)



- ☐ ophthalmia neonatorum
- ☐ endophthalmitis
- ☐ esotropia

ack

 Computer Mo

- ☐ vitreous hemorrhage
- ☐ drusen
- ☐ diabetic macular edema
- ☐ tractional retinal detachment
- ☐ retinal vein occlusion

19

Age-related macular degeneration. which ONE is True?
(2 Points)

- ☐ Intravitreal injection of Anti-VEGF is a treatment option of wet type
- ☐ Drusen are the hallmark of the wet type
- ☐ Usually carries a good prognosis