

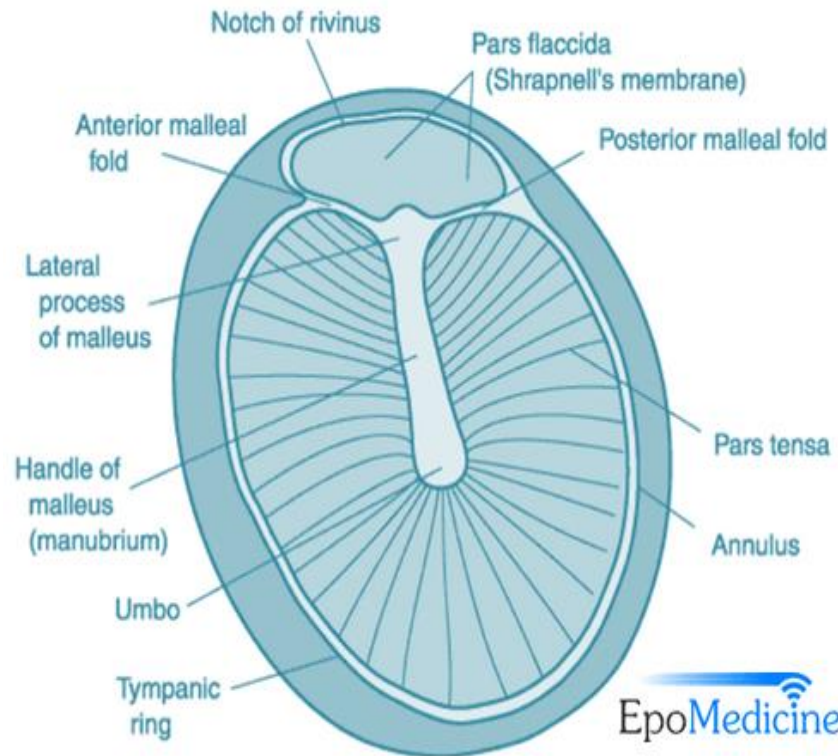
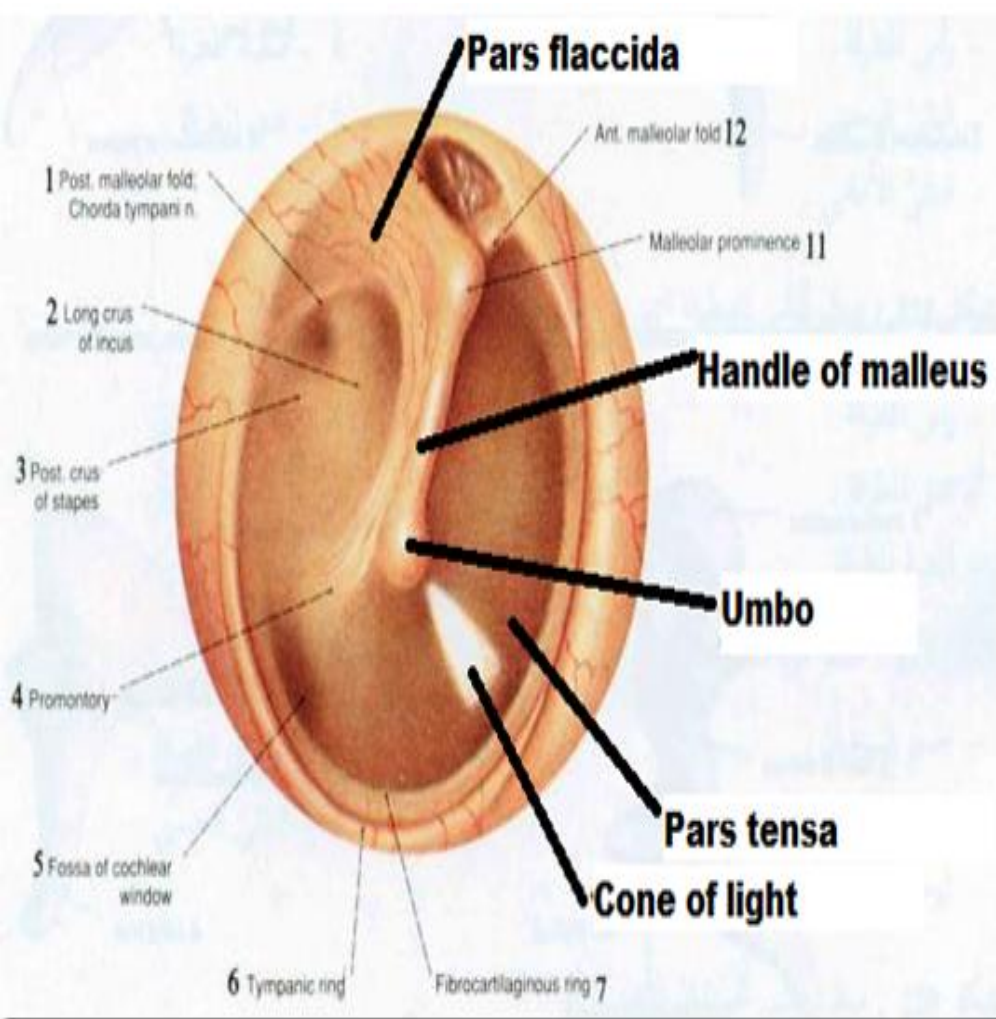
ENT past year questions.

Thanks to “Ethar Hazaimah” for her efforts to arrange the slides according to the topic



Ear

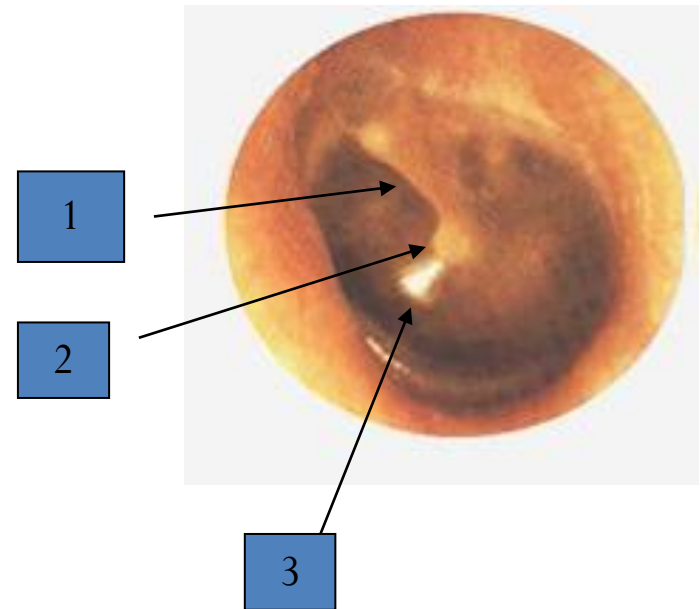
Tympanic membrane



Question#1

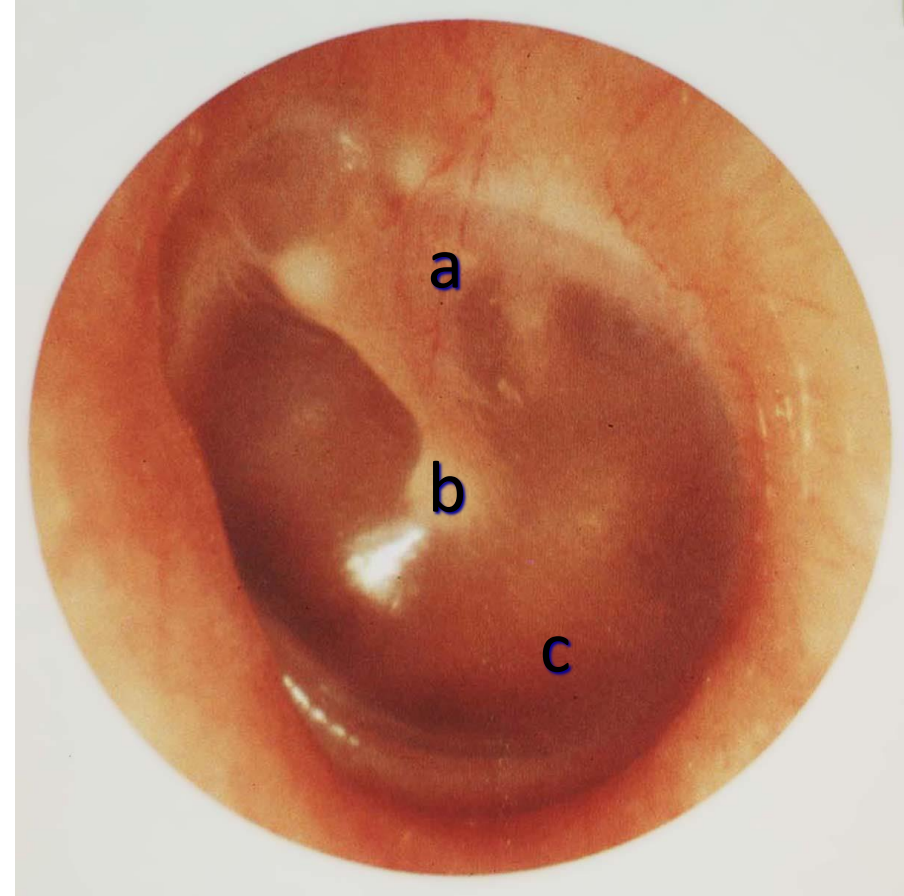
Name the structures :

- 1) Handle of malleus
- 2) Umbo
- 3) Cone of light



Question 2

- A) What is (a)? Pars flaccida
- B) What is (b)? Handle of Malleus (Umbo)
- C) What is (c)? Pars tensa



- Mention the names of the 3 ossicles found in the middle ear.

Uncus, malleus, stapes

Otitis Externa

Otitis Externa

1. Impacted wax

2. Bacterial :

-Acute Otitis Externa (Furunculosis , staph aureus)/severe pain

-Malignant otitis externa (pseudomonas aeruginosa)

3. Fungal : Otomycosis /painless,itchy

*Aspergellosis—black dots

* candidiasis—white

4. Viral

* h.simplex – vesicles in TM (Myringitis)

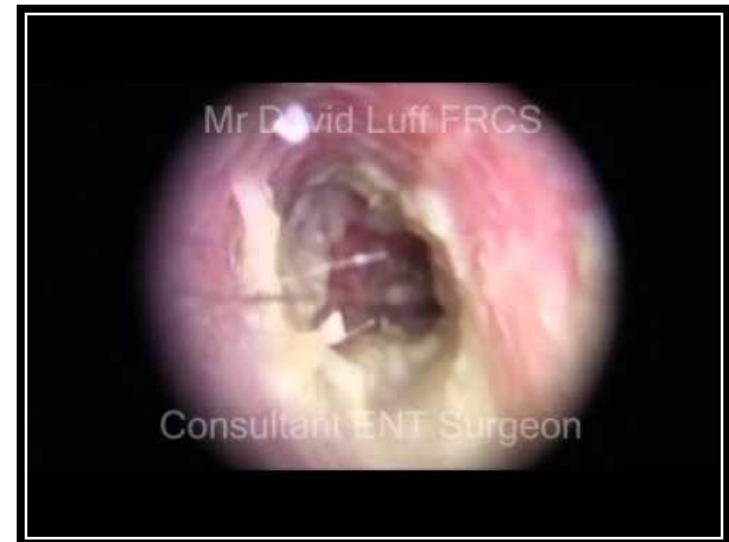
* H.zoster –Ramsay Haunt syndrome (vesicles , ear pain , facial palsy)

5. Eczematous

Q1: history of a 20 year old male with 3 days history of otorrhea, ear pain.

- **What is your diagnosis?** Acute Otitis externa
- **What is the most common microorganism?**
staph. aureus
- **Give one risk factor?**
Swimming/DM/Immunocompromised
- **2 treatment?**
 - aural toilet
 - local antibiotics
 - analgesics

Aural toilet : an outpatient procedure where the ENT surgeon clears wax, debris or foreign bodies from the ear canal.



Q2. a case of malignant (necrotizing)
otitis externa (the dx is written in the
question already)

-what's the micro organism causing this ?

pseudomonas aeruginosa

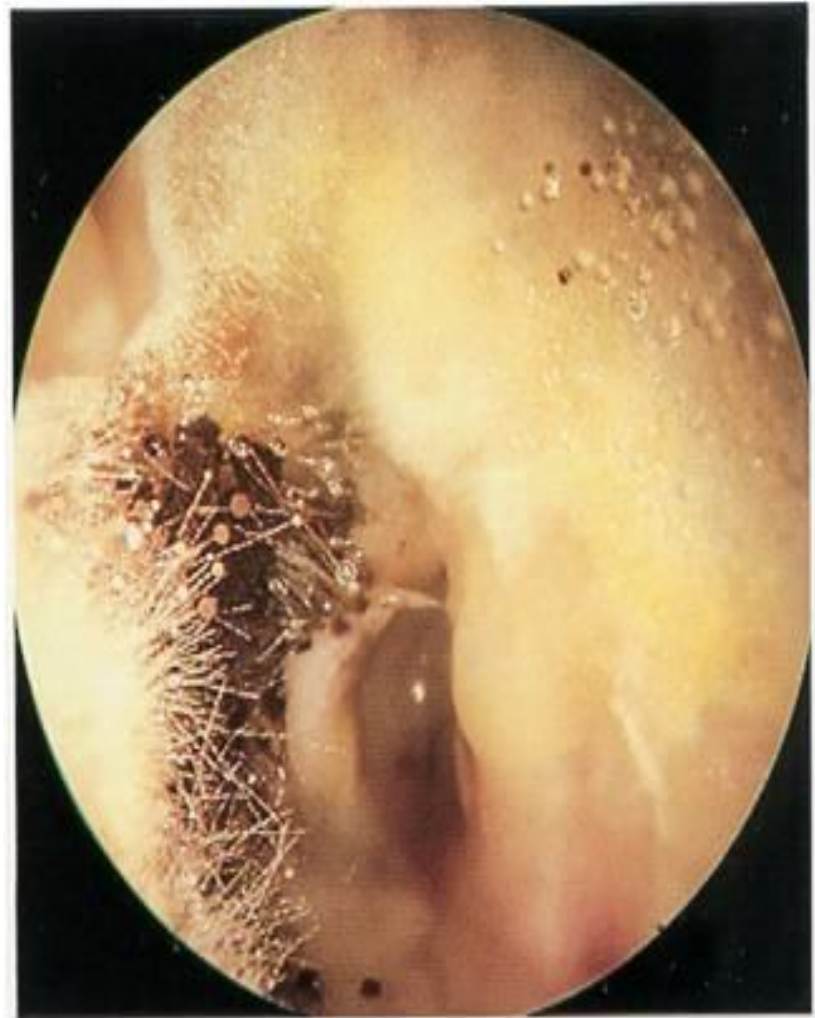-name two complications ?

lower CN palsies

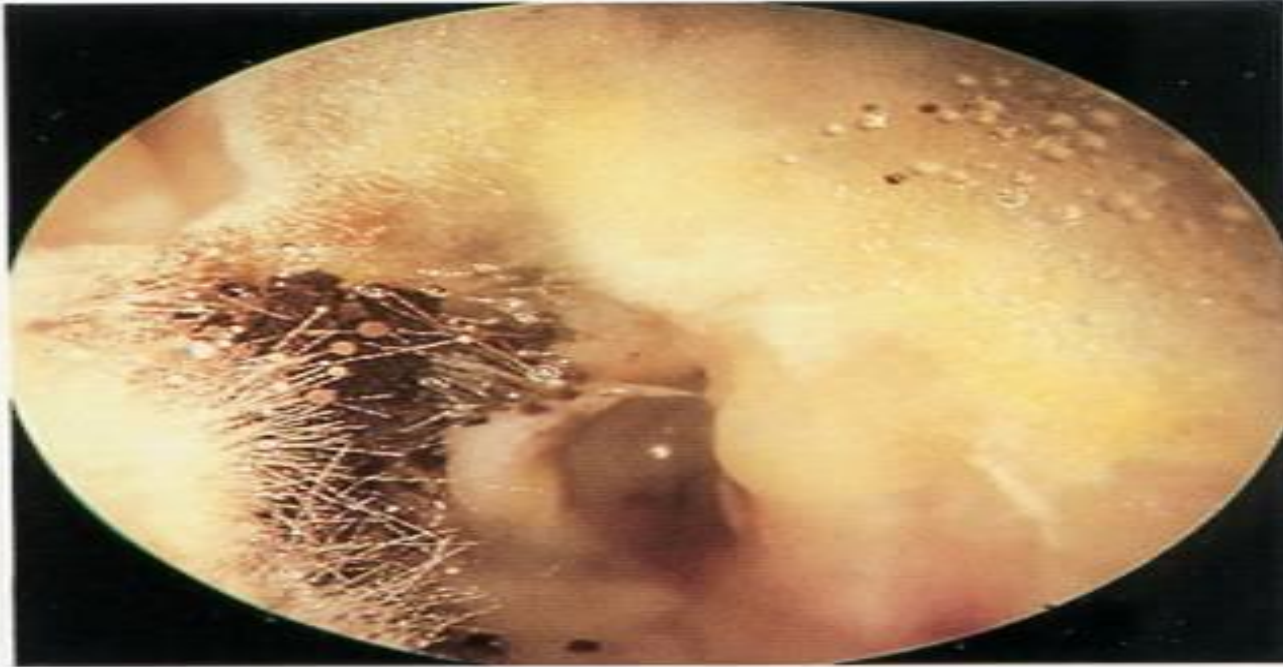
systemic infx

Q3.Ear itching, discharge, ... etc

- Dx ?
- Otomycosis
- Causing MO ?
- *Aspergillus niger*
- Occur in ?
- Immunocompromised patients , DM
- Public Swimming pool users.
- Secondary to bacterial infection



Q4) A patient with a history of pruritus...



- - Diagnosis . aspergillus otomycosis
- Mention 2 lines of treatment

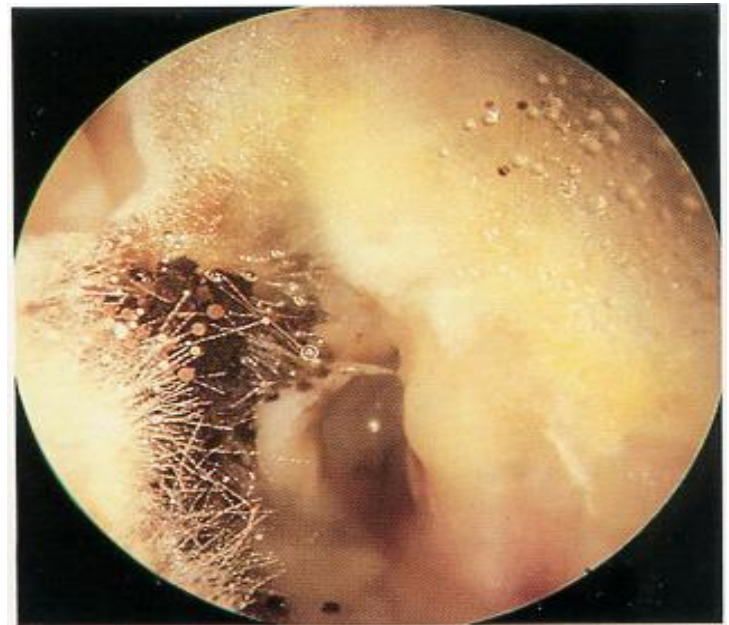Aural toilet. Topical antifungal

- This pt presented with hx of ear itchiness and discharge

- 1) What is your diagnosis

- 2) Mention 2 causative Microorganisms

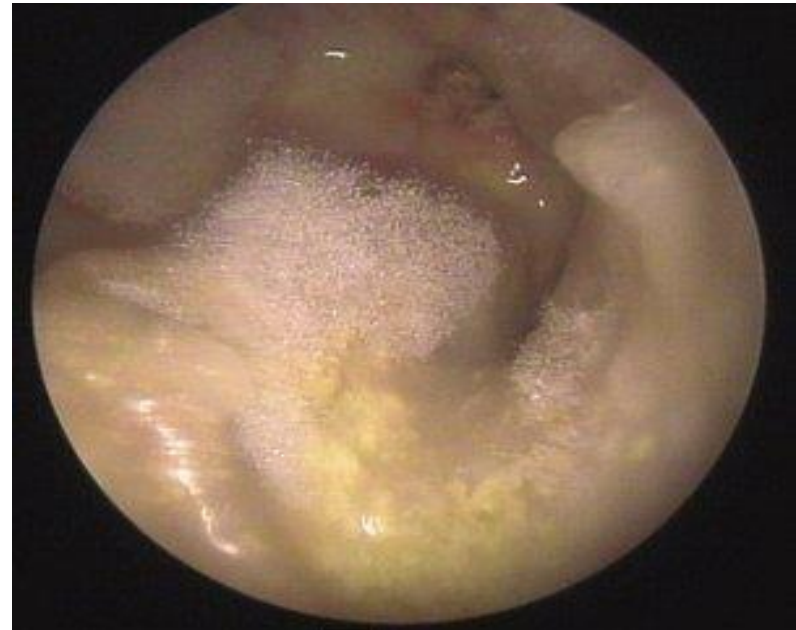- 3) What is the most important step in the treatment?



Q5

This patient presented with ear itching

1. What is your diagnosis?
2. What's your treatment (2 points)
3. What's the most likely causative organism?



1. Otomycosis / Fungal otitis externa
2. A. Aural toilet B. Topical antifungals
3. Candida albicans in this case
(or Aspergillus niger as the most common in general)

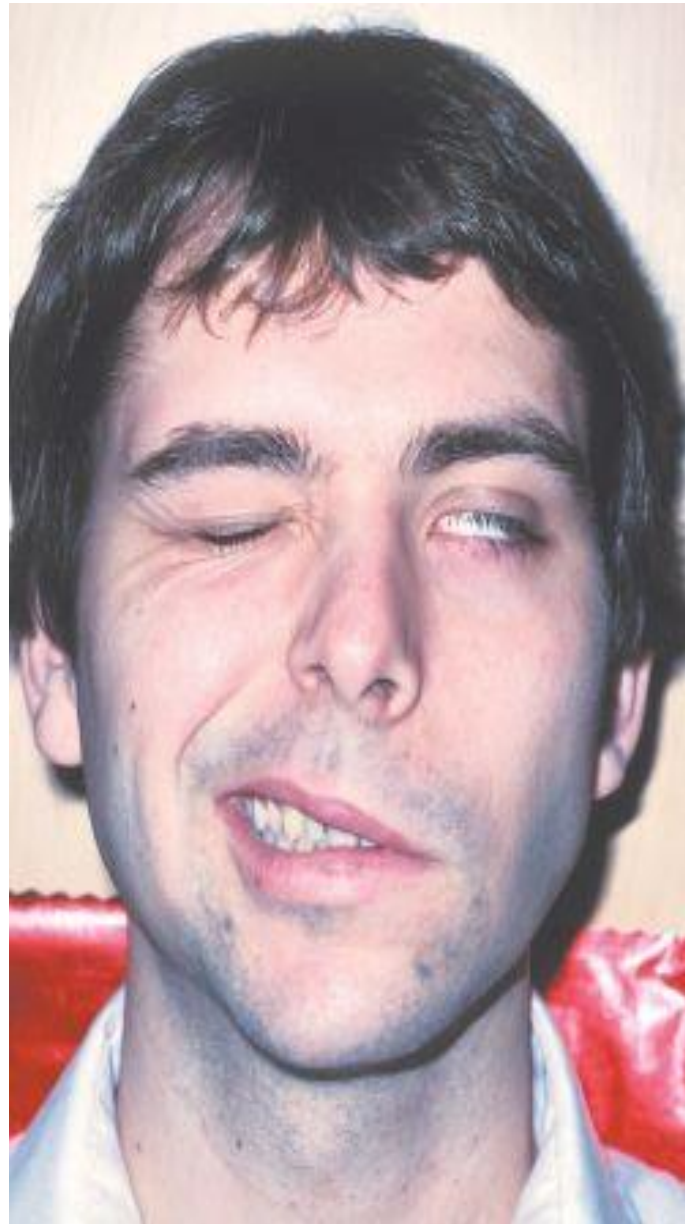
Q6

- otomycosis (1- Dx 2- symptoms 3- treatment)

Q7:

This patient had RTA, and had trauma to the temporal bone and complains of decreasing in hearing:

- Mention one findings.
- What investigation would you like to order?
- Mention 2 other causes for this condition.



1- right mouth deviation

2- CT head

3- bell's palsy, ramsay- hunt syndrome (herpes zoster oticus)

Q8

50 year old male medically free, had ear pain and discharge and on examination he had some vesicles grouped near his ear , and this picture

- 1-name this syndrome.
- 2-name the organism responsible for this syndrome.
- 3-how do you treat .
- 4-in which side is the palsy.



- 1-ramsay hunt syndrome.
- 2-varicellazoster virus.
- 3-Oral antiviral and steroids and Corneal protection.
- 4-in the right side

Q9

- **Pic and case – easy diagnosis Ramsey Hunt Syndrome**
- - What is your diagnosis
- - Organism?

Varicella zoster

- - 1 complication?

Permanent hearing loss and facial weakness

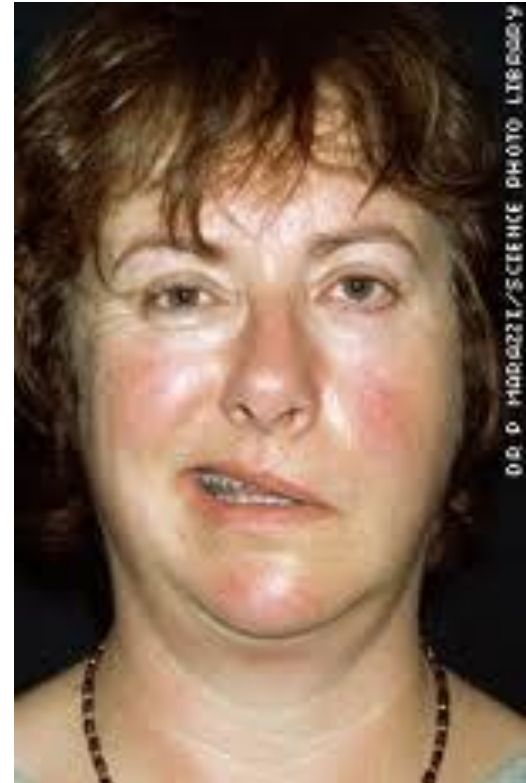Q.10-what's your dx?
Left side Facial palsy
-name two diseases that
can cause this ?
Ramsay hunt syndrome,
MS, temporal bone fx,
mastoiditis



- Q11. A patient with left facial palsy
 - 1-what is this (mention the side)
 - 2-treatment if no underlying cause was found?Steroid

Q11

- What is ur diagnosis?
(mentioning the side is IMP
/left in this Pic)
- Mention 3 ENT causes ?
Mastoiditis, ramsay hunt,
temporal bone fracture

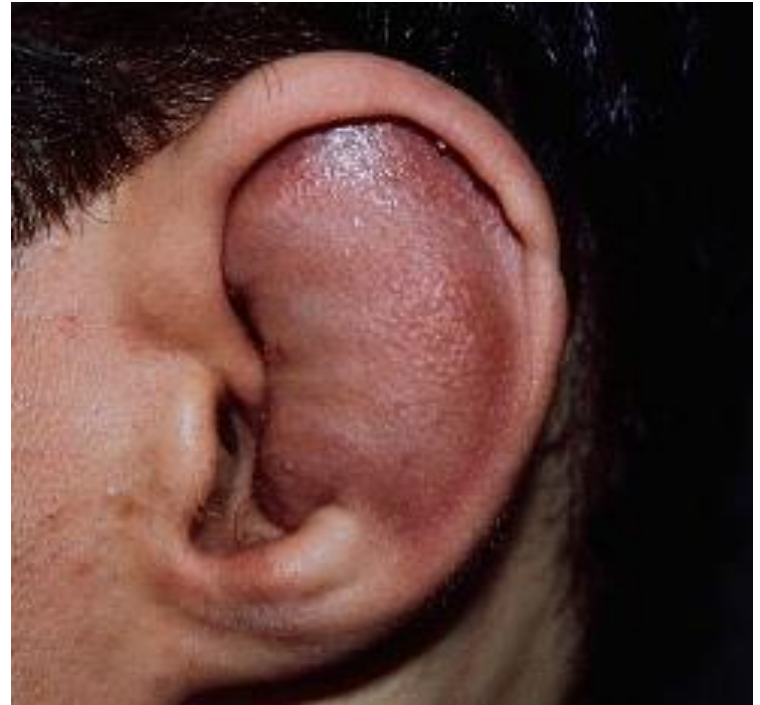



- Q12. What is your diagnose and which side is affected here?
- Mention two diseases of the ear could lead to this.

Question #13

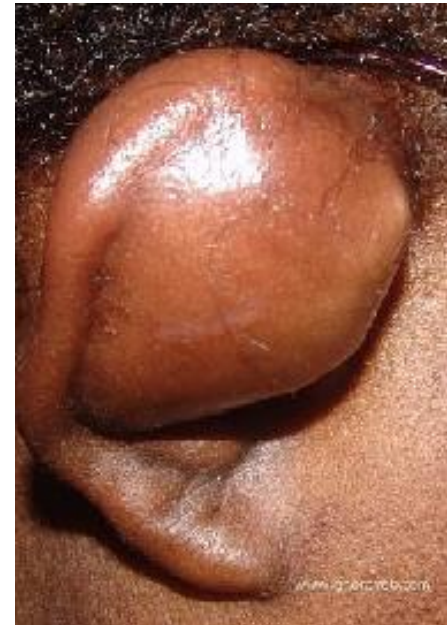1. What's your diagnosis?
2. Mention 1 way for treating it.
3. Mention 1 complication if left untreated.



1. Auricular hematoma.
2. Incision & drainage.
3. Cauliflower ear.

Q14

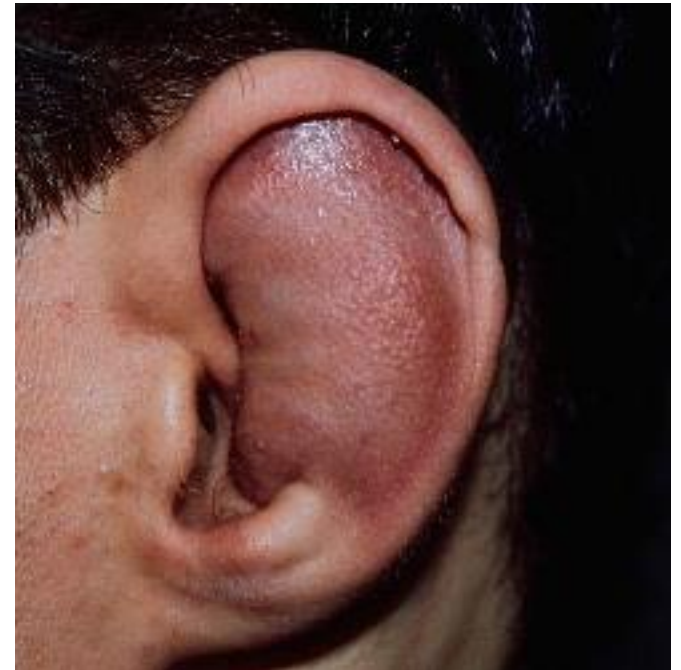- A 6 years old child presented to you with this condition after he fall on his ear while he was riding a bicycle
 - 1) What is your diagnosis
 - 2) Mention 2 options for the Treatment
 - 3) Mention 1 complication



Q15

A 25 year old presented to the ER after a struggle with this picture.

1. What's your diagnosis?
2. What's your treatment?
3. Give 2 complications if it's left untreated.



Answers #15

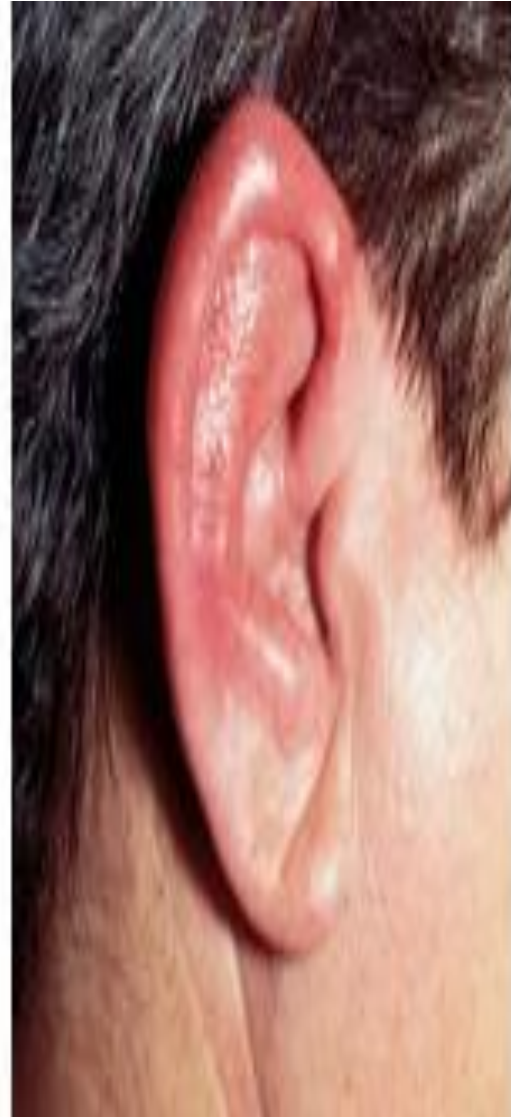1. Auricular hematoma
2. Incision and drainage / evacuation
3. A. Cauliflower ear B. Infection / abscess

Q16

1- What is the diagnosis?

-Give 2 causes.

-Give one complication.



Q16

1- perichondritis

2- a) mastoid surgery

b) ear piercing

c) trauma

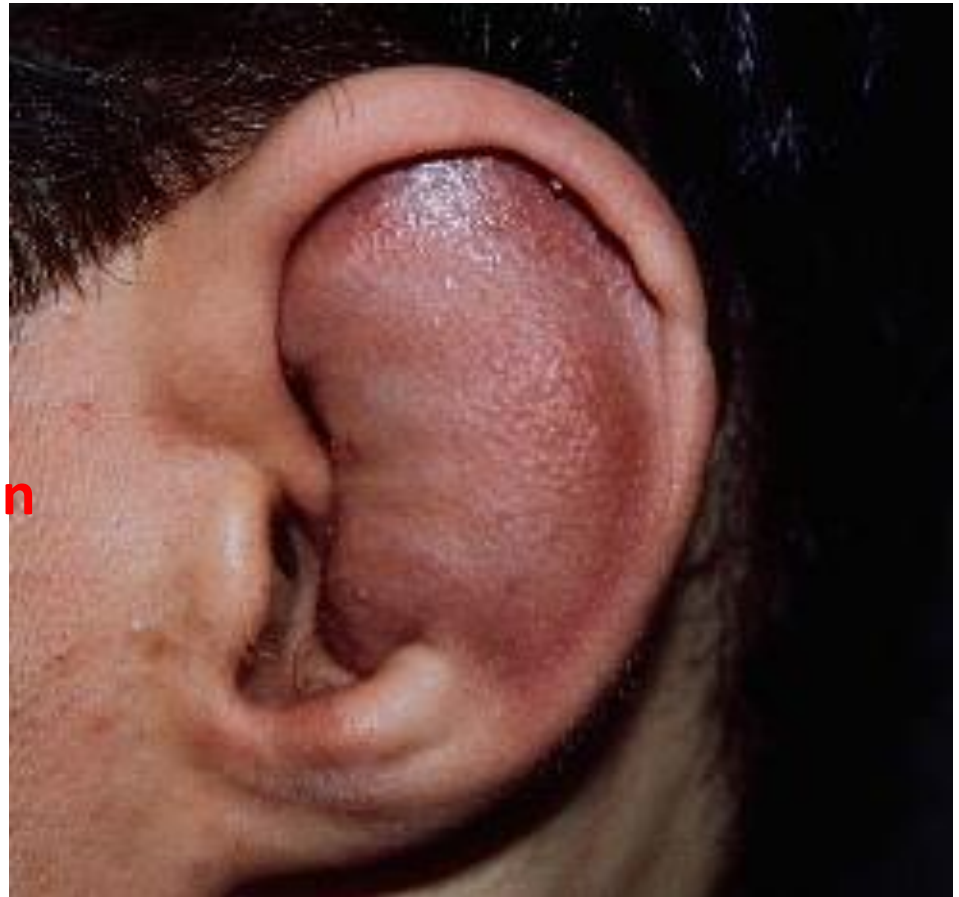3- spread of infection to the ear cartilage
(chondritis)

- Q17) A history of patient coming to ER with trauma
 - Diagnosis.
 - One Complication.
 - 2 lines of treatment

Answers

subperichondrial hematoma.

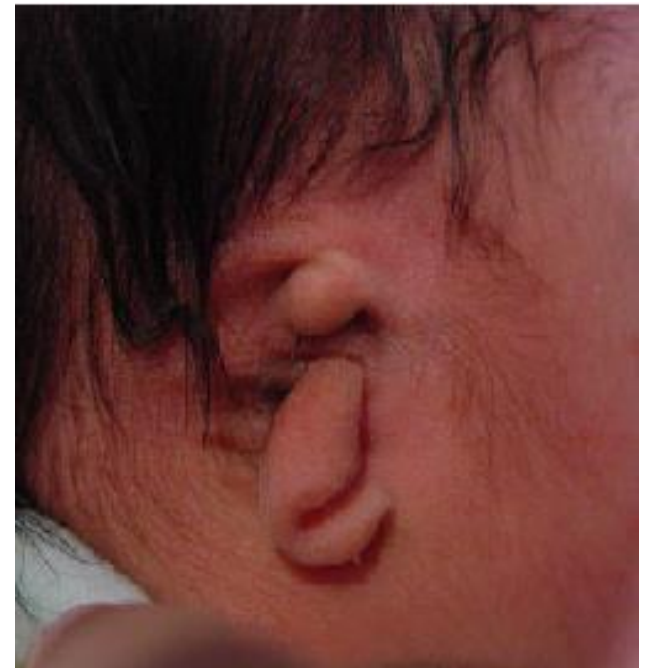- Infection and abscess formation
- evacuation, IV antibiotic



Q18

- 2 years old child, saying only Dada, Mama

- 1) What you can see?
- 2) Mention 1 test you want to do for this pt
- 3) What is the treatment?



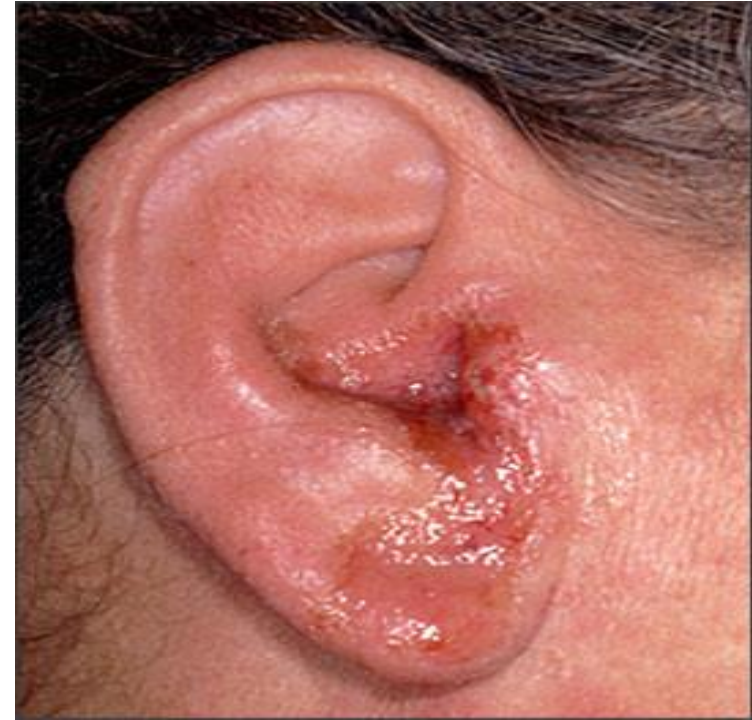Microtia

ABR: auditory brainstem Response test?

kidney US?

Reconstruction of external ear

- **Q19**
- **1)what is the diagnosis? otitis externa**
- **2)What is the treatment?**



1) What is your diagnosis ?

2) What is the first line of treatment ?

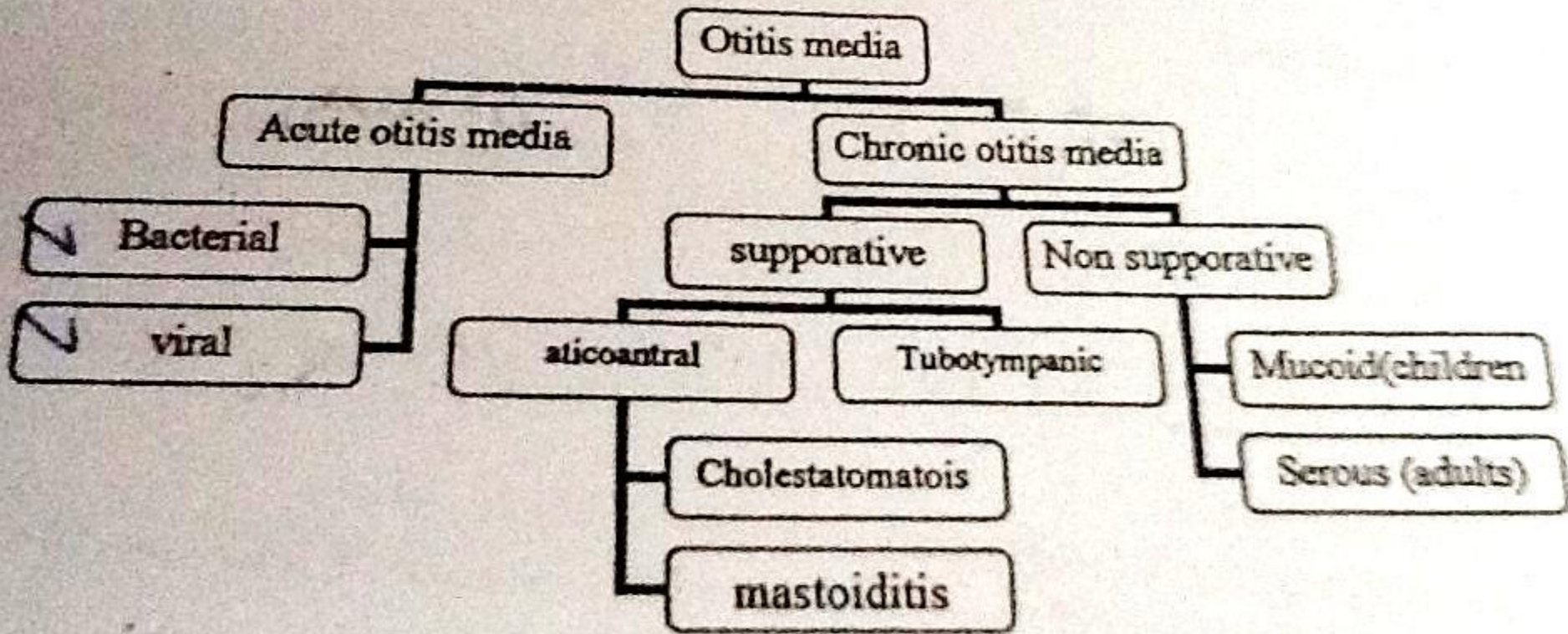
1) Otitis externa

2) regular aural toilet



Otitis Media

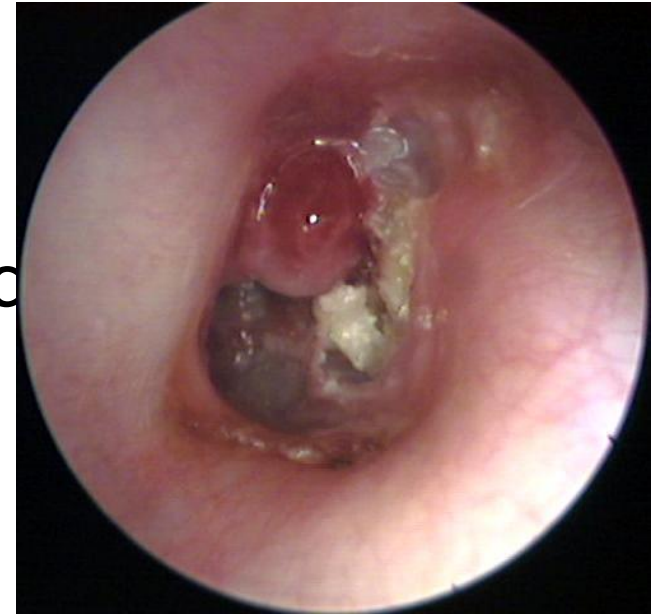Otitis Media



Question#1

Patient presented with ear symptoms (I can't remember them :S) and the following picture examination :

- 1) what's your diagnosis ?
- 2) Treatment ?
- 3) Complications ?

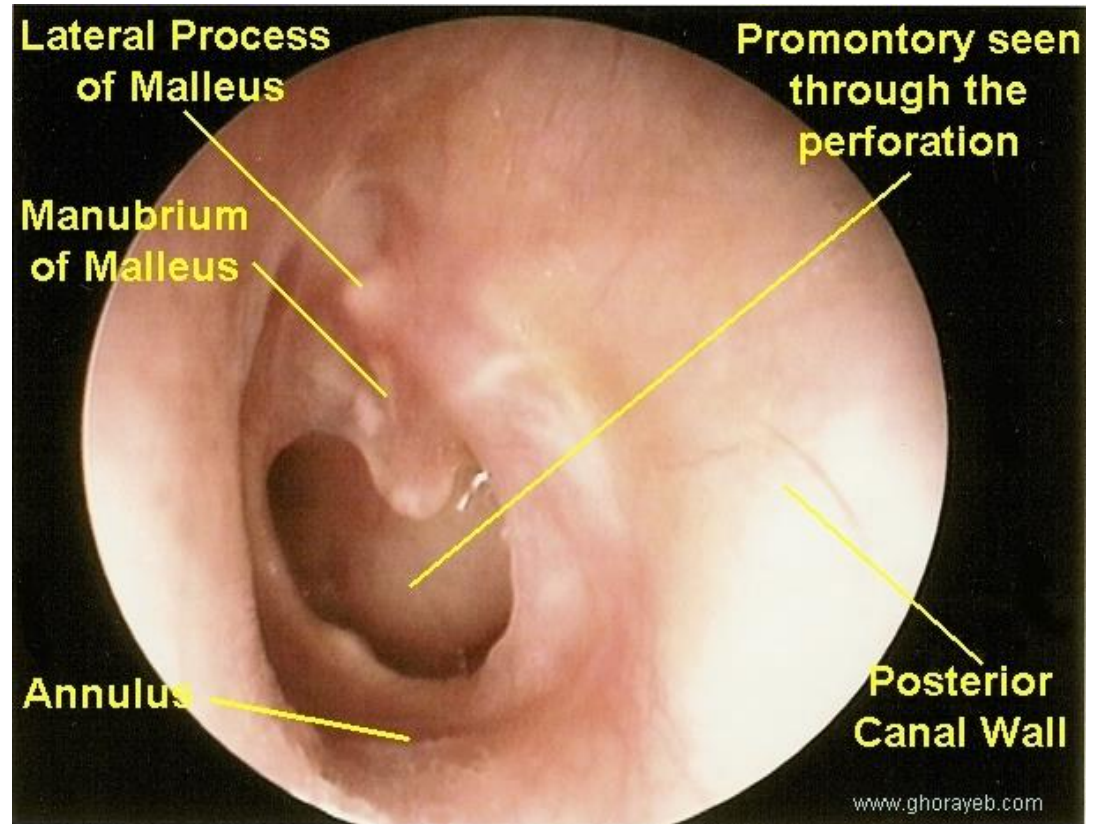


Answers to Question#1

- 1) Chronic suppurative otitis media (atricoantral type)
- 2) Surgical removal of cholesteatoma + antibiotics
- 3) Facial palsy , brain abscess , meningitis

Q2:

- what is the diagnosis?
- What is treatment?
- What the type of hearing you expect to find?
- What is the 2 most common microorganism that cause this condition?



Q2

- 1- chronic suppurative otitis media
- 2- conductive HL
- 3- tympanoplasty
- 4) a) *Pseudomonas aeruginosa*
b) *Staphylococcus aureus*

- Q3)A picture of perforated tympanic membrane for patient with chronic ear pain and discharge

- Diagnosis?

Chronic suppurative otitis media

- Treatment?

tympanoplasty

Q4

History of patient with 10 years Hx of ear discharge , atic perforation ,.....

- What is your diagnosis ?
- Mention 2 complications?
- What is your treatment?

- Chronic suppurative OM
- labyrinthitis, intracranial abscess, petrositis
- Local AB, aural toilet, local steroids (to control granulation tissue)

Q5

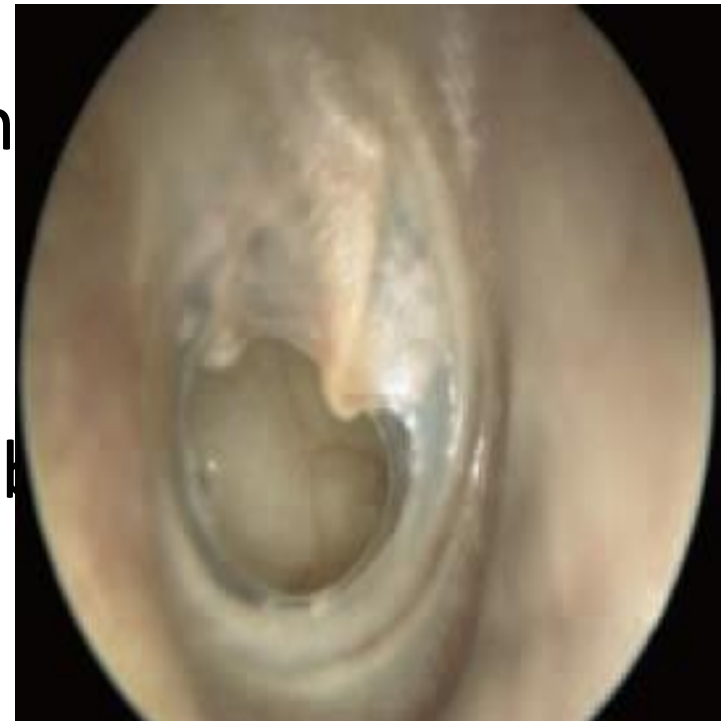- **A patient with right ear discharge and hearing loss for 10 yrs**

Mention 4 complication (an
OM complication)

Treatment:

Aural toilet and proper antibiotic

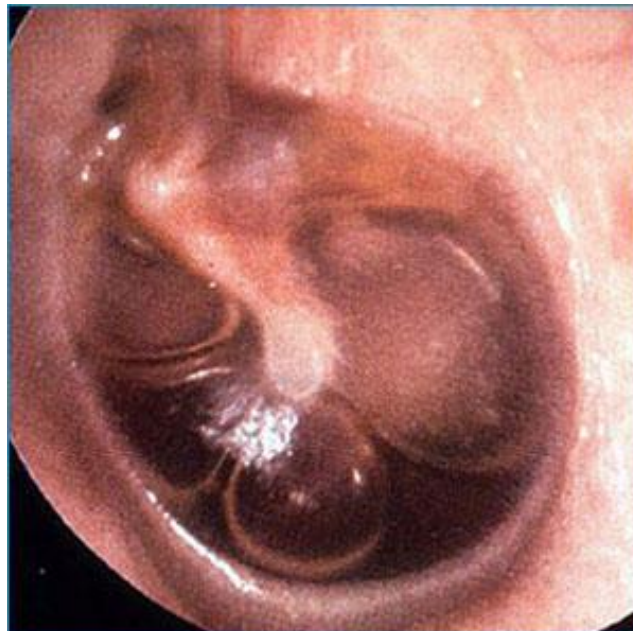Myringoplasty



info

- Glue ear is a common childhood condition in which the middle ear becomes filled with fluid. The medical term for glue ear is otitis media with effusion (OME)
- (also known as secretory otitis media, otitis media with effusion, or serous otitis media)
- The most common cause in children is enlarged Adenoid.

- **Q 6...**
- **1)what is ur diagnosis?**
secretory otitis media
- **2)Give a predisposing factor? Adenoid hypertrophy**



- Q7) A picture of tympanic membrane (intact) with History of adenoid hypertrophy and ear pain

1-diagnosis?

Otitis media with effusion

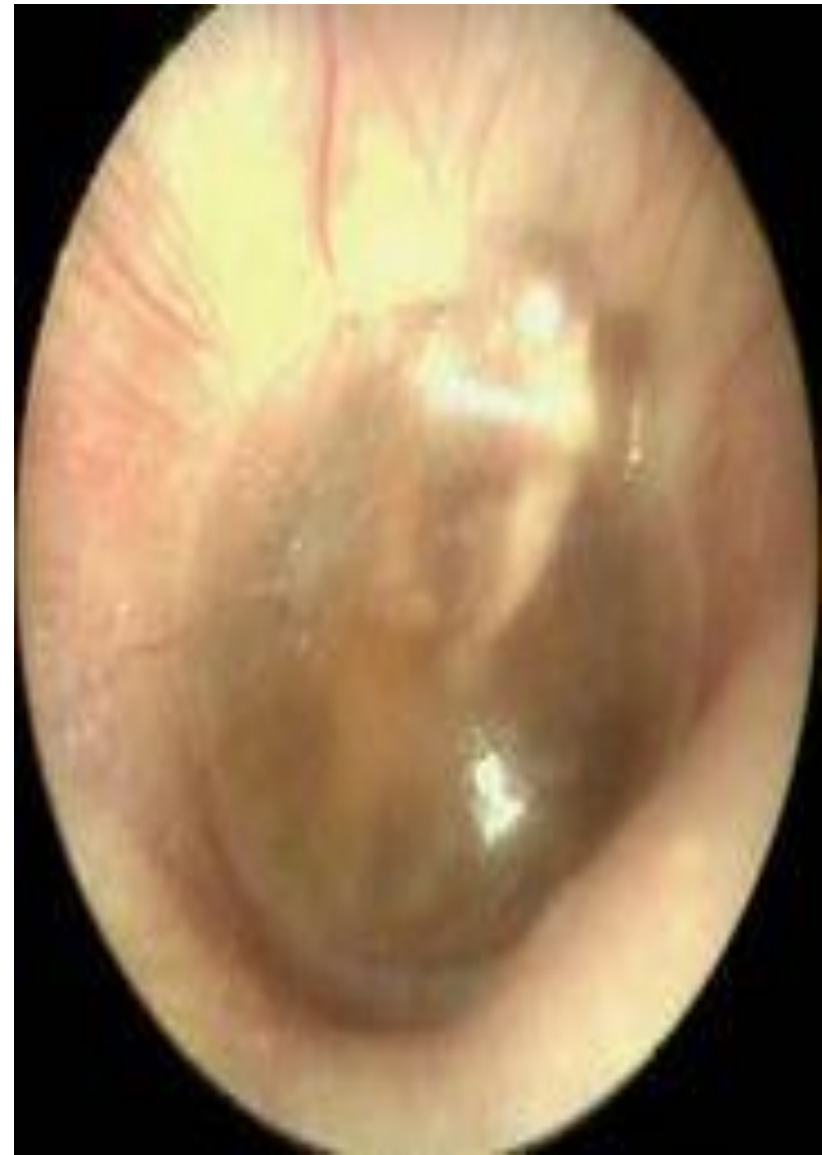2-treatment ?

myringotomy, grommet tubes, adenoidectomy

- Q8) A 4 year old child presented with history of hearing loss and fullness of 1 month duration.
 - What is the diagnosis?
 - What is the main line of treatment?
 - Mention 2 predisposing conditions?

Answers

- Glue ear
- Antihistamine, nasal decongestant, nasal spray (steroid)
- Adenoid hypertrophy, Eustachian tube dysfunction

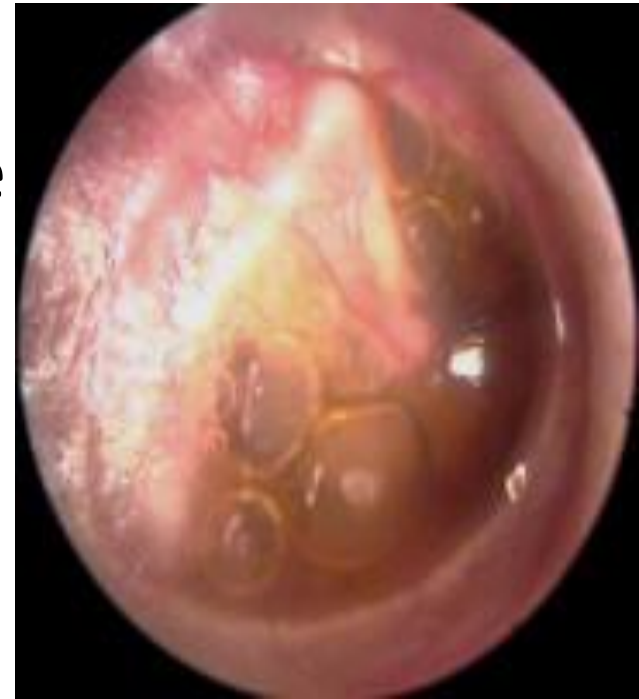

Q10. History of ear fullness and decrease in hearing for 5 months

- 1) What is your diagnosis ? OME

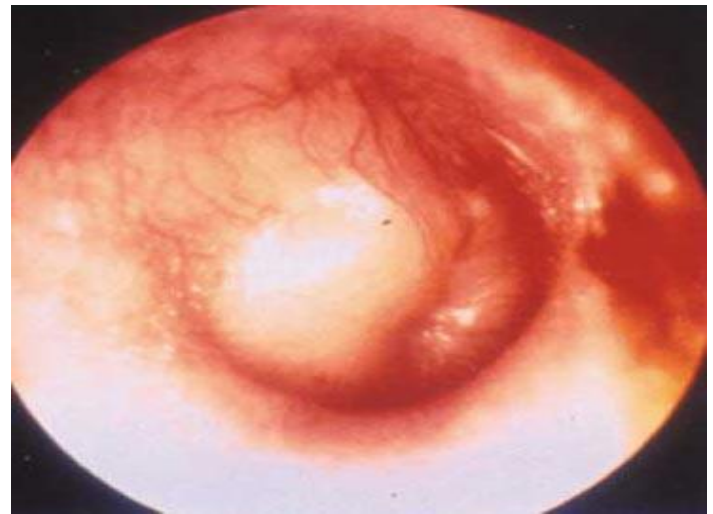
2) What is the treatment ?

Myringotomy with ventilation tube



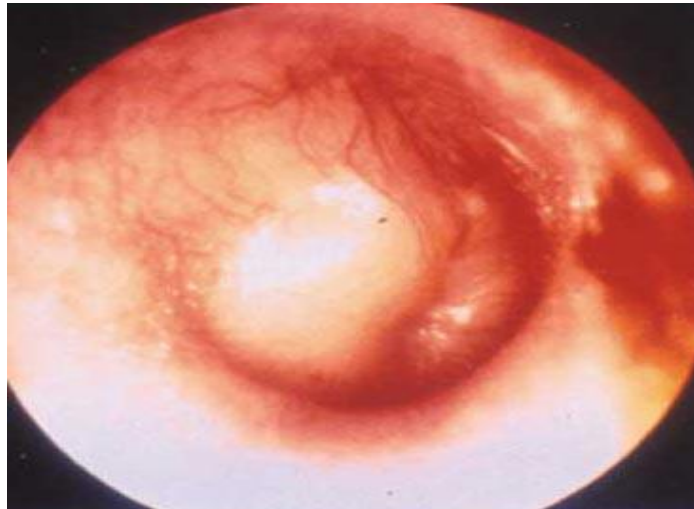
Question #9

- There was a history showing that it's Acute (3 days) & that it's bacterial.
1. What's your diagnosis?
 2. What's the most common microorganism causing this?
 3. Mention 3 extracranial complications.



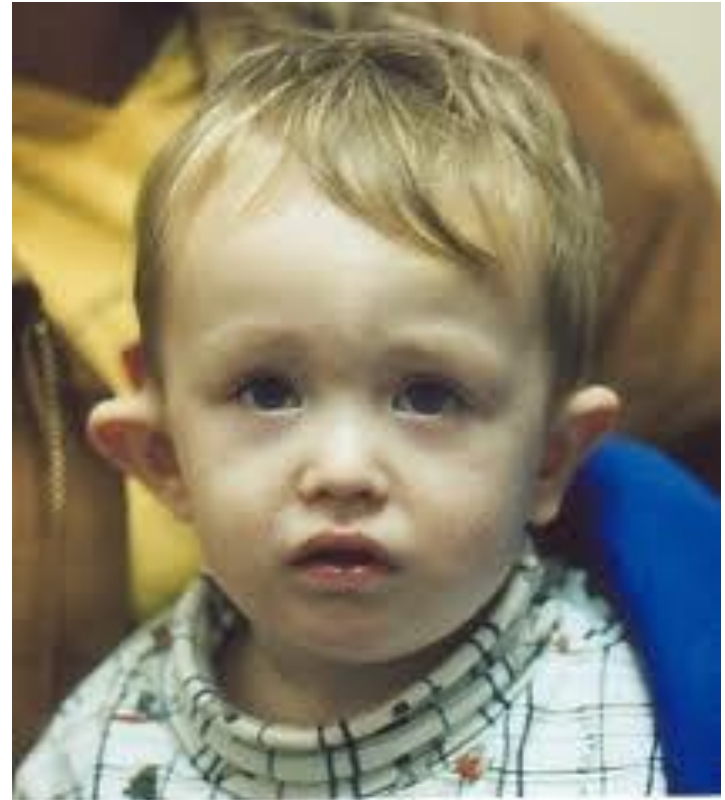1. Acute otitis media.
2. Strep. Pneumonia.
3. Acute Mastoiditis, Facial Palsy & Petrositis.

- **Q...**
- **1)what is ur diagnosis? Acute otitis media**
- **2)what is the best treatment?**



Q11.Ear pushing downward and forward with fever ..
Etc >>> Mastoiditis

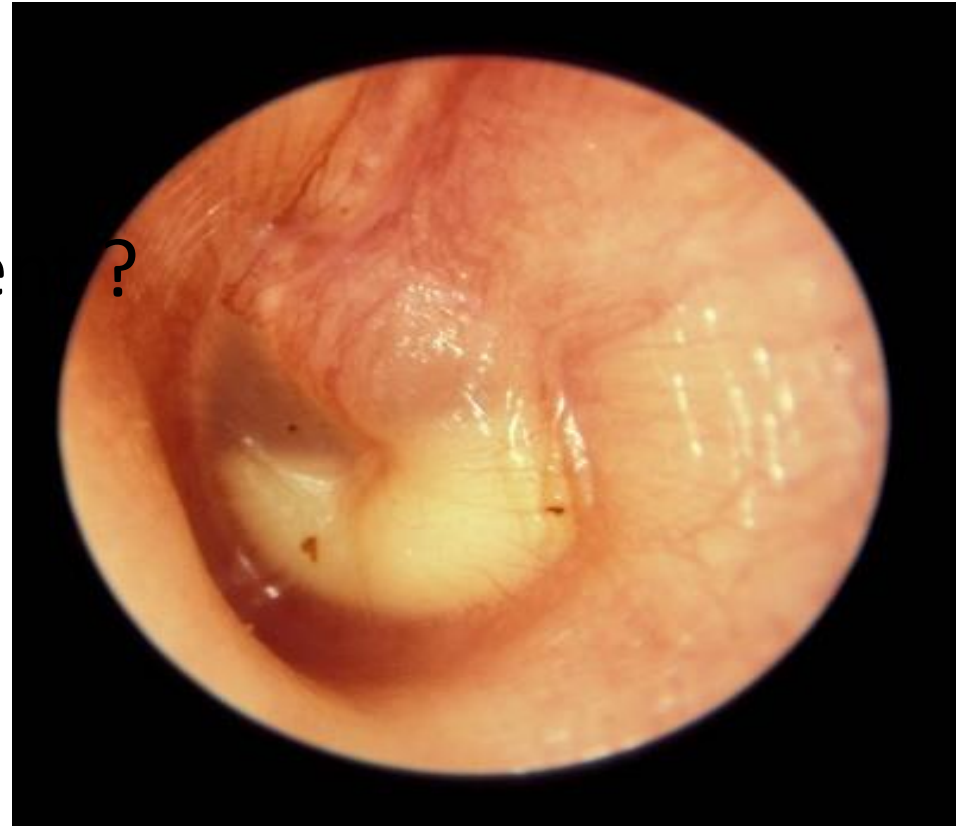
- Rx ?
- antibiotics ..
mastoidectomy...
- 1 extracranial
complication?
- osteomyelitis, and
abscesses deep within
the neck
- Facial palsy?



Q12.A 5 year old child with fever and earache 3 days ago

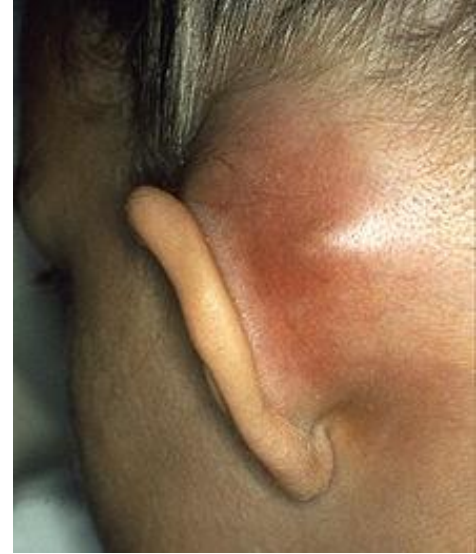1) Mention 3 possible complications ? Subdural abscess, epidural abscess, lateral sinus thrombosis, meningitis, facial nerve palsy, mastoiditis, etc.

2) What is the best treatment ?
antibiotics



Question#13

I can't remember the history ! But
It's obvious from the picture :



- 1) what's your diagnosis ? **Mastoiditis**
- 2) Treatment ? **IV Antibiotics + mastoidectomy**
- 1) 3) Complications ? **Facial palsy**
brain abscess
petrositis

Q14. tympanosclerosis : calcification of tissues in the middle ear

- you did otoscope examination and you find this picture.

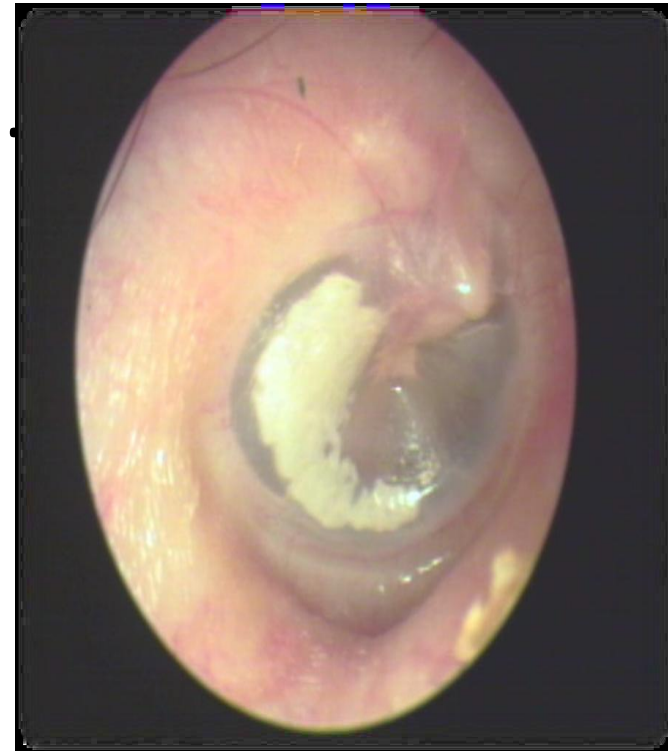
1-What is this. tympanosclerosis

2-give 3 causes for this condition.

A-grommet insertion.

B-perforation.

C-infection.



Q15

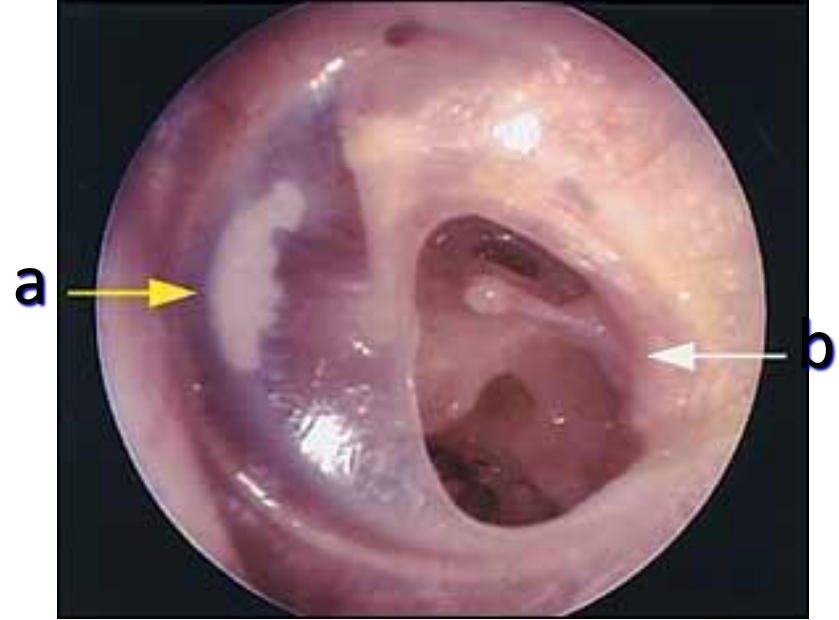
- **Pic of Tympanosclerosis**
- - diagnosis?
- - 2 predisposing factors

glue ear

Insertion of a tympanostomy tube

Question 16

This is the exact same picture we had in the exam



- A) What is (a)?
- B) What is (b)?
- C) What is the treatment of (b)?

Question 16 answers

- A) Tympanosclerosis
- B) Tympanic membrane perforation
- C) Tympanoplasty

Inner ear

Vertigo

- **In inner ear**

1. **BPPV** (no effect on hear , self limiting , reassurance, attack last few seconds)
2. **Meniere's disease** (vertigo, sensorineural hearing loss, tinnitus , N+V)/ attack last few hours
3. **Labyrinthitis**

- **In the nerve itself**

1. **Acoustic neuroma**
2. **Vestibularitis** by URTI , no hearing loss , it is reassurance

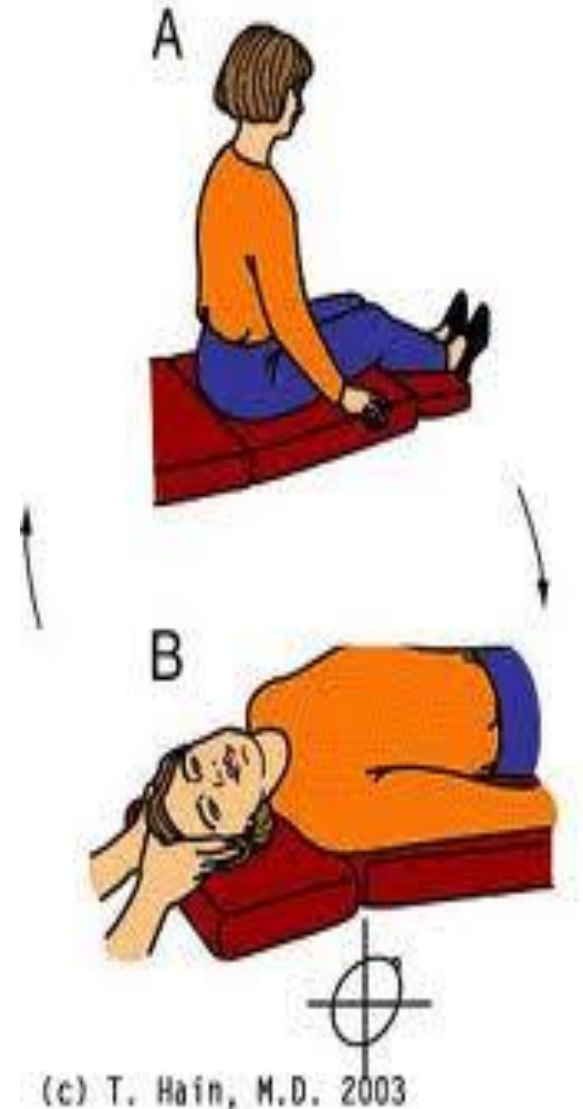
Question#1

Patient complained of dizziness for few seconds initiated by movement of the head.

- 1) what's your diagnosis ? BPPV (benign paroxysmal positional vertigo)
- 2) Test to confirm your diagnosis ? Dix-hall pike test
- 3) The maneuver we use to treat such condition. Epley maneuver

Q2

- Hx suggestive of BPPV.....
- What is your diagnosis ?
- What is name of this test?



Q3

- A pt presented with hx of recurrent attacks of vertigo that continues for seconds with moving the head.

- 1) What is your diagnosis?
- 2) What the name of this maneuver?
- 1) What is the treatment?



Q4: patient with history with aural fullness, vertigo, hearing loss.

- **What is your diagnosis?** meniere's disease
- **Give 2 examples of peripheral vertigo?** BPPV, labyrinthitis
- **Two methods of treatment?**
 - low salt diet
 - diuretics
 - B-Histidine(B-Serc)
 - Anti-emetic
 - surgery

Q.5

a patient had a meniere's disease

name the three symptoms he will have ?

Hearing loss, tinnitus, vertigo

what's the name of the procedure used to treat BPPV.

Epley's maneuver

Q6

- **Menniere's triad**

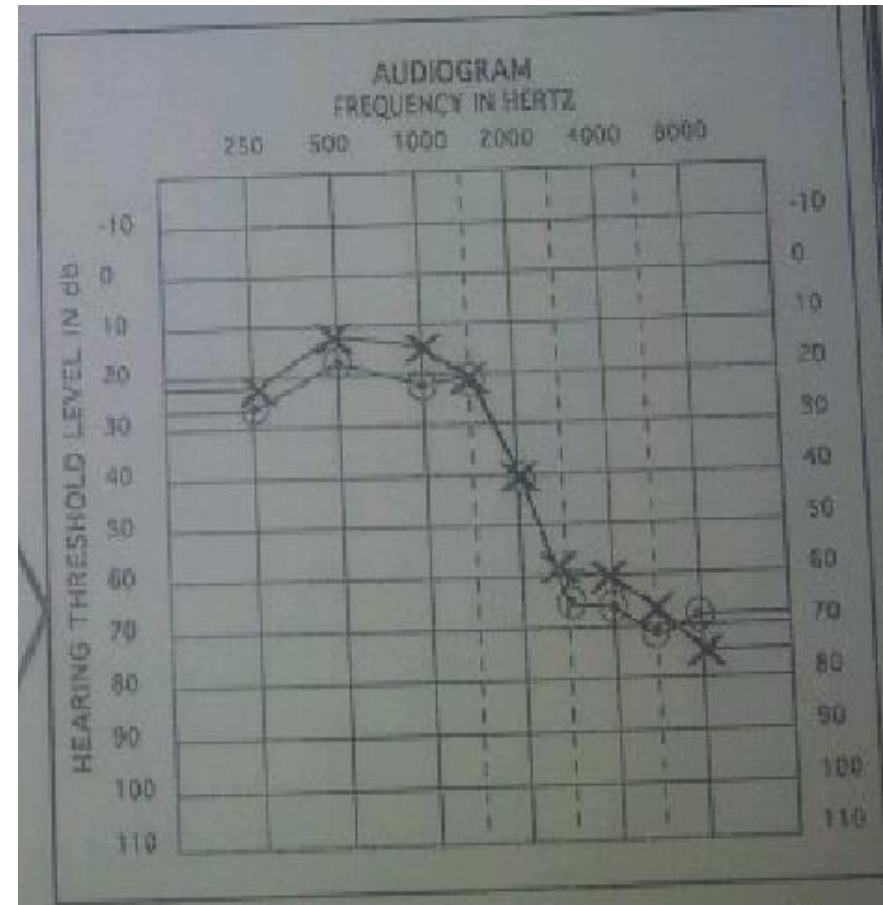
Vertigo

Hearing loss

Tinnitus

Q7. Hearing loss for 20 minutes + vertigo + tinnitus ... etc

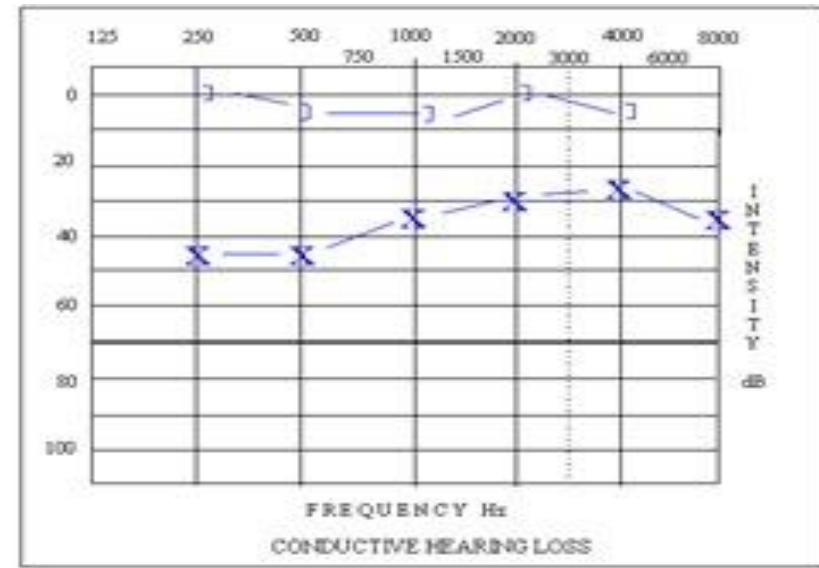
- What is the type of hearing loss ?
- Sensorineural
- What's the cause ?
- Meniere
- Rx?
- Low salt diet, diuretics, b-histidine , antivertigo & antiemetic .. etc.



Question#8

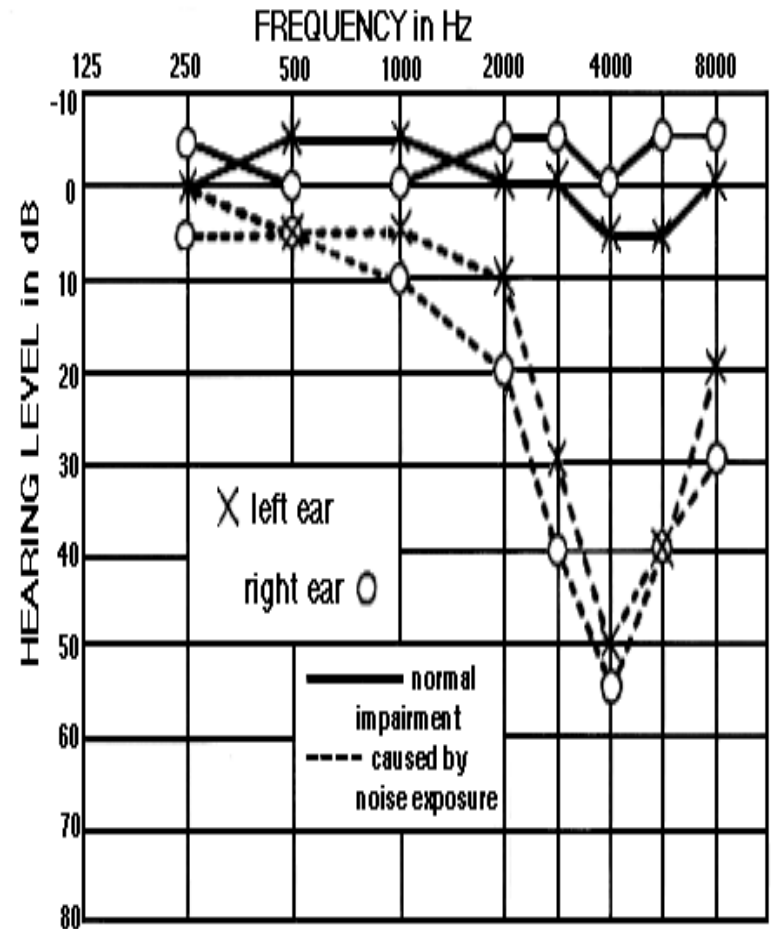
According to this diagram :

- 1) What's the name of the test used ? **PTA (pure tone audiometry)**
- 2) what's the type of hearing loss ? **Conductive hearing loss (Air-bone gap > 10)**
- 3) Give two causes? **Otitis media with effusion , otitis externa**



Question #9

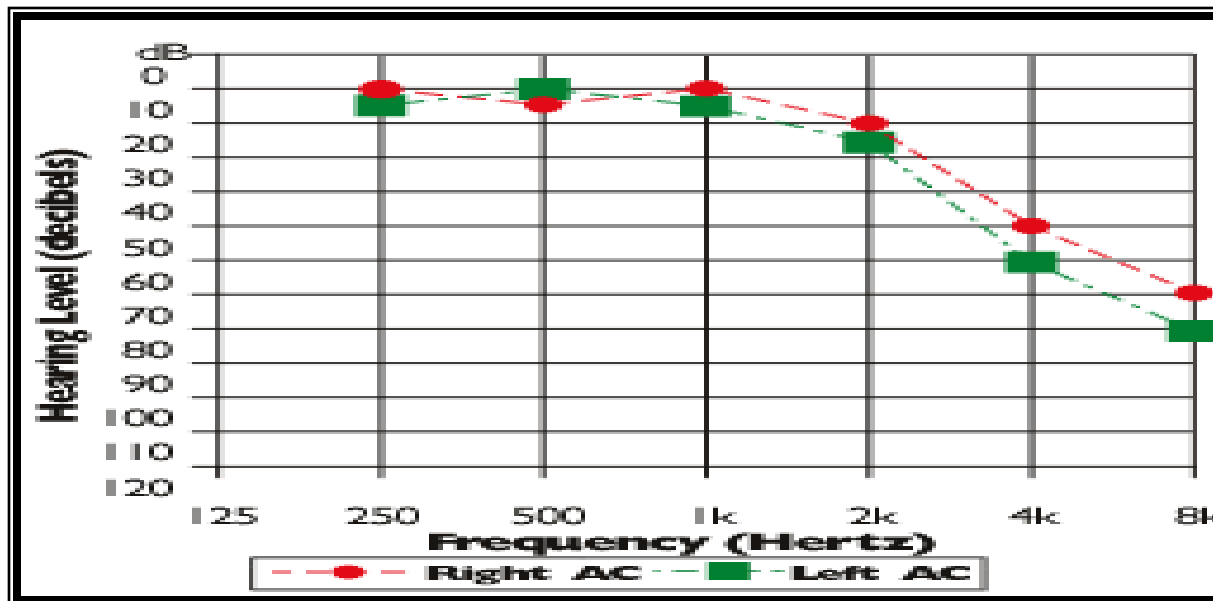
1. What's the name of this test?
2. What's the type of hearing loss?
3. Mention 2 differential diagnoses.

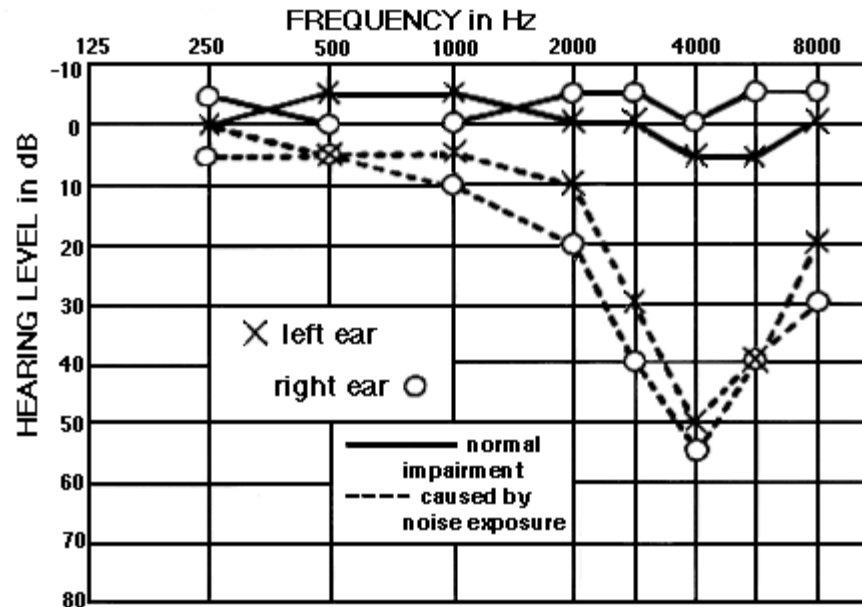


1. Pure Tone Audiometry (PTA).
2. Sensorineural hearing loss.
3. Noise-induced hearing loss & Presbycusis.

Q10: 50 year old male presented with a history of gradual hearing loss without any other findings and sent for PTA the result as you see.

- **1.what is your Dx? SNHL (Presbycusis)**
- **2.what is the result of weber test? Centralized**
- **3.what is the result of rinne test?+ ve**

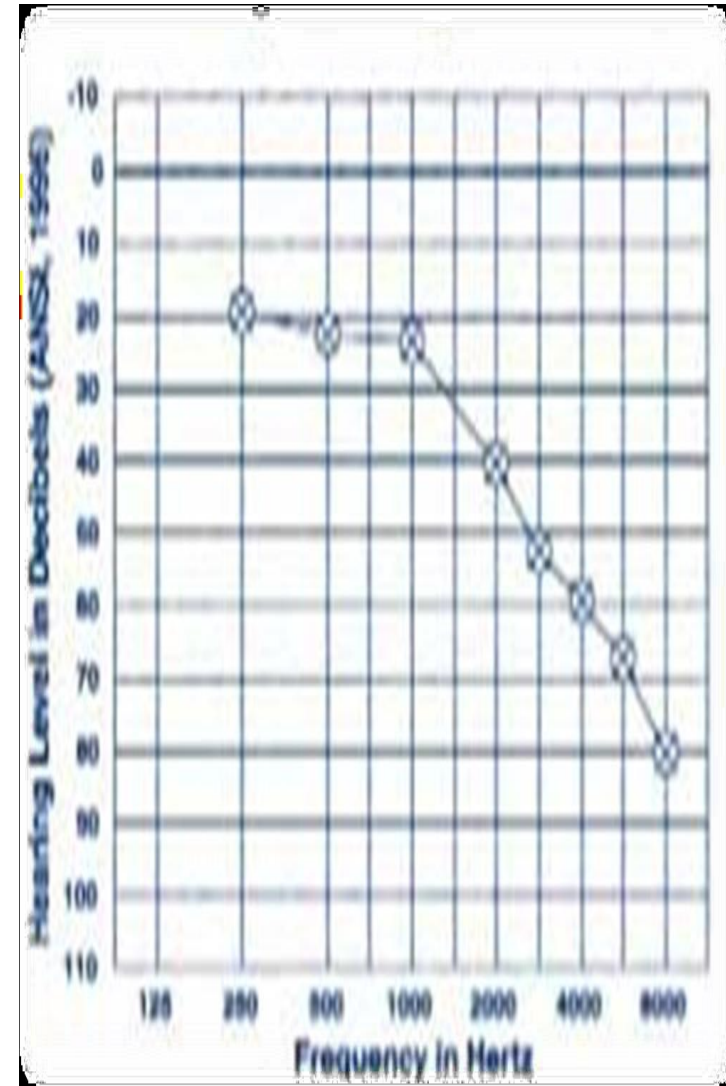




- What is your diagnose? (**Presbycusis**)
- What is the name of this test? (**Audiometry**)
- How will you treat this patient? Hearing aid

Q11

- **75 year old is complaining from bilateral progressive hearing loss and his audiogram showed this .**
- 1-what is the most likely cause.
- 2-how do you treat .

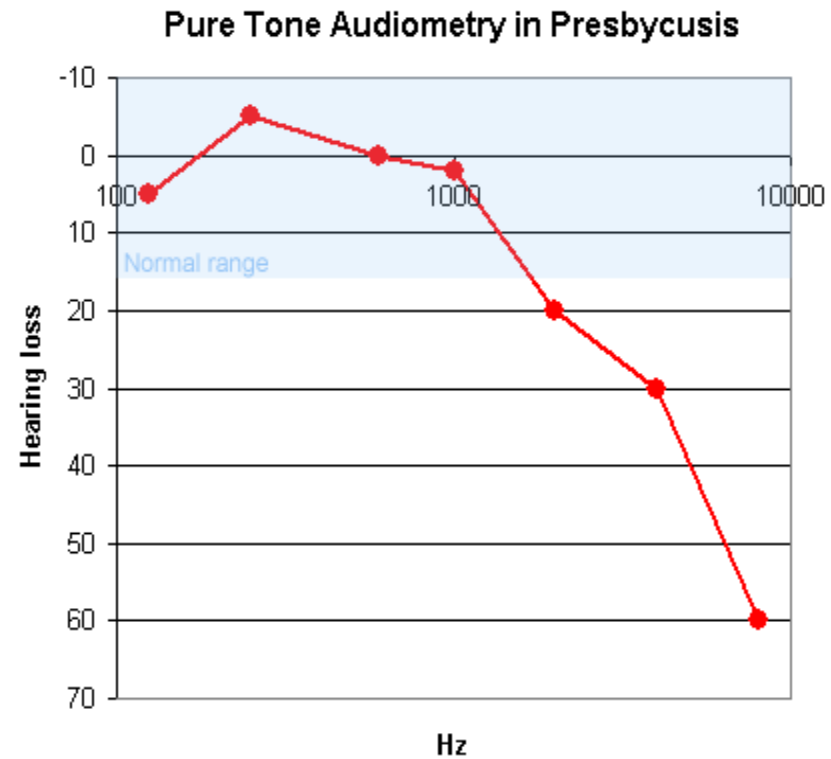


- 1-aging (presbycusis).
- 2-hearing aid.

- Q12

- What is the diagnosis?

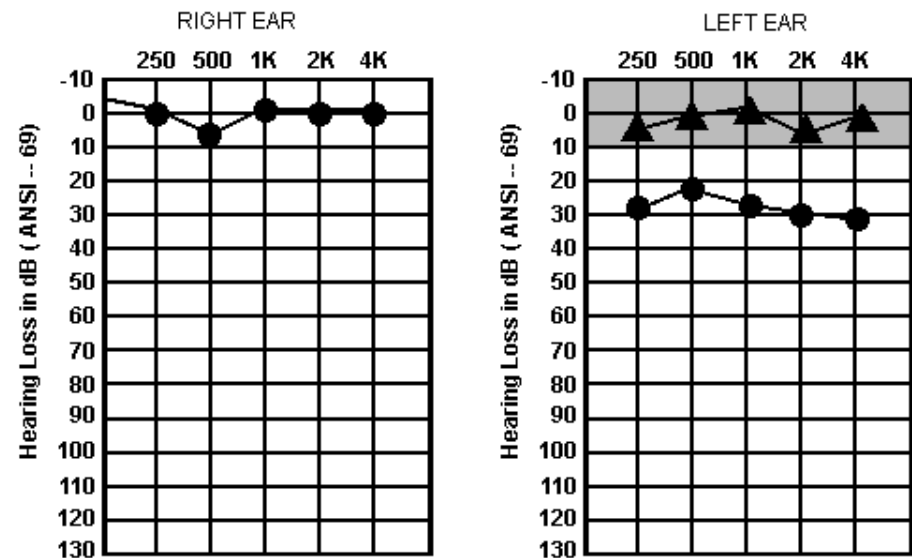
- (sensorineural hearing loss).... (presbycusis)



Question 13

Patient presented with hearing loss in his left ear. His Rinne's test is negative in left ear and this is his audiogram.

A) Mention 4 possible causes of deafness in this patient.



answers

4 causes of conductive deafness:

1. Earwax block
2. Otitis Externa
3. Acute otitis media
4. Congenital atresia of external canal
5. Otosclerosis
6. Tympanic membrane perforation

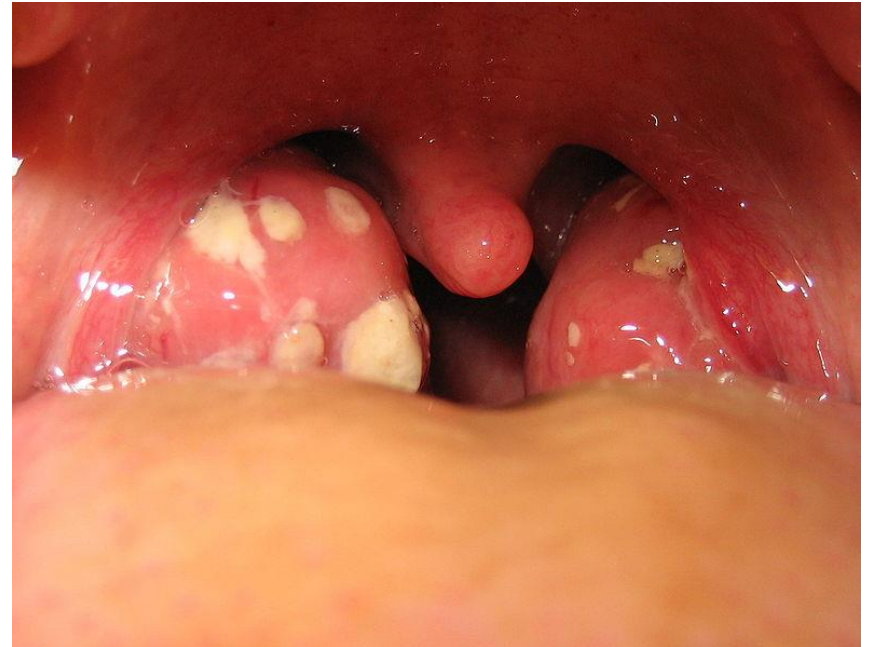Tonsils and Adenoid

Tonsillitis

1. *Acute catarrhal/superficial* viral
 2. *Acute parenchymatous* → tonsil is uniformly enlarged
 3. *Acute follicular* crypts full of pus as yellow spots.
 4. *Acute membranous* exudates coalesce to form membrane on the surface
- Chronic follicular yellow spots
 - Chronic parenchymatous very much enlarged almost touching each other .
 - Chronic fibroid small but infected , with history of repeated sore throat.

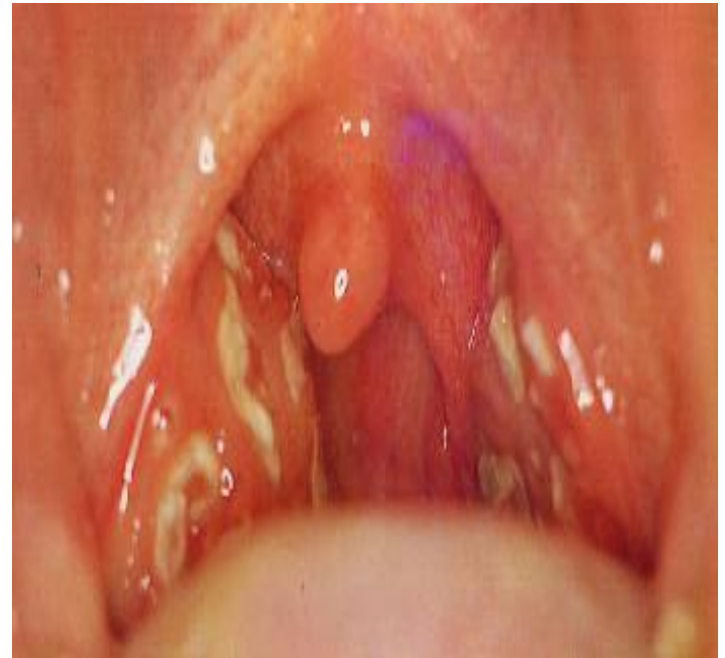Q1.High fever, sore throat, .. etc

- Dx?
- Acute follicular tonsillitis...
- 2 complications?
- Peritonsillar abcess ..
Retropharyngeal
abcess... Rheumatic
fever



Question 2

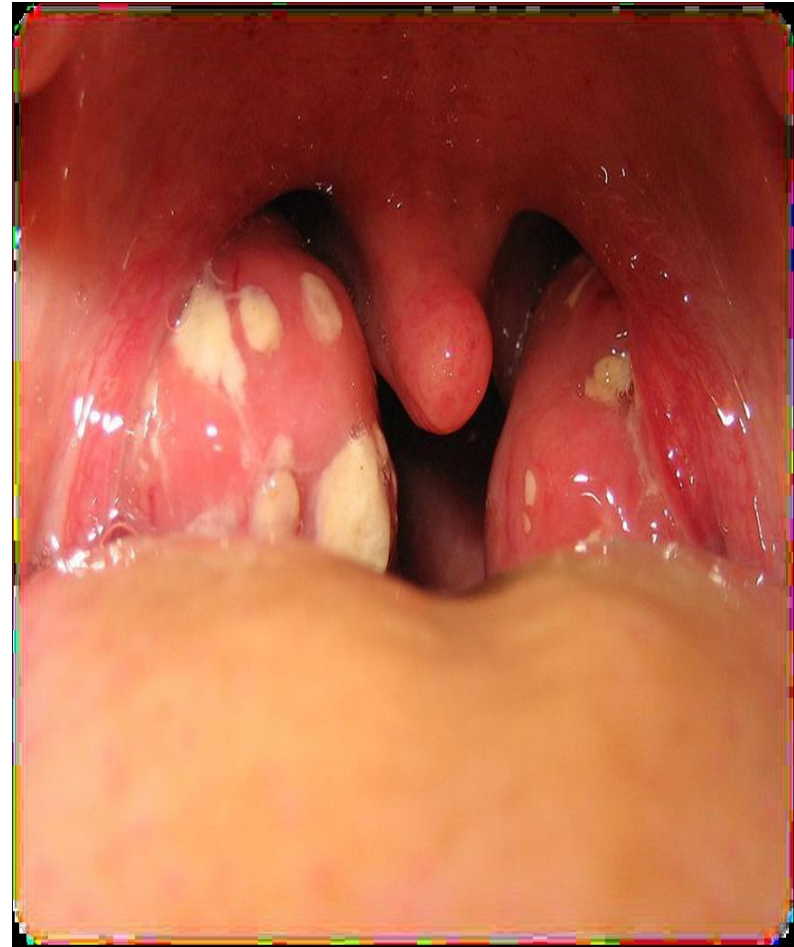1. What's your diagnosis?
2. What's the most common microorganism?
3. The antibiotic of choice is?
4. Mention 2 non-suppurative complications.
5. Mention 2 suppurative complications



1. Acute follicular tonsillitis.
2. Group A Beta Hemolytic Strep.
3. Penicillin or Amoxicillin.
4. Obstructive Sleep Apnea, Rheumatic fever & arthritis.
5. Peritonsillar abscess (Quinsy) & retropharyngeal abscess.

Q3

- **4 year old child have fever and sore throat since 5 days and the throat exam show this picture.**
- 1-what is your diagnosis.
- 2-what is the name of bacteria that cause this condition.
- 3-how would you treat him.
- 4-give 2 complications if left untreated.

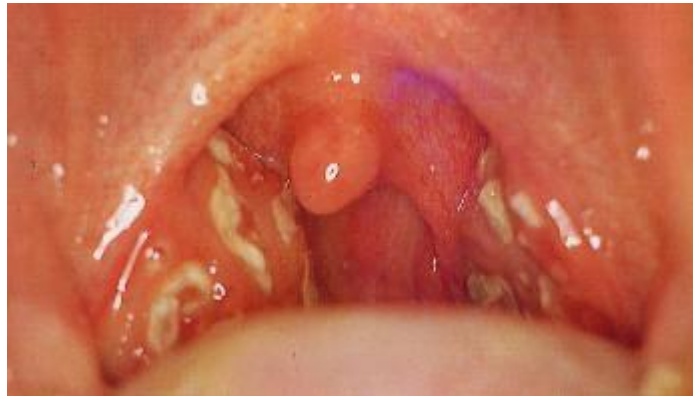

- 1-acute follicular tonsillitis.
- 2-group A beta hemolytic streptococcus.
- 3-by using antibiotics.
- 4-A-peritonsillar abscess.

B-Retropharyngeal abscess

Q4

- ...history of fever & ...(obvious)
- **1)what is ur diagnosis? acute follicular tonsillitis**
- **2)Give 2 complication?**



- Q1) A Picture of follicular tonsillitis (it was unilateral!!)
- 1-diagnosis
- 2-treatment

Antibiotic (amoxicillin), antipyretic, analgesic

- 3-two complications

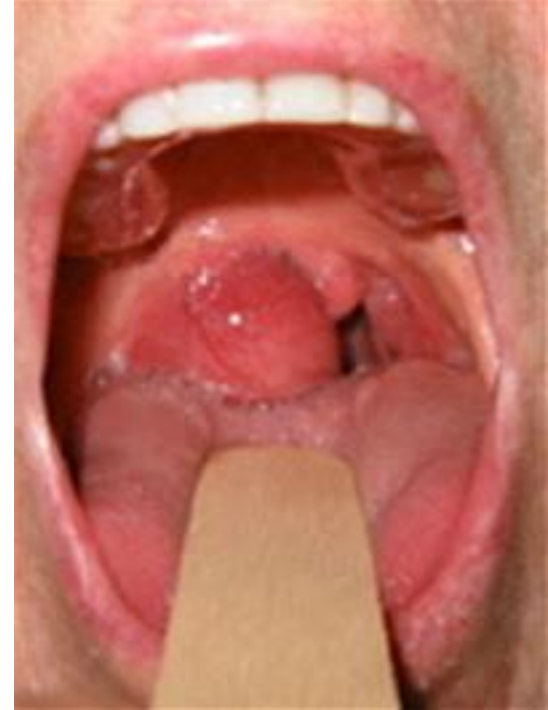Quinsy, retropharyngeal abscess

Question#5

The patient came with severe pain and fever:

- 1) what's your diagnosis?
- 2) What is the treatment?
- 3) What are the complications of his condition?

p.s : sorry couldn't find a better picture.



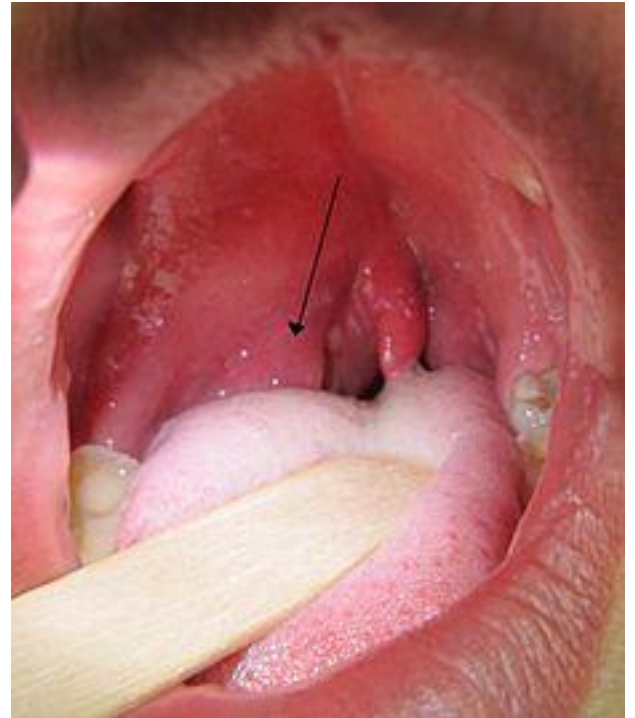Answers to Question#5

- 1) Peritonsillar abscess (quinsy)
- 2) Incision and drainage + antibiotics and then after 6 weeks tonsillectomy
- 3) Retropharyngeal abscess
septicemia

#6

25 year old with trismus and uvular deviation, dysphonia

1. What's your diagnosis?
2. What's the treatment ?
(2 points)



Answers #6

1. Right-sided peritonsillar abscess
2. A. IV antibiotics
B. Incision and drainage
3. C. tonsillectomy after 6 wks

Q7

History of fever, trismus ,uvular deviation ,....

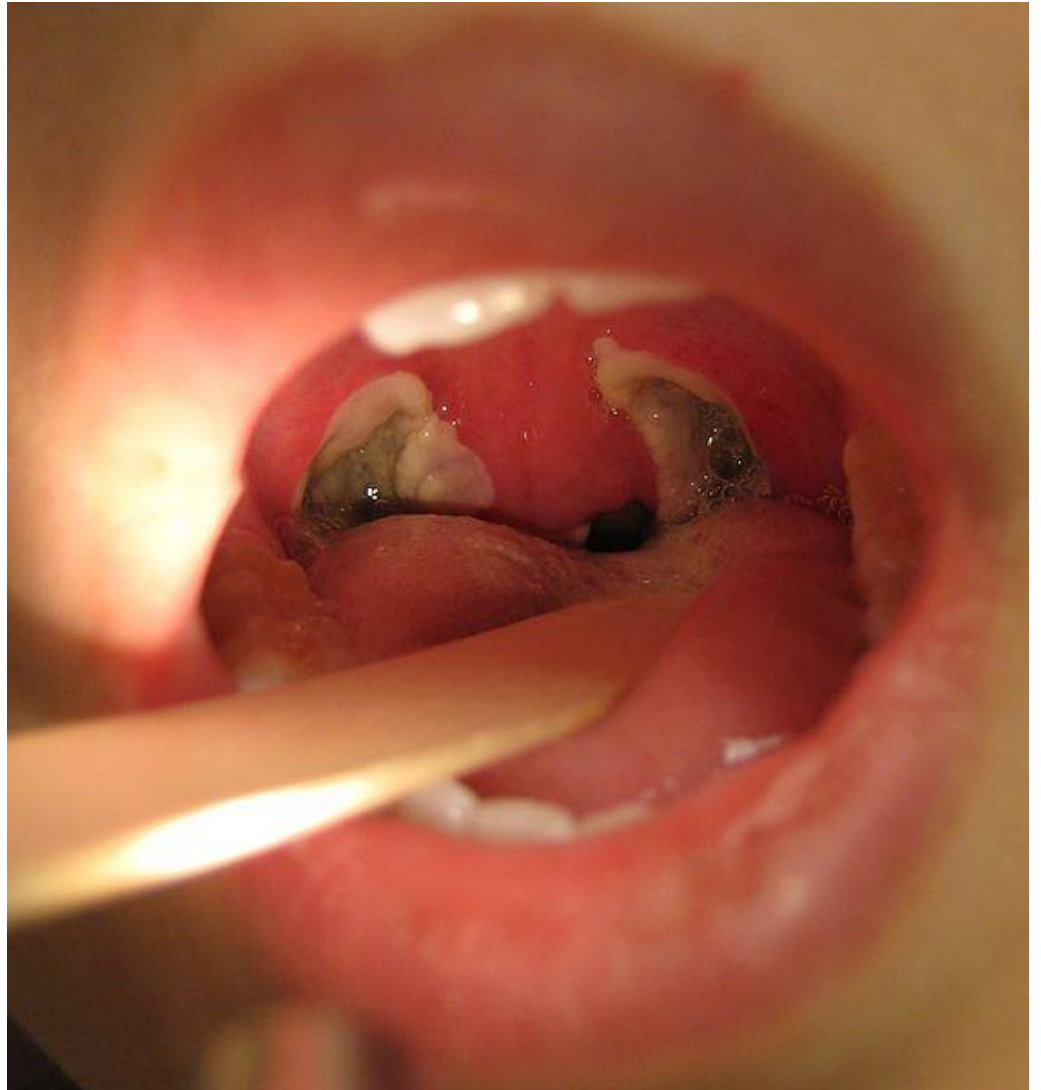
- What is your diagnosis?
- How to confirm your diagnosis?
- What is your treatment?

- Peritonisillar abscess
- Needle aspiration and culture of fluid (??!!)
- IV antibiotics + incision and drainage (under general anesthesia in children and anixous Pts)

Q8:

This patient had tonsillectomy before one week:

- What are you seeing
- Give 2 indications for tonsillectomy
- give 2 complications of tonsillectomy.



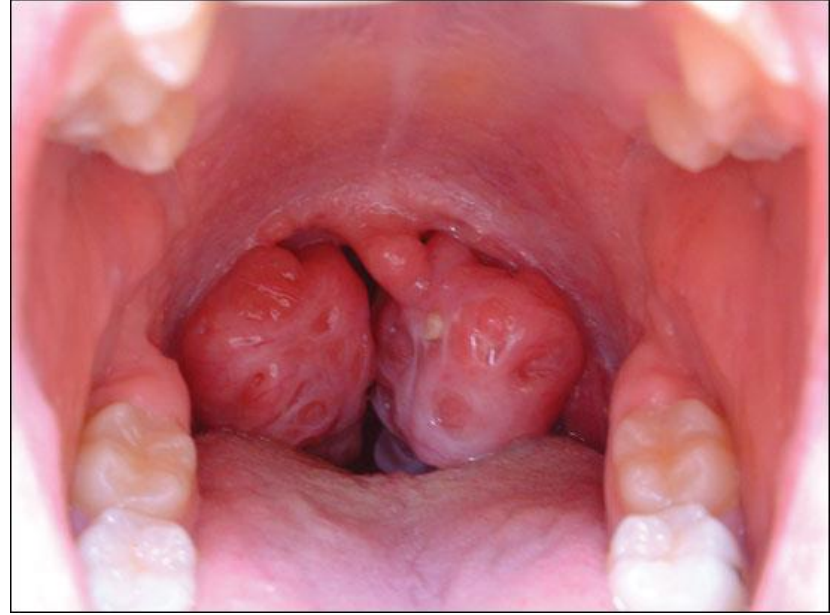Q7

- 1- Typical white membrane appearance of the back of the throat post tonsillectomy.
- 2-
 - a) airway obstruction
 - b) recurrent attacks (*7 in a year, 5 per year for 2 years, or 3 or more per year for 3 years*)
 - c) *tonsillitis complicated with peritonsillar abscess*
 - d) *suspected malignancy*
- 3-
 - a) *bleeding (the three phases)*
 - b) *infection*
 - c) *peritonsillar abscess*

Q9

- **Mention 4 indications to do tonsillectomy**
- Sleep apnea
- Acute Airway obstruction
- Febrile seizure
- Peri-tonsillar abscess resistant to medication
- For biopsy

Question 10



A young boy presented to you complaining of snoring. This picture is seen on examining the child's throat.

- A) What is your diagnosis?
- B) What is your management?
- C) Give 2 indications for your management.

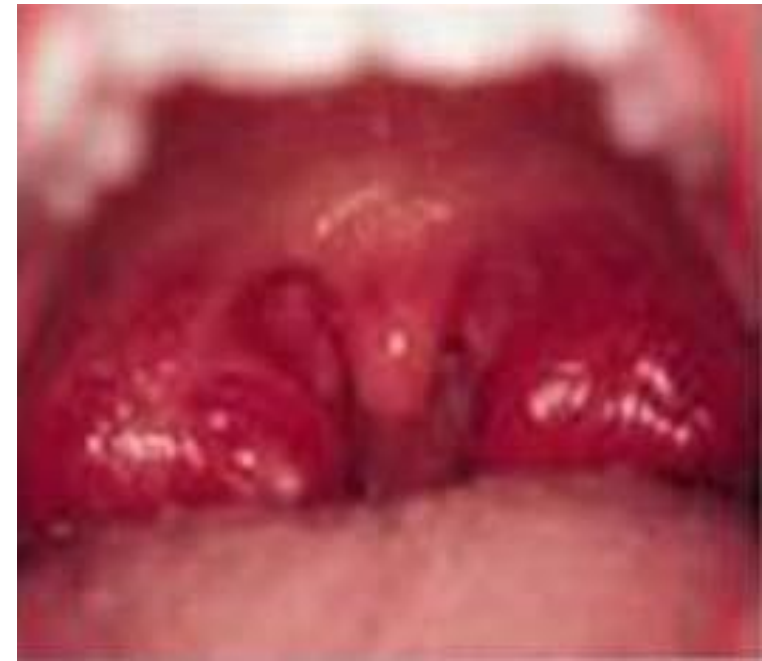Question 10 answers

- A) Tonsillar hypertrophy
- B) Tonsillectomy
- C) 1- Recurrent infections
2- Sleep apnea
3- Dysphagia

Q11

- A child presented with recurrent apneas with these tonsils
- 1) What is your diagnosis ? Hypertrophied tonsils

2) What is your treatment
tonsillectomy

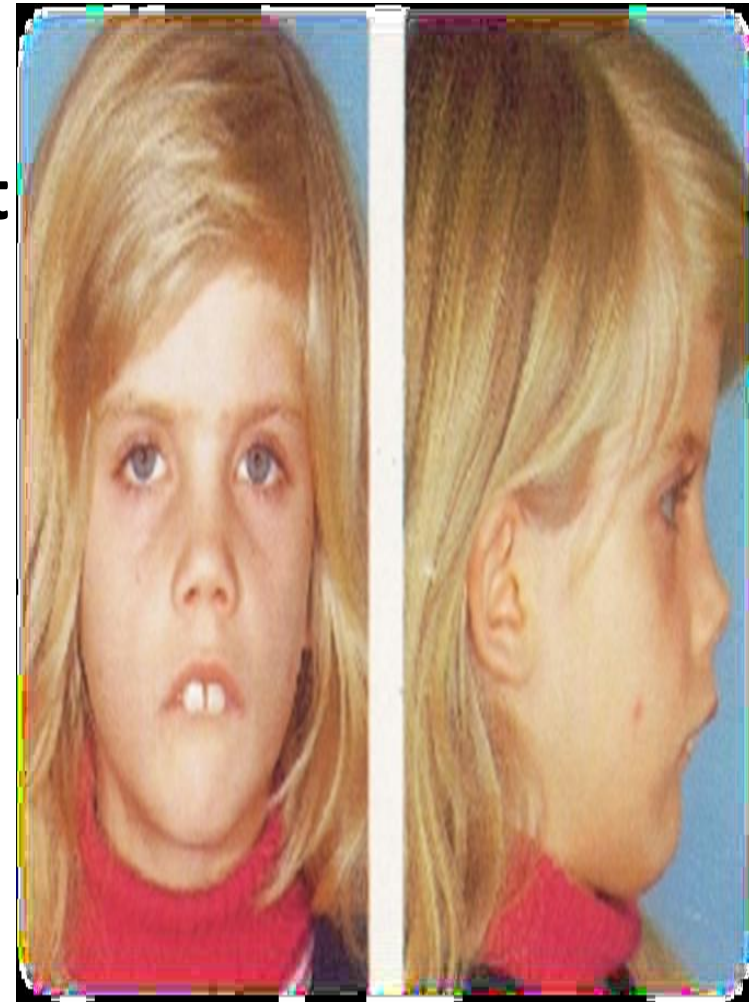

Q12

- 1- pic for acute tonsillitis (the q : 1- wt is the Dx 2- treatment 3- mention 2 complications)

Q13

- **this 5 year old girl came with her mother to the clinic, the mother said that her daughter have nasal obstruction, snoring and mouth breathing.**
- 1-what is your diagnosis.
- 2-give 2 complications for this.
- 3-how do you treat.



- 1-adenoid hypertrophy.
- 2-A. otitis media with effusion.
- B. obstructive sleep disorder.
- 3-adenoidectomy.

Q14

Snoring, mouth breathing, flat midface, dark circles around the eye.....

- What is your diagnosis?
- Mention 2 complications?
- What is your treatment?

- Adenoid hypertrophy
- Eustachian tube dysfunction leading to OM

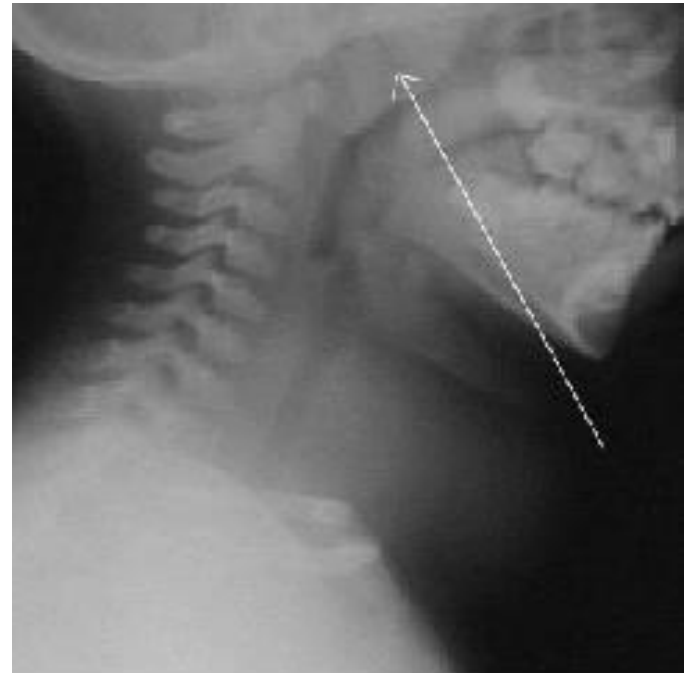
Malocclusion

OSA

- Rx: adenoidectomy

Q15

- A child with a Hx suggestive of adenoids hypertrophy
 - 1) What is your diagnosis
 - 2) Mention 2 contraindications for the surgical intervention



Q16

- **Cant remember case, typical adenoid hypertrophy case**

- - diagnosis?
- - 2 complications

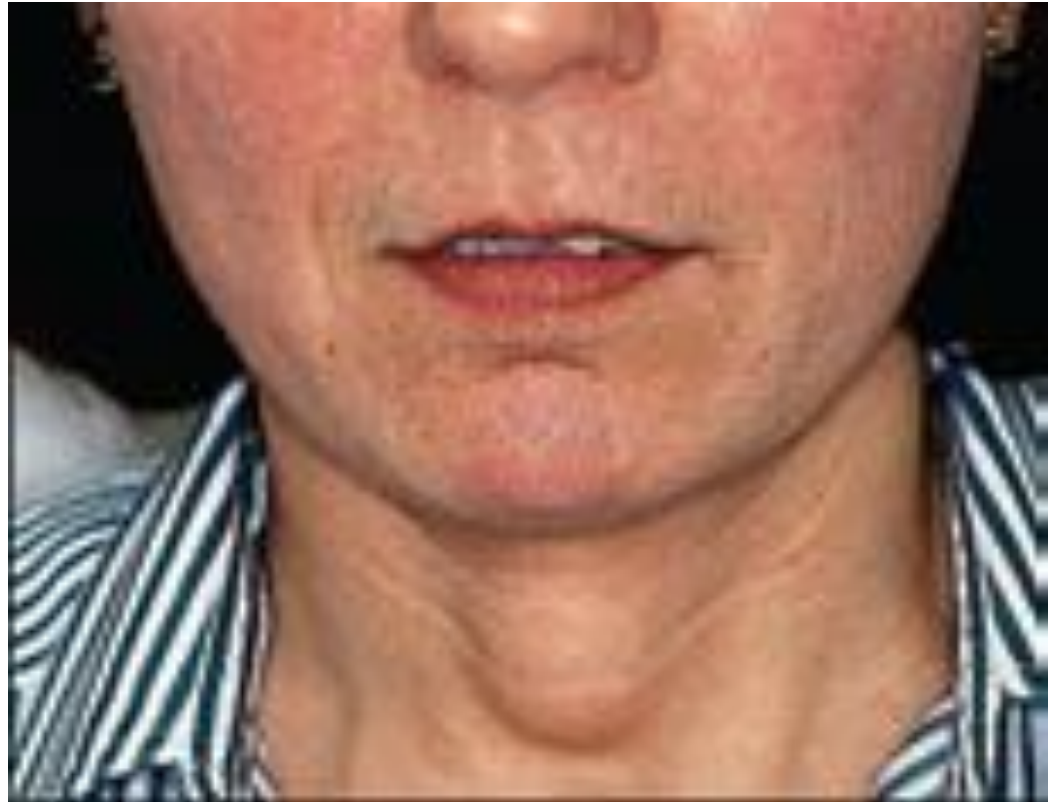Sleep apnea, malocclusion

- -treatment
adenoidectomy

Neck masses and other masses

EXTRA INFO *A midline neck mass thyroglossal cyst*

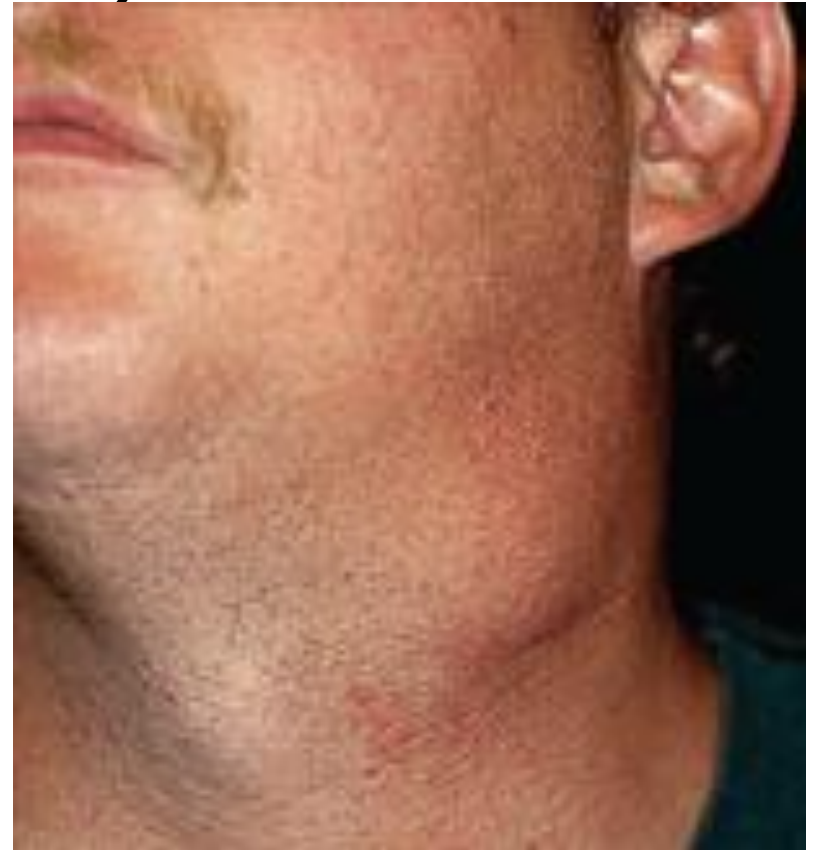- The most common
- usually presents in the midline and elevates with swallowing or tongue protrusion. To distinguish it from a congenital dermoid cyst.



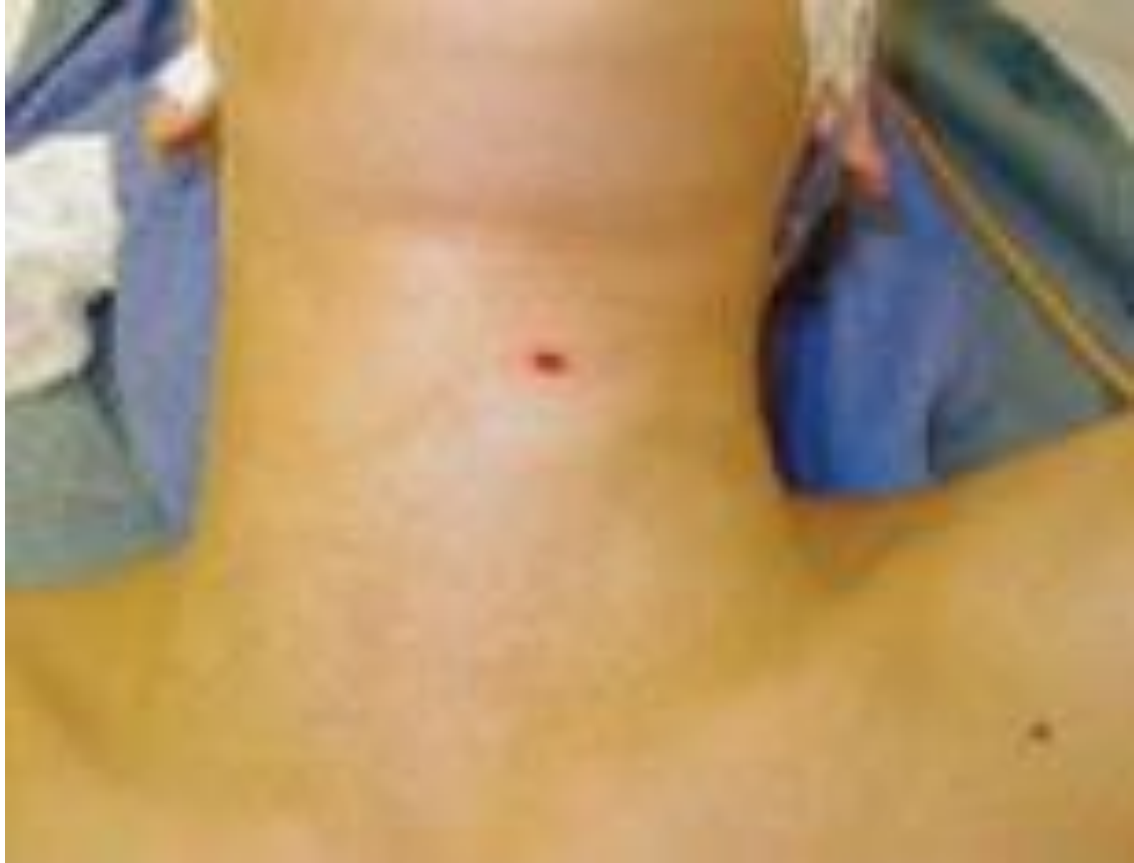EXTRA INFO *A lateral neck mass, ant.*

Triangle — a branchial cyst.

- present in early adulthood,
- occur anywhere along the anterior border of the SCM
- seem to appear rapidly following an URTI.

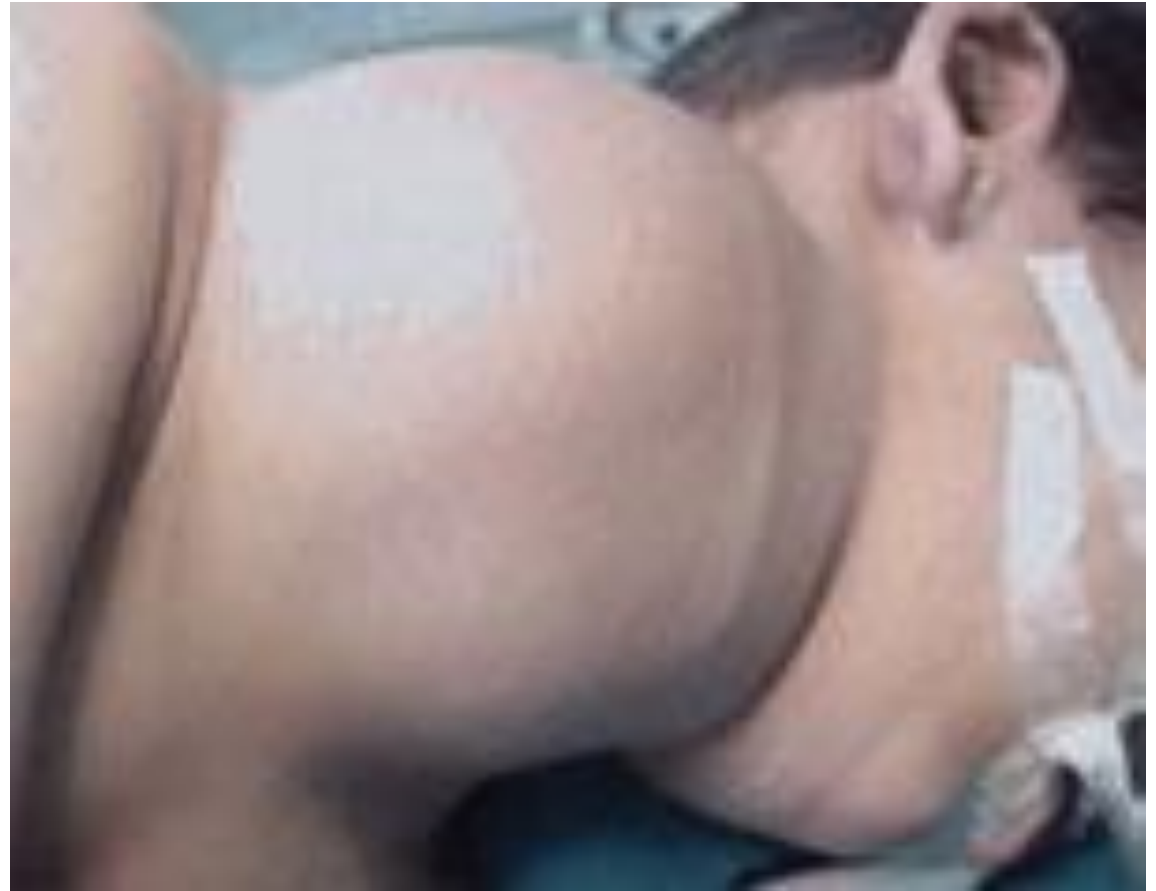

EXTRA INFO *A branchial fistula.*



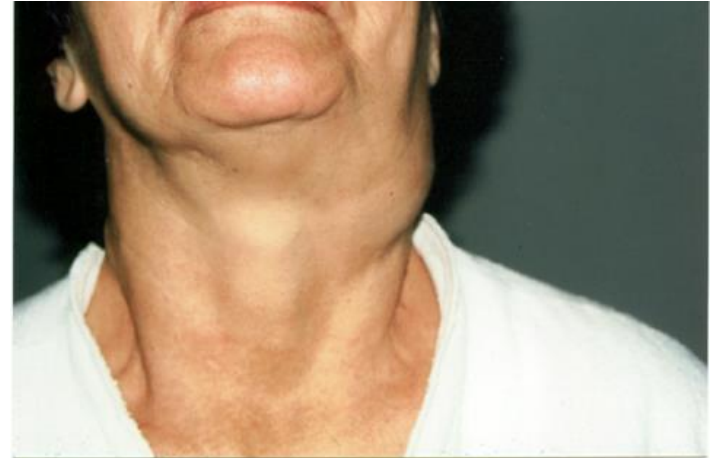EXTRA INFO *A cystic hygroma.
Lateral neck , post. Triangle*

Lymphangiomas
present
in early infancy
and can often be
transilluminated.



EXTRA INFO Carotid body tumor

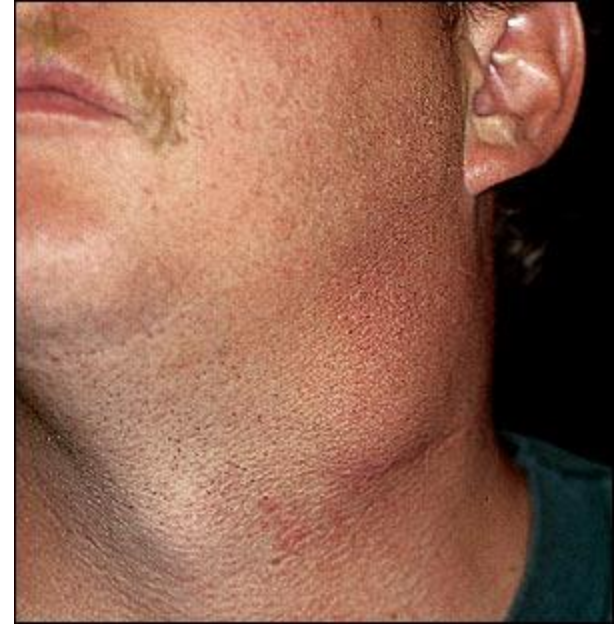
- Originate from small chemoreceptive and baroreceptive organs
- Located at the **adventitia** of the common carotid artery bifurcation.
(paragangliomas)



Question#1

40 year old male patient presented with multiple enlarged cervical lymph nodes over the past 6 months:

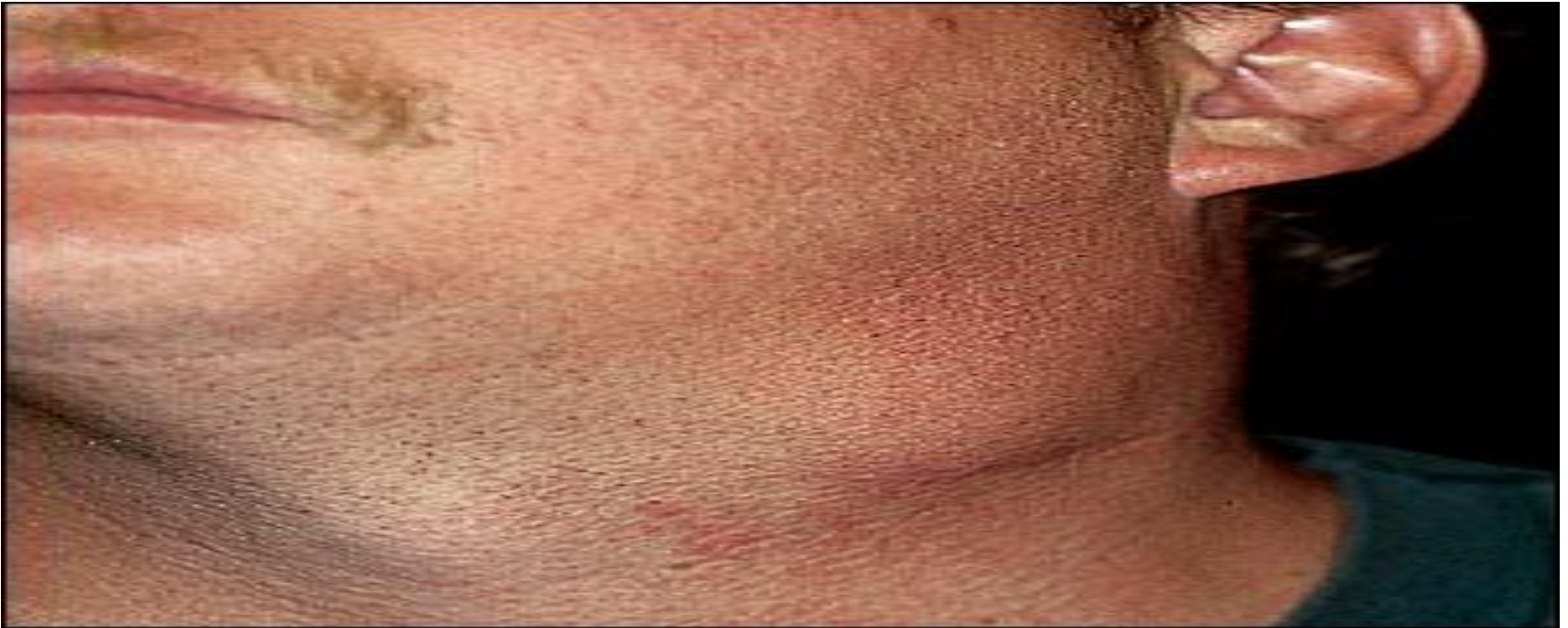- 1) Give 2 DDX
- 2) What are the investigations
- 3) If the patient had glue ear what do you want to do next as an investigation ?



Answers to Question#1

- 1) Lymphoma , Lymphadenopathy (Infectious mononucleosis, ...), branchial cysts.
- 2) FNA , US
- 3) Nasopharyngoscopy

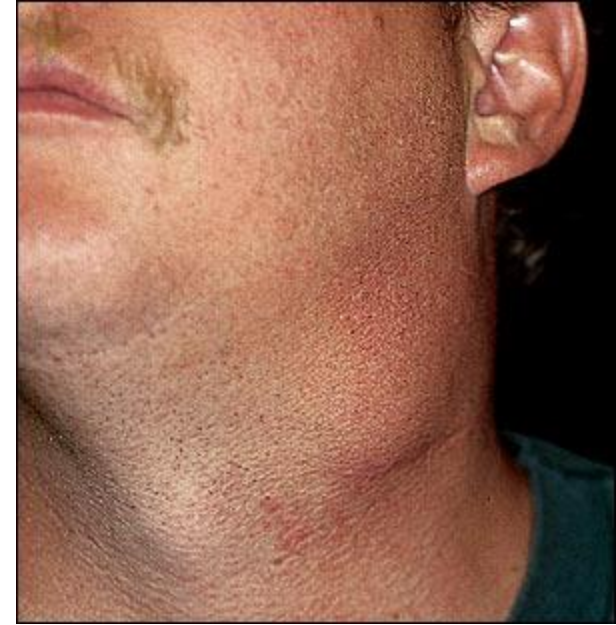Q2



- a+b) mention 2 differentials
- c) What is the best investigation to start with
 - US

Question 3

I couldn't find the picture we had!



Patient presented with neck mass, anterior to the Sternocleidomastoid muscle.

- A) Give two differential diagnosis.
- B) Give two investigations.

Question 3 answers

A) 1- Lymphadenopathy (lymph node enlargement)

Dermoid cyst

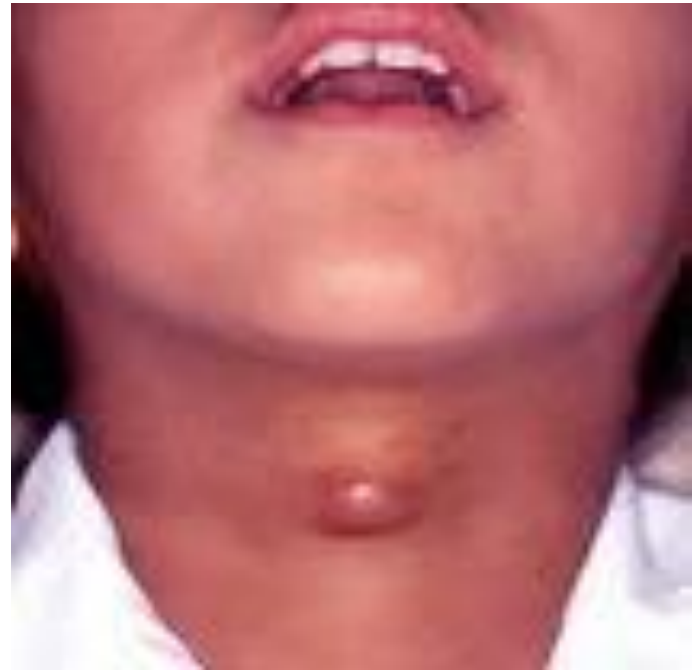2-

B) 1- CT scan with contrast

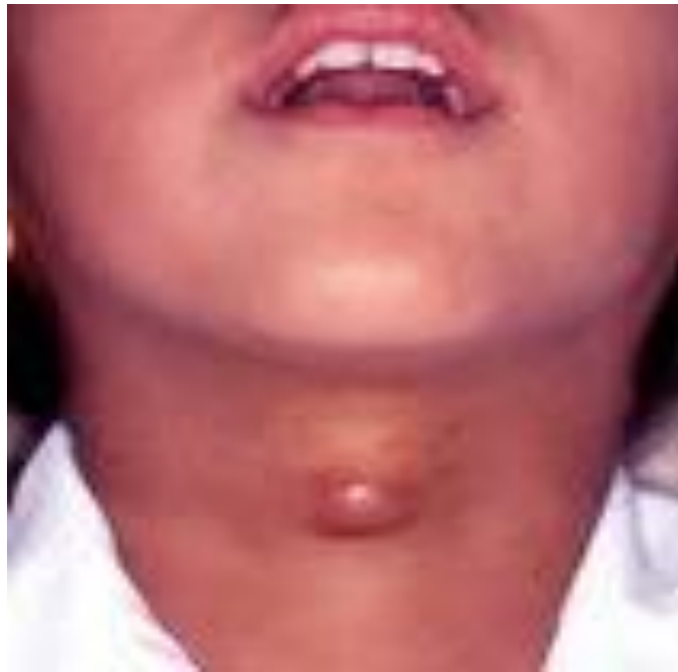2- FNA

Question #4

- This patient presented with a PAINFUL mass.
1. Give 2 differentials.
 2. Mention 2 investigations.



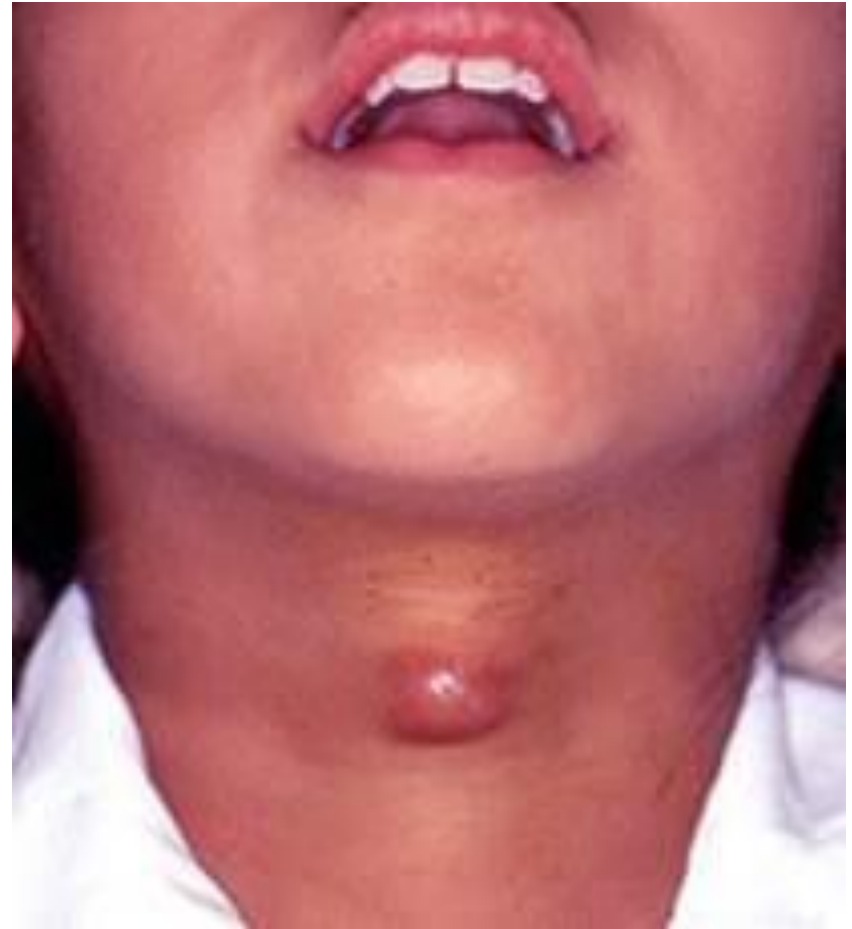- **Q 5...**
- **1)what is this?**
- **2) give 2 other midline masses?**



1. Infected Thyroglossal cyst, infected Dermoid cyst , infected thyroid nodule (not sure).
2. Ultrasound, FNA?, CT scan.

Q6

- Mention 3 differential Diagnosis?
- What is your next Investigation?

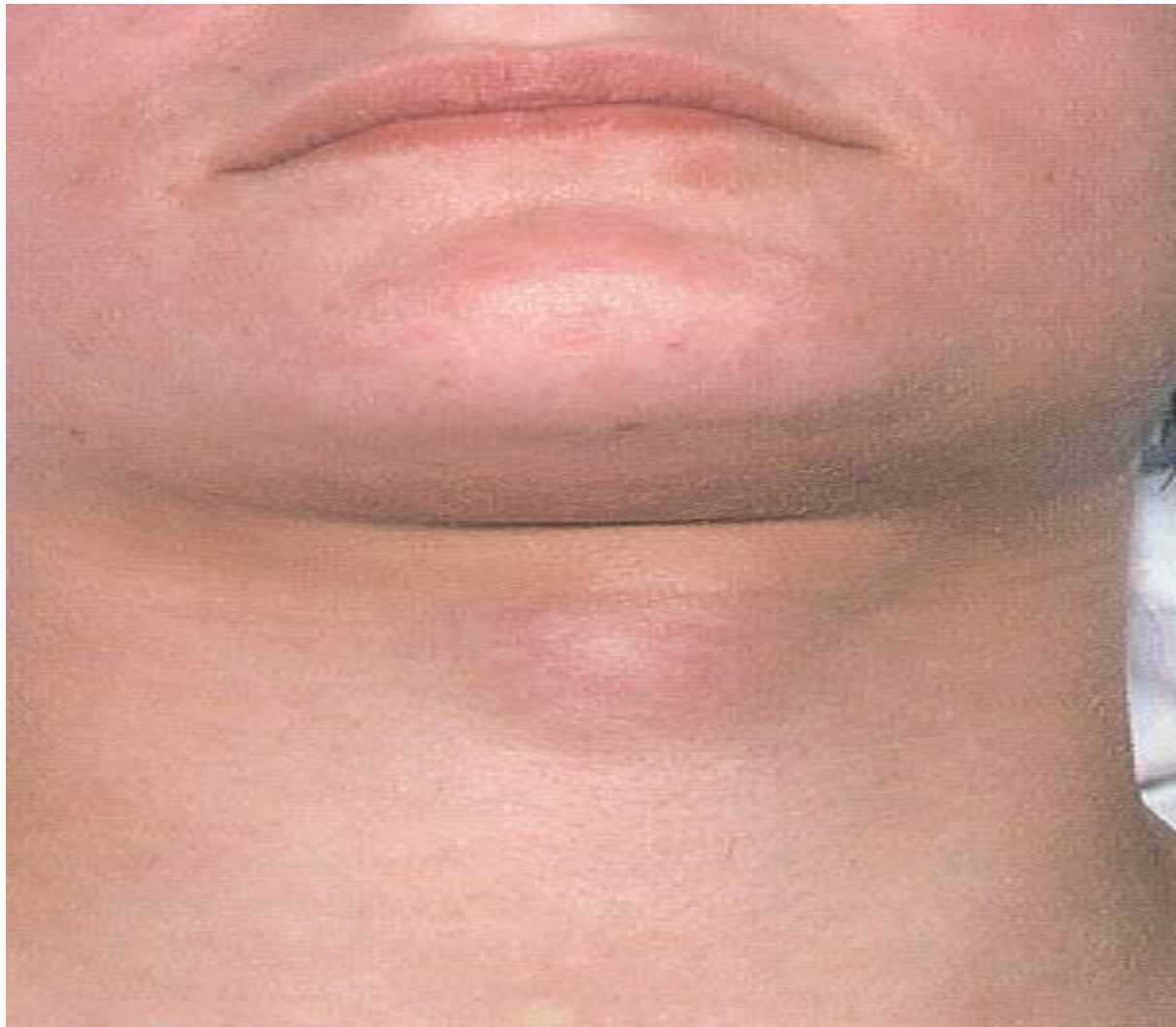

1.thyroglossal cyst

2.dermaoid cyst

3.goiter

- Ultrasound



This mass moves with protruding tongue

1) What is your diagnosis ?

Thyroglossal cyst

2) Mention 2 differential diagnoses?

goiter, dermoid cyst, lipoma

- Q7) A picture of central neck mass moves with tongue protrusion

1-what is this :thyroglossal cyst

2-how it is formed

vestigial remnant of thyroglossal duct

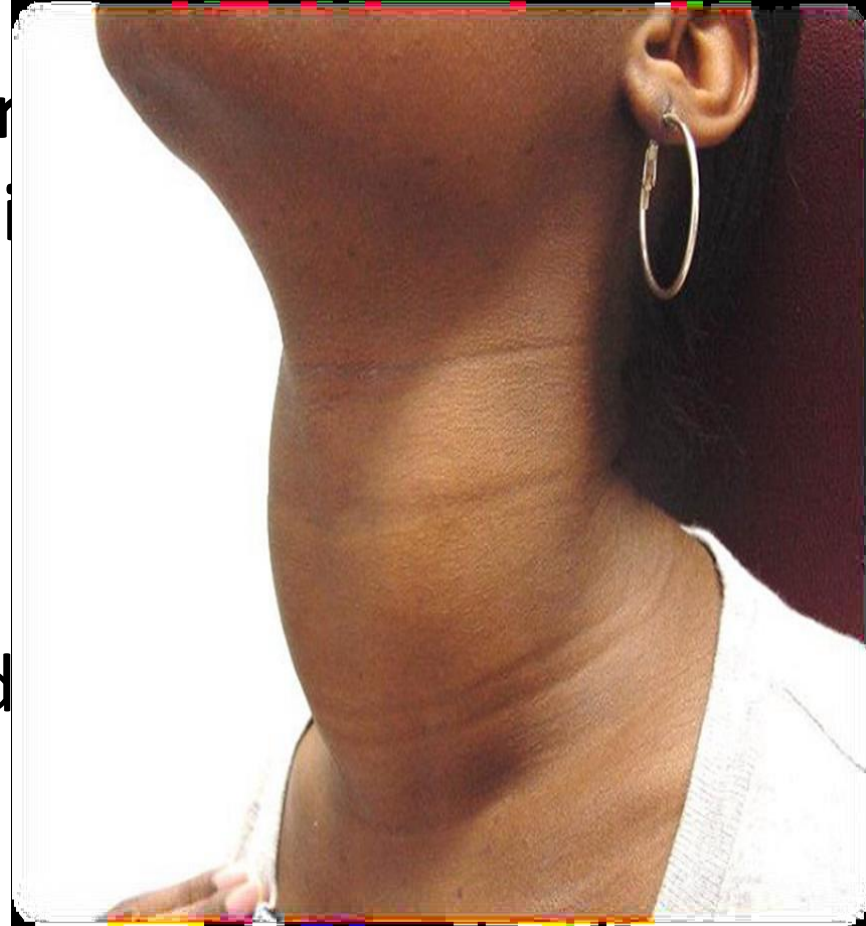
Rx: complete excision (sistrunk procedure:
removal of central portion of hyoid + complete
excision of thyroglossal duct)

Q8

- **15 year old female can**
complaining of this mi
line mass.

1-give 2 differential
diagnosis.

2-what do you want to d
next.



Q9

- 1-goiter, dermoidcyst, thyroglossalcyst , lipoma.
- 2-ultrasound.

Q10

- **Mention 3 DDx**

Lymphadenitis

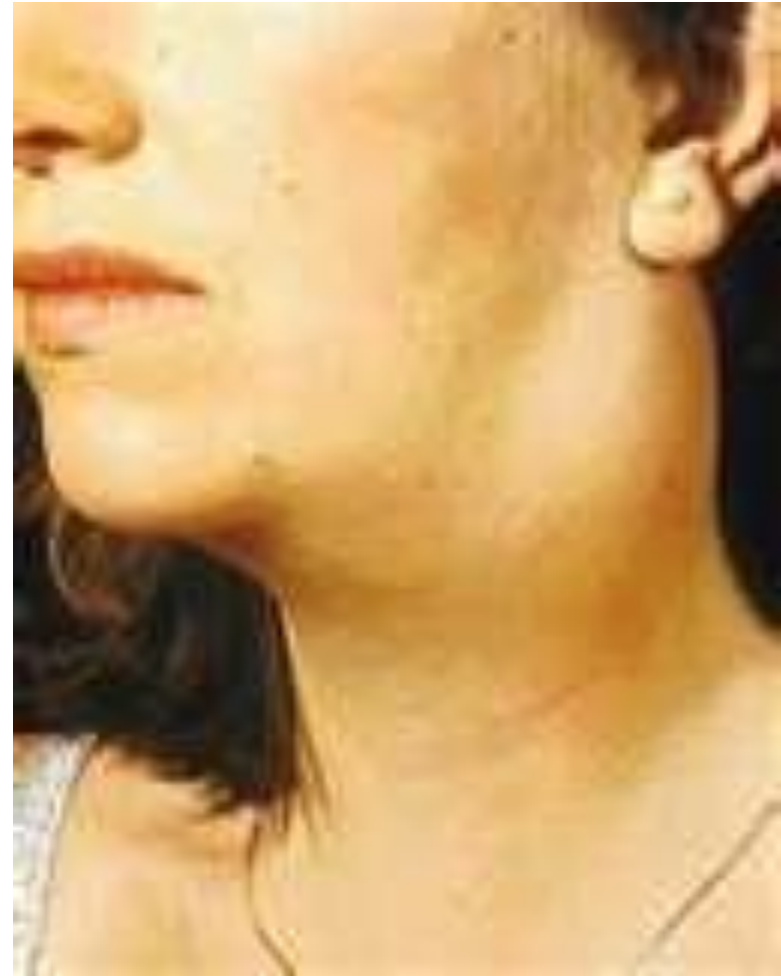Branchial cyst

Lymphoma

Carotid body tumor

- If infection was excluded, what is the first investigation to be done?

FNA



Q11: 50 year old male presented with a history of painless swelling as in the picture.

- **What is the origin of this swelling?** Parotid gland
- **Give 2 causes?** Malignancy, benign adenoma



Malignant 20% (mucoepidermoid most common), benign 80% (pleomorphic adenoma)

Q12

- A Hx of painless mass for 2 yrs in a young adult

(there were 2 pics, 1 for a large mass below the chin and another one for an axial head CT showing the mass!!,, actually I dnt know what they were thinking about!

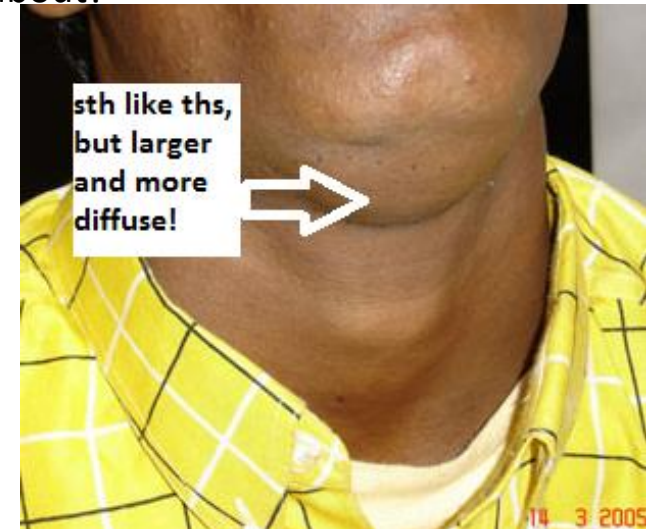
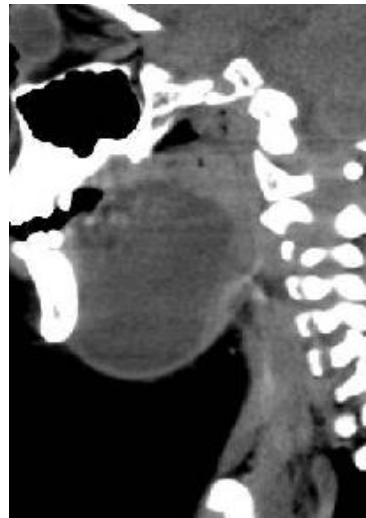I didn't find anything that looked like the pics they brought,
but these 2 are examples)

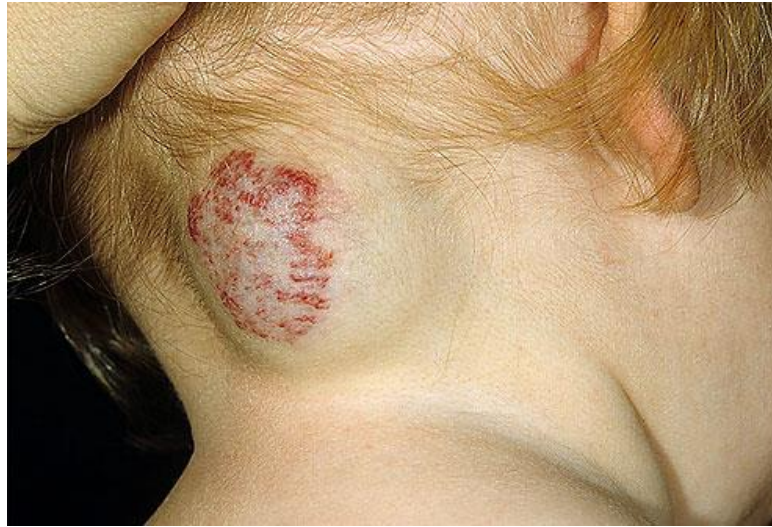1) What is your diagnosis?

(ranula, lipoma, dermoid cyst,, I dnt know :()

2) What is your treatment?

3) Give 1 DDx.





- What is your diagnose? (**Hemangioma**)
- What is the treatment?
- Mention one investigation you will do for this child.

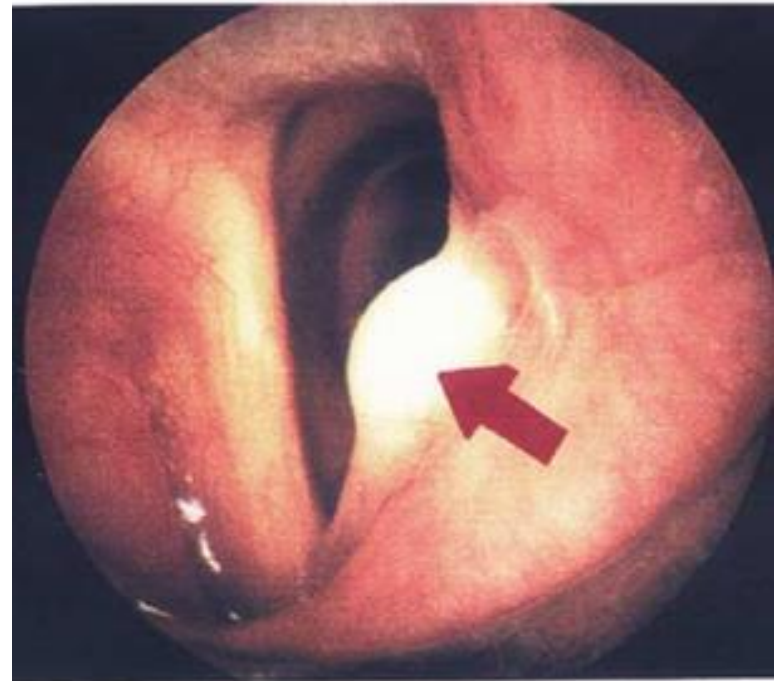
Larynx

Hoarseness Of Voice

- If cancer --- in elderly, most common is SCC, next is supraglottic CA
- Smoking --- nodule on the vocal cord.

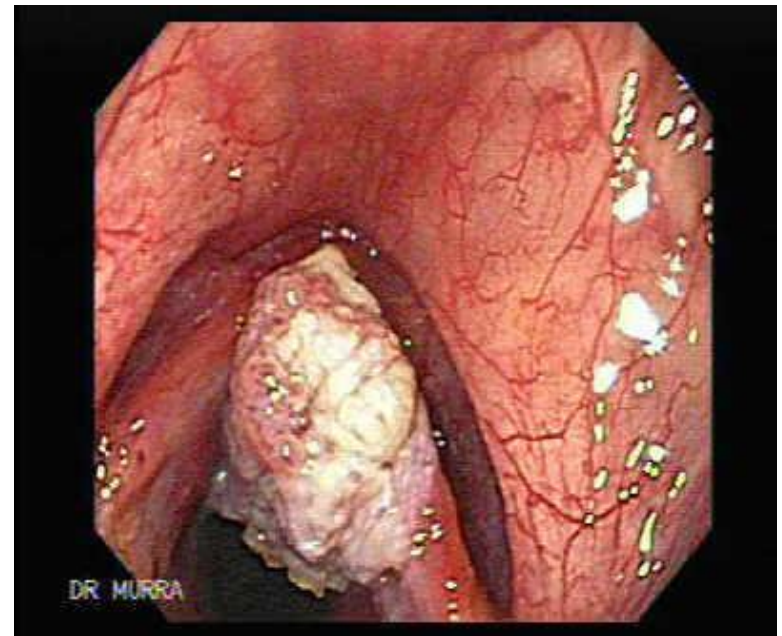
Q1.Hx of smoking, old age, male, hoarseness of voice ...
etc

- Dx ?
- Laryngeal cancer...
- Commonest histological type?
- Scc...
- 2 lines of Rx ?
- Surgery , Radiotherapy



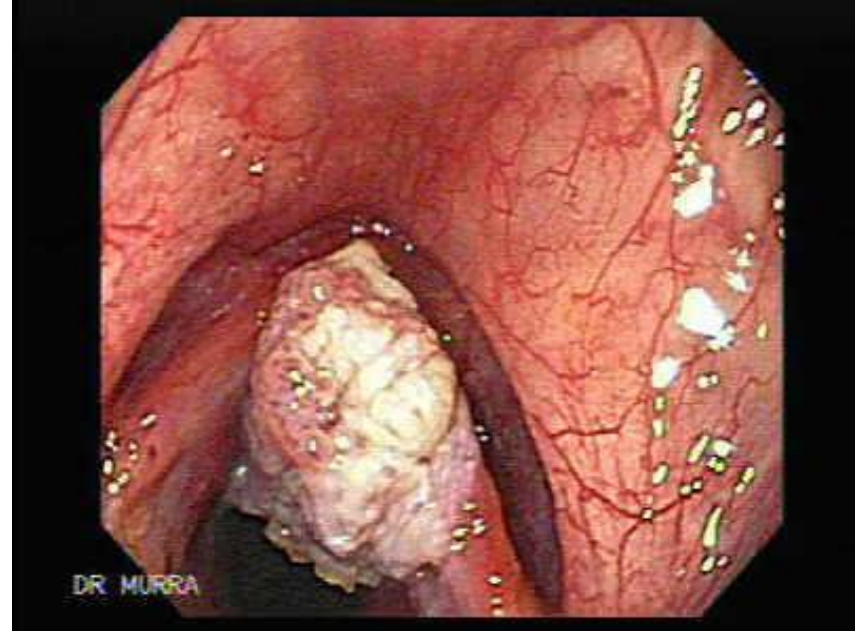
Question #2

- This patient had a history of hoarseness of voice & this image on Laryngoscopy. The tumor was on the vocal cords.
 1. What's your diagnosis?
 2. What's the most common histological type?
 3. Mention 2 investigations.
 4. Mention 2 modalities of treatment.



1. Laryngeal Carcinoma.
2. Squamous cell carcinoma.
3. CT & Biopsy.
4. Surgery & Radiotherapy.

Question 3



This is a patient with Laryngeal carcinoma complaining of hoarseness of voice

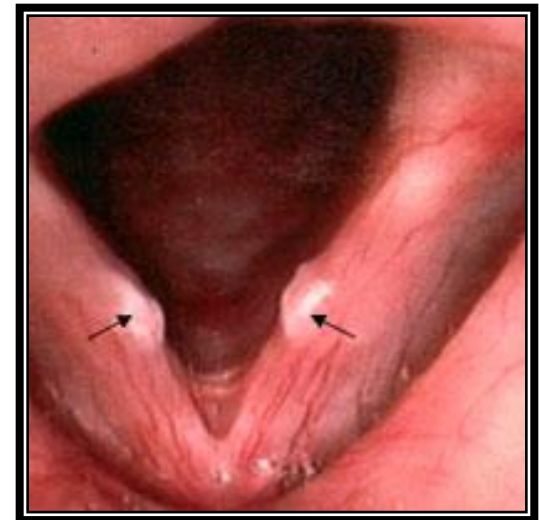
- A) What is the most common type of laryngeal cancer?
- B) Give two predisposing factors.
- C) Suggest two other complains.

Question 3 answers

- A) Squamous Cell Carcinoma
- B) 1- Smoking
Voice abuse (screaming, singing) 2-
- C) 1- Cough
2- Stridor
3- Sore throat (feeling of something stuck!)
4- Bad breath

Q4: This picture is a laryngoscope for adult female presented with a 2 months history of hoarseness of voice.

- **What is your diagnose?** Vocal cord nodule
- **Give 2 risk factors?** Voice abuse, smoking
- **two lines of treatment?**
 - voice rest
 - speech therapy
 - surgery for resistant cases



Q5:

1. What is the diagnosis?

Singer's nodule

2. give 2 causes

a) Voice abuse

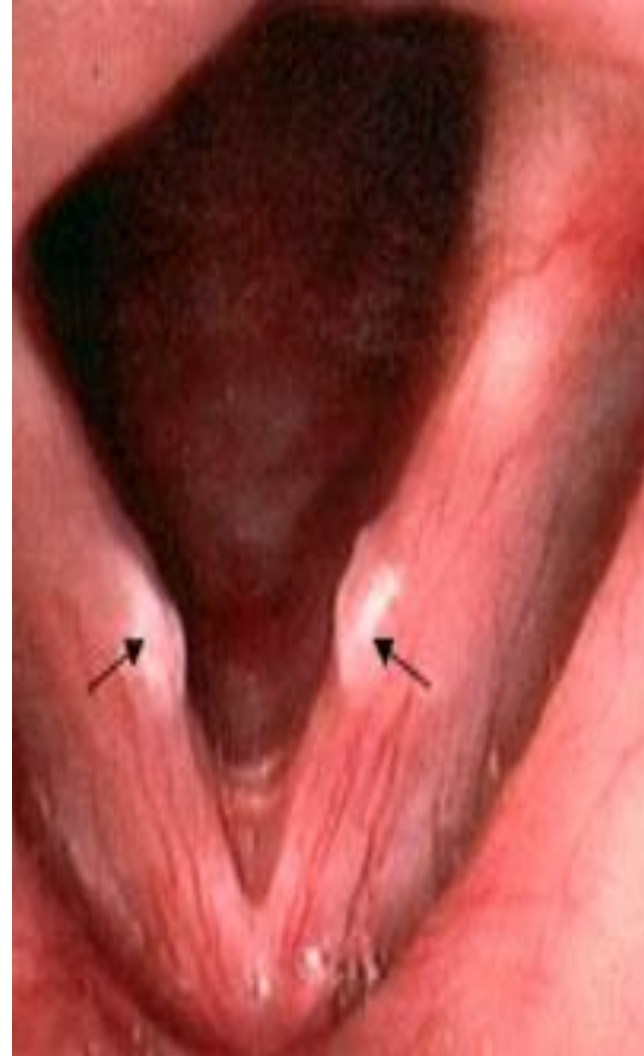b) frequent URTI

c) smoking

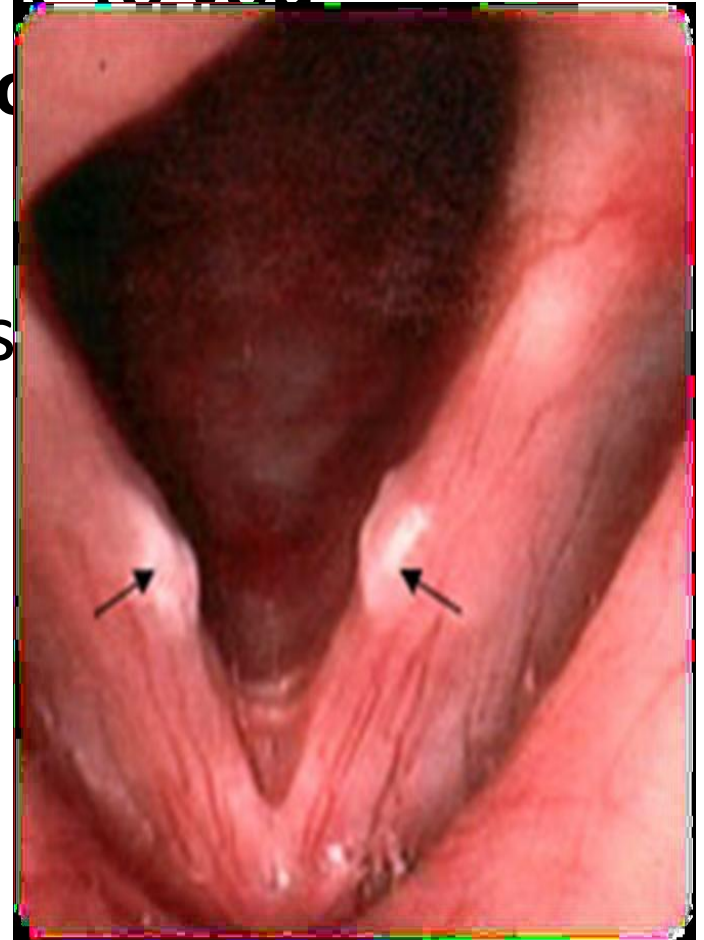
3. what is the treatment?

voice rest / speech
therapy

surgical removal



- **this 35 year old teacher came to you**
complaining of hoarseness of
- 1-what is your diagnosis.
- 2-give 2 precipitating factors
- 3-how would you treat.



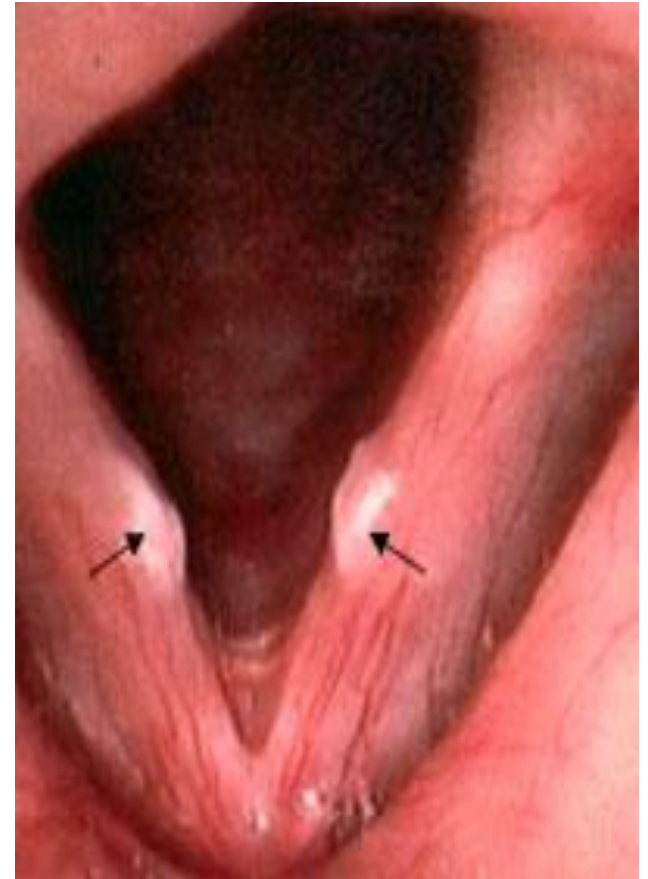- 1-singer nodules.
- 2-A. voice misuse or abuse
- B. smoking.
- 3-voice rest, physiotherapy, then we can do surgical excision

- This for a singer female patient

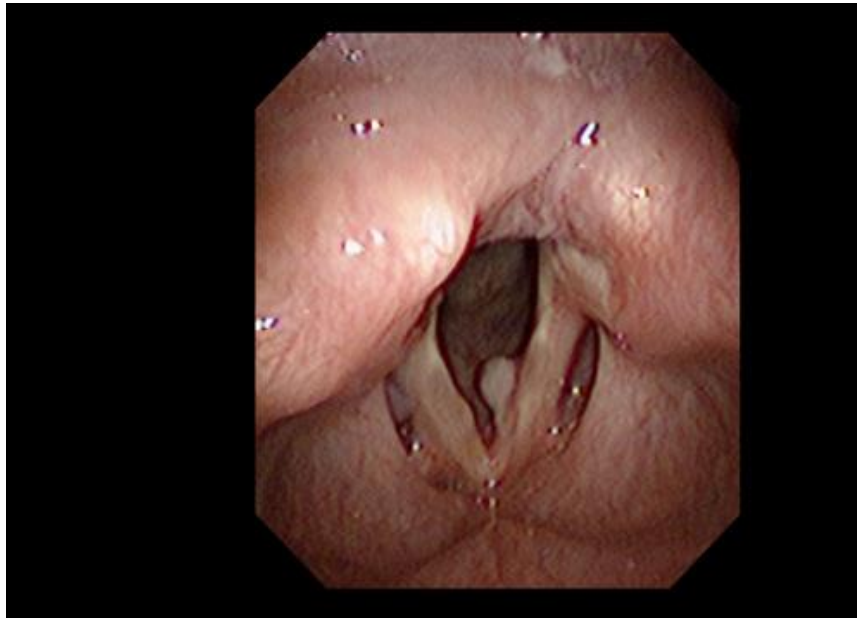
What is ur diagnosis ?

Mention 2 risk factors?

What is your treatment?



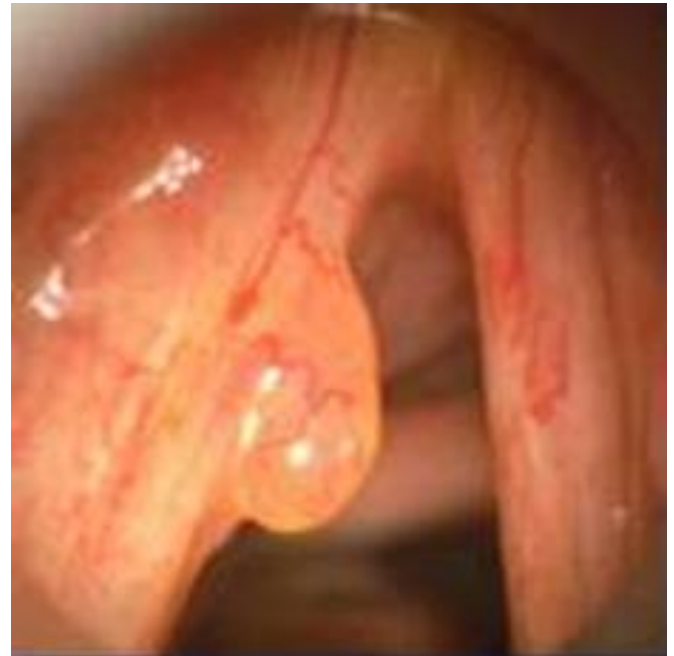- **Q6..history that the patient is teacher & has hoarseness of voice**(from lecture note)
- **1)what is the diagnosis? Singer's nodule**
- **2)give 2 causes? Voice abuse & cough**
- **3)what is the treatment?**

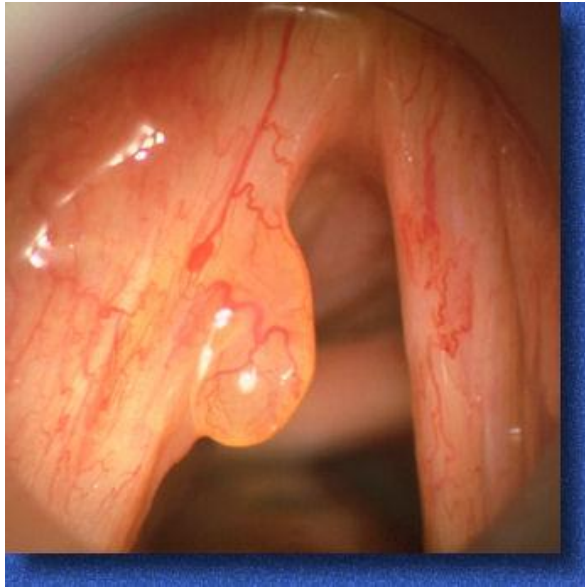


Q7

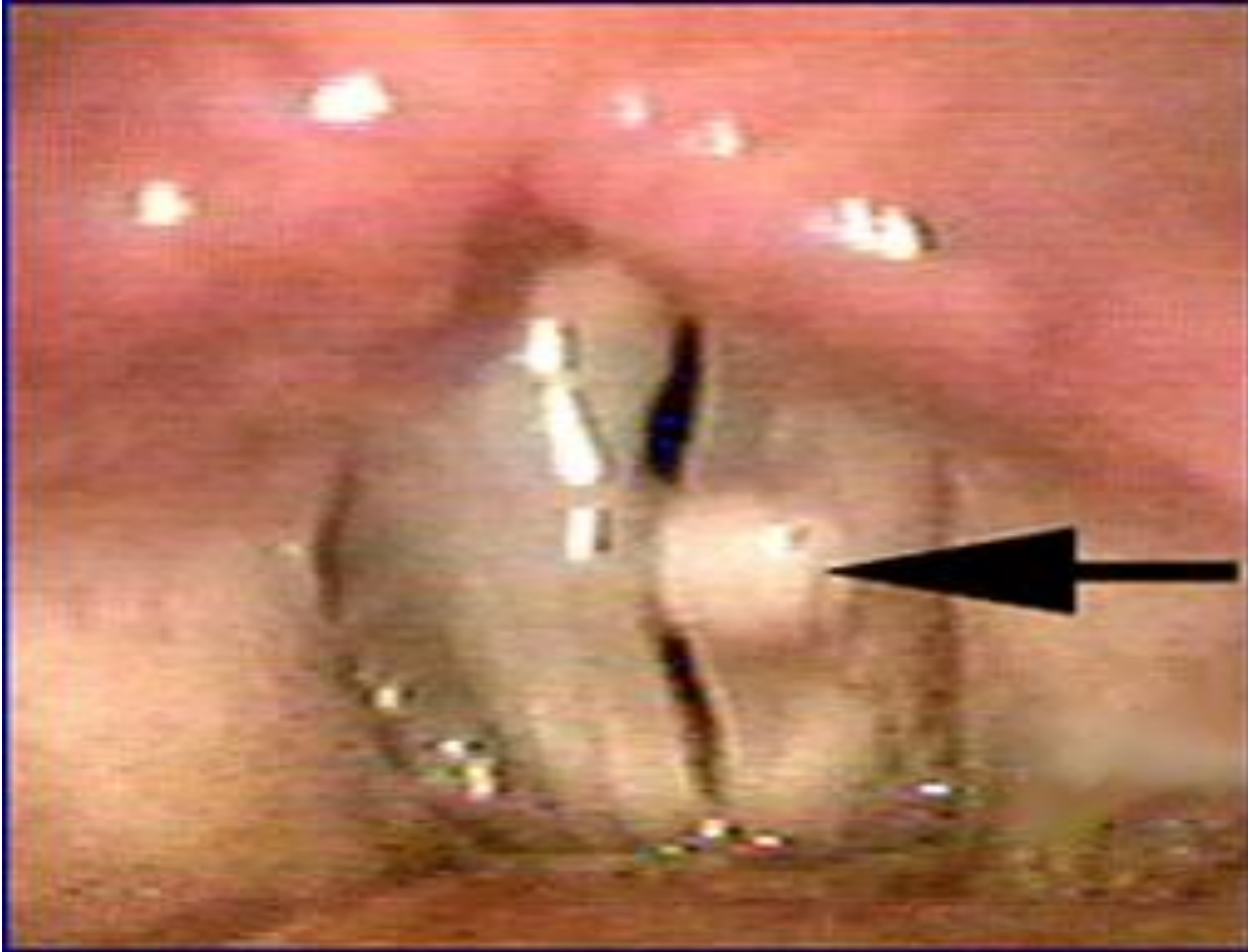- A 20 years old female was found to have this mass
 - 1) Mention 2 risk factors
 - 2) Mention 2 investigations you want to do for her

Vocal cord polyp
GERD, voice abuse





- What is your diagnose?
- How will you treat this patient?



Q8. A 40 year old man smoker presented with change in voice

1) What is your diagnosis ?

Laryngeal cyst

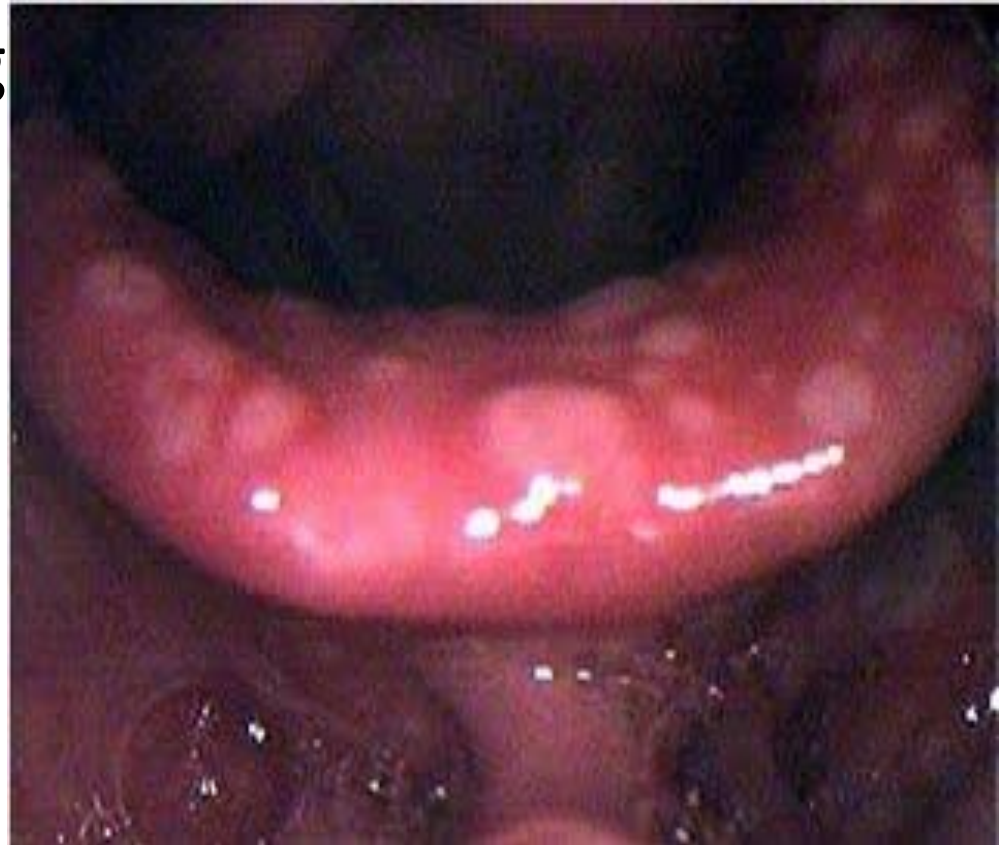2) Mention 2 risk factors ?

Intubation , congenital

3) what is the treatment ? surgery

Q9

- A 7 year old child presented to the ER with stridor and toxic appearance and fever with difficulty in breathing



1) What is the diagnosis ?

2) What is the most common cause for it ?

1) Acute epiglottitis

2) H. influenza type B

Haemophilus influenzae type b

Q10

- **Mention 3 causes of inspiratory stridor**

Foreign body

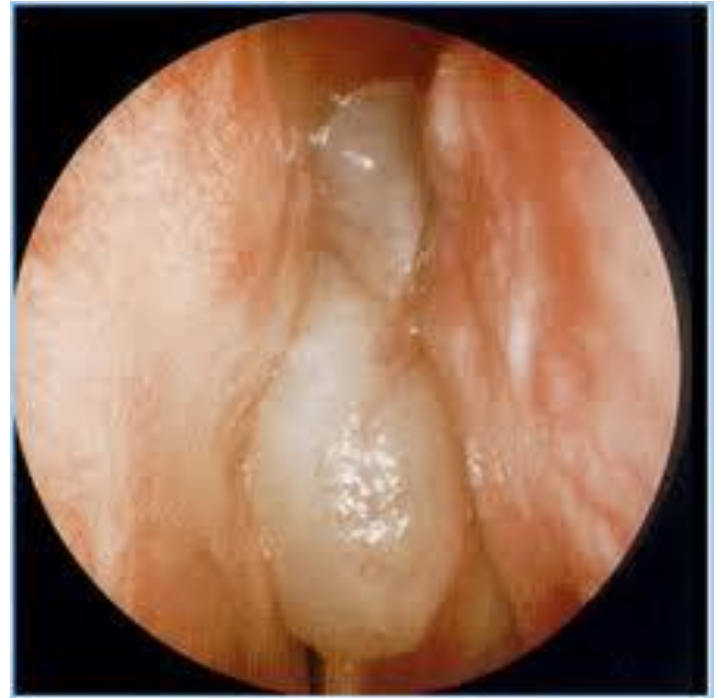Laryngeal tumors

Acute Epiglottitis

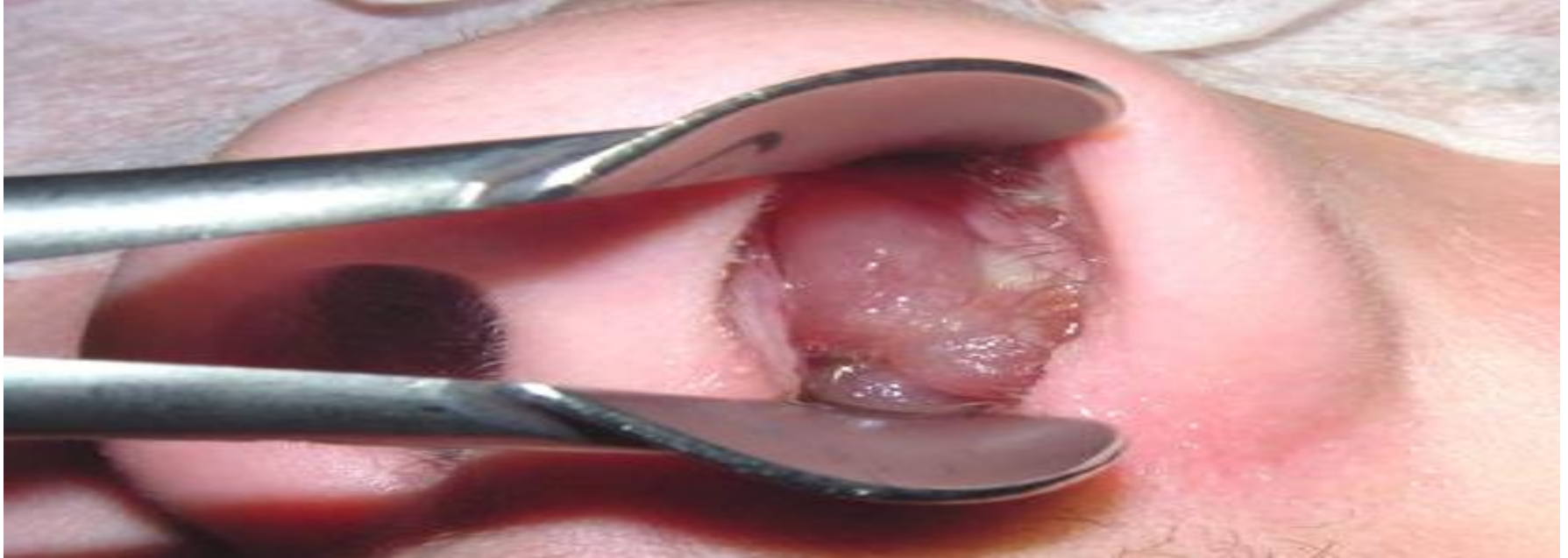Nose

Question #1

- History of a young male with runny nose, nasal congestion & obstruction.
1. What's your diagnosis.
 2. Mention 2 investigations.
 3. Mention 2 modalities of treatment.



1. Nasal Polyp.
2. CT scan & rhinoscopy (rigid or flexible).
3. A. Avoid the allergen, give antihistamine
& local corticosteroids
B. Surgery



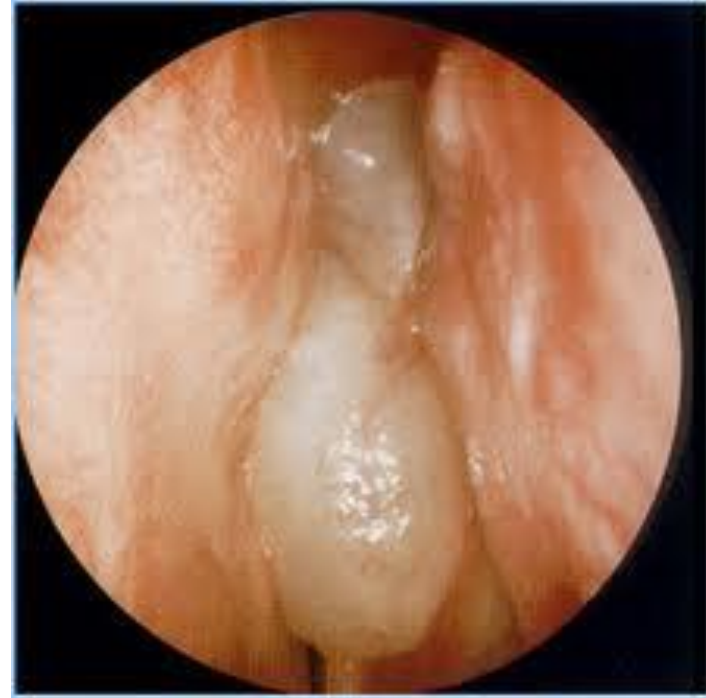- Q2) History of patient with nasal obstruction and rhinorrhea.
 - Diagnosis.
 - What is the mainstay of the treatment.
 - Mention 2 complications.
 - If this condition was associated with aspirin sensitivity and asthma. Name this syndrome?

- Nasal polyp
 - Not sure (but may be everything of allergy management except surgery)
- sinusitis, brain abscess,... mention any 2 complications of sinusitis.
 - Samter syndrome

Question 3

History of a young male with runny nose and nasal congestion, and frequent nasal infections.

- A) What is your diagnosis?
- B) What is your management?



Question 3 answers

- A) Nasal polyp
- B) Surgical excision

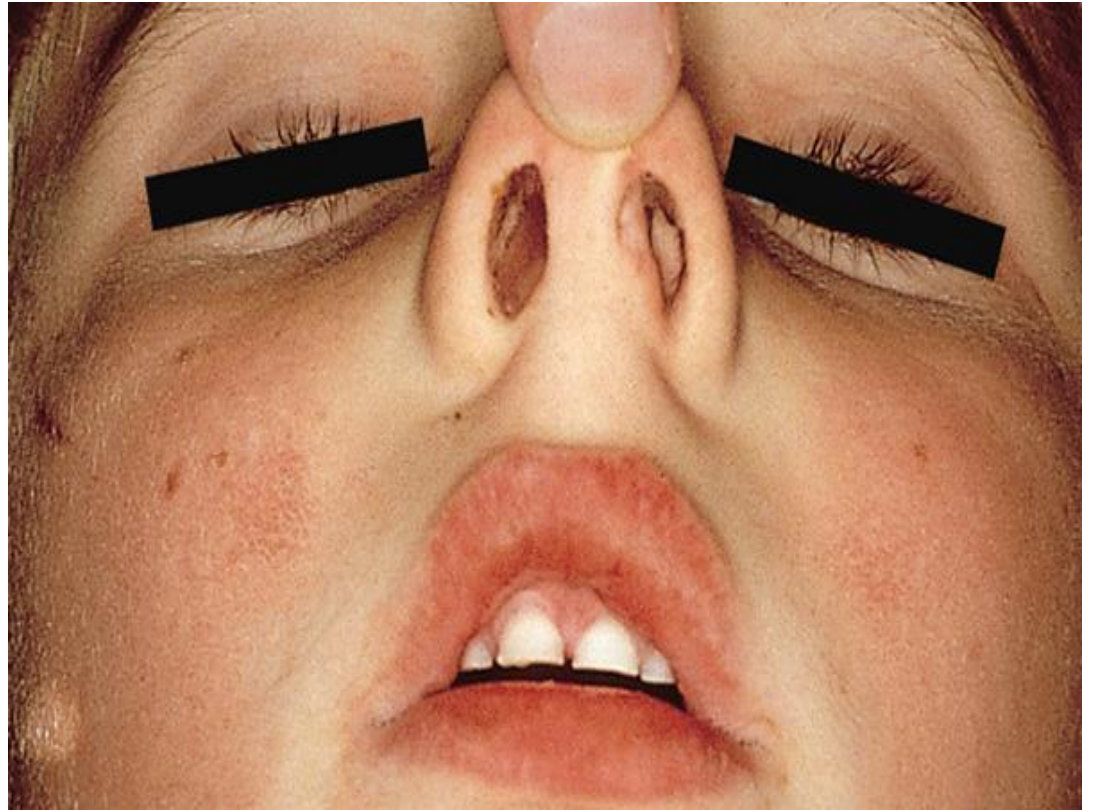Q4:

This child had
epistaxis and
anosmia:

1- what is this
procedure called?

2- give 2
differential
diagnosis

3- give definitive
treatment.



Not the same picture

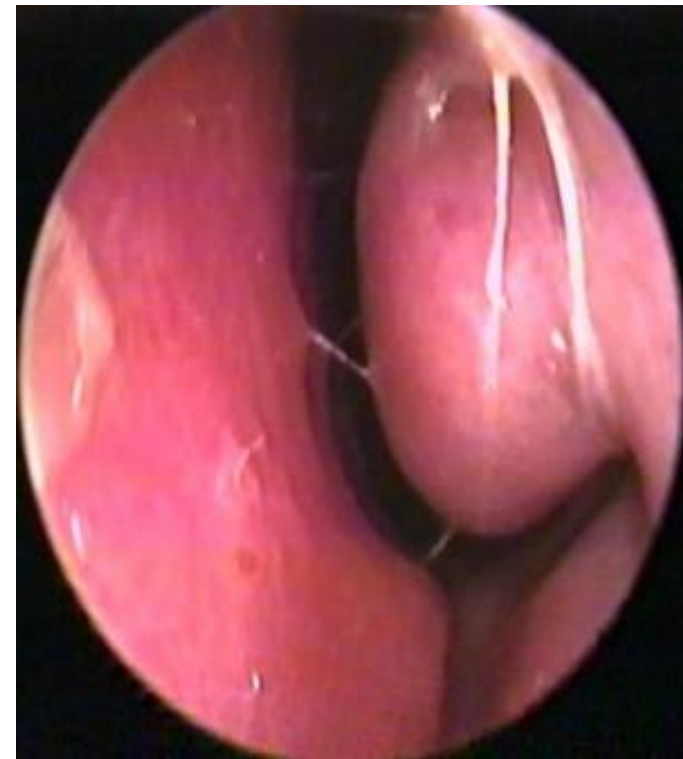
Q4

- 1- anterior rhinoscopy
- 2- a) suppurative Chronic rhinosinusitis
b) asthma
c) cystic fibrosis
- 3- topical steroid (intranasal steroid)

#5

- 25 years old with history of eczema, rhinorrhea. This is a picture of his anterior rhinoscopy

1. What's your diagnosis?
2. What's the treatment (2 points)
3. Give 1 investigation to confirm the diagnosis.

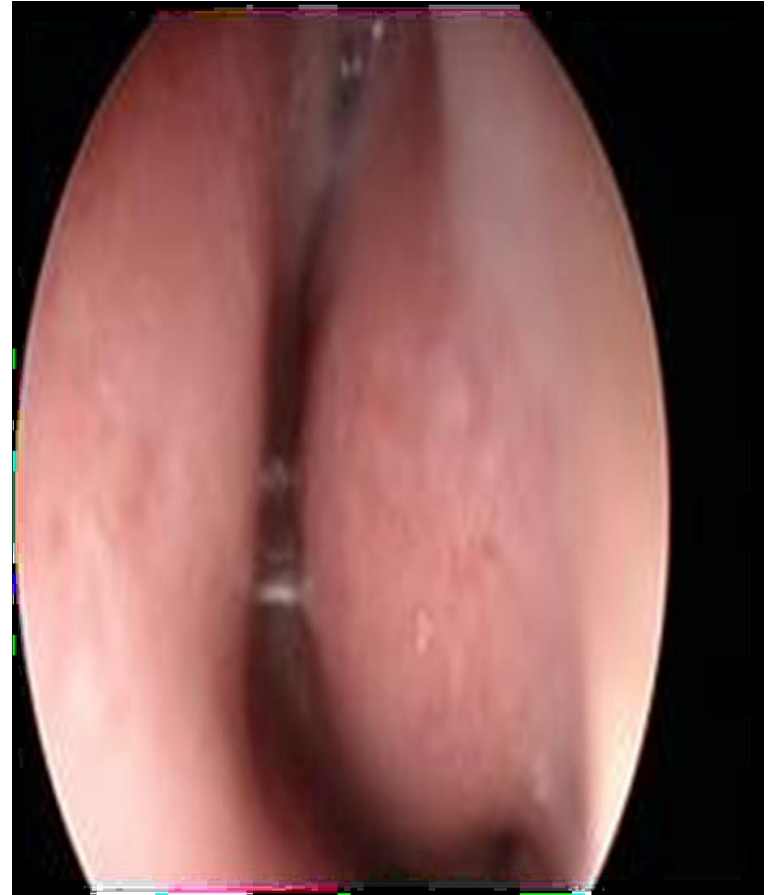

Answers #5

1. Allergic rhinitis
2. A. Avoid allergens
B. Topical steroids, decongestants, antihistamine, cromolyn sodium
3. Skin prick test or RAST

Q6

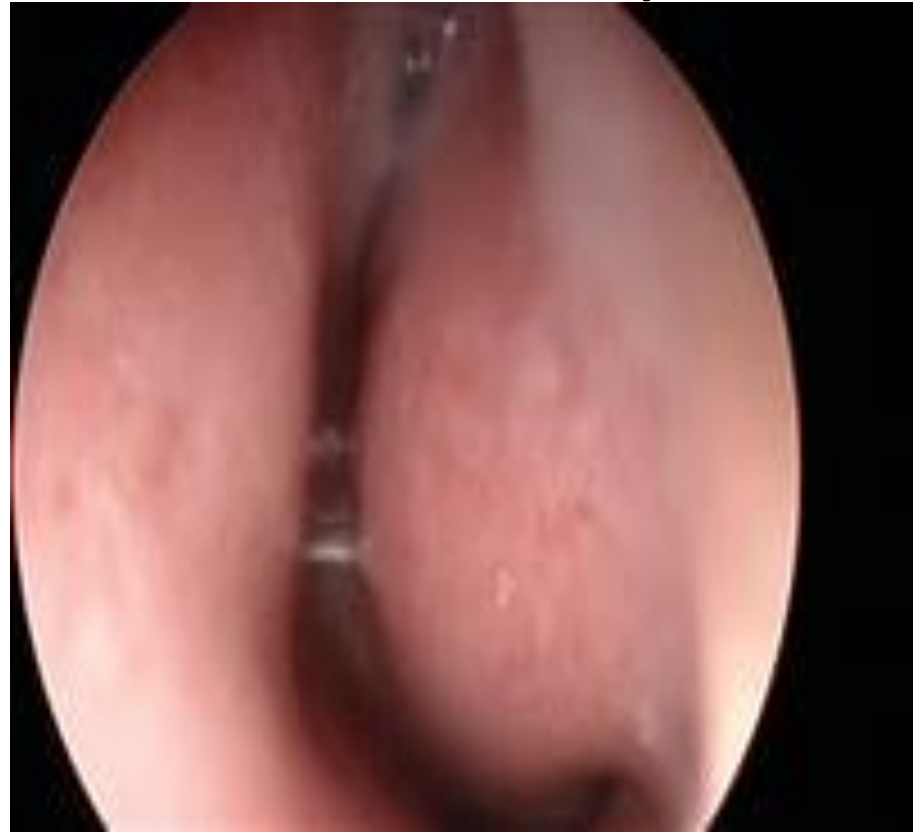- 40 year old female has atopic dermatitis and she complains of sneezing and nasal discharge mainly at spring time came to hospital for her check up and found to have this picture.
- 1-what is your diagnosis.
- 2-how would you treat this condition.
- 3-give one otological complication for this condition.



- 1-allergic rhinitis.
- 2-first avoidance ,antihistamine, analgesia, topical steroids.
- 3-otitis media with effusion

Q7

- A 10 year old male having this pic with runny nose and sneezing that is increased every summer



- 1) What is your diagnosis?
- 2) Mention 2 possible complications?
- 3) what is the main treatment?

- 1) Allergic rhinitis**
- 2) sinusitis, otitis media , etc.**
- 3) Avoid the allergen**

Q8

- **A patient with alternating nasal obstruction, rhinorhea and itching during summer, mention 4 treatment**

Avoidance to the allergic causes

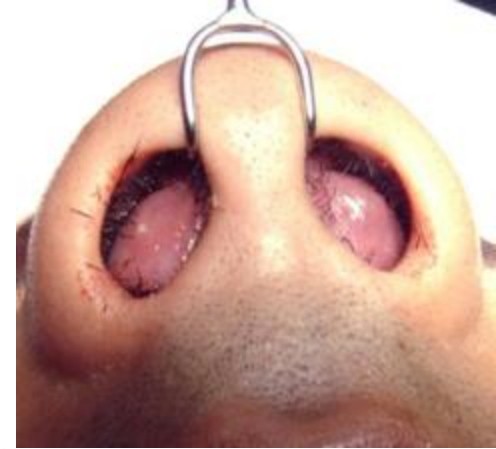Antihistamine

Nasal decongestant

Local steroid

Sodium cromoglycate

Question#9



The patient had a surgery in his nose few days ago :

- 1) what's your diagnosis ? **bilateral septal hematoma**
- 2) What are the complications if we don't treat ? **Necrosis & septal perforation, infection**
- 3) What's the treatment ? **evacuation (incision and drainage)**

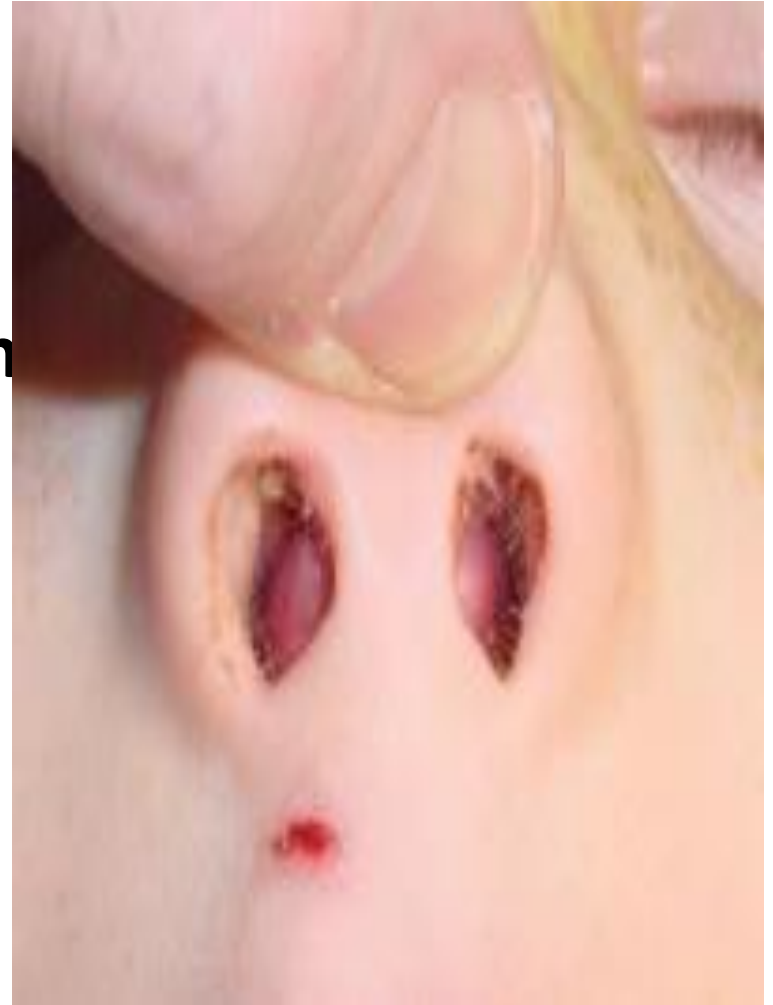Q10

- **A patient underwent septoplasty, came after one week suffering from bilateral nasal obstruction**

Dx → septal hematoma

Treatment → evacuation

Complication if untreated
→ necrosis and perforation



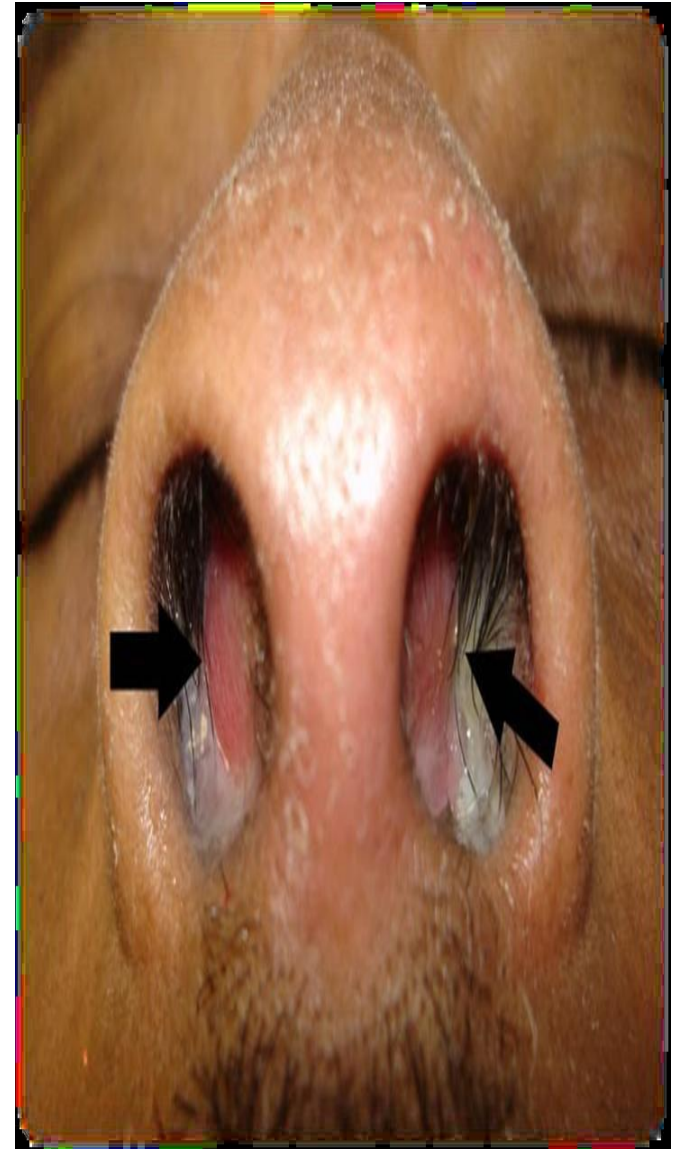
Q11

- **patient came to you after history of trauma yesterday complaining of this picture**

1-what is your diagnosis.

2-what is the most step you have to do next.

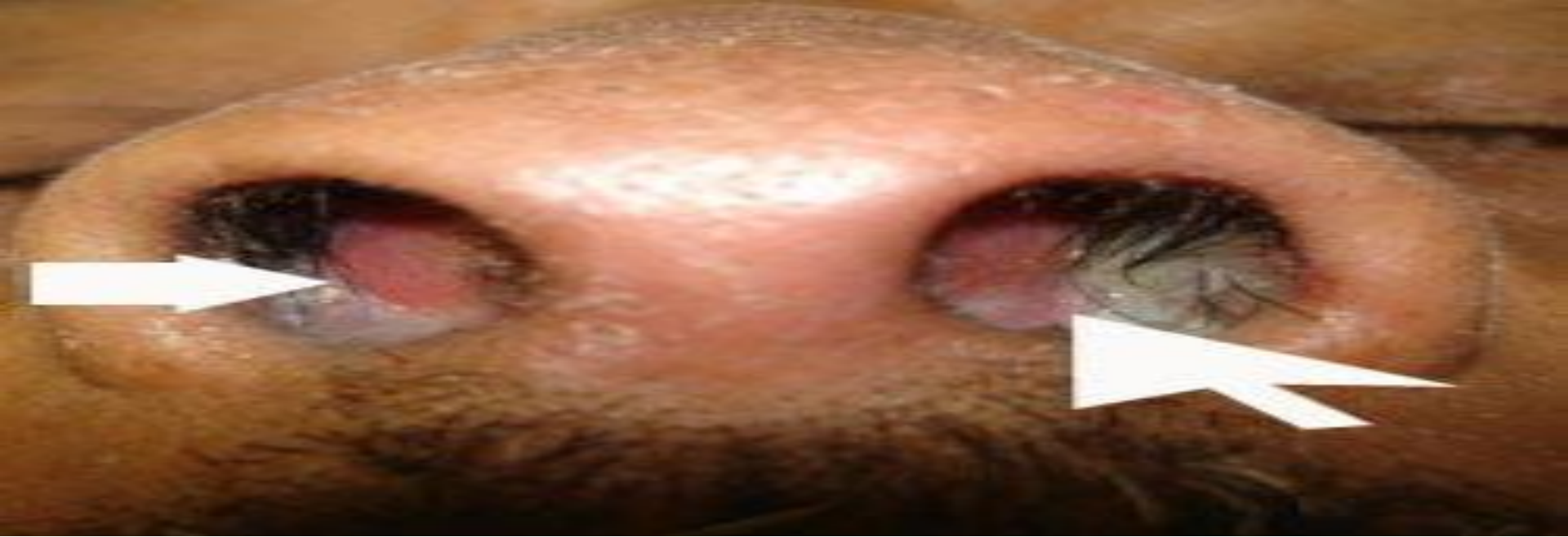3-what is the complications if left untreated.



1-septal hematoma.

2-evacuation.

3-septal necrosis and septal perforation



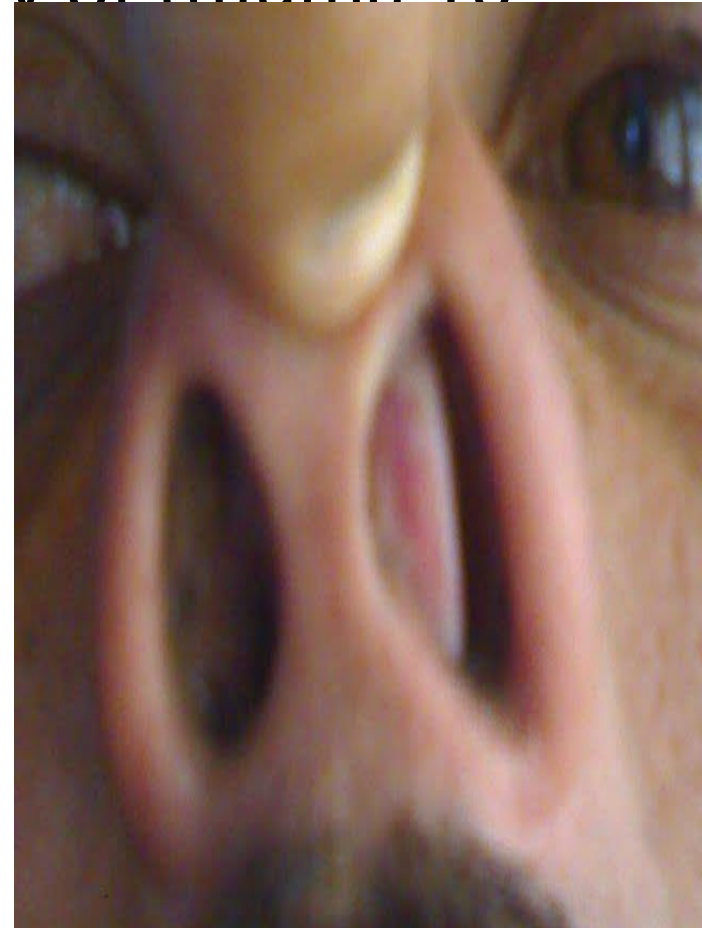
- Q12) A patient presented with bilateral nasal obstruction after a surgery of septoplasty
 - What is the diagnosis?
 - What is the treatment?
 - Mention one complication

- -Bilateral septal hematoma
- -Evacuation
- -nasal septal necrosis

Q13

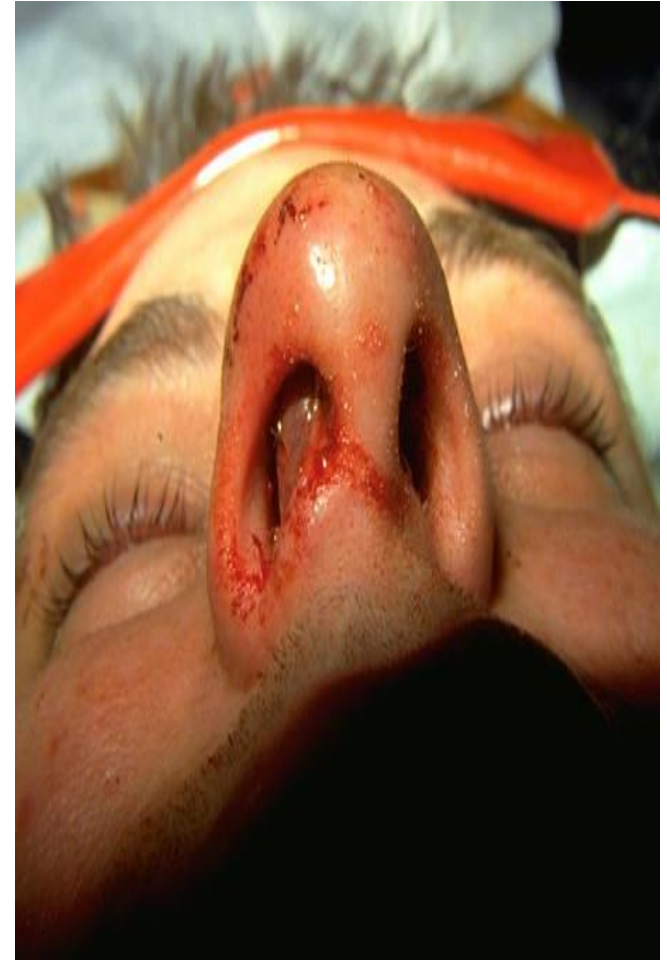- A 20 year old male with history of trauma 10 years ago
- 1) What is your diagnosis ?
Septal deviation
- 2) What is the treatment ?

Septoplasty



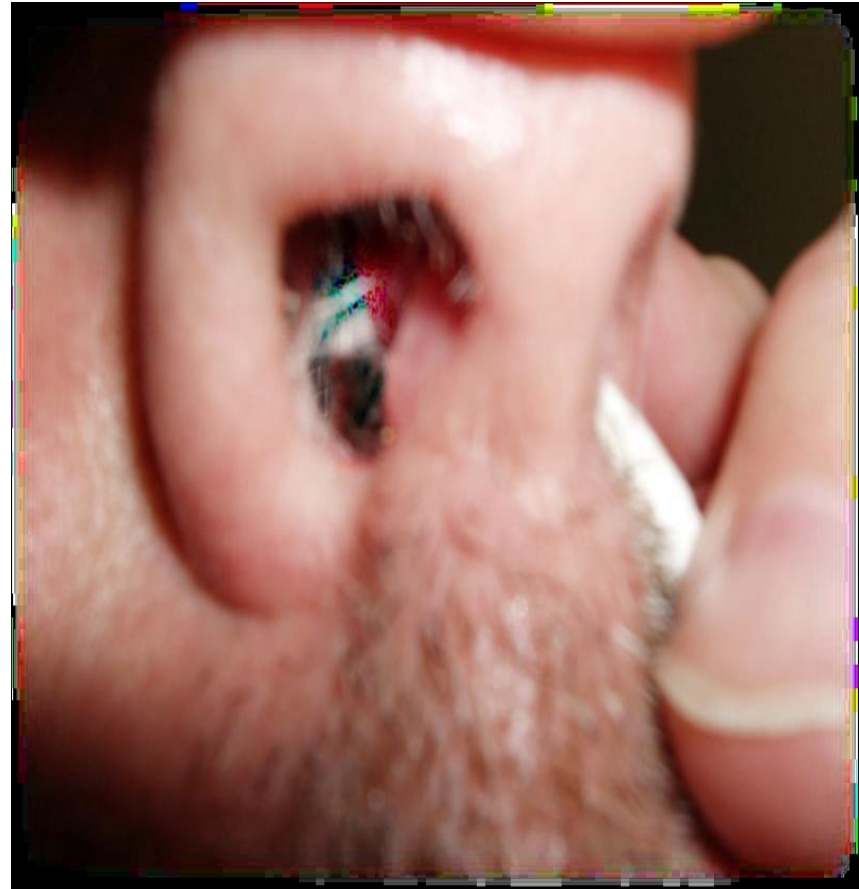Q14

- Patient presented with this after nose surgery
 - What is your diagnosis?
septal Hematoma
 - Mention 1 other Cause? trauma
 - Mention 1 complication?
infx
 - What is the treatment ?
Evacuation (incision & drainage)



Q15

- **patient came to you with this picture after having a surgery to his nose .**
- 1-what is your diagnosis.
- 2-give 2 non-surgical causes for this condition.



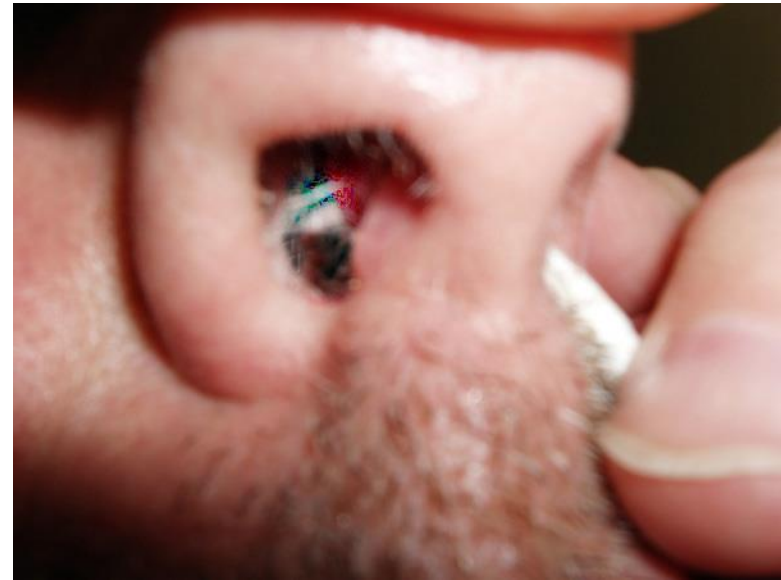- 1-septal perforation.
- 2-A-trauma .
- B-cocaine sniffing, carcinoma.

..pic of septal perforation & history of multiple surgery in the nose...

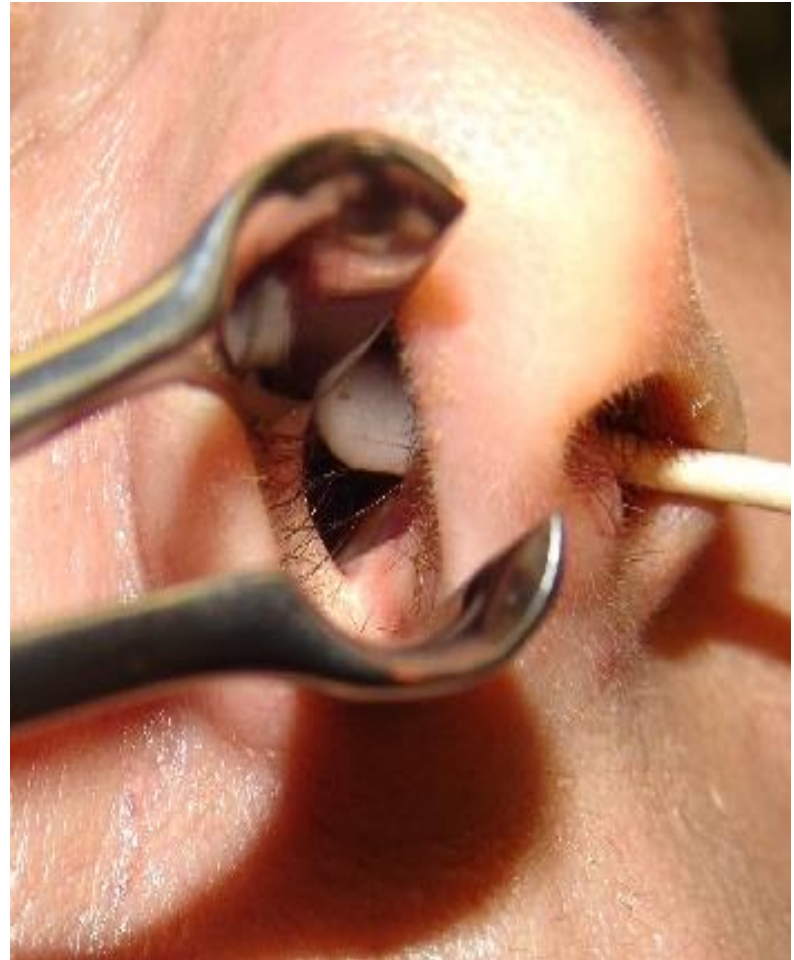- **1)give 2 causes**

traumatic, iatrogenic,
inflammatory/malignant, and inhalant
related

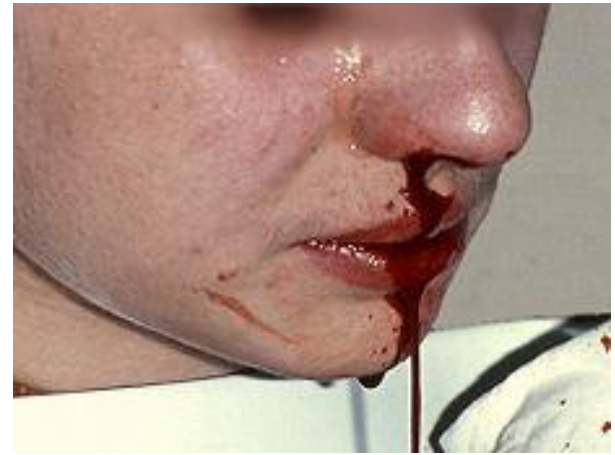- **2)what is the treatment**



- What is your diagnosis ?
Septal perforation

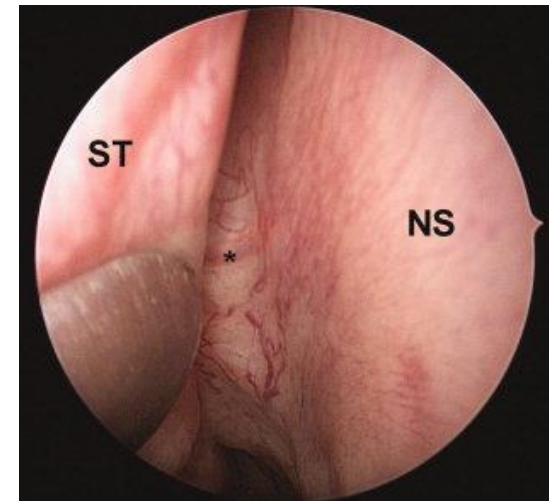


Question#16



Patient presented with epistaxis :

- 1) What's the blood supply of the area affected ?
- 2) Treatment ?
- 3) Complications of treatment?



Answers to Question#16

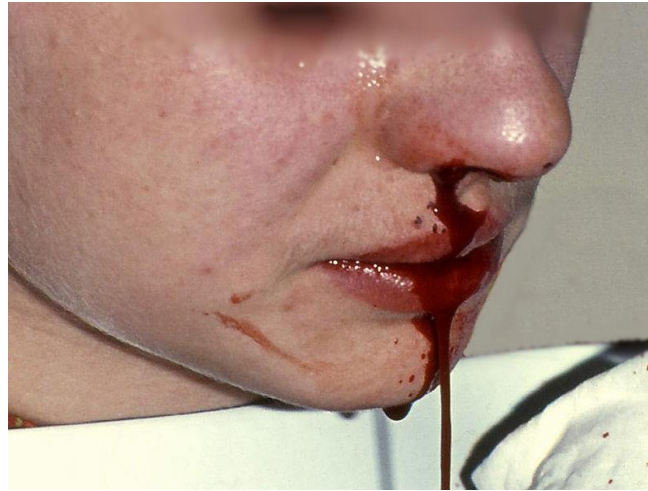1) Anterior area : superior labial , anterior ethmoidal , sphenopalatine , greater palatine

2) Cautarization

(some wrote anterior pack am not sure which is the best answer ! The complications of ant.pack is infection).

1) Necrosis , septal perforation

The patient had nasal bleeding for 30 minutes and now she became dizzy, this is not the first time this happens to her.



- What is your diagnose?
- Mention two causes.
- How will you treat this patient?

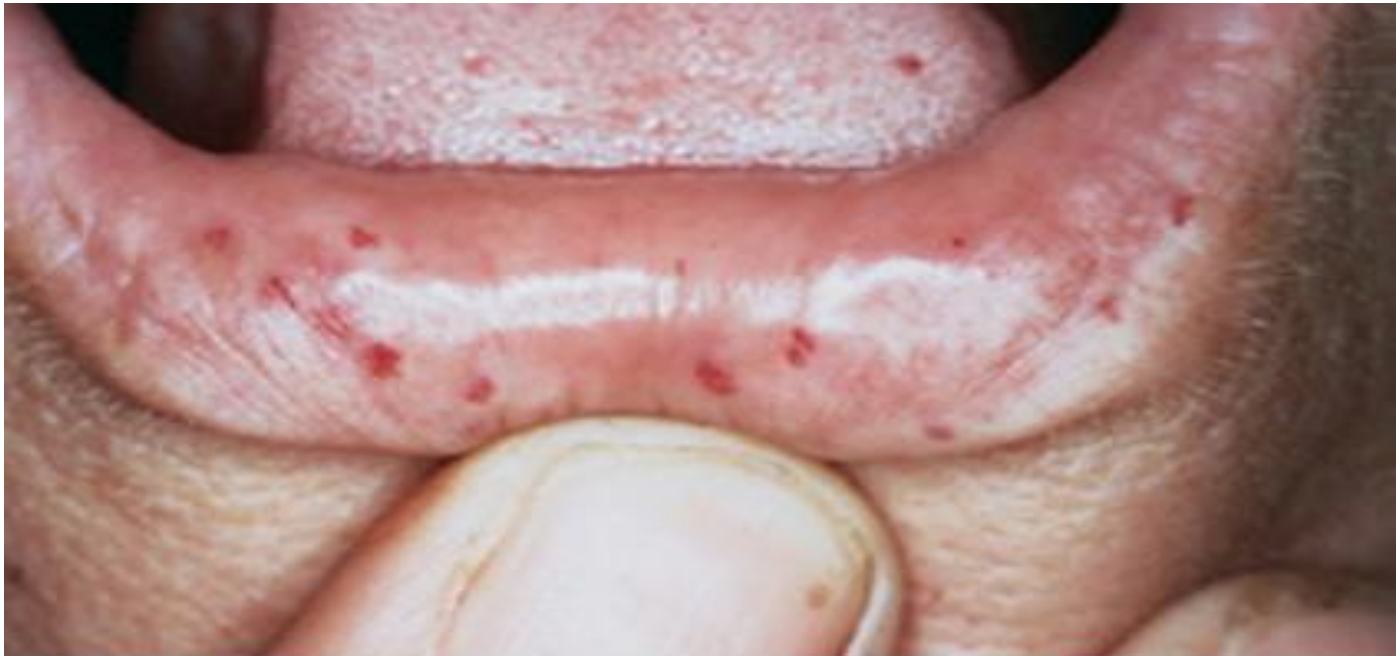- Q17) A picture for patient with nasal bleeding and a family history of epistaxis

1-what is the most likely cause

hereditary hemorrhagic telangiectasis (osler weber Rendu syndrome)

2-treatment

- A 40 year old male presented with multiple small red spots on his cheeks and lips and tongue with epistaxis, he has 2 brothers and 3 sisters, 2 of them had the same disease



1) What is your diagnosis?

2) Mention 3 risk factors for epistaxis?

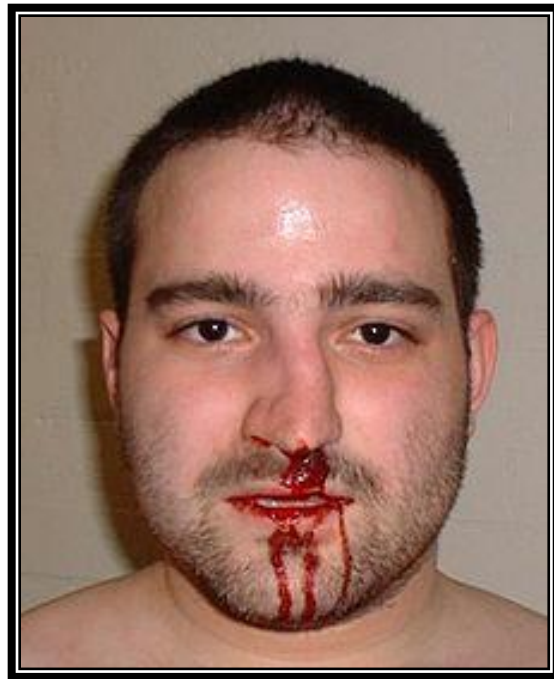- 1) Hereditary telangiectasia
- 2) HTN, hemophilia, trauma, etc.

- **Q18..epistaxis (not important pic)**
- **1)what is the blood supply?**
- **2)what is the most common site?**
- **3)give 2 causes?**

- question about the epistaxis (1- wt is the bld supply for nasal cavity 2- mention 3 predisposing factors for epistaxis)

Q19: this is a picture of adult man after RTA.

- **What is your diagnosis?** Nasal fracture with septal deviation
- **What is the treatment?** Surgery/Septoplasty

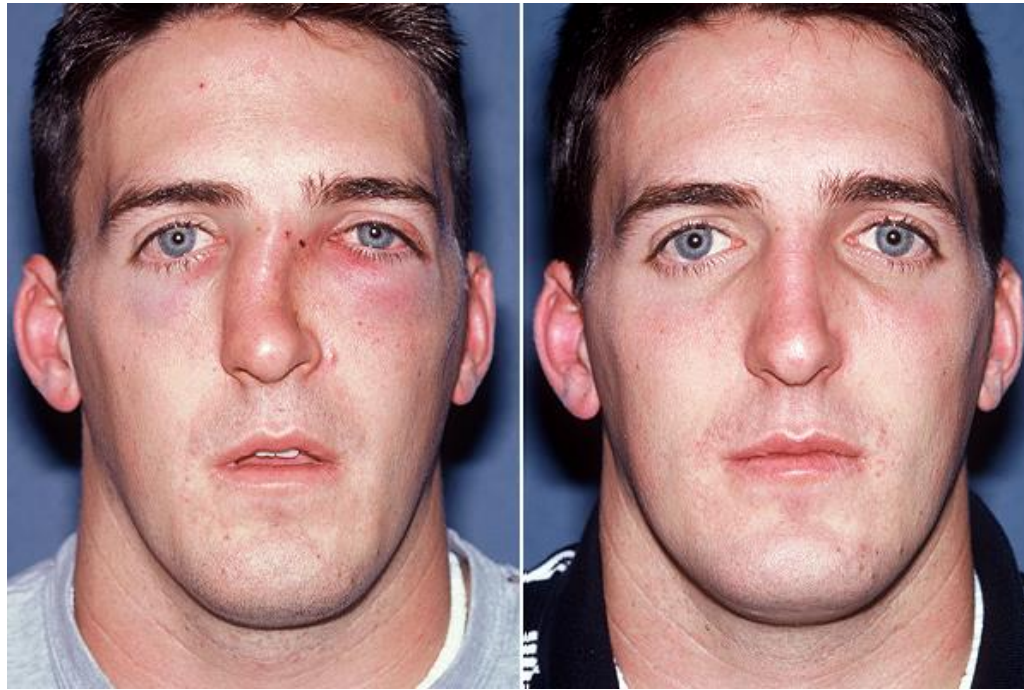


- Q20) A picture of facial trauma (nasal fracture)

1-what is this?

2-treatment

Surgery/Septoplasty



1-What is the abnormality in the left picture?(Nasal bone fracture)

2- Mention two complications for this.

Q.21

a young man came to the ER with epistaxis from trauma

-name two other causes of epistaxis?

JNA, rhinitis

-mention two things you'll look for in the physical exam of this patient.

obvious site of bleeding, skin bruises (bleeding tendency)

-name a hereditary cause of epistaxis

osler-weber-rendu synd.

Q22

- Mention 3 important qs in Hx you want to ask for a pt with epistaxis

duration of bleeding

triggers (eg, sneezing, nose blowing, picking)

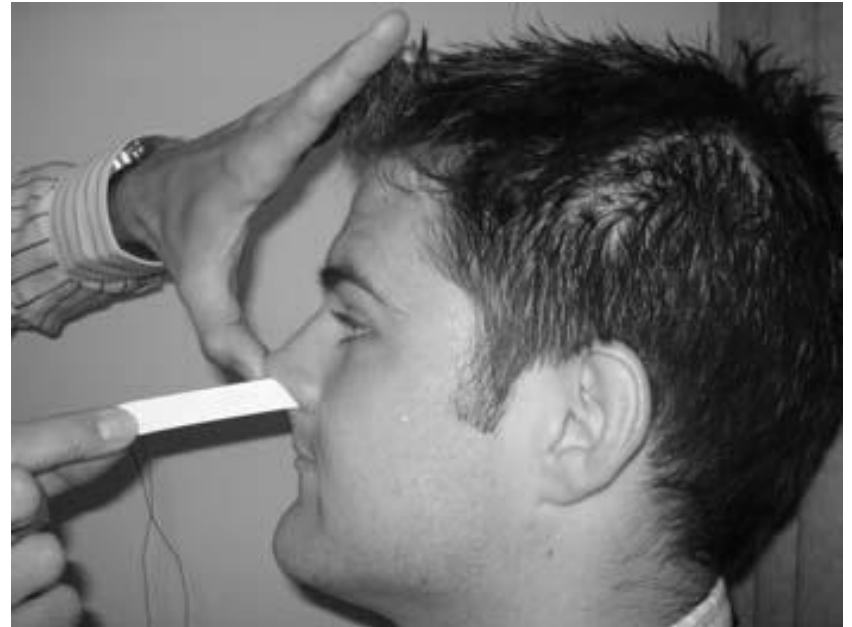Important associated symptoms prior to onset include symptoms of a URTI, sensation of nasal obstruction, and nasal or facial pain.

The time and number of previous nose-bleeding episodes and their resolution

symptoms of excessive bleeding, including easy bruising; bloody or tarry stools; hemoptysis; blood in urine; and excess bleeding with toothbrushing, phlebotomy, or minor trauma.

Question 23

This is the exact same picture we had in the exam



- A) What is the name of this procedure?
- B) Name one indication.
- C) Name one complication.

Question 23 answers

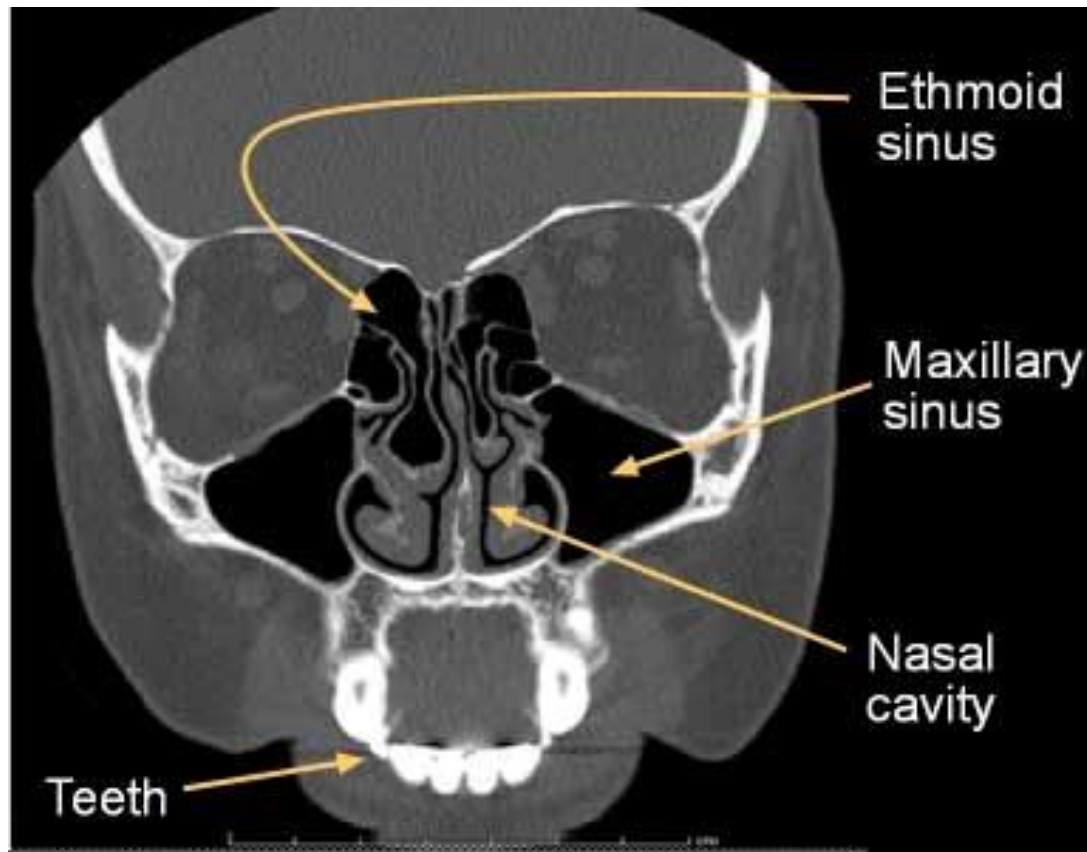
- A) Anterior packing (*note the strings hanging from the other end*)
- B) Epistaxis
- C) Infection / Nasal septum perforation.

Q24

- **Case of man after trauma, with pic**
- - diagnosis? Nasal hematoma
- - first thing to do?
- - complication?

Sinuses

Normal Sinus



#1

1. What's the name of this radiological modality.

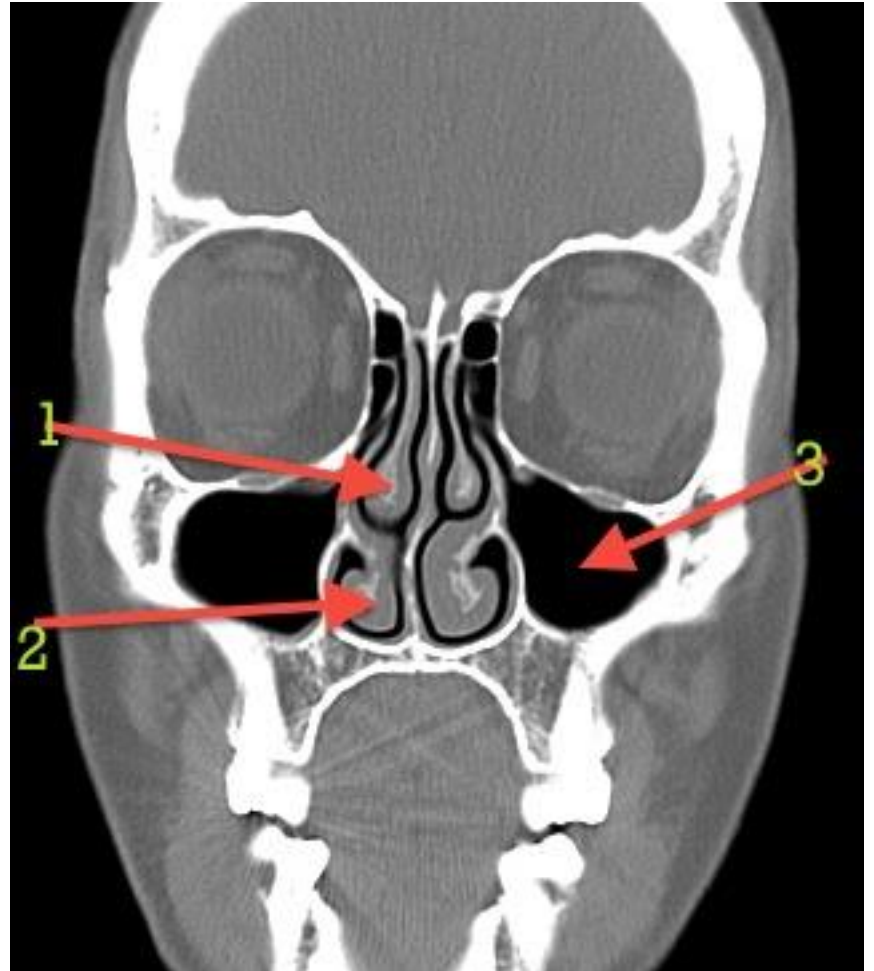
CT sinuses – coronal view

2. What are the numbered parts

(1) Right middle turbinate

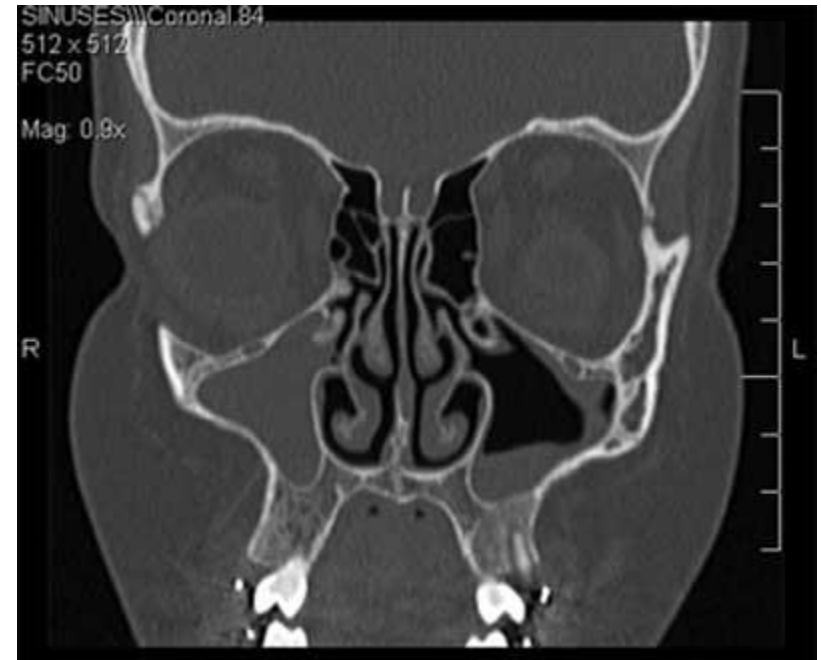(2) Right inferior turbinate

(3) Left maxillary sinus



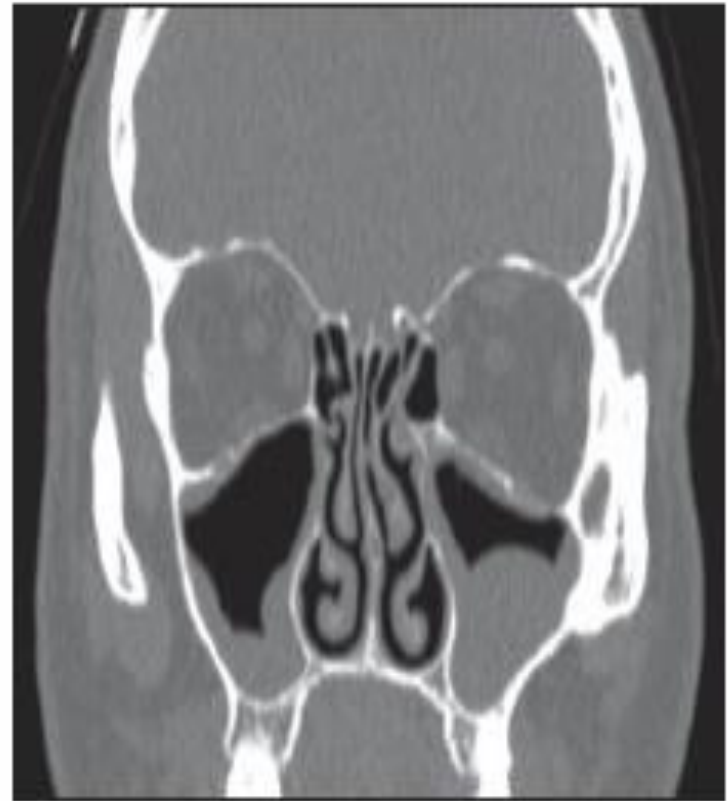Q2.A week of nasal discharge, headache, .. etc

- Dx?
- Acute right maxillary sinusitis...
- Rx?
- Antibiotics .. Nasal corticosteroids...
- Commonest MO ?
- Strep pneumonia



Question 3

- The history showed that it's Acute <4 wks (the picture was clear that the right maxillary sinus is the one involved).
1. What's your diagnosis?
 2. Mention 2 common microorganisms causing this?
 3. What's the treatment?



1. Acute right maxillary sinusitis.
2. Strep. Pneumonia & haemophilus influenza.
3. , Intranasal corticosteroids, Antibiotic (amoxicillin + clavulanic acid)

Q4. CT of maxillary sinusitis

-what's the dx ?

-name two complications?

Orbital cellulitis/ abscess, meningitis /
intracranial abscess

-what's the surgery used to treat this case ? FESS

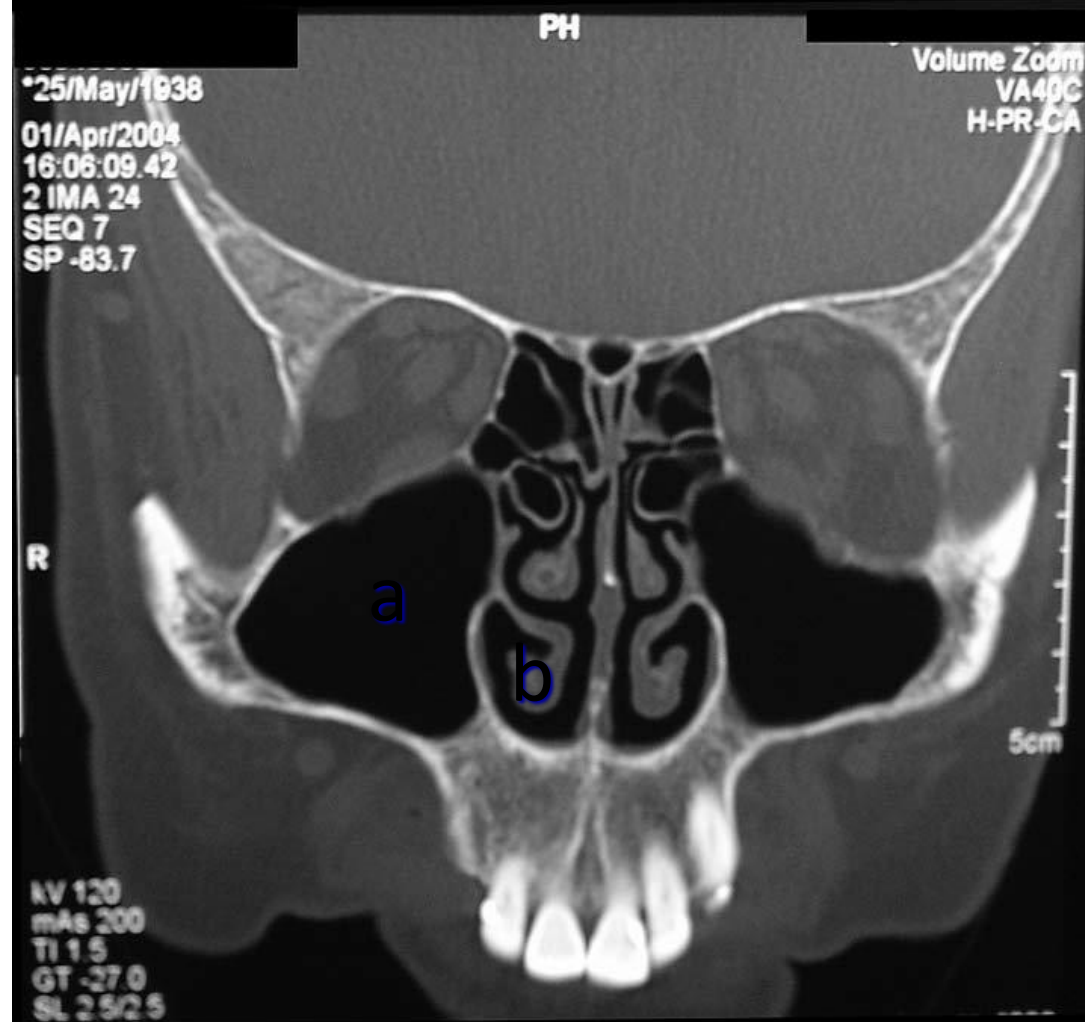
-name 2 complications of this surgery ? synechia,
injury to orbit or optic n.

-what's the arrow indicating ?

(was so clear ,, middle turbinate)

Question 5

- A) What is (a)?
- B) What is (b)?
- C) Where does the ethmoidal sinus drain?



Question 5 answers

- A) Maxillary sinus
- B) Inferior turbinate (inferior meatus is also accepted)
- C) Middle meatus* (Middle turbinate is not accepted at all!)

An X-ray of sinusitis

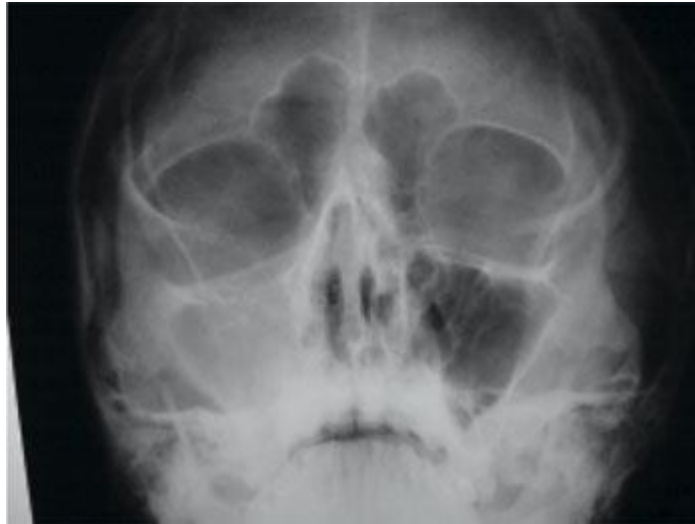1-diagnosis

2-two complications

meningitis, intracranial abscess, subperiosteal frontal bone abscess (pott's puffy tumor), orbital abscess, orbital cellulitis

- 3-treatment

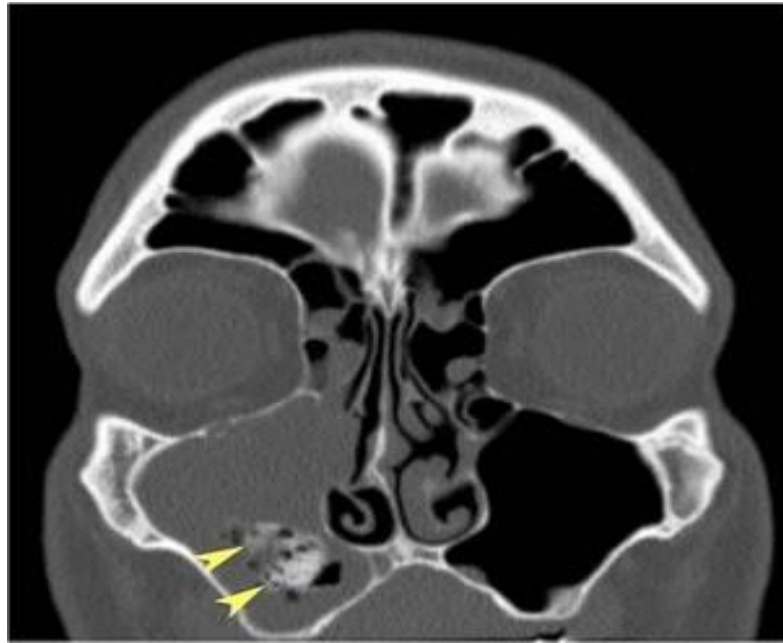
Augmentin, Intranasal steroid

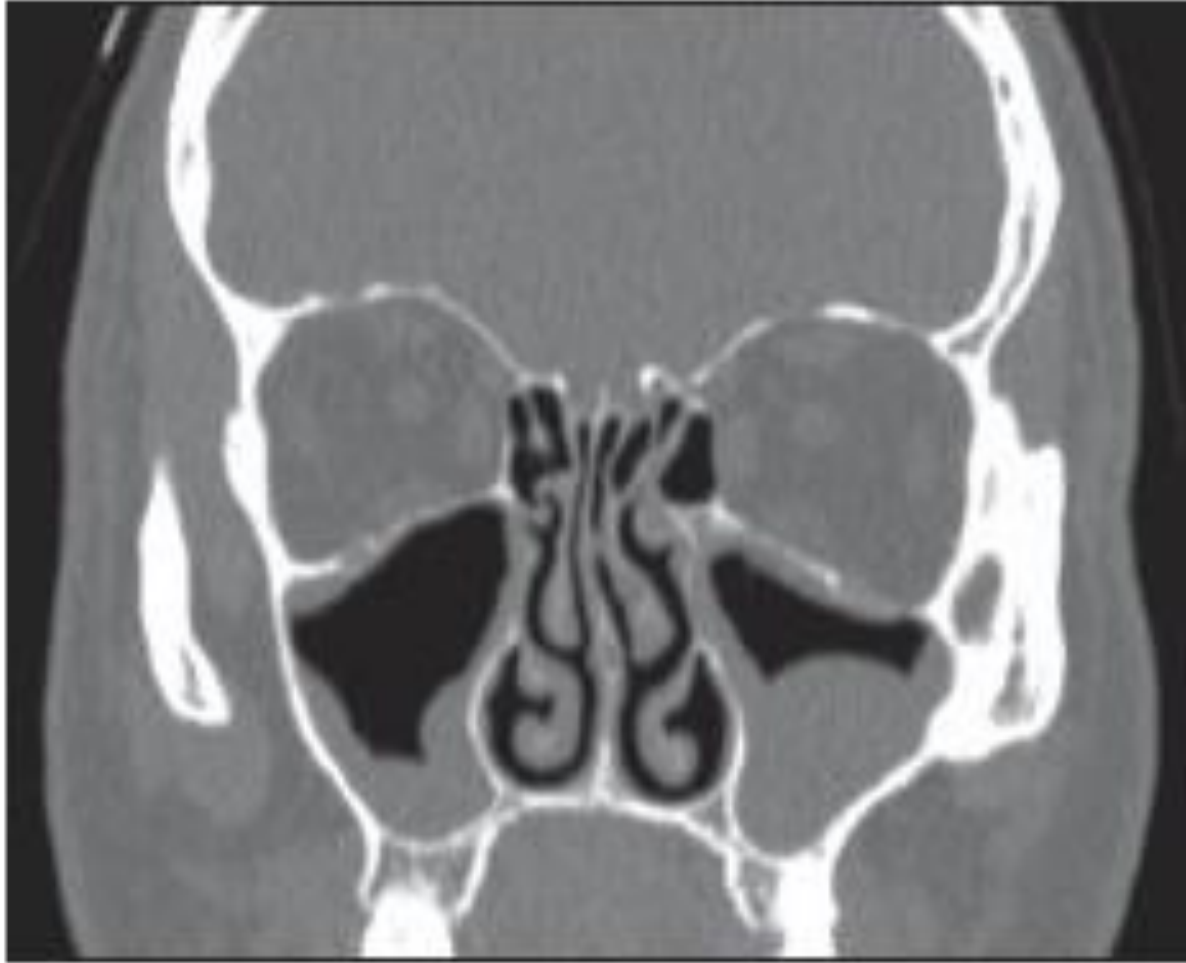

- What is your diagnose?
- How will you treat this patient?

..the problem since 6 month...

- **1)what is ur diagnosis? chronic Maxillary sinusitis**
- **2) write 3 complication ?**





Q6. History of facial pain and runny nose

1) What is your diagnosis?

2) Mention 2 possible complications?

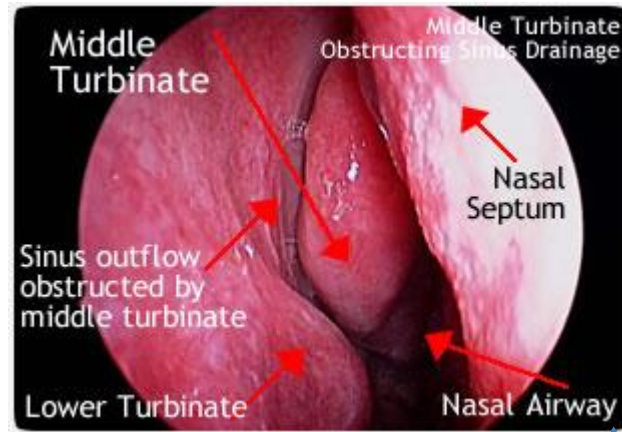
3) mention 2 common microorganism causing this?

1) Sinusitis or rhinosinusitis

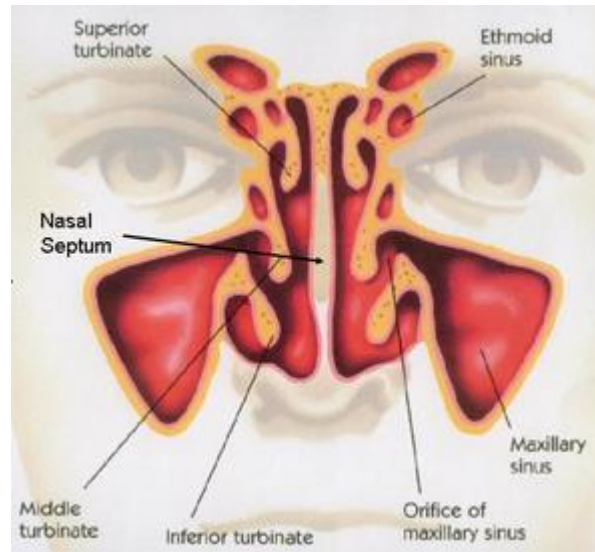
2) Meningitis, subdural/ epidural/ brain-abscess, cavernous sinus thrombosis, etc.

3) S. pneumonia, H.influenza, etc.

- sinusitis (cT scan)
(1- Dx 2- findings (mucosal thickening and opacity or air fluid level) 3- mention 2 predisposing factors)

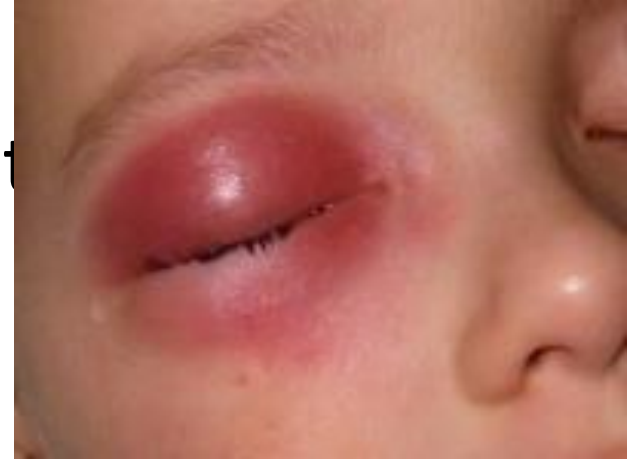

- In the question there was a picture close to this one, they marked the middle turbinate and asked which sinuses drain in? and there was a mark at the nasal septum and they asked what is this part.
- **This is another helpful picture:**



Question#7

I can't remember the history but
the patient is a child presented
swelling like in the picture :



- 1) what's your diagnosis ?
- 2) Give two DDX ?
- 3) What are the complications ?

Answers to Question#7

- 1) Orbital cellulitis
- 2) Orbital abscess , preseptal cellulitis (am not sure if it's the wanted answer!)
- 3) cavernous sinus thrombosis

menengitis

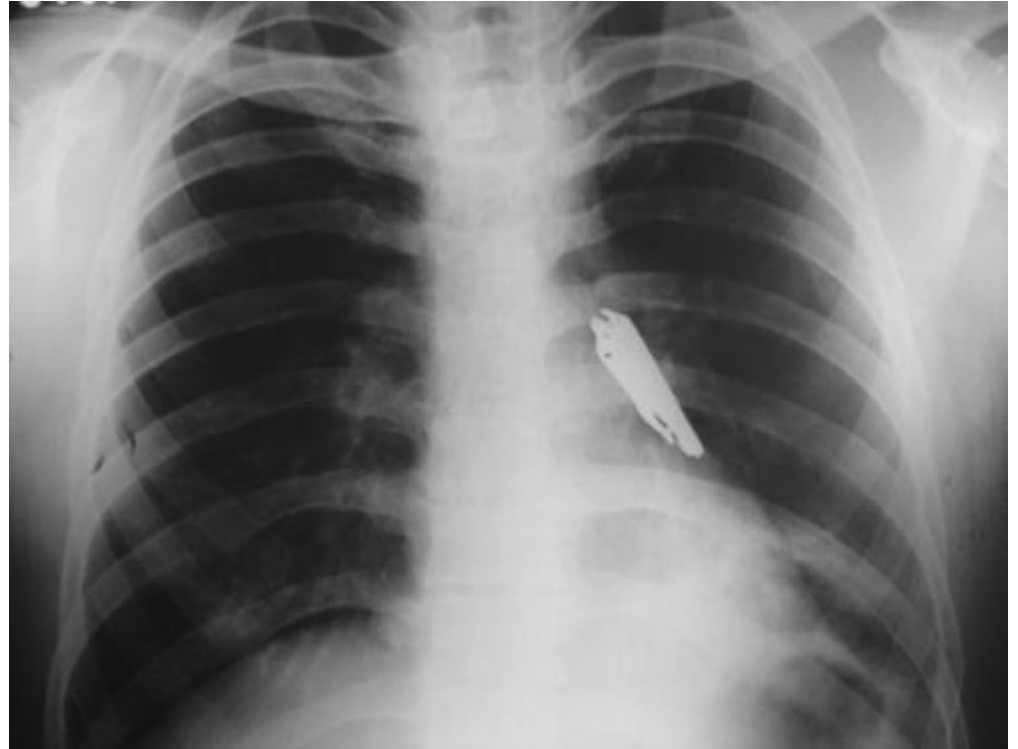(those are the complications of chronic sinusitis mainly the ethmoid sinus)

Foreign body aspiration

Q1:

**this is x-ray for
child, he was plying
with his brother
when he developed
tachypnea and
stridor:**

- What is the
diagnosis**
- what is the
management?**
- Give 2
complications.**

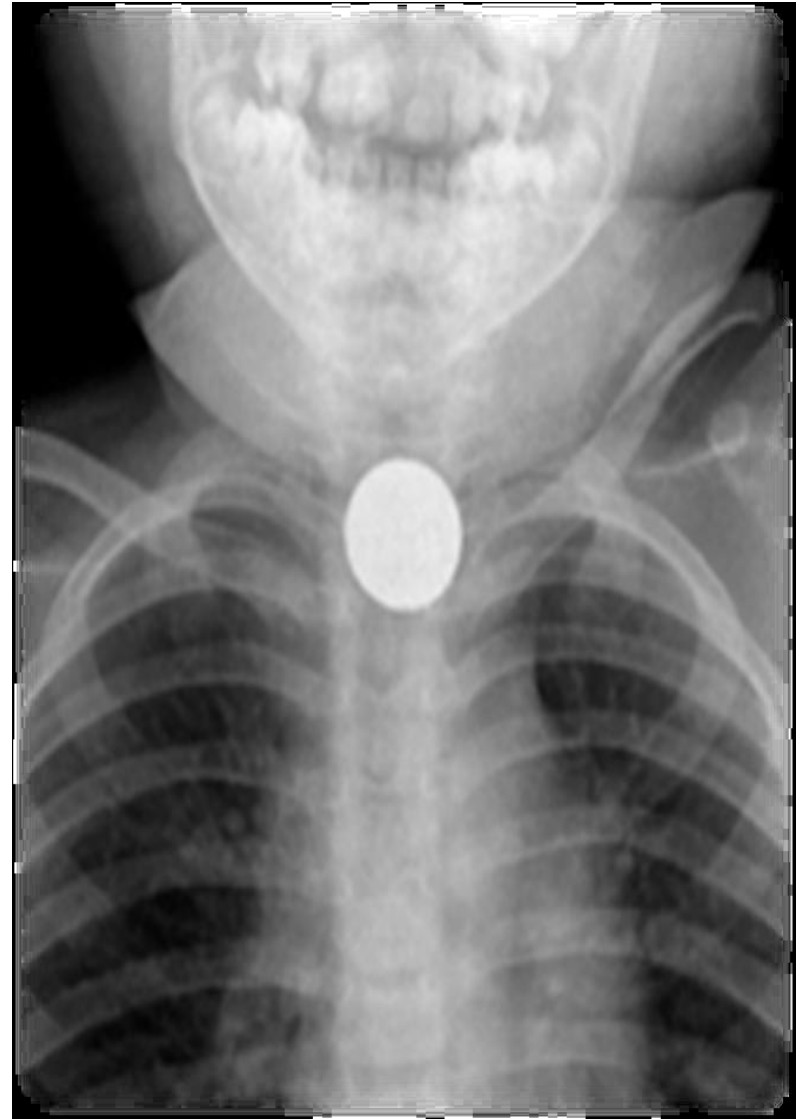


Q1

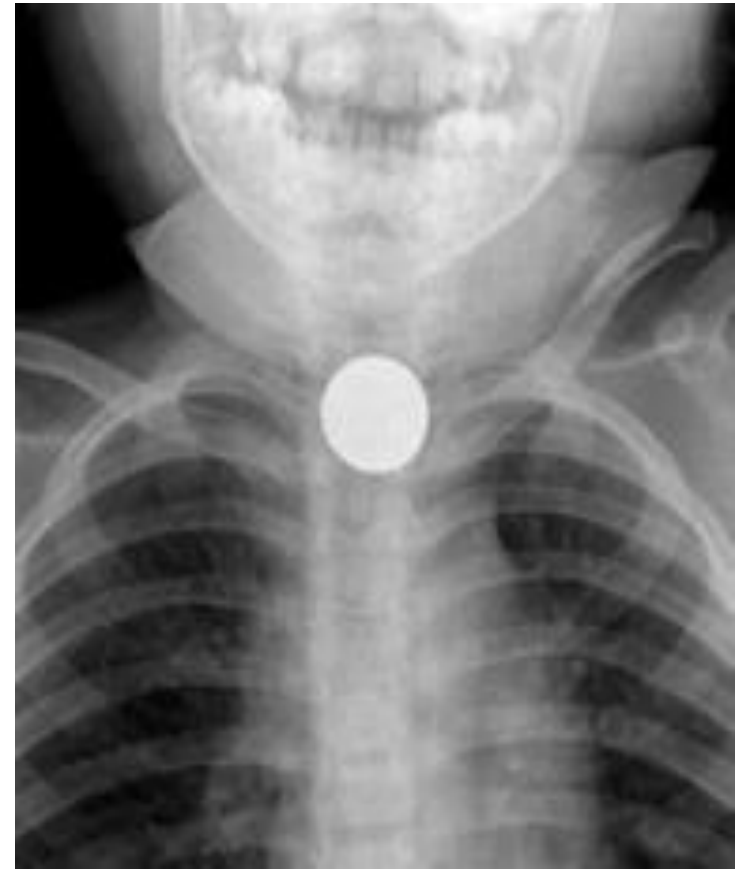- 1- foreign body aspiration
- 2- by rigid bronchoscopy
- 3- a) pneumonia
 - b) atelectasis

Q2

- a mother came to you afraid cause her 5 year old child swallowed a coin you did x-ray and found this picture.
- 1-what do you want to do next. **esophagoscope.**
- 2-what is the most common place for the foreign body to be in? **upper constrictor of the esophagus.**

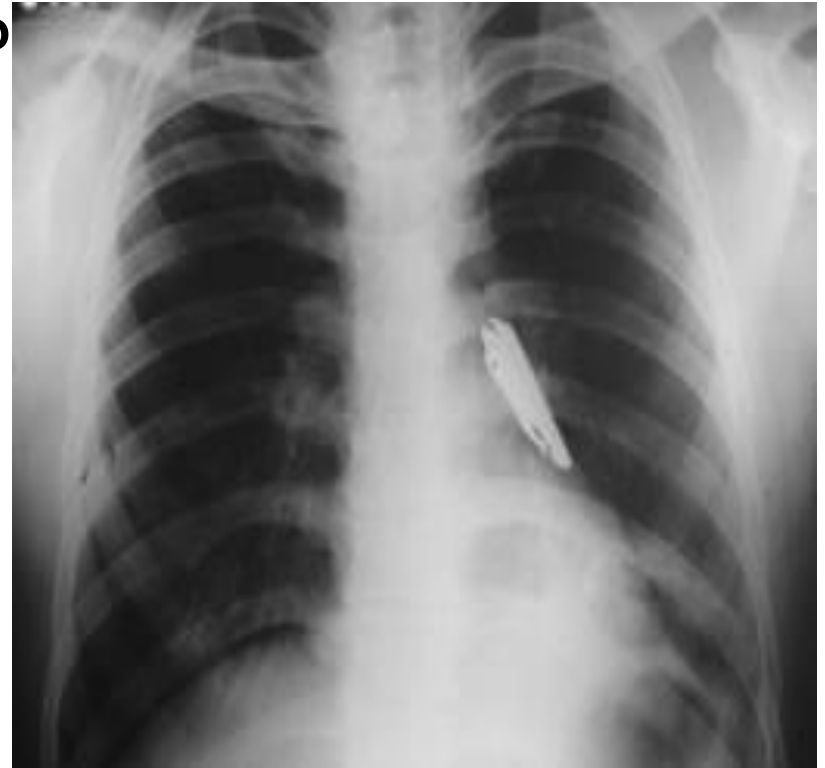

- Q3) A history of a child presented with choking and dysphagia.
 - Where is the impaction
 - What is the treatment?
 - What is the most common site of foreign body entrapment in esophagus?



- In the esophagus
- Removal by esophagoscopy.
 - Children: upper esophageal sphincter.
- Adults: lower esophageal sphincter.

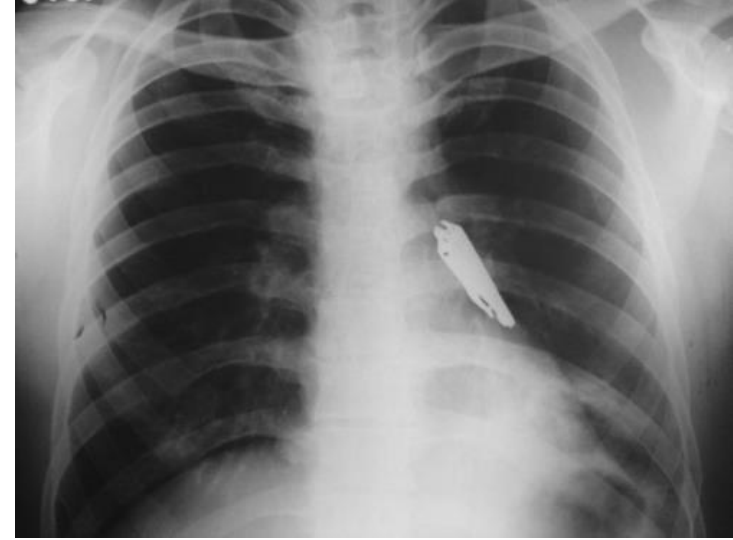- What is your diagnosis?
- What will you do for this patient?



- Foreign Body Aspirations
- Rigid Bronchoscopy

Question 4

I couldn't find the picture we had!



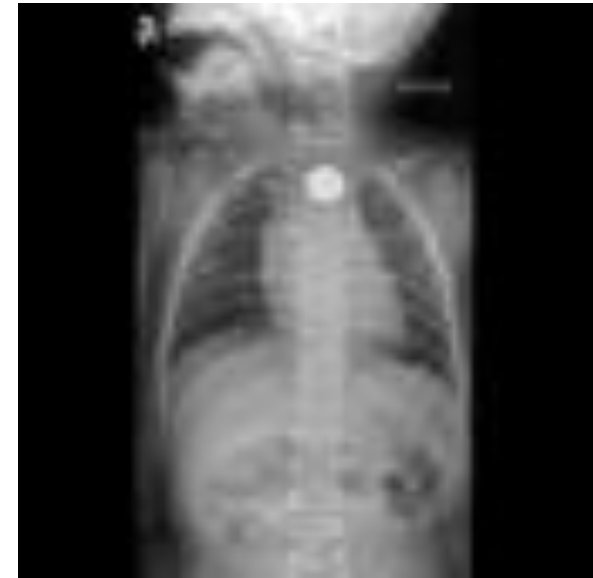A child presented with history of choking. We did him this X-ray.

- A) What is your diagnosis?
- B) What is your management?
- C) Give two complications to this condition.

Question 4 answers

- A) Foreign body aspiration
- B) Rigid bronchoscopy
- C) 1- Pneumonia
2- Lung collapse

- **Q5..this x-ray for child no history of SOB & good breathing)**
- **1)what is the most common site? Upper oesophageal sphincter of oesophagus**
- **2)what is the treatment?**
oesophagoscopy



Q6

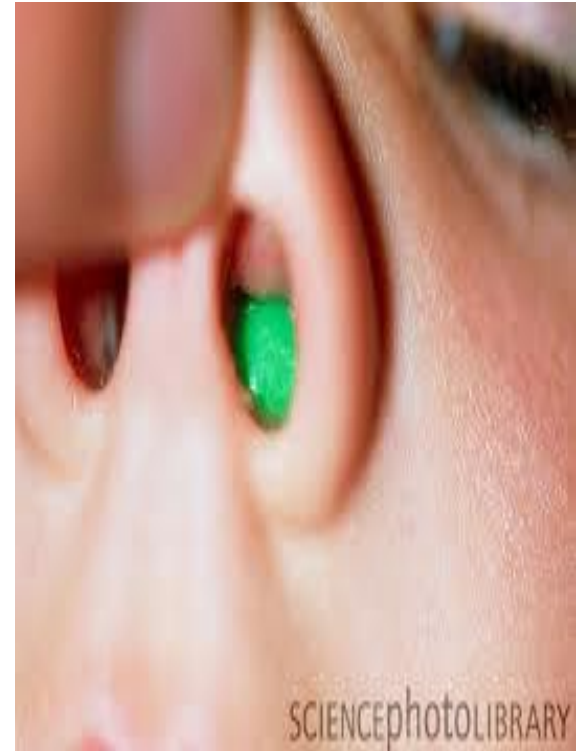- **A patient (5 or 4 yrs old ???) presenting with unilateral nasal obstruction, foully smelling discharge**

Diagnosis → intranasal foreign body

Treatment → to remove the foreign body

Q7

- Child with Hx of unilateral Nasal discharge
- What is your diagnosis ?
Nasal FB
- How to treat ?
Removal by forceps (direct instrumentation)



Others

- Q1) Mention 3 EBV diseases related to ENT
 - Infectious mononucleosis
 - Nasopharyngeal carcinoma
 - Hodgkin's lymphoma

Q2.

pic of big inflamed tonsils and a rash
on the leg

-what's the dx ? infectious
mononuclosis

-what's the drug that caused the
rash ? amoxicillin

Q.3

pic of otosclerosis

what's your dx?

name two causes ?

Idiopathic!, risk factors: family Hx

(AD w/ variable penetrance),

pregnancy

Q4

A 50 yrs old heavy smoker male, presented with right ear otitis media, right nasal obstruction and neck mass (nasopharyngeal CA)

- How to approach the patient??

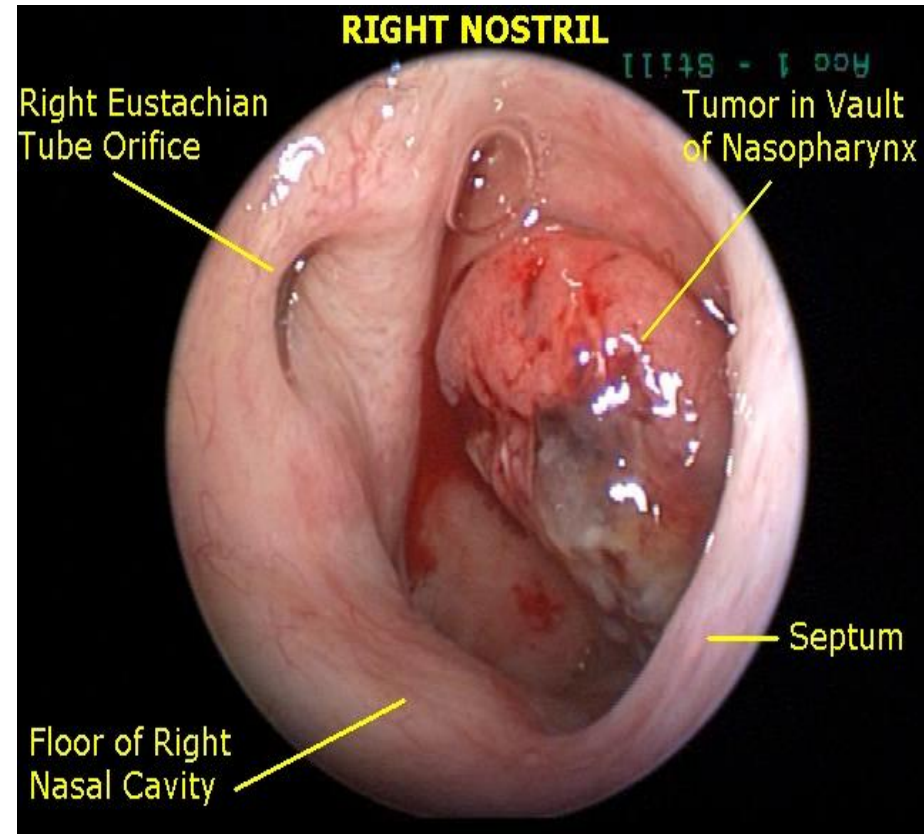
Indirect rhinoscope

- If it was SCC, what is the treatment??

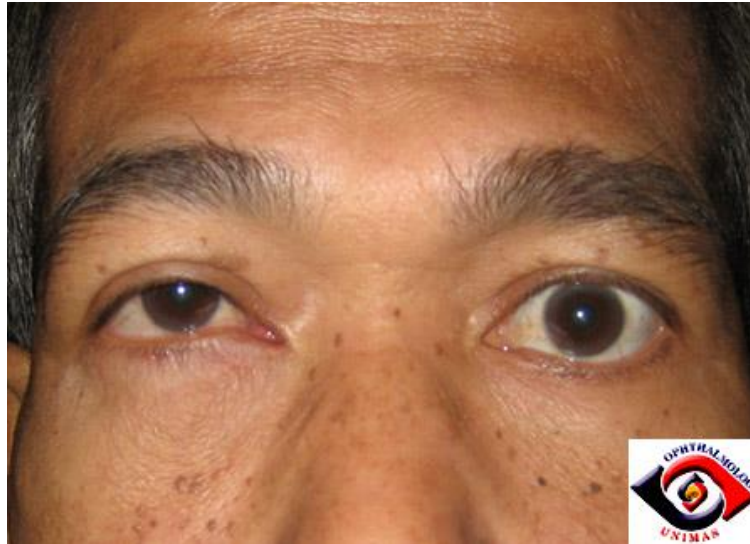
Radiotherapy

- 3 predisposing factors

Asian people, EBV, radiation, asbestosis, smoking, alcohol consumption



Q5 This patient with nasopharyngeal carcinoma



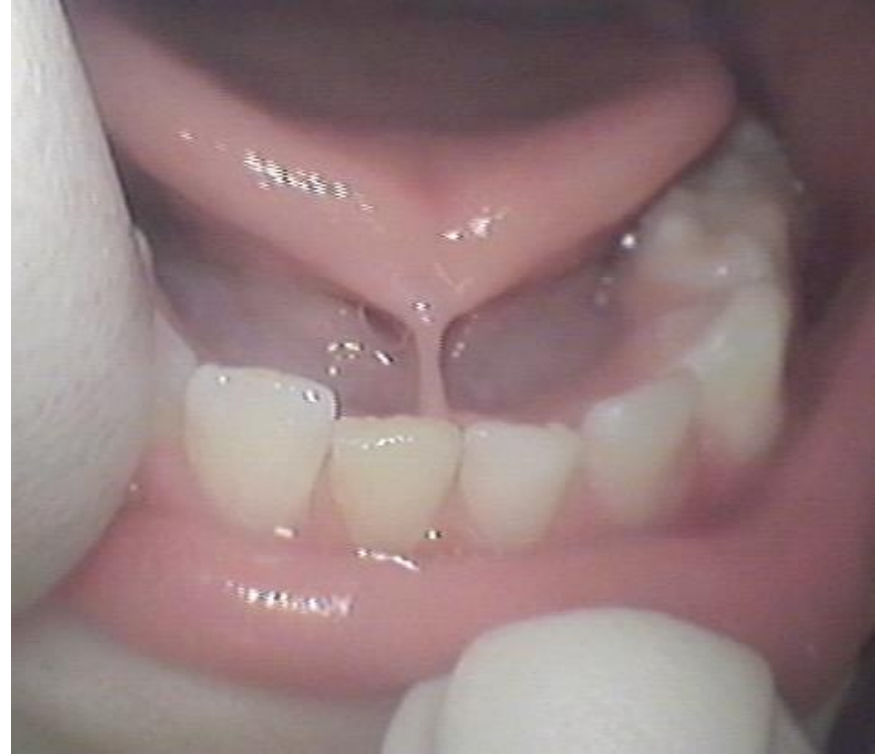- How will you treat this patient? radiotherapy
 - Mention a complication of this tumor.
- CN palsies

Q6

- This station was MATCHING!, in one column there were 2 sentences, and in the other one there were 6 choices!
- A) Recurrent attacks of vertigo, tinnitus and hearing loss _____meniere's_____
- B) Unilateral nasal obstruction in an adult most commonly is __deviated nasal septum?_____

Question 7

This is the exact same picture we had in the exam



A) What is this condition? Tongue tie

A) What is your management? Tongue release surgery

Q8

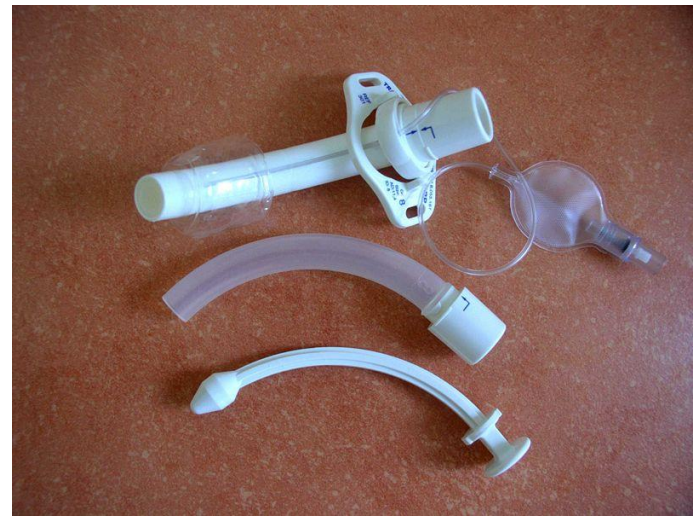- **Picture**
- - diagnosis? Mumps
- - complication?

Orchitis, pancreatitis

Devices

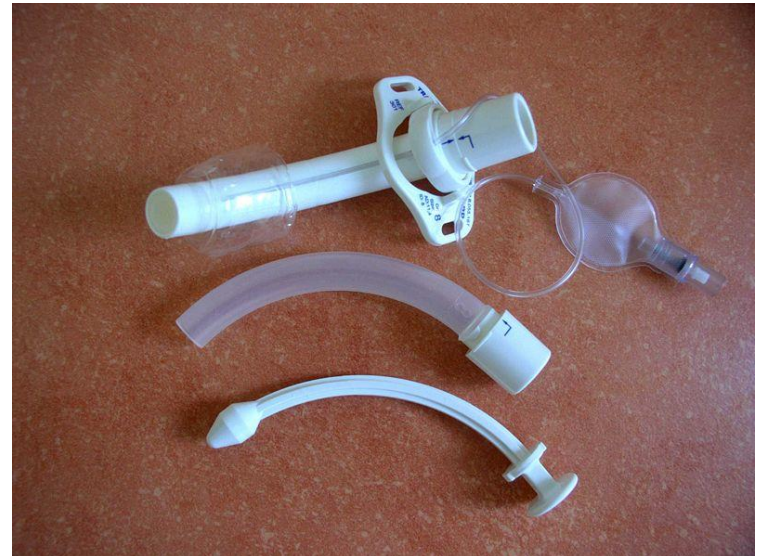Q #1

1. What's this device?
2. Mention 2 indications.
3. Mention 2 complications.



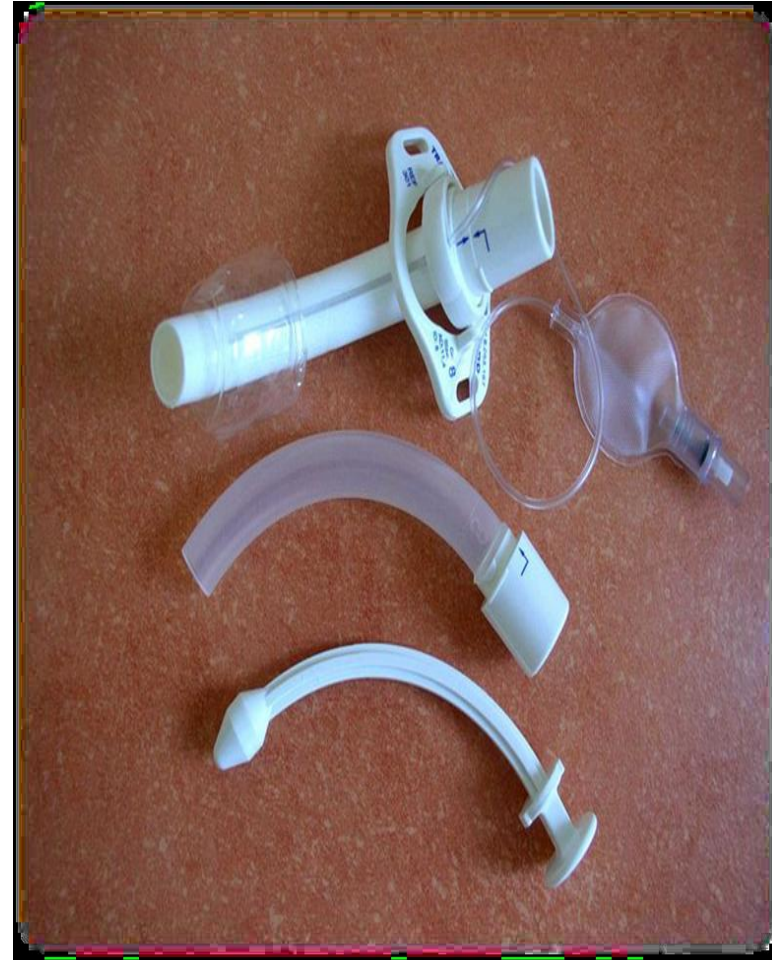1. Tracheostomy tube.
2. A-Mechanical obstruction of the upper airways.
B-Retention of bronchial secretions
C-Protection of tracheobronchial tree in patients at risk of aspiration.
D-Respiratory failure.
E-Elective tracheostomy, e.g. during major head and neck surgery a tracheostomy can provide/improve surgical access and facilitate ventilation.
3. Dislodgment, Obstruction ... etc

1. What's this?
2. Give 2 indications
3. Give 2 complications
4. Give 2 indications
5. Give 2 complications



1. Tracheostomy tube
2. A. Prolonged intubation
B. Mechanical upper airway obstruction
3. A. Pneumomediastinum, Pneumothorax
B. Infection

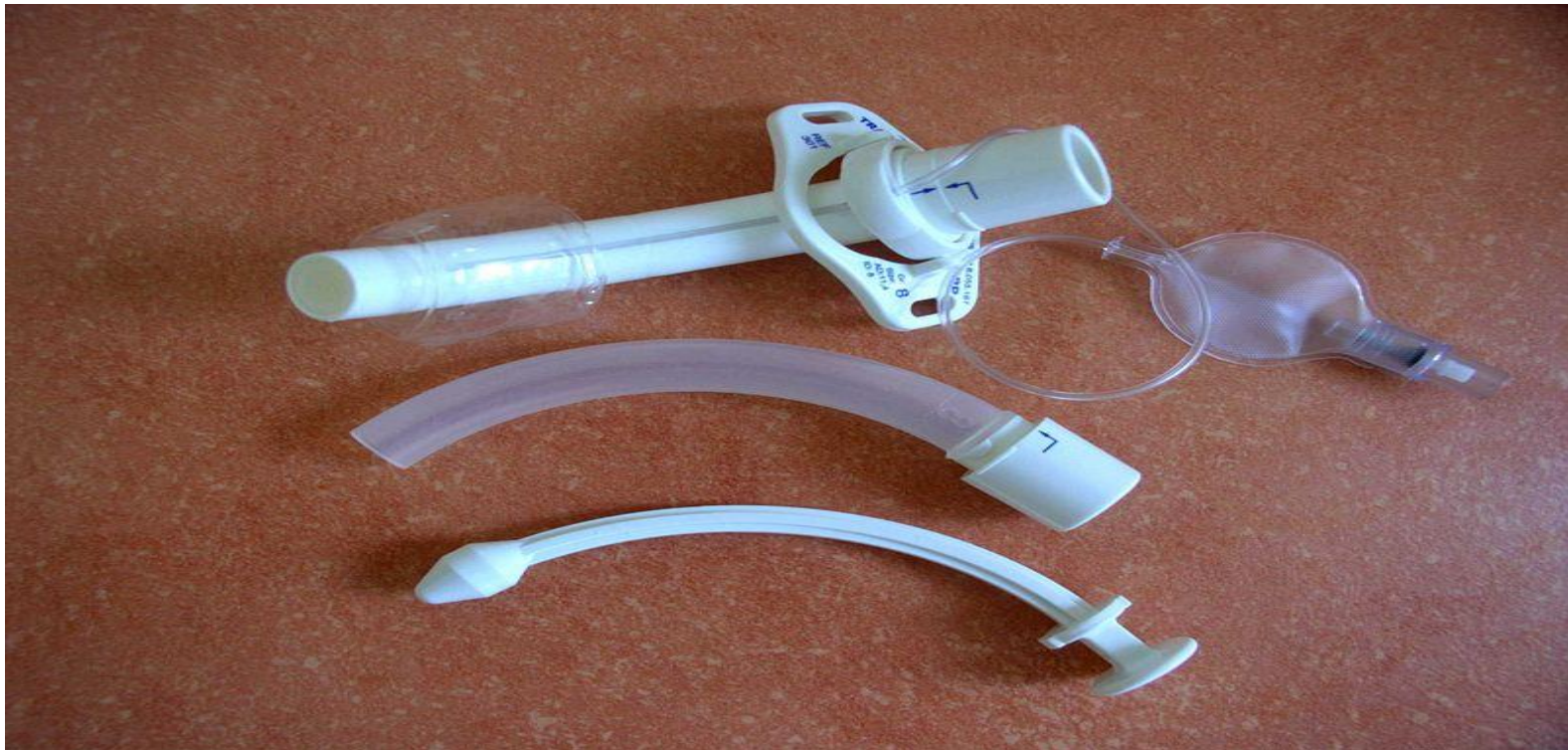1-Name this tube.
2-name 3
indication for the
use.



- 1-tracheostomytube.
- 2-the indications are:

A-Mechanical obstruction of the upper airways.B- Retention of bronchial secretionsC-Protection of tracheobronchialtree in patients at risk of aspiration.D-Respiratory failure.E- Elective tracheostomy, e.g. during major head and neck surgery a tracheostomycan provide/improve surgical access and facilitate ventilation.

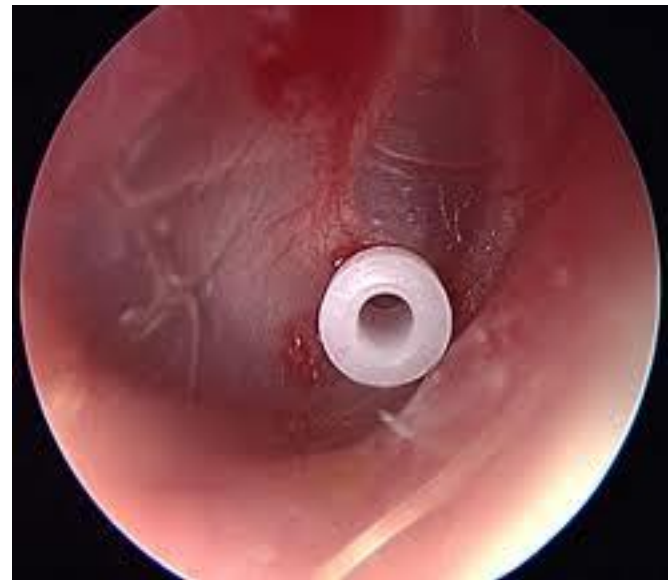- Name this device.
- Mention 2 indications.
- Mention 2 complications.



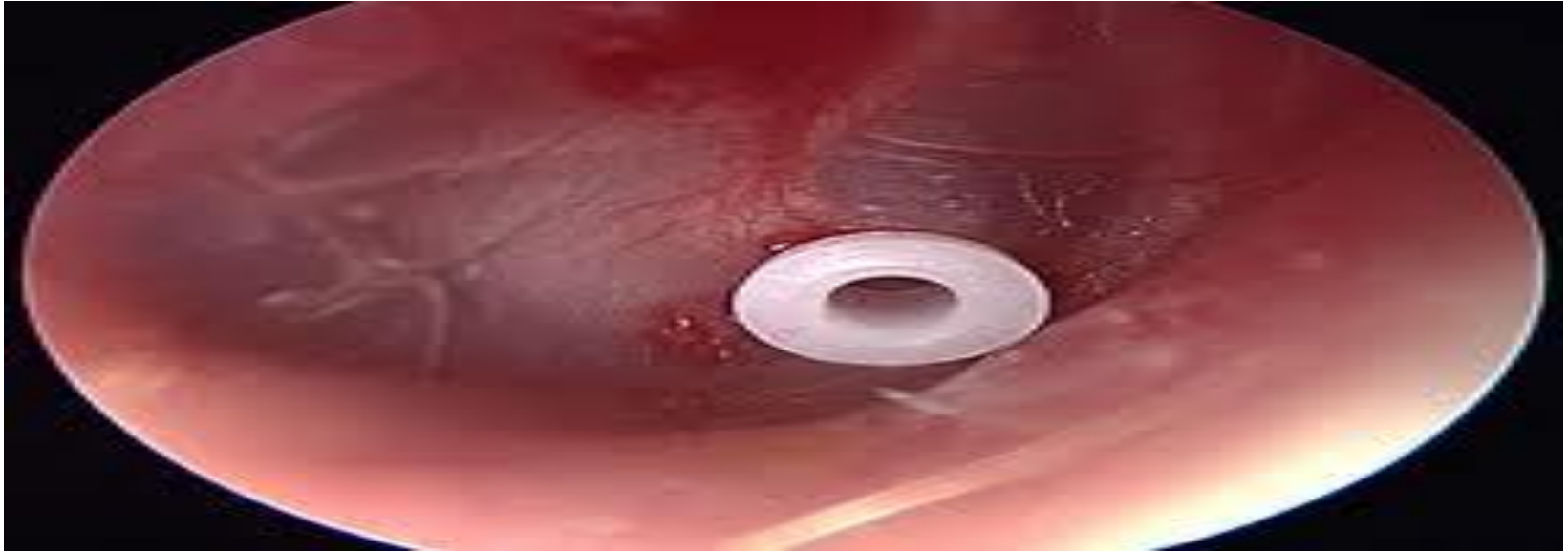
- -tracheostomy tube
 - Please refer to the slides
- - Dislodgment (complete or partial), obstruction by a crust

Question #2

1. What's this tube?
2. Mention 2 indication for using it.



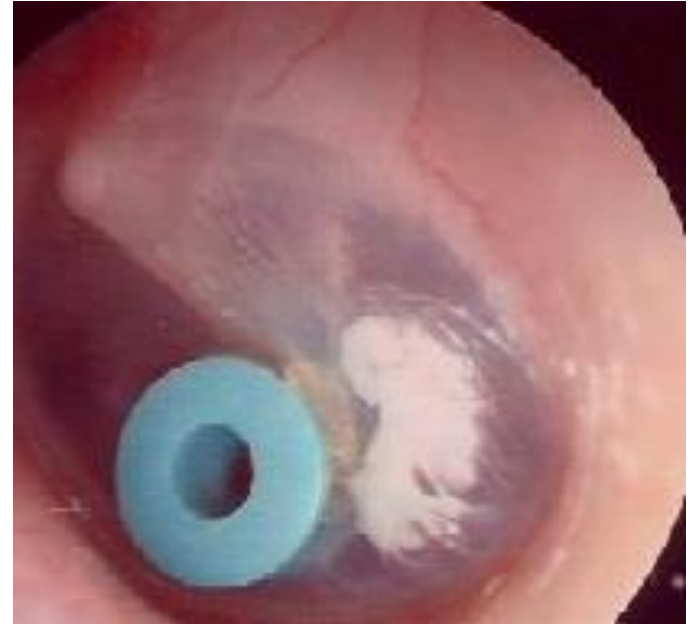1. Grommet.
2. Glue ear & eustachian tube dysfunction.



- - What is this device?
 - Mention 1 indication
 - Mention 2 complications

- Grommet or myringeostomy tube
- glue ear
 - Myringiosclerosis, permanent perforation, early extrusion, obstruction

- 1) What is the name of this tube?
- 2) Mention 2 indications for using it
- 3) Mention 1 complication



Q3 identified these instruments:



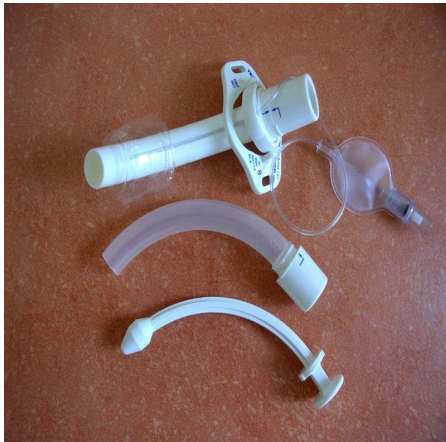1



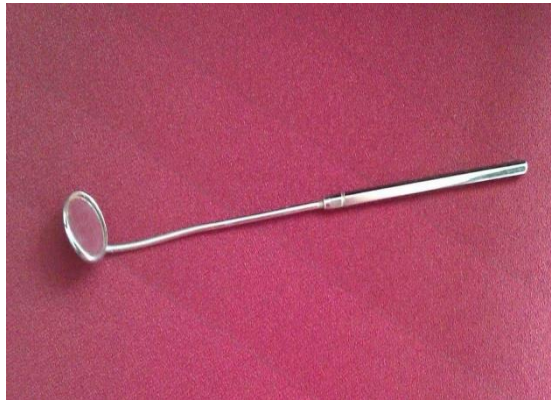2



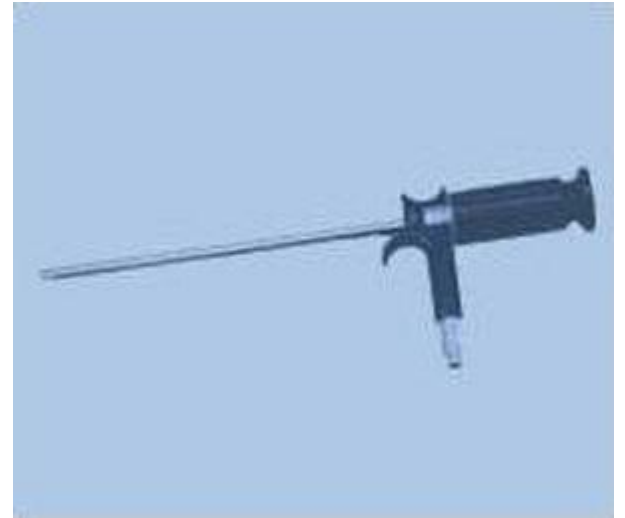3



4



5



6

- 1- anterior nasal pack
- 2- tuning fork
- 3- killian nasal speculum
- 4- tracheostomy tube
- 5- indirect laryngoscope mirror
- 6- direct rigid laryngoscope

- Q4)
 - What is this instrument?
 - Mention 2 tests to be done with it

-Tuning Fork
- Weber's test, Rinne's test



*Q5.mention 2
uses of this tool
* if it didn't give
you enough
information ,,
what's the
alternative tool
?



- indirect laryngoscopy mirror
change in voice (examination of larynx)
dysphagia
- direct rigid laryngoscope

Notice the difference between indirect laryngoscopy mirror
& Posterior rhinoscopy mirror (used for Adenoids,
nasopharyngeal tumor (lesions in post. Nasal space))



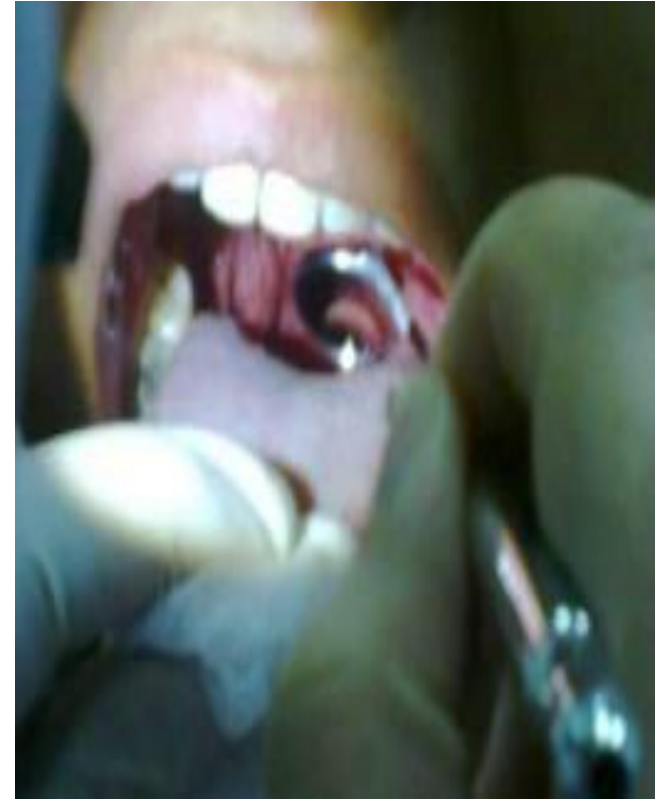Question 6



- A) What is this instrument? Nasal speculum
- B) What is the name of the diagnostic procedure that is made using this instrument? Anterior rhinoscopy (Nasal inspection)

Q7

- What is the site you see using this method ?
(indirect laryngoscope)
Larynx (vocal cords)
- Mention Other method to Use ? Direct laryngoscope



Q8

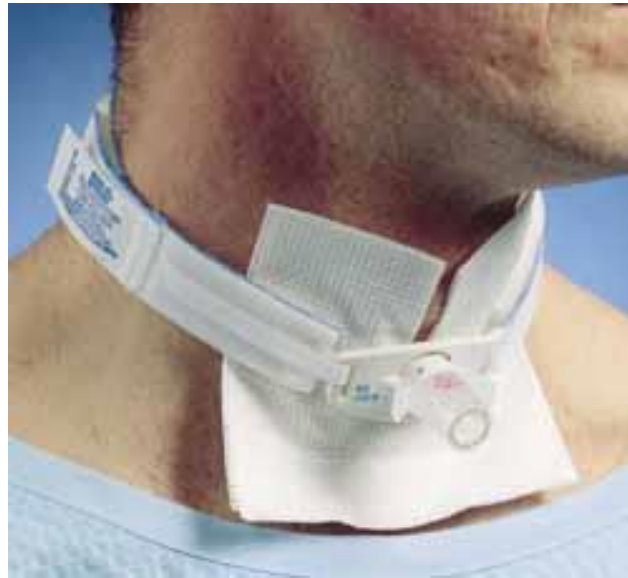- **3 tests for hearing**

PTA

Tympanometry

auditory Brainstem response (ABR)

otoAcoustic emission



- What is this instrument?
- Mention two uses.
- Mention one complication.

SAMA 2013

Mini-OSCE Exam ENT

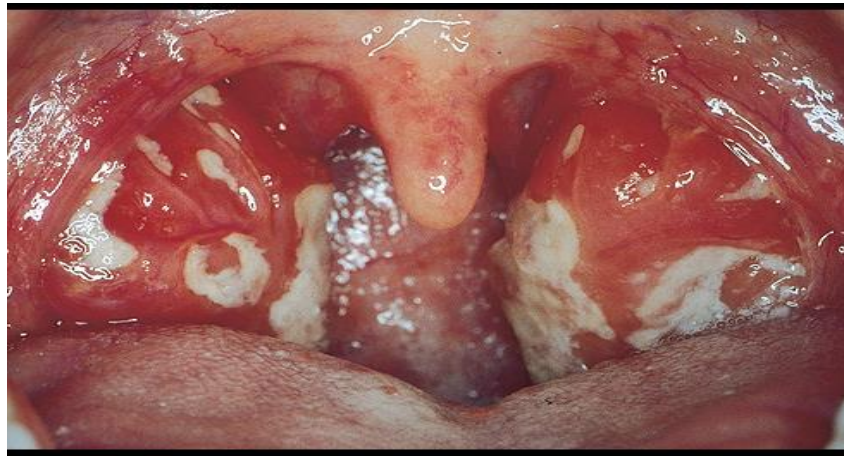
Groups A3 – A4
17.4.2014

Done by
Rawan Moneer D'ahir
Abeer Ruzeah

Question 1

A 10 years old child complained of sore throat, fever, & fatigue. He was treated with cefixime for 7 days. Few days later his condition didn't improve and he complained of abdominal pain, and on examination he had cervical lymphadenopathy and this picture. Also he developed a skin rash on his both lower limbs.

1. What is the most likely diagnosis?
2. What is the causative microorganism?
3. What is the antibiotic that is contraindicated to be given?
4. What is your advice to the child's parents regarding his activity?



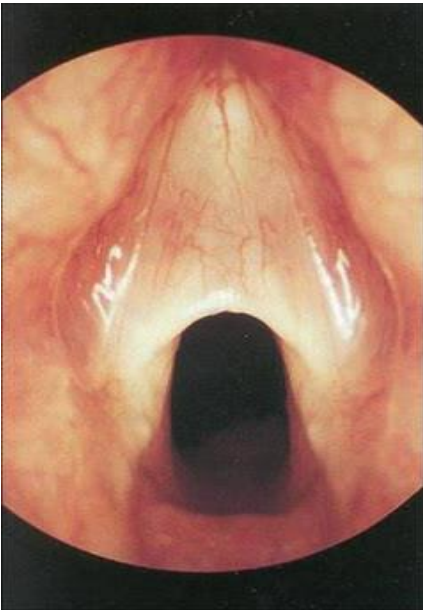
Question 1

1. Infectious Mononucleosis
2. EBV
3. Amoxicillin
4. The child should decrease his activity especially Contact Sports, because he has Splenomegaly and there is a risk of splenic rupture.

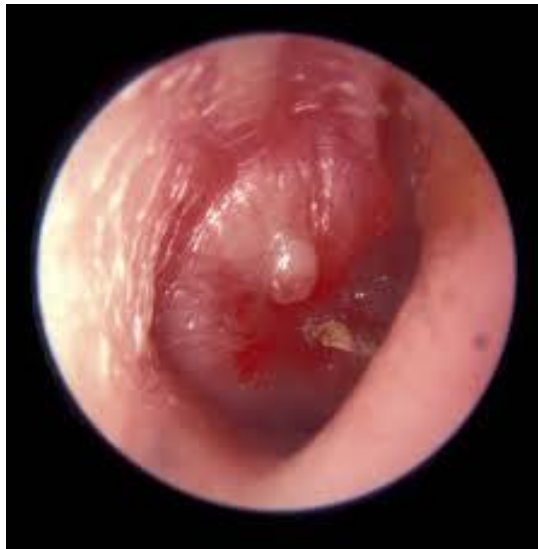Question 2

- Give 3 spot diagnoses.

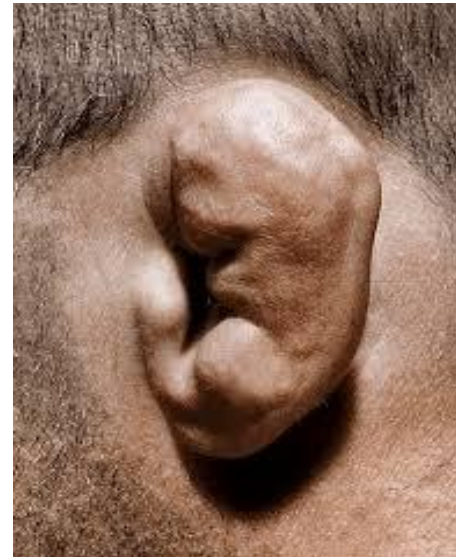A



B



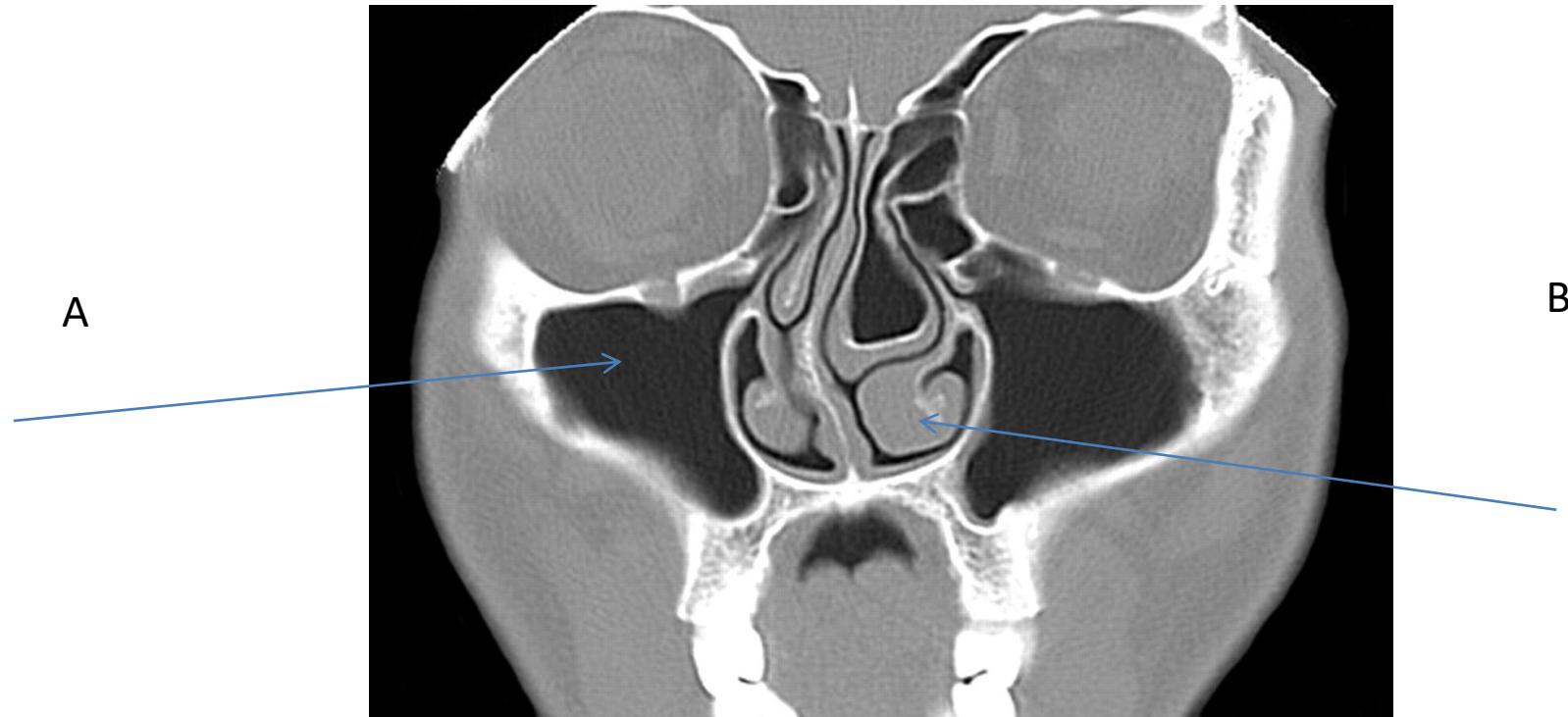
C



Question 2

- A. Laryngeal web
- B. Acute otitis media
- C. Cauliflower ear

Question 3



1. Mention 2 abnormalities seen in the above picture.
2. What are the structures pointed in A, B?

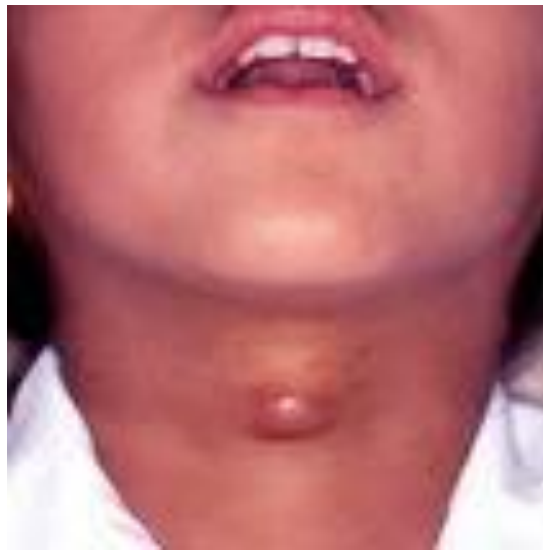Question 3

- 1. Deviated nasal septum to the right, Hypertrophied left inferior turbinate, Concha bullosa in left middle turbinate
- 2. A- Right maxillary sinus
B- Left inferior turbinate

Question 4

Young female patient presented with this lump in her neck. On examination, the mass moves with protrusion of the tongue and swallowing.

1. What is your diagnosis?
2. What is its embryonic origin?
3. Give other two midline congenital masses in the neck.



Question 4

- 1. Thyroglossal Cyst
- 2. Dermoid cyst

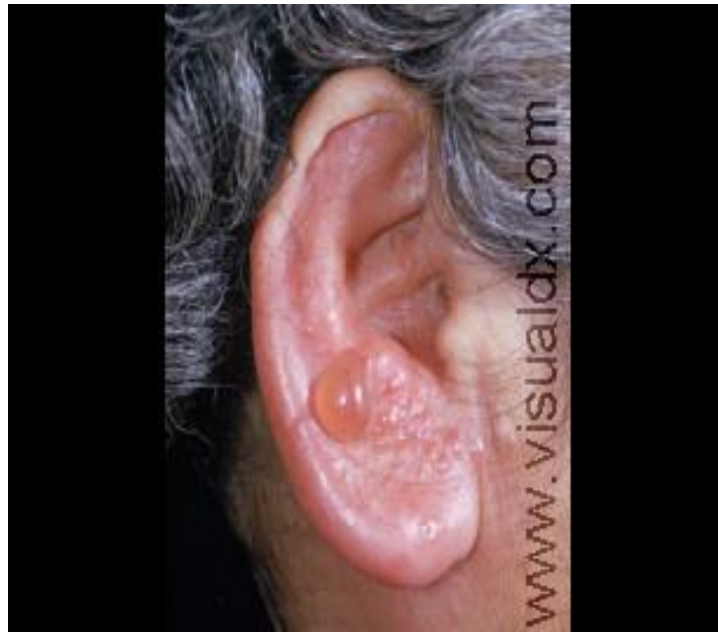Lipoma

(They asked for a *congenital* mass, but accepted all midline masses regardless if they're congenital or not.)

Question 5

Poorly controlled diabetic patient presented with otalgia, decreased hearing , and unilateral facial palsy.

1. What is the most likely diagnosis?
2. Give 2 modalities of treatment.
3. What is your concern regarding the patient's eye?

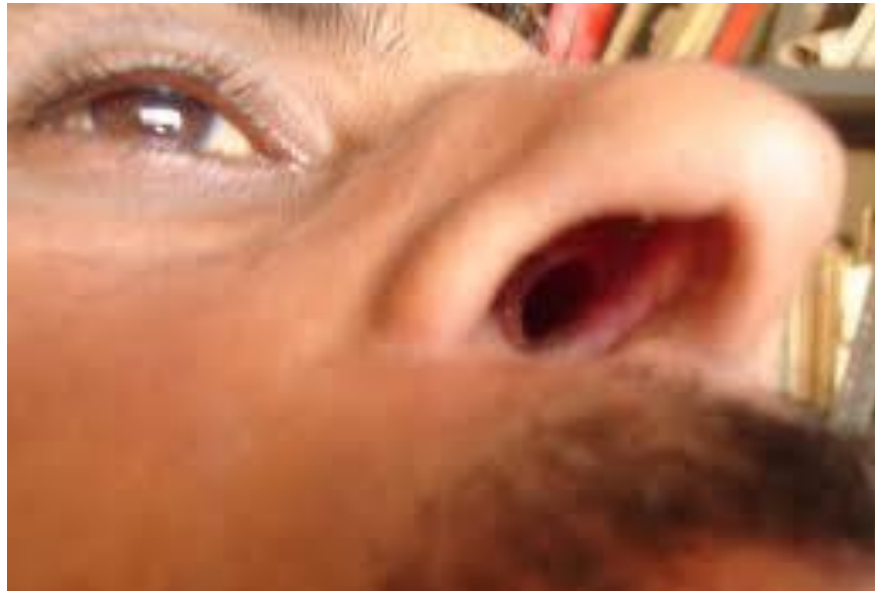

Question 5

1. Ramsey Hunt Syndrome
2. Oral antiviral, oral steroids
3. There is a risk of corneal involvement (keratitis) so patient should protect his cornea

Question 6

1. Give two causes for this condition.
2. Mention 2 symptoms the patient may complain of.

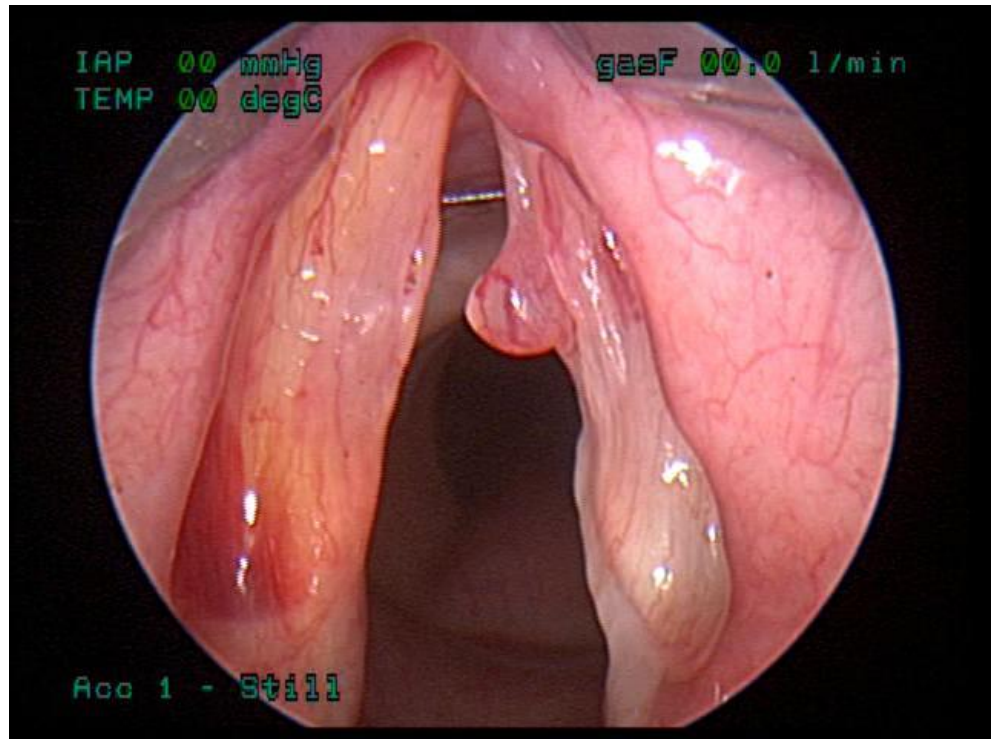


Question 6

***It's Septal Perforation!**

1. -post-op complication like septoplasty or rhinoplasty
 - cocaine sniffing
 - aggressive nose picking
 - blunt trauma
 - NG tube placement
 - tumor
2. -runny nose
 - whistling sound during nasal breathing
 - episodes of epistaxis
 - nasal obstruction

ENT Exam B1 + B2 2013



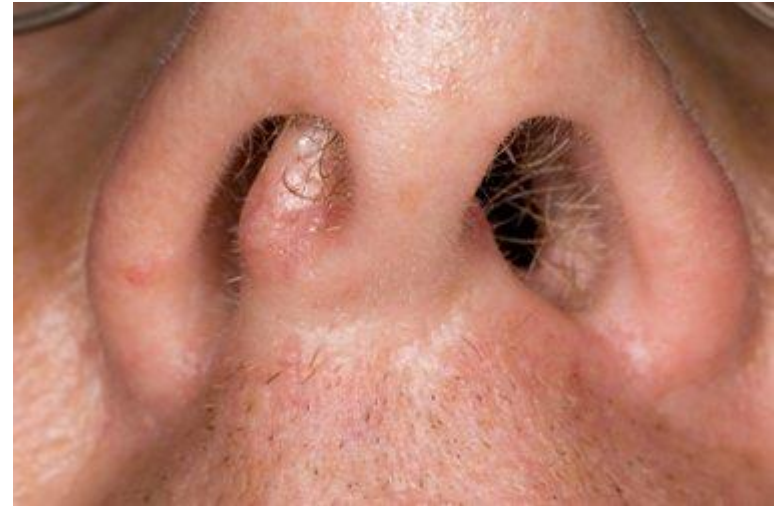Q1)

- Diagnosis
- site of the polyp
- right or left side vocal cord

- laryngeal polyp (vocal cord polyp)
- on the junction btw anterior 1/3 and posterior 2/3
- Right

Q2)

- Give two diagnosis
- Two investigation
- a question regarding the picture [nasal speculum]

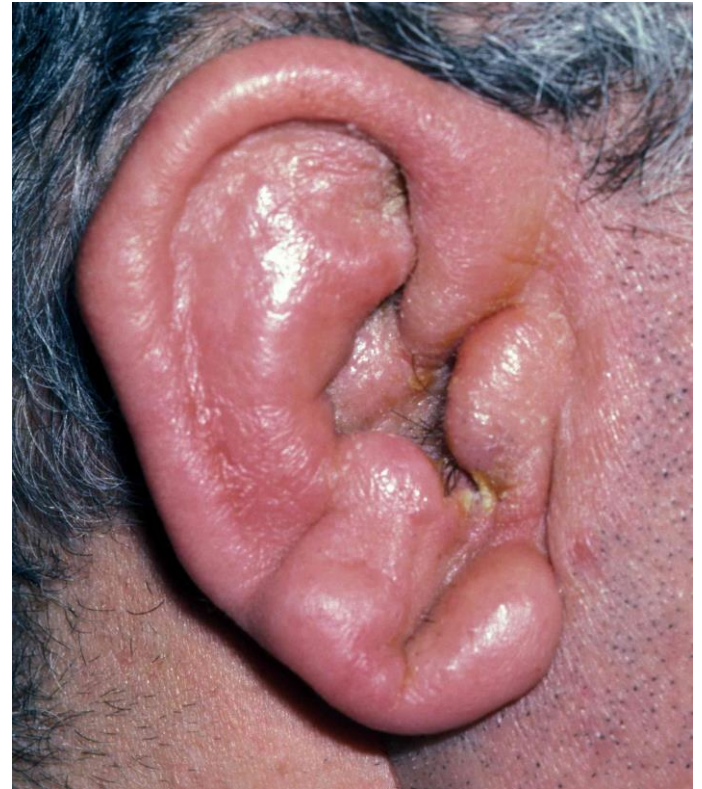


- nasal polyp, septal hematoma
- Anterior rhinoscopy, CT-scan
-

Q3)

- Diagnosis
- Most common microorganism
- Treatment
- Complication

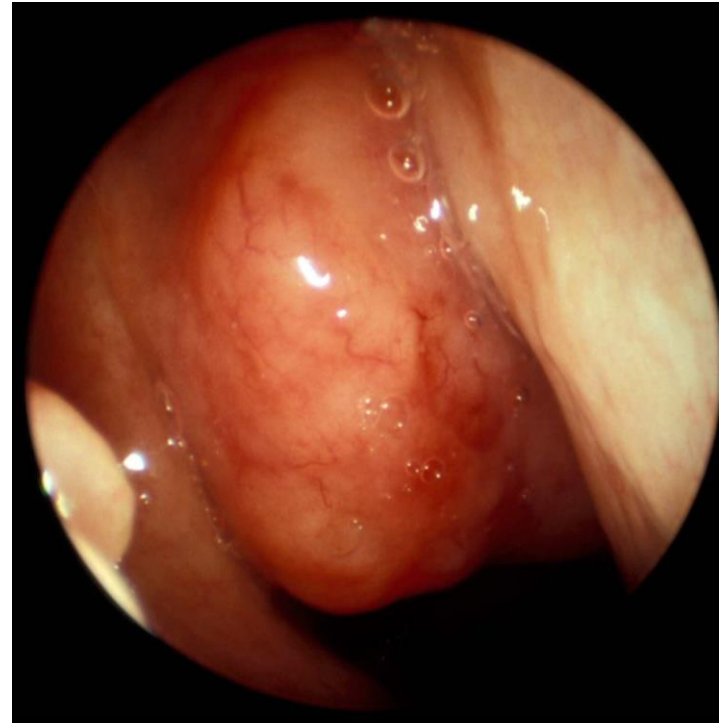
- Perichondritis
- Pseudomonas aeruginosa
- antibiotics, drainage (if there is pus accumulated)
- cauliflower ear ,



Q4) 60 Year old patient complaining of swelling of the lymph nodes in the neck , excessive rhinorrhea and decrease in hearing ...

- most common type??
- most common histological type ??
- treatment
- most common site

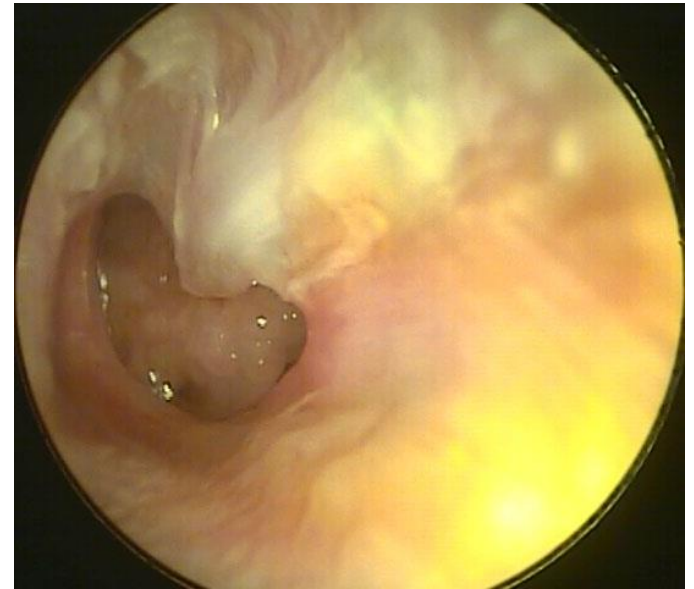- nasopharyngeal tumor
- SCC
- Surgery (excision)
- lateral nasopharyngeal recess or fossa of Rosenmüller (a recess behind the entrance of the eustachian tube opening



Q5)

- diagnosis
- most common microorganism
- investigation
- treatment

- Chronic otitis media
- *Pseudomonas aeruginosa*
-
-



ENT MINIOSCE EXAM B3,4

DONE BY : **SAMAH NIMER**

1st question

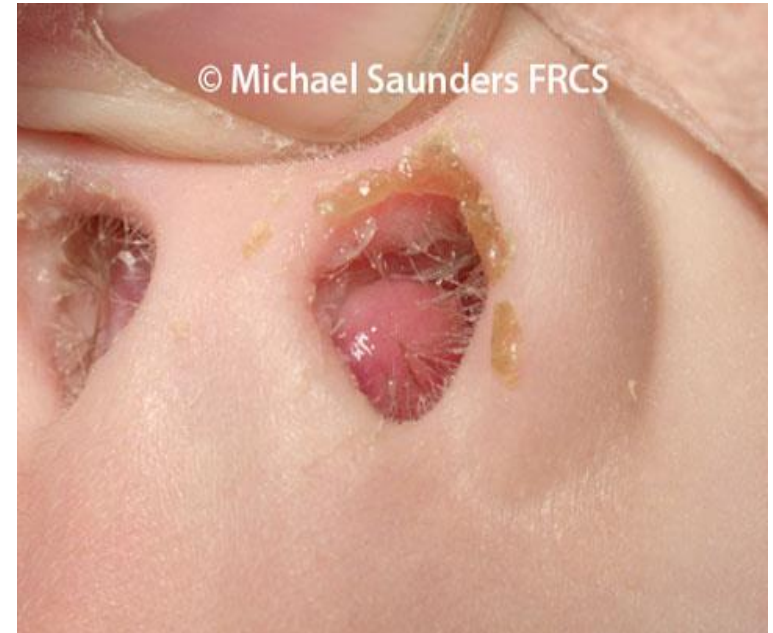- Audiogram (sensorineural hearing loss) with a hx of tinnitus and vertigo
- 1- the diagnosis ? Meniere's disease
- 2- 2 lines of treatment ?
- - low salt diet
- -diuretics
- -also anti vertigo , anti emetics

2nd question

- Audiogram (normal right ear , CHL left ear)
- 1- what's the result of rinne test for
- Rt ear :+ve $ac > bc$
- Left ear: -ve $bc > ac$
- 2-Weber result : lateralized to the cond.

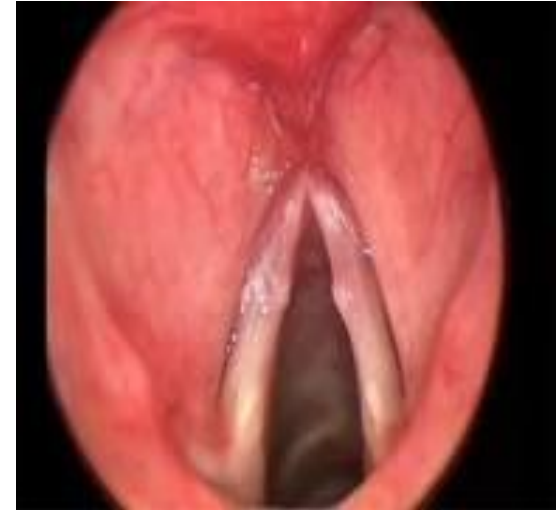3rd question

- 1- diagnosis :
- -nasal septal hematoma
- 2- 2 lines of treatment?
- - evacuation “drainage”
- - antibiotics
- 3- if left untreated ,2complications?
- - septal necrosis and perforation
- -infection and abscess formation



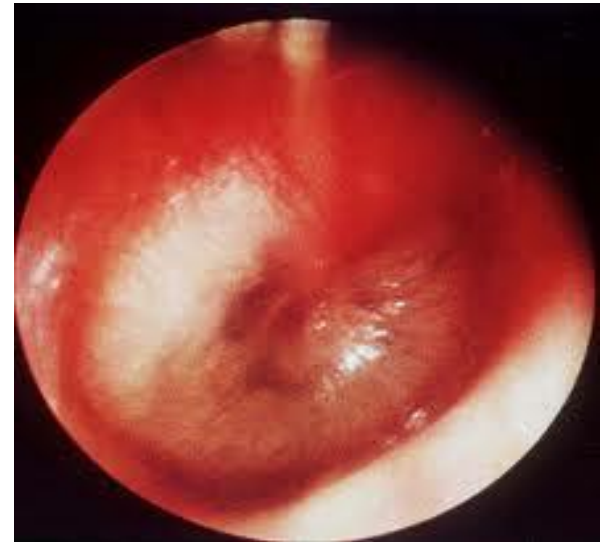4th question

- 1-Diagnosis ?
 - - vocal cord nodules
- 2- treatment?
 - - voice rest
 - - speech physiotherapy
 - - surgery



5th question

- Type 3 MO that cause this condition
- - strep. Pneumonia
- -h.infleunza
- -m. cattahrralis



6th question

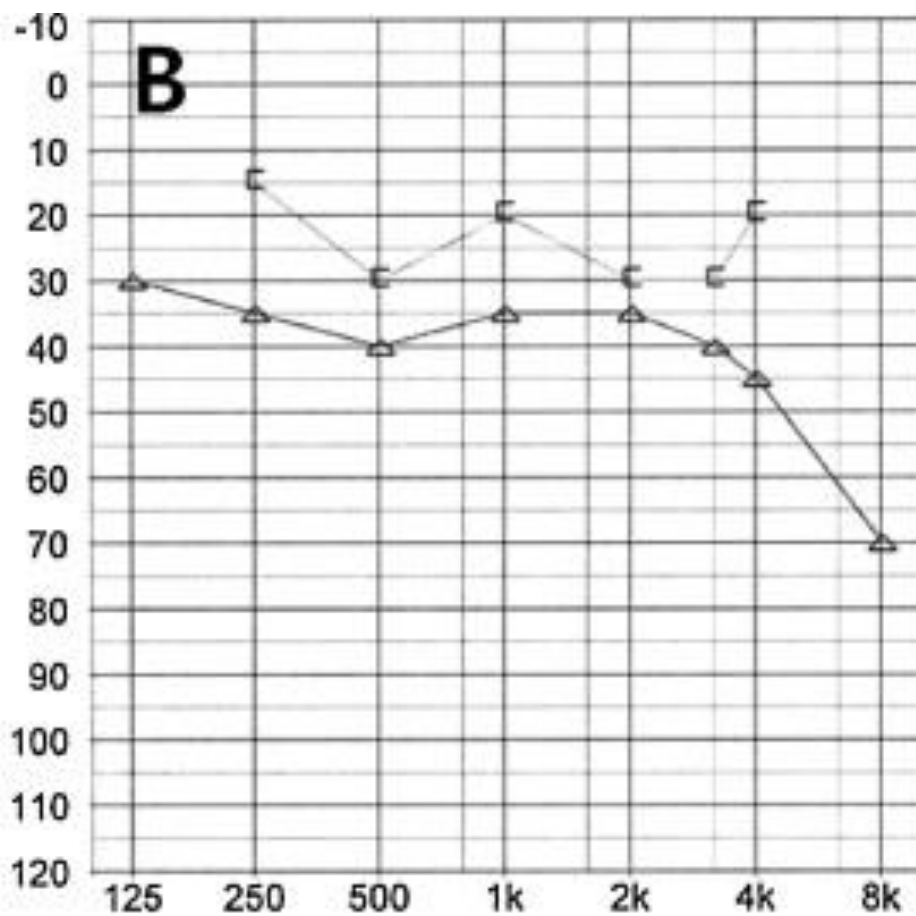
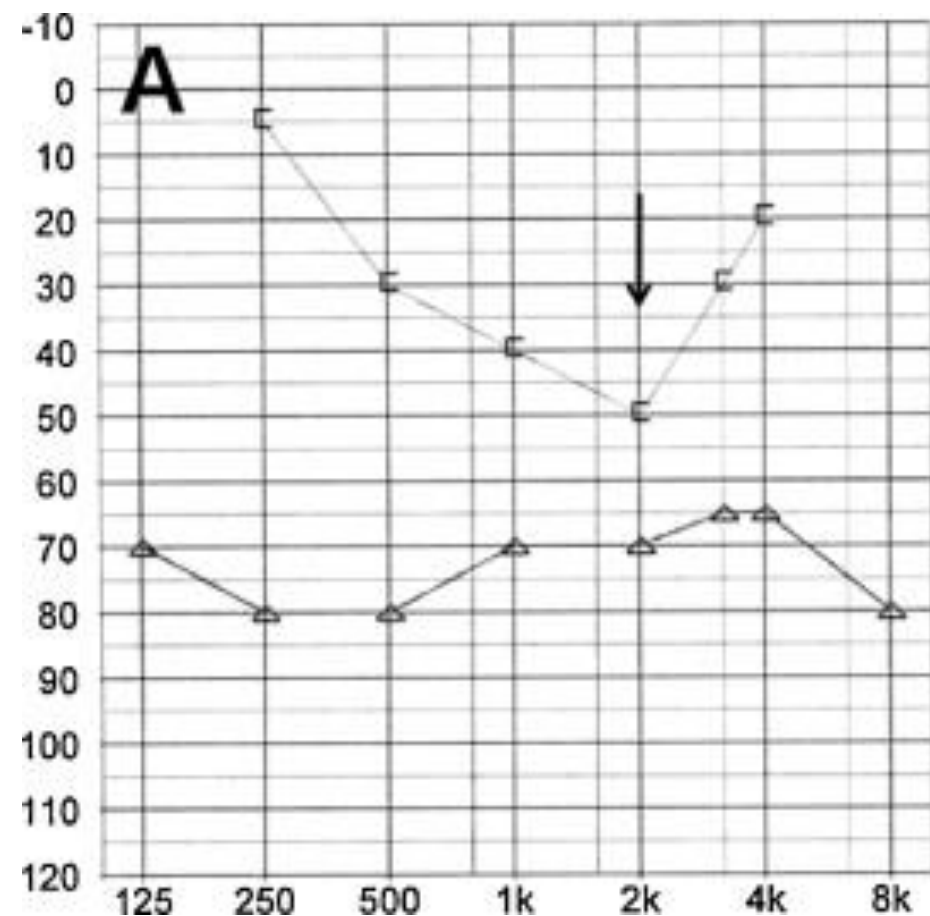
- 3 pics “ msh wad7en “
- 1- tl3t cystic higroma **
- 2- acute follicular tonsilitis “ hay kant wad7a”
- 3- tl3t nasal polyps **

Hope 2014-2015

Groups B4 , B3 exam

ENT

Done by : Talaal Al-Wishah



A 40 year old patient presented with hearing loss with +ve family history and with normal bilateral otoscopic findings ..

1- what is your diagnosis

2- what the sign indicated by the arrow

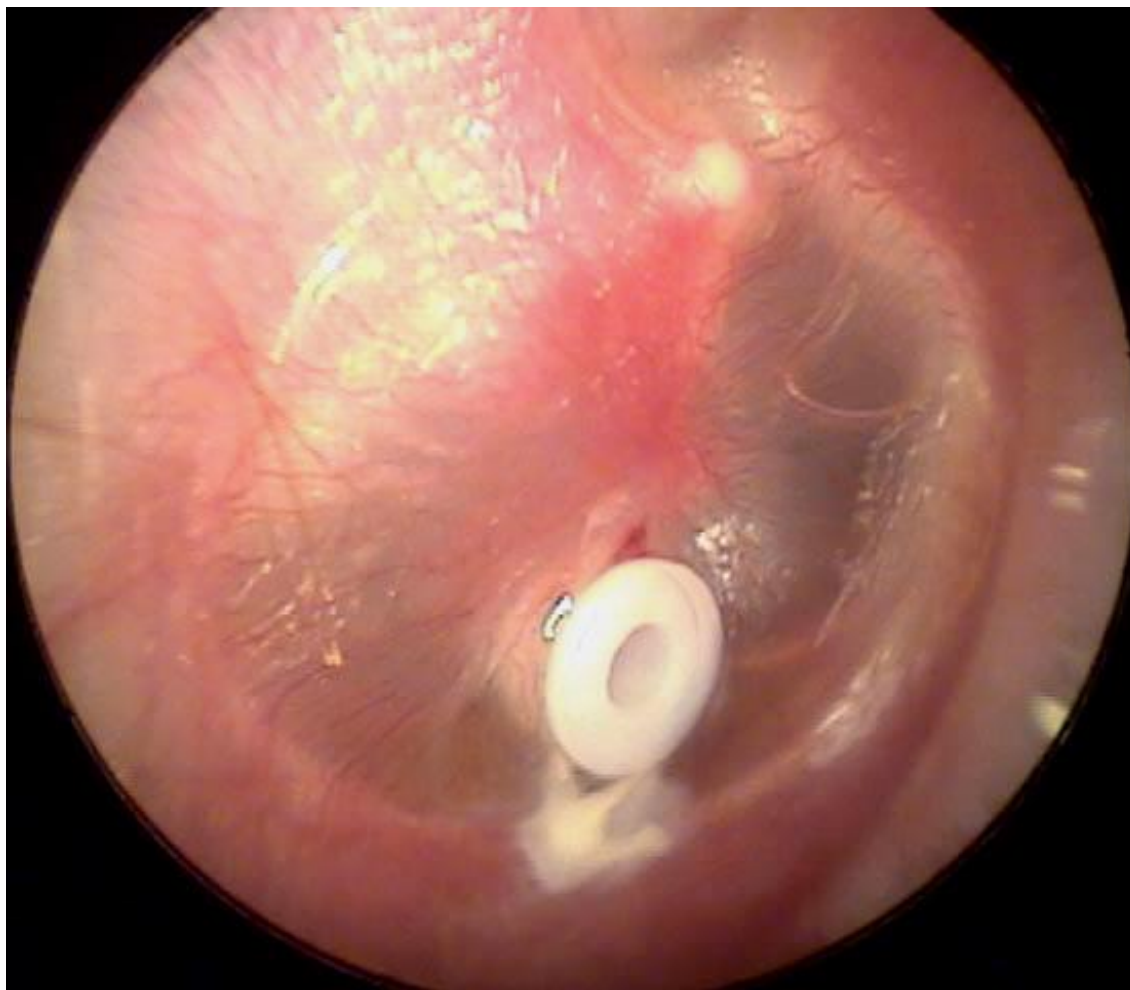
3- mention 2 lines of management

- 1- otosclerosis
- 2- carhart notch
- 3- a- hearing aids b- stapedectomy



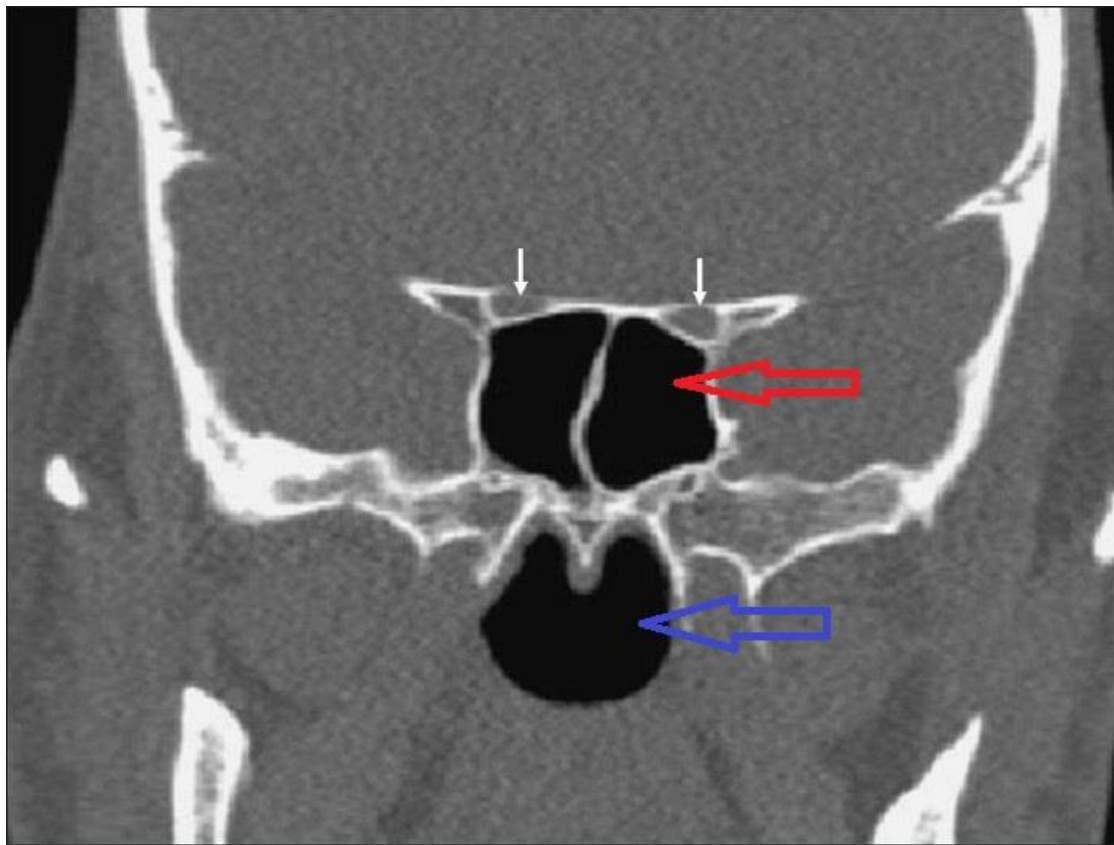
- 1- what is the affected side
- 2- mention 2 cases related to ENT

- 1- Left side
- 2- Ramsy-hunt syndrome , acute or chronic otitis media , mastoditis , temporal bone fracture



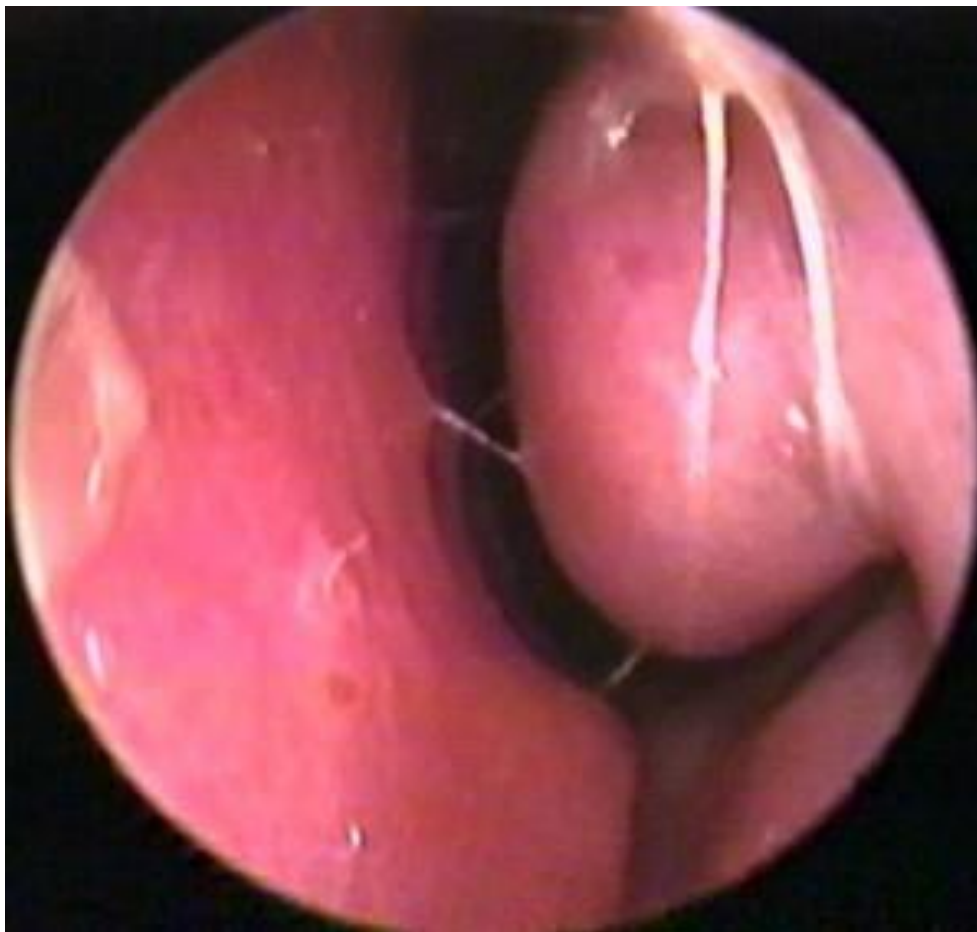
Mention 2 uses of this tube

- 1- Otitis media with effusion
- 2- Eustachian tube dysfunction



- 1- what is the structures indicated by red and blue arrows
- 2- mention 2 pathologies affect them

- 1- Red : sphenoid sinus , Blue : Nasopharynx
- 2- infection allergy abscess malignancy .. etc



Mention 2 arteries supply this area (anterior rhinoscopy)

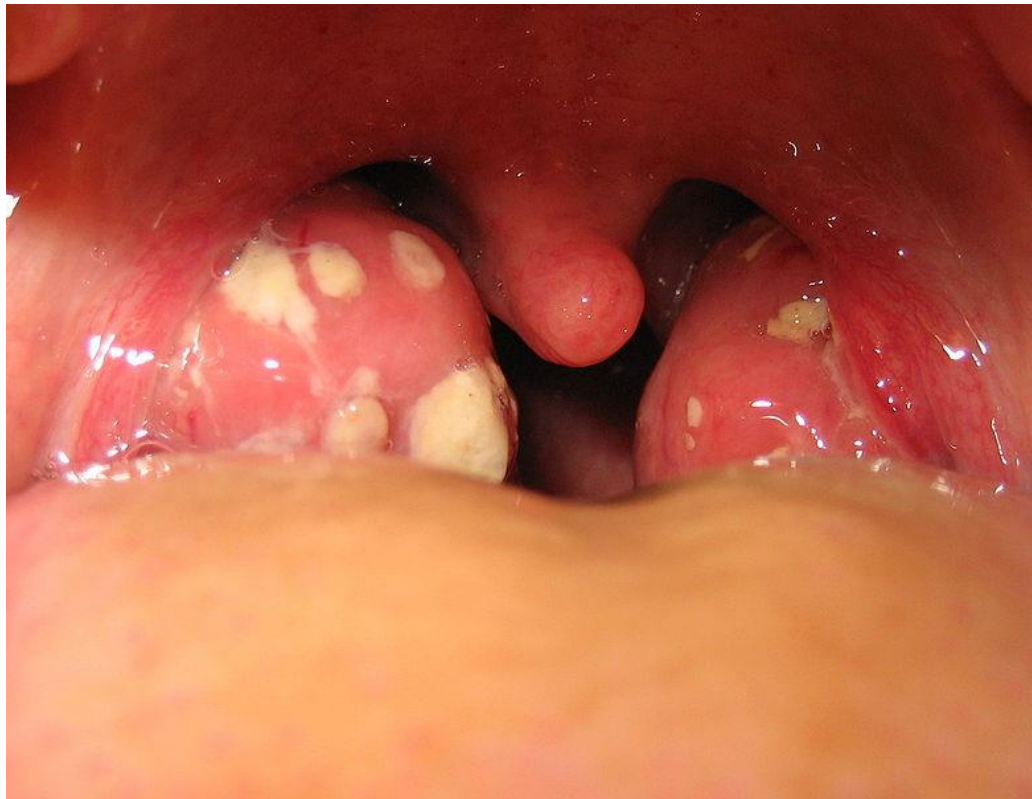- Superior labial , great palatine ,
sphenopalatine , anterior ethmoidal ..

Hope 2014-2015

Groups B1 , B2 exam

ENT

DONE BY SAMER HUSSANY



1-MOST COMMON MO ? GROUP A BETA HEMOLYTIC STREPTOCOCCUS.

2-ABSOLUTE INDICATIONS FOR TONSILLECTOMY?

A- ASSOCIATED WITH PERITONSILLAR ABSCESS.

B- SUSPICION OF MALIGNANCY.

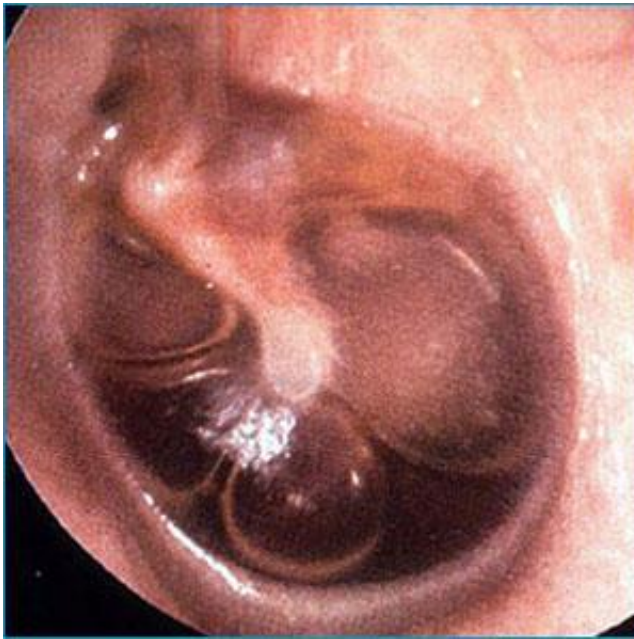
C-ACUTE UPPER AIRWAY OBSTRUCTION.

3-MENTION 2 NON-SUPPURATIVE COMPLICATIONS?

A-RHEUMATIC FEVER/ARTHRITIS.

B-OBSTRUCTIVE SLEEP APNEA.

Q2



1) LEFT OR RIGHT EAR? LEFT EAR

2) WHAT IS UR DIAGNOSIS?

SECRETORY OTITIS MEDIA

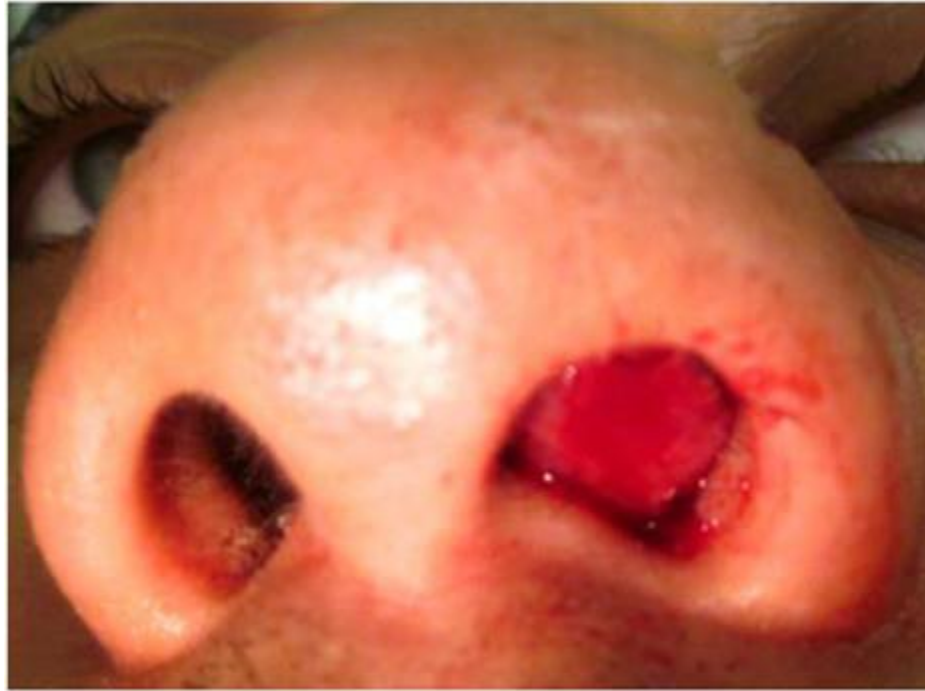3) WHAT IS THE FINDING IN :

A- WEBER'S TEST : SOUND IS HEARD LOUDER IN THE AFFECTED EAR

B- RENNIE TEST : NEGATIVE ON THE LEFT EAR (BONE>AIR)

4) SURGICAL TREATMENT ? GROMMET TUBE(MERINGYOTOMY)

Q3



A CASE AFTER INJURY....

1-WHAT IS YOUR DIAGNOSIS? LEFT SEPTAL HEMATOMA

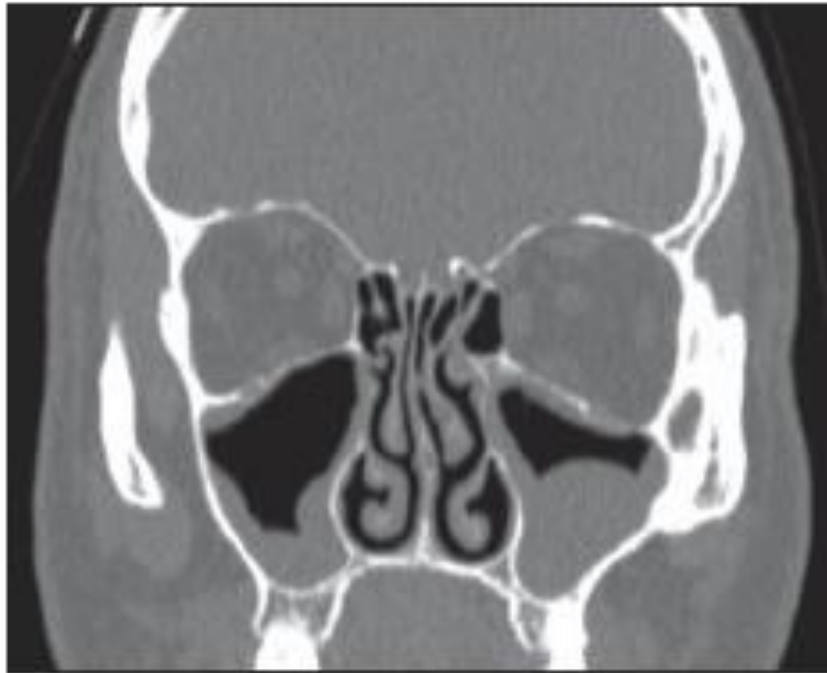2-WHAT'S THE TREATMENT ?

INCISION AND DRAINAGE

3- WHAT ARE THE COMPLICATIONS IF WE DON'T TREAT ?

SEPTAL NECROSIS AND SEPTAL PERFORATION

Q4



- **A CASE OF CHRONIC OTITIS MEDIA, ACCORDING TO THE QUESTION**
- **1- WHAT IS THE FINDING IN CULTURE?**
- **STREP. PNEUMONIA, STAPH. AUREUS (ANY UPPER BACTERIA)**
- **2- EXTRACRANIAL COMPLICATIONS?**
- **ORBITAL ABSCESS, (OSTEOMYELITIS!!!!)**

وَلَا تَيَاسُ فَإِنَّ الْيَأْسَ كُفْرٌ
لَعَلَّ اللَّهَ يُغْنِي مِنْ قَلِيلٍ
وَأَنَّ الْعُسْرَ يَتَّبِعُهُ يَسْرٌ
وَقَوْلُ اللَّهِ أَصْدَقُ كُلِّ قِيلٍ

على بن أبي طالب

Good Luck !!! :D