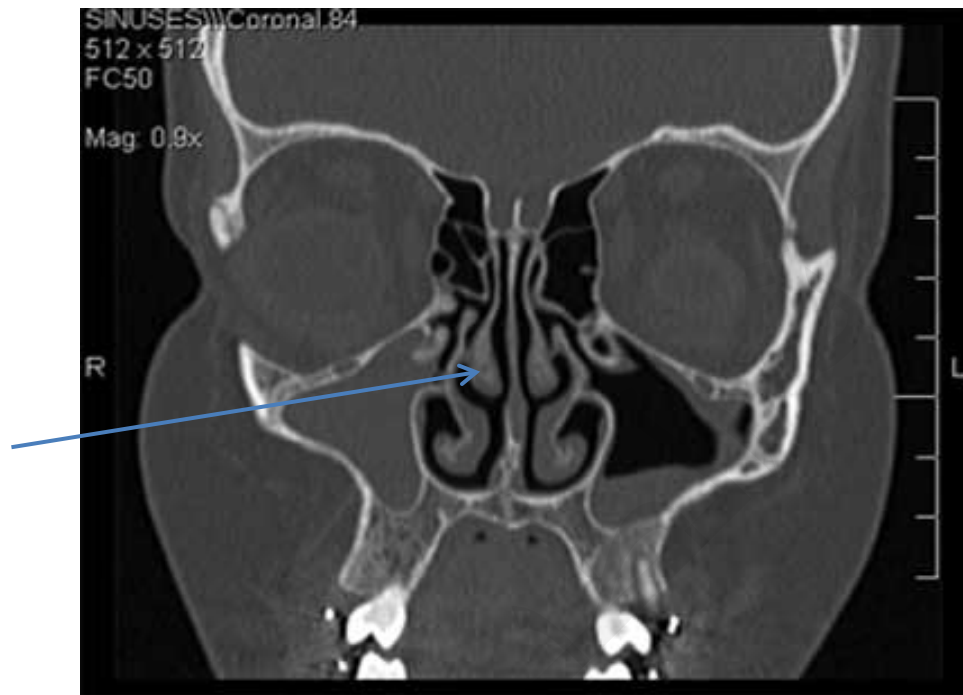




**ENT HU Past Papers**

# ENT Mini OSCE

Older Batches



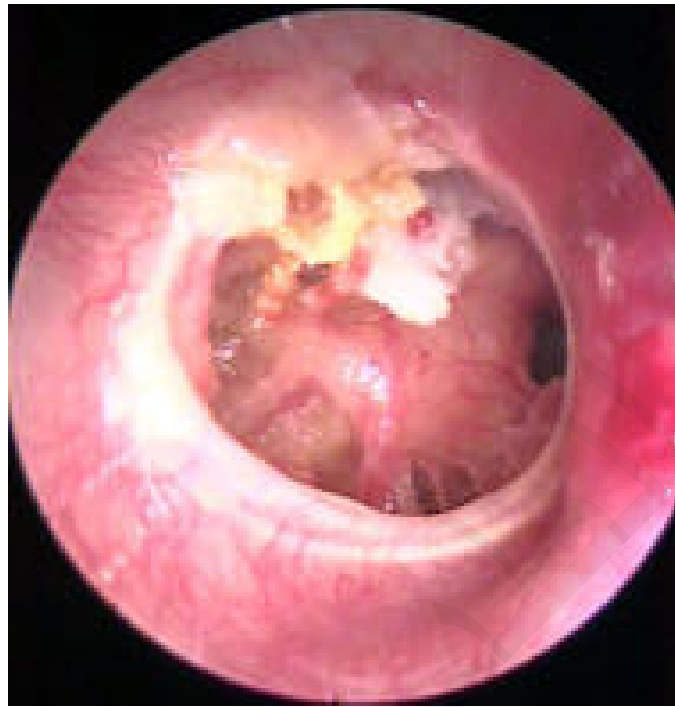What is the diagnosis ? acute rhinosinusitis •

Mention 2 Intra cranial complications? •

Epidural abscess , brain abscess

name the structure that the arrow points to? •

Right middle turbinate



What is the diagnosis? Cholesteatoma a.

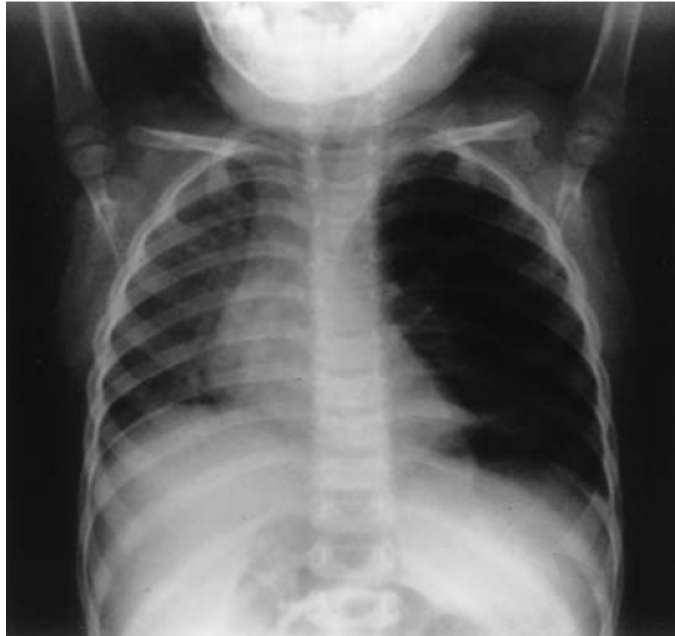Tympanometry ? type b b.

What is the management ? .c

Aural toilet and keeping the ear dry .1

2. Tympanomastoidectomy (tympanomastoid surgery)

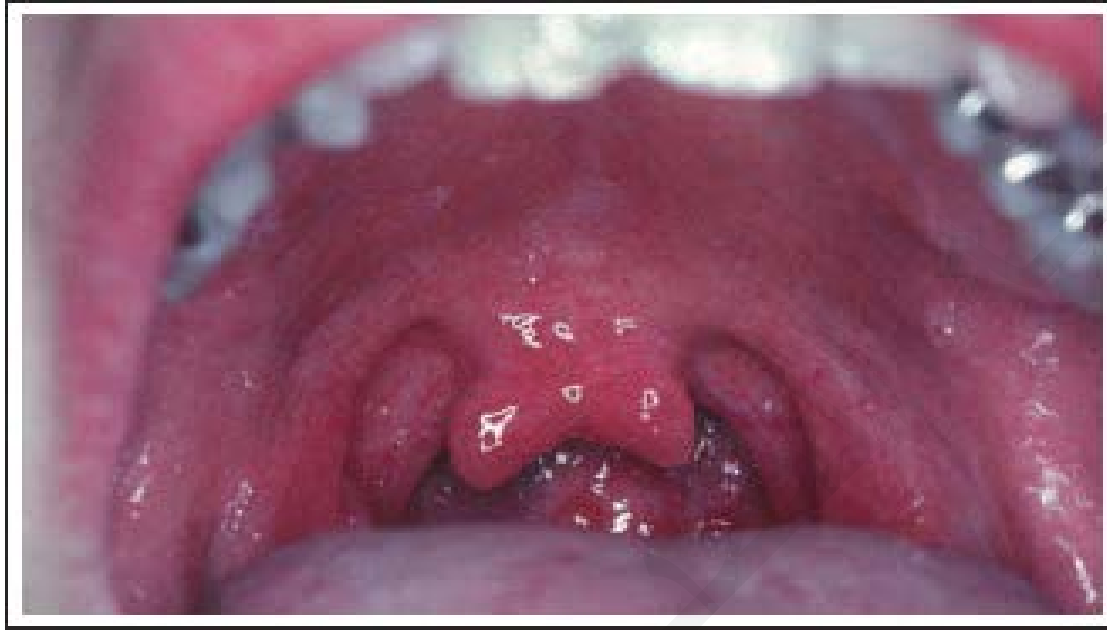



What is the diagnosis ? foreign body a.  
aspiration/inhalation

Appropriate line of management? b.  
Bronchoscopy

A possible complication? Lung collapse/ c.  
pneumonia/ ...



Mention 2 Indications for tonsillectomy? a.

Cleft palate, recurrent acute tonsillitis with febrile convulsions, obstructive sleep apnea,...

Why is the pathology in the pic significant? b.

Indicates submucous cleft palate

A pic of vocal cords and the pt is a 5.  
teacher:

What is the diagnosis? Singer's nodule / a.  
vocal cord nodule

Describe the line of management? Voice b.  
rest , speech therapy

A pic of rash around the ear: 6.

What is the diagnosis? Ramsey-hunt a.  
syndrome/ herpes zoster oticus

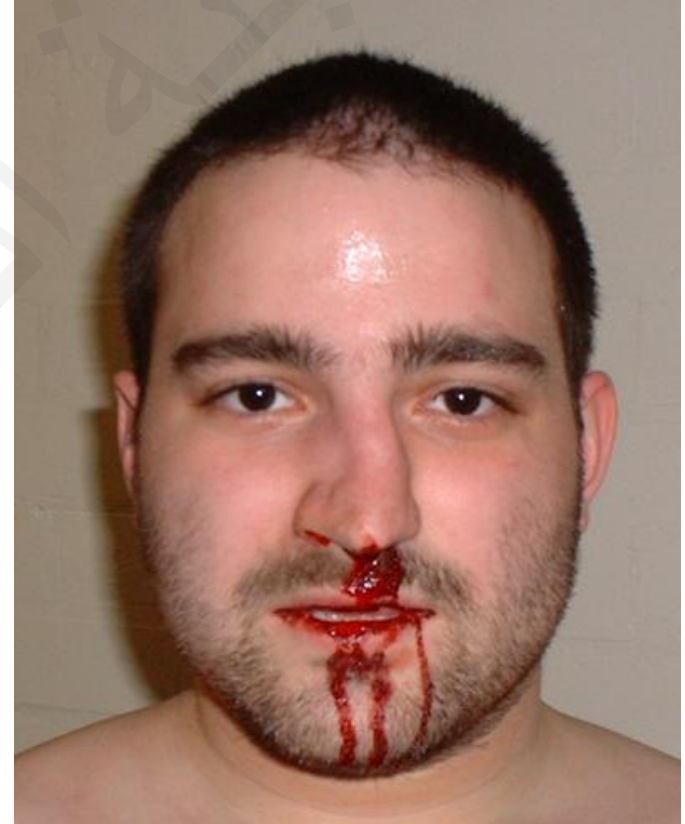Mention one complication? Facial nerve b.  
palsy / sensory neural hearing loss/ corneal  
dryness

What is the first line of management? Trotter's maneuver •

Mention 2 of the non-traumatic causes? HTN, osler weber rendu syndrome (HHT) •

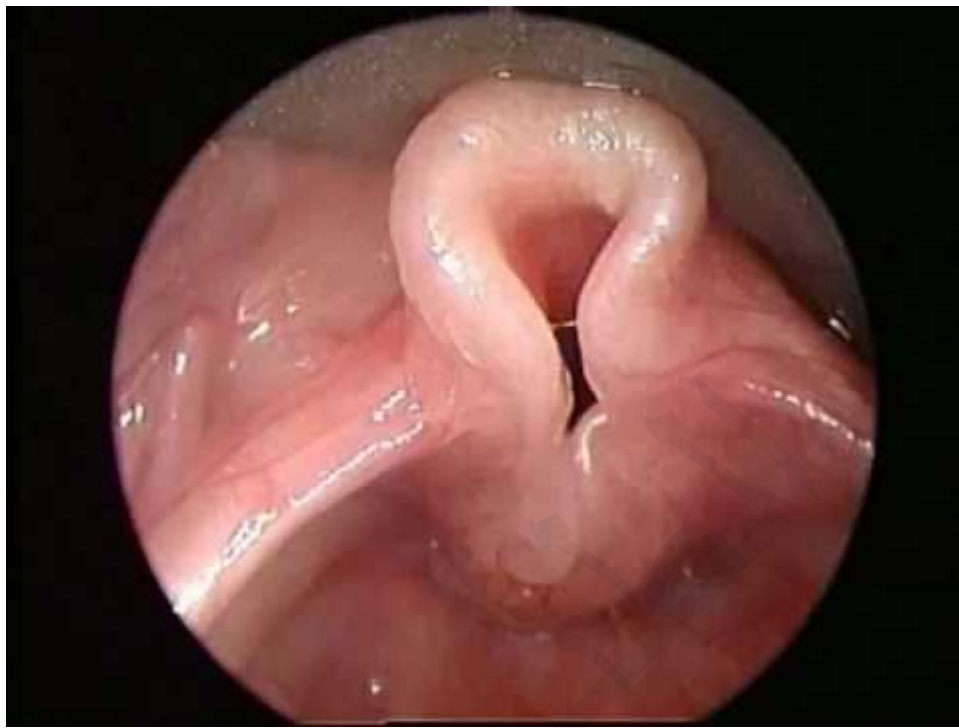Mention a surgery for ttt? •

Ligation of the anterior ethmoidal artery / carotid artery ligation

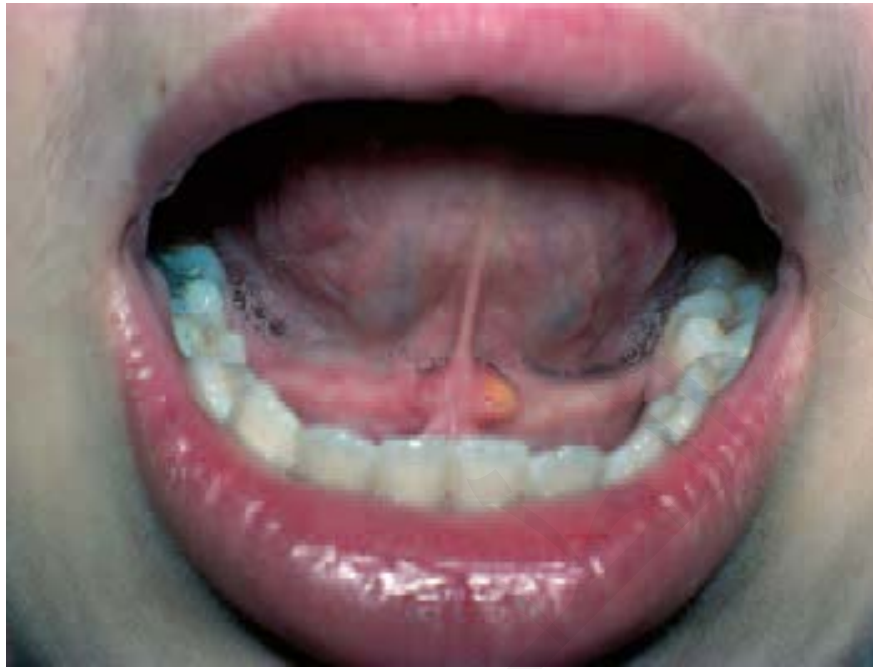

A progressive bilateral hearing loss in old .8  
age/PTA of the pt:

- What is the diagnosis? Presbycusis a.
- Line of management? Hearing aids b.
- Rinne test result? Positive c.



- What is the diagnosis? Laryngomalacia
- What is the sign in the pic? Omega sign



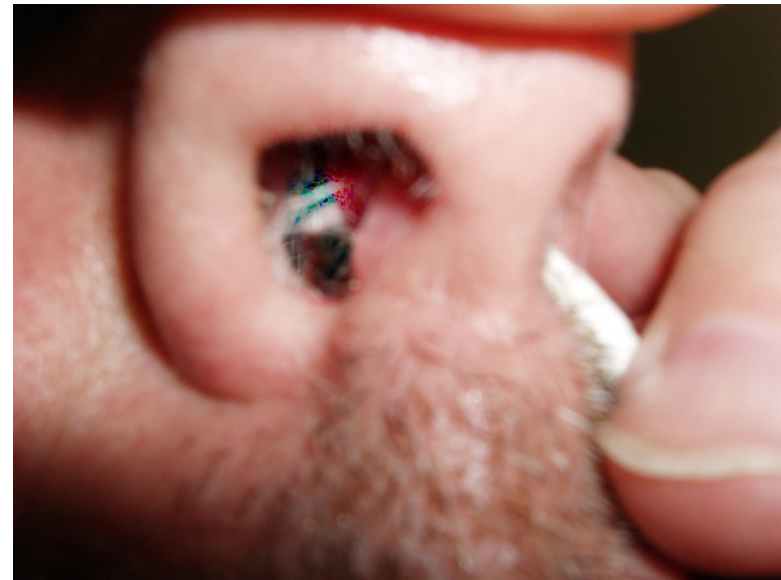What is the diagnosis? Sialolithiasis/ •  
salivary calculus

Imaging study? Sialogram/ CT scan •

Where does the stensen's duct open? Upper •  
second molar tooth

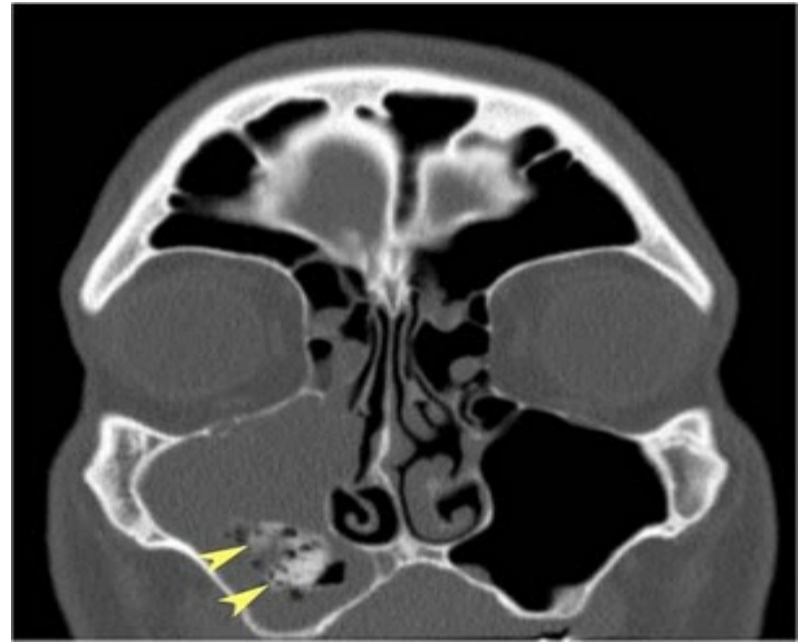


- **Q1..pic of septal perforation & history of multiple surgery in the nose...**
- **1)give 2 causes :**
- **Septoplasty -cautary -nasal digitorum**
- **2)what is the treatment:**
- **Nothing if no symp**
- **Supporative and surgery if symp**
- **Rotational mucosal septalflap**

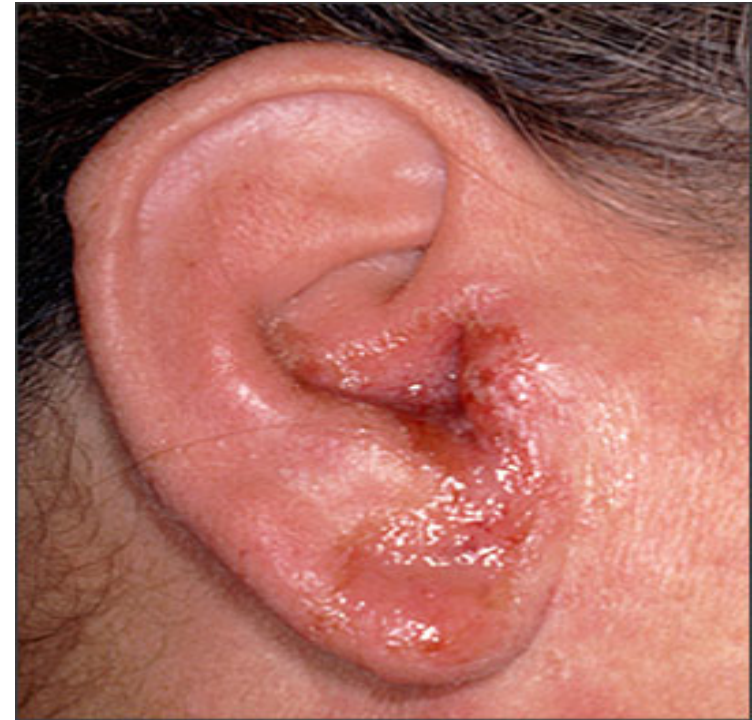

- **Q2..epistaxis( not important pic)**
- **1)what is the blood supply?**
- **Anterior ethmoidal artery –  
sphenopalatine –labial- greater palatine**
- **2)what is the most common site?**  
**Anterior**
- **3)give 2 causes? Truma –foreign body**

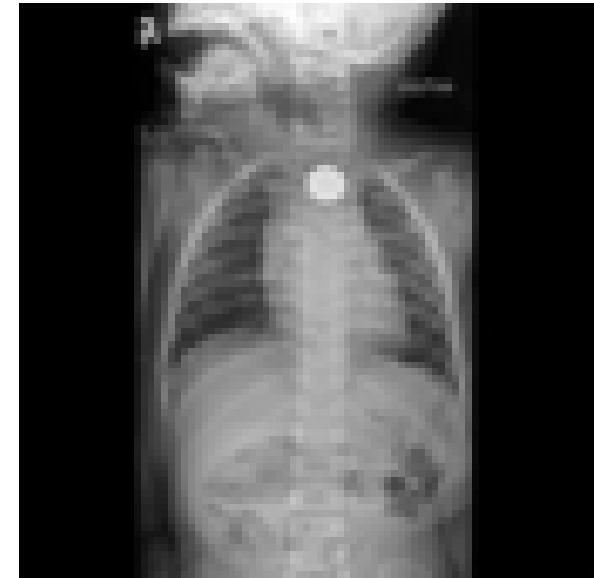
- **Q3..the problem since 6 month...**
- **1)what is ur diagnosis? chronic Maxillary sinusitis**
- **2) write 3 complication ? Brain abcess – meningitis –otitis media**



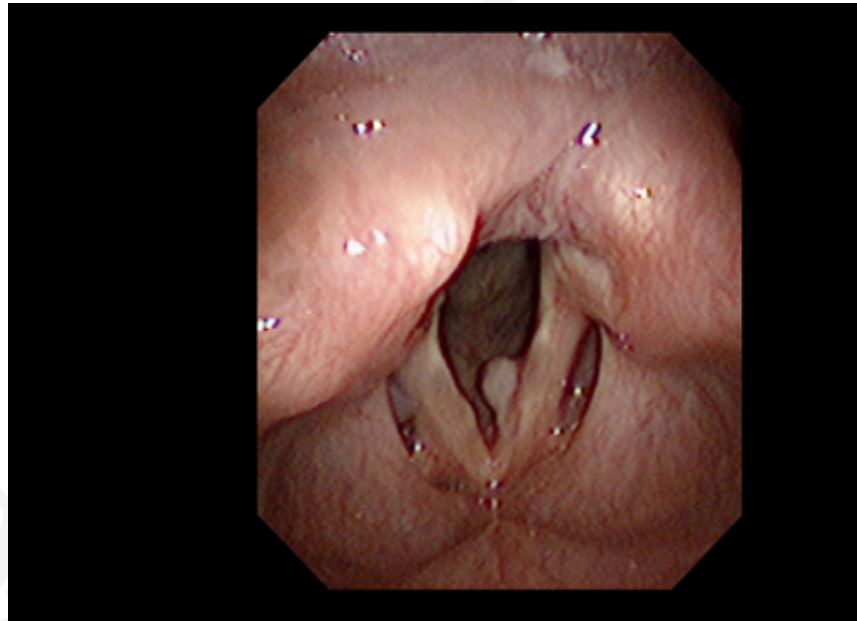
- **Q4..**
- **1)what is the diagnosis?otitis externa**
- **2)What is the treatment? Aural toilet – abx**



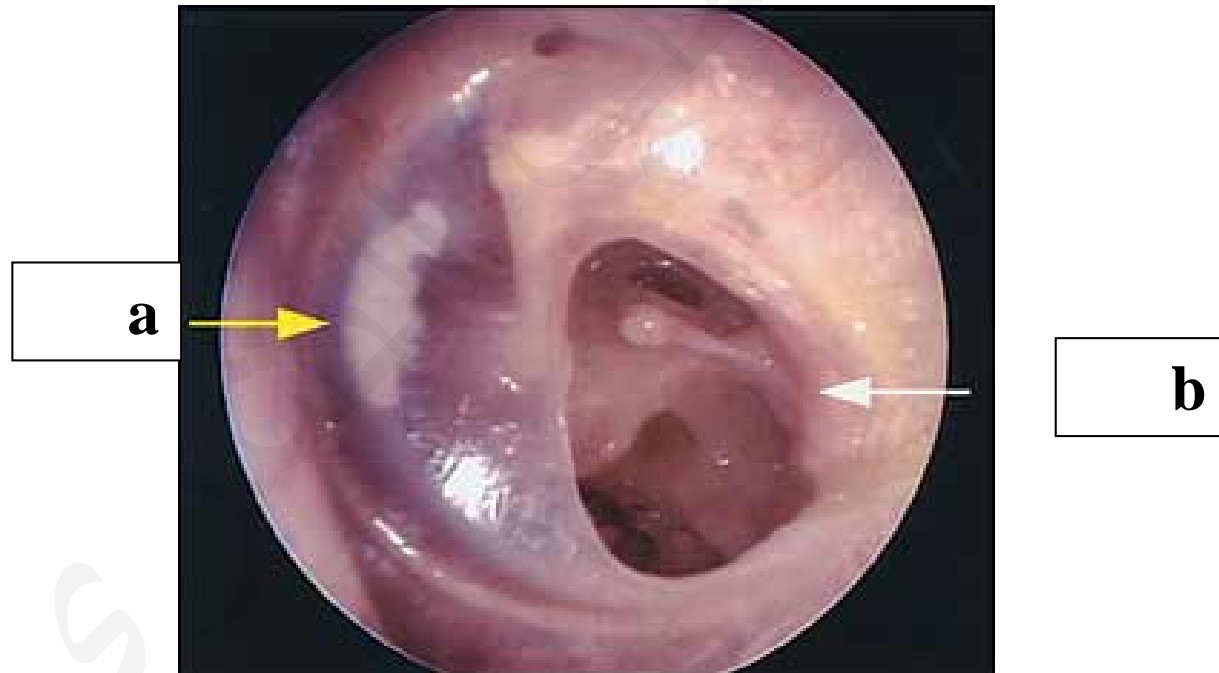
- **Q5..this x-ray for child & history of no SOB & good breathing )**
- **1)what is the most common site? Upper oesophageal sphincter of oesophagus**
- **2)what is the treatment?  
oesophagoscopy**



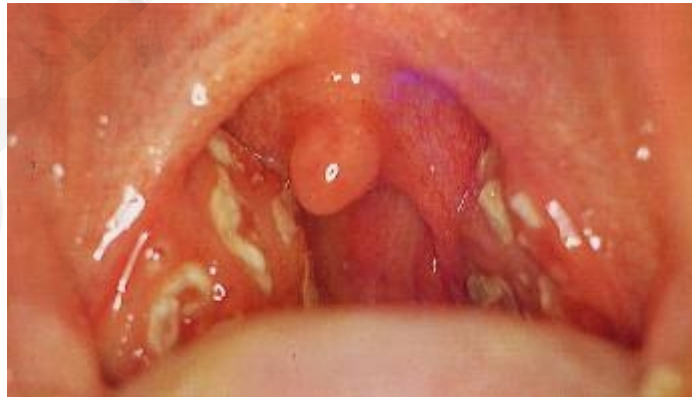- **Q6..history that the patient is teacher & has hoarseness of voice**( from lecture note)
- **1)what is the diagnosis? Singer's nodule**
- **2)give 2 causes? Voice abuse & cough**
- **3)what is the treatment?**



- Q 7...
- 1)what is a? tympanosclerosis
- 2)what is b? septal perforation
- 3)what is the treatment for b? tympanoplasty

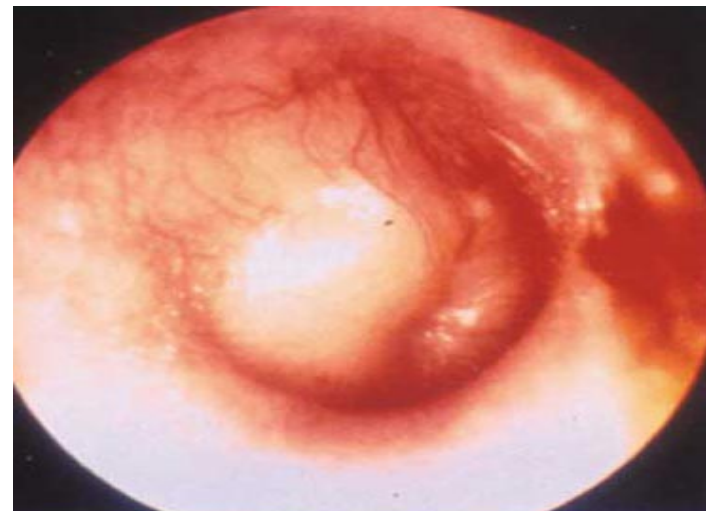


- **Q8...history of fever & ...(obvious)**
- **1)what is ur diagnosis?acute follicular tonsillitis**
- **2)Give 2 complication?peritonsillar abcess – desending infection**

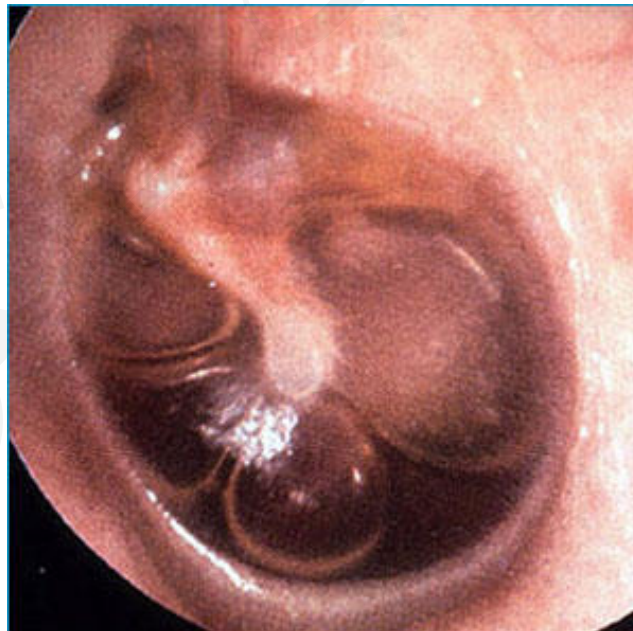




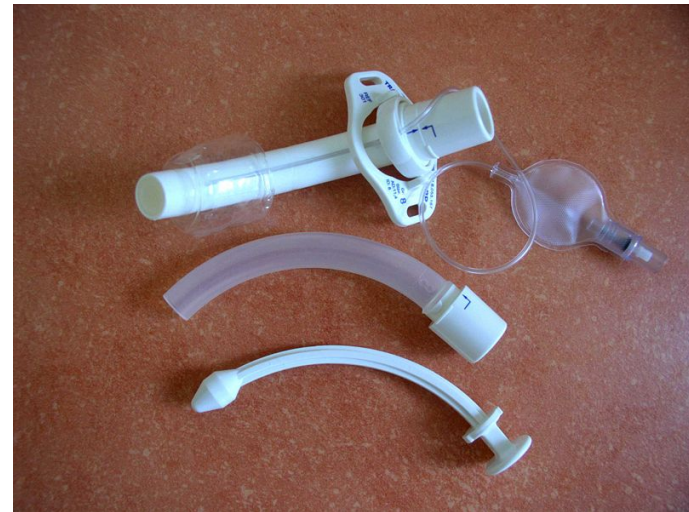- **Q9...**
- **1)what is ur diagnosis? Acute otitis media**
- **2)what is the best treatment? Aural toilet - abx**



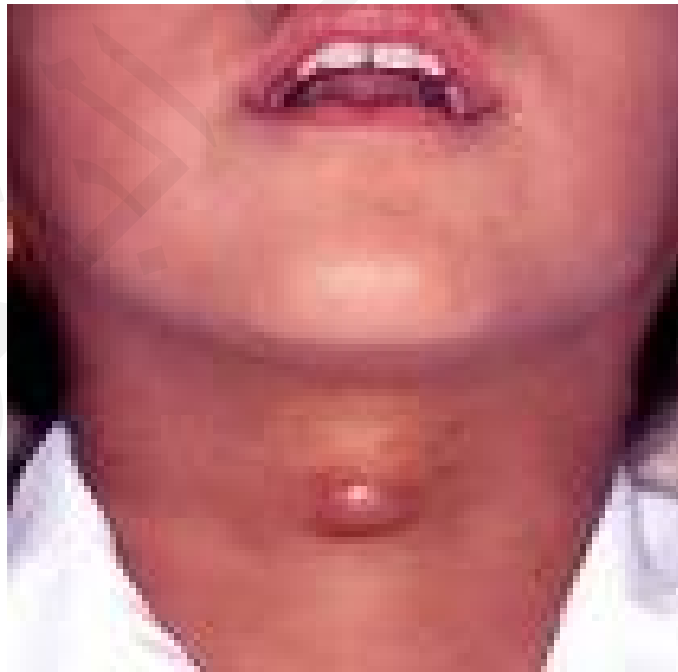- **Q 10...**
- **1)what is ur diagnosis?**  
**secretory otitis media**
- **2)Give a predisposing factor? Adenoid hypertrophy**

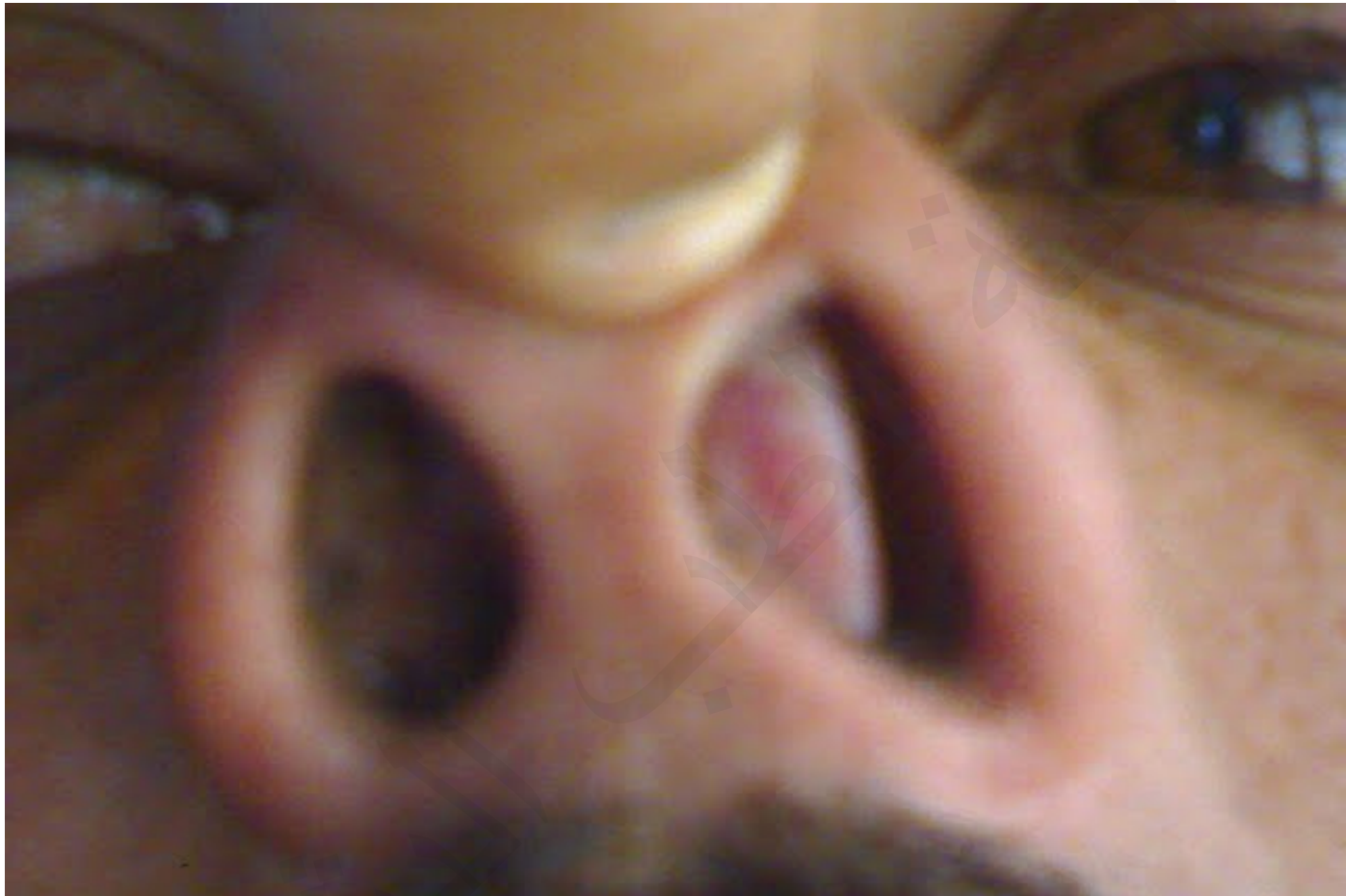

- **Q 11...**
- **1)what is this? Tracheostomy tube**
- **2)Give 2 uses?**



- **Q 12...**
- **1)what is this?**
- **2) give 2 other midline masses?**



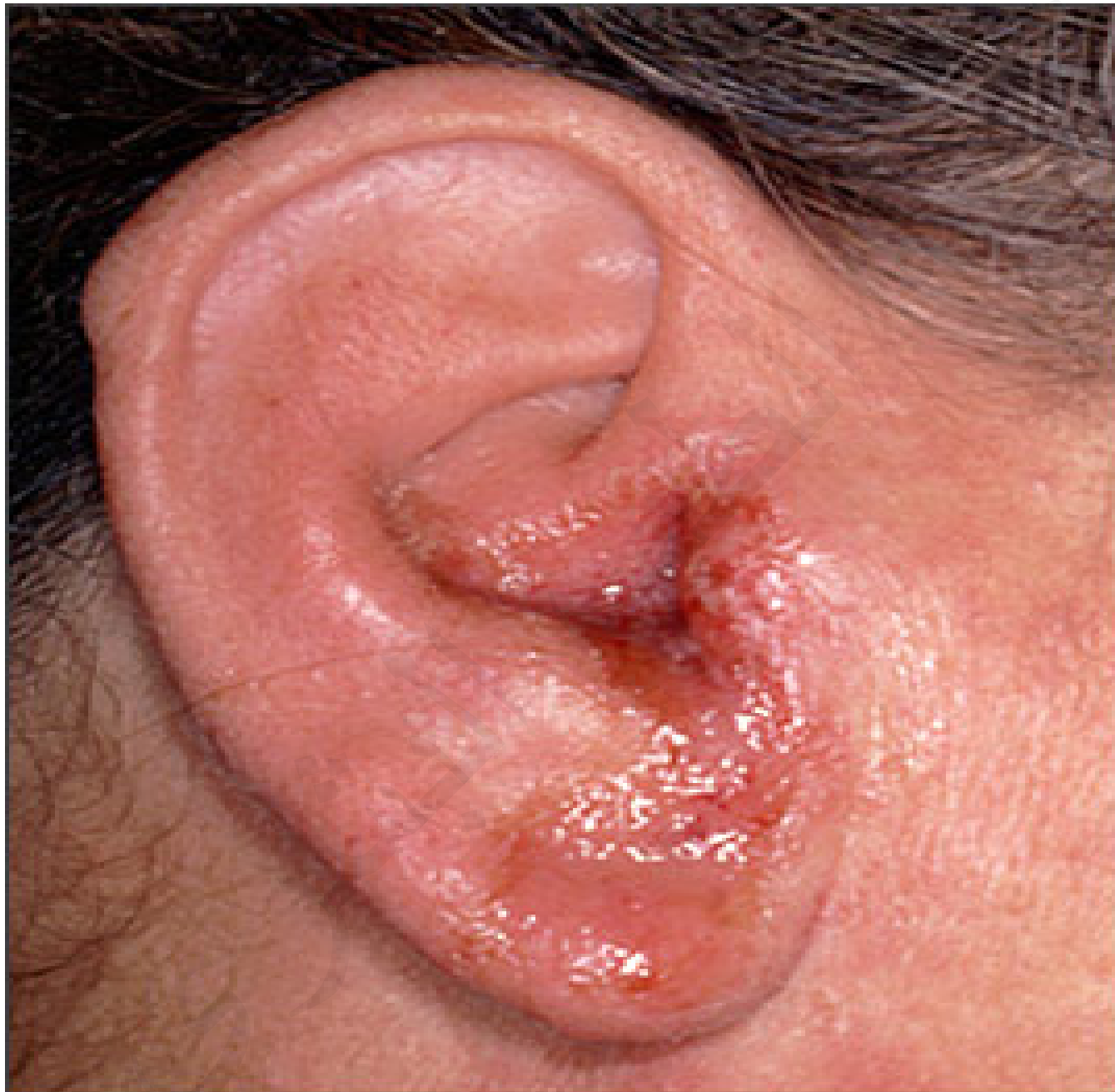

A 20 year old male with history of trauma  
10 years ago

1) What is your diagnosis ?

2) What is the treatment ?

- 1) Septal deviation
- 2) septoplasty



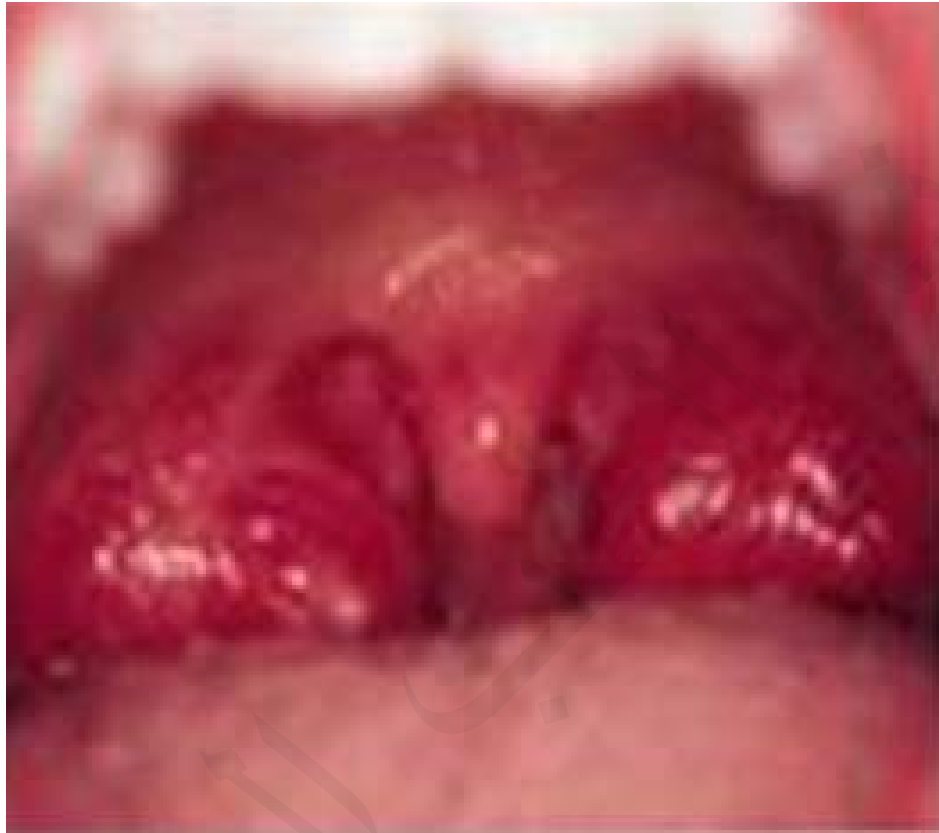

1) What is your diagnosis ?

2) What is the first line of treatment ?

1)Otitis externa

2) regular aural toilet

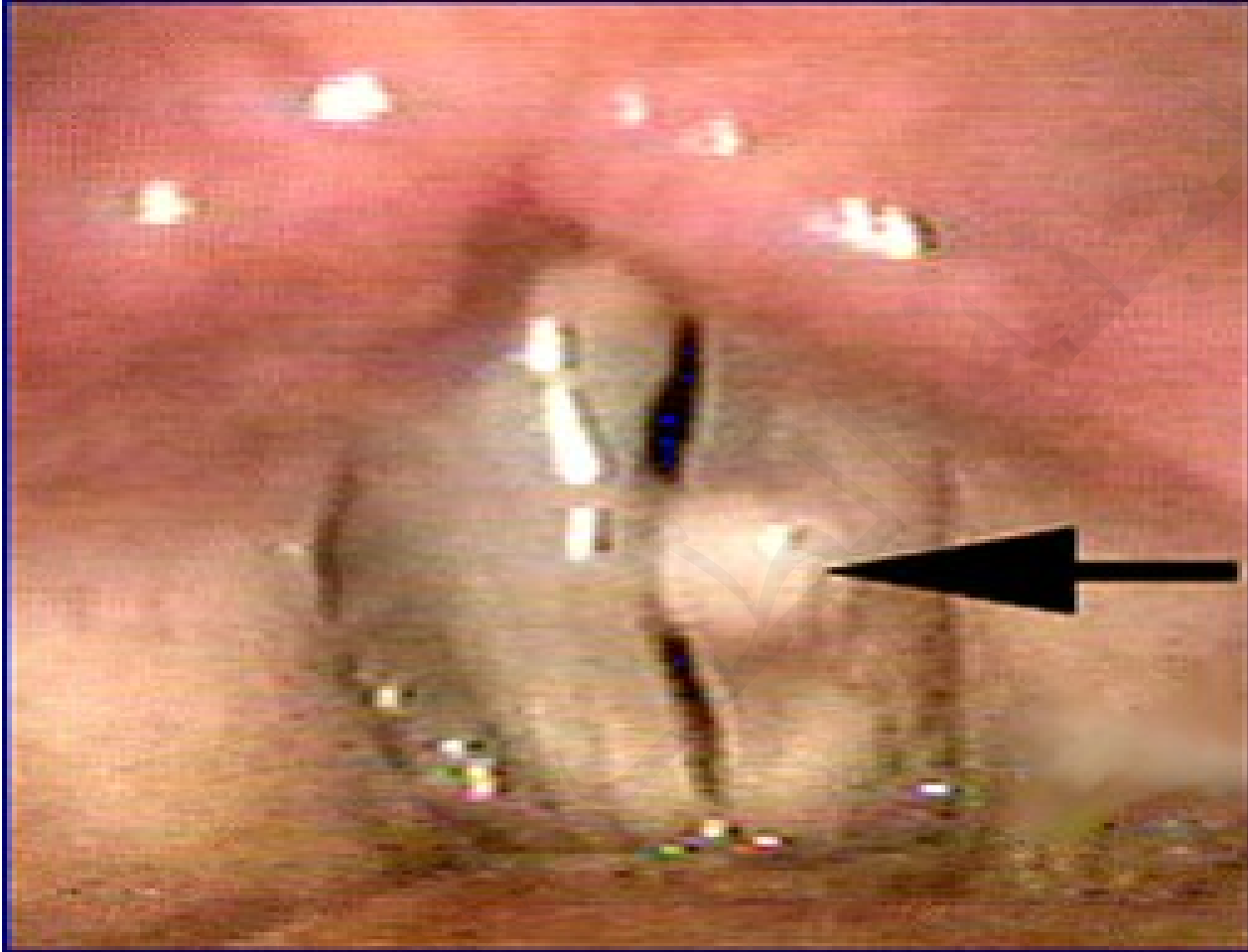


A child presented with recurrent apneas with these tonsils

1) What is your diagnosis ?

2) What is your treatment ?

- 1) Hypertrophied tonsils
- 2) tonsilleectomy



A 40 year old man smoker  
presented with change in voice

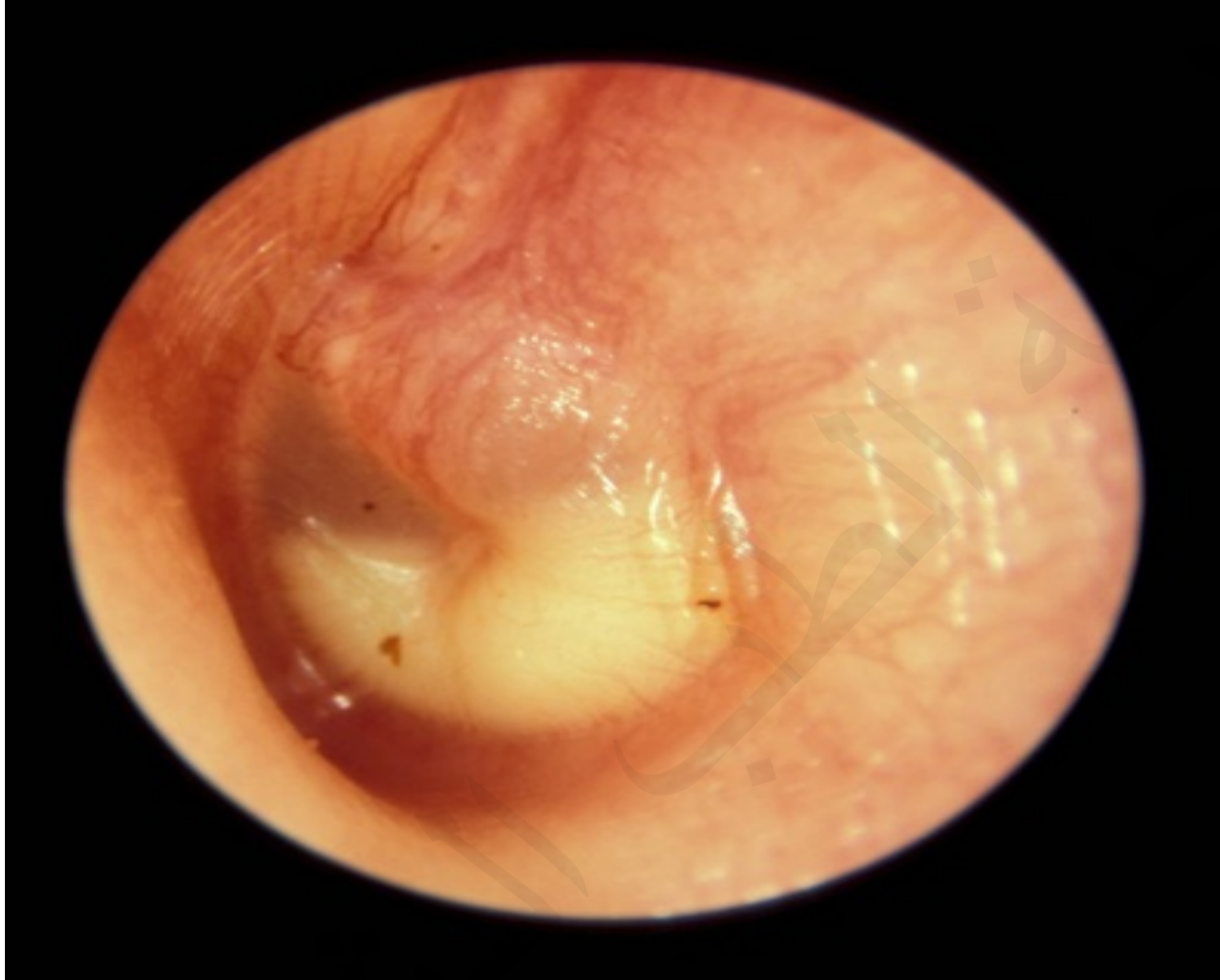
1) What is your diagnosis ?

2) Mention 2 risk factors ?

3) what is the treatment ?

- 1) Laryngeal cyst
- 2) Intubation , congenital
- 3) surgery





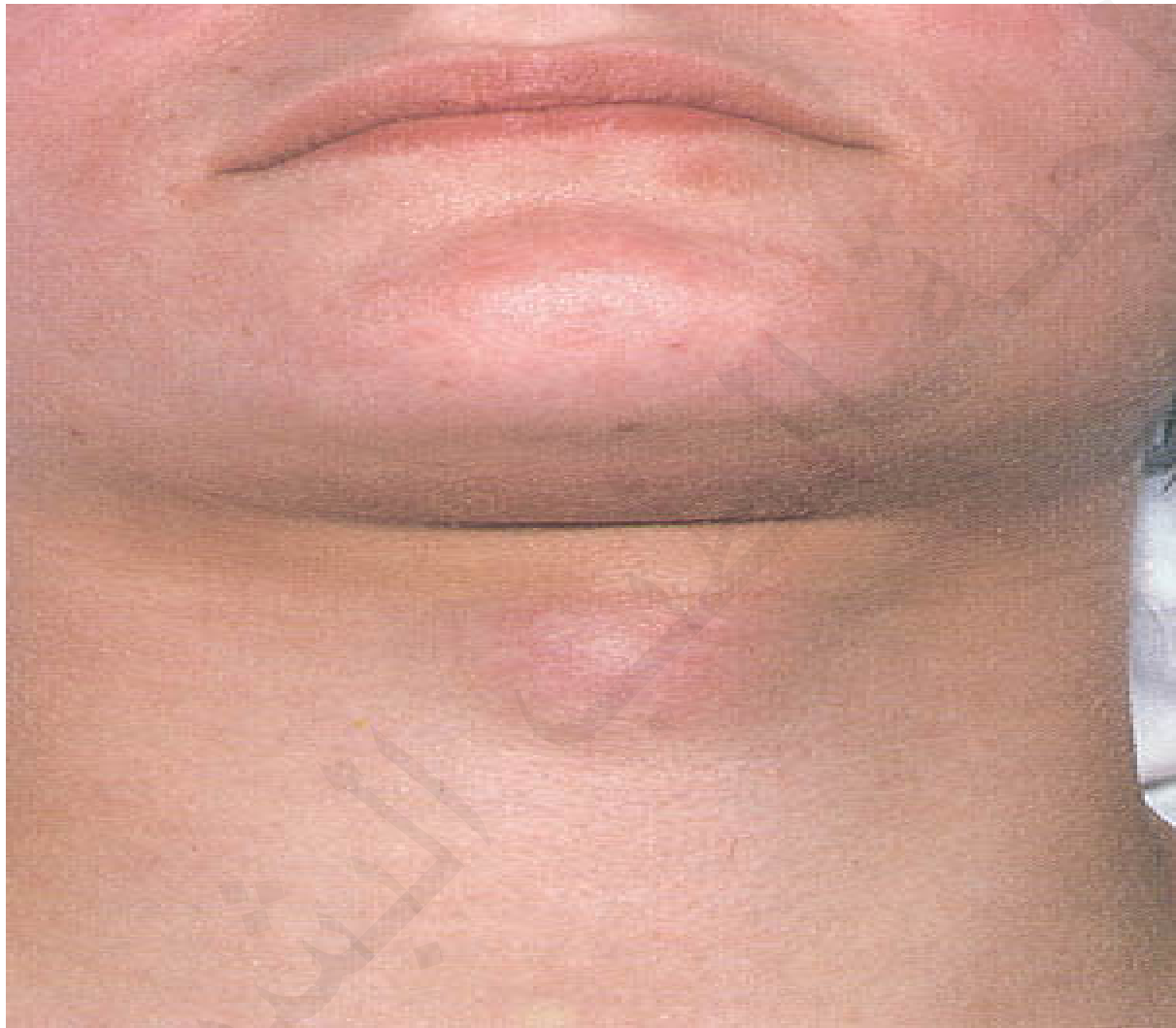A 5 year old child with fever and earache 3 days ago

1) Mention 3 possible complications ?

2) What is the best treatment ?

1) Subdural abscess, epidural abscess, lateral sinus thrombosis, meningitis, facial nerve palsy, mastoiditis, etc.

2) antibiotics



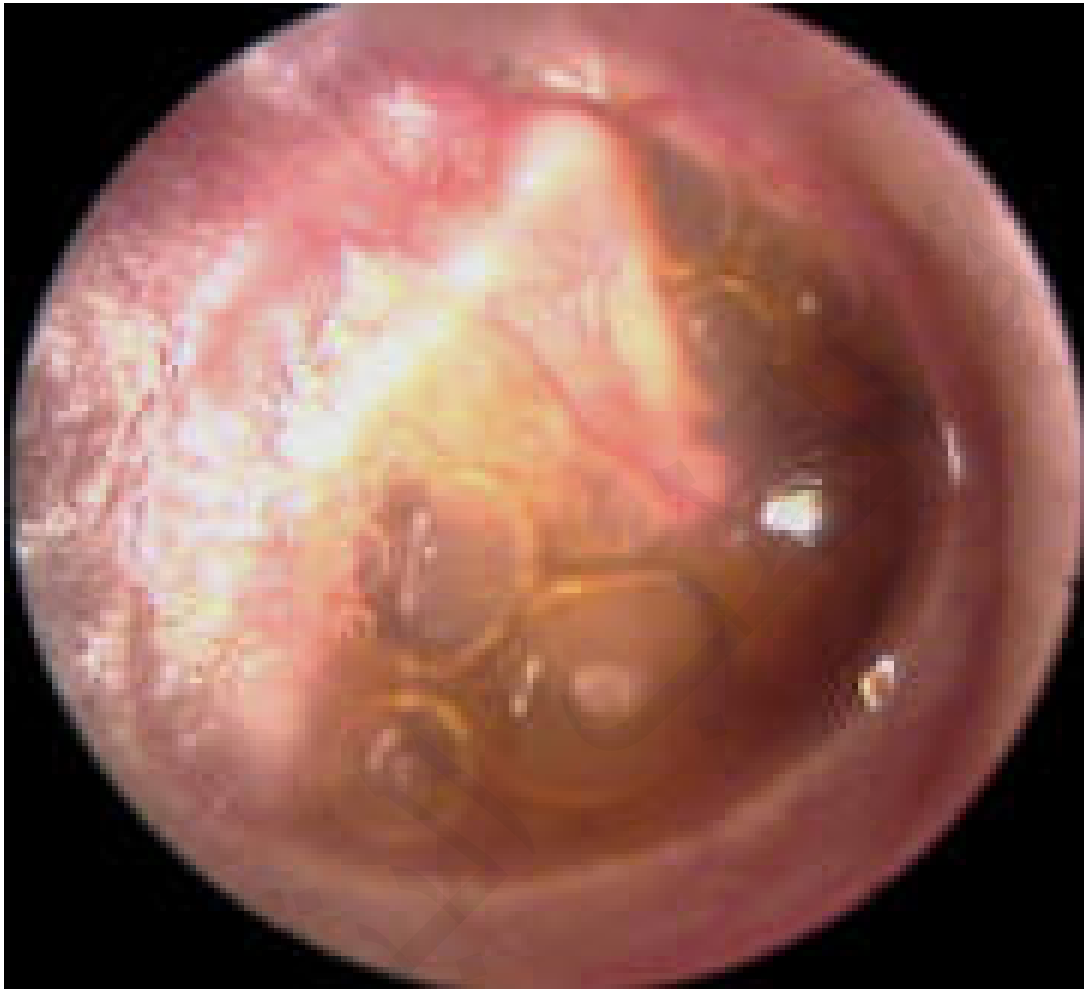This mass moves with protruding tongue

1) What is your diagnosis ?

2) Mention 2 differential diagnoses?

1)Thyroglossal cyst

2)goiter,dermoid cyst, lipoma



History of ear fullness and decrease in hearing for 5 months

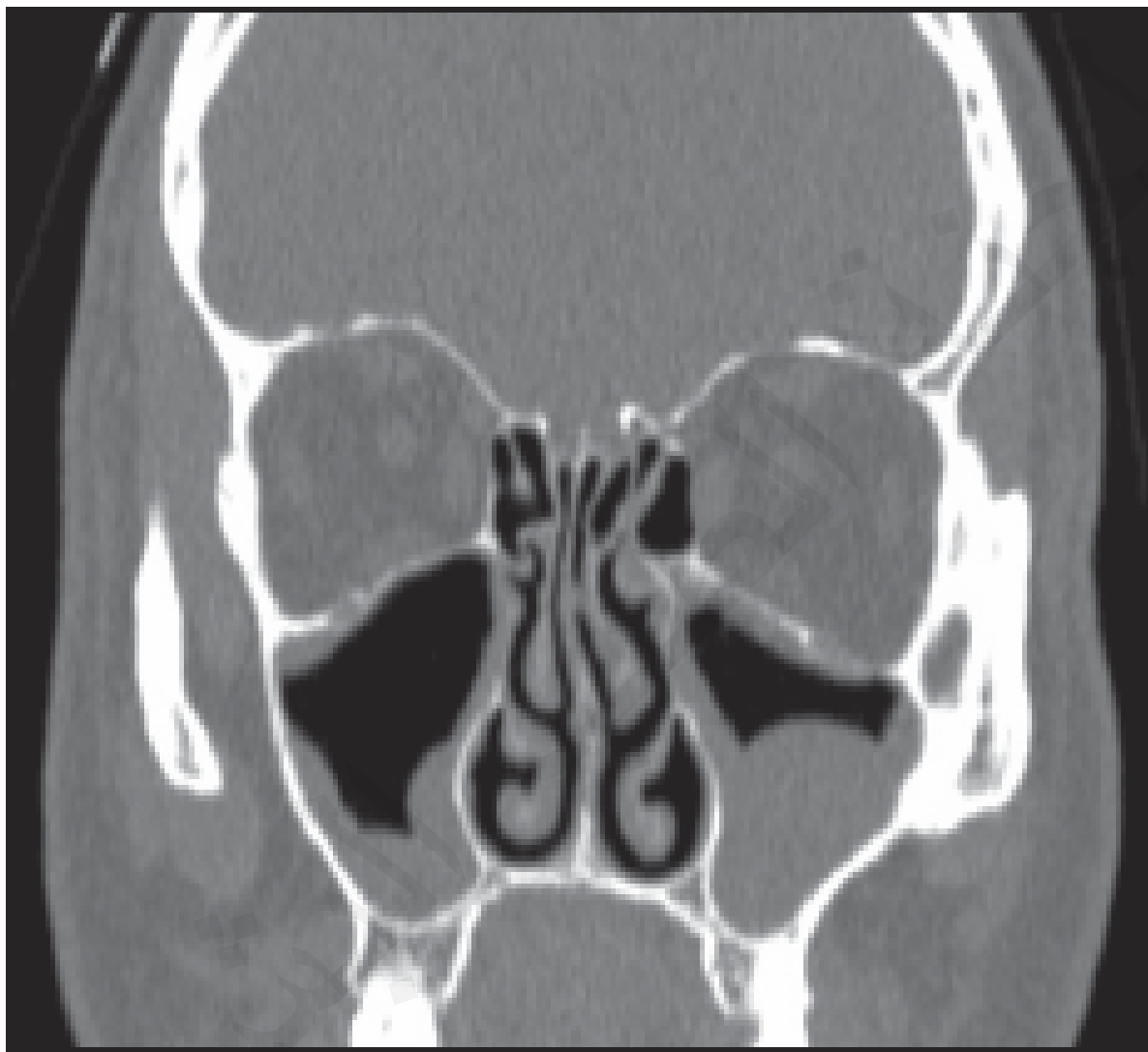
1) What is your diagnosis ?

2) What is the treatment ?



1) OME

2) Myringotomy with ventilation  
tube



History of facial pain and runny nose

1) What is your diagnosis?

2) Mention 2 possible complications?

3) mention 2 common microorganism causing this?

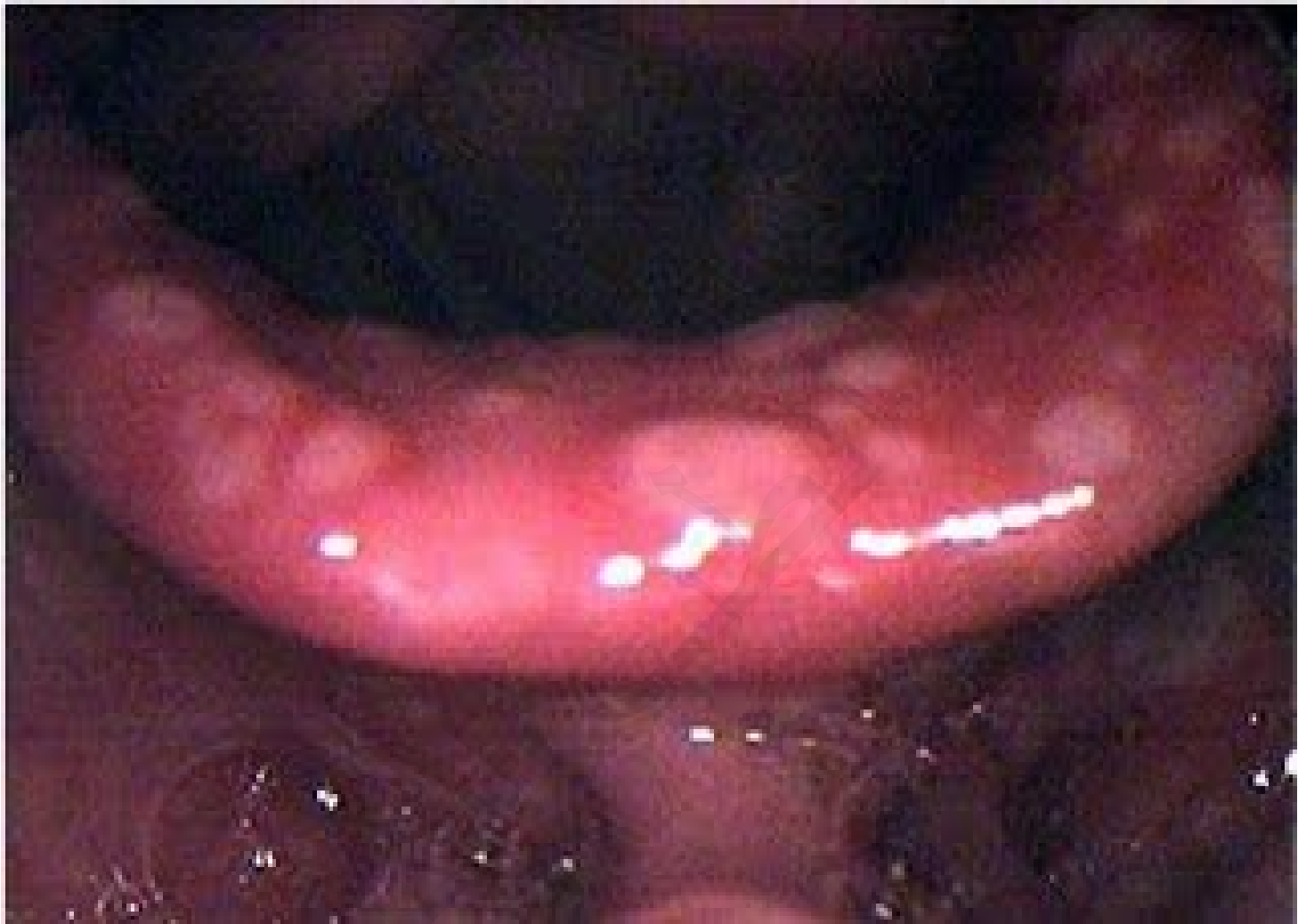- 1) Sinusitis or rhinosinusitis
- 2) Meningitis, subdural/ epidural/ brain-abscess, cavernous sinus thrombosis, etc.
- 3) S. pneumonia, H.influenza, etc.



1) What is this instrument?

2) Mention 2 hearing tests done by it ?

- 1) Tunning fork
- 2) rennei's test, webber's test



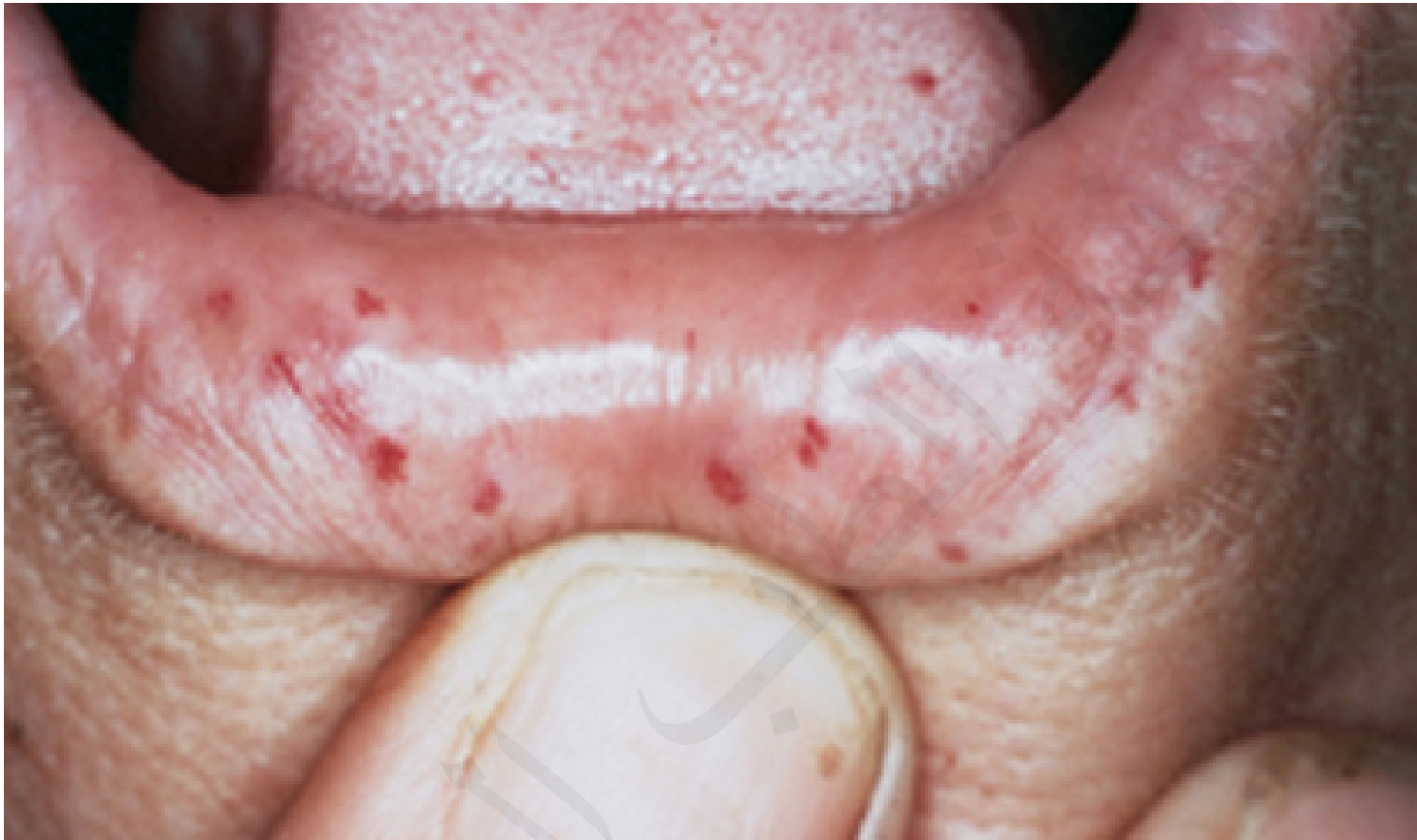A 7 year old child presented to the ER with stridor and toxic appearance and fever with difficulty in breathing



1) What is the diagnosis ?

2) What is the most common cause  
for it ?

- 1) Acute epiglottitis
- 2) H. influenza type B



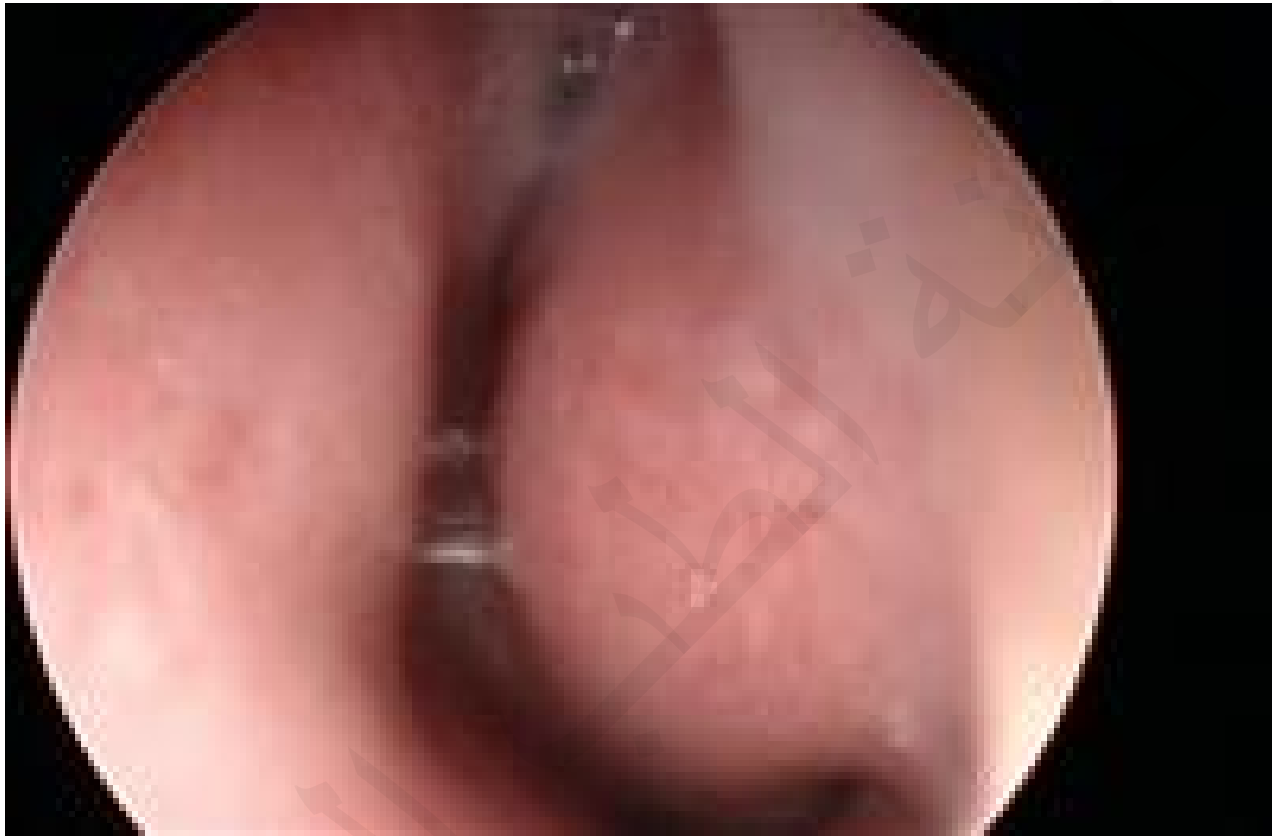© Elsevier 2004. Habib: Clinical Dermatology 4E - [www.clinderm.com](http://www.clinderm.com)

A 40 year old male presented with multiple small red spots on his cheeks and lips and tongue with epistaxis, he has 2 brothers and 3 sisters, 2 of them had the same disease

1) What is your diagnosis?

2) Mention 3 risk factors for epistaxis?

- 1) Hereditary telangiectasia
- 2) HTN, hemophilia, trauma, etc.



A 10 year old male having this pic with runny nose and sneezing that is increased every summer

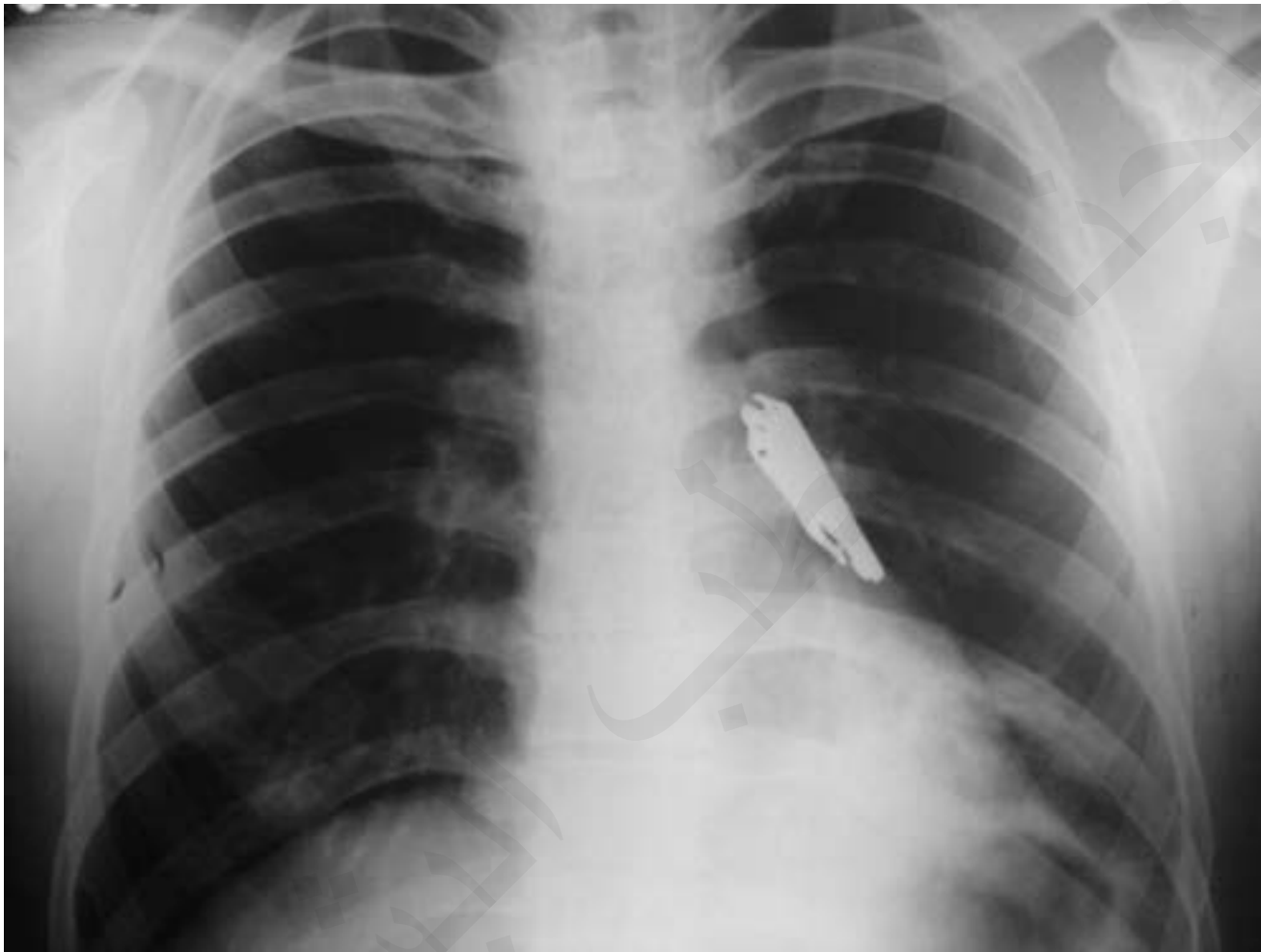1) What is your diagnosis?

2) Mention 2 possible complications?

3) what is the main treatment?

- 1) Allergic rhinitis
- 2) sinusitis, otitis media , etc.
- 3) Avoid the allergen





A child presented with sudden stridor with this CXR

1) What is your diagnosis?

2) What is the main step in treatment?

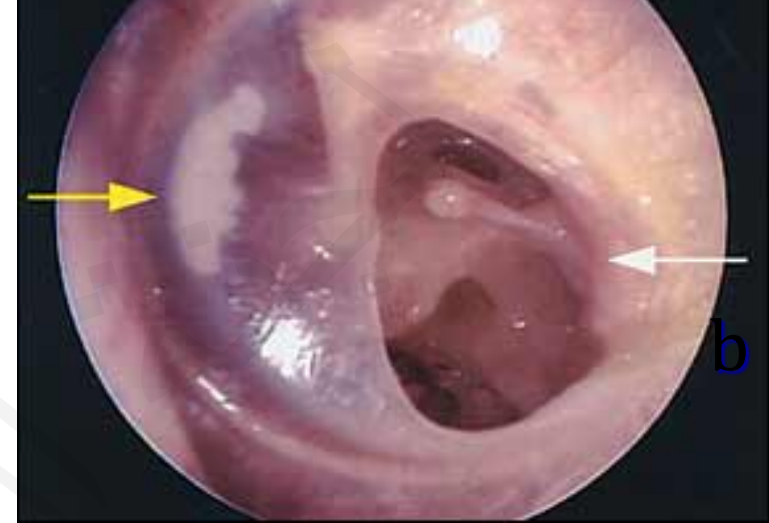
3) mention one possible complication?

- 1) Foreign body aspiration
- 2) bronchoscopy
- 3) asphyxiation, death, etc.

# Question 1

This is the exact same picture we had in the exam

a



What is (a)? (A

What is (b)? (B

What is the treatment of (b)? (C

# Question 1 answers

Tympanosclerosis (A

Tympanic membrane perforation (B

Tympanoplasty (C

## Question 2



What is this instrument? (A  
What is the name of the diagnostic (B  
procedure that is made using this  
instrument?

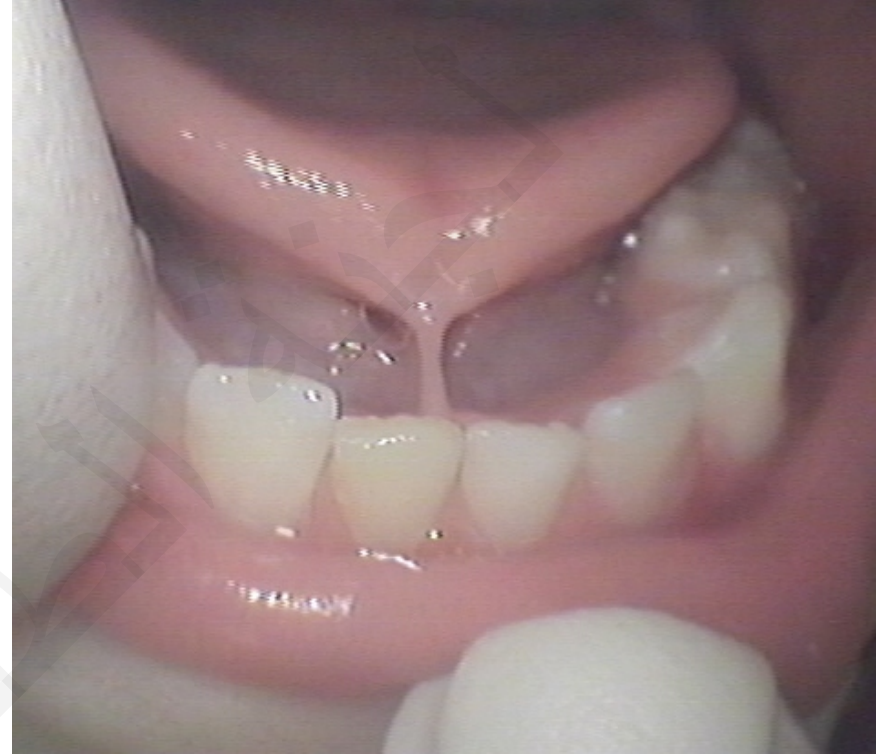# Question 2 answers

Nasal speculum (A

Anterior rhinoscopy (Nasal inspection) (B

# Question 3

This is the exact same picture we had in the exam



What is this condition? (A)  
What is your management? (B)



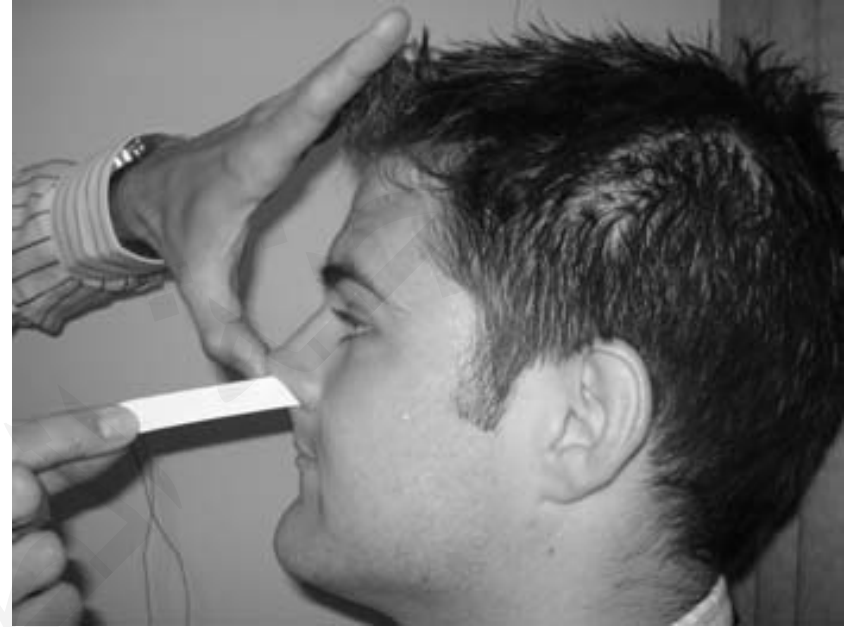# Question 3 answers

Tongue tie (A

Tongue release surgery (B

# Question 4

This is the exact same picture we had in the exam



What is the name of this procedure? (A

Name one indication. (B

Name one complication. (C

## Question 4 answers

Anterior packing (*note the strings hanging from the other end*) (A)

Epistaxis (B)

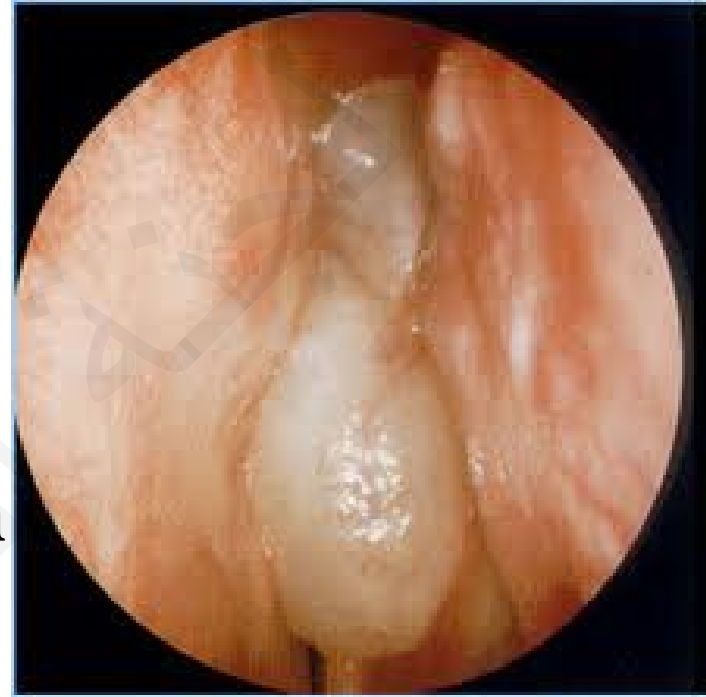Infection / Nasal septum perforation. (C)

## Question 5

History of a young male with runny nose and nasal congestion, and frequent nasal infections.

What is your diagnosis? (A

What is your management? (B

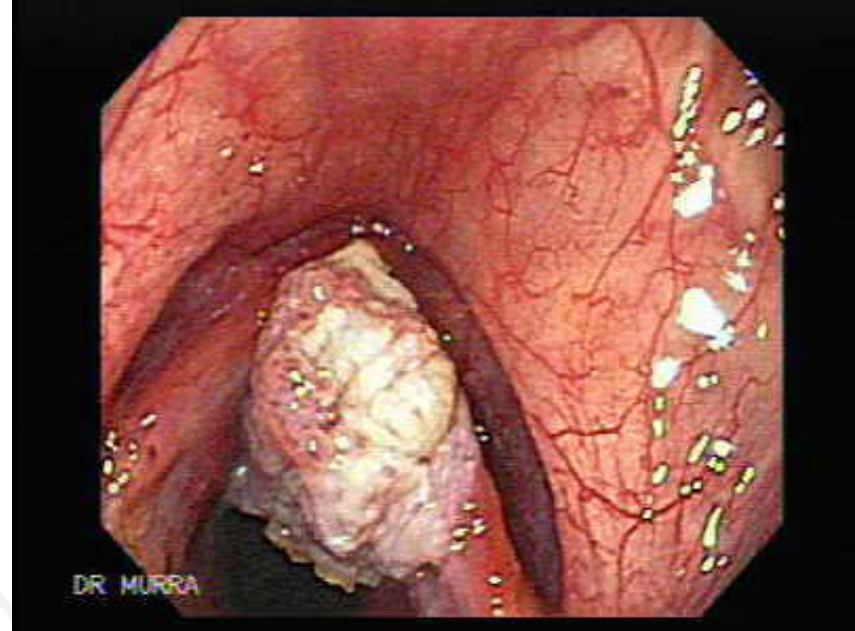


# Question 5 answers

Nasal polyp (A

Surgical excision (B

## Question 6



This is a patient with Laryngeal carcinoma complaining of hoarseness of voice

What is the most common type of (A  
laryngeal cancer?

Give two predisposing factors. (B

Suggest two other complains. (C

# Question 6 answers

Squamous Cell Carcinoma (A

2-

1- Smoking (B

Voice abuse (screaming, singing)

1- Cough (C

2- Stridor

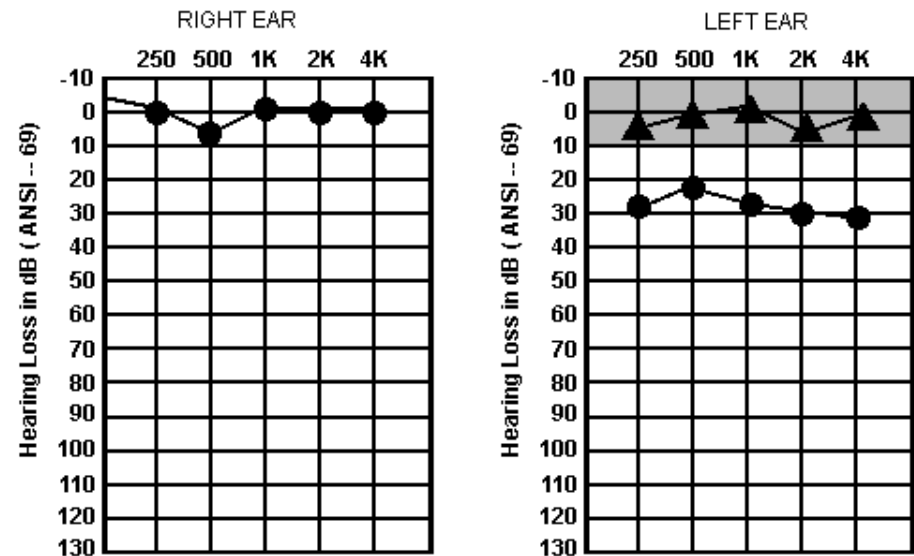
3- Sore throat (feeling of something stuck!)

4- Bad breath

# Question 7

Patient presented with hearing loss in his left ear. His Rinne's test is negative in left ear and this is his audiogram.

A) Mention 4 possible causes of deafness in this patient.





# Question 7 answers

4 causes of conductive deafness:

Earwax block .1

Otitis Externa .2

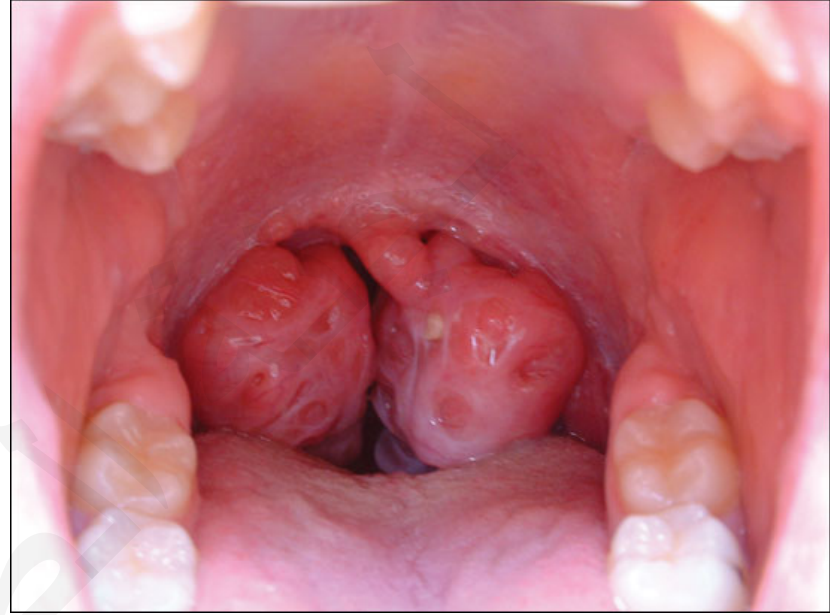
Acute otitis media .3

Congenital atresia of external canal .4

Otosclerosis .5

Tympanic membrane perforation .6

## Question 8



A young boy presented to you complaining of snoring. This picture is seen on examining the child's throat.

- What is your diagnosis? (A)
- What is your management? (B)
- Give 2 indications for your management. (C)

# Question 8 answers

Tonsillar hypertrophy (A

Tonsilectomy (B

1- Recurrent infections (C

2- Sleep apnea

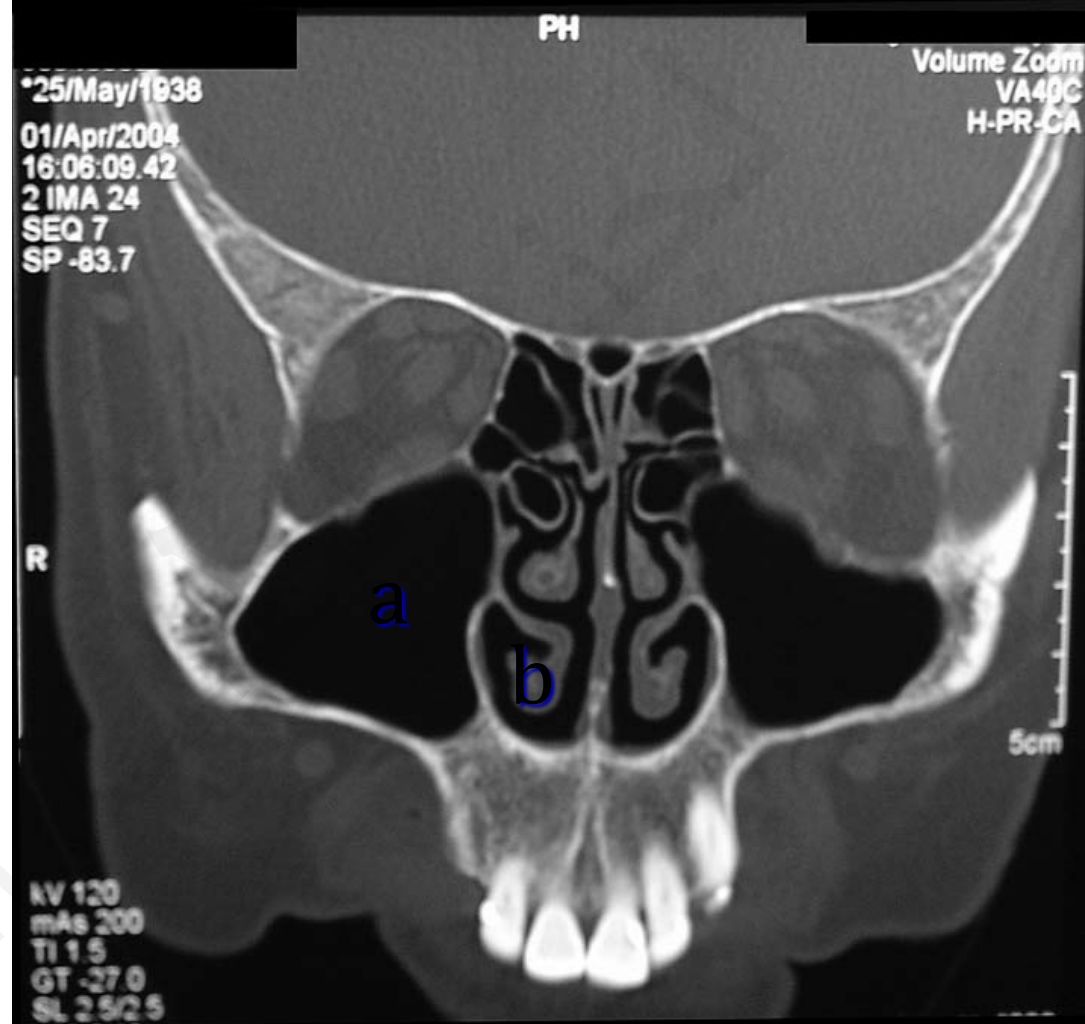
3- Dysphagia

# Question 9

A) What is (a)?

B) What is (b)?

C) Where does the ethmoidal sinus drain?



# Question 9 answers

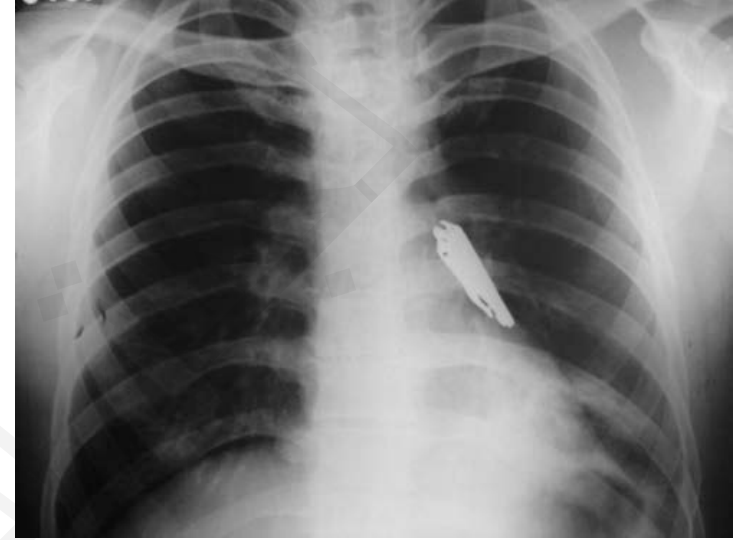Maxillary sinus (A

Inferior turbinate (inferior meatus is also (B  
accepted)

Middle meatus\* (Middle turbinate is not (C  
accepted at all!)

# Question 10

I couldn't find the picture we had!



A child presented with history of choking. We did him this X-ray.

What is your diagnosis? (A

What is your management? (B

Give two complications to this condition. (C

# Question 10 answers

Foreign body aspiration (A

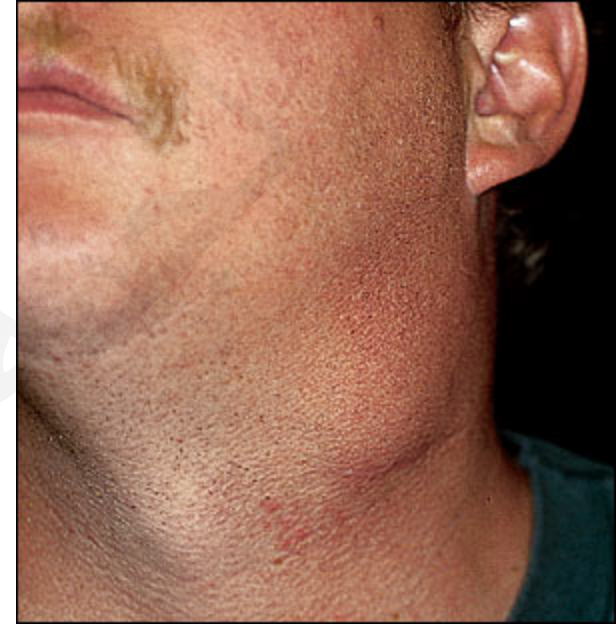Rigid bronchoscopy (B

1- Pneumonia (C

2- Lung collapse

# Question 11

I couldn't find the picture we had!



Patient presented with neck mass, anterior to the Sternocleidomastoid muscle.

Give two differential diagnosis. (A

Give two investigations. (B



# Question 11 answers

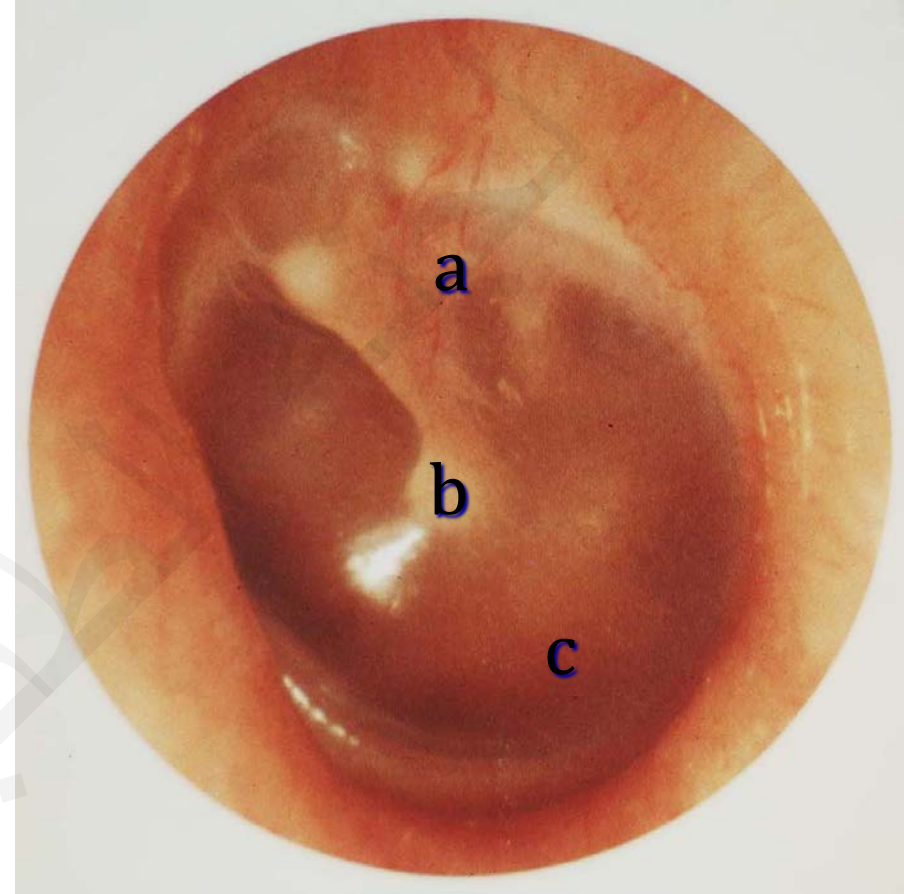
- 1- Lymphadenopathy (lymph node enlargement)
- 2- Dermoid cyst
- 1- CT scan with contrast (B)
- 2- FNA

## Question 12

What is (a)? (A

What is (b)? (B

What is (c)? (C

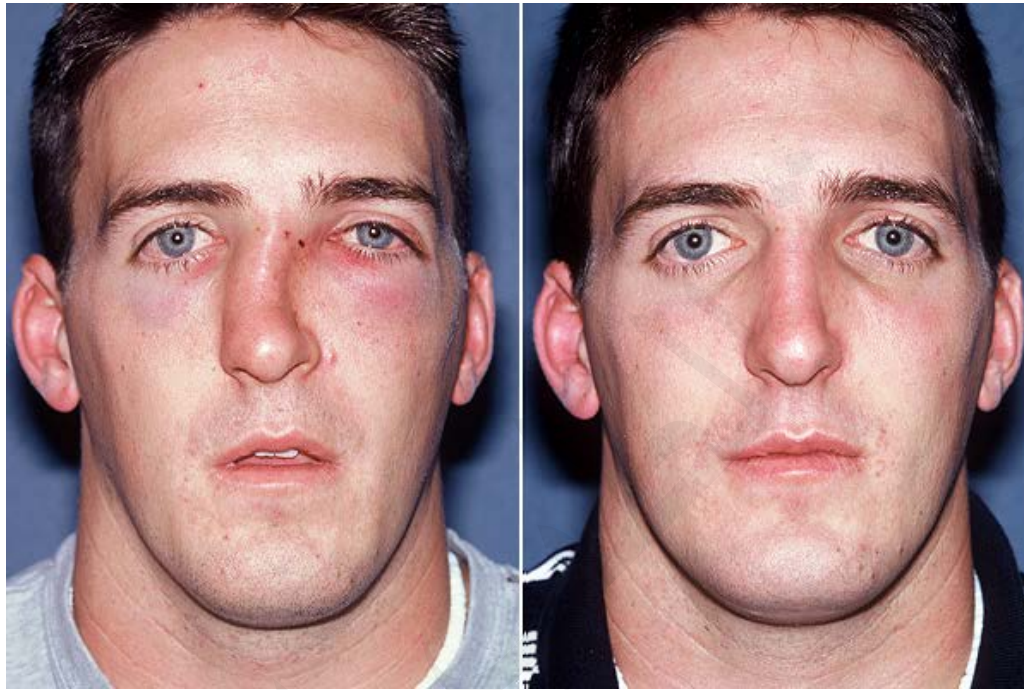


# Question 12 answers

Pars flaccida (A

Handle of Malleus (Umbo) (B

Pars tensa (C

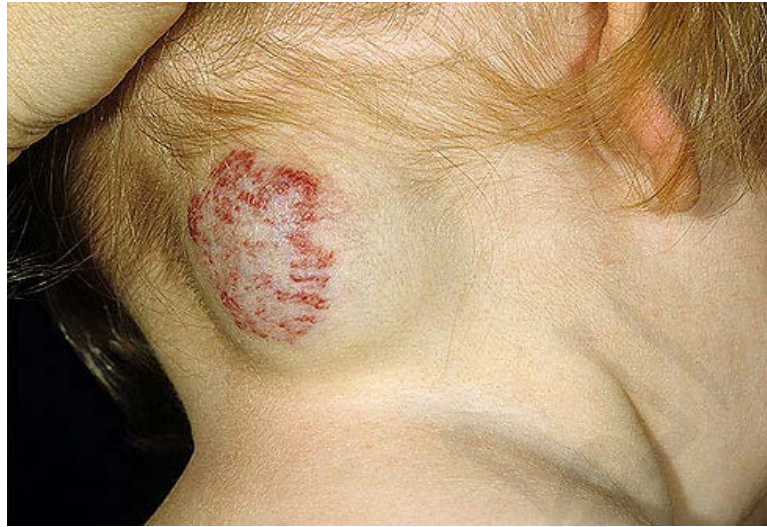

1-What is the abnormality in the left picture?(Nasal bone fracture)

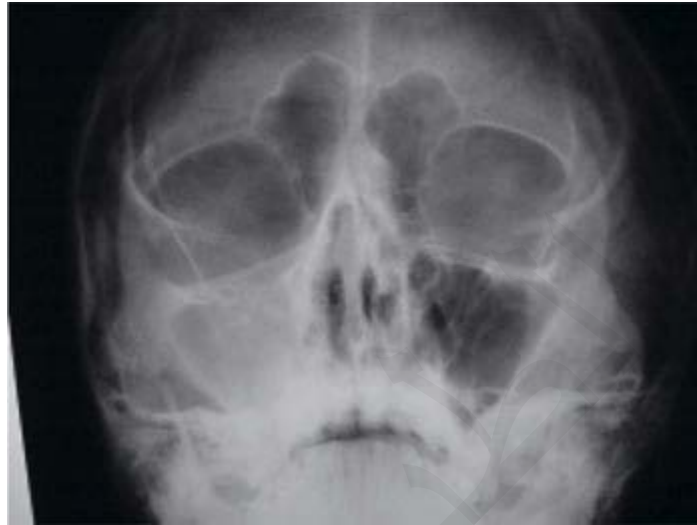2- Mention two complications for this.



- What is your diagnose and which side is affected here?
- Mention two diseases of the ear could lead to this.

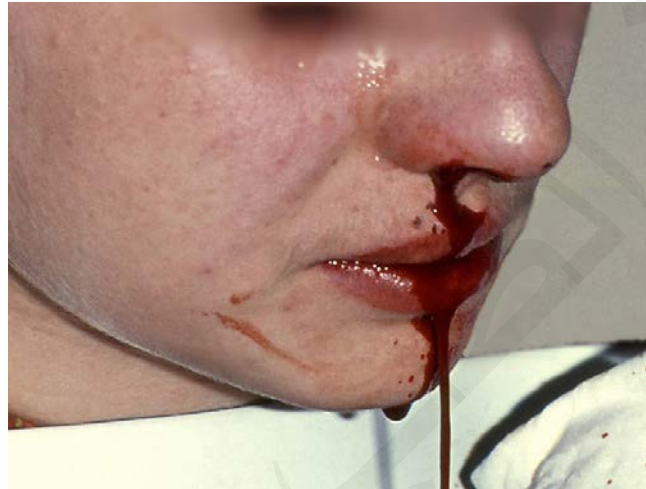

- What is your diagnose? (**Hemangioma**)
- What is the treatment?
- Mention one investigation you will do for this child.



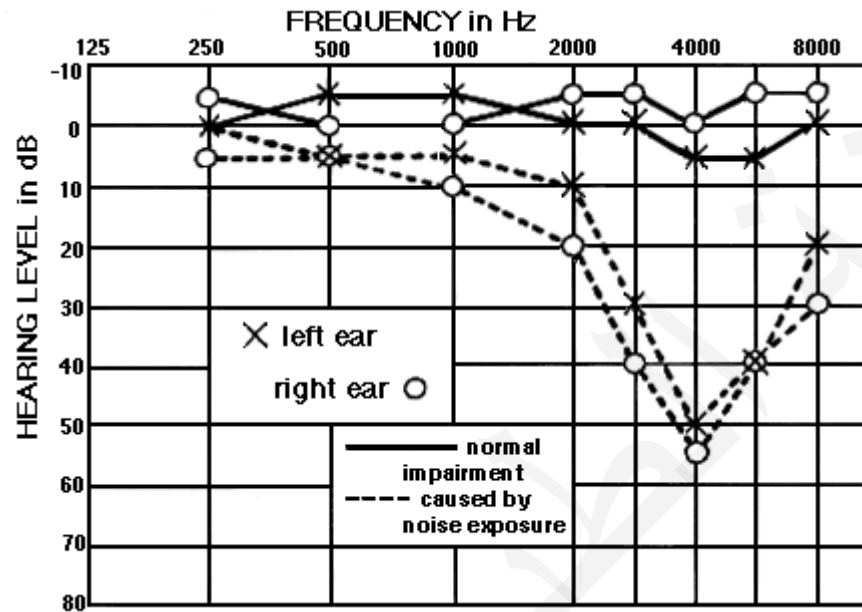
- What is your diagnose?
- How will you treat this patient?

The patient had nasal bleeding for 30 minutes and now she became dizzy, this is not the first time this happens to her.

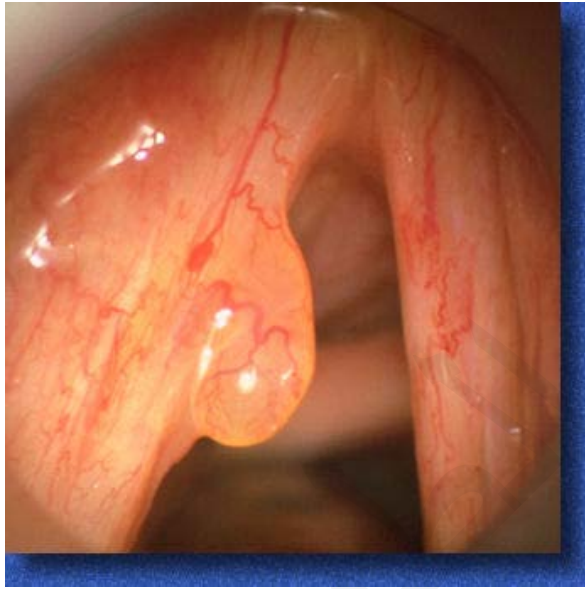


- What is your diagnose?
- Mention two causes.
- How will you treat this patient?



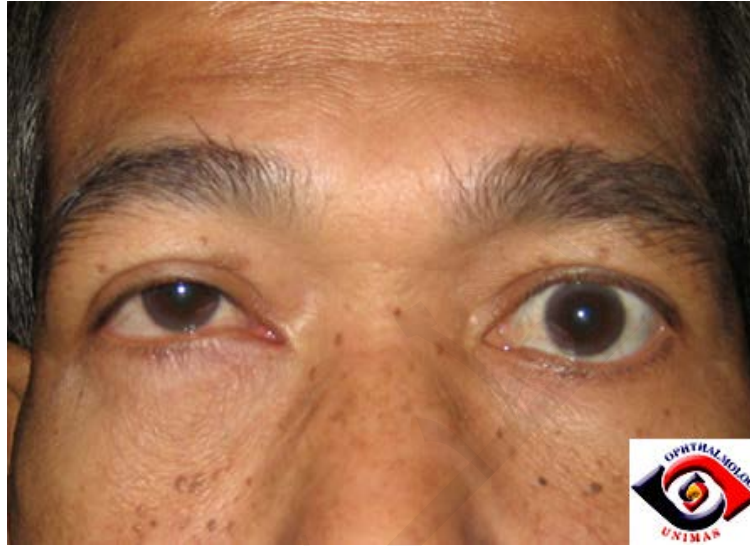


- What is your diagnose? (**Presbycusis**)
- What is the name of this test? (**Audiometry**)
- How will you treat this patient?

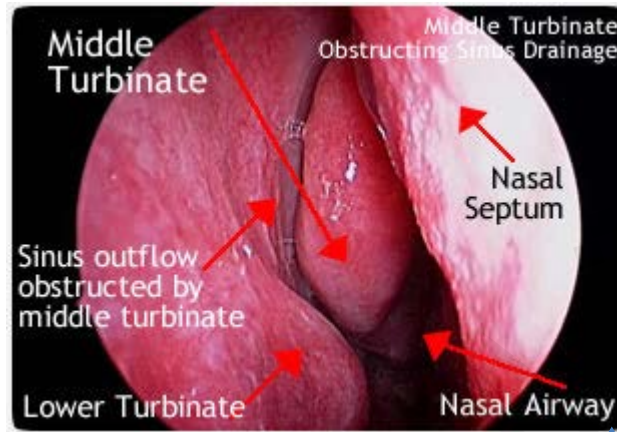


- What is your diagnose?
- How will you treat this patient?

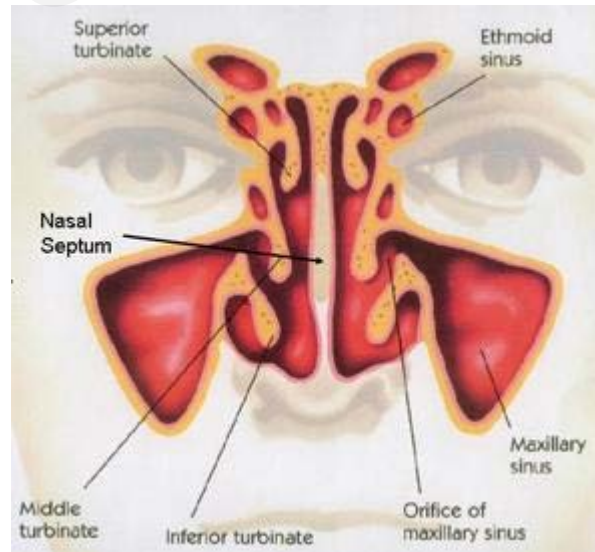
This patient with nasopharyngeal carcinoma

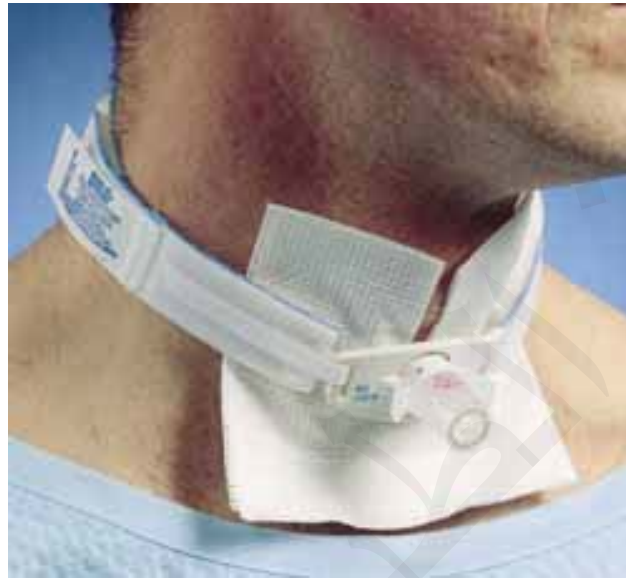

- How will you treat this patient?
- Mention a complication of this tumor.

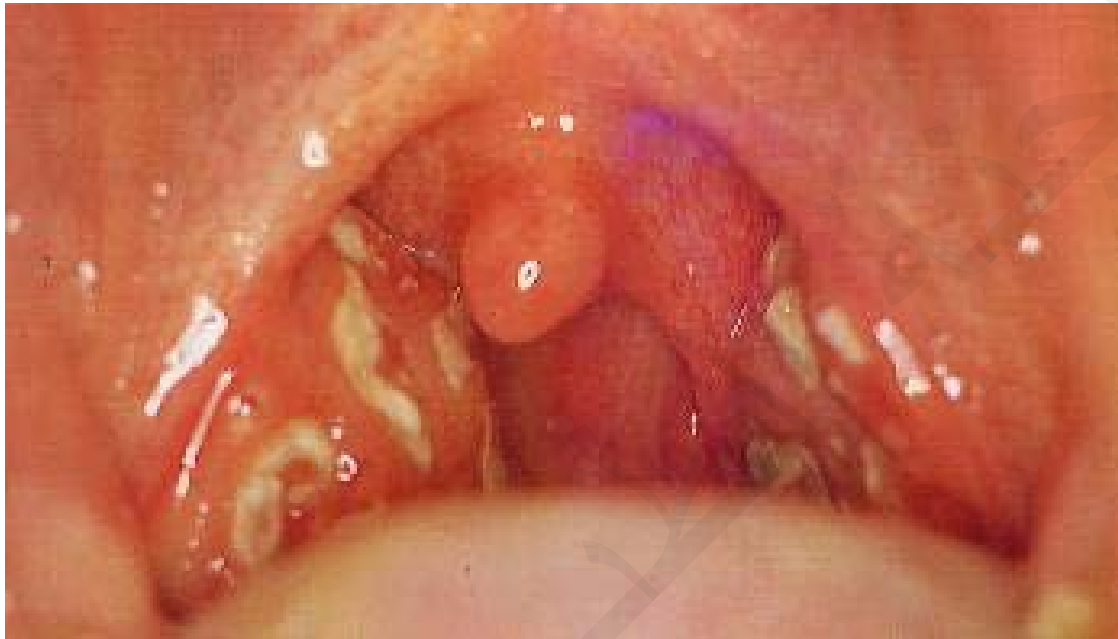

- In the question there was a picture close to this one, they marked the middle turbinate and asked which sinuses drain in? and there was a mark at the nasal septum and they asked what is this part.
- **This is another helpful picture:**





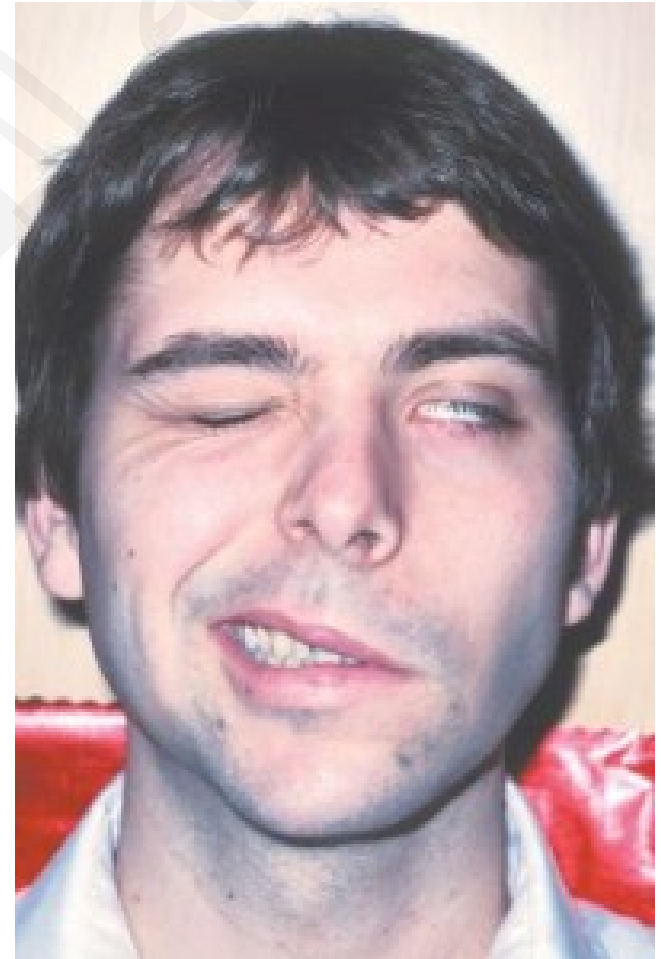- What is this instrument?
- Mention two uses.
- Mention one complication.



- What is your diagnose?
- How will you treat this patient?

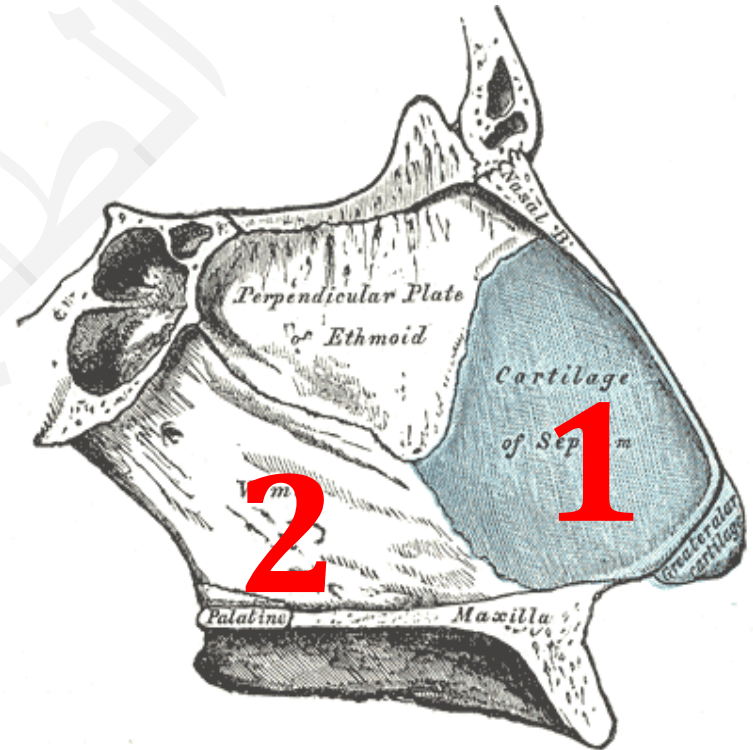
# Question #1

1. what is the diagnosis ? **facial palsy**
2. which side is affected ? **left side**
3. mention 2 complications of this condition ?
  1. **corneal ulceration**
  2. **muscle weakness**



## Question #2

Name each structure in the picture





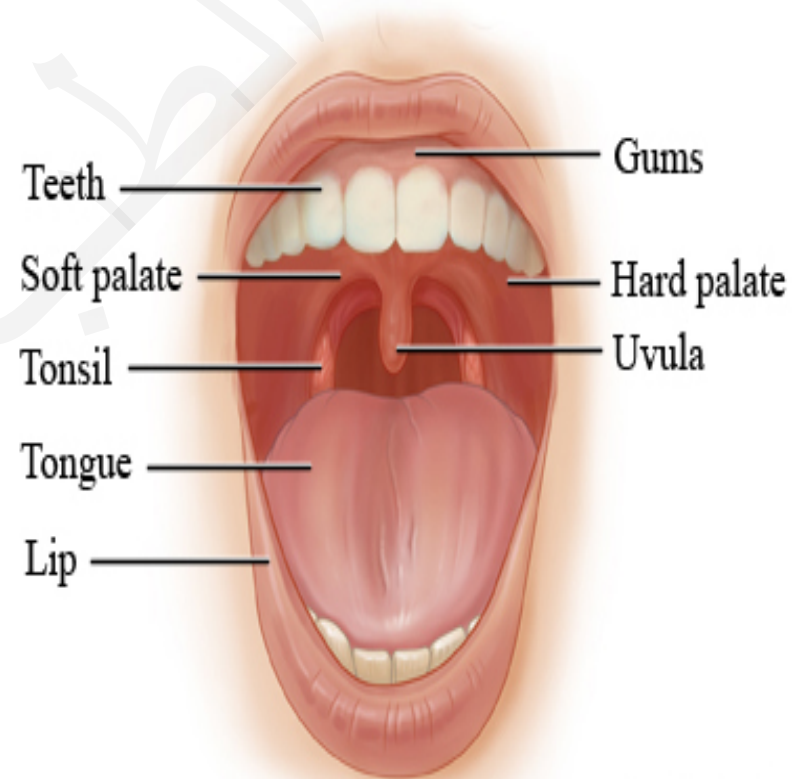
# Question #3

1. what is the name of this tool ? **ear piece or speculum**
2. what is the tool which we use with this tool ? **otoscope**
3. for what is it used ? **Ear examination**



## Question #4

Name the 5 structures seen :



© Healthwise, Incorporated

# Question #5

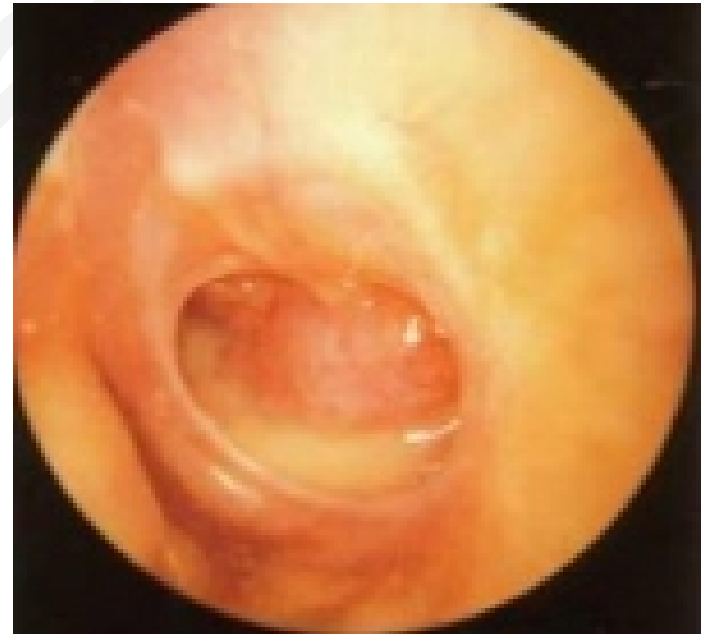1. What is the diagnosis ?

CSOM (chronic suppurative  
otitis media)

2. Mention 1 intracranial and 2  
extracranial complications for this  
condition ??

**Intracranial** : Meningitis,  
brain abscess, lateral sinus  
thrombosis, cerebellar abscess ..

**Extracranial** : Mastoiditis,  
facial nerve palsy, Petrositis ...

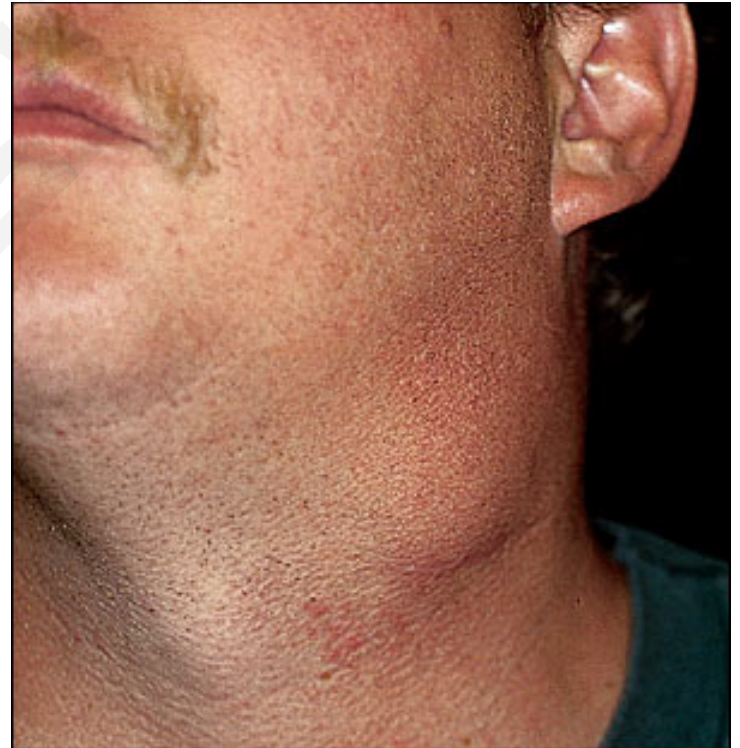

# Question #6

What is your next step ? **FNA** .1

Suppose it is a malignant lymph .2  
node , mention 2 sites u expect to  
find primary  
tumor at ?

**larynx , pharynx ... (anything  
within the neck)**



# Question #7

1. What is the name of this tube ?

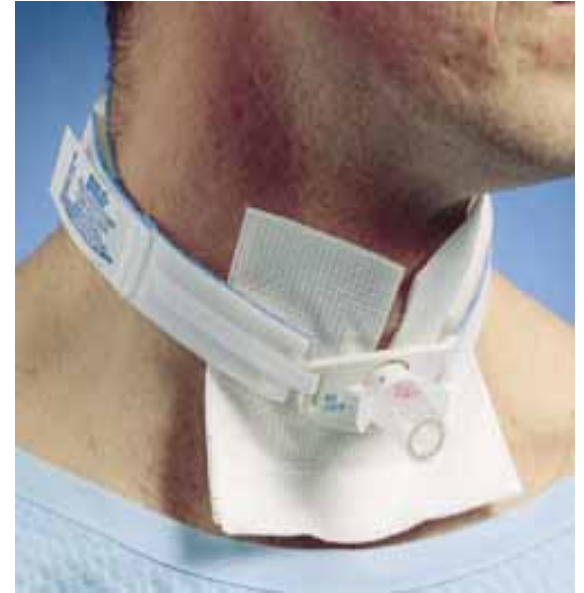tracheostomy tube

2. Mention 3 indications ?

1. upper airways obstruction

2. to protect lower airways  
(bronchial tree) from aspiration in  
comatose patients or patients with  
neural disorders

3. respiratory failure



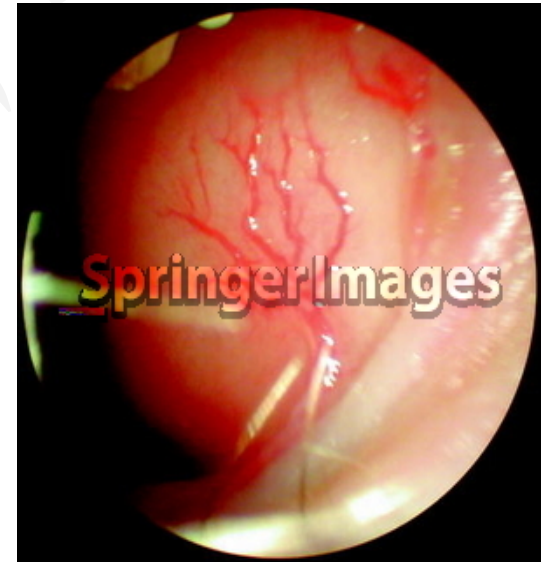
# Question #8

1. The most common site for epistaxis is supplied by these arteries :

1. Anterior Ethmoid artery
2. Greater Palatine artery
3. Sphenopalatine artery
4. Superior Labial artery

2. how would you can treat this patient ?

Chemical cautery with silver nitrate /  
electrical cautery or diathermy



# Question #9

Patient with runny nose, sneezing, pyrexia, fatigue, stomachaches .

1. what is the diagnosis ?

common cold / acute rhinnitis

2. mention 2 complications of this condition ?

Otitis

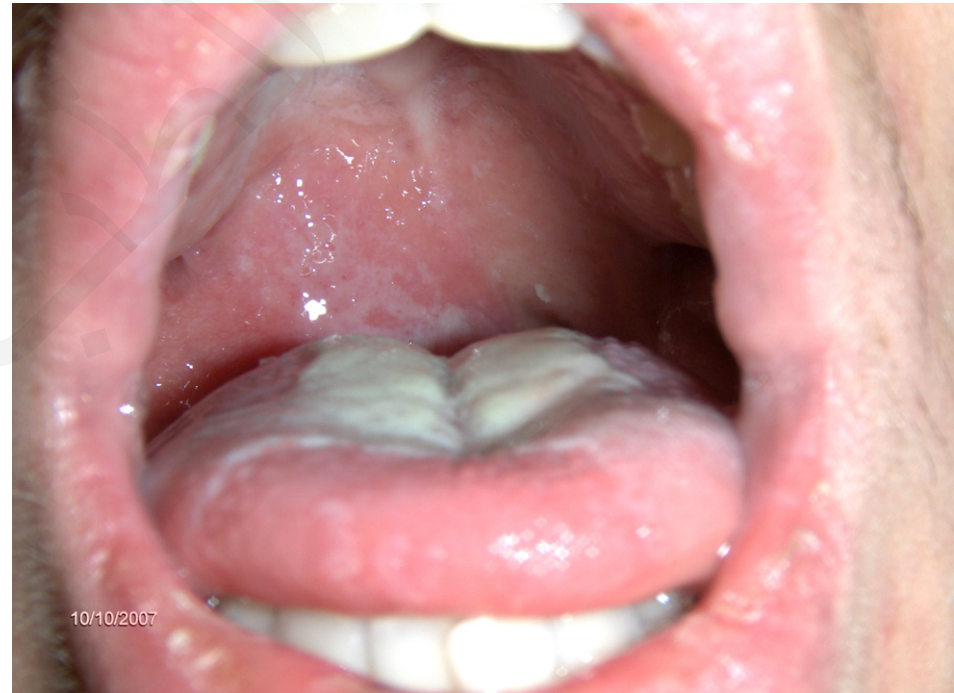tonsillitis ...



# Question #10

Patient with trismus .....

1. what is ur diagnosis ?  
**peritonsillar abscess**
2. mention one cause of this ?  
**tonsillitis**
3. how to treat ?  
**drainage and antibiotics**





# Question #11

Lady in a restaurant, sudden SOB with stridor ...

1. what is ur diagnosis ?

**foreign body aspiration**

2. mention 2 maneuvers / ways to save this patient in the restaurant !?

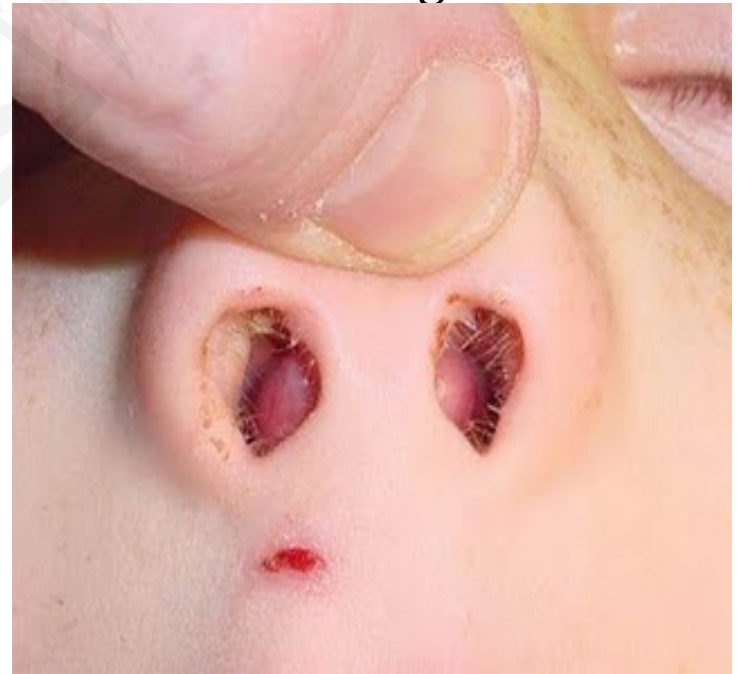**1. hemlich's maneuver**

**2. tracheostomy**

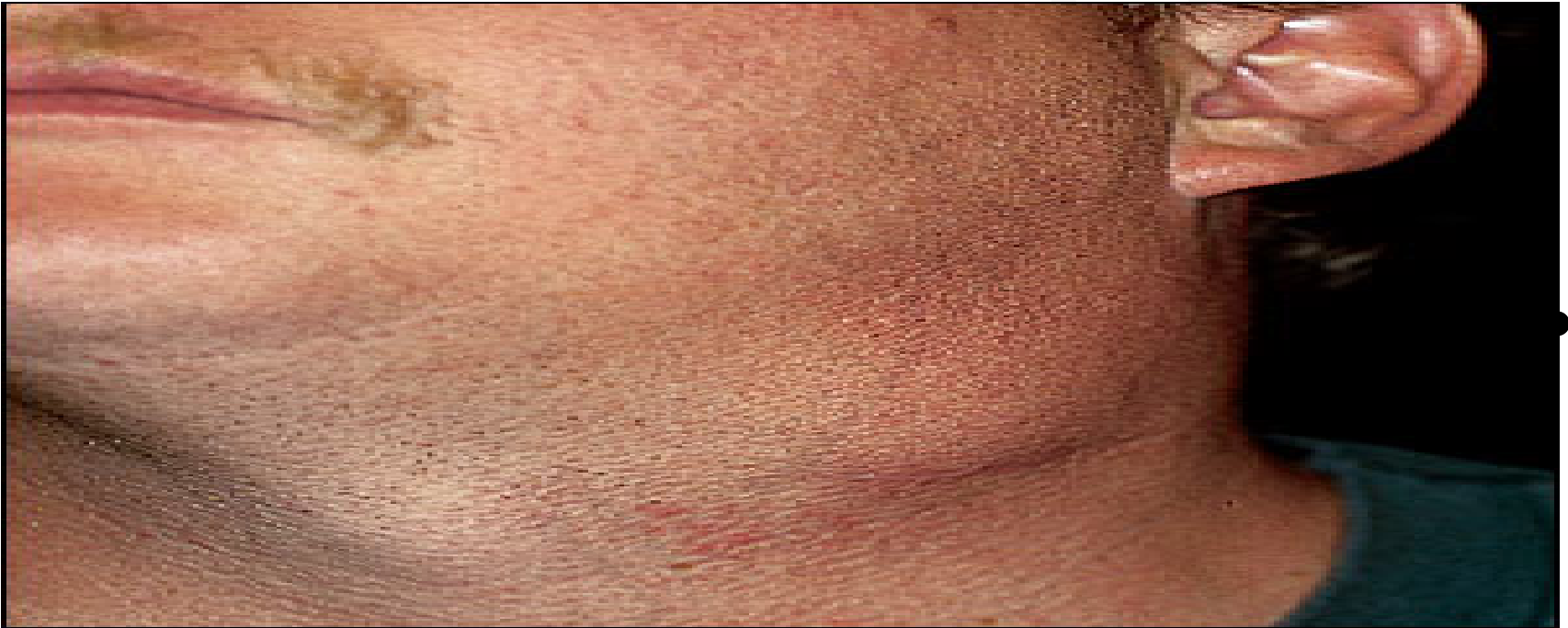

## Question #12

What is the diagnosis ? ●



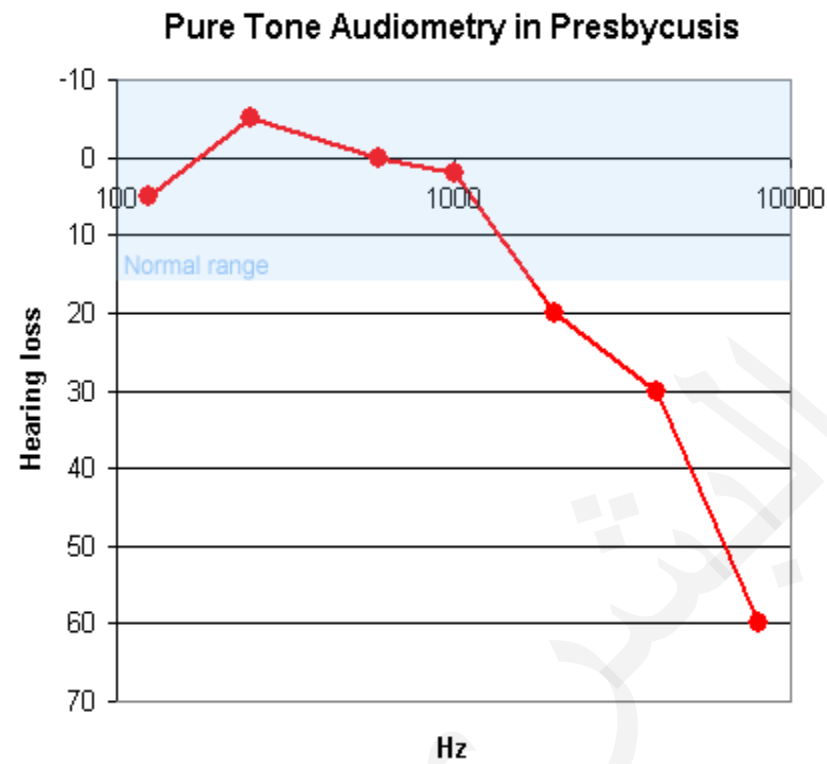
Q1



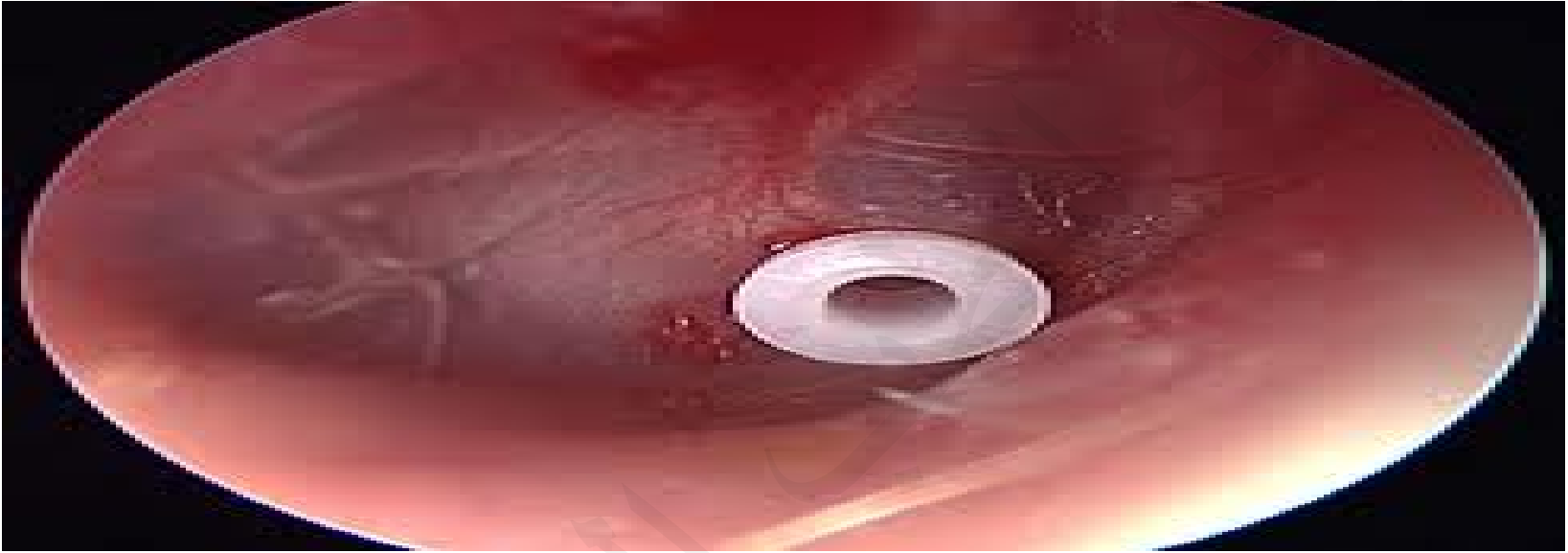
- a+b) mention 2 differentials •
- c) What is the best investigation to start with

Q2) •

- What is the diagnosis?

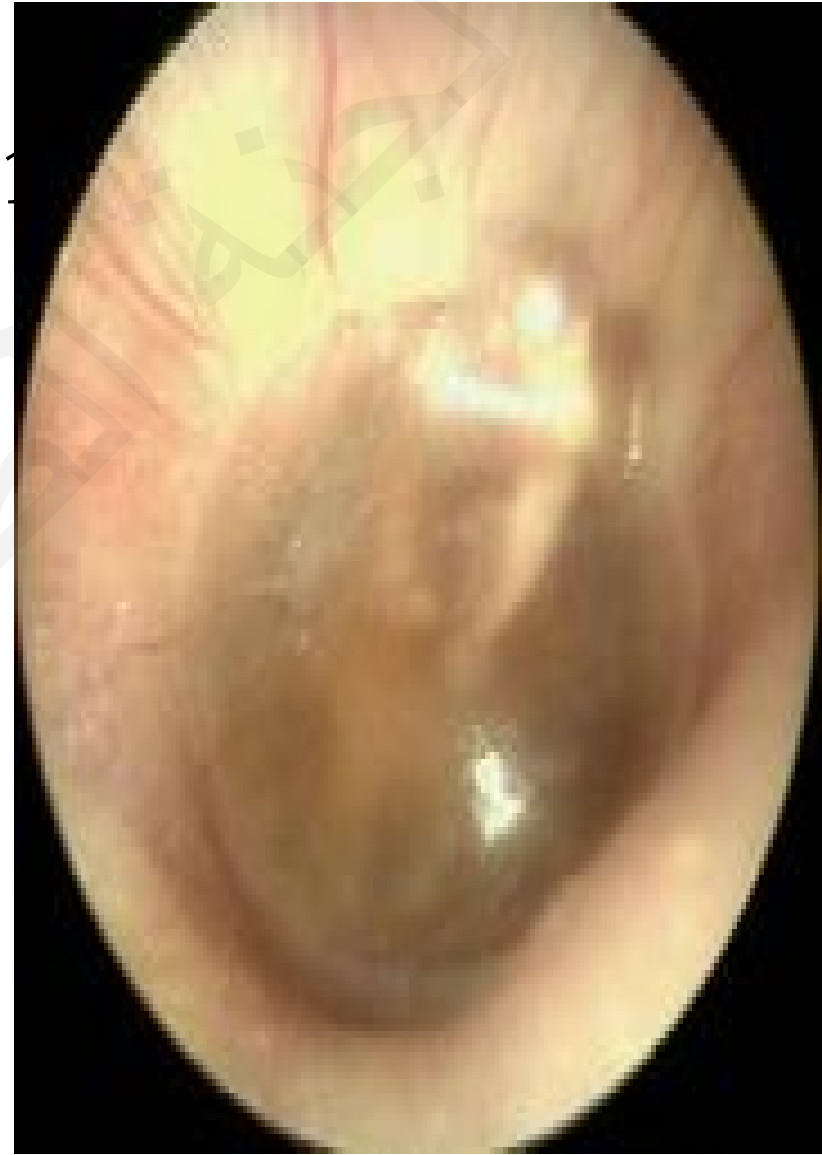

# Q3

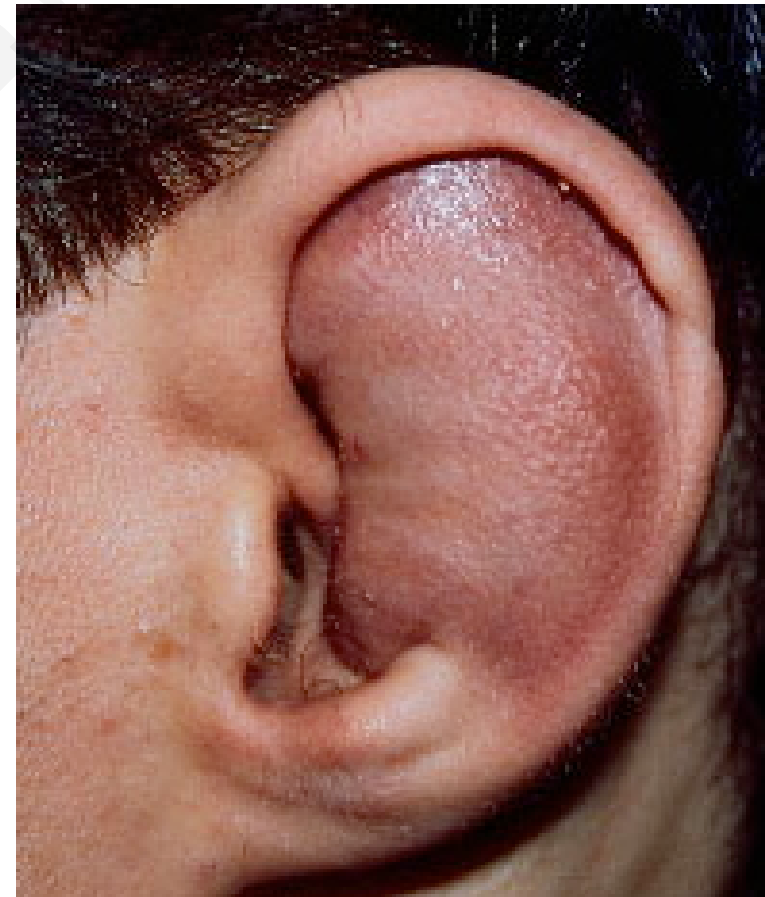

- - What is this device?
  - Mention 1 indication
  - Mention 2 complications

- Q4) A 4 year old child presented with history of hearing loss and fullness of 1 month duration.
  - What is the diagnosis?
  - What is the main line of treatment?
  - Mention 2 predisposing conditions?

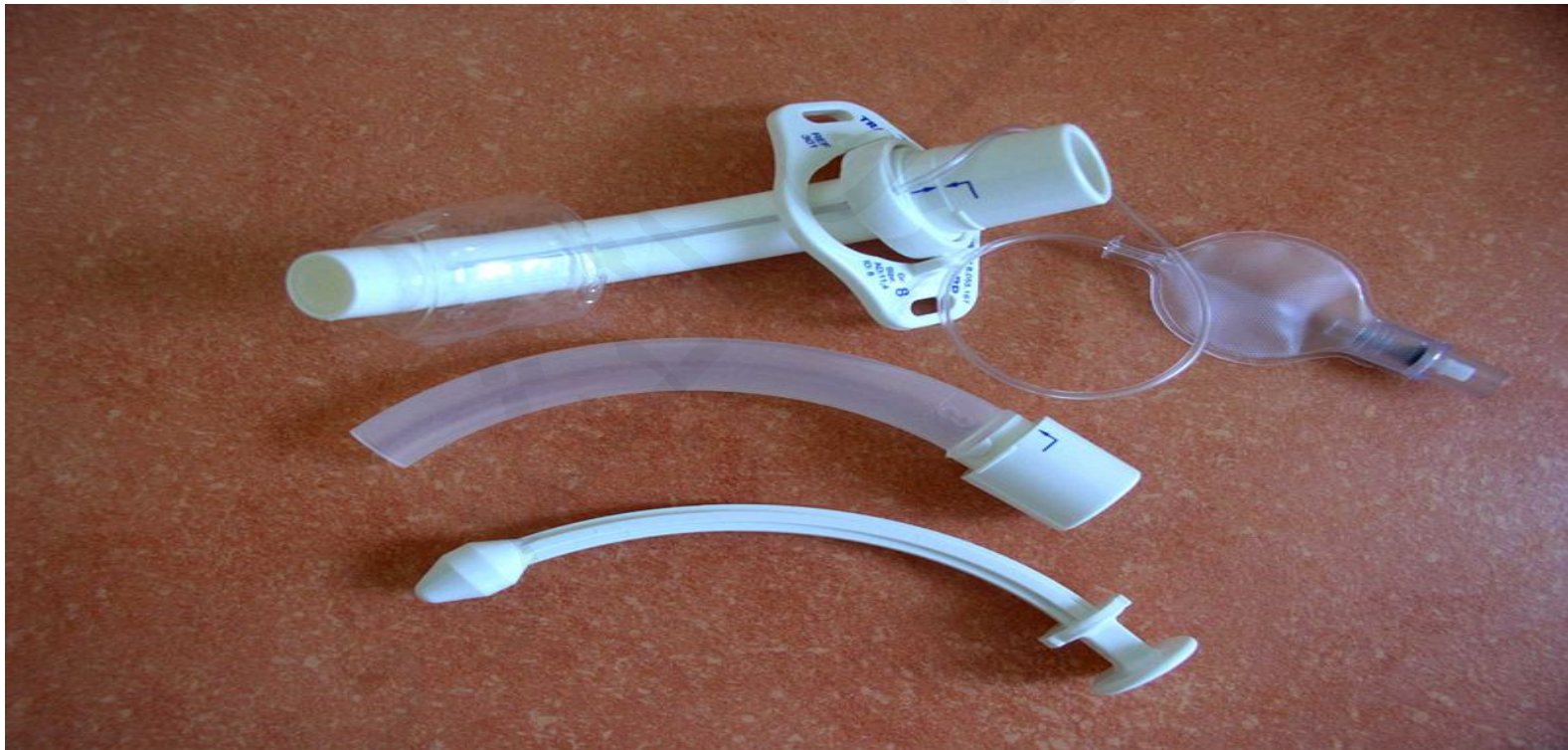

- Q5) A history of patient •  
coming to ER with trauma
- Diagnosis.
  - One Complication.
  - 2 lines of treatment



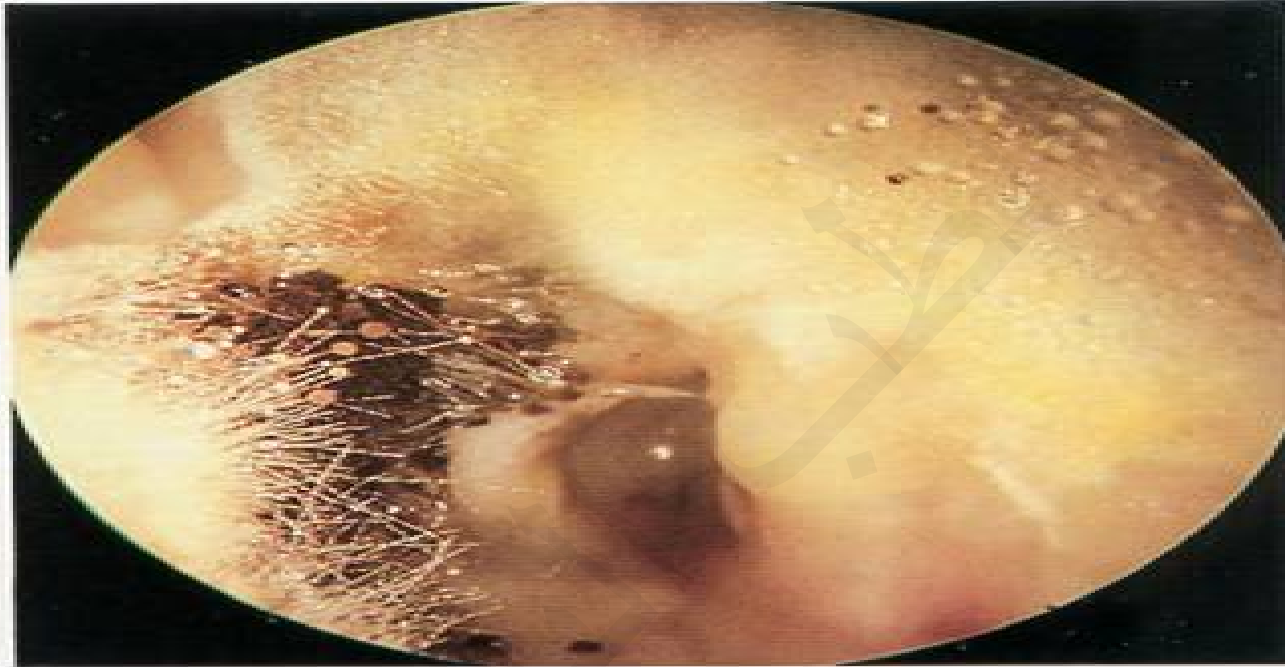
## Q6

- Name this device.
- Mention 2 indications.
- Mention 2 complications.

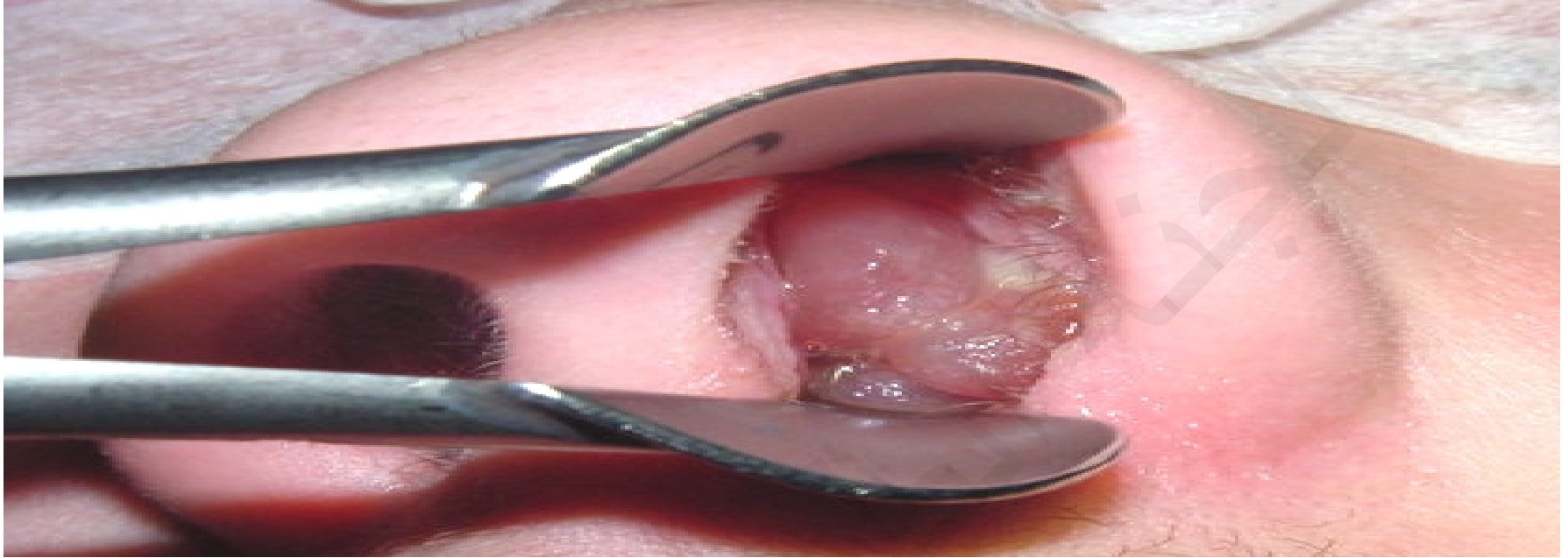




Q7) A patient with a history of pruritis...



- 
- Diagnosis •
- Mention 2 lines of treatment

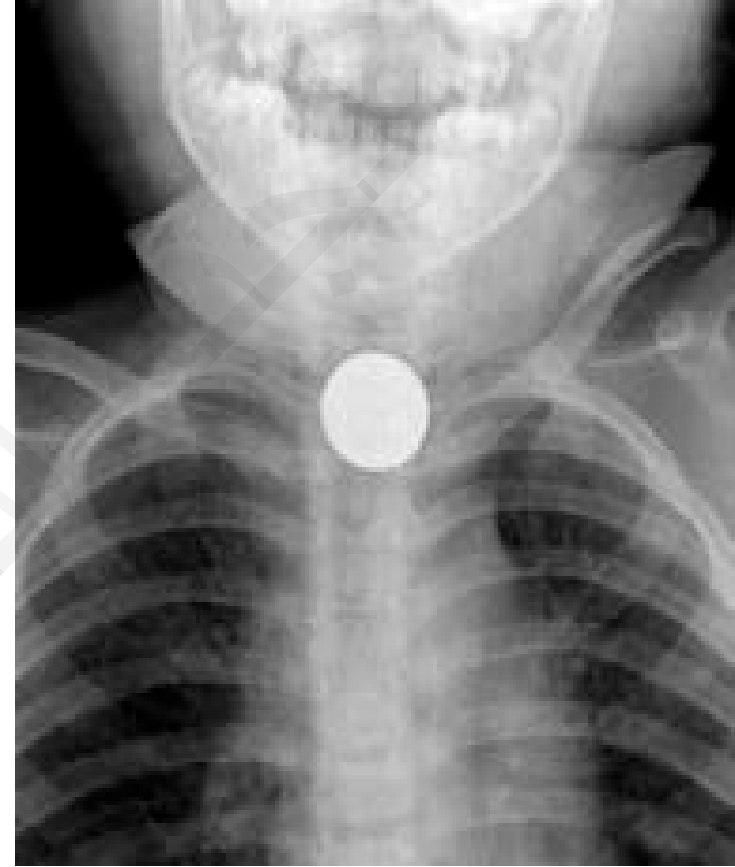

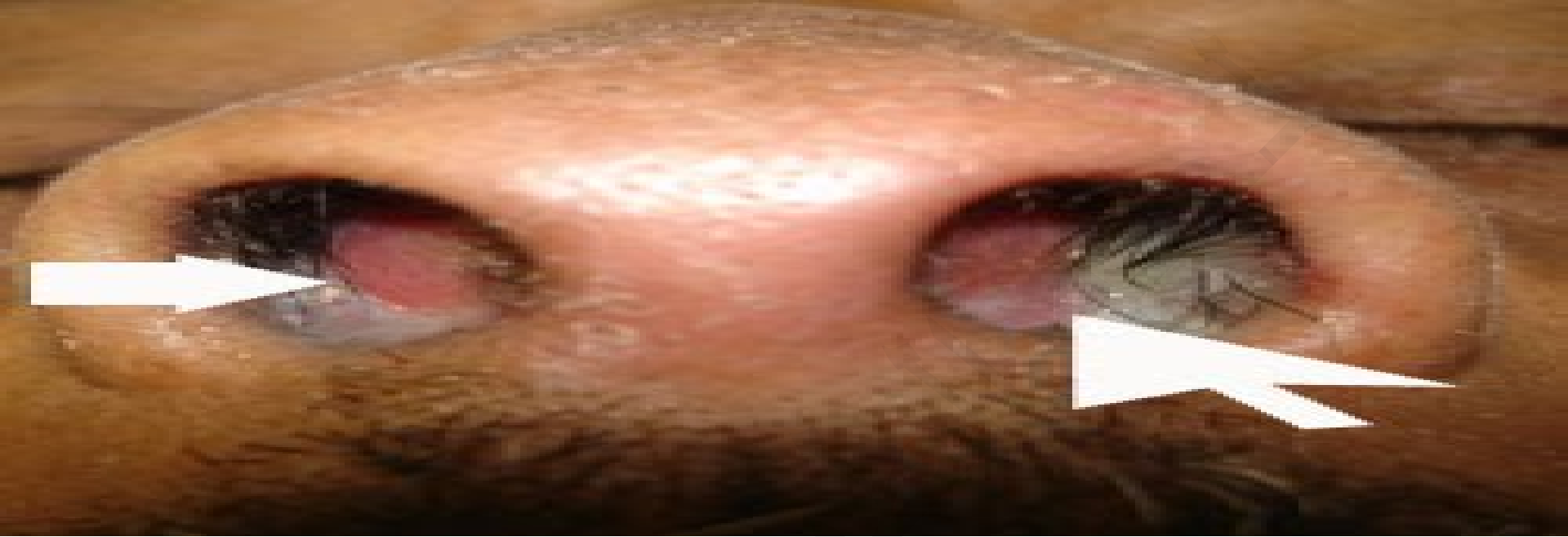- Q8) History of patient with nasal •  
obstruction and rhinorrhea.
- Diagnosis.
  - What is the mainstay of the treatment.
  - Mention 2 complications.
  - If this condition was associated with aspirin sensitivity and asthma. Name this syndrome?

Q9) Mention 3 EBV diseases related to ENT •

Q10) A history of a child •  
presented with choking and  
dysphagia.

- Where is the impaction
- What is the treatment?
- What is the most common  
site of foreign body  
entrapment in esophagus?



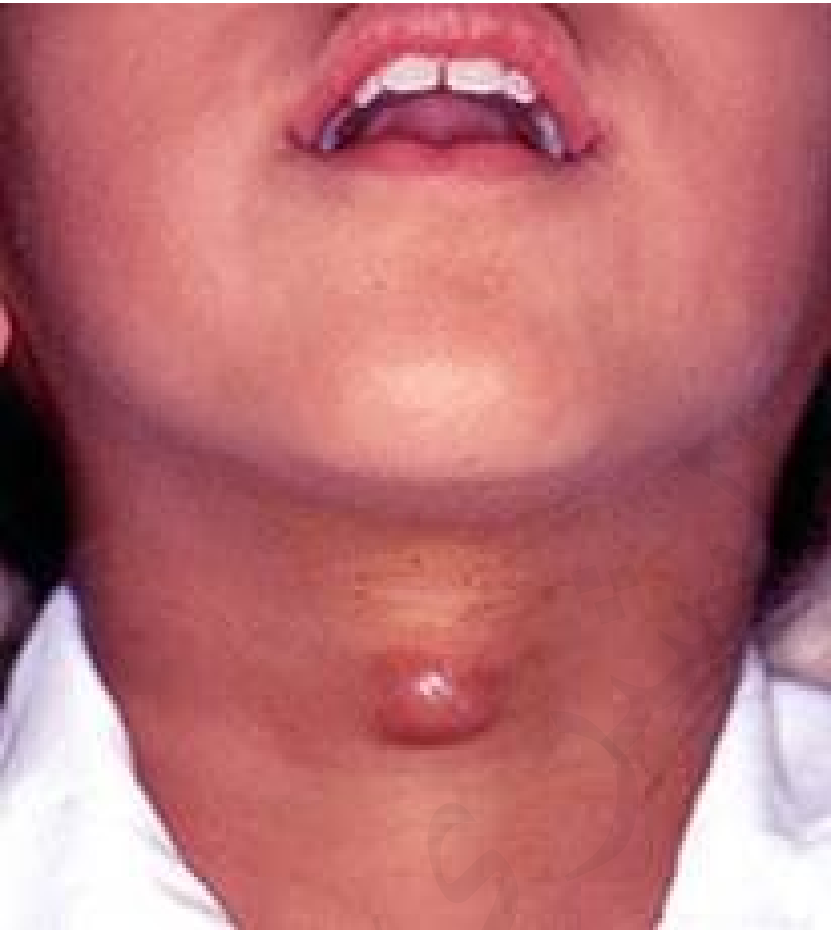

- Q11) A patient presented with bilateral •  
nasal obstruction after a surgery of  
septoplasty
- What is the diagnosis?
  - What is the treatment?
  - Mention one complication

Q12) •

- What is this instrument?
- Mention 2 tests to be done with it





Mention 3 differential •

Diagnosis?

What is your next •

Investigation?

1.thyroglossal cyst •

2.dermaoid cyst •

3.goiter •

Ultrasound •



History of fever, trismus ,uvular deviation •  
.....

What is your diagnosis? •

How to confirm your diagnosis? •

What is your treatment? •

- Peritonisillar abscess
- Throat swab and culture (??!!)
- IV antibiotics + incision and drainage  
(under general anesthesia in children and  
anxious Pts)

History suggestive of adenoid hypertrophy •

What is your diagnosis? •

Mention 2 complications? •

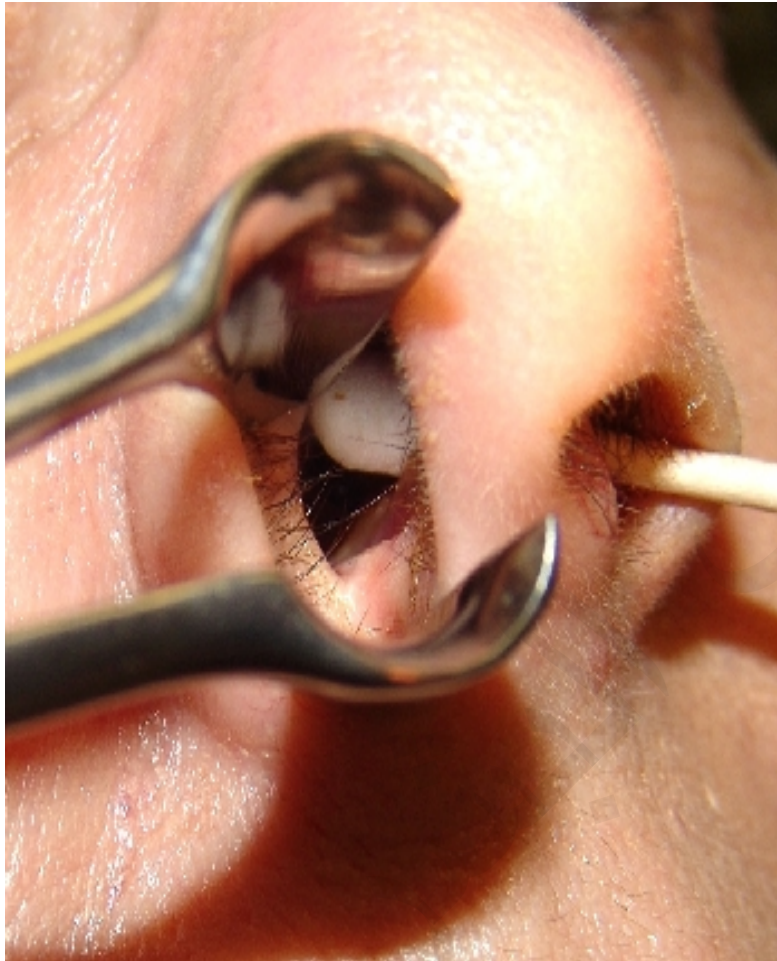What is your treatment? •

History of patient with 10 years Hx of ear •  
discharge , atic perforation ,.....

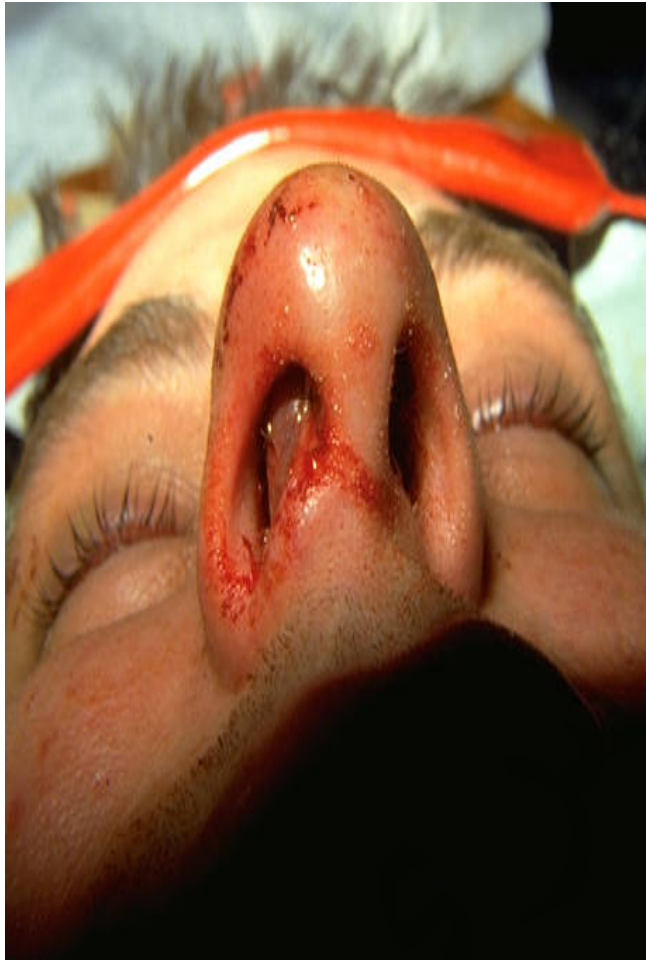What is your diagnosis ? •

Mention 2 complications? •

What is your treatment? •



What is your •  
diagnosis ? •



Patient presented •  
with this after nose  
surgery ...(septal Hematoma )

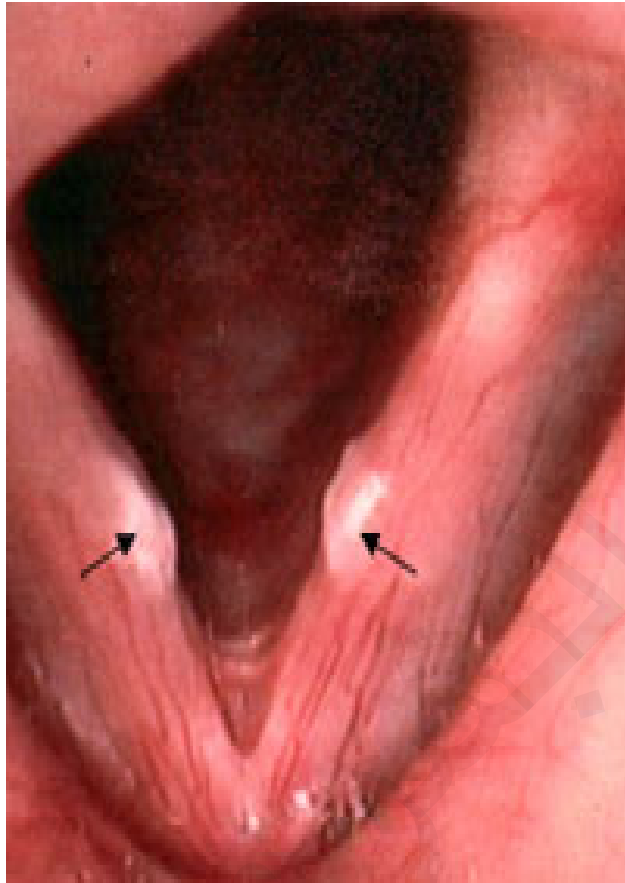
What is your diagnosis?

Mention 1 other

Cause?

Mention 1 complication?

What is the treatment ?

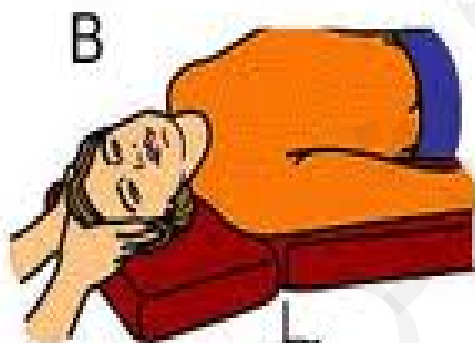
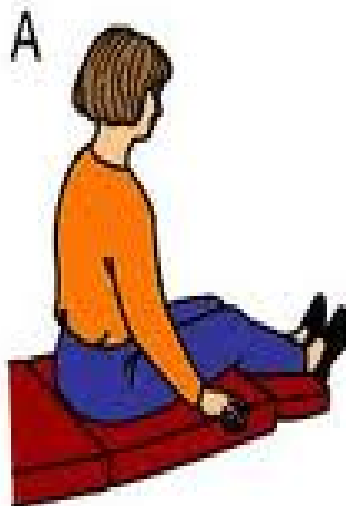

This for a singer female •  
patient ....

What is ur diagnosis ?

Mention 2 risk factors?

What is your treatment?

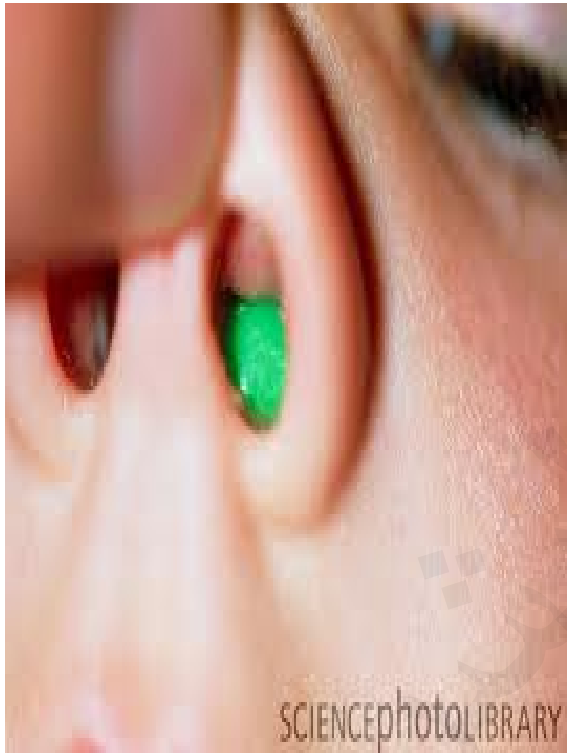

Hx suggestive of BPPV..... •

What is your diagnosis ? •

What is name of this test? •

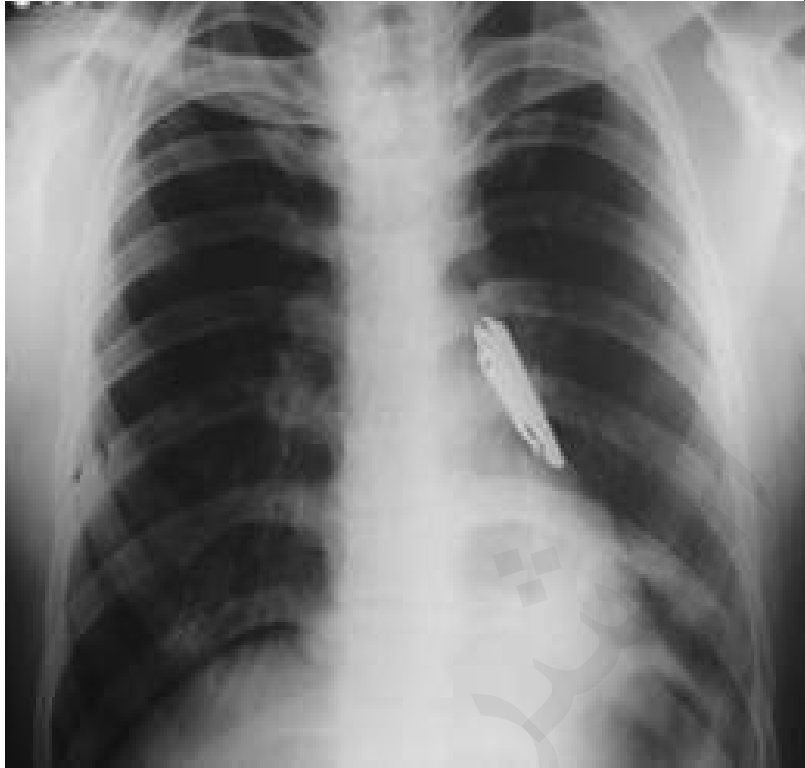



Child with Hx of unilateral •  
Nasal discharge ....

What is your diagnosis ? •

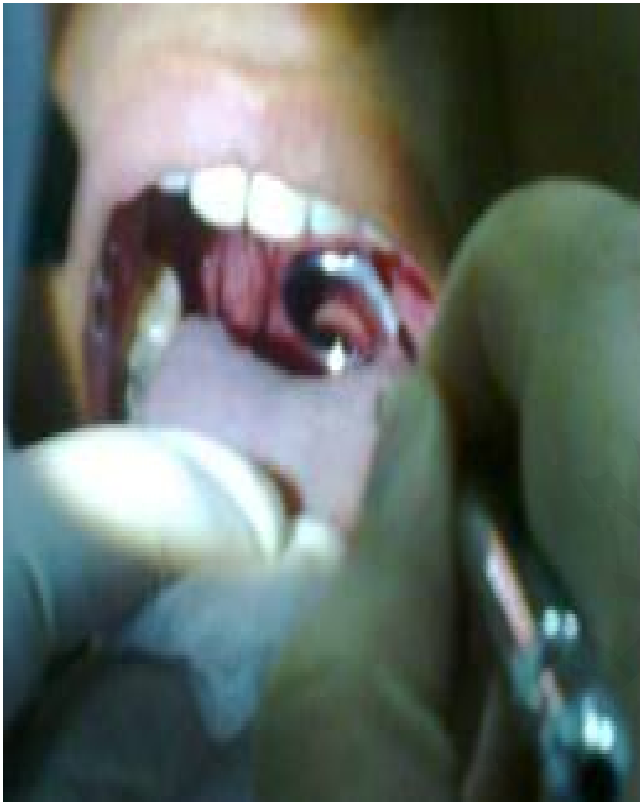How to treat ? •



What is your diagnosis? •

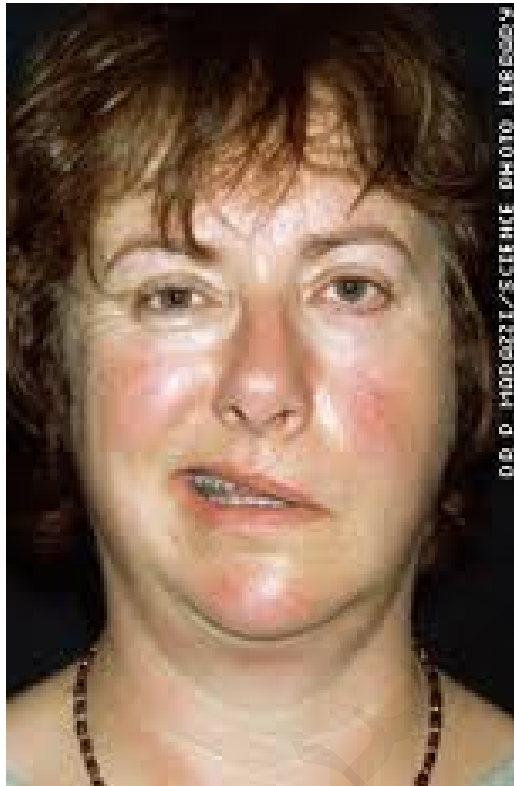What will you do for  
this patient? •

Foreign Body Aspirations •  
Rigid Bronchoscopy •




What is the site you •  
See using this method ?  
(indirect laryngoscope )


Mention Other method to •  
Use ? Direct laryngoscope



- What is ur diagnosis?  
(mentioning the side is IMP  
/left in this Pic )
- Mention 3 ENT causes ?



**Pulse Batch**



# ENT mini-OSCE

## Group C3&C4

# Question 1

**A patient presented with headache and nasal discharge for a week**

**1-What is your Dx?**

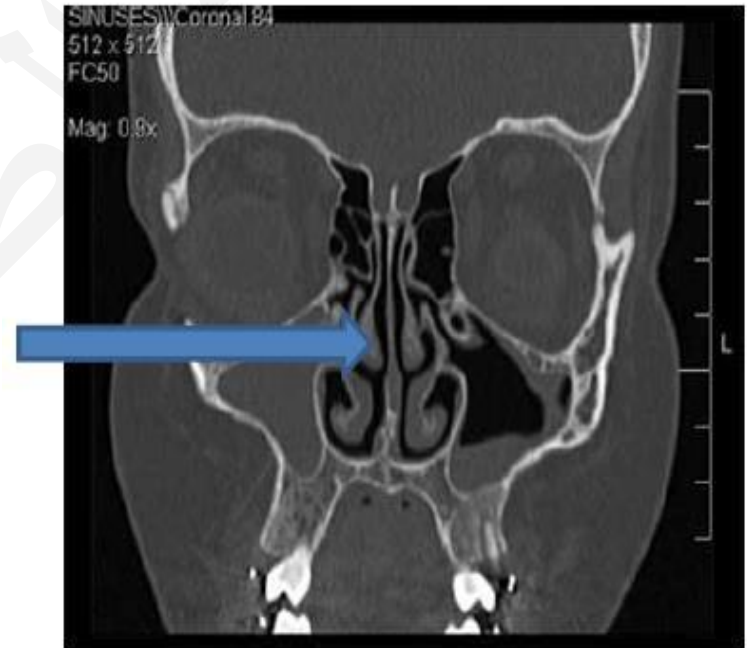
**Acute infective rhinosinusitis**

**2-What is the structure on the arrow?**

**Right middle turbinate**

**3- What is the most common nasopharyngeal tumor that occurs exclusively in males?**

**Nasopharyngeal angiofibroma**





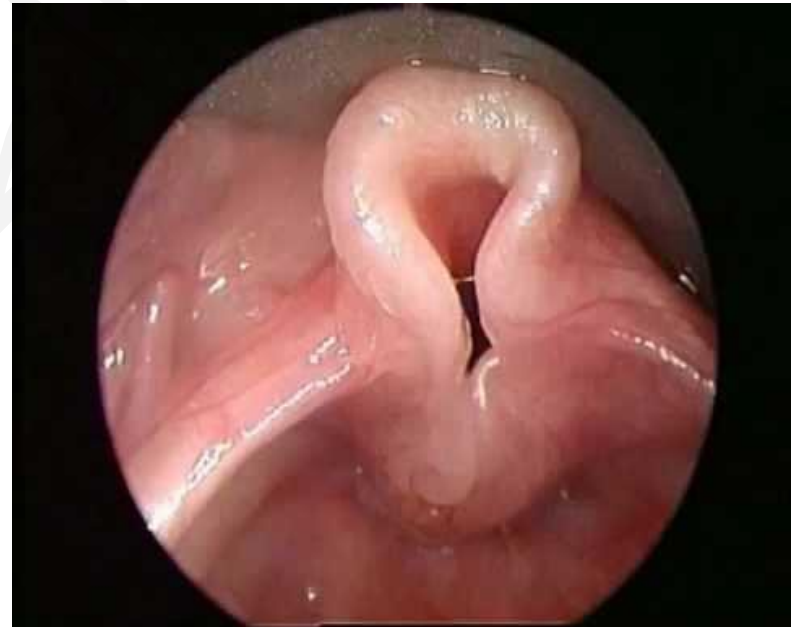# Question 2

**1-What is the diagnosis?**

**Laryngomalacia**

**2-What is the sign in the pic?**

**Omega sign**



# Question 3

Male 60 years old with progressive bilateral hearing loss, with this PTA

1- What is the diagnosis?

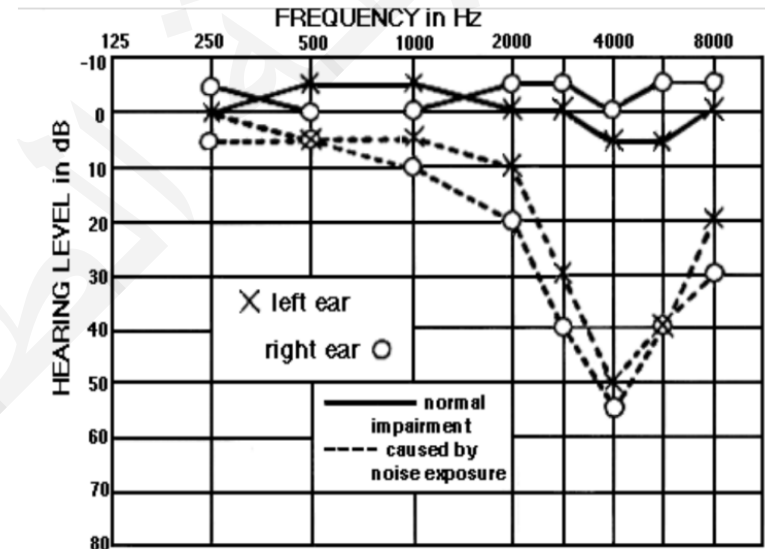
Presbycusis

2- First line of management?

Hearing aids

3- What is the diuretic that has an ototoxic effect?

Loop diuretics (Furosemide)



# Question 4

**1- What is the diagnosis?**

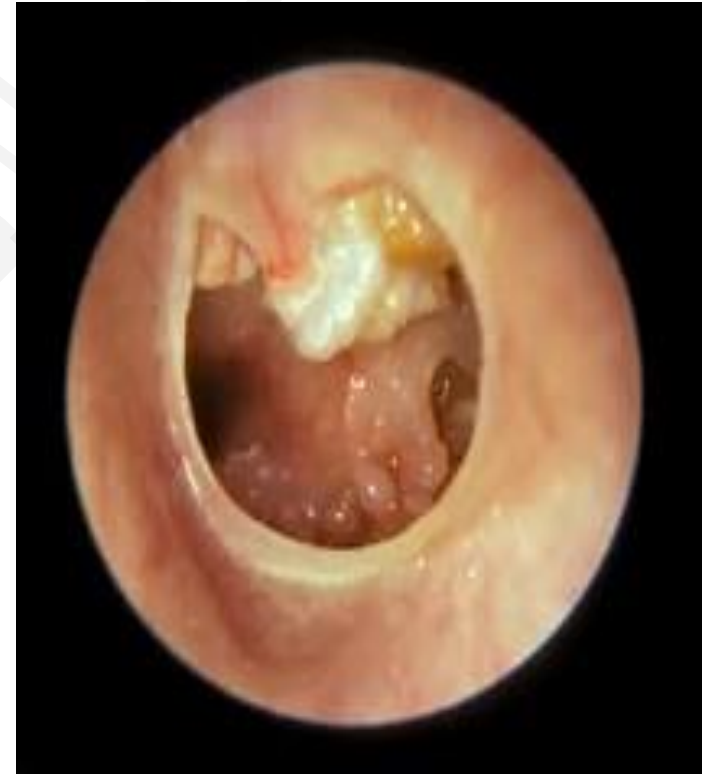Chronic suppurative OM with  
Cholesteatoma

**2- What do you see on  
tympanometry?**

Type B

**3- What is the treatment ?**

Tympanomastoidectomy



# Question 5

**1- What is the first line of management?**

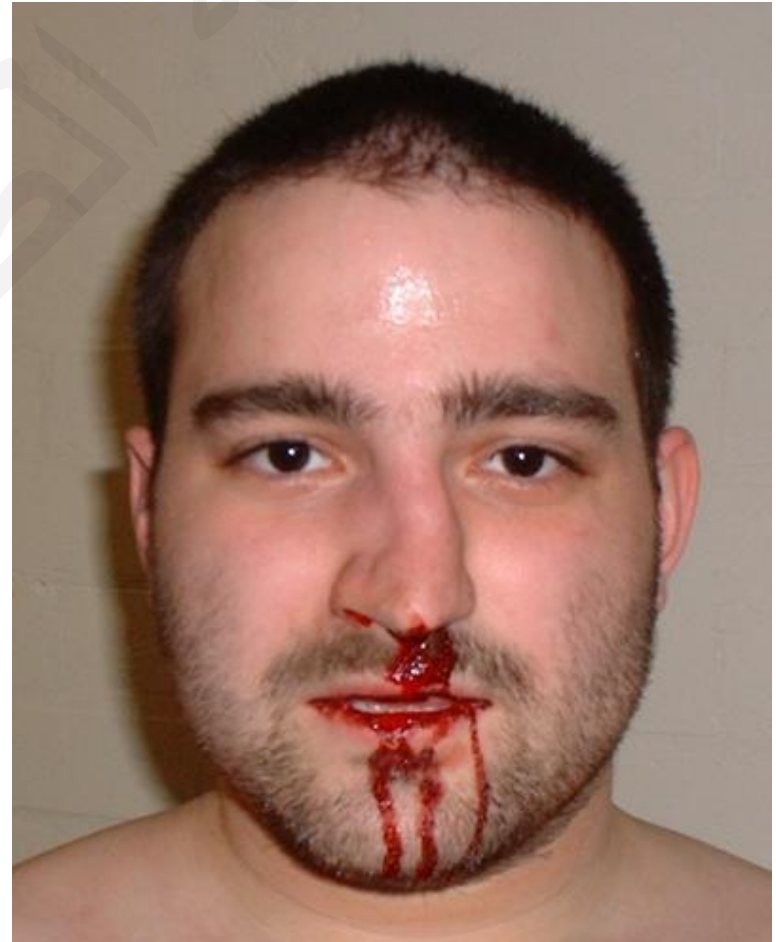Digital compression/Trotter's maneuver

**2- Mention a surgery for treatment?**

Ligation of the anterior ethmoidal artery

**3- Mention 2 iatrogenic causes of septal perforation?**

Septoplasty, nasal catheter



# Question 6

**1- What is the diagnosis?**

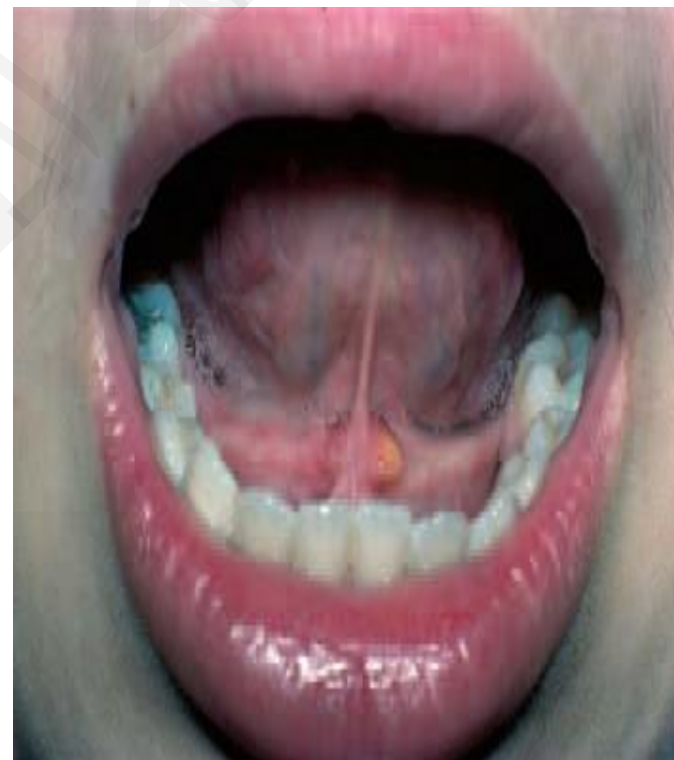**Left Sialolithiasis/ salivary calculus**

**2- Where does the stenson's duct open?**

**Opposite to the Upper second molar tooth**

**3- What is the most common salivary gland tumor?**

**Pleomorphic adenoma**



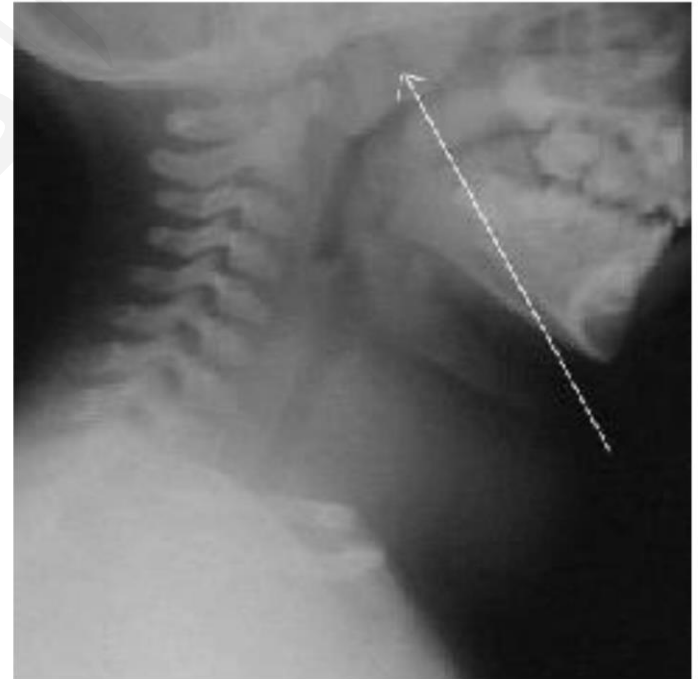# Question 7

**1- What is your diagnosis?**

**Adenoid hypertrophy**

**2- Mention two contraindications for adenoidectomy ?**

**Cleft palate, acute infection, bleeding tendency**



# Question 8

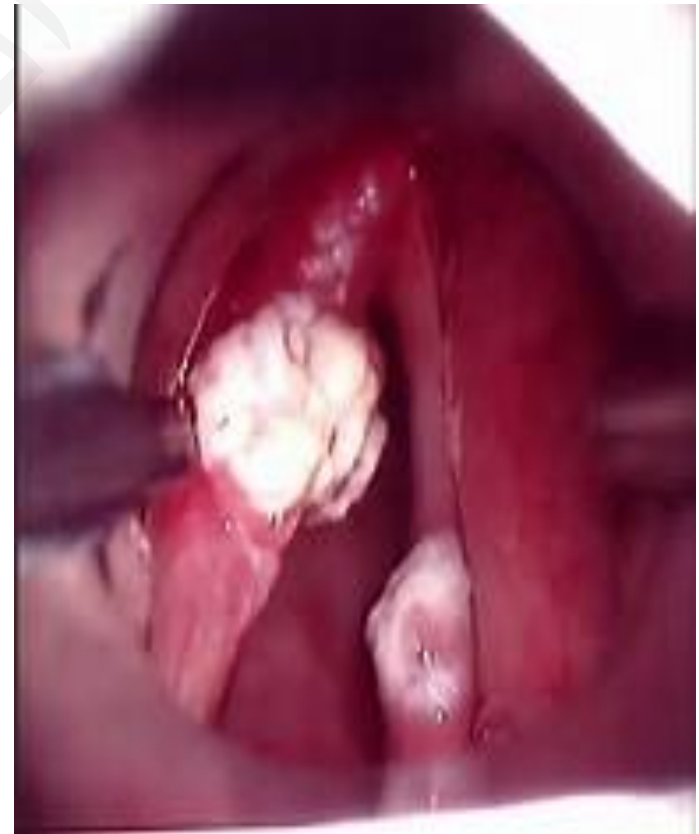**A patient diagnosed with laryngeal cancer**

**1- Mention 2 risk factors.**

**Smoking, voice abuse**

**2- what is the movement of vocal cords during inspiration?**

**Abduction**



# Question 9

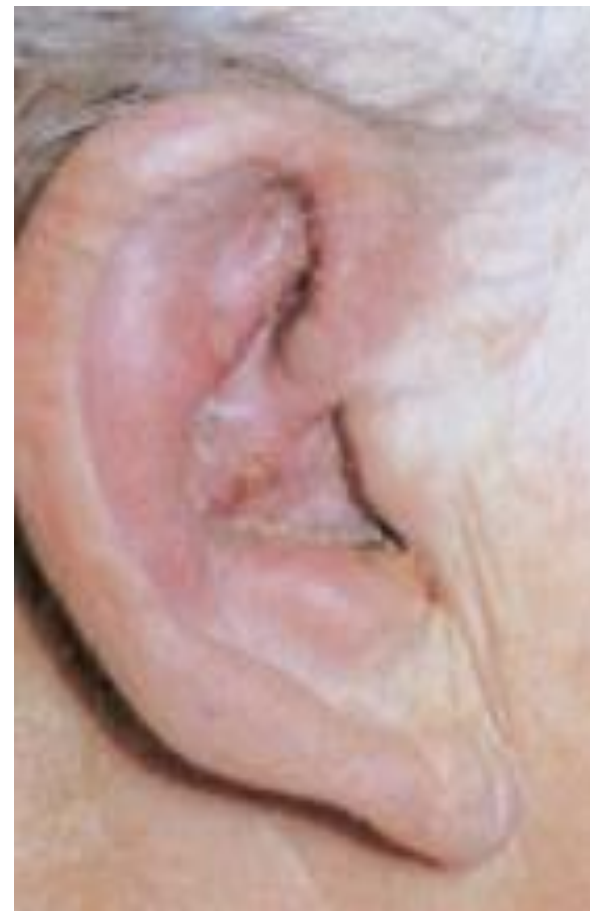**A patient presented with vesicles around his ear**

**1- What is the diagnosis?**

**Herpes Zoster oticus (Ramsy-Hunt syndrome)**

**2- Mention one complication for this diagnosis.**

**Facial nerve palsy**





# Question 10

A child is brought by his worried mother complaining of choking and difficulty breathing

1- what is the diagnosis?

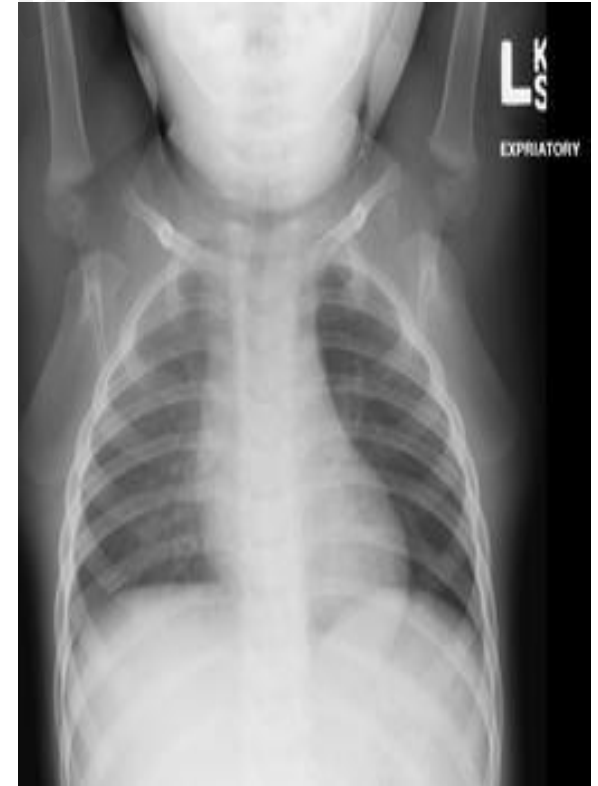Foreign body aspiration

2- what is the first line of management?

Bronchoscopy

3- Mention 2 complications if left untreated.

Pneumonia, lung collapse



# **Pulse Question Team**

## **(Farah Badwan)**

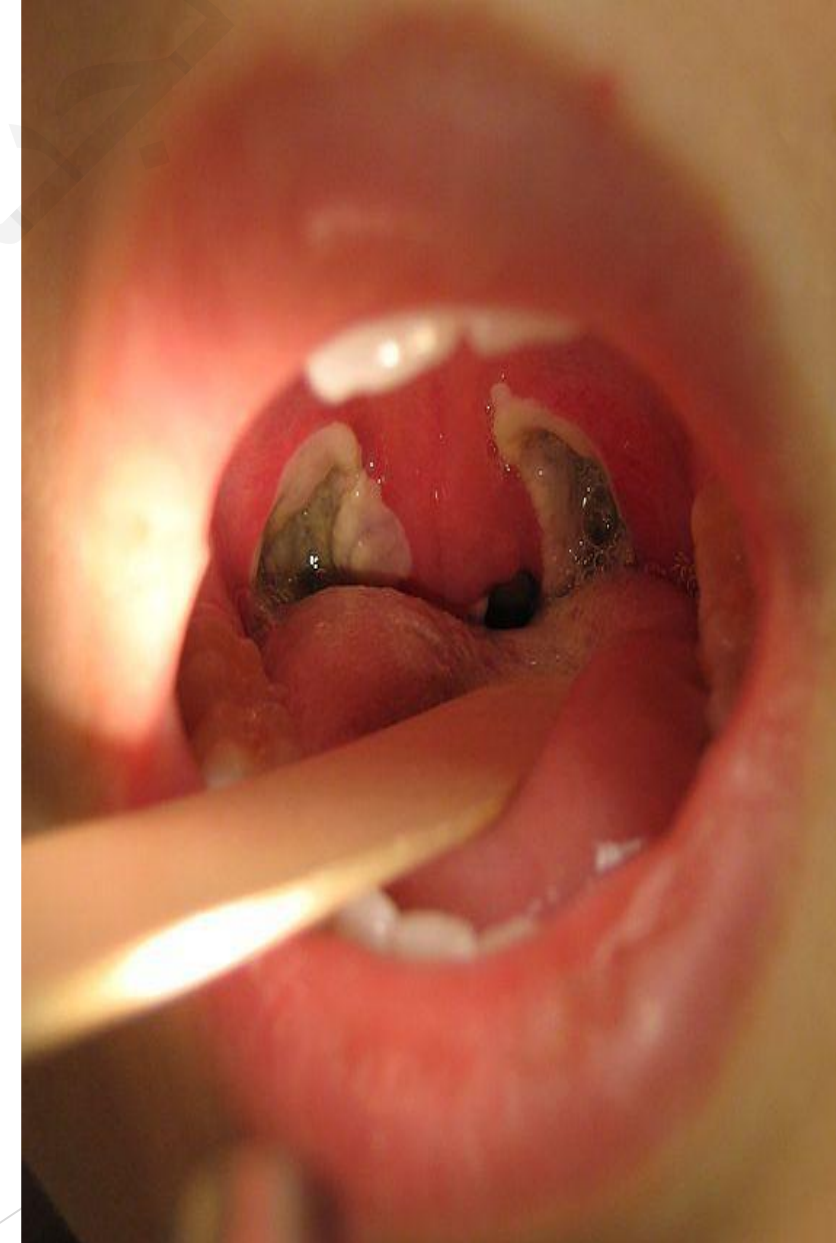


# ENT Mini-OSCE & OSCE Group C1&C2

April 6<sup>th</sup> 2017

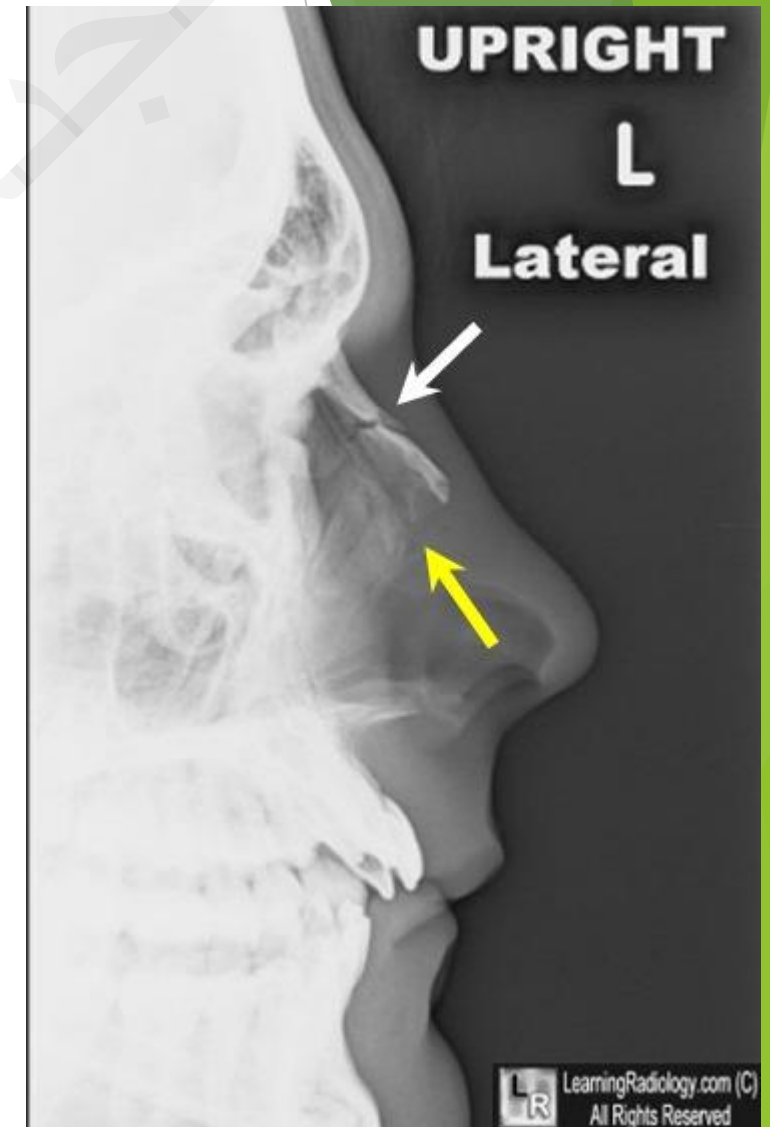
1) A 5 year old is brought to the emergency department by his parents because they saw a white exudate on his throat, he had a tonsillectomy 2 days ago.

- ▶ 1-What is the cause of this?
  - ▶ Normal fibrinoid reaction after tonsillectomy
- ▶ 2-Give 2 indications for tonsillectomy?
  - ▶ A-Recurrent acute tonsillitis
  - ▶ B-Complicated tonsillitis as in febrile convulsion



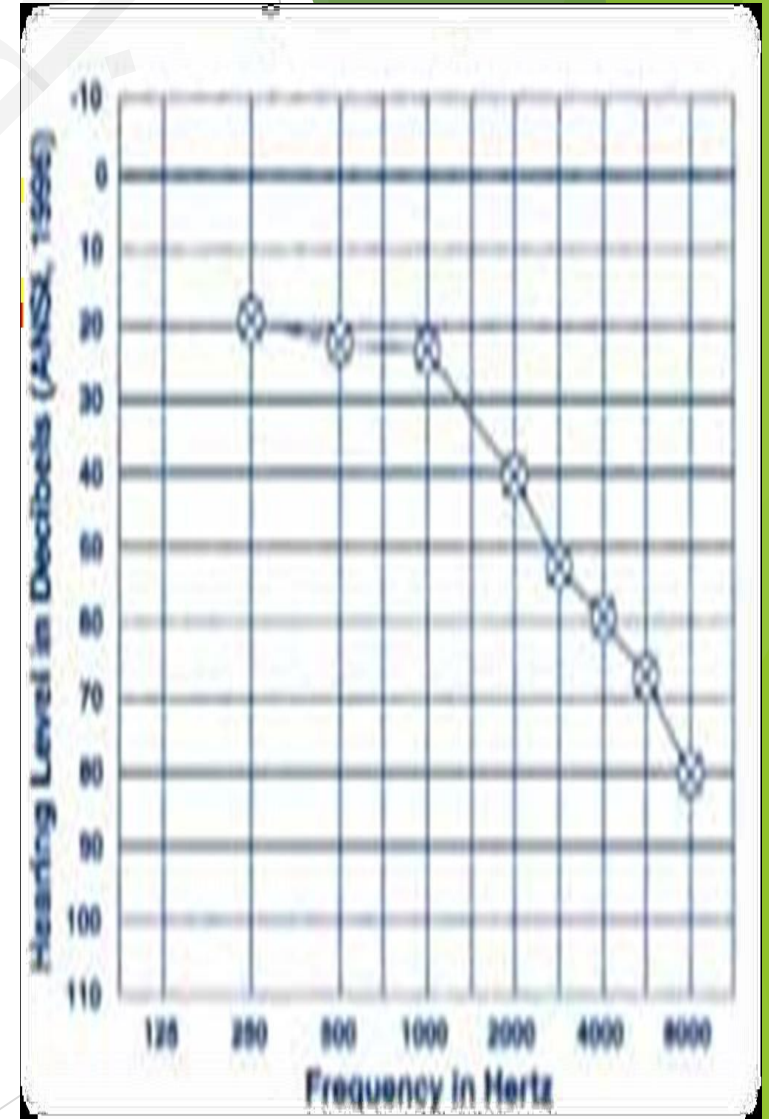
2) A 25 year old patient is brought to the ER after a quarrel, he has pain in his nose.

- ▶ 1-What is the diagnosis as indicated by the arrow?
  - ▶ Nasal bone fracture
- ▶ 2-What is the first step in management after ABC?
  - ▶ Reduction of fracture
- ▶ 2-What is the name where there is recurrent epistaxis and multiple telangiectasia?
  - ▶ Hereditary hemorrhagic telangiectasia



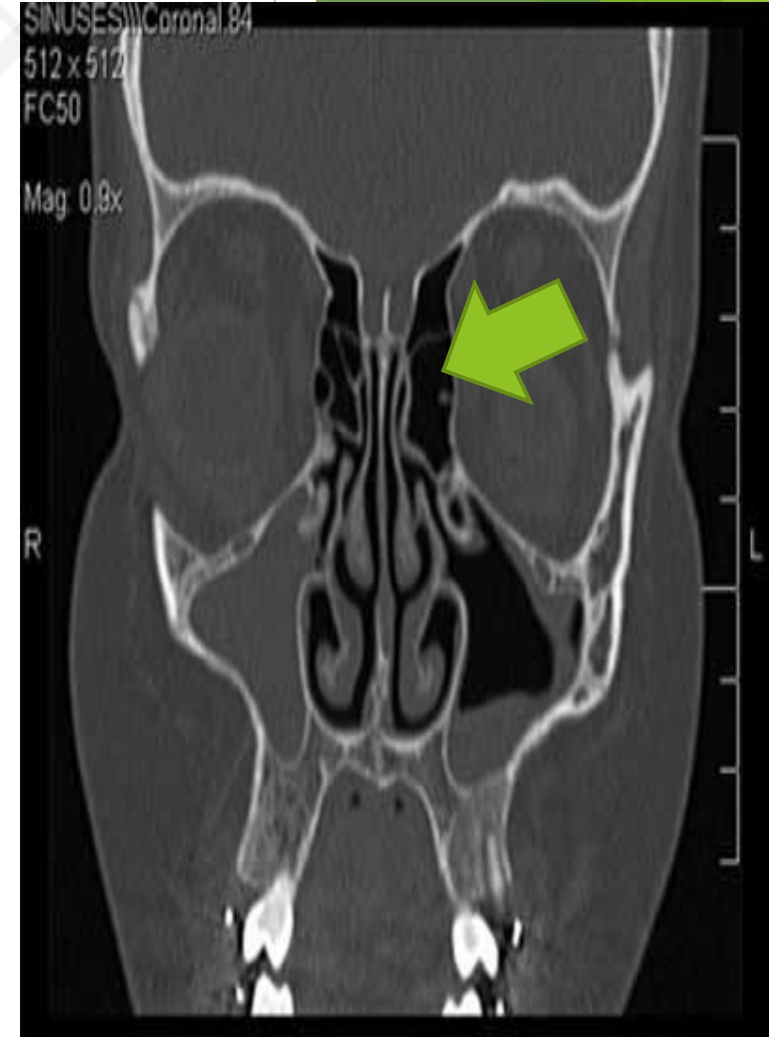
### 3) A 75 year old male patient complaining of progressive bilateral hearing loss.

- ▶ 1- How do you treat?
  - ▶ Hearing Aid
- ▶ 2- What is the name of the disease where there's craniofacial deformities, hearing loss and micrognathia?
  - ▶ Treacher Collins syndrome



4) A 20 year old female patient presented with 10 days duration of yellow nasal discharge.

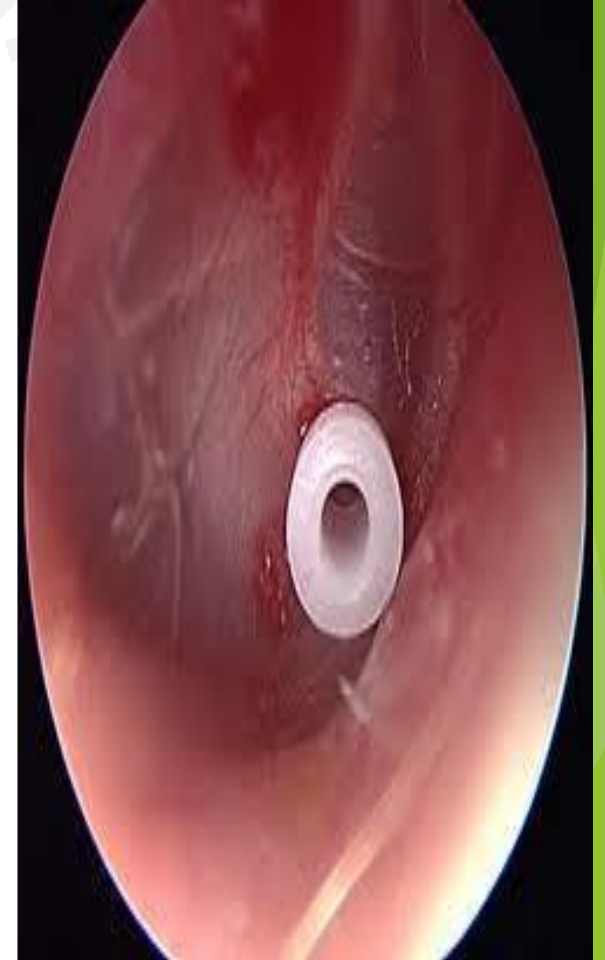- ▶ 1- What is the diagnosis?
  - ▶ Acute infective rhinosinusitis
- ▶ 2- What is the most likely microorganism?
  - ▶ Streptococcus pneumonia
- ▶ 3- What is the name of the surgery for refractory cases?
  - ▶ FESS (Functional endoscopic sinus surgery)
- ▶ 4-What is indicated by the arrow?
  - ▶ Left ethmoidal sinus





## 5) A 4 year old is brought for a check up.

- ▶ 1- What is the most likely cause of insertion of this tube (Preoperative diagnosis)?
  - ▶ Otitis media with effusion (OME)
- ▶ 2- Mention 2 complications of this tube?
  - ▶ Permanent perforation
  - ▶ Dislodgment
- ▶ 3- What is the most likely cause for his preoperative condition?
  - ▶ Adenoid hypertrophy





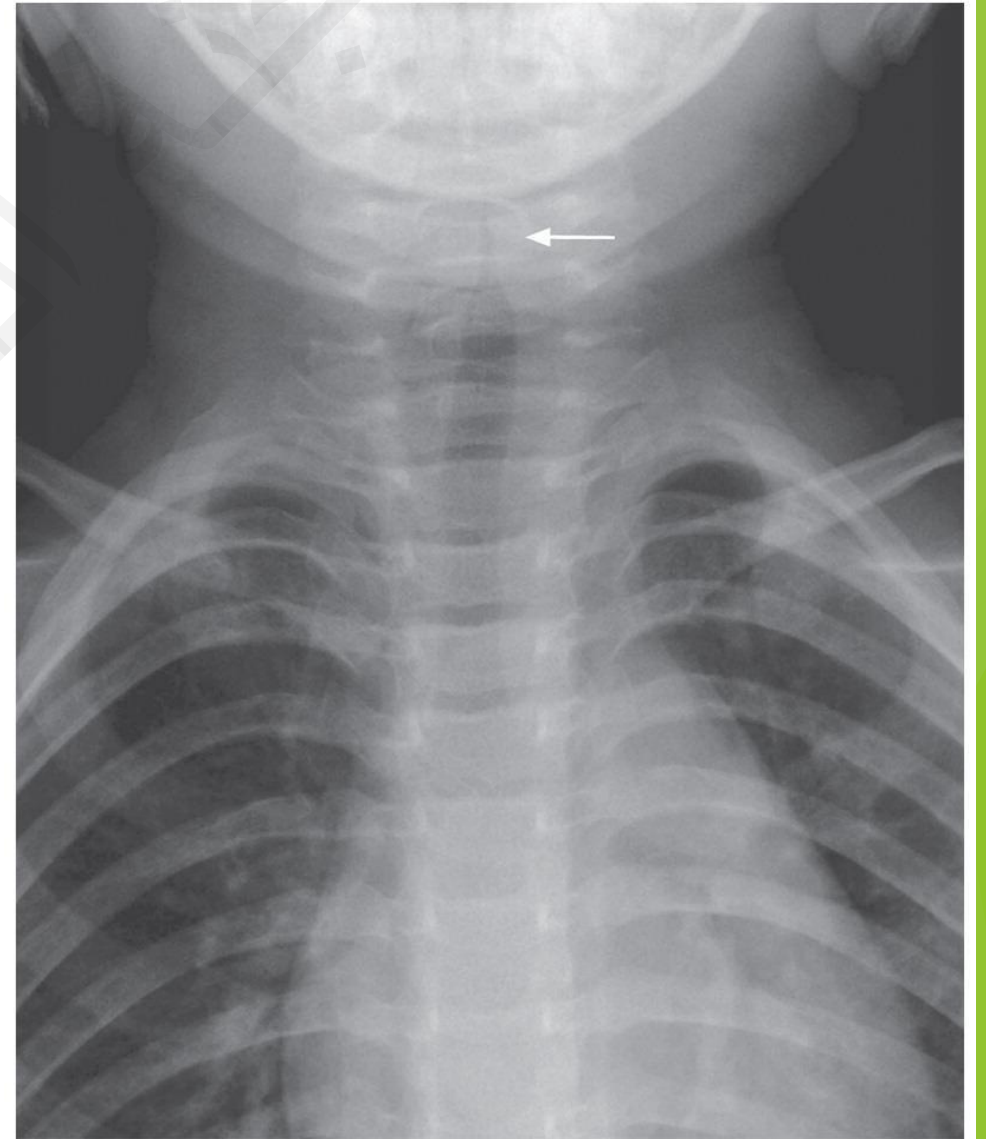
6) A patient is complaining of decrease hearing, he has impacted ear wax.

- ▶ 1- What is this technique?
  - ▶ Ear syringing technique
- ▶ 2- Mention 2 complications of this procedure?
  - ▶ Tympanic membrane perforation
  - ▶ Injury to ear canal
- ▶ 3- What is the type of tympanometry for this patient?
  - ▶ Type B



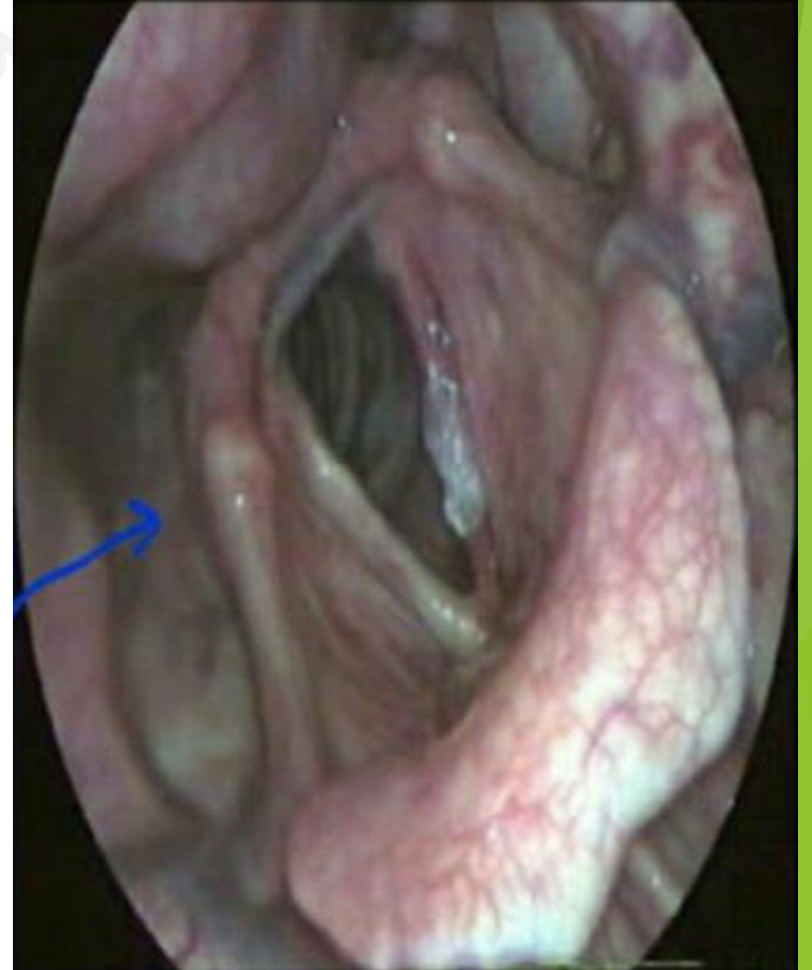7) A child presented to the ER, he is complaining of stridor and SOB.

- ▶ 1- What is the sign seen on this X-ray?
  - ▶ Steeple sign
- ▶ 2- What is the most likely microorganism?
  - ▶ Parainfluenza virus
- ▶ 3- What is the management?
  - ▶ Racemic nebulizer & steroids.



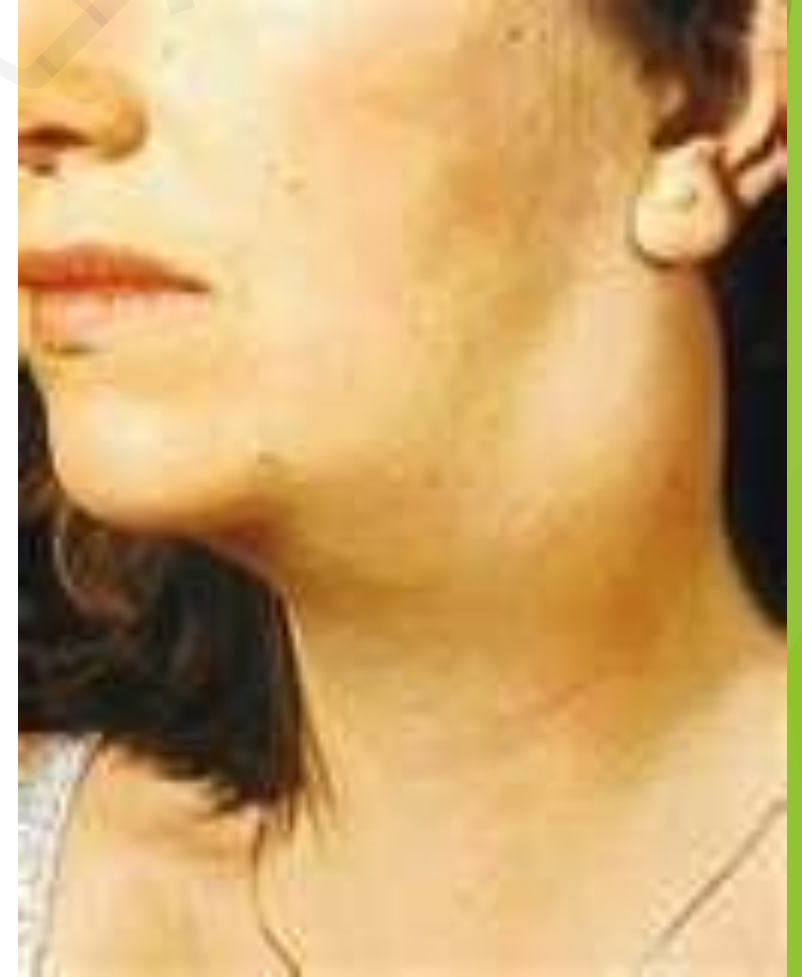8) A 55 year old male smoker, is complaining of dysphonia. His initial work up suggests malignancy

- ▶ 1- What is the most common subtype?
  - ▶ Squamous cell carcinoma
- ▶ 2- What is the name of the area the arrow is point at?
  - ▶ Right piriform fossa



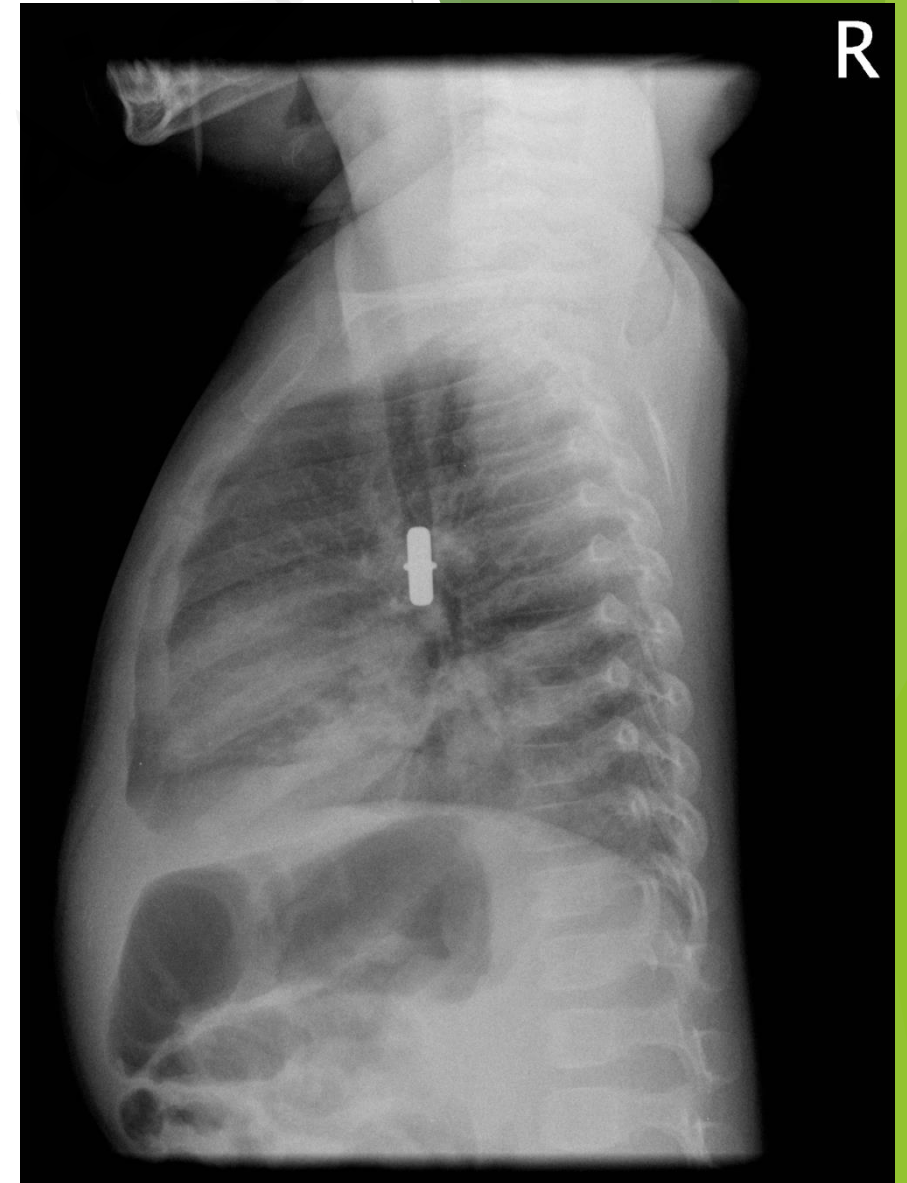
## 9) A patient complaining of a neck mass for 3 months duration.

- ▶ 1- Mention 2 differential diagnoses?
  - ▶ Lipoma
  - ▶ Lymphoma
- ▶ 2- Best next step in management?
  - ▶ FNA




10) A 4 year old patient is brought to the ER complaining of dyspnea and stridor for the past hour.

- ▶ 1- What is the next line in management?
  - ▶ Bronchoscopy
- ▶ 2- Mention one complication if this was not treated properly?
  - ▶ Pneumonia.



# Pulse Question Team (Omar Sallam)



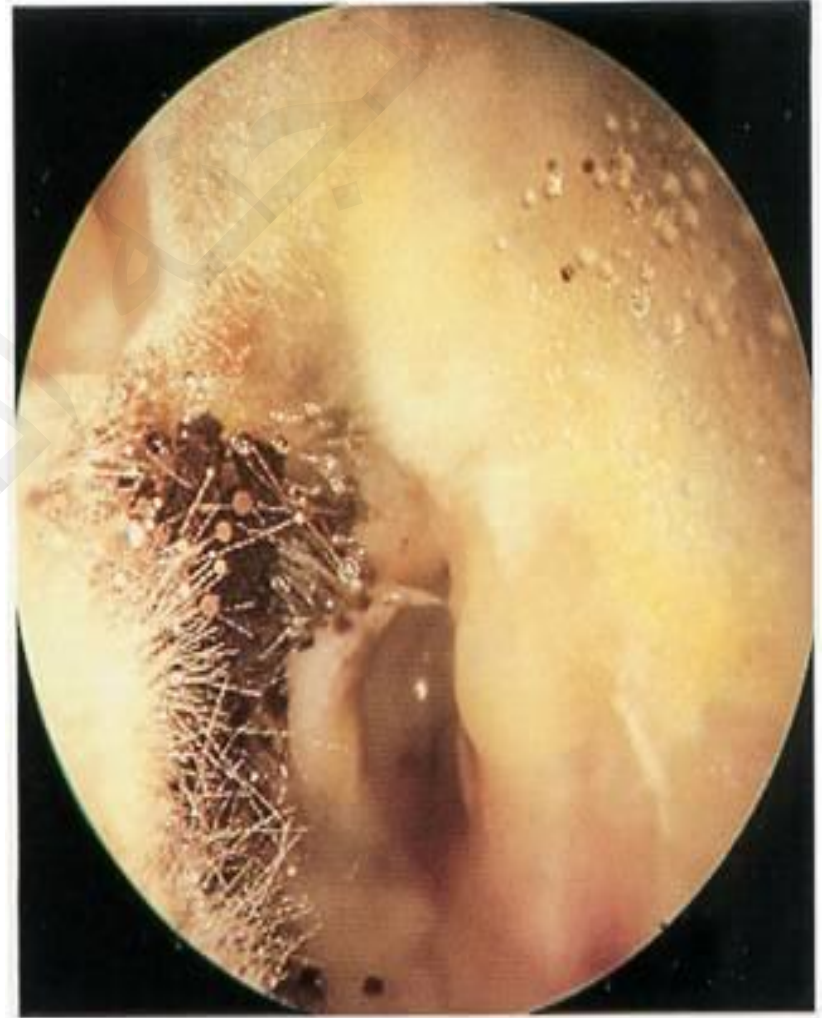


# **ENT mini-OSCE**

## **Group C5&C6**

**This pt. presented with Hx of ear itchiness.**

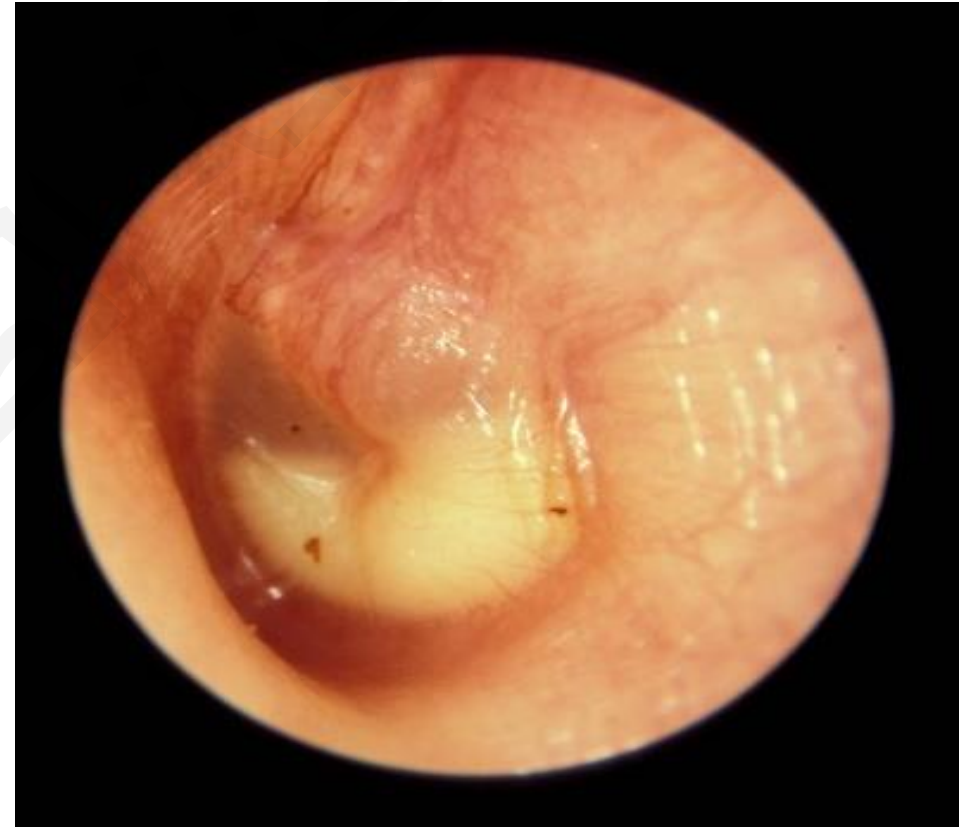- What is your diagnosis?
  - Otomycosis
- Two lines of management?
  - Aural toilet and keep the ear dry
  - Topical antifungals





**This pt. presented with Hx of 3 days duration of pain, fever, ...**

- Most common organism?
  - S. pneumoneae
- 2 Orbital complications?
  - Orbital cellulitis
  - Abscess
- On tympanometry?
  - Type B

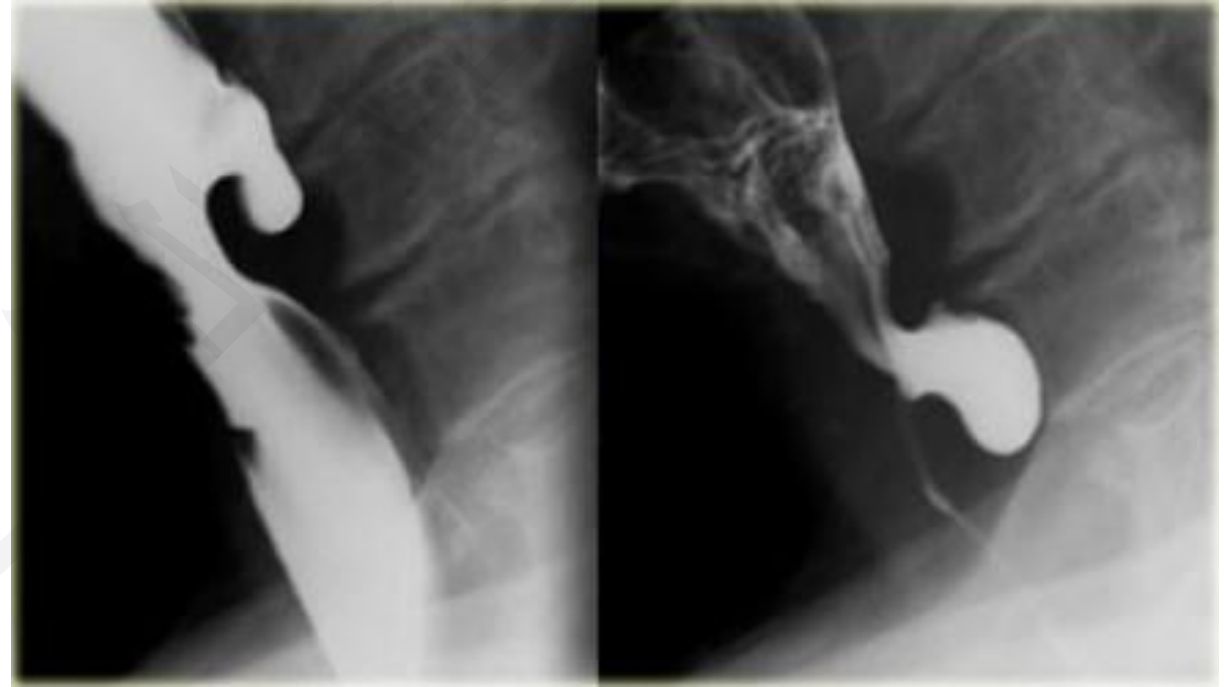

# Chocking and cyanosis while eating in a restaurant..

- Best maneuver?
  - Heimlich maneuver
- Next step in this situation?
  - Cricothyroidotomy

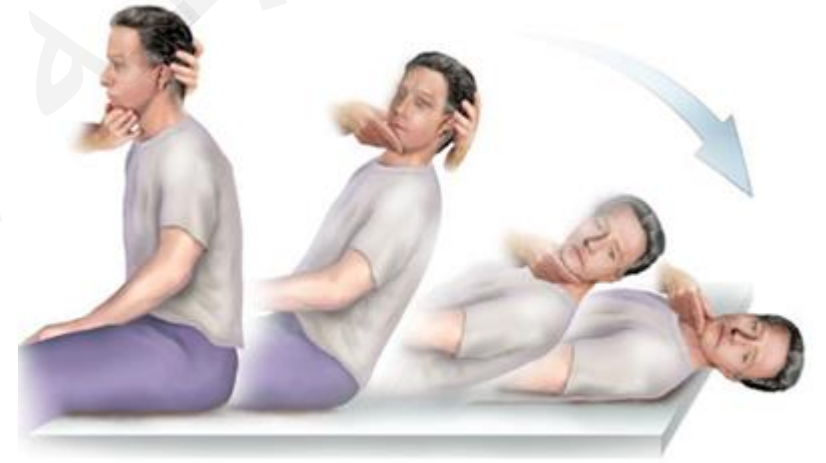# Dysphagia, regurgitation, ...

- Diagnosis?
  - Zenker's diverticulum
- Anatomical site?
  - Killian triangle



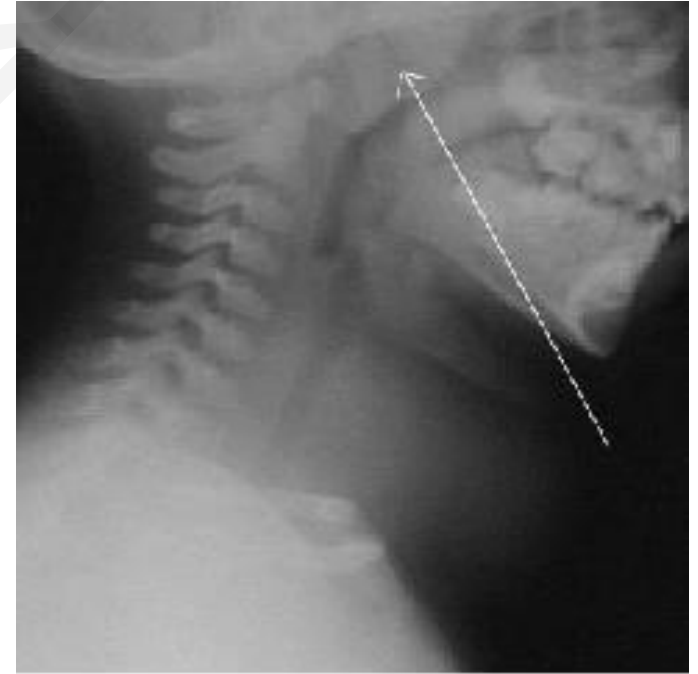**A patient presented with history of recurrent attacks of vertigo that continues for seconds with moving the head, Dix-hallpike positive.**

- What is the next Step?
  - Epley's maneuver
- Finding in the Dix-hallpike maneuver?
  - Nystagmus

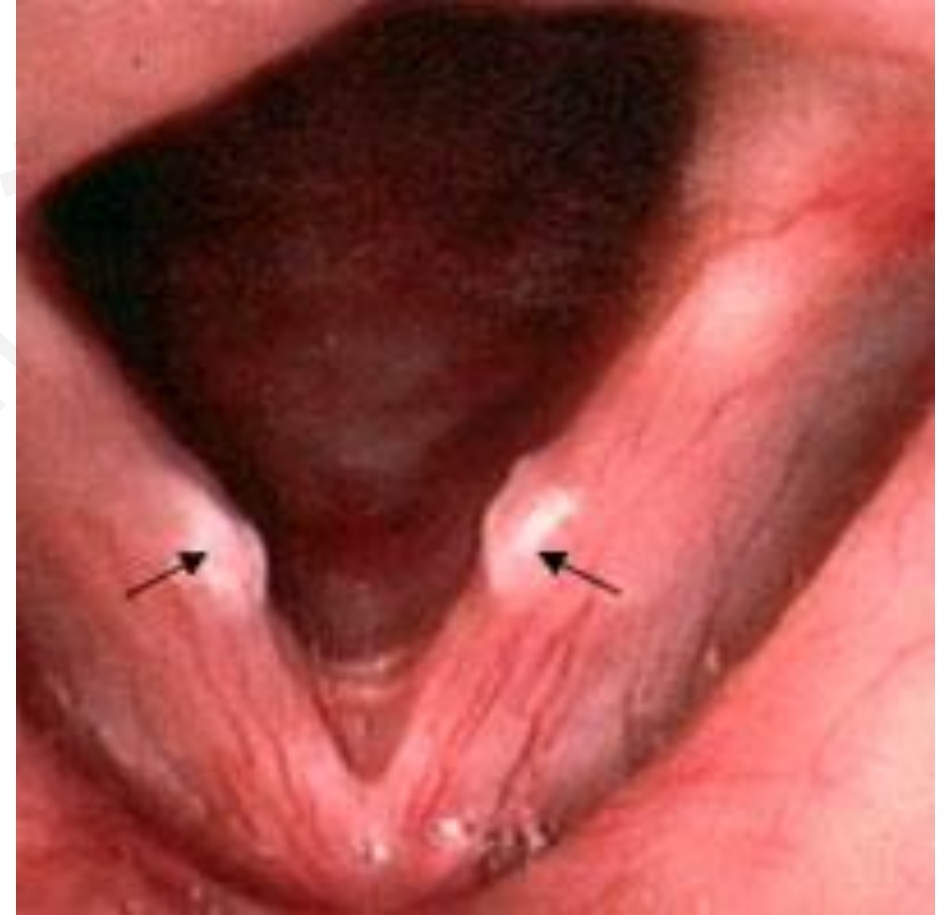

# A child with nasal obstructive symptoms

- What is your diagnosis?
  - Adenoid Hypertrophy
- One complication?
  - OM with effusions

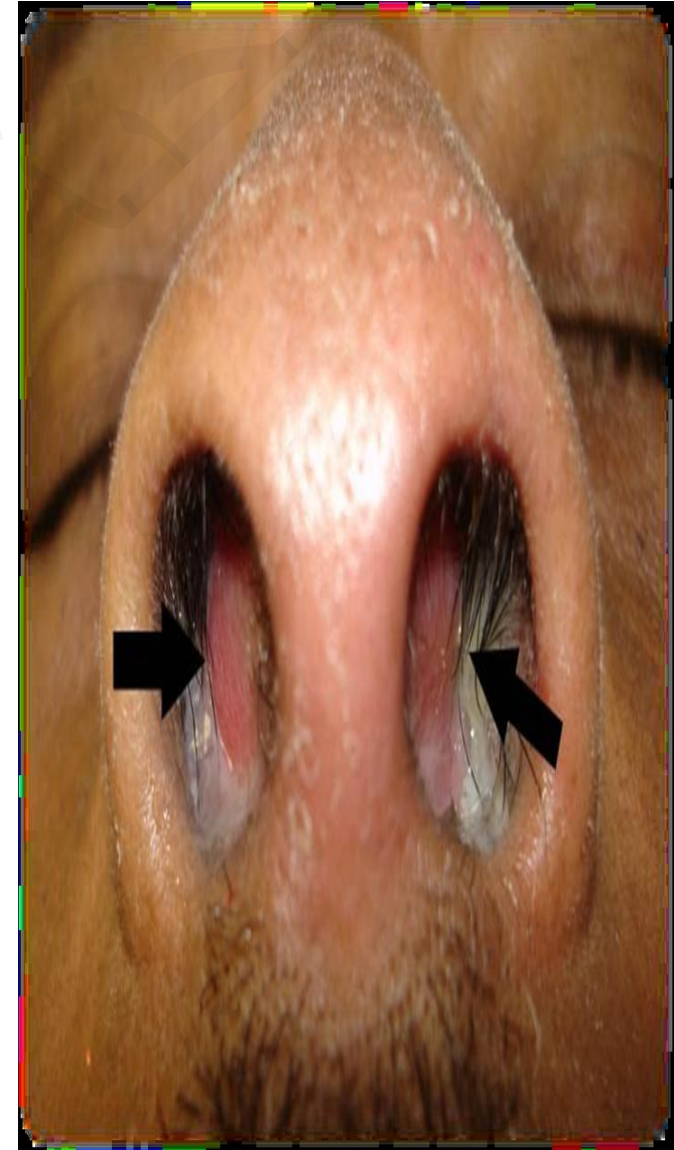


- What is the diagnosis?
  - Singer's nodule
- One line of management?
  - Voice rest / speech therapy



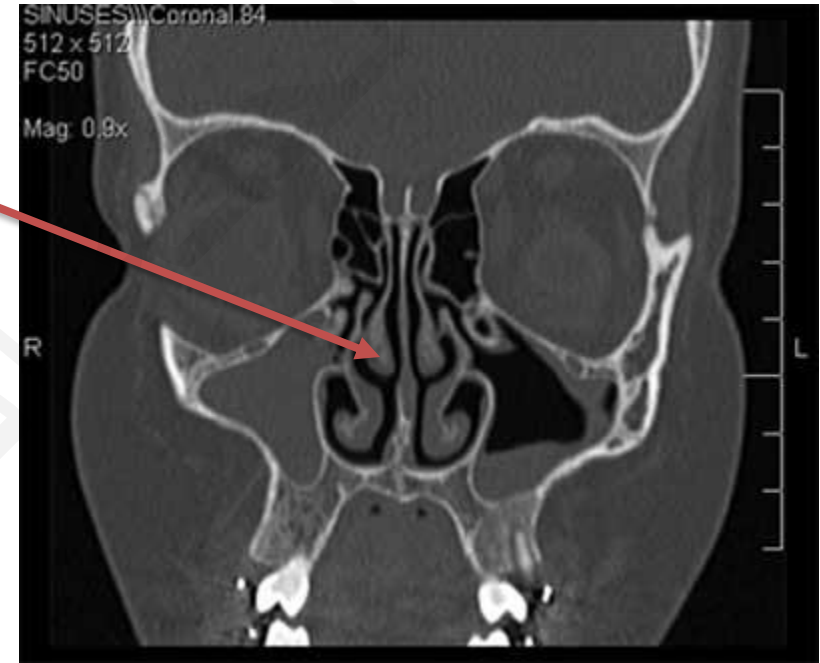
**Patient came to you after history of trauma yesterday complaining of this picture**

- What is your diagnosis?
  - Septal Hematoma
- 2 complications?
  - Abscess
  - Perforation



## 4 weeks duration, rhinorrhea, ...

- Diagnosis?
  - Chronic right maxillary sinusitis
- Arrow?
  - Right middle turbinate

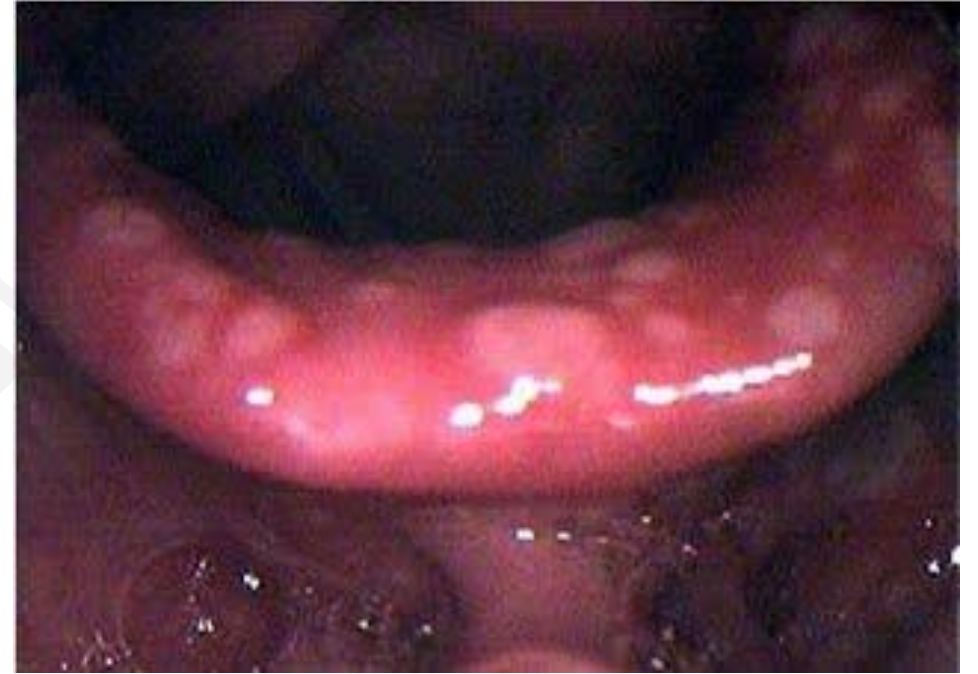



- Name of an IgE antibody?
  - Omalizumab
- Two non-surgical lines of management of sleep apnea in adults?
  - Weight reduction
  - CPAP

**A 7 year old child presented to the ER with dysphagia, drooling and fever with difficulty in breathing.**

- Most common organism?
  - H. influenza
- Best way to secure airway?
  - Endotracheal intubation



**Pulse Question Team**  
**(Ala'a Omar & Saif Khasawneh)**



# **ENT mini-OSCE**

## **Group C7&C8**

# Question 1

A patient complaining of hoarseness in voice, presented with this picture

1-What is your most likely diagnosis?

Laryngeal ca (most common type is SCC)

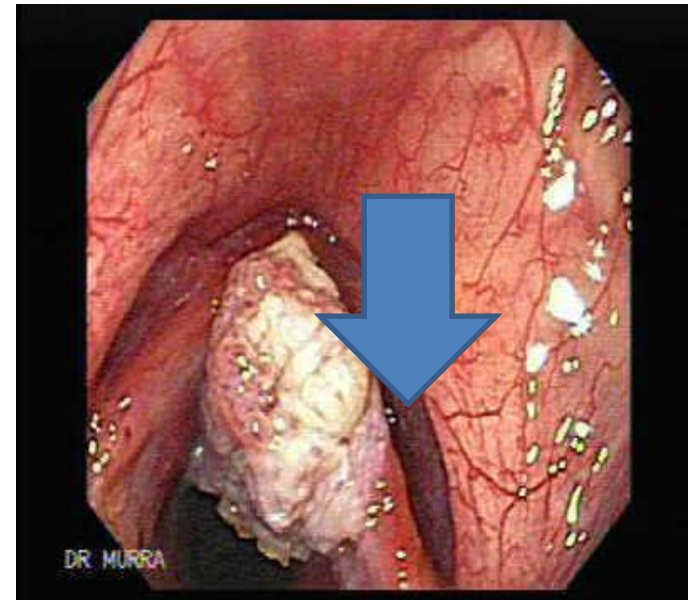
2-Give 2 risk factors?

A-Smoking

B-Voice Abuse

2-What is the structure on the arrow?

piriform recess, pyriform sinus, piriform fossa



# Question 2

A patient presented with headache and nasal discharge for a week

1-What is your Dx?

Acute infective rhinosinusitis

2-What is the structure on the arrow?

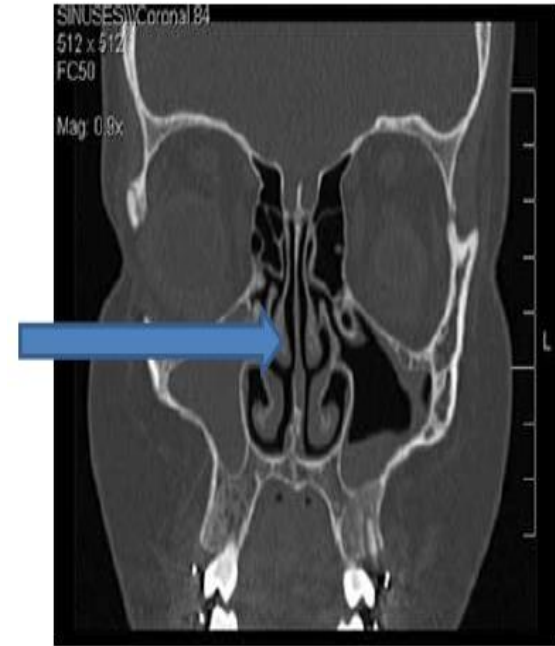
Right middle turbinate

3-what we call the syndrome when the pt had aspirin intolerance, asthma and a nasal polyp?

SAMTER syndrome

4- Most common site of origin of nasopharyngeal carcinoma?

Rosemnüller fossa



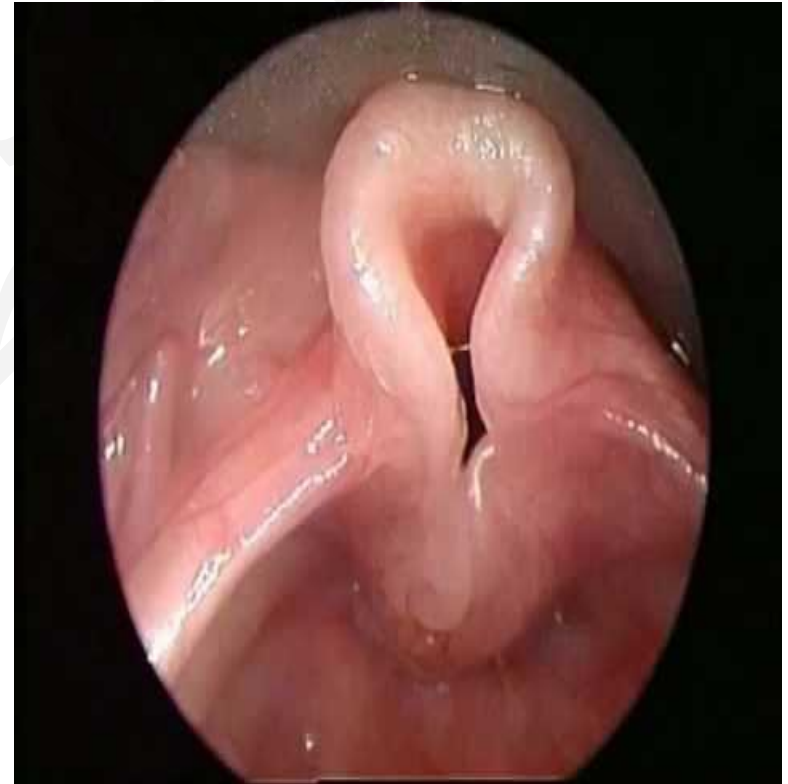## Question 3

**1-What is the diagnosis?**

**Laryngomalacia**

**2-What is the sign in the pic?**

**Omega sign**



# Question 4

**1-What is your diagnosis?**

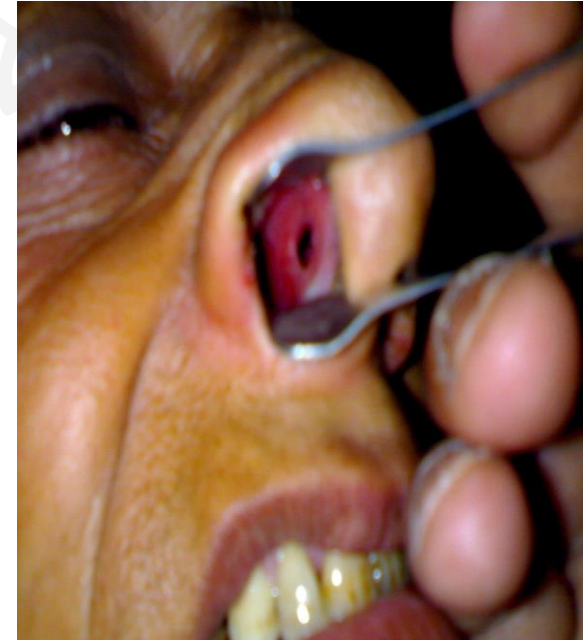
-Nasal septum perforation

**2-Give two non-iatrogenic causes.**

-Foreign body

-Warfarin

-Cocaine sniffing





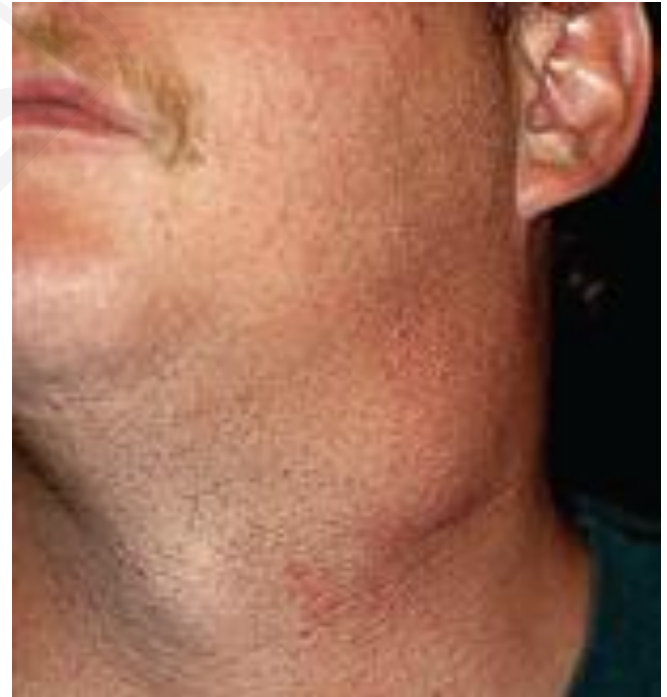# Question 5

**1- mention 2 DDx?**

- lymphadenopathy
- branchial cyst

**2- Next gold standard step  
for diagnosis**

- FNA



# Question 6

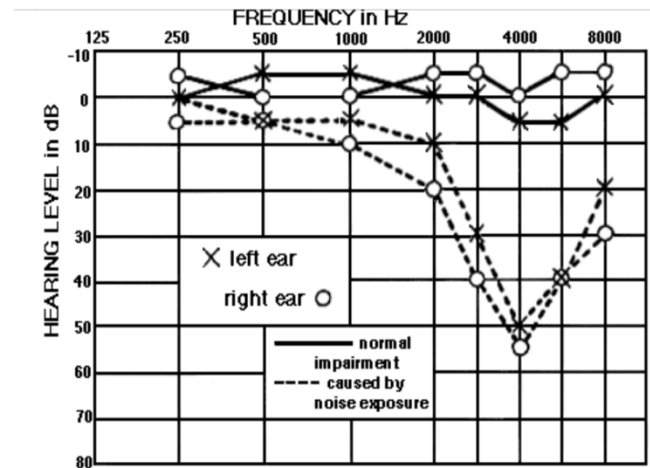
- Male 60 years old with progressive bilateral hearing loss , with this PTA

**1- First line of management?**

**Hearing aids**

**2-What is the clinical finding in positive dix-hallpike test?**

**Nystagmus**



# Question 7

**1- what's your Dx?**

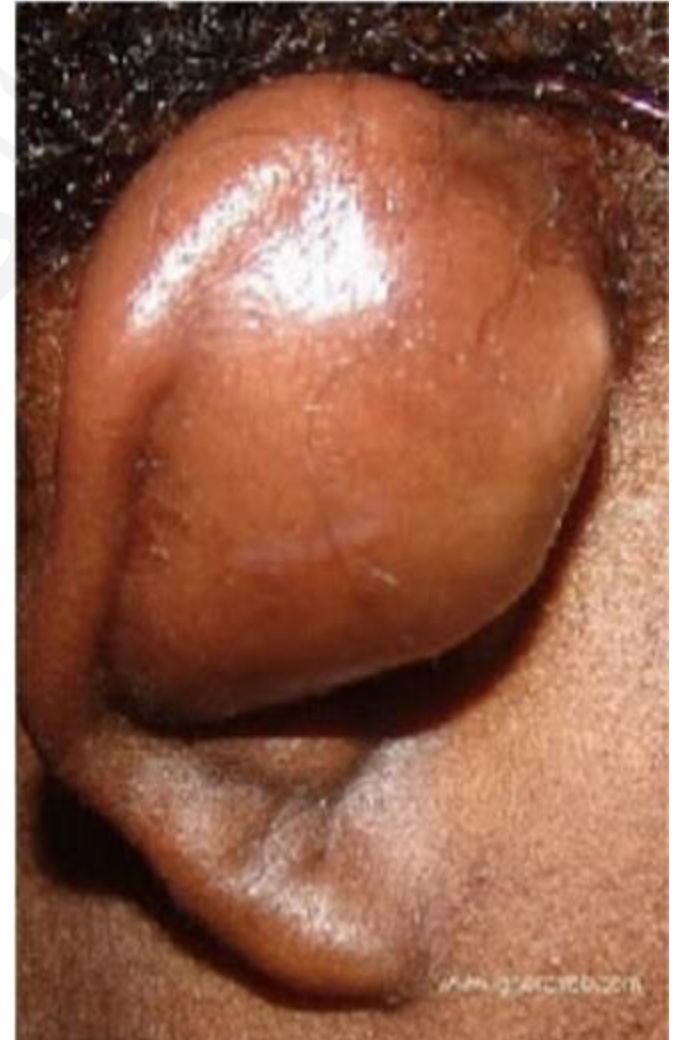**Auricular hematoma**

**2- management?**

**Incision and evacuation**

**3- possible complication if left untreated?**

**Auricular abscess**



# Question 8

- Hx. Of 6 years old child with bilateral dull tympanic membrane and delayed speaking.

1-What is your diagnosis?

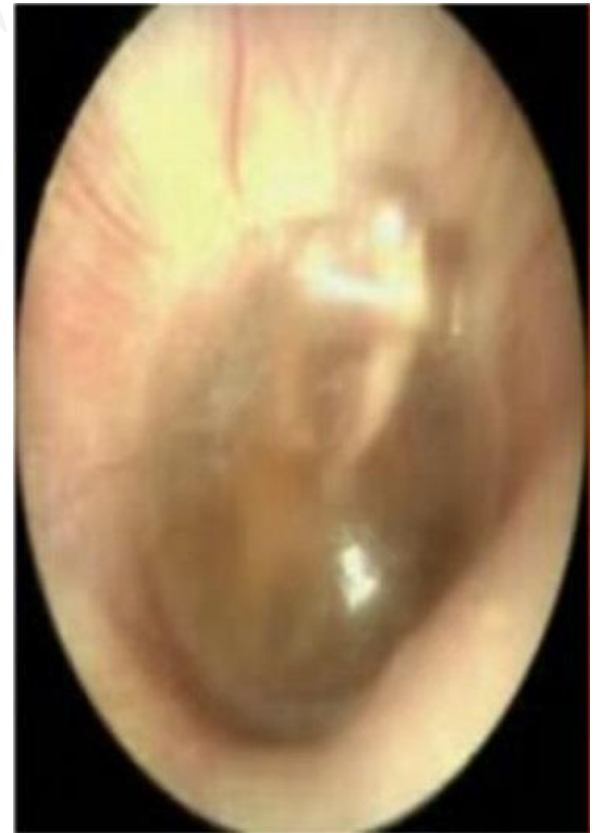OME

2-what to do for management?

Myringotomy and ventilation tube

3-What is the type of tympanometry?

Type B



# Question 9

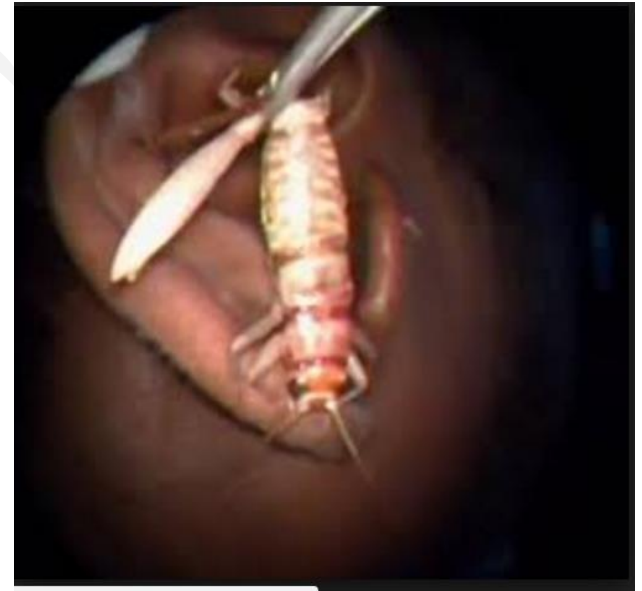**Patient with buzzing tinnitus**

**1-First line of management?**

**Kill insect with alcohol**

**2-Complications?**

**TM perforation**



# Question 10

- A 7 year old child presented to the ER with stridor and toxic appearance and fever with difficulty in breathing

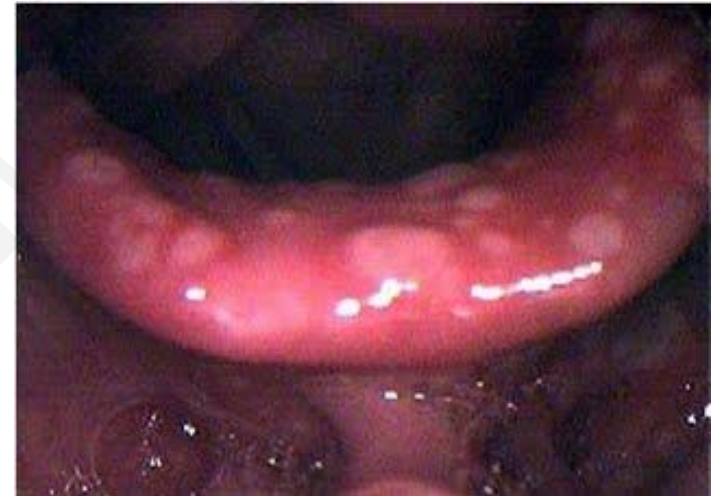1- What is the diagnosis ?

Acute epiglottitis

2-Mention 2 EBV cancers


Nasopharyngeal carcinoma

Hodgkin's lymphoma



# **Pulse Question Team**

## **(Hamzeh Al-Rimawi)**

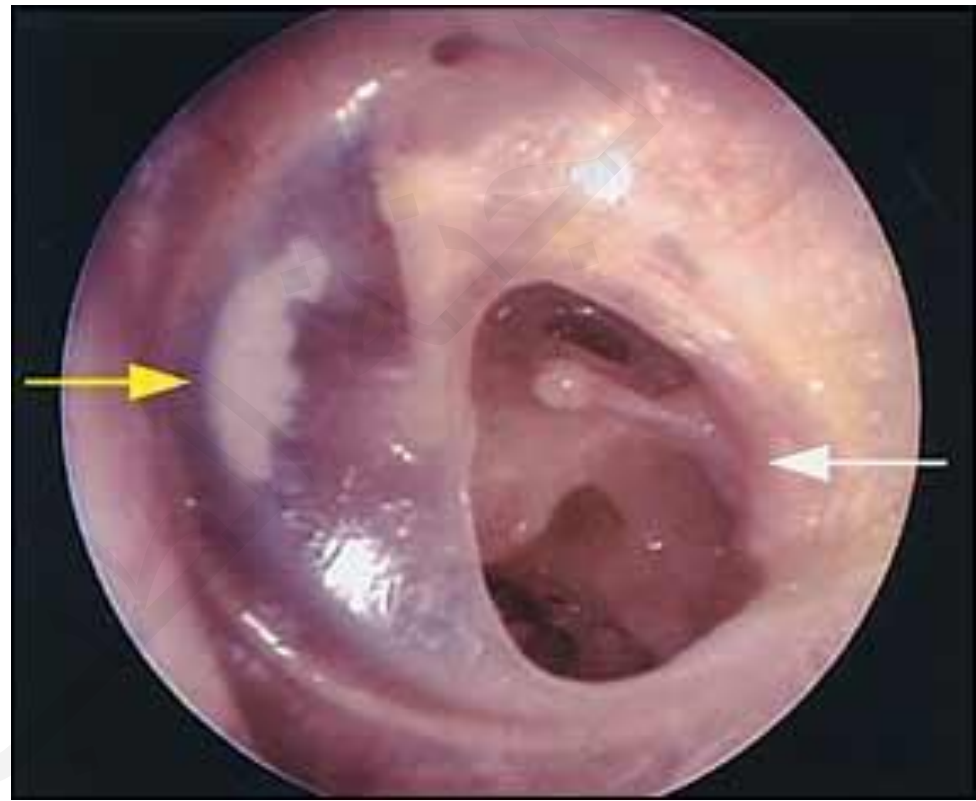


# ENT mini-OSCE

Group D1&D2



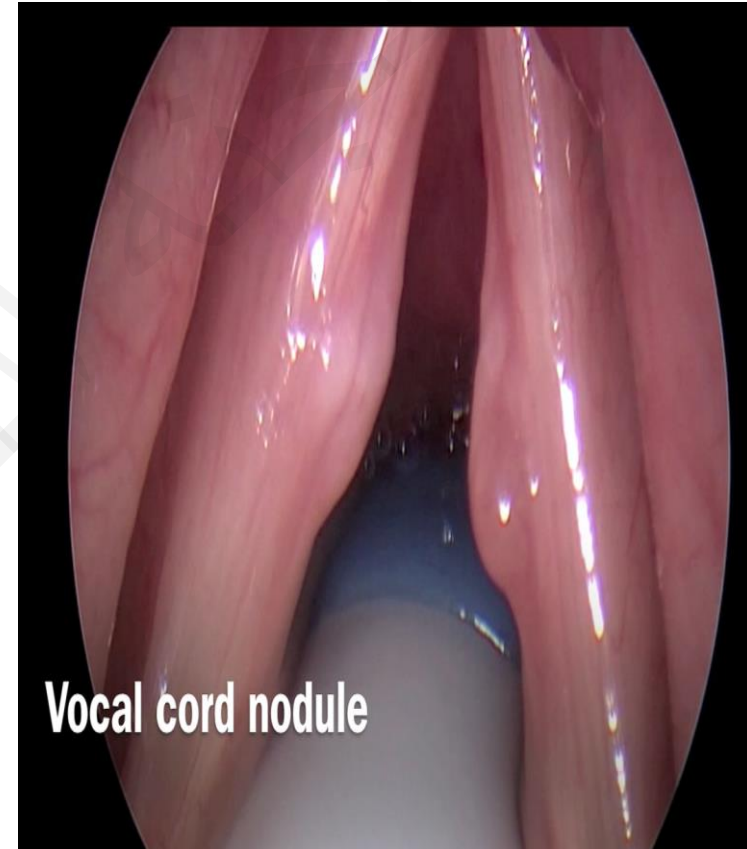
- Mention two findings.
  - Tympanic membrane perforation
  - Myringosclerosis
- What is the name if the syndrome involves hearing loss with mucosal retinitis ?
  - Usher syndrome



\*Not the same picture and it was without arrows.

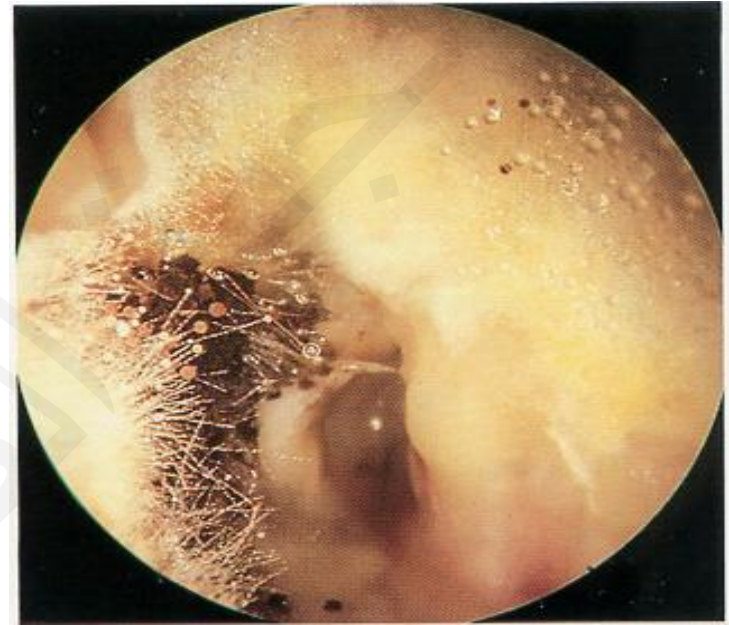**A 30 years old teacher  
presented with dysphonia.**

- What is the working  
dianosis to do?
  - Vocal cord nodule



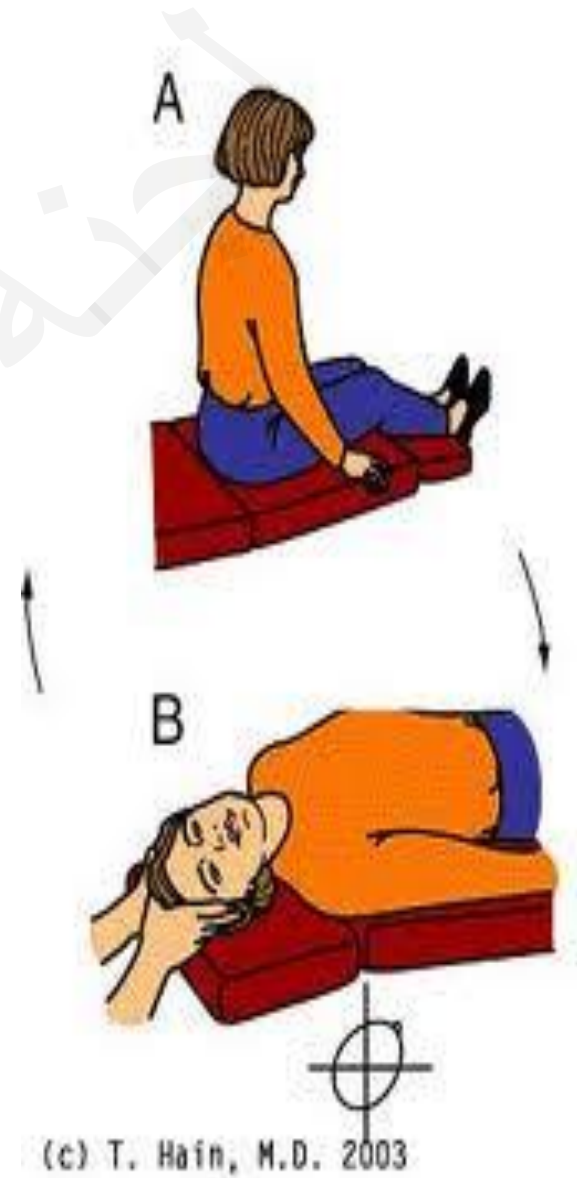
**This pt. presented with Hx of ear itchiness.**

- What is your diagnosis?
  - Otomycosis
- What is the treatment?
  - Keep ear dry and aural toilet
  - Topical antifungal

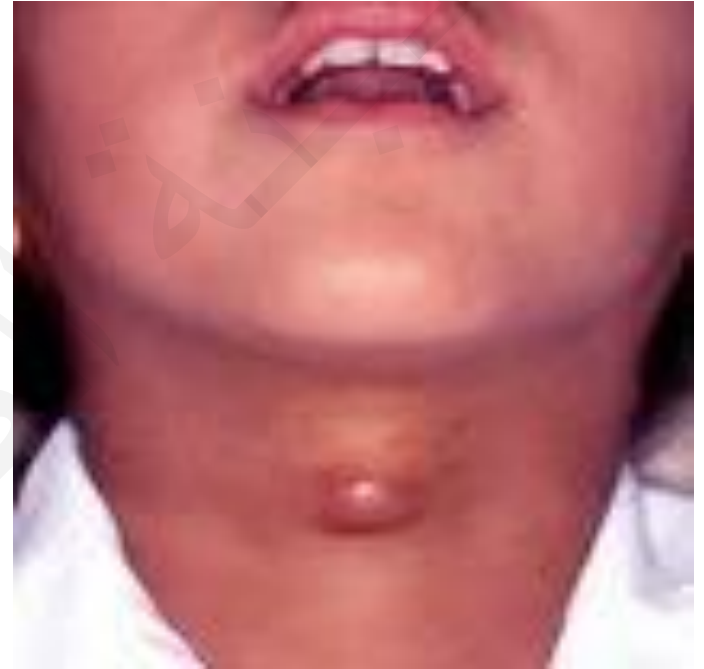

# History suggestive of BPPV..

- What is your diagnosis?
- What is the treatment?  
Ebley maneuver

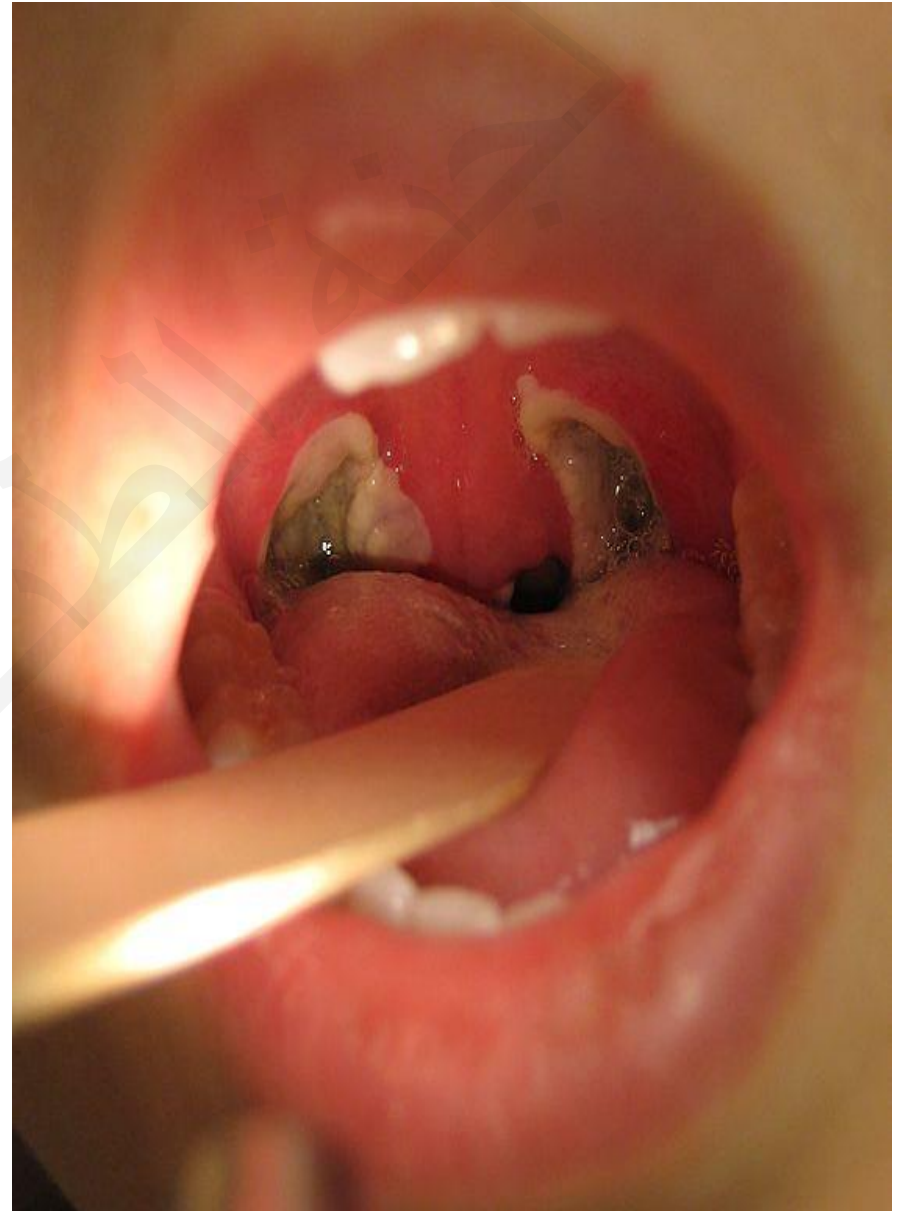


- What is this?
  - Thyroglossal cyst
- Typical surgery?
  - Sistrunk surgery



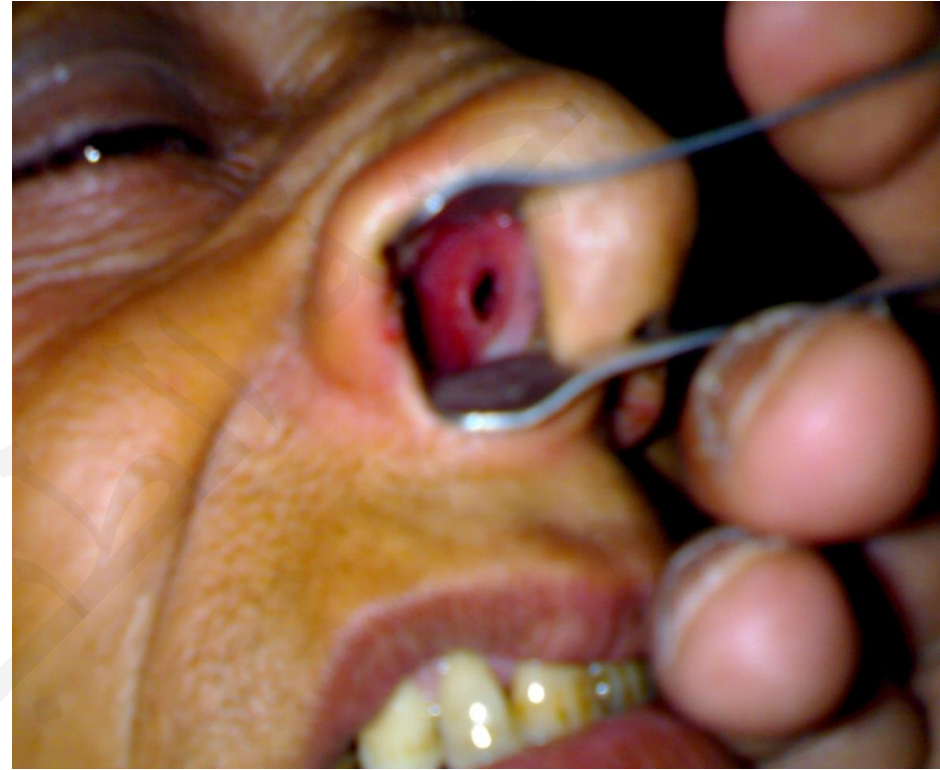**This patient had tonsillectomy before one week.**

- What can you see?
  - Normal fibrinoid reaction after tonsillectomy
- Give 2 indications for tonsillectomy.
  - Recurrent attacks (*7 in a year, 5 per year for 2 years, or 3 or more per year for 3 years*)
  - *Tonsillitis complicated with peritonsillar abscess*

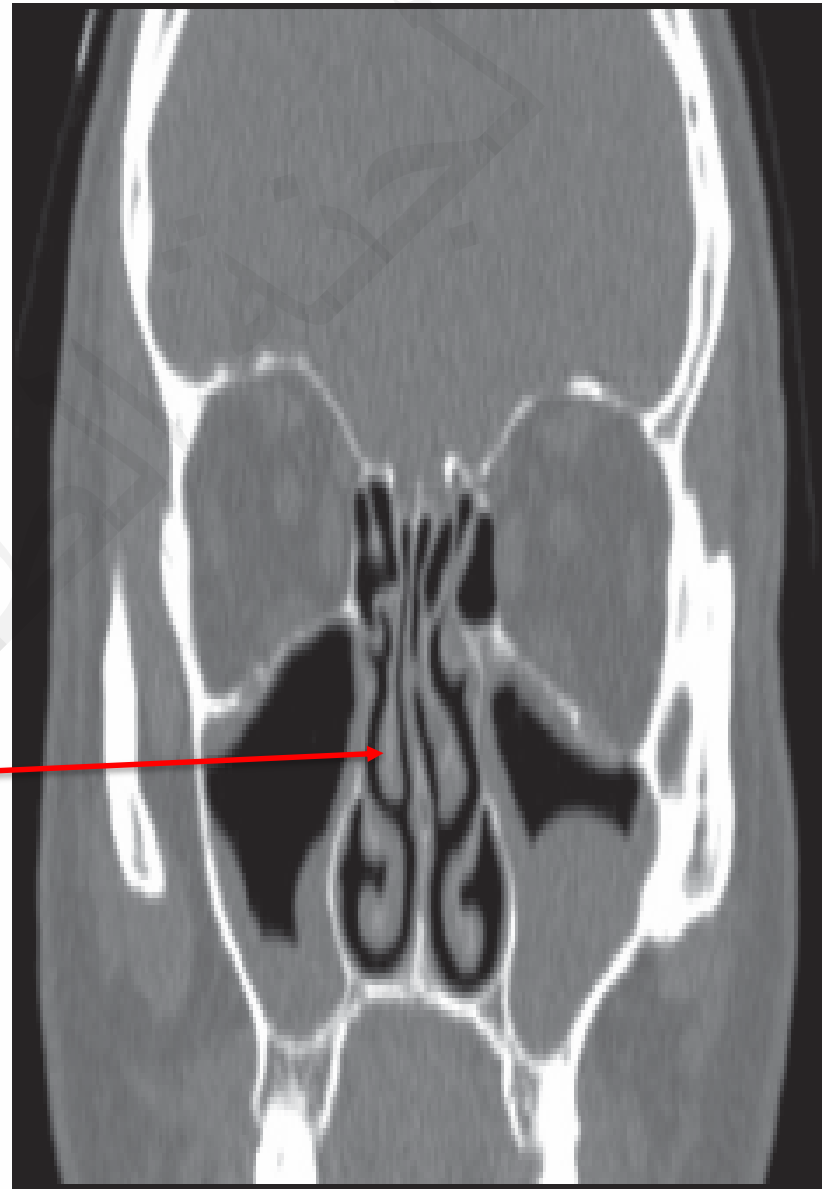



- What is your diagnosis?
  - Nasal septum perforation
- Give two non-iatrogenic causes.
  - Foreign body
  - Warfarin

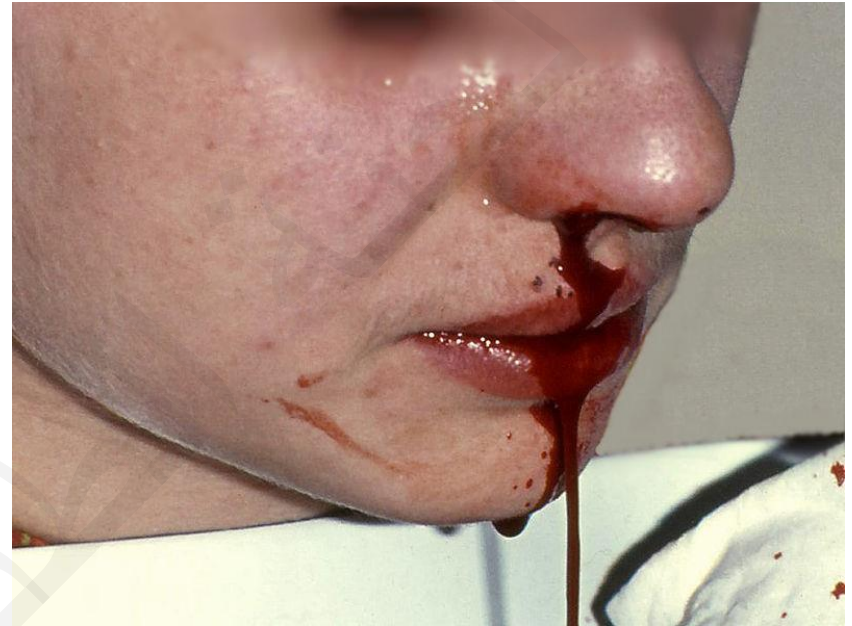

- What is your diagnosis?
  - Acute maxillary sinusitis
- If refractory to medical management, what's the surgery used to treat this case ?
  - FESS
- Complications ?
  - Myringosclerosis
  - Permanent perforation
- Most common cause of this disease?
  - Adenoid hypertrophy
- Arrow?
  - Right middle turbinate





- How will you treat this patient, first thing to do?
  - Trotter's maneuver
- Surgery to do ?
  - Anterior ethmoidal artery ligation




## **In restaurant a man develops choking.**

- First thing to do?
  - Heimlich maneuver
- If patient becomes unconscious, what to do?
  - Cricothyroidotomy
- Give 2 indications & 2 complications of tracheostomy tube.
  1. A-Mechanical obstruction of the upper airways.  
B-Retention of bronchial secretions  
C-Protection of tracheobronchial tree in patients at risk of aspiration.  
D-Respiratory failure.  
E-Elective tracheostomy, e.g. during major head and neck surgery a tracheostomy can provide/improve surgical access and facilitate ventilation.
  2. Dislodgment, Obstruction, Pneumomediastinum, Pneumothorax, Infection

# **Pulse Question Team**

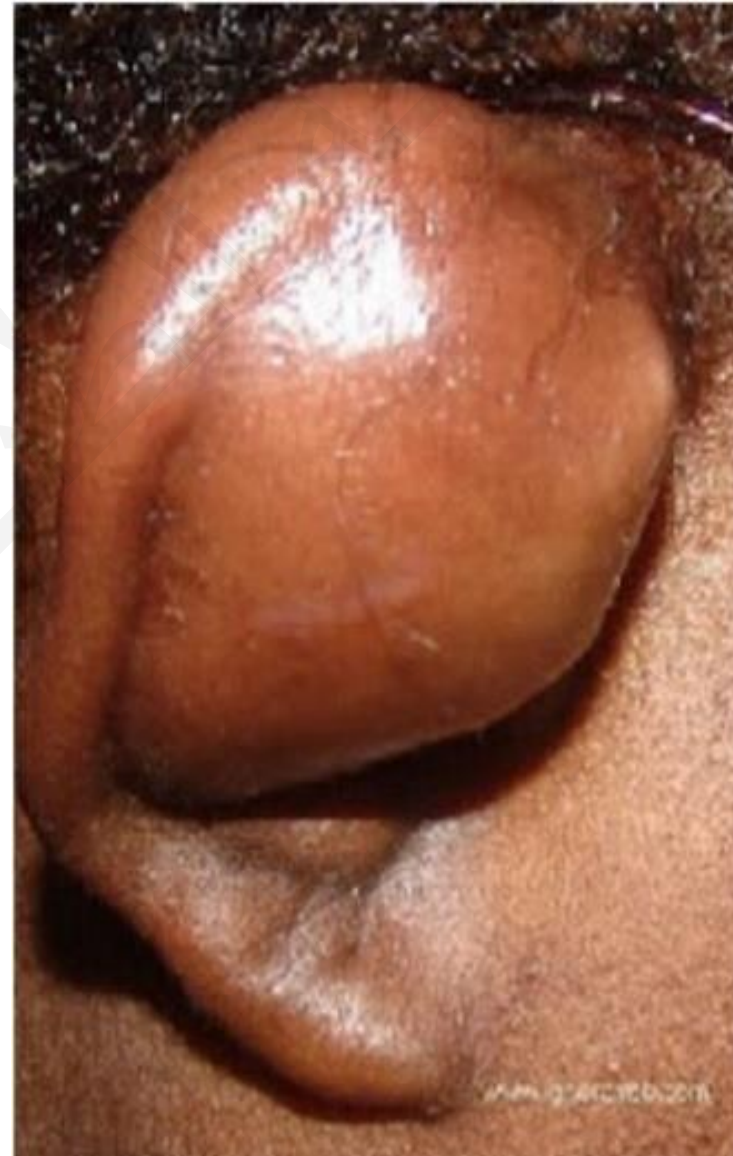## **(Maha Albadawi)**



# **ENT mini-OSCE**

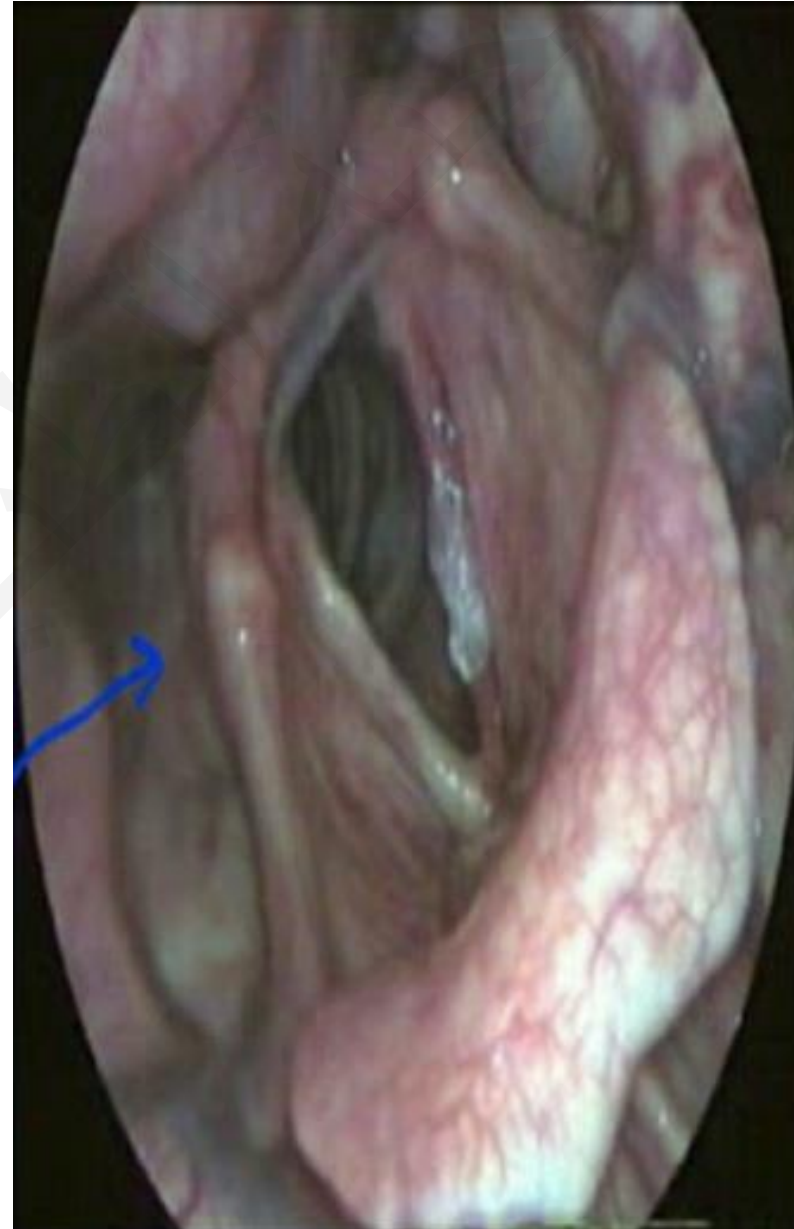## **Group D7&D8**

- What's the diagnosis ?  
Auricular Hematoma
- Management?  
Incision and drainage
- Complications?  
Cauliflower ear



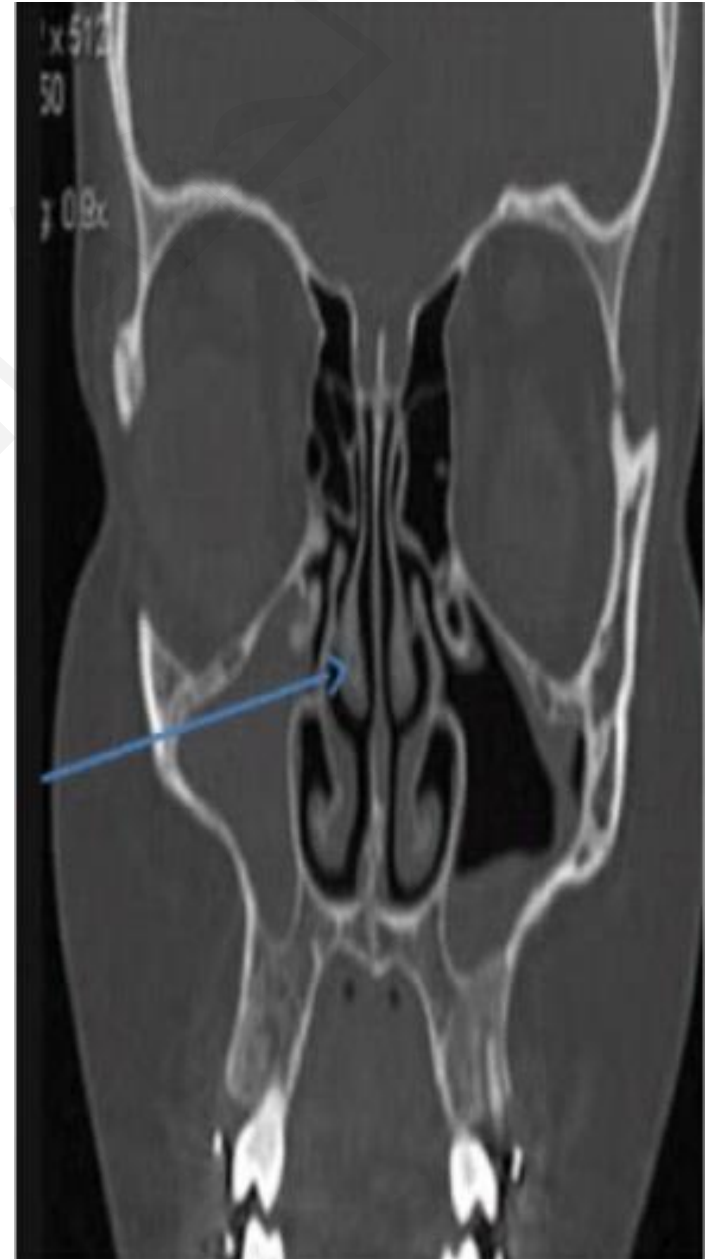
## Hx. of laryngeal cancer.

- What is the most common histopathological type?  
SCC
- Mention two risk factors?  
GERD and Smoking
- Arrow?  
Pyriform Sinus



**Hx. of 10 days fever and yellow rhinorrhea.**

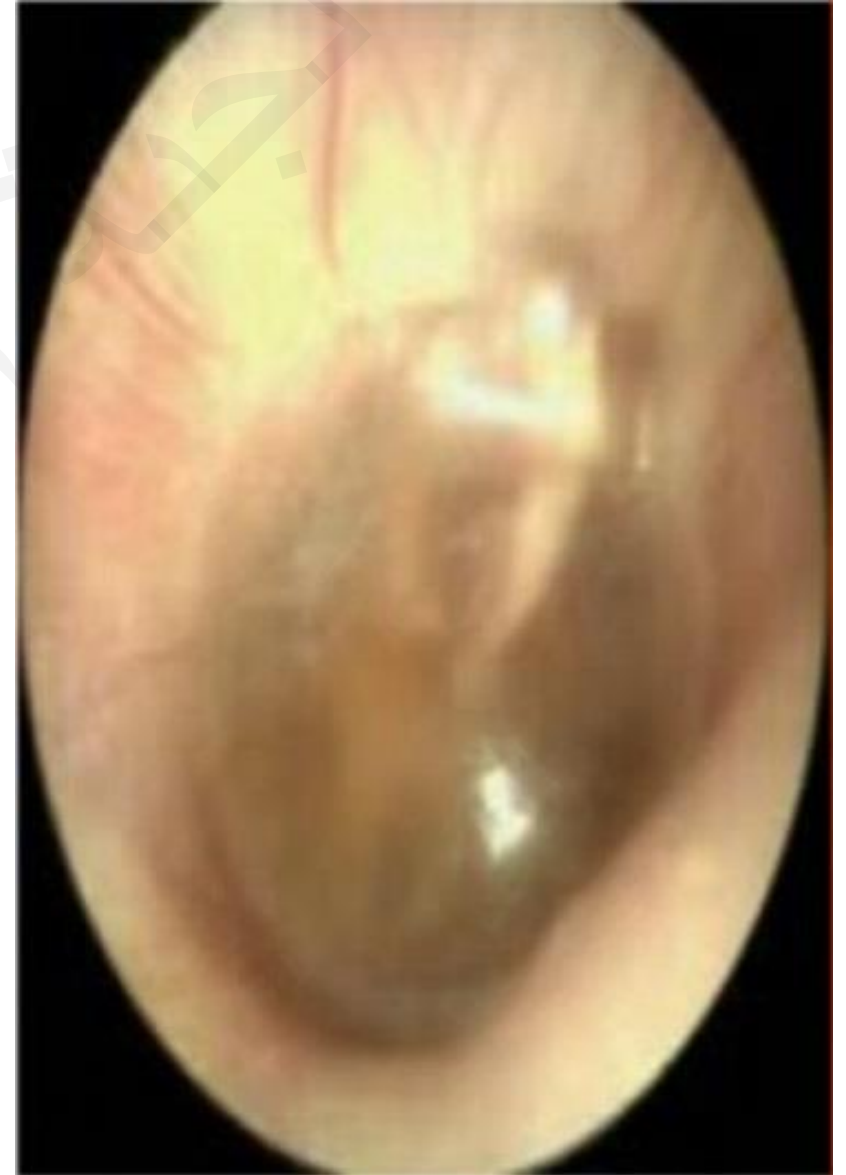- What is your diagnosis?  
Acute infective rhinosinusitis
- Arrow?  
Right middle turbinate
- Surgery of refracted case?  
FESS





**Hx. Of 6 years old child with bilateral dull tympanic membrane and delayed speaking.**

- What is your diagnosis?  
OME
- Surgery?  
Myringotomy and ventilation tube
- What is the type of tympanometry?  
Type B
- Significant of recurrent acute otitis media?  
Rule out hypogammaglobulinemia

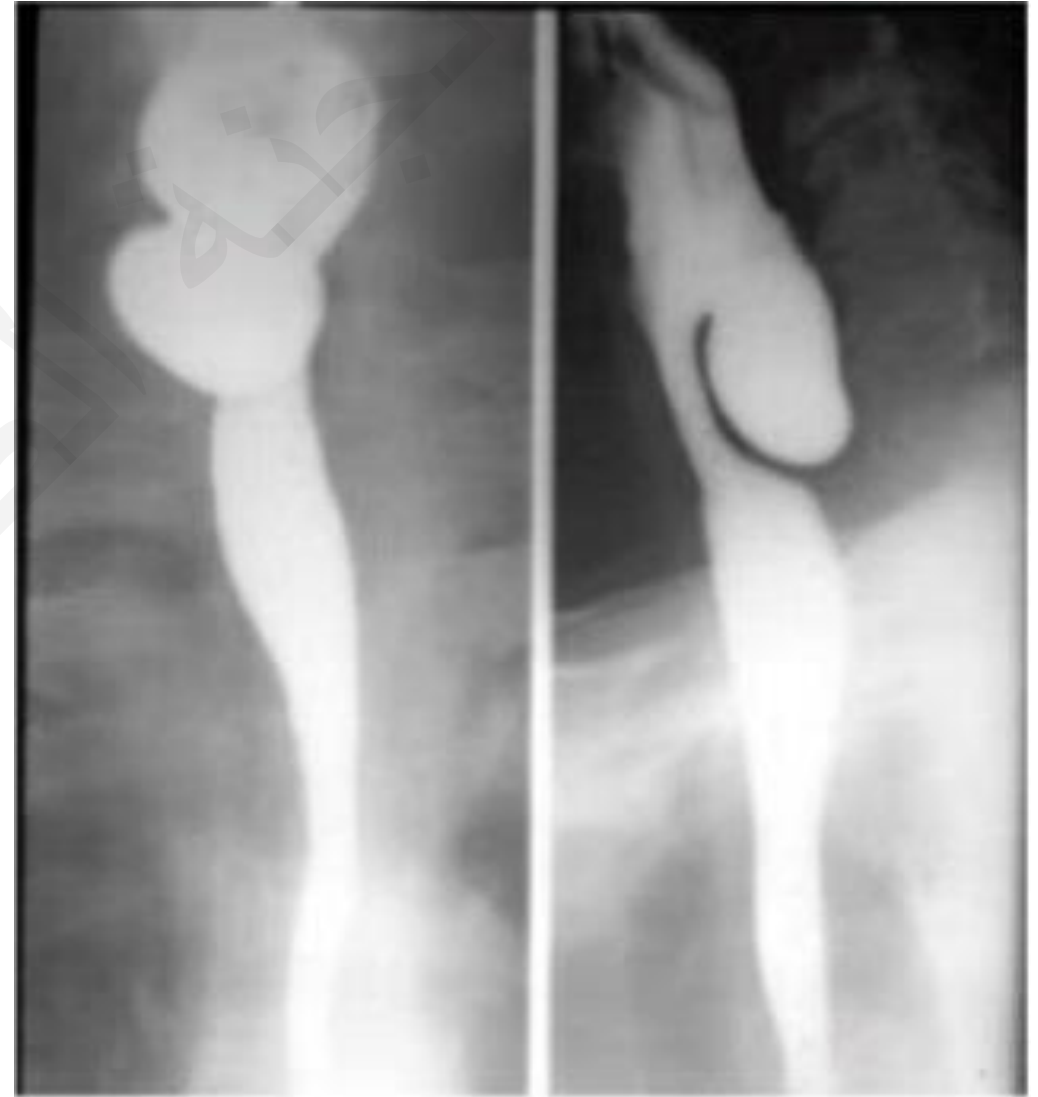



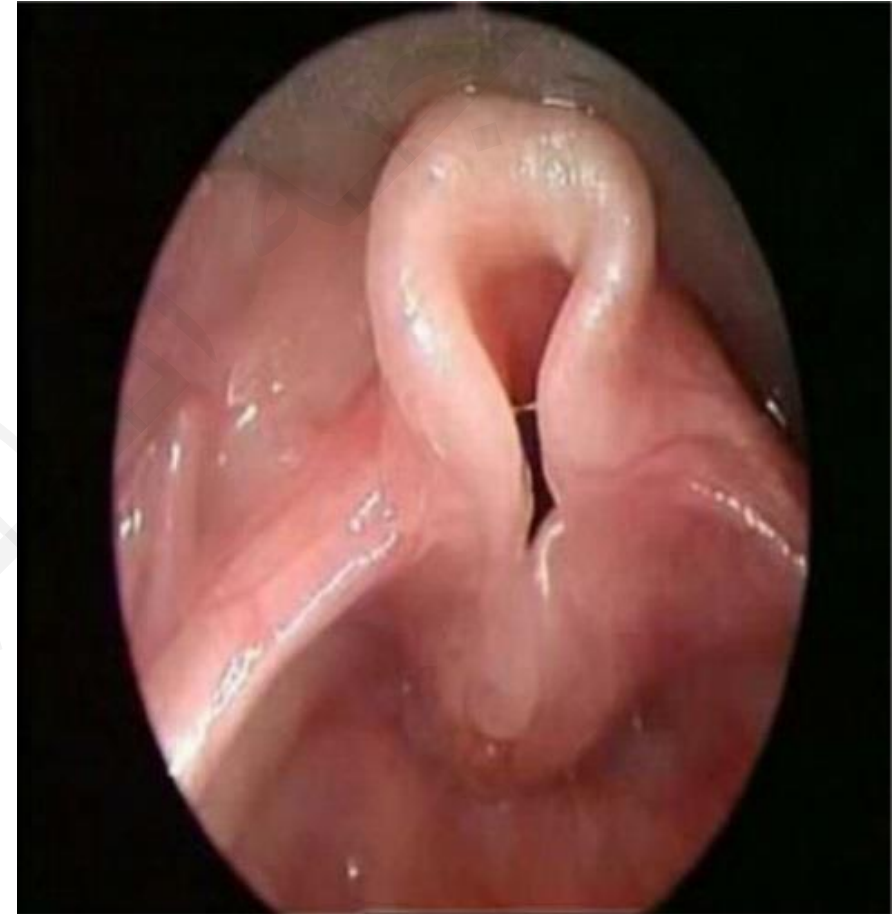**There is a pic. of bee in ear but the pic. was unclear, history of buzzy and tinnitus.**

- First line of management?  
Kill insect with alcohol
- Complications?  
TM perforation

- What is your diagnosis?  
Zenkers Diverticulum
- Site of pathology?  
Killians Dehiscence

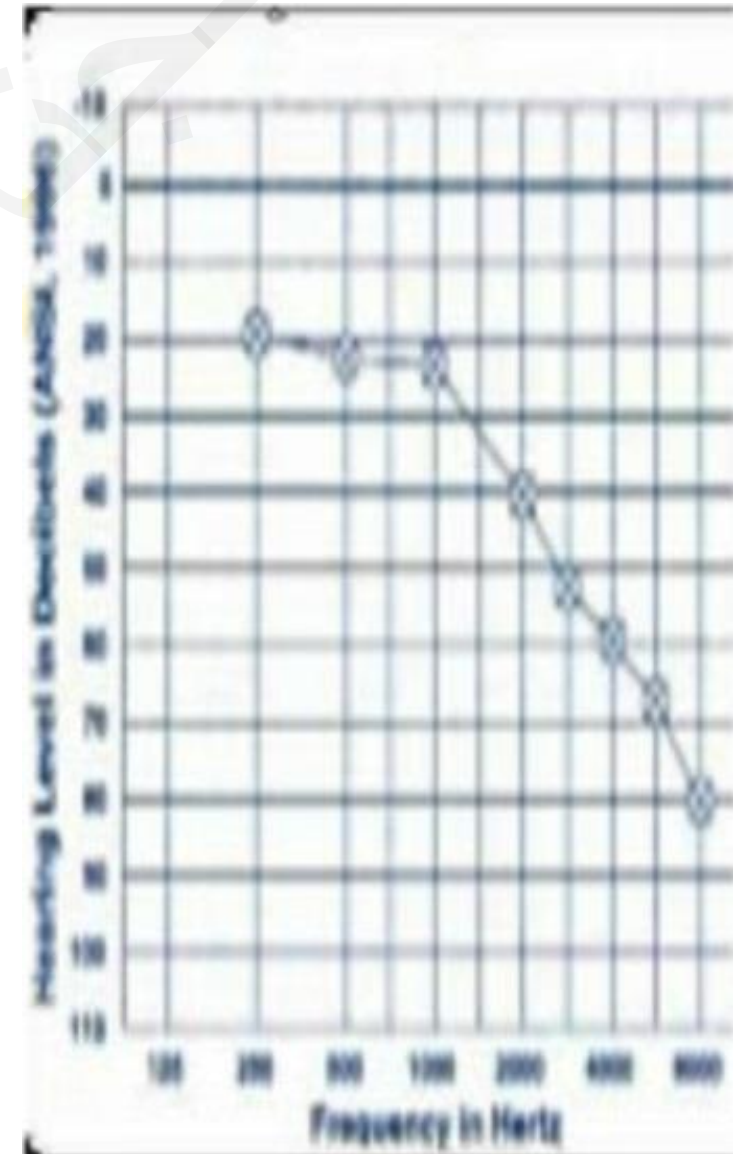


- What is your diagnosis?  
Laryngomalacia
- Sign?  
Omega

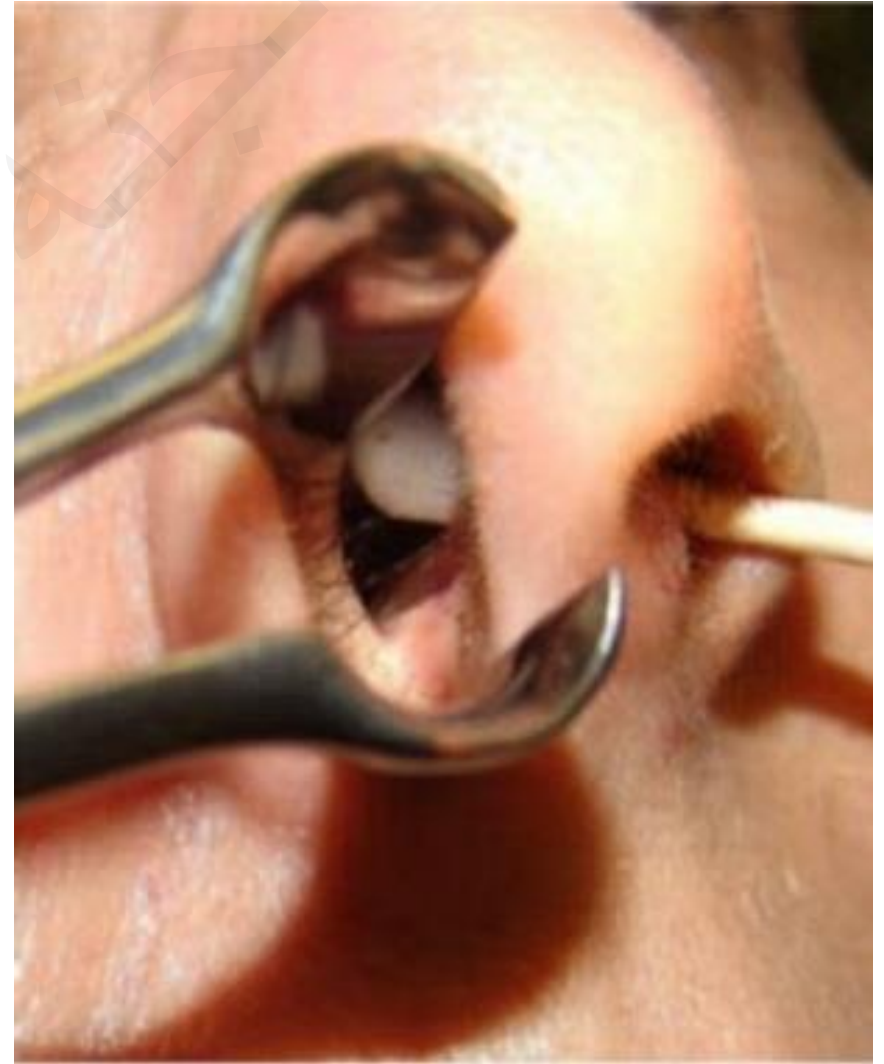

**65 year old man is complaining from bilateral progressive hearing loss and his audiogram showed this .**

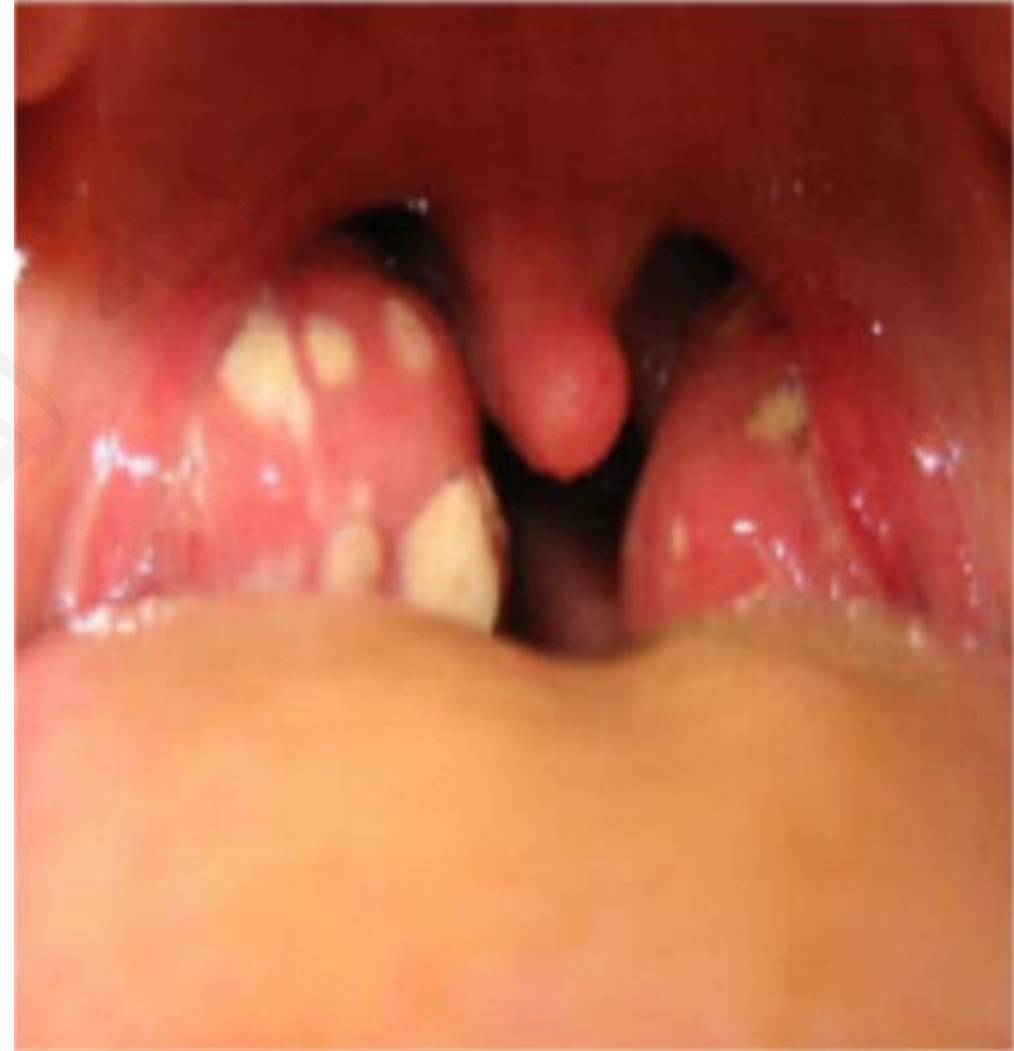- How do you treat?  
Hearing Aids
- Congenital hearing loss, iris pigmentary abnormality, dystopia canthorum, hair hypopigmentation.. What is the name of this syndrome?  
Waardenburg syndrome




- What is your diagnosis?  
Septal perforation
- Mention two non-traumatic causes?
  - Sarcoidosis
  - Chronic infection(TB)



- What is the most common bacterial cause?  
Group A beta hemolytic strep. Pyogenes
- Mention two aseptic complications?  
Scarlet fever  
Rheumatic fever
- What is the most common cause of  
secondary bleeding after tonsillectomy?  
Infection



**Pulse Question Team**  
**(Lina Abunameh & Shereen Hijjawi)**

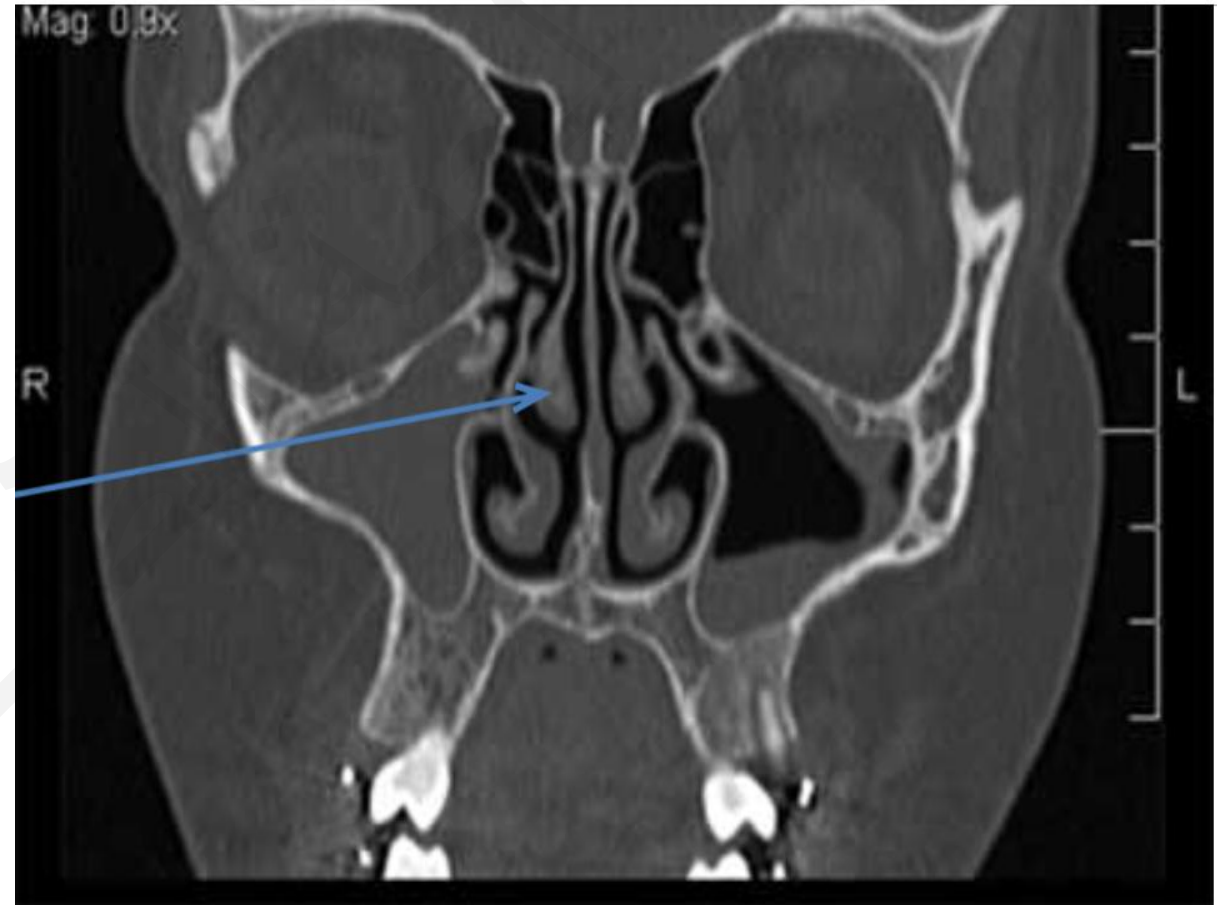


# ENT mini-OSCE

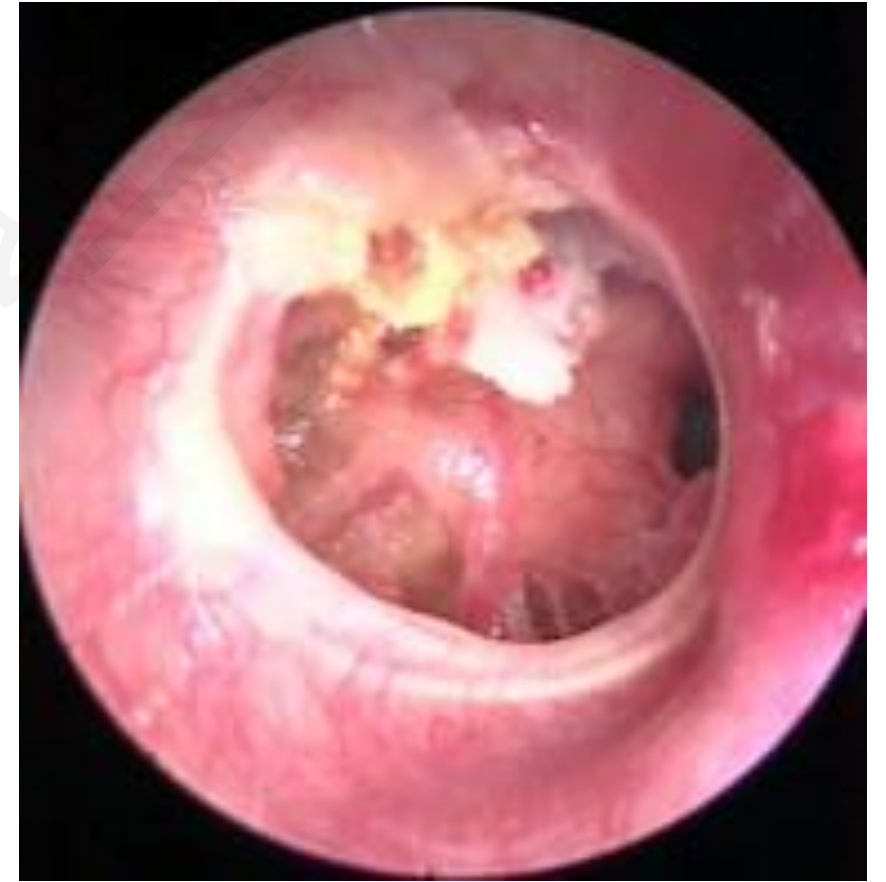Group D3&D4



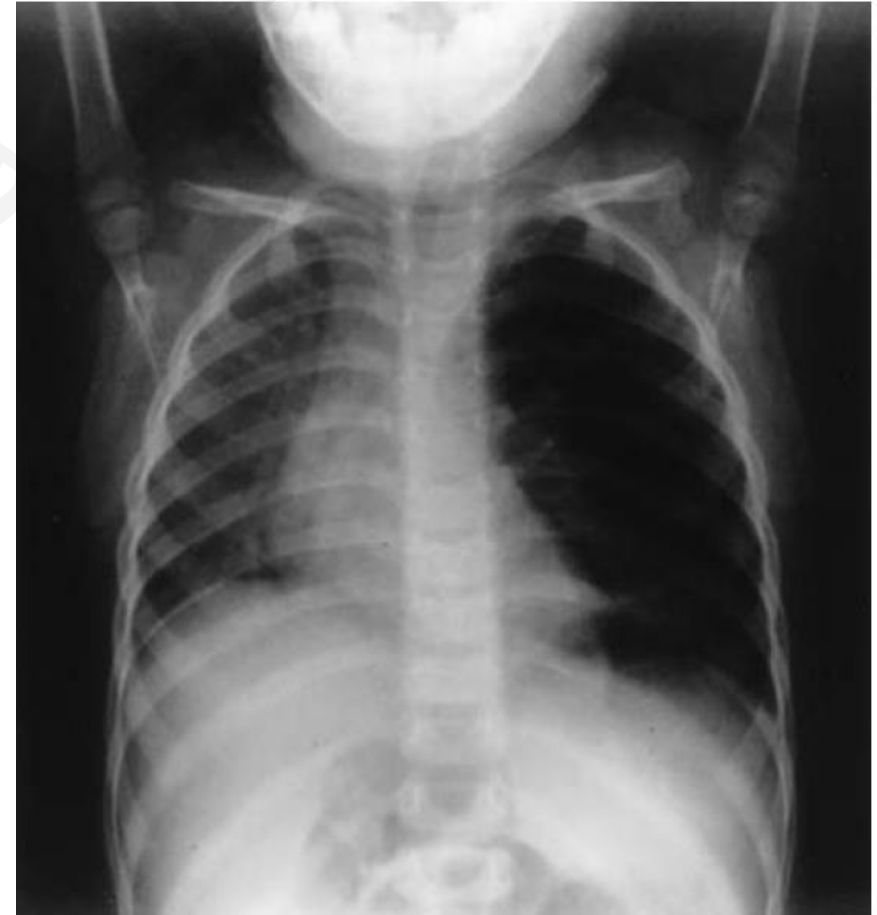- What is the diagnosis ?
  - Acute infective rhinosinusitis
- Mention 2 Intra orbital complications?
  - Orbital cellulitis, cavernous sinus thrombosis
- Name the structure that the arrow points to?
  - Right middle turbinate



- What is the diagnosis?
  - Cholesteatoma
- Tympanometry ?
  - Type B
- What is the management ?
  - Aural toilet and keeping the ear dry
  - Tympanomastoidectomy (tympanomastoid surgery)



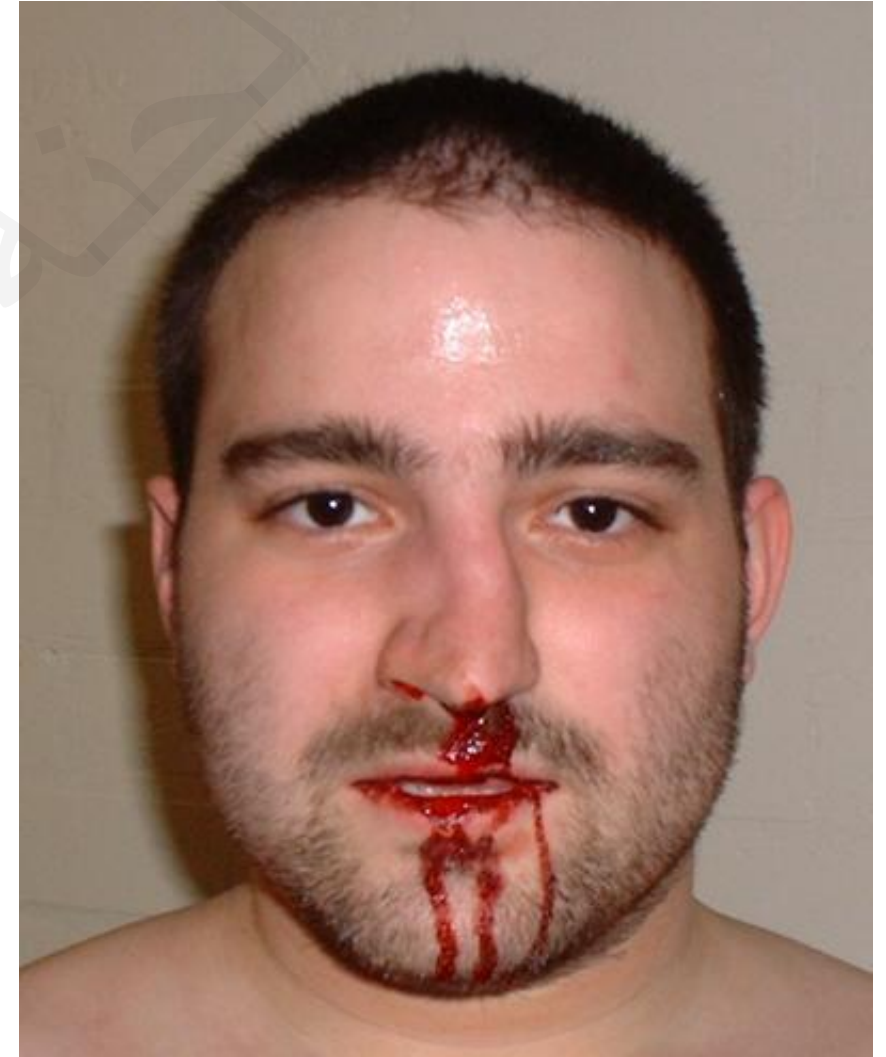- What is the diagnosis?
  - Foreign body => aspiration/inhalation
- Appropriate line of management?
  - Bronchoscopy
- A possible complication?
  - Lung collapse/ pneumonia...etc.



## A picture of vocal cords and the patient is a teacher.

- What is the diagnosis?
  - Singer's nodule / vocal cord nodule
- Describe the line of management?
  - Voice rest , speech therapy

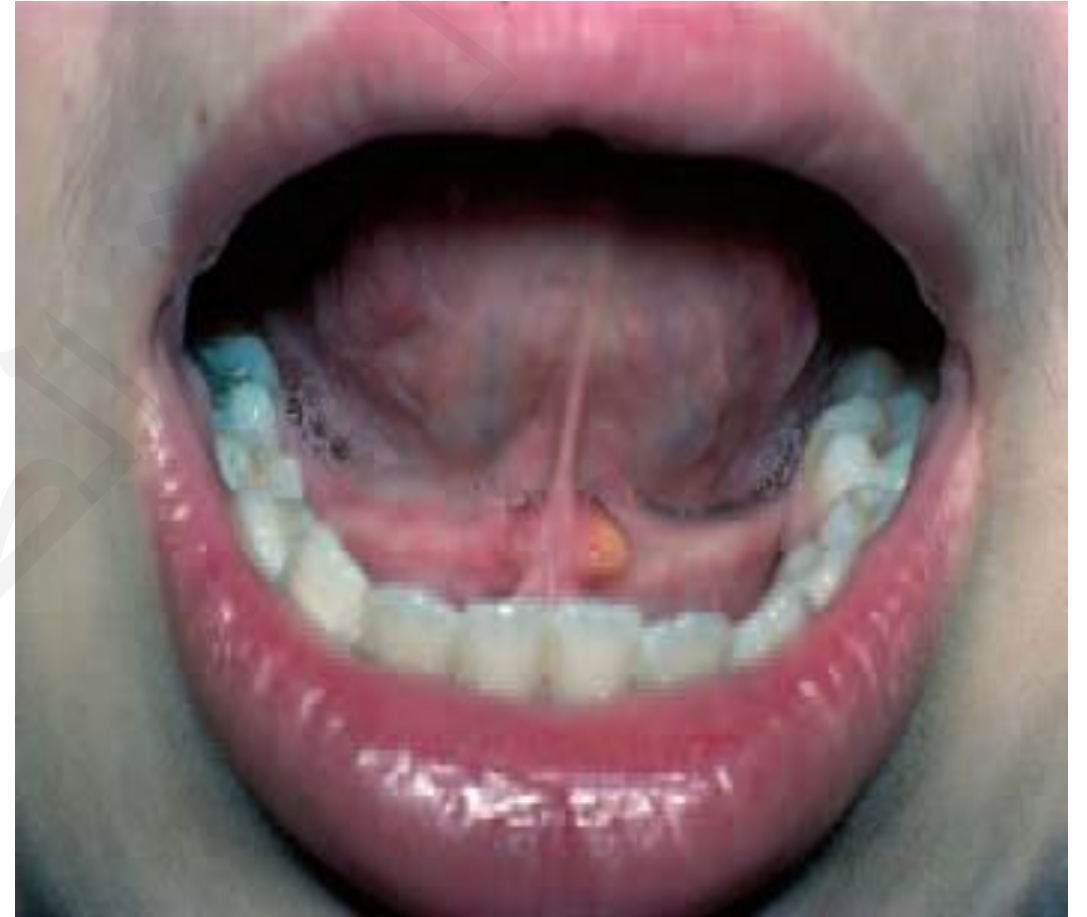- What is the first line of management?
  - Trotter's maneuver
- Mention 2 of the non-traumatic causes?
  - HTN, Osler Weber Rendu syndrome (HHT)
- Mention a surgery for treatment?
  - Ligation of the anterior ethmoidal artery/  
carotid artery ligation



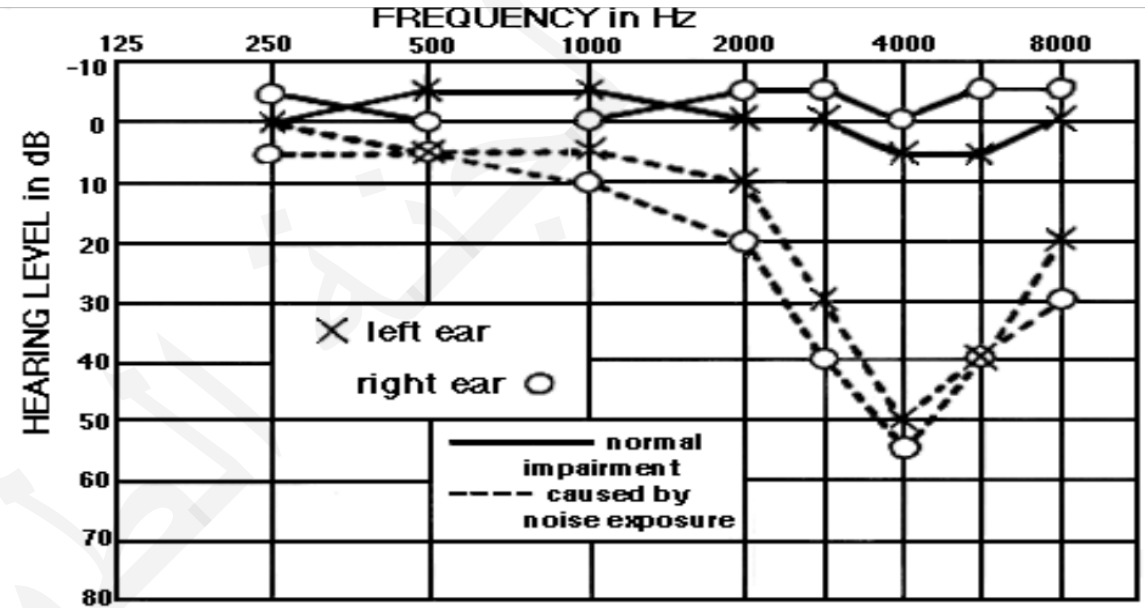
- What is your diagnosis?  
-Laryngomalacia
- What is the sign in the picture?  
-Omega sign



- What is the diagnosis?
  - Sialolithiasis/ salivary calculus
- Imaging study?
  - Sialogram/ CT scan
- Where does the stensen's duct open?
  - Upper second molar tooth

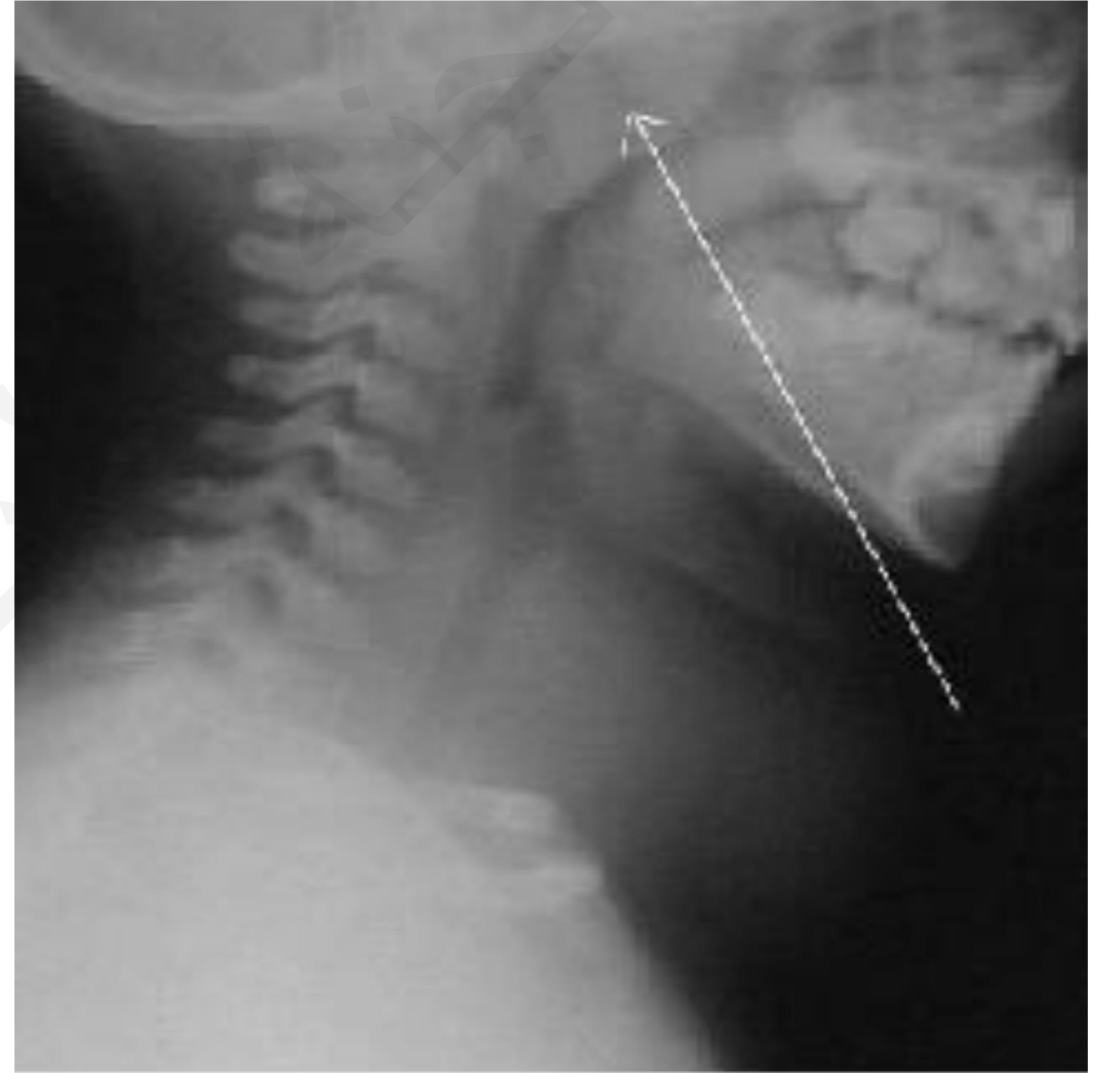

- What is your diagnosis?  
-Presbycusis
- What is the treatment?  
-Hearing aids
- Rennie test for this patient?  
-Positive
- To diagnose a patient with sleep apnea and how many attack he has what the test you use?  
-Poly somnography



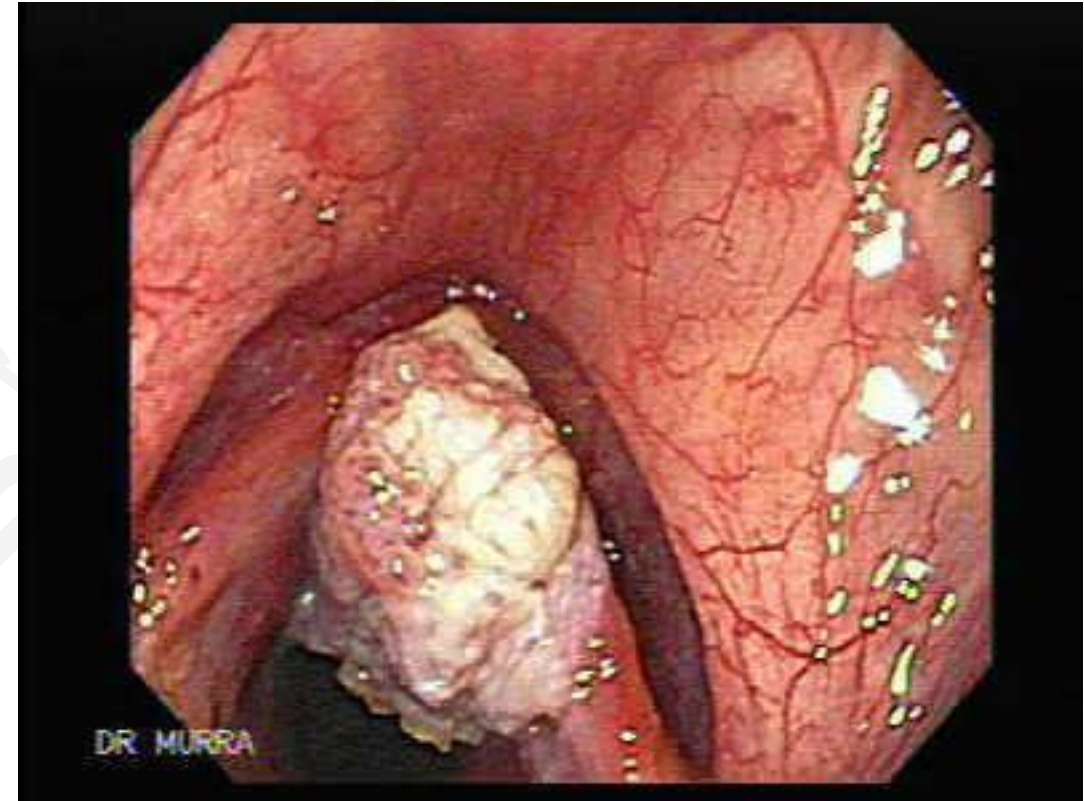


- What is your Dx?
  - Adenoid hypertrophy
- Mention two contraindications for adenoidectomy ?
  - Cleft palate , acute infection , bleeding tendency




A patient complaining of hoarseness in voice, presented with this picture.

- What is your most likely diagnosis?
  - Laryngeal ca (most common type is SCC)
- Give 2 risk factors?
  - A-Smoking
  - B-Voice Abuse
- Asking the patient to say “eeee” examines, what movement of the vocal cords?
  - Adduction (in phonation)



**Pulse Question Team**  
**(Sally Al-Deseet & Farah Alhajjah)**



# ENT mini-OSCE

Group B5&B6

- What's the diagnosis ?

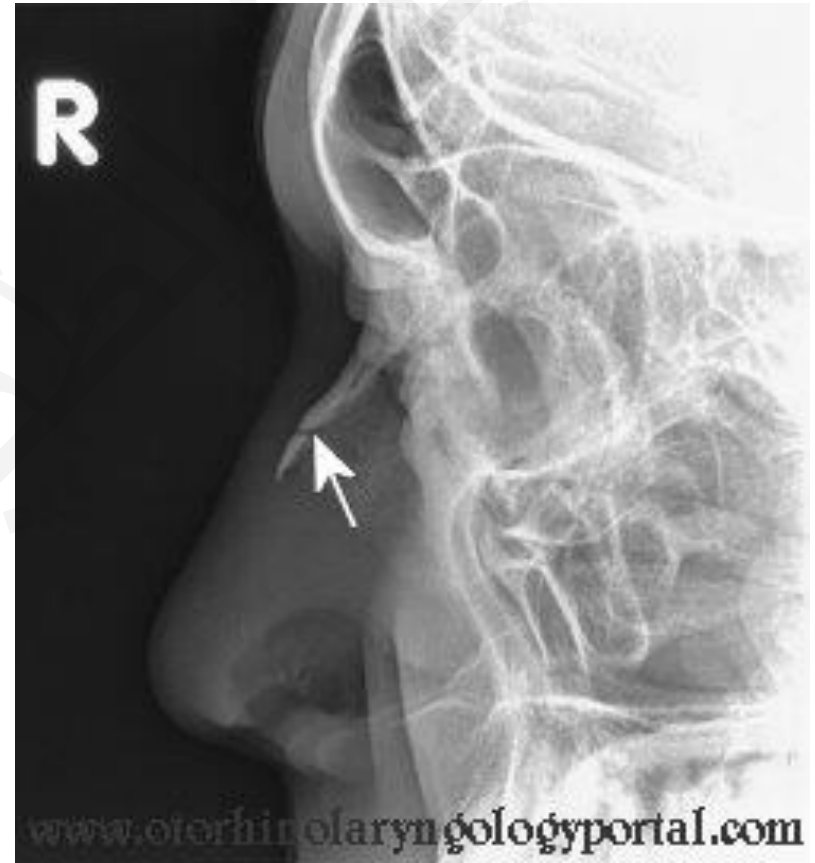Nasal bone fracture

- Next step after doing ABC ?

Nasal reduction

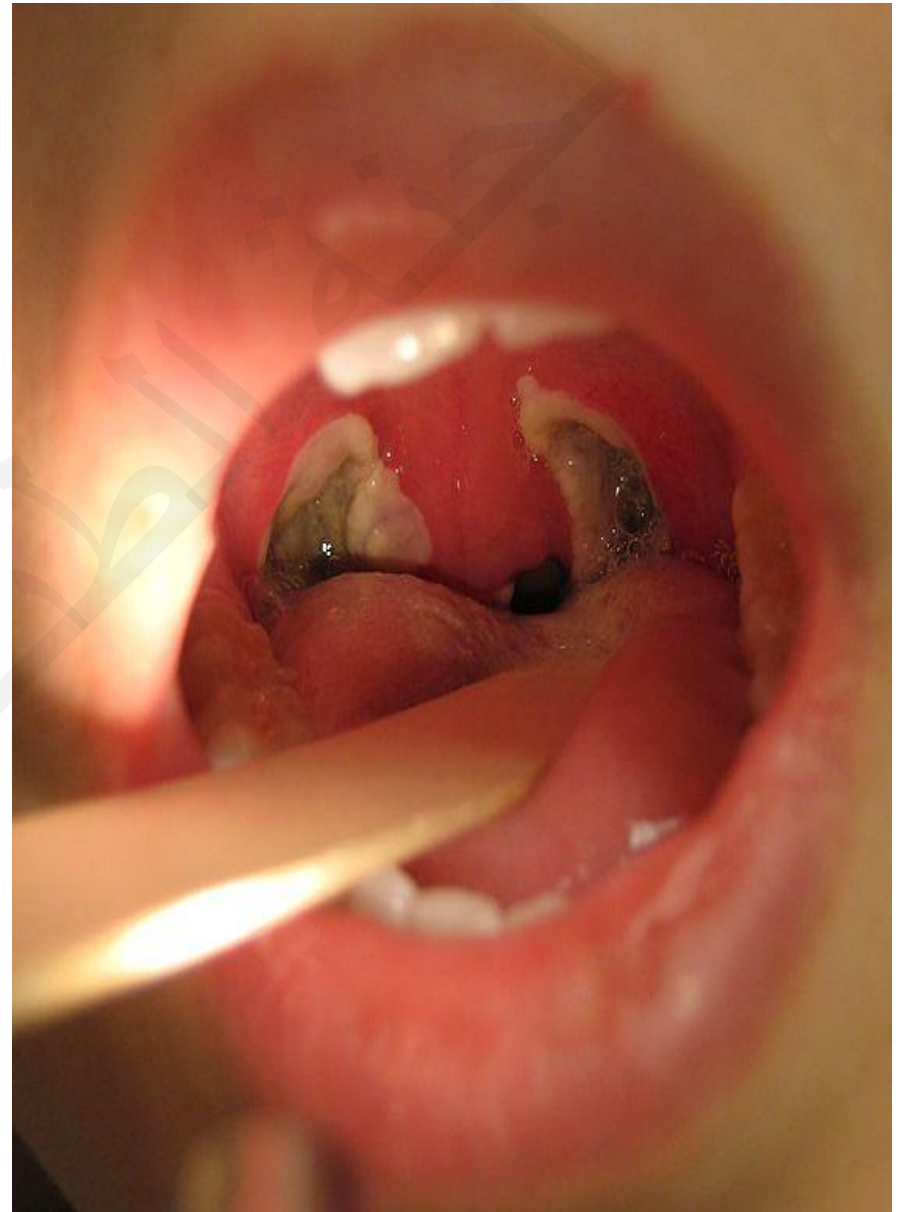
- What's the name of syndrome of recurrent epistaxis ?

Osler-weber-randu syndrome



This patient had tonsillectomy before one week:

- What can you see?  
Normal fibrinoid reaction after tonsillectomy
- Give two aseptic complication ?
  - Rheumatic fever
  - Scarlet fever



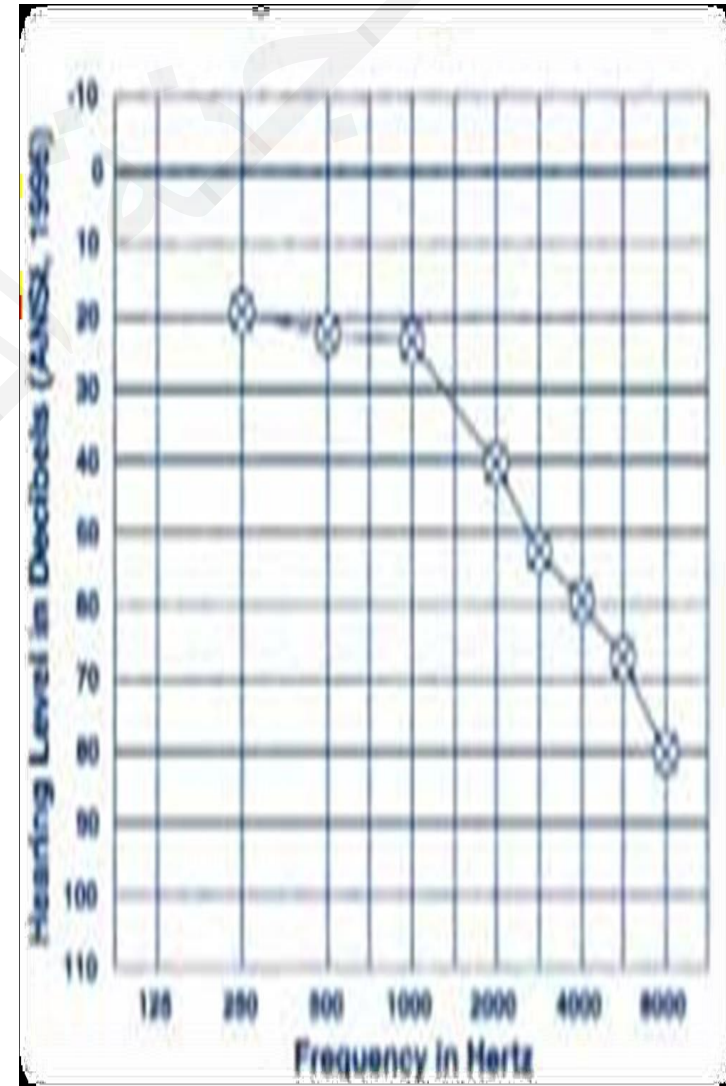
**75 year old is complaining from bilateral progressive hearing loss and his audiogram showed this .**

- how do you treat ?

Hearing aid

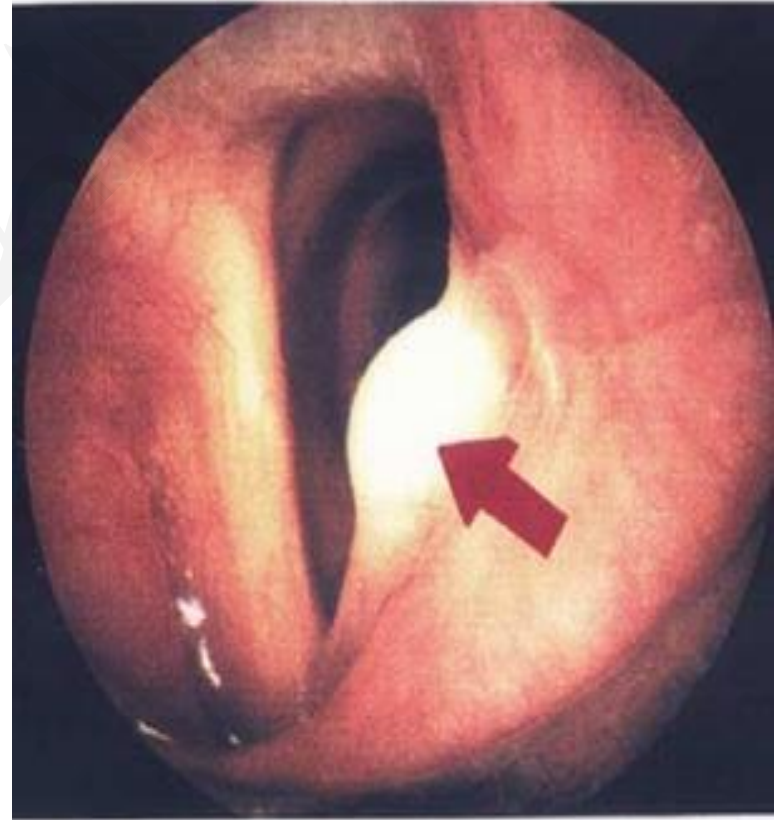
- Antibiotics known to cause ototoxicity ?

Gentamycin .....



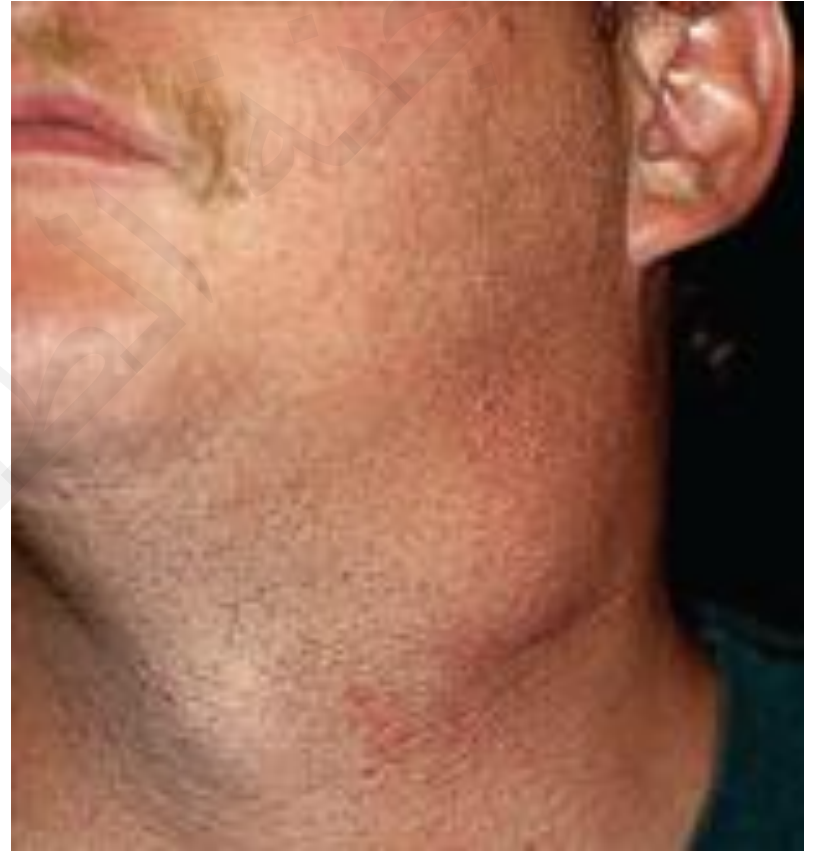

- Q about laryngeal ca
- Most common histological type ? SCC
- ttx ? Radiotherapy

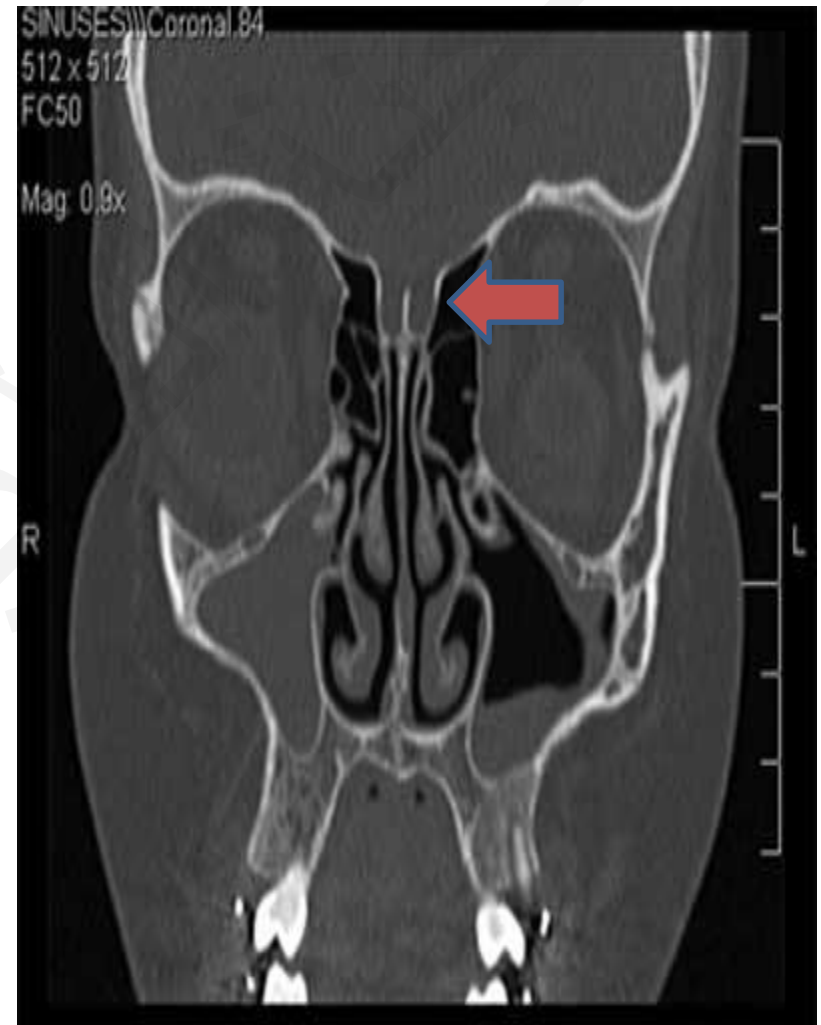




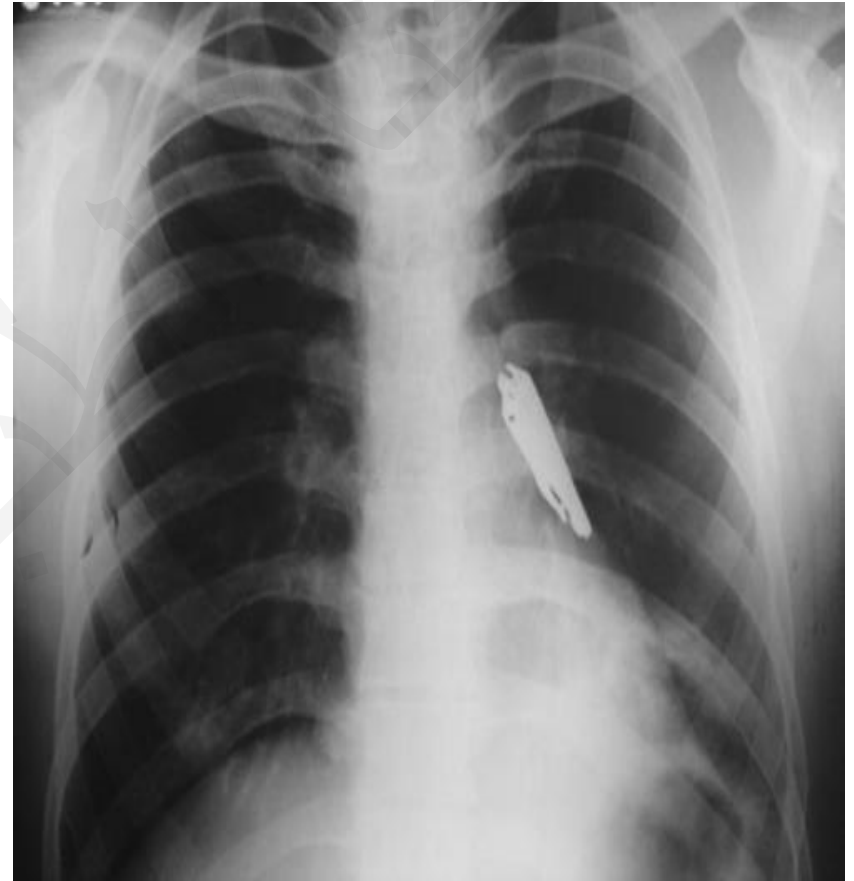- Mention 2 DDx
  - Lymphadenitis
  - Branchial cyst
- First test ? FNA



- Q about acute infective rhinosinusitis
- What's the name of this structure ?
  - Left ethmoid sinus
- Give example about anti-leuktriene drugs ?
  - ziferleukast
- Give one intracranial complication?
  - Brain abscess



- what do you want to do next ?
  - Rigid bronchoscopy
- Complications ?
  - Lung collapse
  - Pneumothorax



- Mention one indication for using it ?

-OME

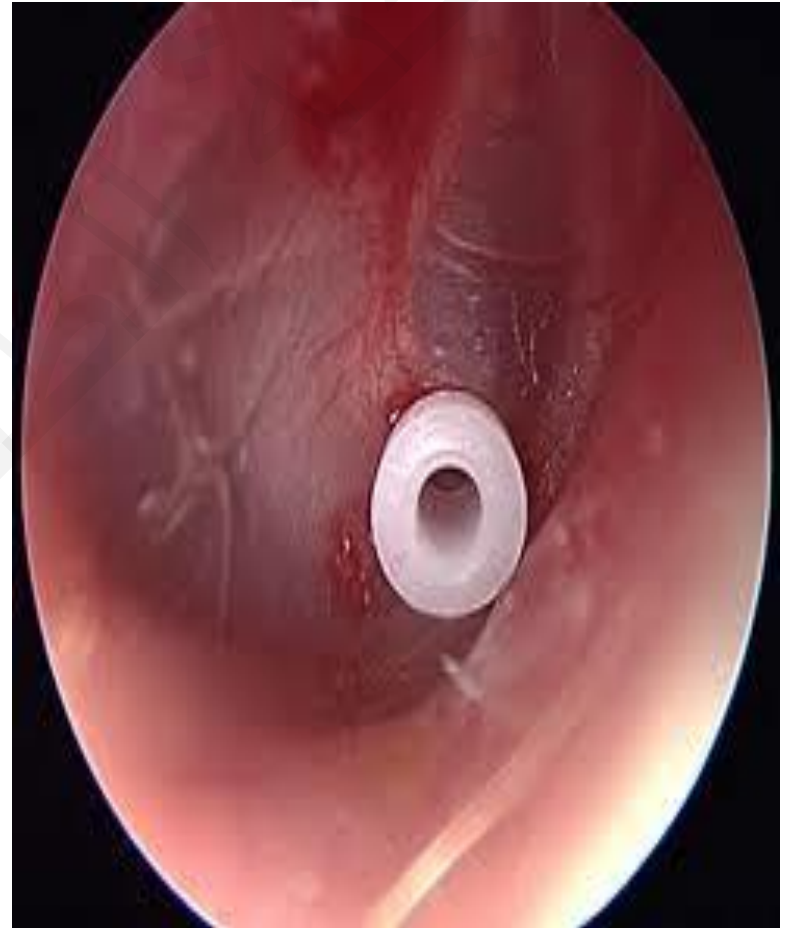
- Complications ?

-Myringosclerosis

-Permanent perforation

- Most common cause of this disease?

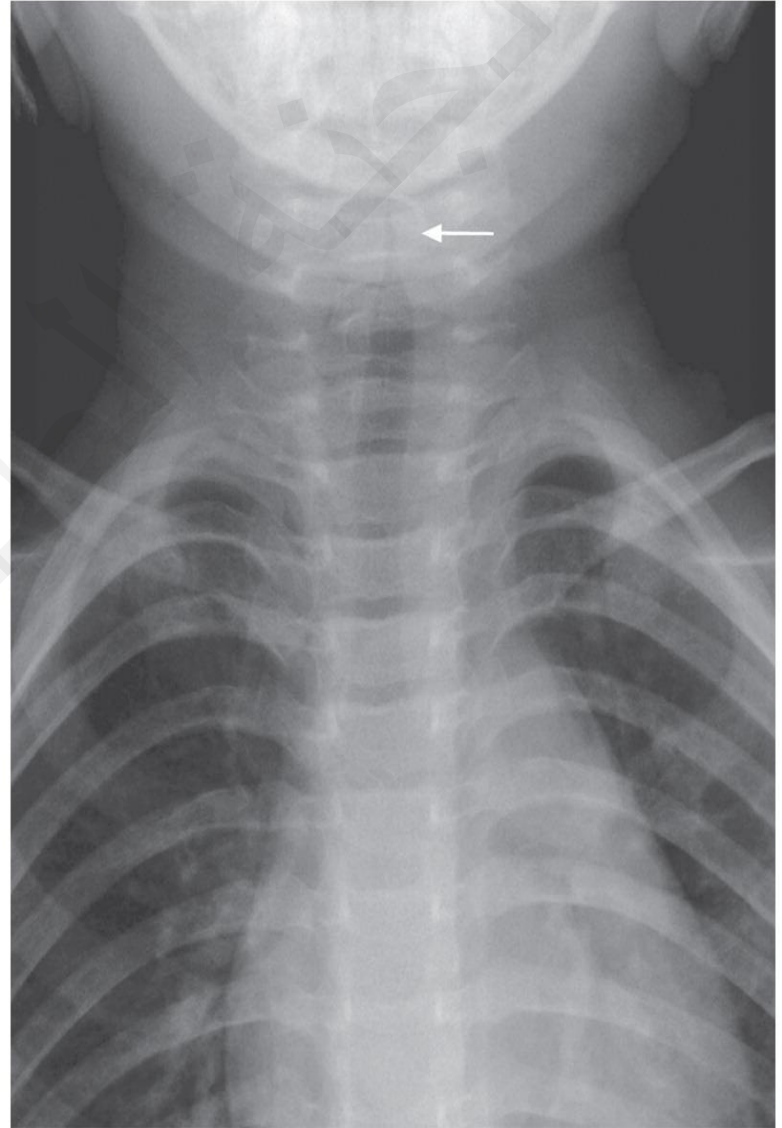
-Adenoid hypertrophy



- Q about impacted wax
- Name this procedure ?
  - ear syringing procedure
- Give 2 complications ?
  - TM perforation
  - Infection
  - Bleeding
- On tympanometry ?
  - Type b



- Child with stridor and tachypnea .....( about croup )
- Name this sign?
  - Steeple sign
- Cause?
  - parainfluenza virus
- Management?
  - Racemic nebulizer (3 nebulizers, 30 minutes between each) + steroids



# **Pulse Question Team**

## **(Safa Hussein)**

# ENT MINIOSCE

Group A1/A2 2016



# Q1

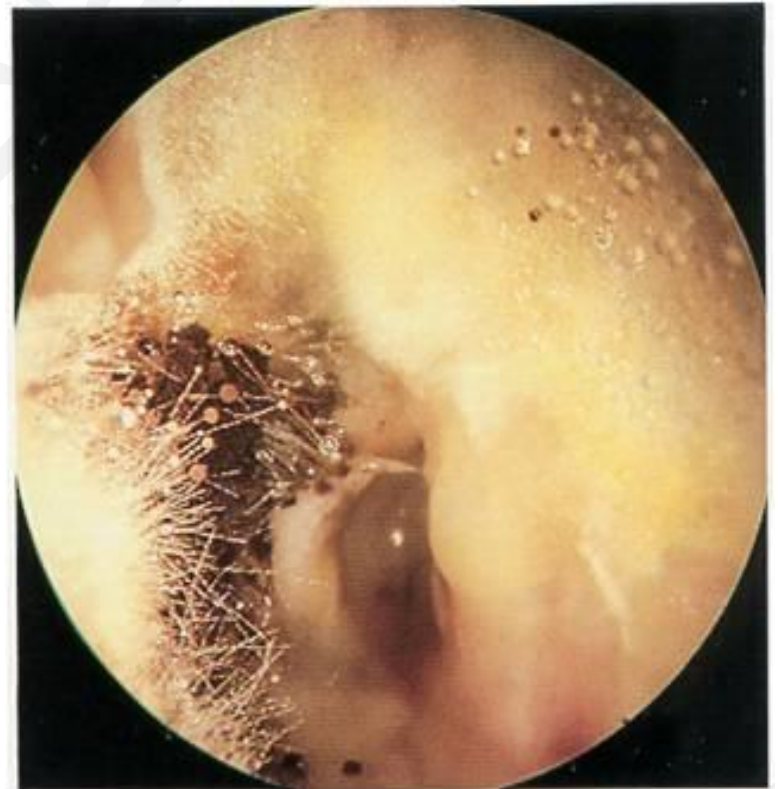- You were having a meal at a restaurant and suddenly someone starts choking
  1. What maneuver are you going to perform ?
  2. The person became cyanosed and lost consciousness what's the appropriate next step ?

# Answers

1. Heimlich's maneuver
2. Cricothyroidotomy

## Q2

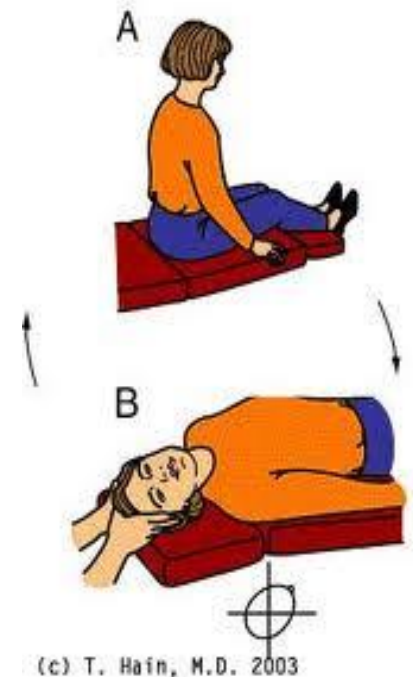
- What's the diagnosis ?
- Mention 2 lines of management ?



1. Otomycosis ( aspergiles niger )
2. Aural toilet and keep the ear dry
3. Topical antifungals

## Q3

- A patient develops vertigo for seconds on performing dix hillpike test to the left
1. What's the diagnosis ?
  2. What's the management ?
  3. What do you expect to see in the test ?

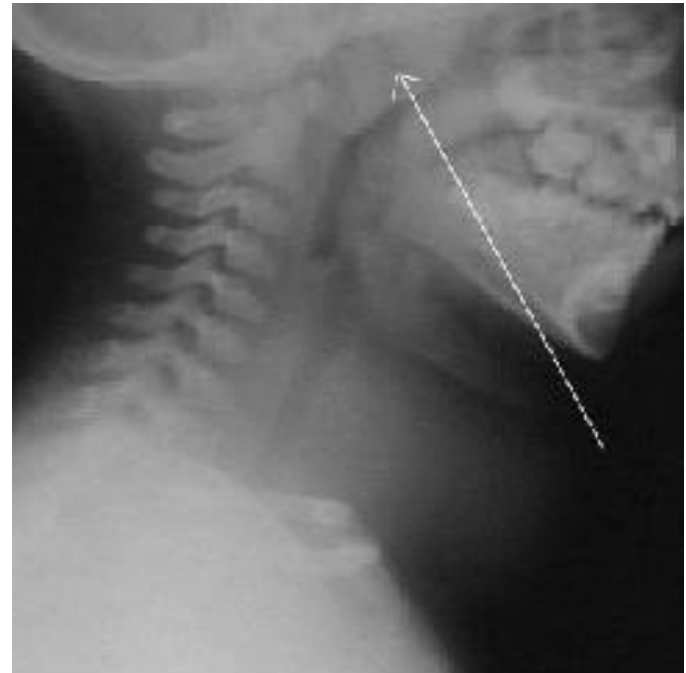

# Answer

1. BPPV
2. Epleys maneuver
3. Nystagmus

## Q4

- What's the diagnosis ?
- Mention one complication to this condition ?



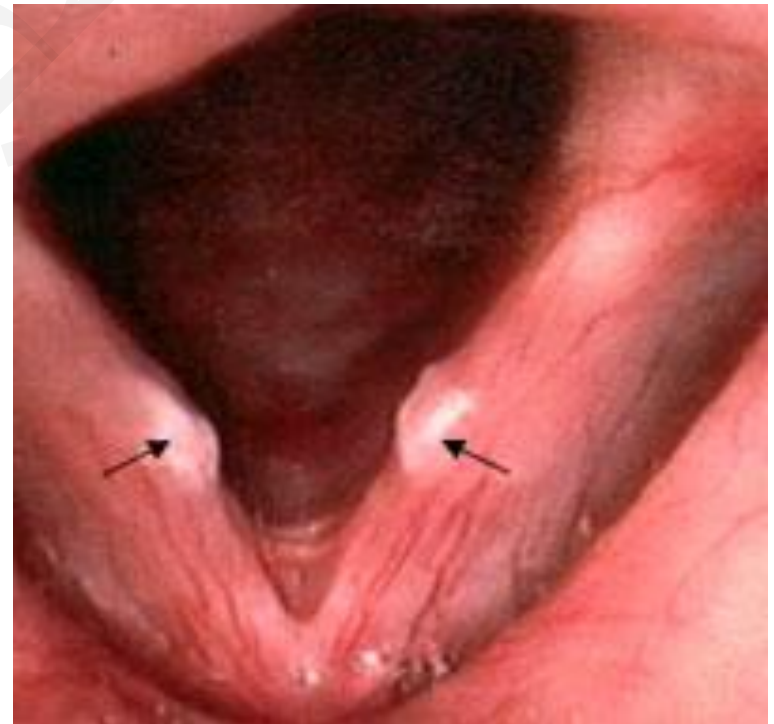
# Answers

1. Adenoid hypertrophy
2. OSA, snoring, mouth breathing.....



## Q5

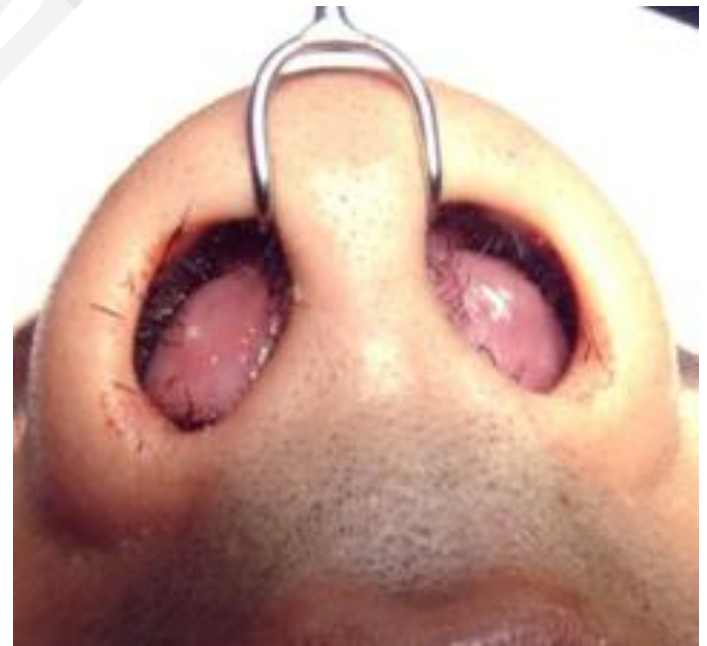- What's the diagnosis ?
- Mention one line of management ?



1. Bilateral vocal cord nodules
2. Vocal rest and speech therapy

## Q6

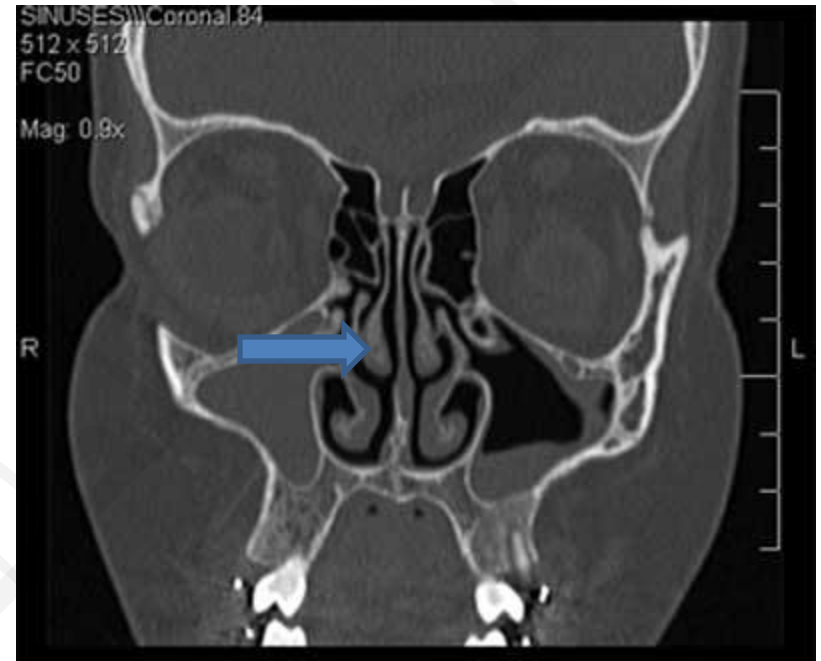
- A patient showed this on A. rhinoscopy few days after rhinoplasty
- What's the diagnosis ?
- Management ?



# Answers

1. Bilateral septal hematomas
2. Incision and drainage

Q7



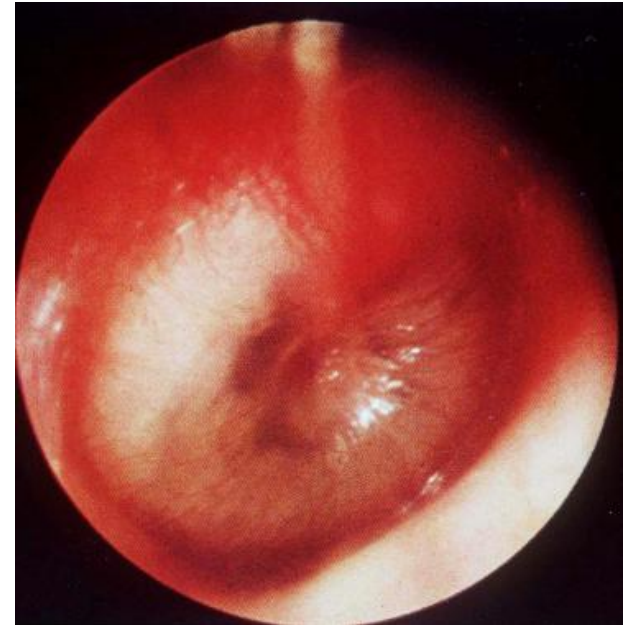
- What's your diagnosis ?
- Name the structure pointed at ?
- Mention 2 orbital complications ?
- Name the surgery performed If condition was refractory to medication ?

# Answers

1. Acute allergic rhinitis
2. Right middle turbinate
3. Orbital abscess, orbital cellulitis
4. FESS ( Functional endoscopic sinus surgery )

## Q8

- What's the diagnosis ?
- What's the most common cause of this infection ?
- What do you expect to find on tympanometry ?



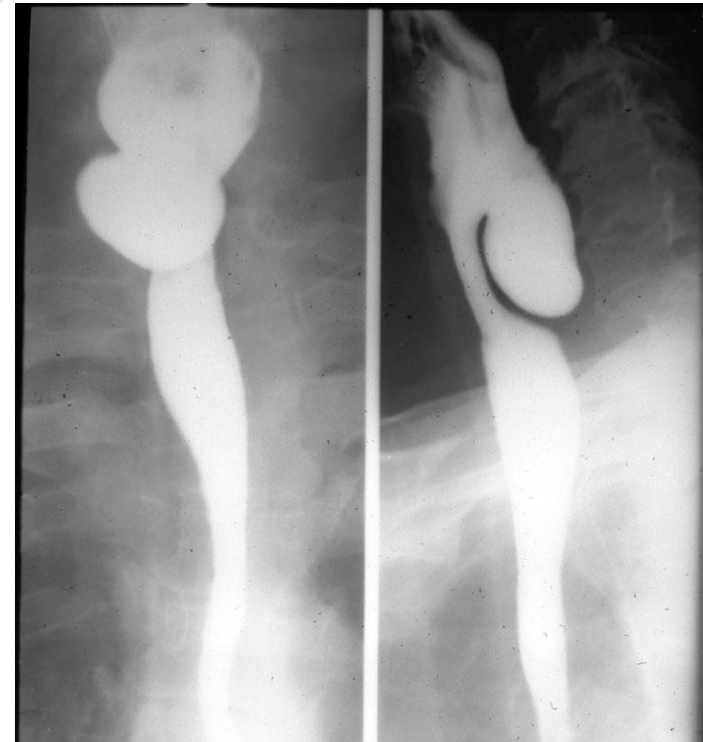
# Answers

1. AOM
2. Streptococcus pneumonia
3. Curve B



## Q9

- What's the diagnosis ?
- What's the site pathology ?

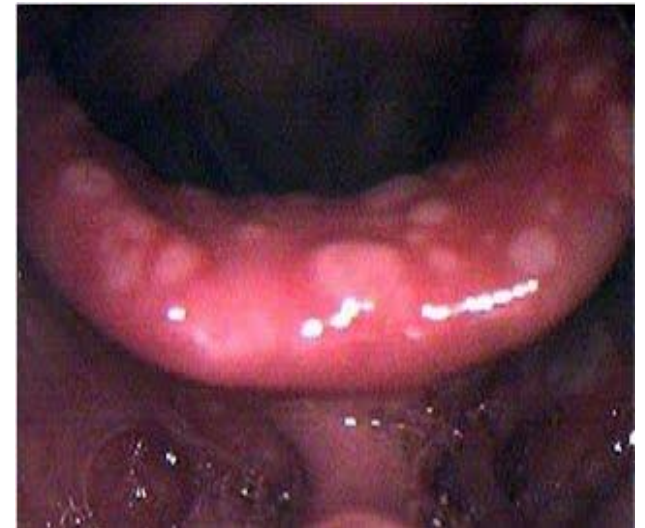

# Answers

1. Zenkers diverticulum
2. Killians dehiscence


## Q10

- A child presented with stridor, difficulty breathing, fever and continues drooling
- What's the diagnosis ?
- What's the most common causative organism ?
- Appropriate management ?



# Answers

1. Acute epiglottitis
2. Hemophilus influenza type B
3. Immediate intubation



# ENT miniOSCE Exam

## Groups A3+A4

Tuesday  
20-12-2016

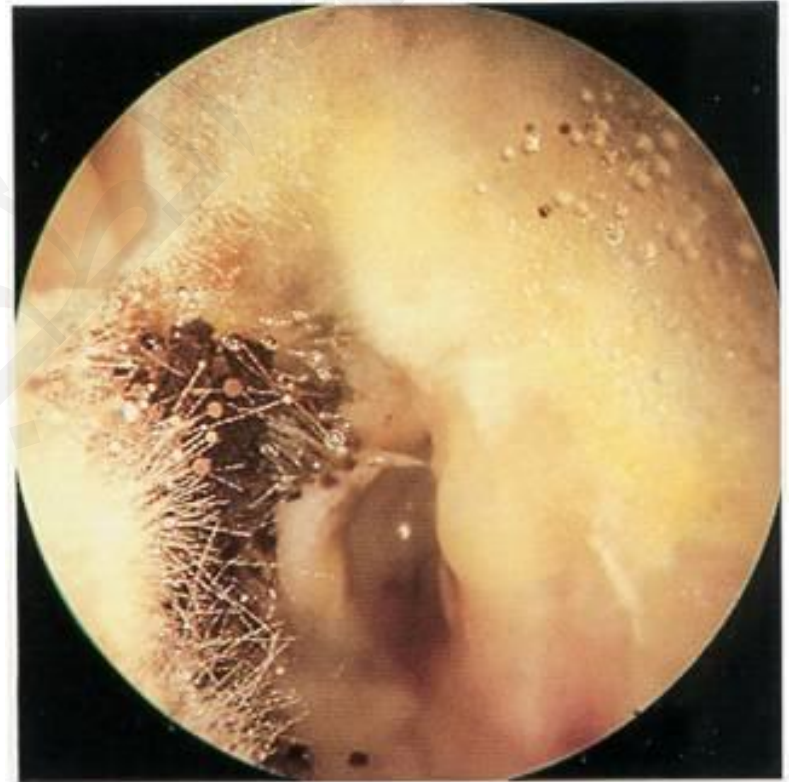1- What is your Dx?

**Otomycosis**

2- Mention 2 lines of management?

**A- Aural toilet and keep the ear dry**

**B- Topical anti-fungal as Clotrimazole**



This patient had tonsillectomy before one week,

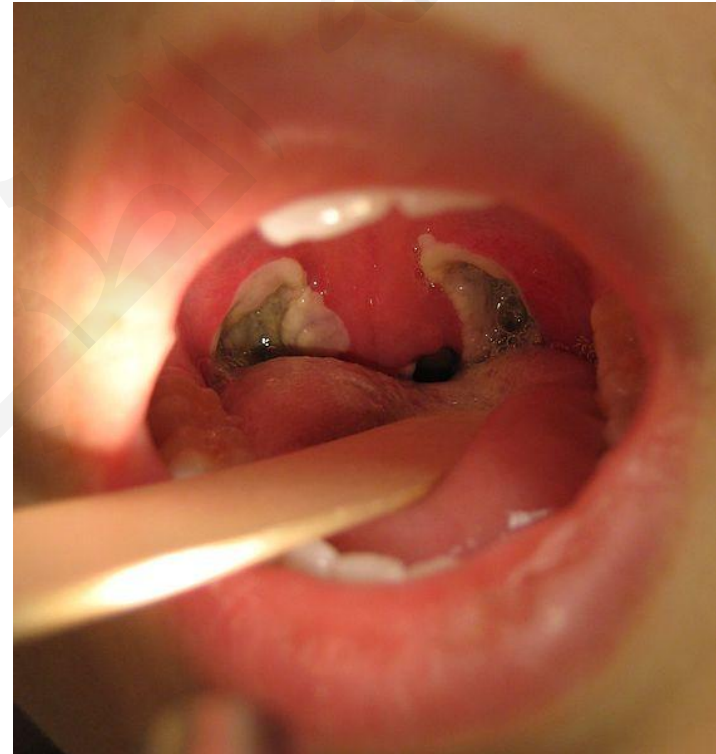
1- What can you see?

Normal fibrinoid reaction after tonsillectomy

2- Give 2 indications for tonsillectomy?

A- Recurrent acute tonsillitis

B- Complicated tonsillitis as in febrile convulsion



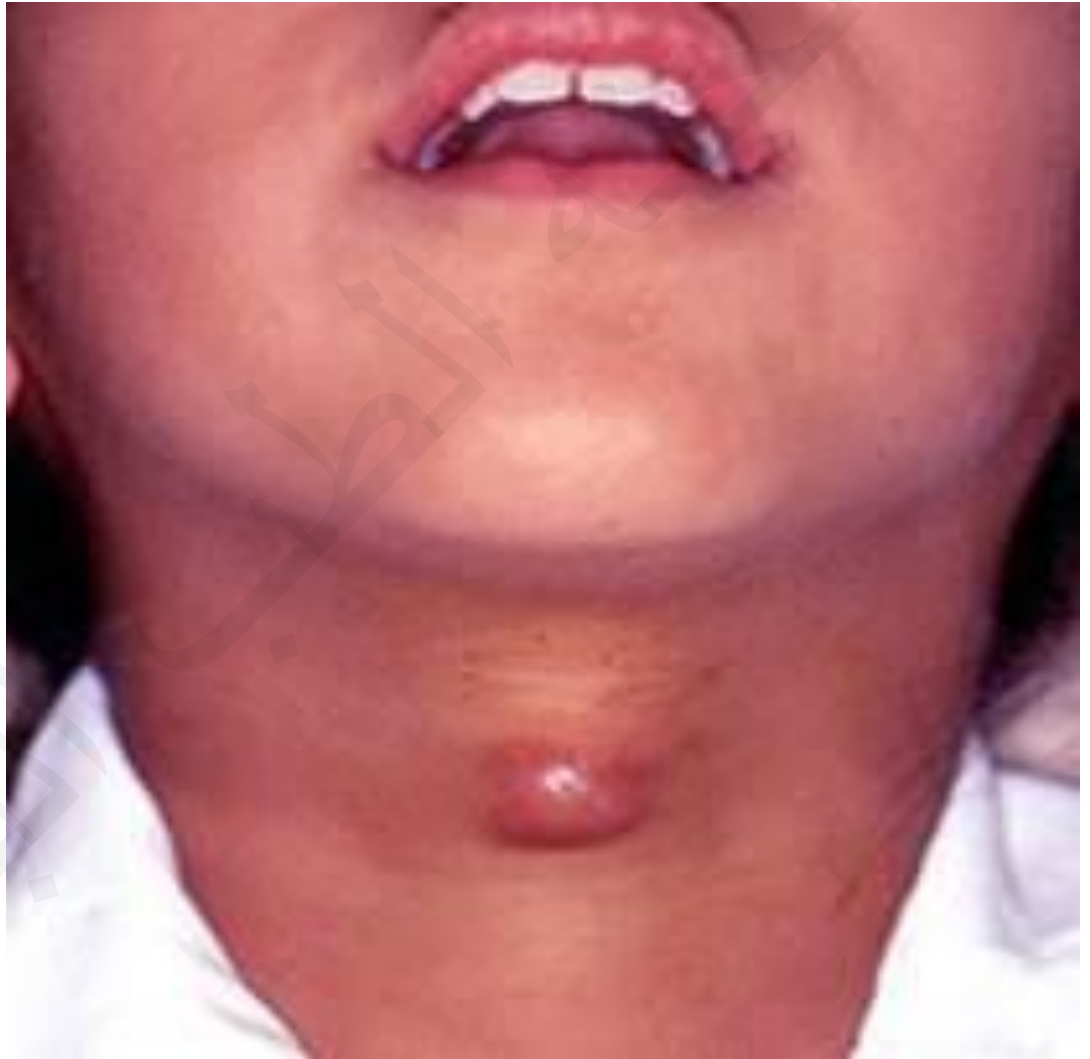This patient presented with painful mass in the midline,

1- What is your Dx?

**Thyroglossal cyst**

2- Name the surgery you do for your Dx?

**Sistrunk surgery**





A patient complaining of hoarseness in voice, presented with this picture,

1- What is your most likely diagnosis?

Laryngeal ca (most common type is SCC)

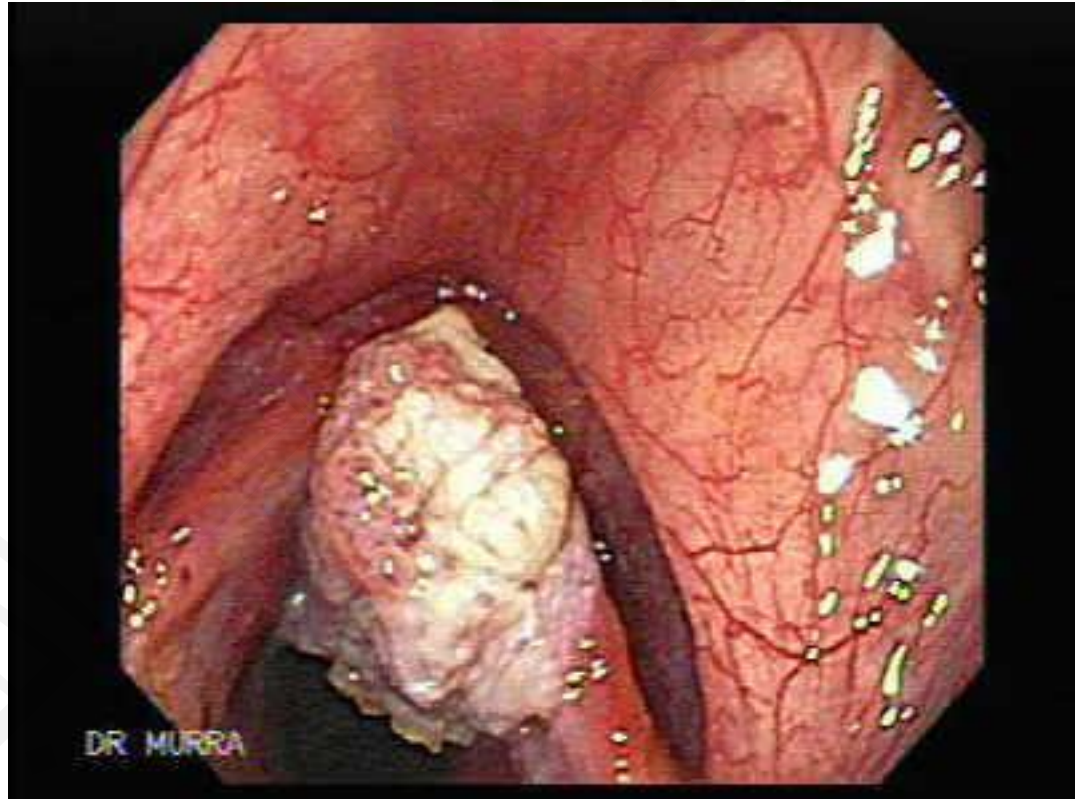
2- Give 2 risk factors?

A- Smoking

B- Voice Abuse

3- Asking the patient to say "eeee" examines what movement of the vocal cords?

Adduction (in phonation)



This picture is for a man after an RTA several hours ago,

1- What is the first line of management?

Digital pressure (trotter method)

2- Name a surgery you can do to stop the bleeding?

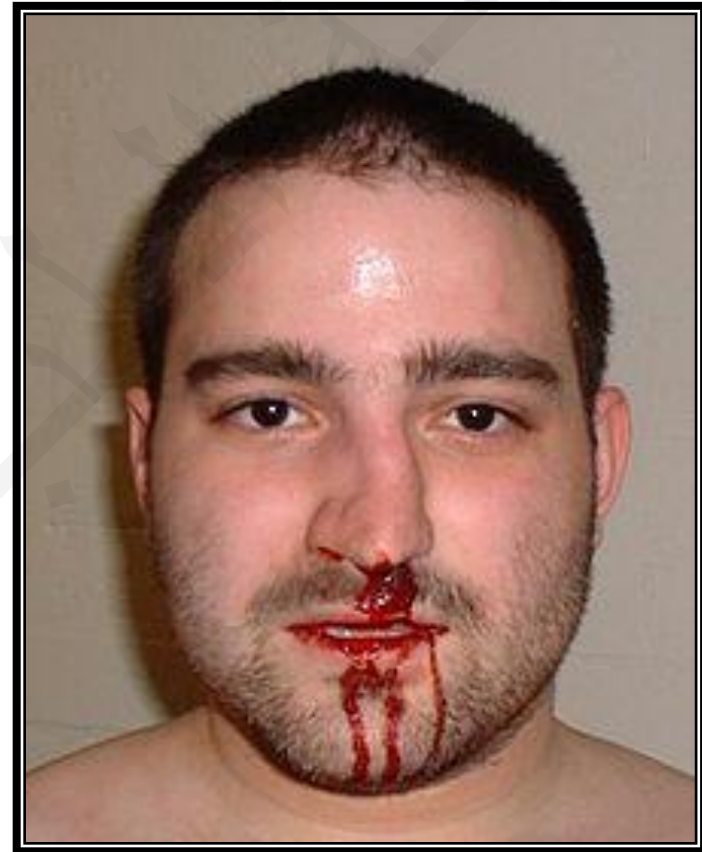Ligation of the anterior ethmoidal artery

3- mention 2 non-traumatic causes of this condition?

A- Hypertension

B- Hemophilia

C- Hereditary telangiectasia



A patient presented with headache and nasal discharge for a week,

1- What is your Dx?

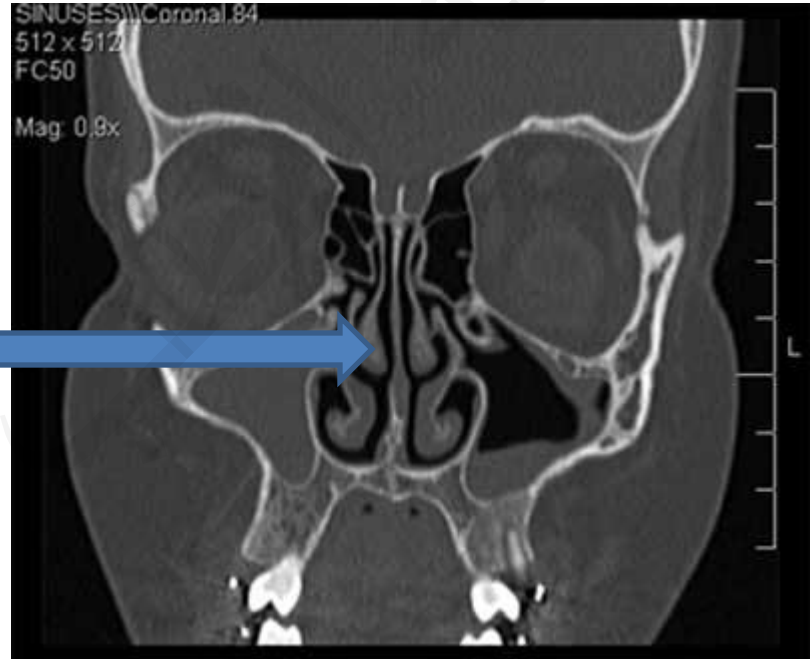
**Right maxillary rhinosinusitis  
(Acute RS)**

2- What is the structure on the arrow?

**Right middle turbinate**

3- what we call the syndrome when the pt had aspirin intolerance, asthma and a nasal polyp?

**SAMTER syndrome**



a mother came to you  
afraid because her 5  
years old child had  
choking. She mentioned  
that he was playing with  
his toys before he  
started choking,

1- What is your Dx?

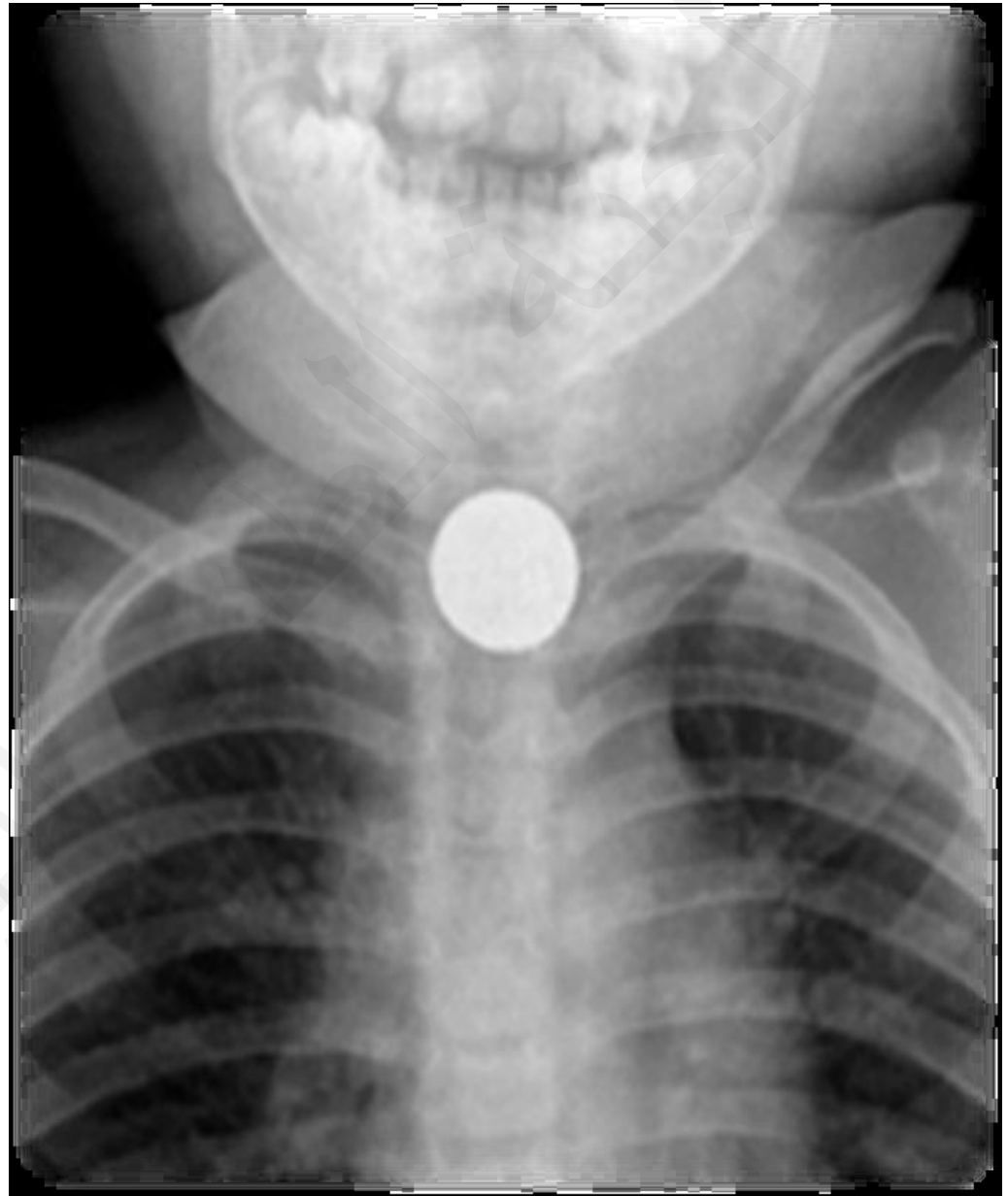**Foreign body aspiration**

2- What do you want to  
do?

**Esophagoscopy**

3- Mention a complication  
if left untreated?

**Esophageal perforation  
or abscess**



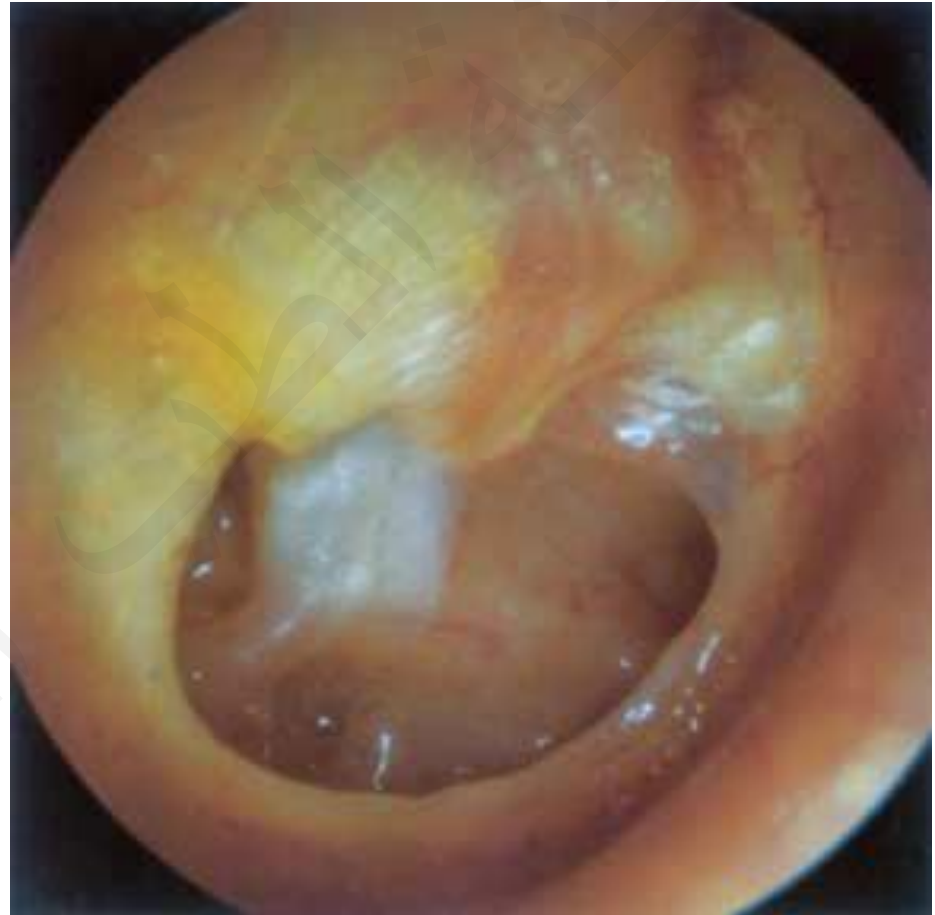1- Mention 2 signs you can see?

A- Tympanosclerosis

B- Tympanic membrane perforation

2- What type of Tympanometry you will have for this case?

Type B



A Patient presented with hearing loss in his left ear. His Rinne's test is negative in left ear and this is his audiogram.

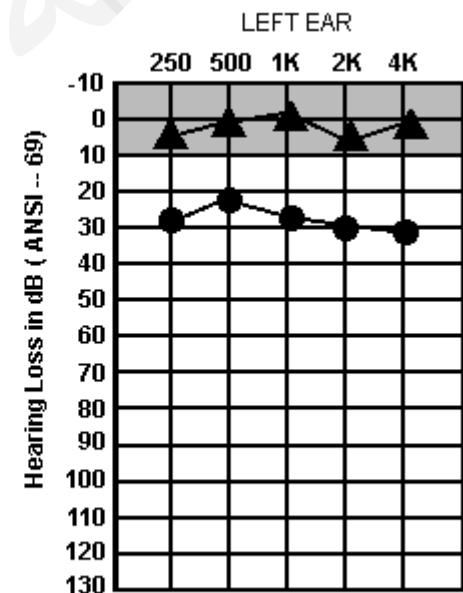
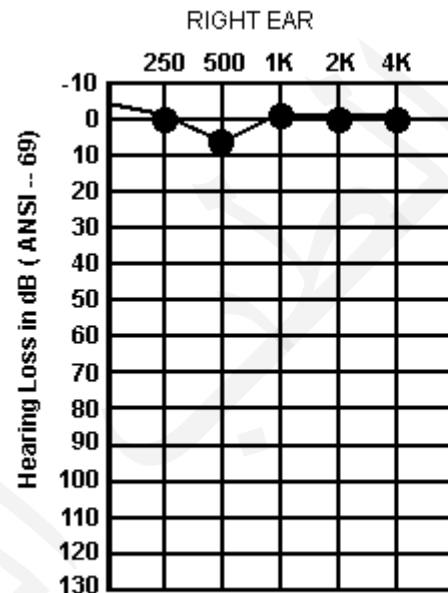
Mention 3 possible causes of deafness in this patient ?

A- Otitis Externa

B- Acute Otitis media

C- Tympanic membrane perforation

(causes of conductive hearing loss)





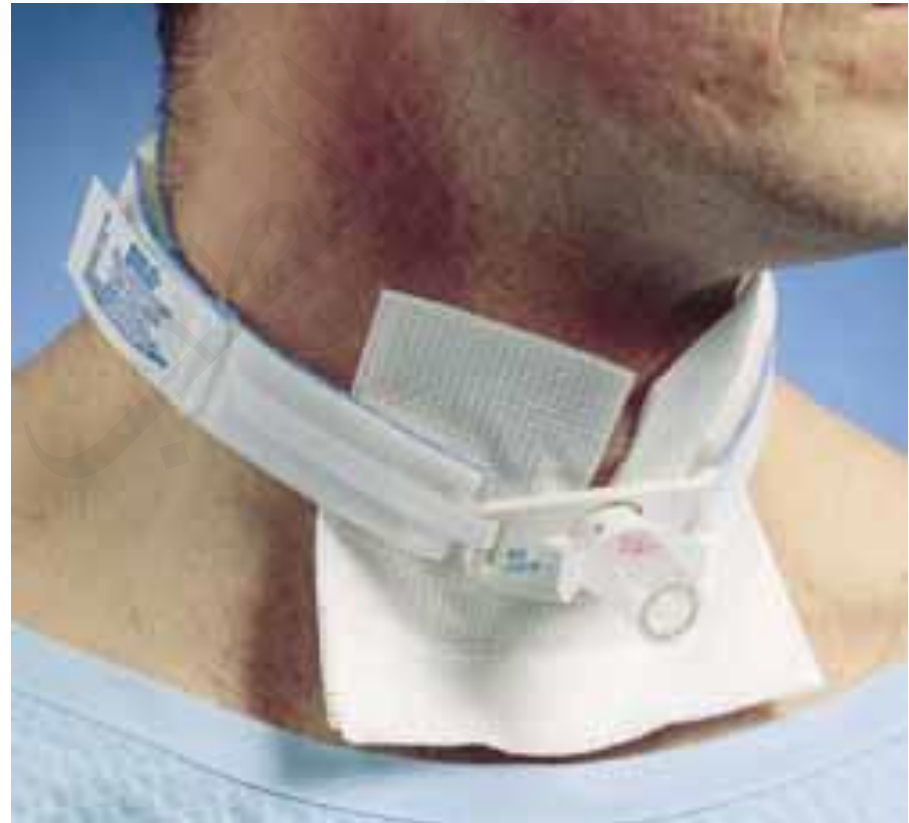1- What is the name of this tube ?

Tracheotomy tube

2- Mention 2 indications for this tube?

A- Respiratory Failure

B- Upper airway obstruction





**Ihsan Batch**





# ENT mini osce

## Groups A

Ihsan batch

# Groups A1-A2

- جميع الأسئلة كانت من السنوات باستثناء سؤال واحد وهو كالتالي:
- إذا كنت تعمل thyroidectomy وما لقيت ال recurrent laryngeal nerve, شو بتتوقع يكون النيرف؟
- الجواب: non-recurrent laryngeal nerve

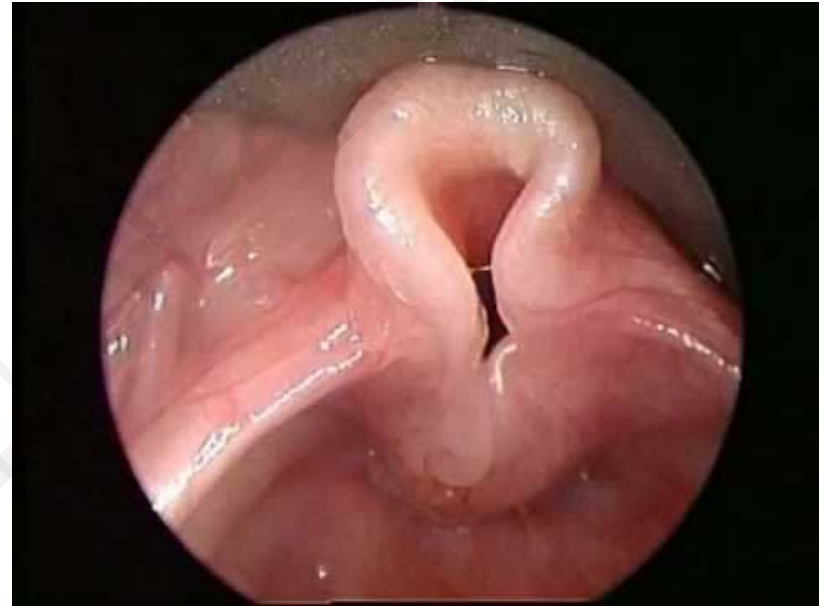# Groups A3-A4

- جميع الأسئلة كانت من السنوات

# Groups A5-A6

- What is the diagnosis ?

Ans : **Laryngomalacia**



- What is the sign in the pic ?

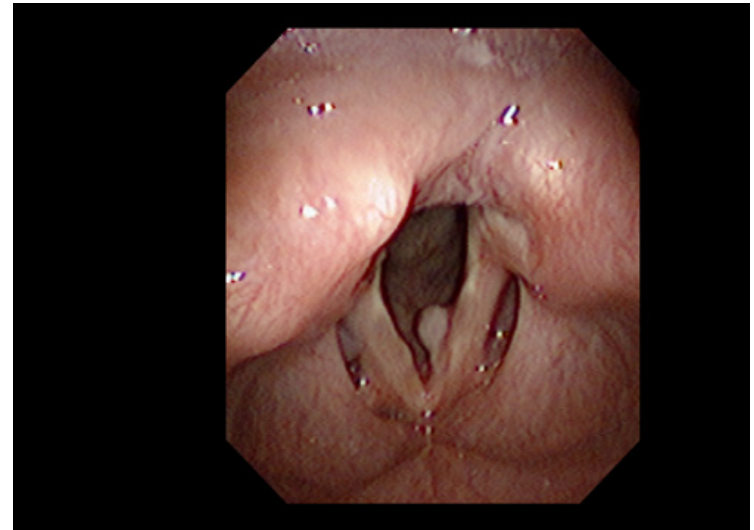
Ans : **Omega sign**

- Q6..history that the patient is teacher & has hoarseness of voice
- 1)what is the diagnosis?

Ans : singer nodules

2) treatment ?

Ans : speech therapy  
voice rest



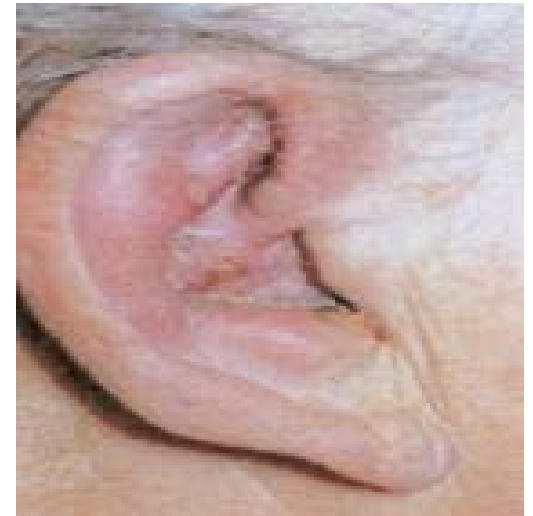- Pt presented with vesicles around his ear :

1) what is the diagnosis ?

Ans : **Ramzy hunt syndrome**

2) mention one complication for this Dx ?

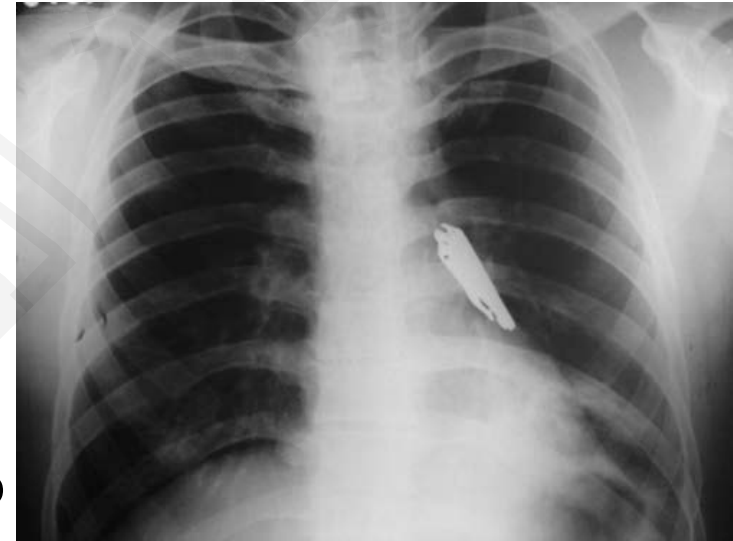Ans : **facial nerve palsy**



A child presented with history of choking. We did him this X-ray :

1) What is your diagnosis?

Ans : foreign body aspiration



2) What is your management?

Ans : Bronchoscopy

3) Give two complications to this condition ?

Ans : pneumonia , lung collapse

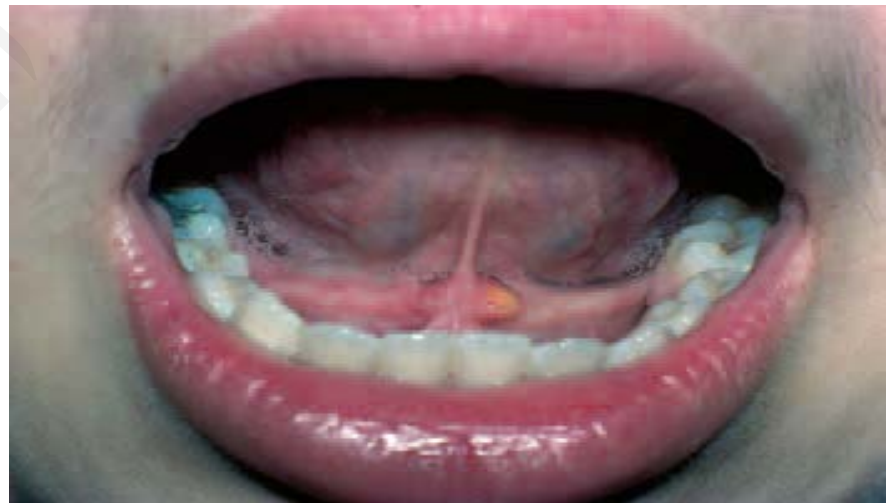

1) What is the diagnosis?

Ans : Sialolithiasis

2) Where does the stensen's duct open?

Ans : Opposite to Upper second molar tooth



1) What is the first line of management?

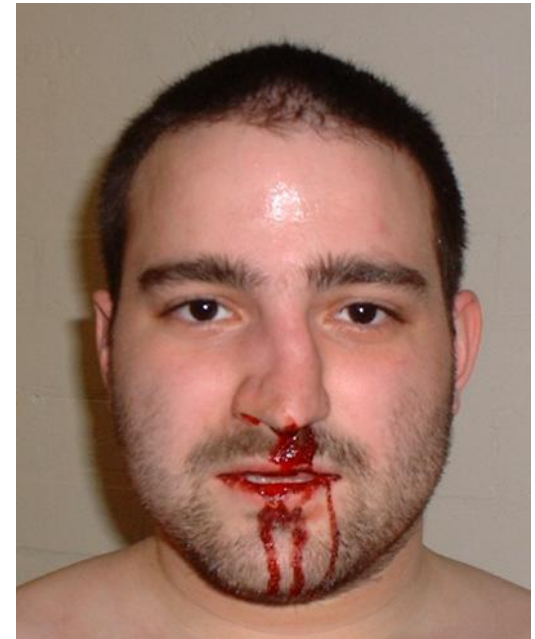Ans : Trotter's maneuver

2) Mention 2 of the local causes of epistaxis ?

Ans : trauma , septal perforation

3 ) Mention a surgery for ttt ?

Ans : Ligation of the anterior ethmoidal artery



1) What is your diagnose?

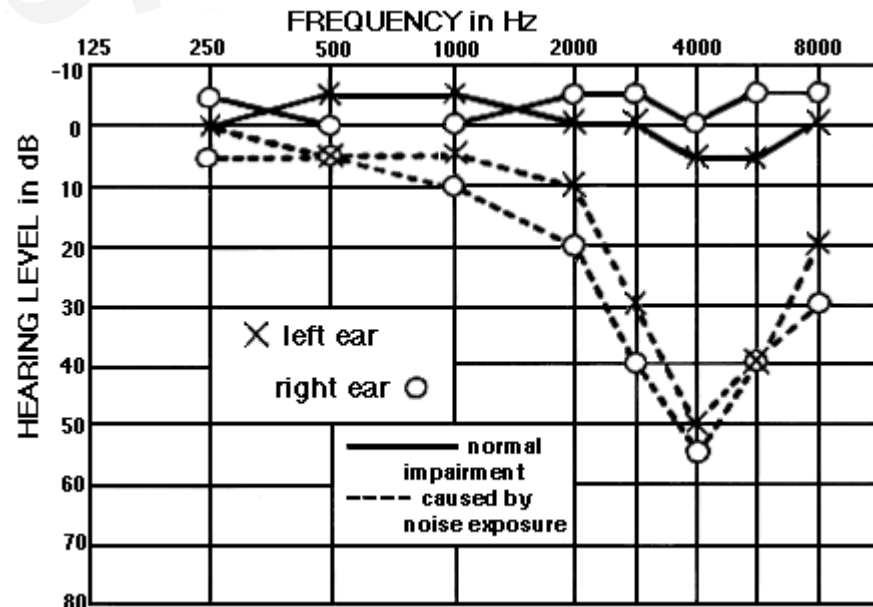
Ans : Presbycusis

2) What is the name of this test?

Ans : Audiometry

3) What is the result of rennie test ?

Ans : +ve rennie test



1) What is the diagnosis ?

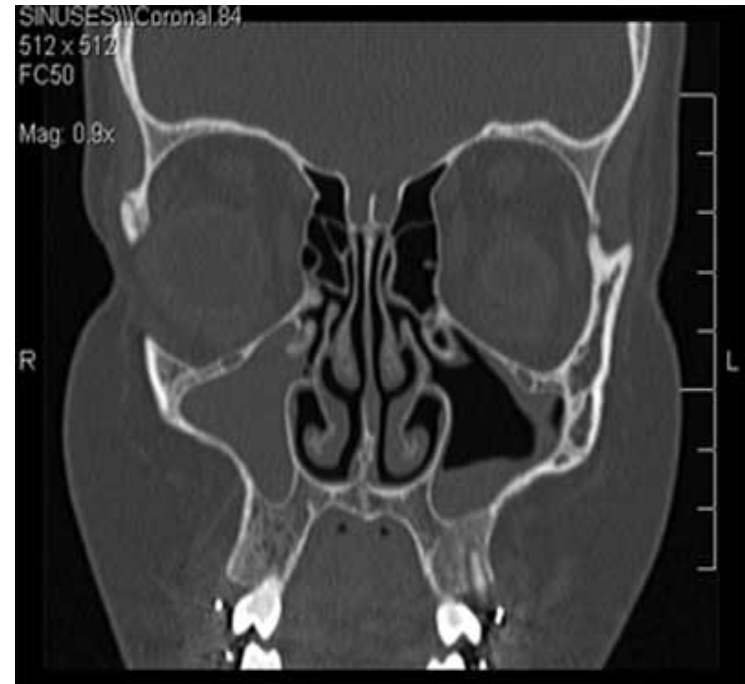Ans : **Acute infective rhinosinusitis** ( acute according to HX  
) **don't mention the site**

2) name the structure that the arrow points to?

Ans : **right middle turbinate**

3) What is the first thing to do  
if there is an insect in the ear ?

Ans : **kill it with alcohol**



1) What is the diagnosis?

Ans : chronic suppurative otitis  
Media with Cholesteatoma

2) What do u see on tympanometry ?

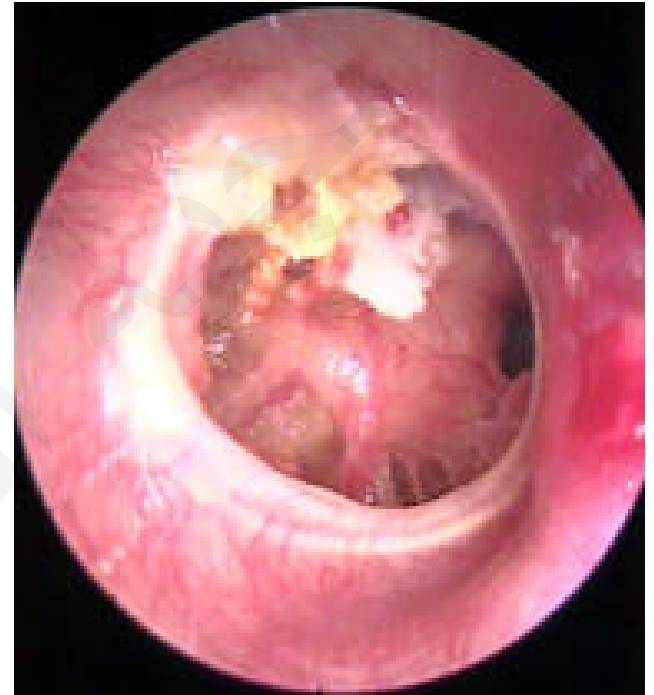Ans : type B

3) write 2 features of papillary cancer?

Nuclear groove

Psammoma bodies

Orphan annie neuculi

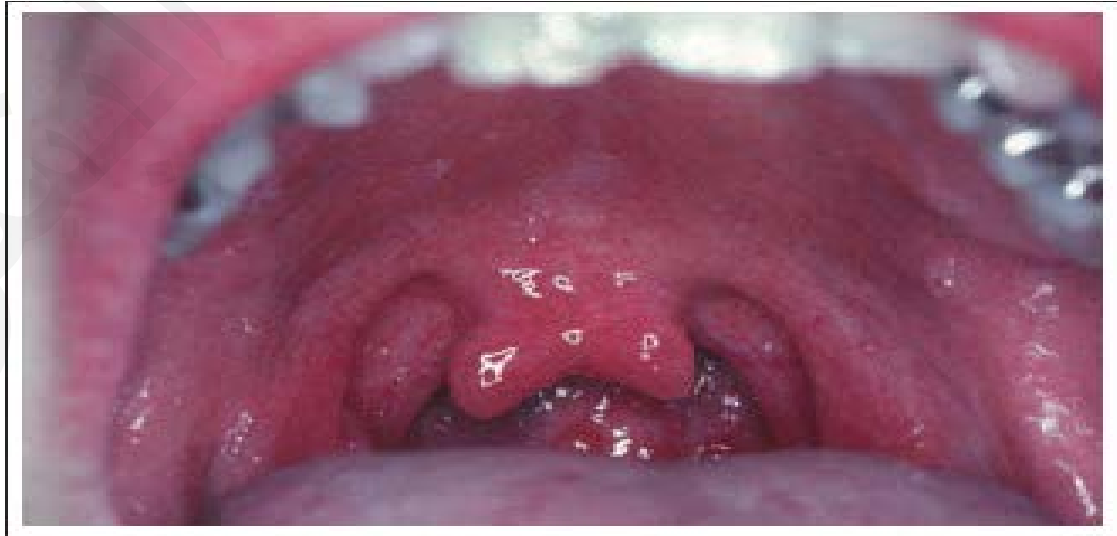

1) Mention 2 Indications for tonsillectomy ?

Ans : Cleft palate, recurrent acute tonsillitis with febrile convulsions

2) Why is the pathology in the pic significant?

Ans : Indicates submucous cleft palate



# Groups A7-A8

# Q1: A patient presented with headache and nasal discharge for 5 months:

What is your Dx:

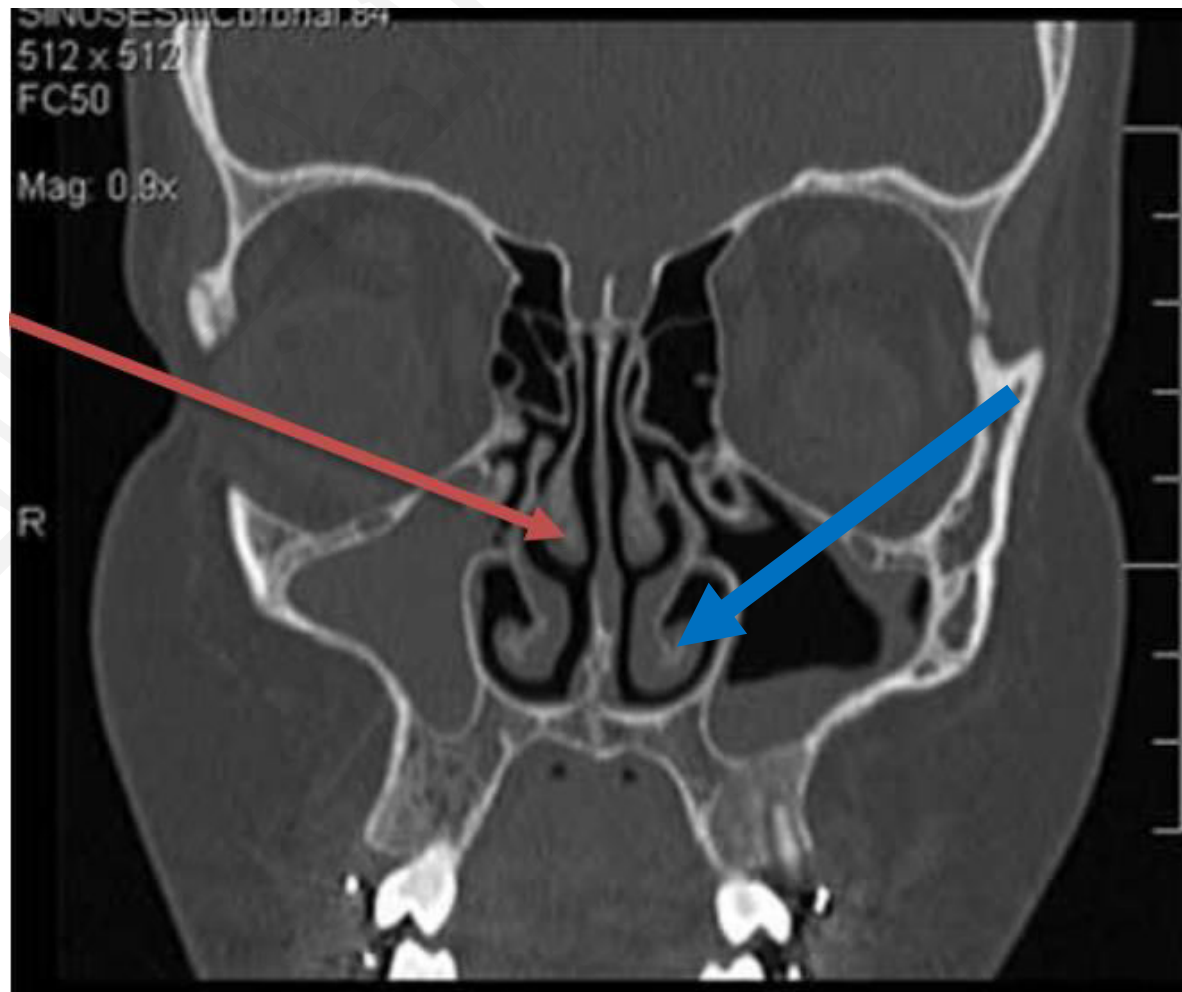
right Maxillary chronic rhinosinusitis

mention 2 risk factors:

- a. adenoid hypertrophy
- b. allergic rhinitis

what is the structure  
(blue arrow):

left Inferior turbinate





**Q2: A 5 year old is brought to the emergency department by his parents because they saw a white exudate on his throat, he had a tonsillectomy 2 d ago:**

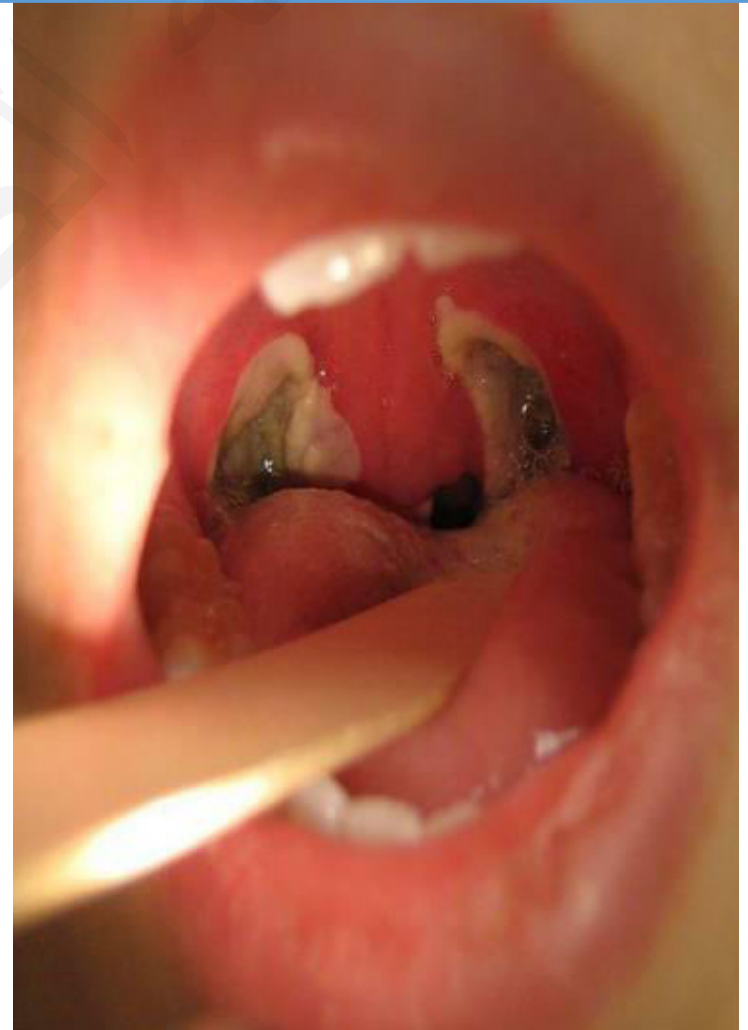
**What is the cause of this:**

Normal fibrinoid reaction after  
tonsillectomy

**in the Eagle Syndrome what is the  
affected cranial nerve:**

Glossopharyngeal (9<sup>th</sup> nerve)

**what is the most common cause of  
obstructive sleep apnea in adults:**  
Obesity



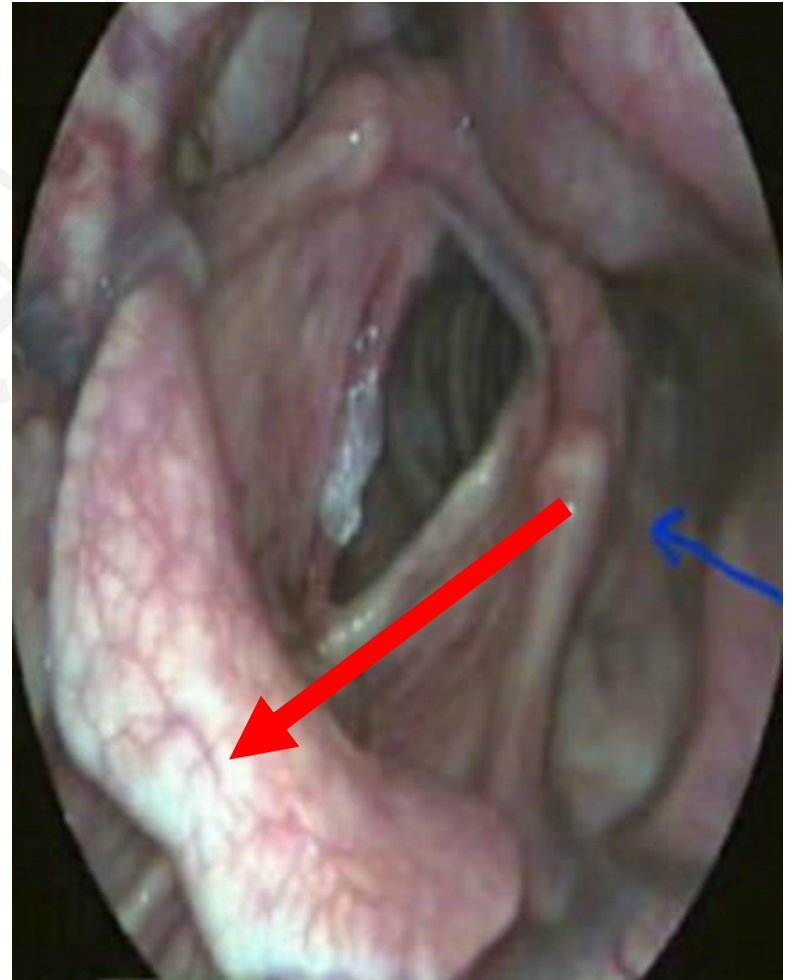
Q3: A 55 year old male smoker, is complaining of dysphonia, his initial work up suggests malignancy:

What is your initial Dx:

Laryngeal Cancer – SCC

What is the Structure  
(**Red Arrow**):

Epiglottitis



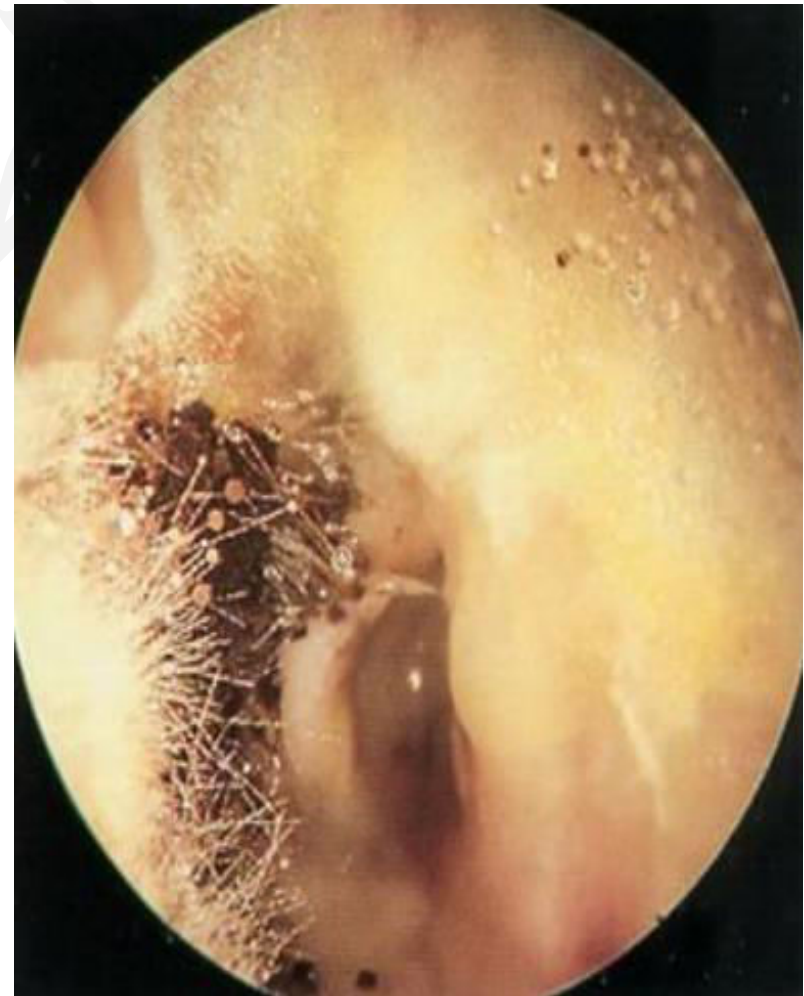**Q4: This patient presented with history of ear itchiness:**

**What is your Dx:**

Otomycosis

**Mention two lines of management:**

- Aural toilet
- Topical antifungal medications



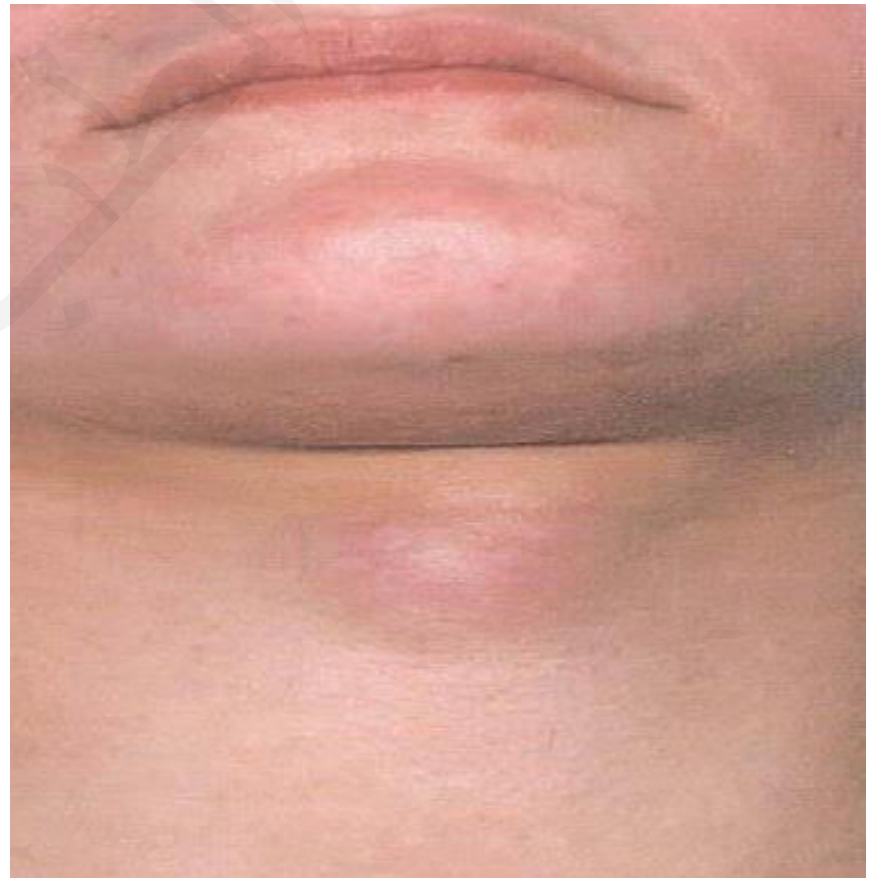Q5: This patient presented a central mass in the neck that moves with tongue protrusion:

What is your Dx:

- Thyroglossal duct cyst

What surgery is done:

- Sistrunk procedure



# Q6: This picture is for a man after an RTA several hours ago:

**What is your 1<sup>st</sup> line of management:**

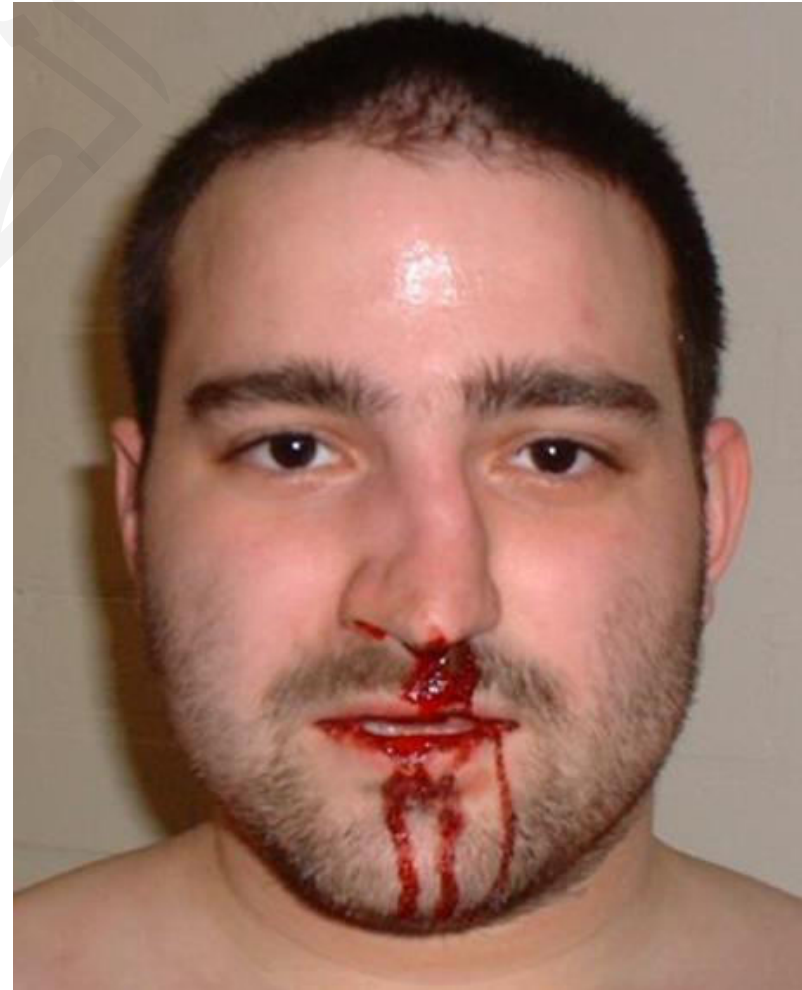- Digital compression (Trotters maneuver)

**What refractive surgery done for this patient:**

- Anterior ethmoidal artery ligation

**Mention 2 non-traumatic causes of epistaxis:**

- Hypertension
- Hemophilia





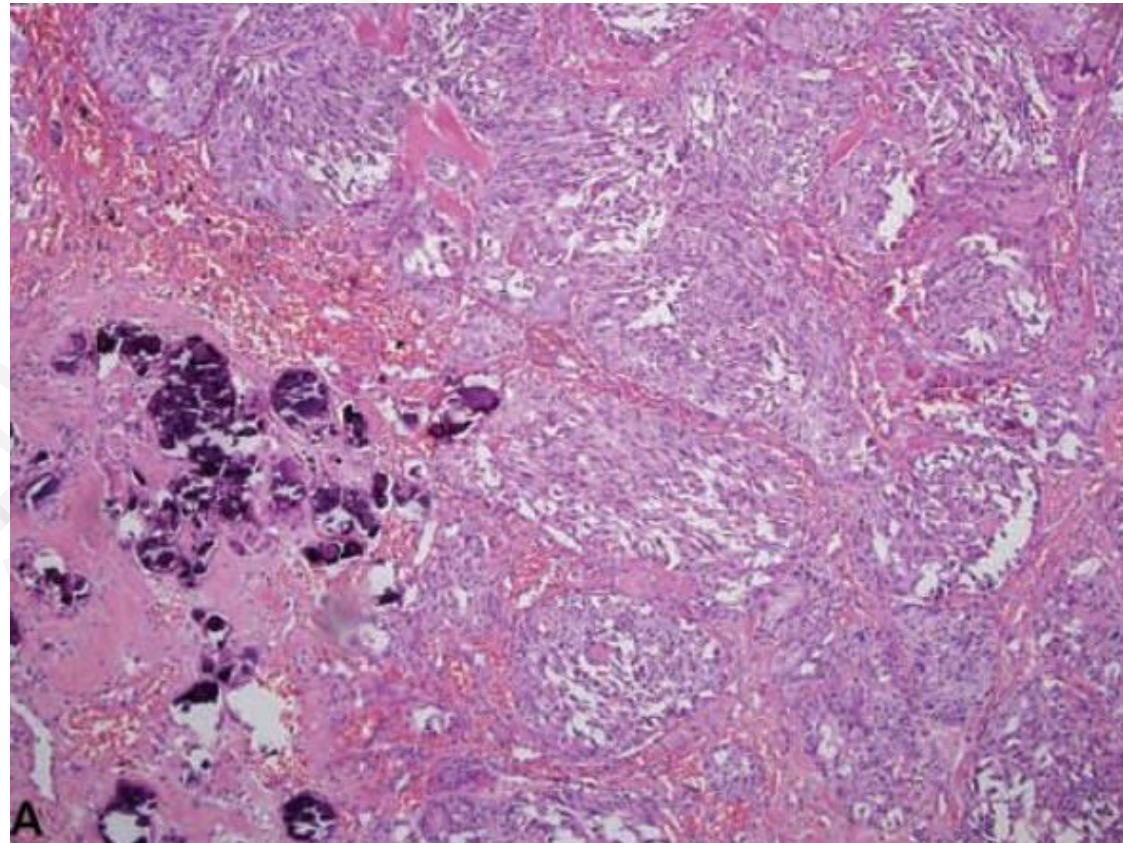
Q7: There was a suspicious for malignancy thyroid mass, FNA results showed Amyloid:

What is your Dx:

- Medullary thyroid carcinoma

What is the hormone that detects the early level changes in this type of malignancy:

- Calcitonin



Q8: a mother came to you afraid because her 5 year old child had choking and dysphagia, she mentioned that he was playing with his toys before choking:

What is your Dx:

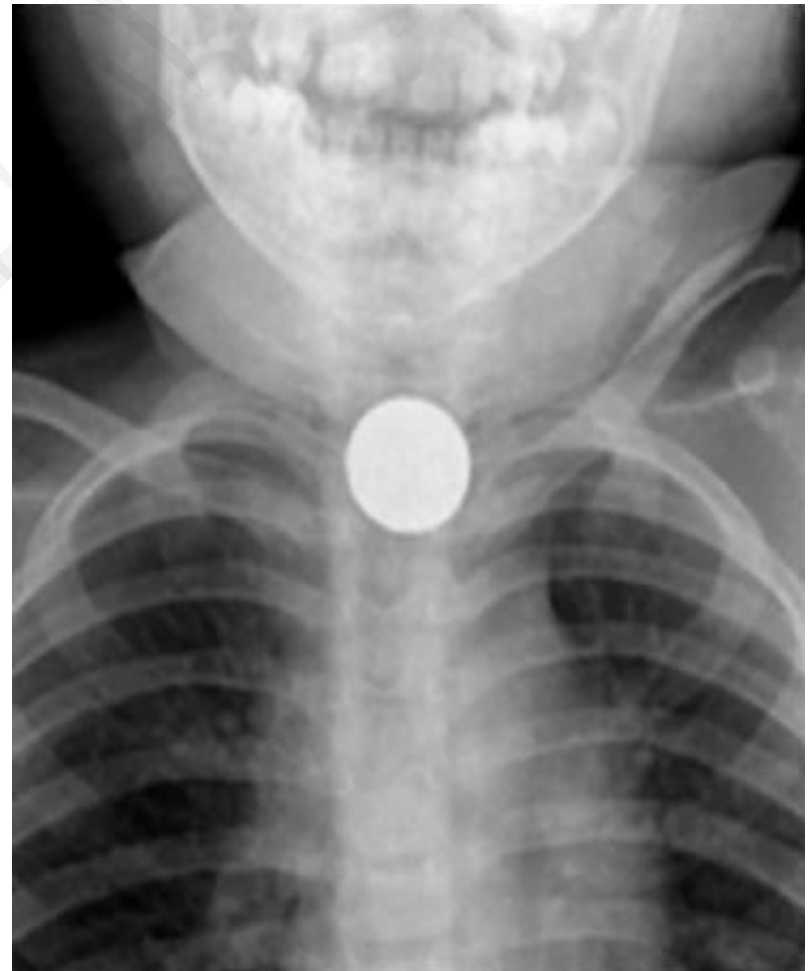
- Foreign body ingestion

(Note: FB aspiration: means its in the tracheobronchial tree, ingestion means its in his esophagus, you can see the difference in the history!)

What is your management:

- Esophagoscopy

(Note: in aspiration – bronchoscopy)



**Q9: After examining a patient you see this picture:**

**Mention 2 signs you see:**

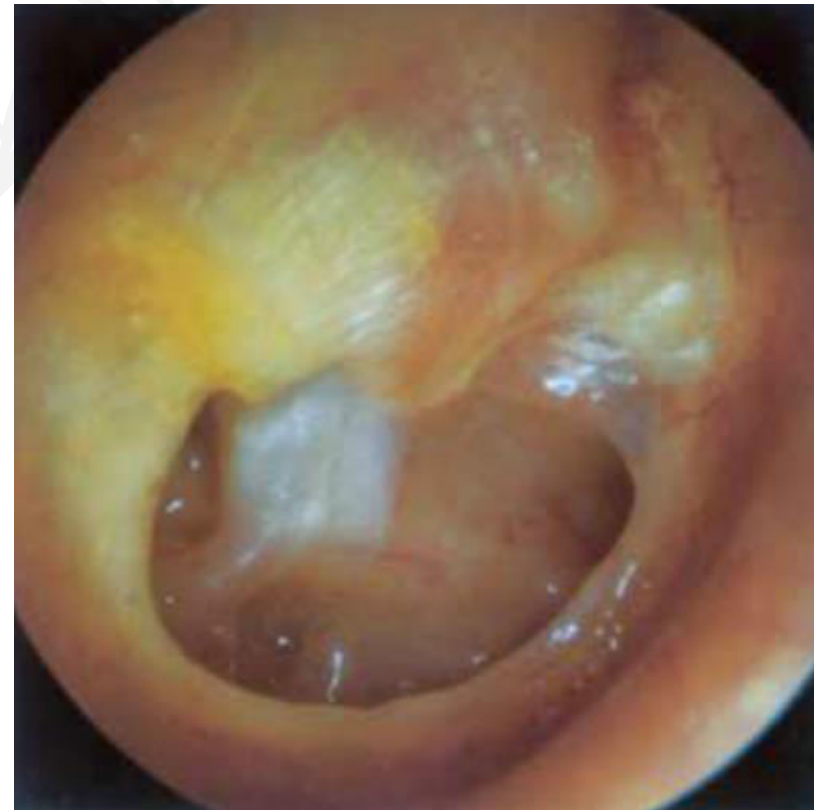- Tympanosclerosis
- Tympanic membrane perforation

**Which Type of Tympanometry:**

- Type B

**What is the result of Rennie test:**

- Negative





# Q10: Answer the following questions related to this picture:

**Mention 2 indications:**

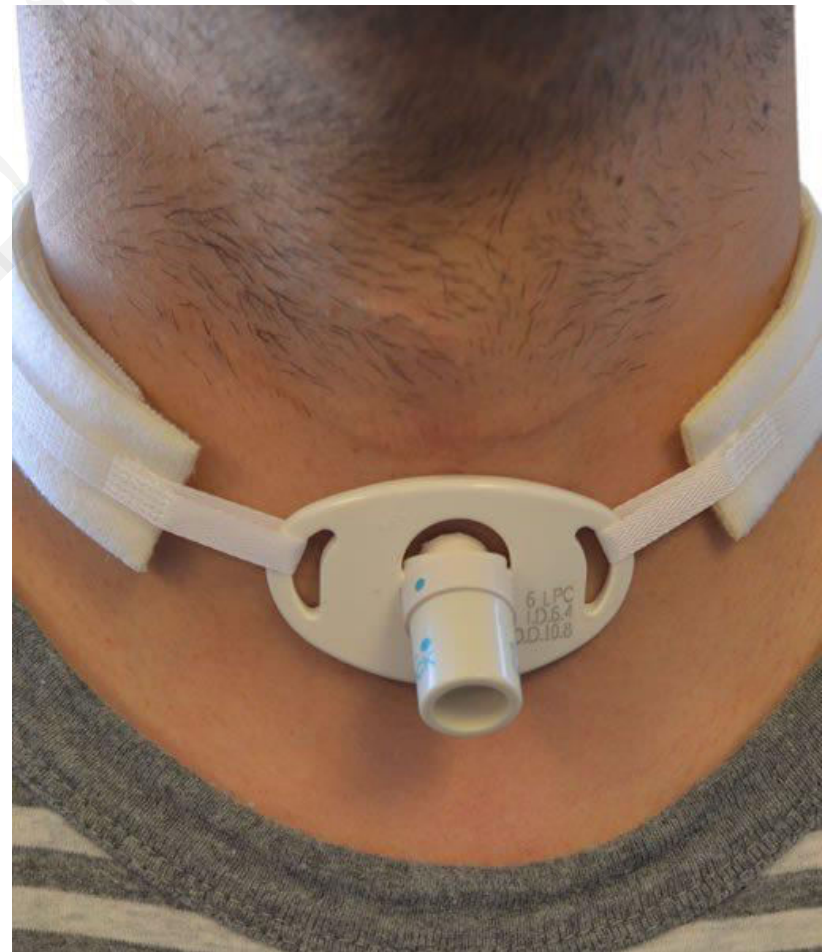- Upper airway obstruction
- Respiratory Failure

**Mention 1 Contraindication:**

- Pediatric age (the only absolute CI)

**At which tracheal ring is the tube inserted:**

- the 2<sup>nd</sup> tracheal ring



# ENT Mini OSCE

## Groups B

Ihsan Batch

# Groups B1-B2

- جميع الأسئلة من السنوات باستثناء سؤال واحد وهو التالي:

Name 5 prognosis factors for thyroid tumors:

الجواب:

MACIS (Metastasis, Age, Completeness of resection,  
Invasion, Size)

Groups B3-B4

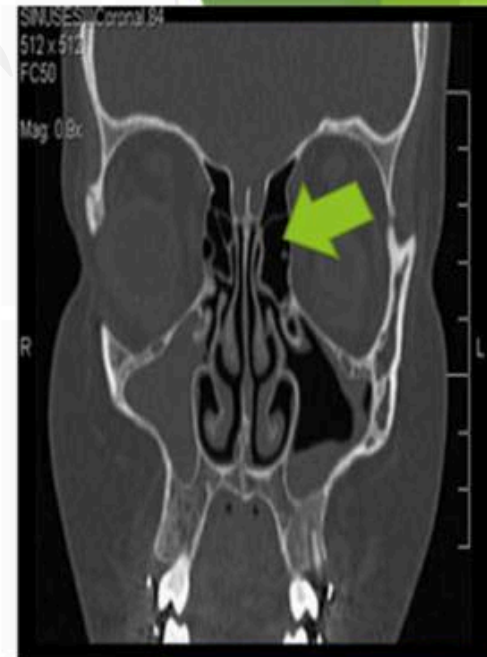
جنته الطبر  
البحر

4) A 20 year old female patient presented with **4 months** duration of yellow nasal discharge.

- ▶ 1- What is the diagnosis?

### **Chronic infective rhinosinusitis**

- ▶ 3- What is the name of the surgery for refractory cases?
  - ▶ FESS (Functional endoscopic sinus surgery)
- ▶ 4-What is indicated by the arrow?
  - ▶ Left ethmoidal sinus



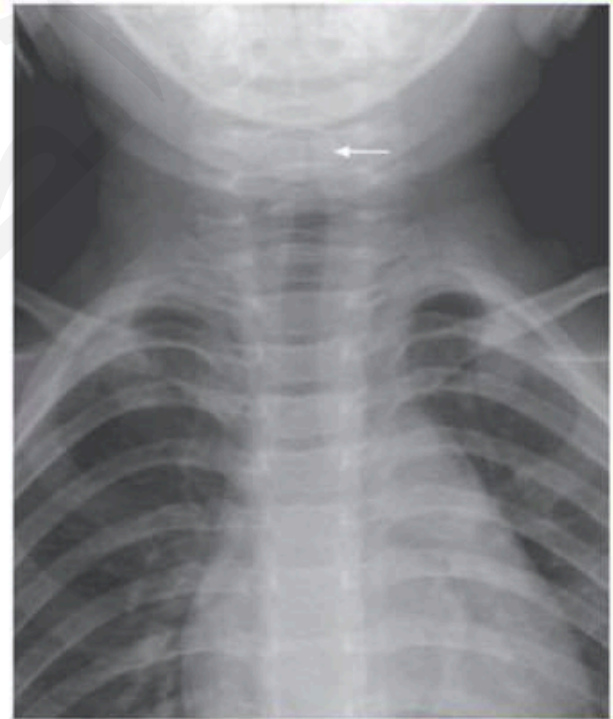
6) A patient is complaining of decrease hearing, he has impacted ear wax.

- ▶ 1- What is this technique?
  - ▶ Ear syringing technique
- ▶ 2- Mention 2 complications of this procedure?
  - ▶ Tympanic membrane perforation
  - ▶ Injury to ear canal
- ▶ 3- What is the type of tympanometry for this patient?
  - ▶ Type B



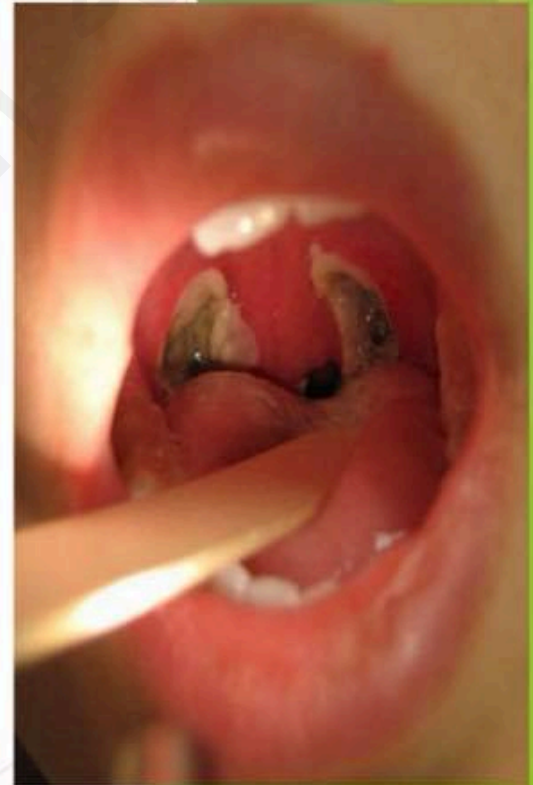7) A child presented to the ER, he is complaining of stridor and SOB.

- ▶ 1- What is the sign seen on this X-ray?
  - ▶ Steeple sign
- ▶ 2- What is the most likely microorganism?
  - ▶ Parainfluenza virus
- ▶ 3- What is the management?
  - ▶ Racemic nebulizer & steroids.



1) A 5 year old is brought to the emergency department by his parents because they saw a white exudate on his throat, he had a tonsillectomy 2 days ago.

- ▶ 1-What is the cause of this?
  - ▶ Normal fibrinoid reaction after tonsillectomy
- ▶ 2-Give 2 indications for tonsillectomy?
  - ▶ A-Recurrent acute tonsillitis
  - ▶ B-Complicated tonsillitis as in febrile convulsion





## Question 10

A child is brought by his worried mother complaining of choking and difficulty breathing

1- what is the diagnosis?

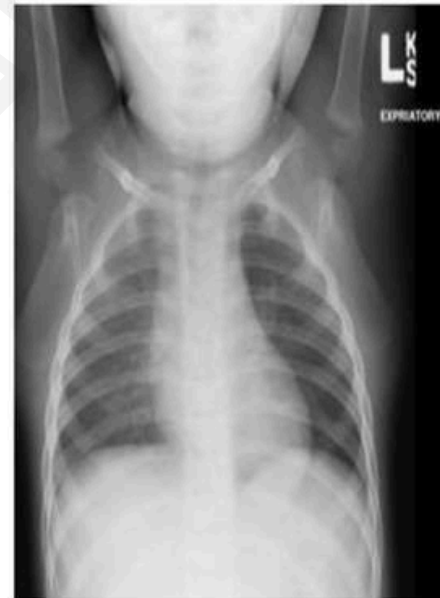Foreign body aspiration

2- what is the first line of management?

Bronchoscopy

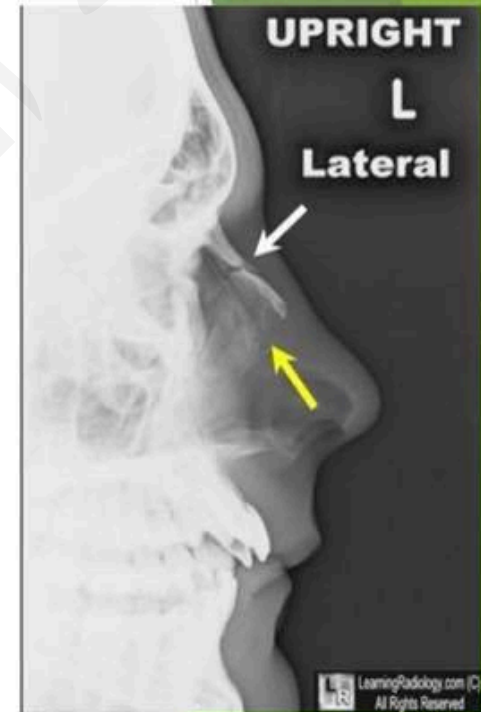
3- Mention 2 complications if left untreated.

Pneumonia, lung collapse



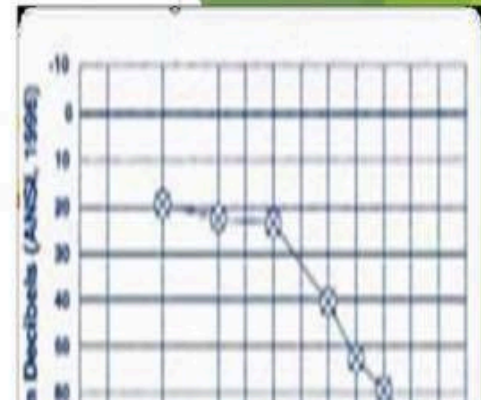
2) A 25 year old patient is brought to the ER after a quarrel, he has pain in his nose.

- ▶ 1-What is the diagnosis as indicated by the arrow?
  - ▶ Nasal bone fracture
- ▶ 2-What is the first step in management after ABC?
  - ▶ Reduction of fracture
- ▶ 2-What is the name where there is recurrent epistaxis and multiple telangiectasia?
  - ▶ Hereditary hemorrhagic telangiectasia



3) A 75 year old male patient complaining of progressive bilateral hearing loss.

- ▶ 1- How do you treat?
  - ▶ Hearing Aid



- Pic of male with neck pulsatile mass

1- differential diagnosis ? Carotid body tumor

2- the best definitive diagnostic method? MRI

3- treatment? Radiotherapy

- Direct origin of inferior thyroid artery?

Thyrocervical trunk of subclavian artery

# Groups B5-B6

- جميع الأسئلة كانت من السنوات

# Groups B7-B8

- جميع الأسئلة كانت من السنوات