

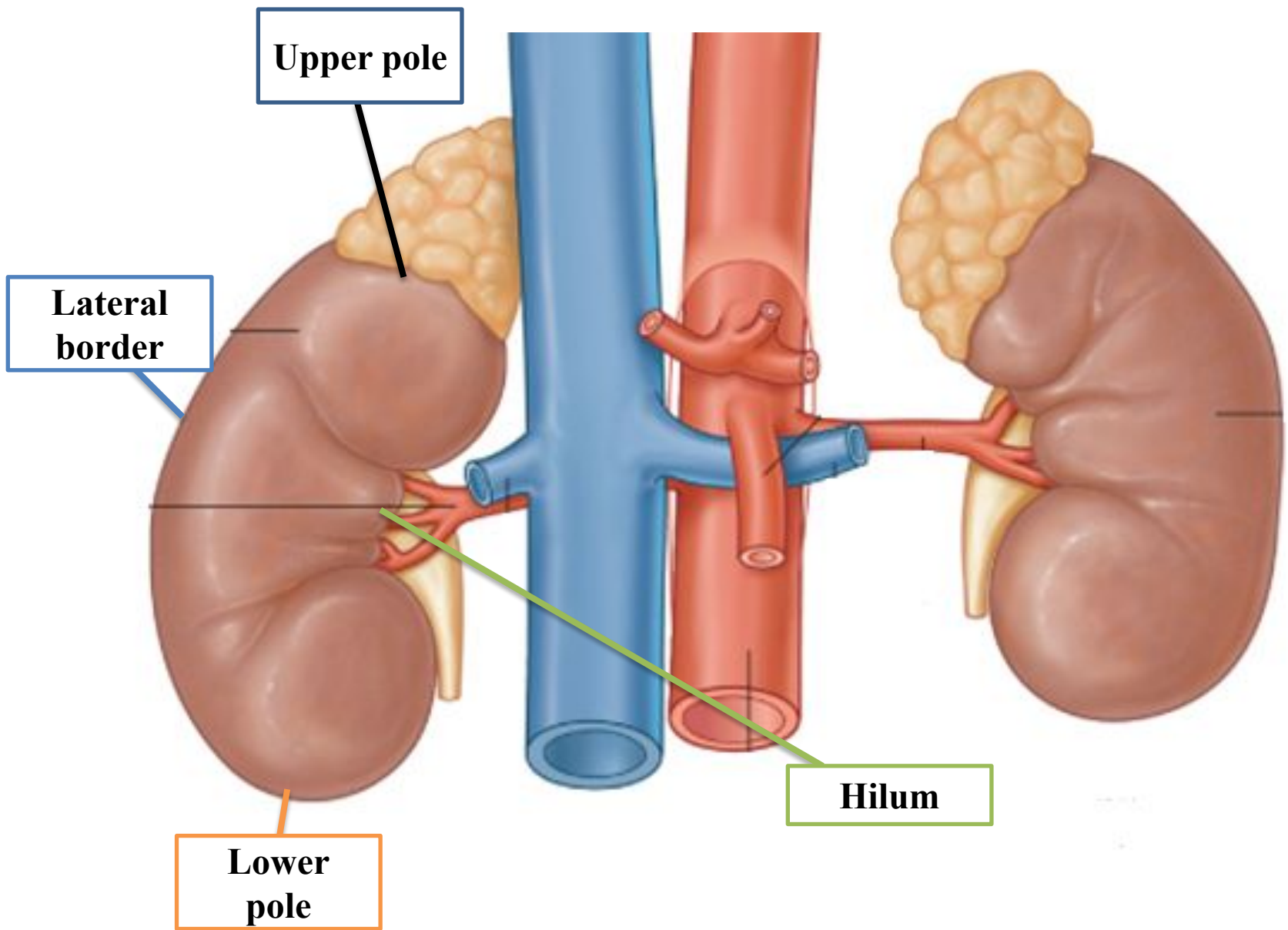
UGS Lecture – 1

(2021)

The Kidneys

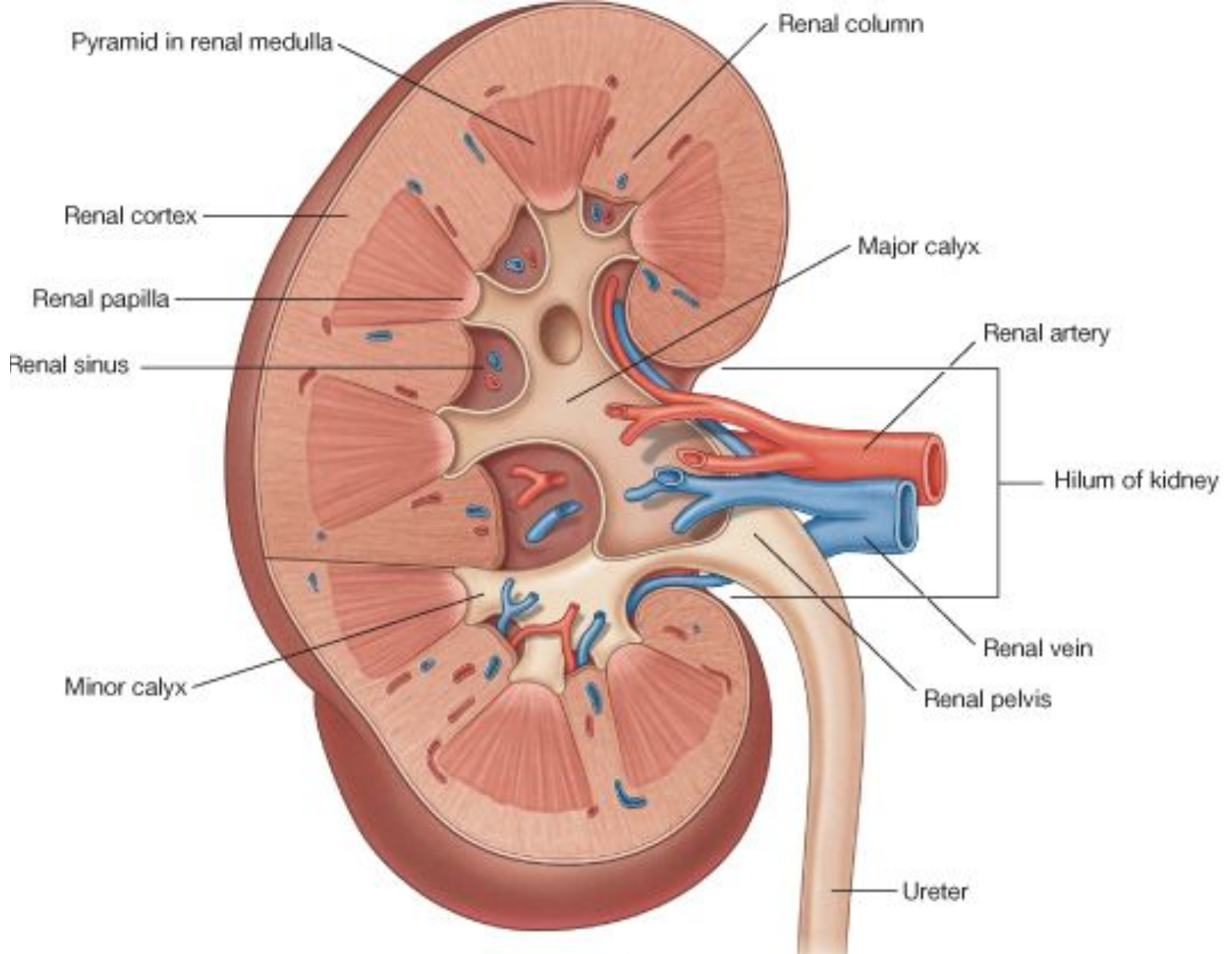
- **The kidneys are bean-shaped, reddish brown in color and approximately 10 cm long, 5 cm wide, and 2.5 cm thick.**
- **They lie retroperitoneally in the posterior abdominal wall, on each side of the vertebral column.**
- **Each kidney has two poles, Upper and lower; two borders, medial and lateral; and two surfaces, anterior and posterior.**
- **The medial border presents about its mid-point, a deep vertical slit, the hilum of the kidney, through which structures enter or leave the kidney.**

- **Upper pole lies opposite – T12 vertebra.**
- **Lower pole lies opposite – L3 vertebra.**
- **Hilum lies opposite – L1 vertebra or transpyloric plane.**



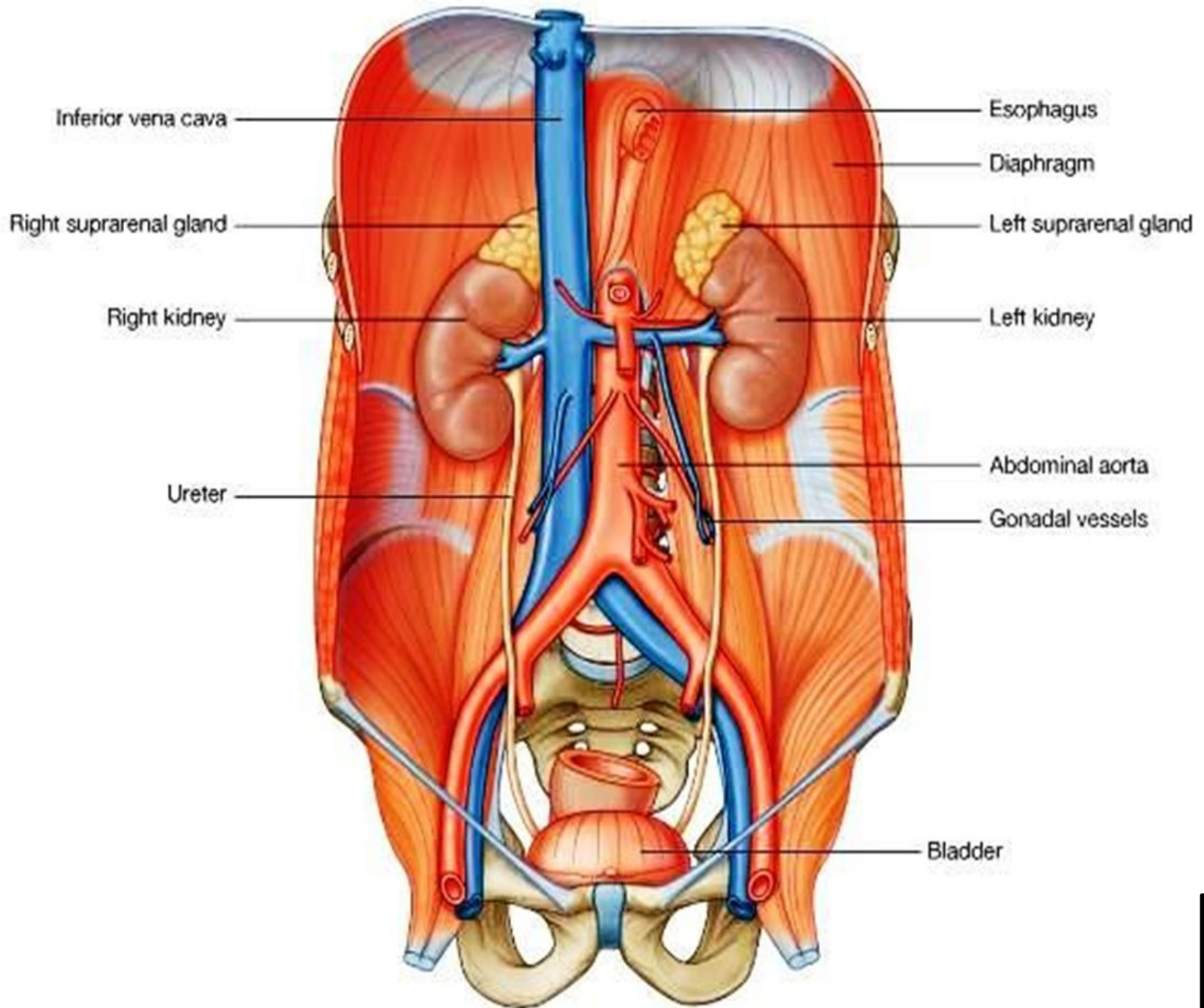
The kidneys

- **The hilum transmits, from the front backward: Renal vein, renal artery, ureter; in addition it transmits Lymph vessels and sympathetic fibers.**
- **During respiration, both kidneys move downward in a vertical direction as much as 1 in (2.5 cm).**
- **The right kidney is slightly lower than the left, because of the large size of the right lobe of the liver. 5**



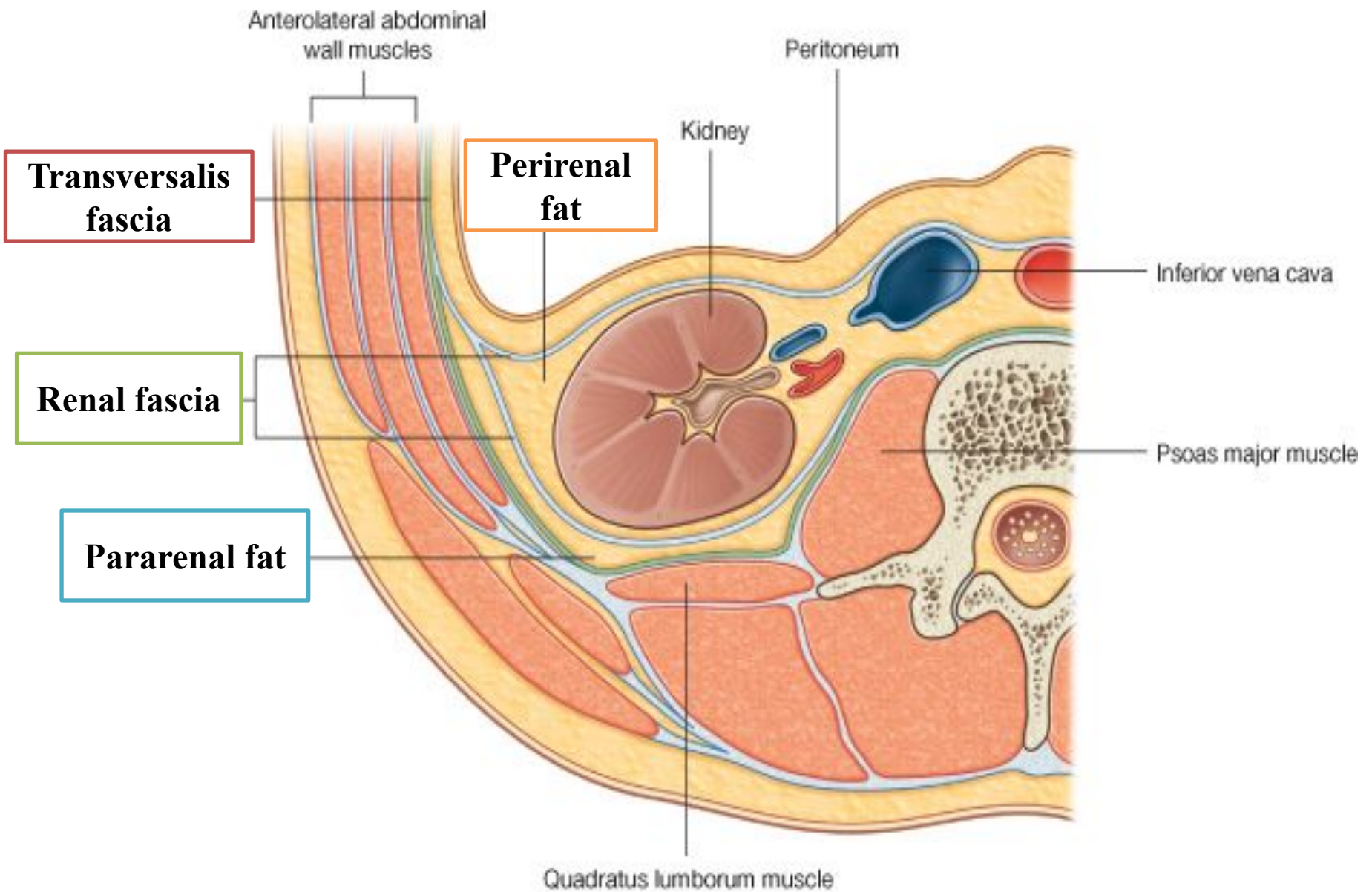
Structures enter the hilum of the kidneys

- **The long axis of each kidney is directed downwards and laterally (the upper poles are slightly nearer midline than the lower poles):**
- **Upper pole – 2.5 cm from the midline.**
- **The hilum – 5 cm from the midline.**
- **Lower pole – 7.5 cm from the midline.**

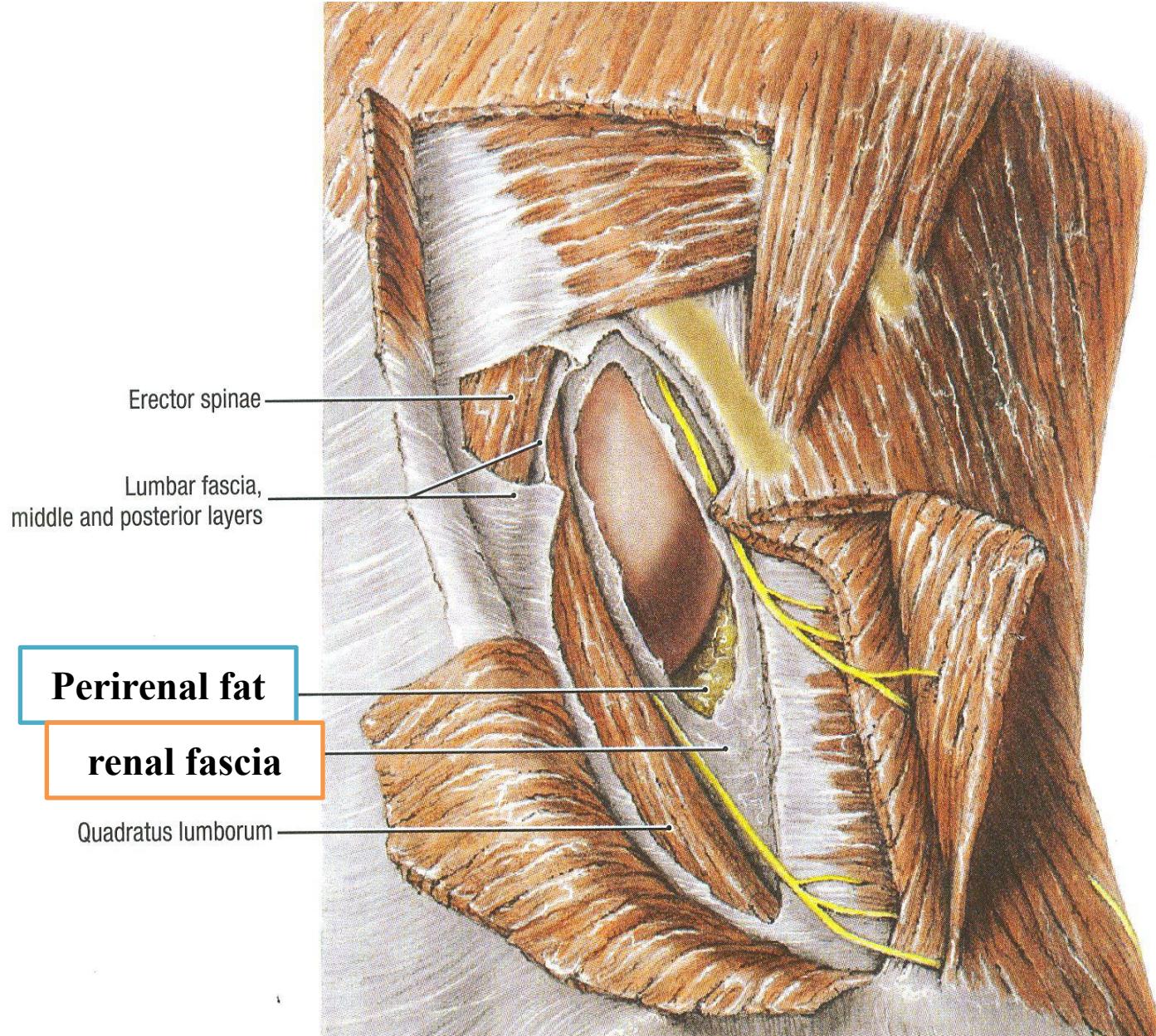


▪ The kidney is surrounded by a delicate fibrous capsule called the renal capsule, which in turn is surrounded by the following coverings:

- a. Perirenal fat – Adipose tissue enclose capsule.
- b. Renal fascia – Condensation of C.T. continue laterally with transversalis fascia.
- c. Pararenal fat – Forms part of retroperi-toneal fat.



Renal fat and fascia



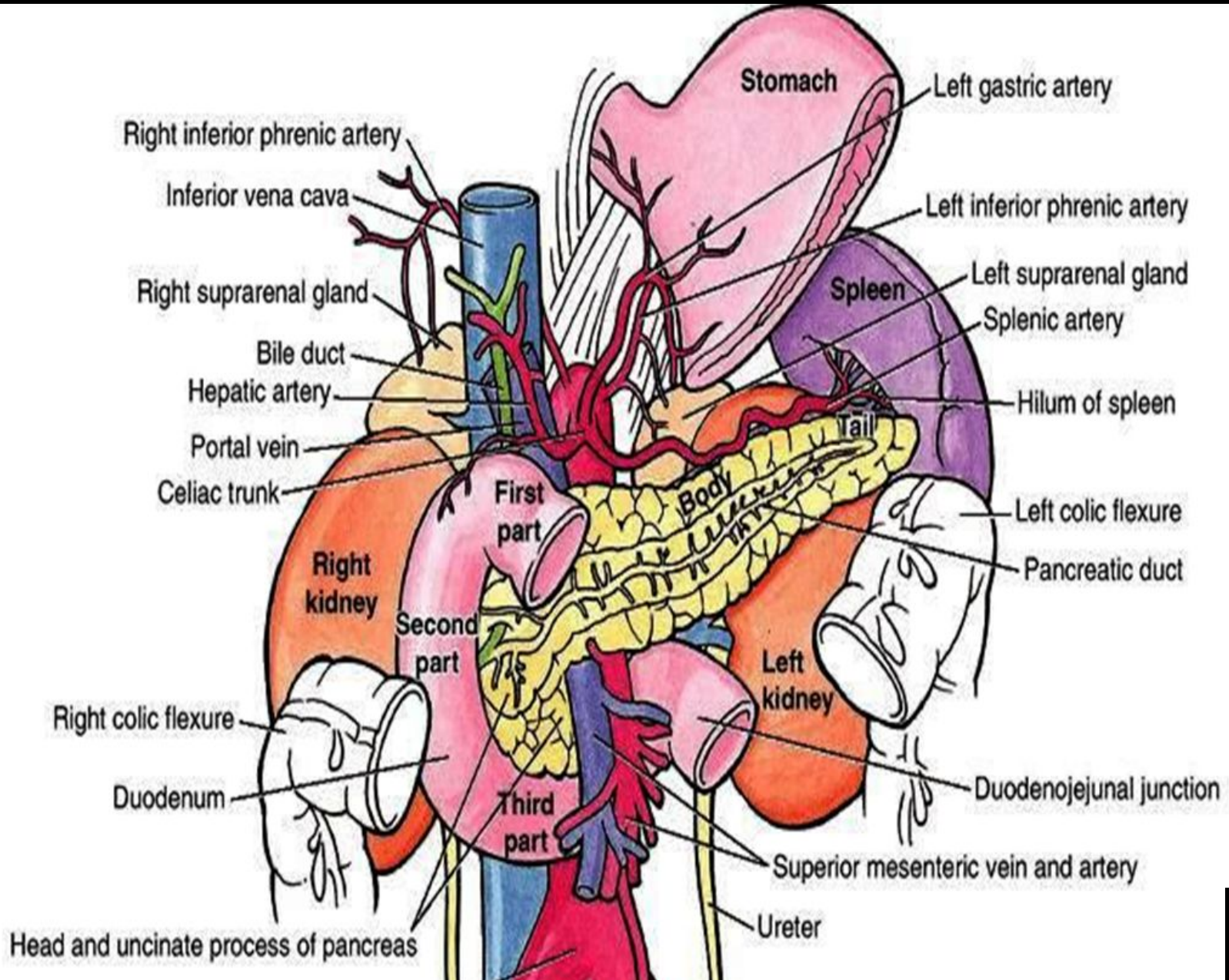
Renal fat and fascia

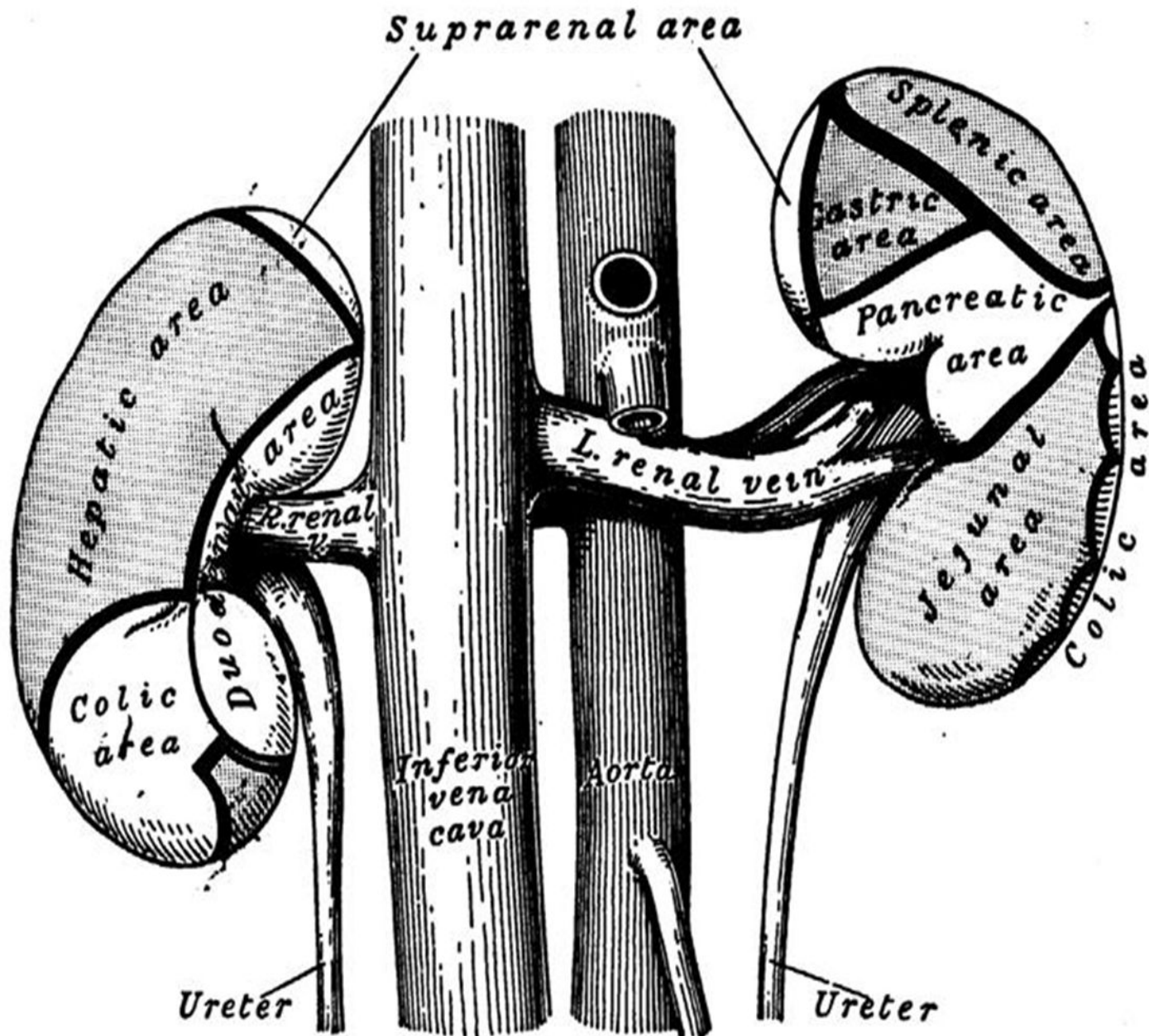
Anterior relations of Right kidney

- **The upper pole is covered by suprarenal gland.**
- **Three-fourth of this surface below suprarenal gland is related to right lobe of liver.**
- **The remaining area is related to the right colic flexure.**
- **The 2nd (descending) part of duodenum descends along the medial border of right kidney.**

Anterior relation of right kidney

A



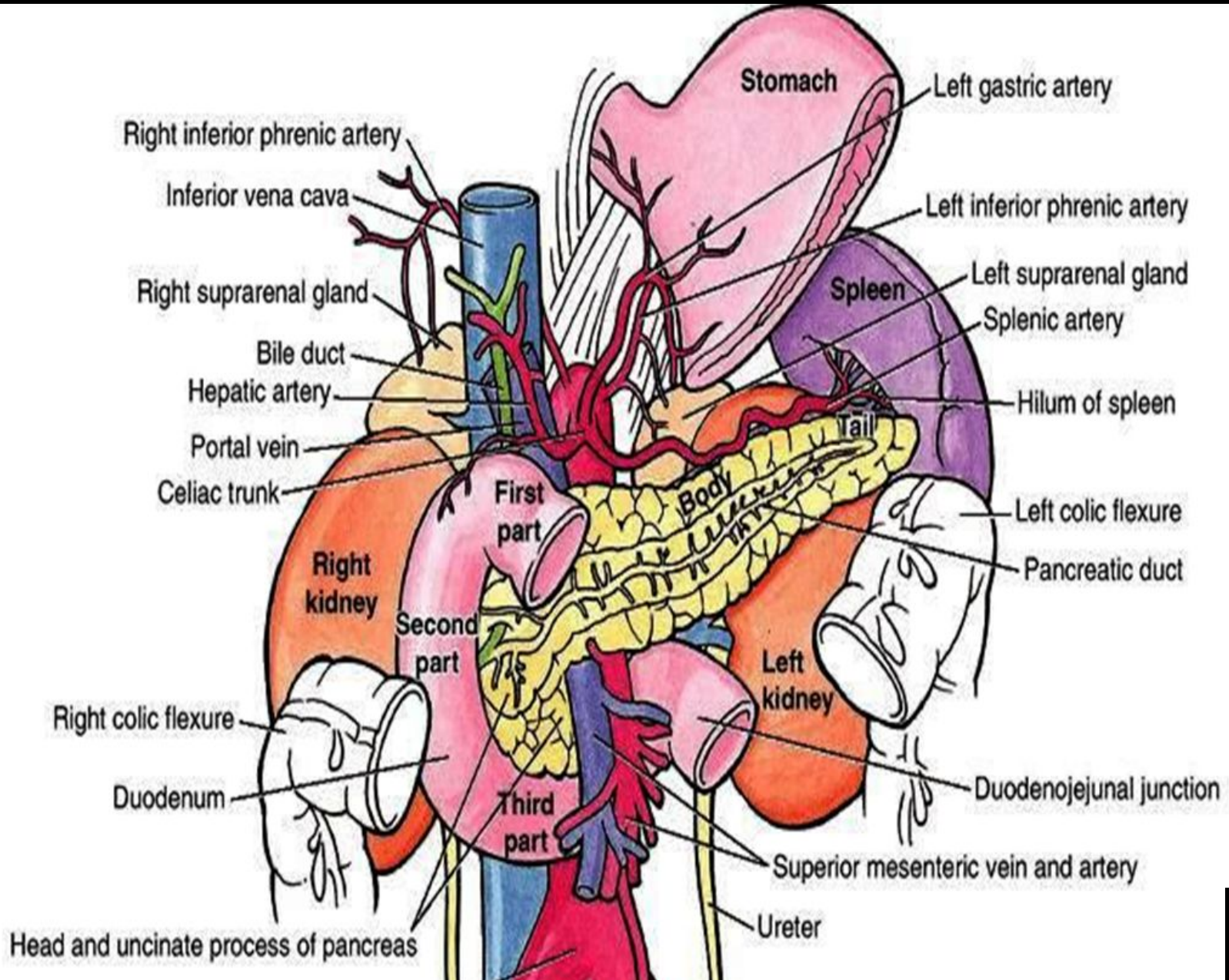


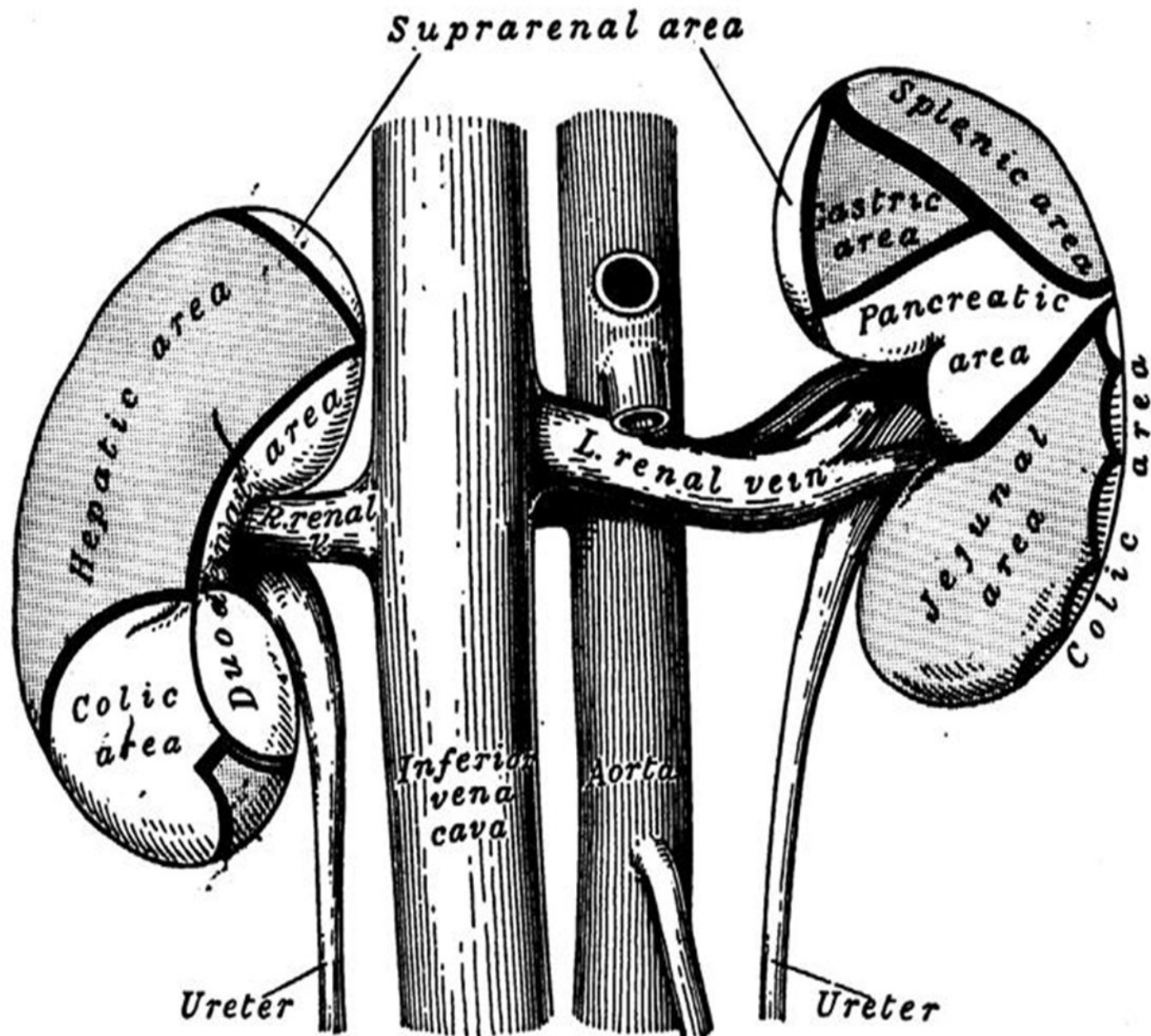
Anterior relations of left kidney

- **Is related to the suprarenal gland, spleen, stomach, pancreas, left colic flexure, and coils of jejunum.**

Anterior relation of left kidney

A

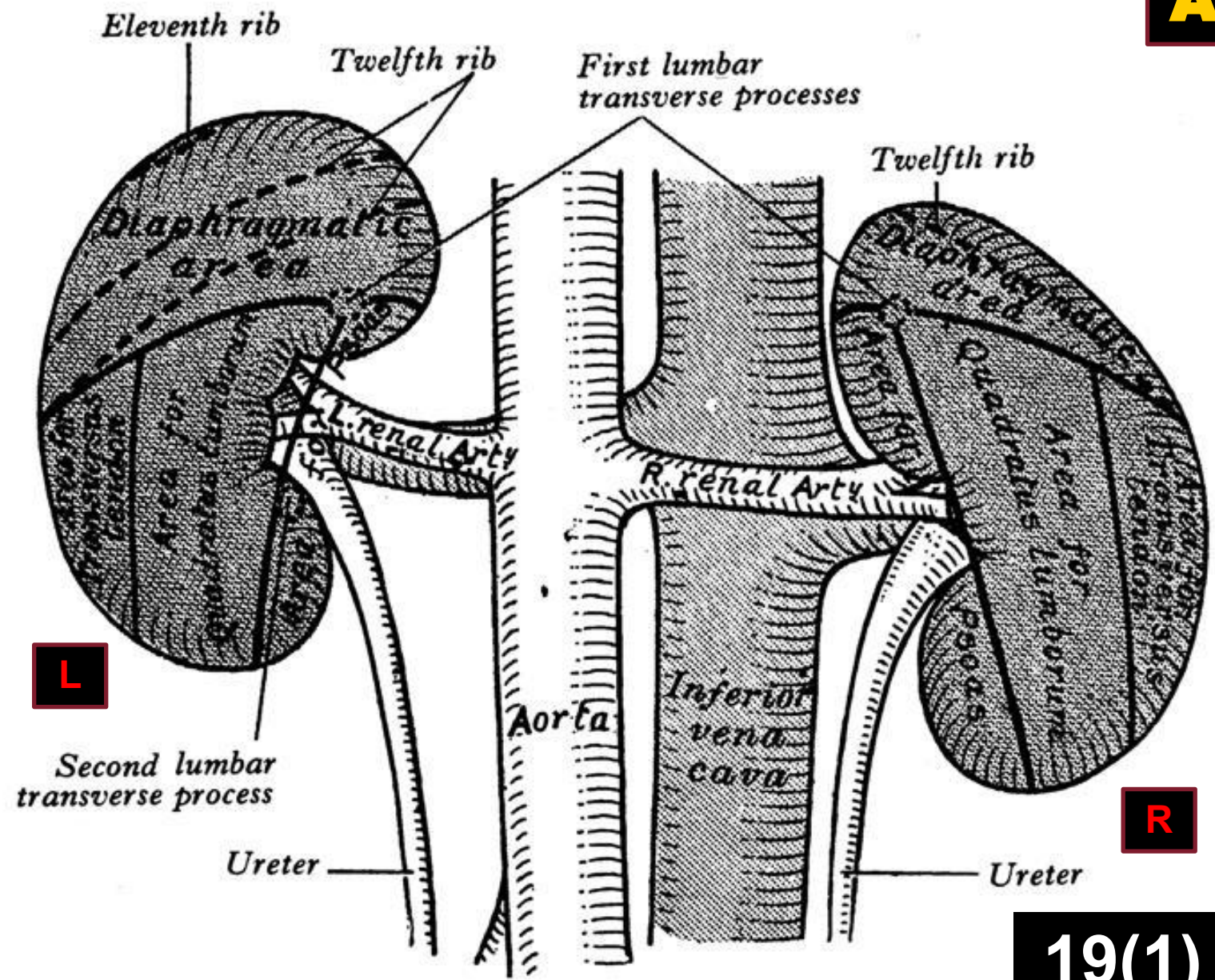




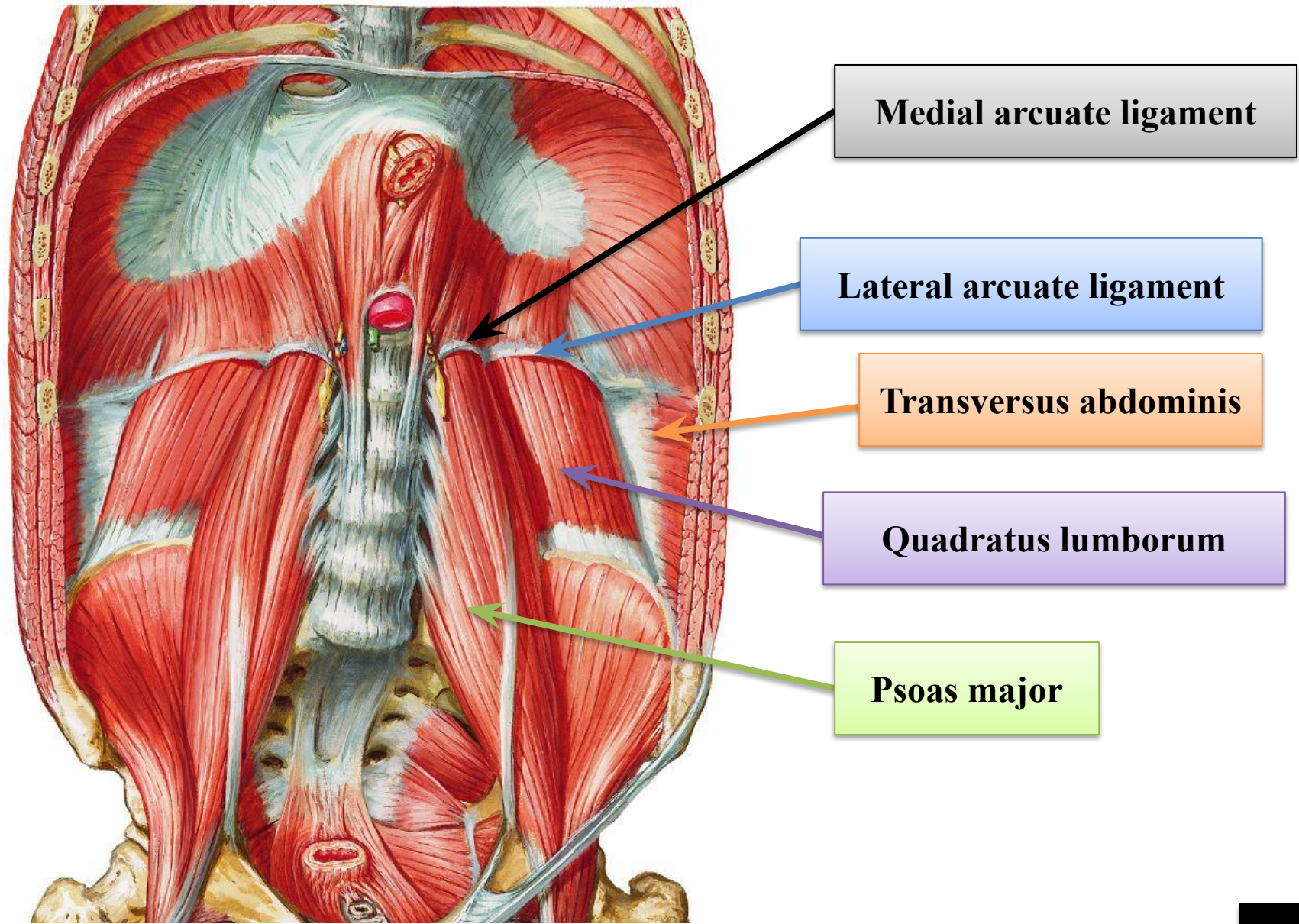
Anterior relation of left kidney

Posterior relations

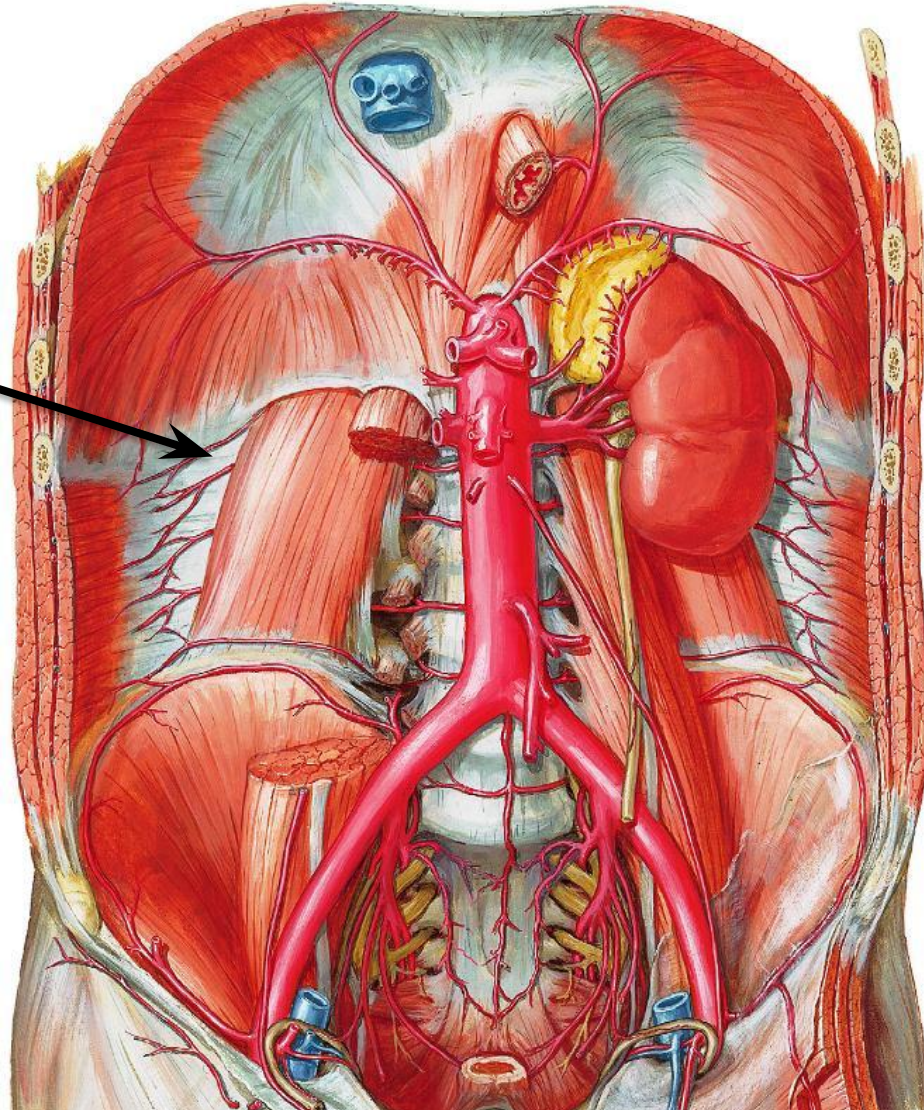
- The posterior surface of the kidneys is devoid of the peritoneal covering.
- Both kidneys are related to the diaphragm, the medial and lateral arcuate ligaments, the psoas major, quadratus lumborum and transversus abdominis muscles, the subcostal vessels, and the subcostal, iliohypogastric and ilioinguinal nerves.
- The upper pole of the right kidney is related to the twelfth rib; the left to the eleventh and twelfth ribs.



Posterior relations of the kidneys

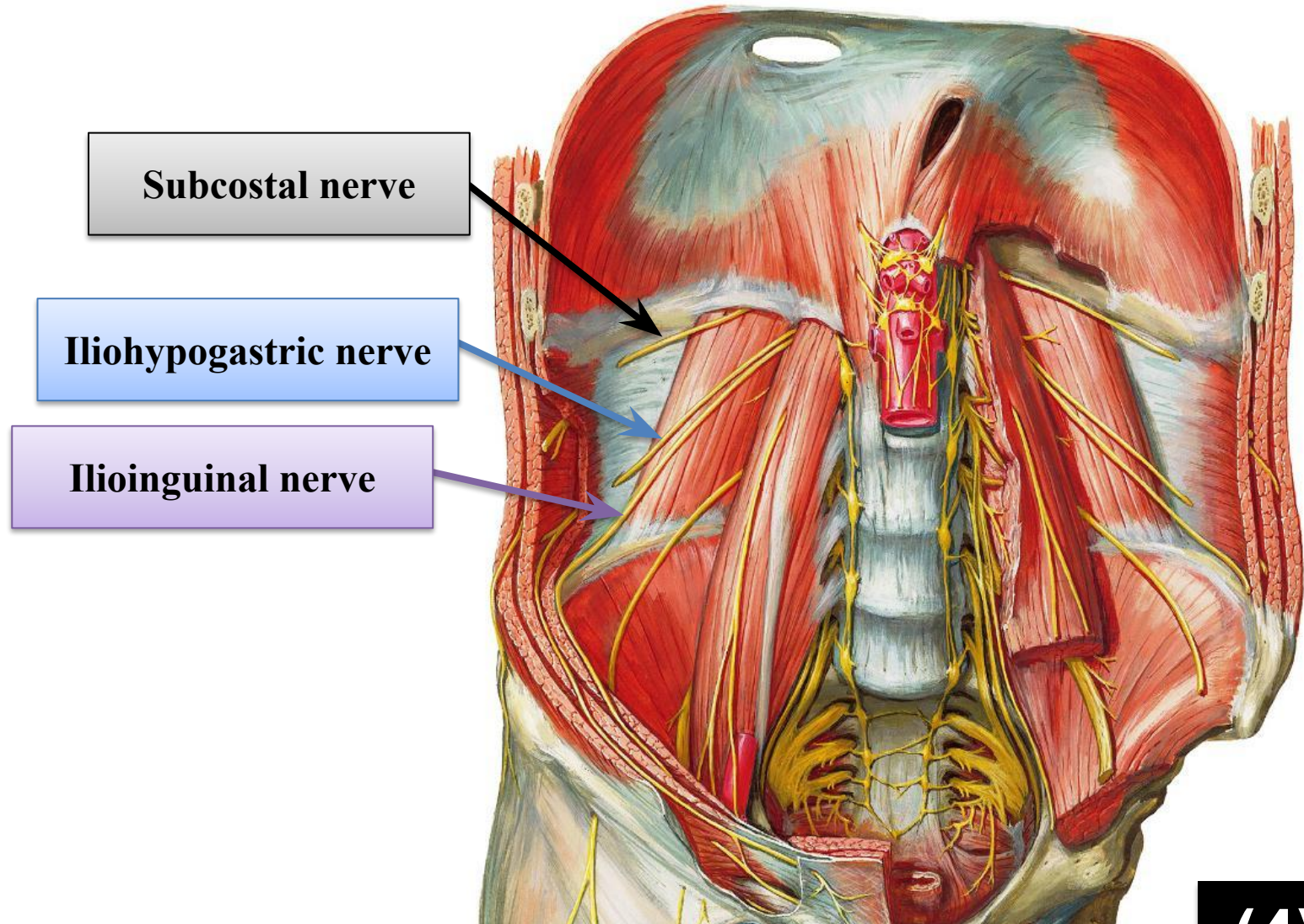


Subcostal artery



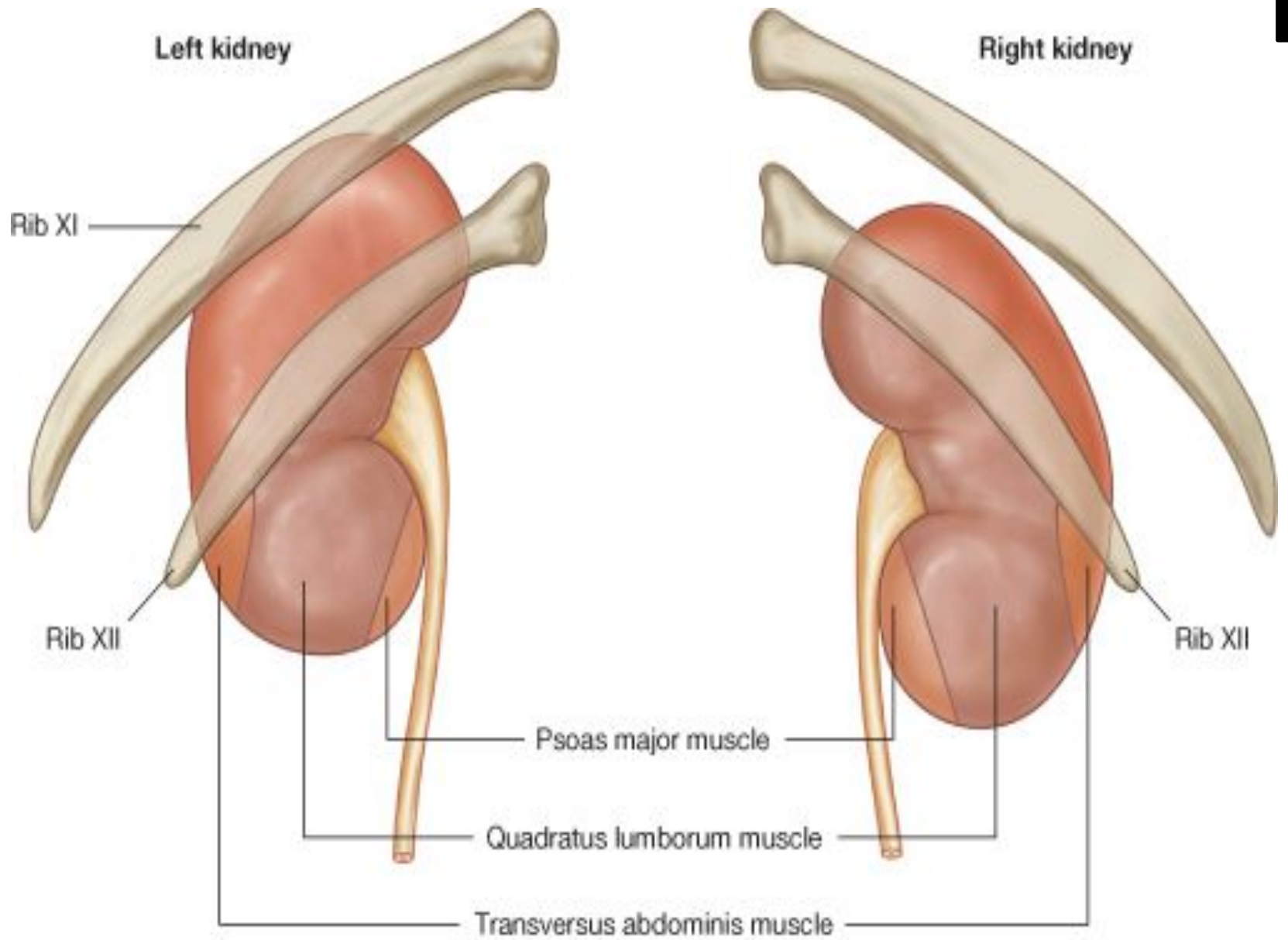
(3)19

Posterior relations of the kidneys



(4)19

Posterior relations of the kidneys



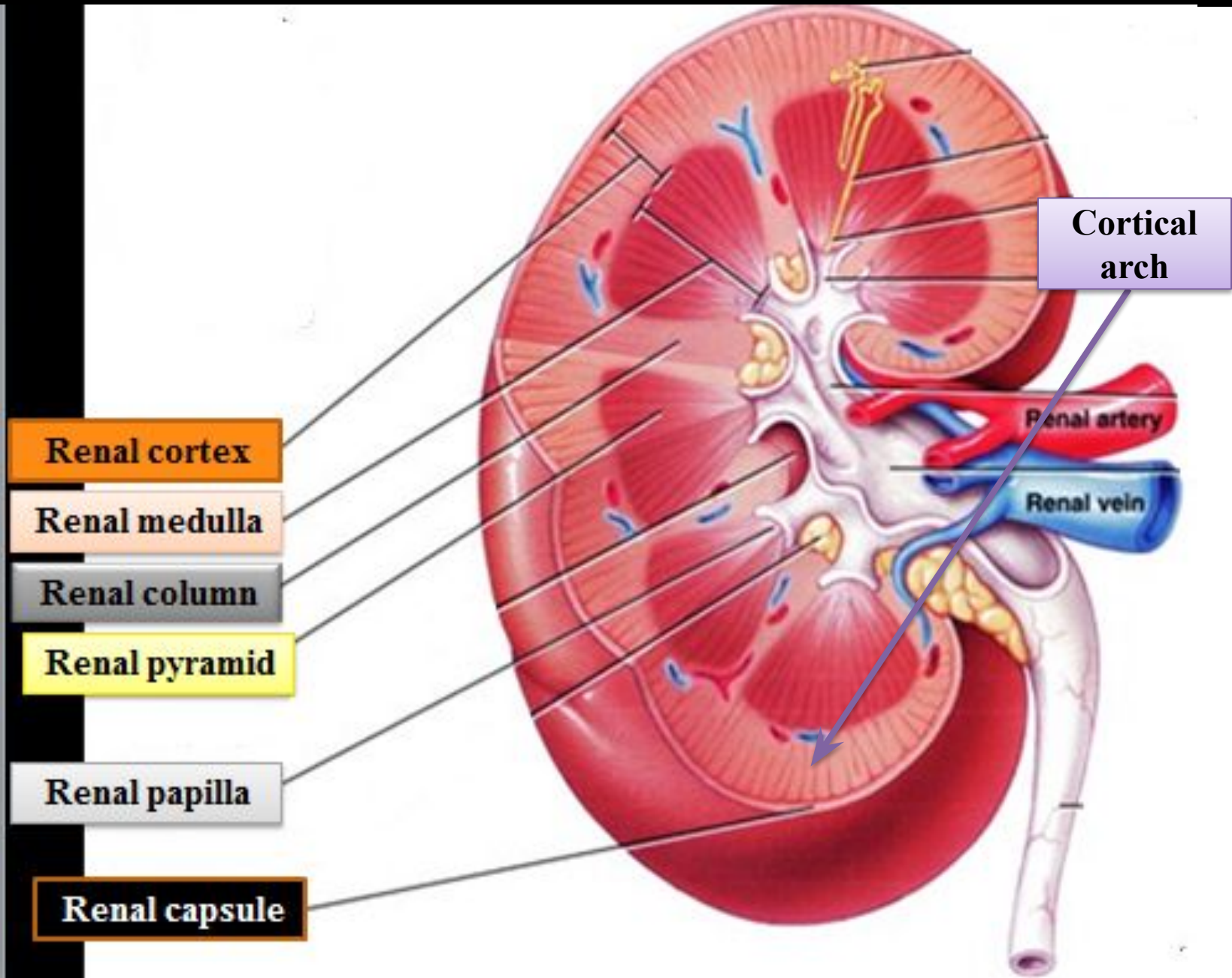
- **A frontal (sagittal) section through the kidney reveals two distinct regions: a superficial, paler area called the cortex, which is granular to the naked eye, and a deep darker area called the medulla.**
- **The medulla is composed of about 12 – 20 conical masses termed the renal pyramids, each having its base oriented toward the cortex, and its apex, the renal papilla, projects medially into the interior of a minor calyx.**

- **Renal pyramids are separated by cortical tissue called renal (cortical) column.**
- **The region of the cortex between the bases of the pyramids and fibrous capsule are called the cortical arches or cortical lobules**
- **Extending from the bases of renal pyramids into cortical arches are striations of medullary tissue called the medullary rays.**
- **The hilum of the kidney leads into a large cavity in the kidney devoid of renal tissue called the renal sinus.**

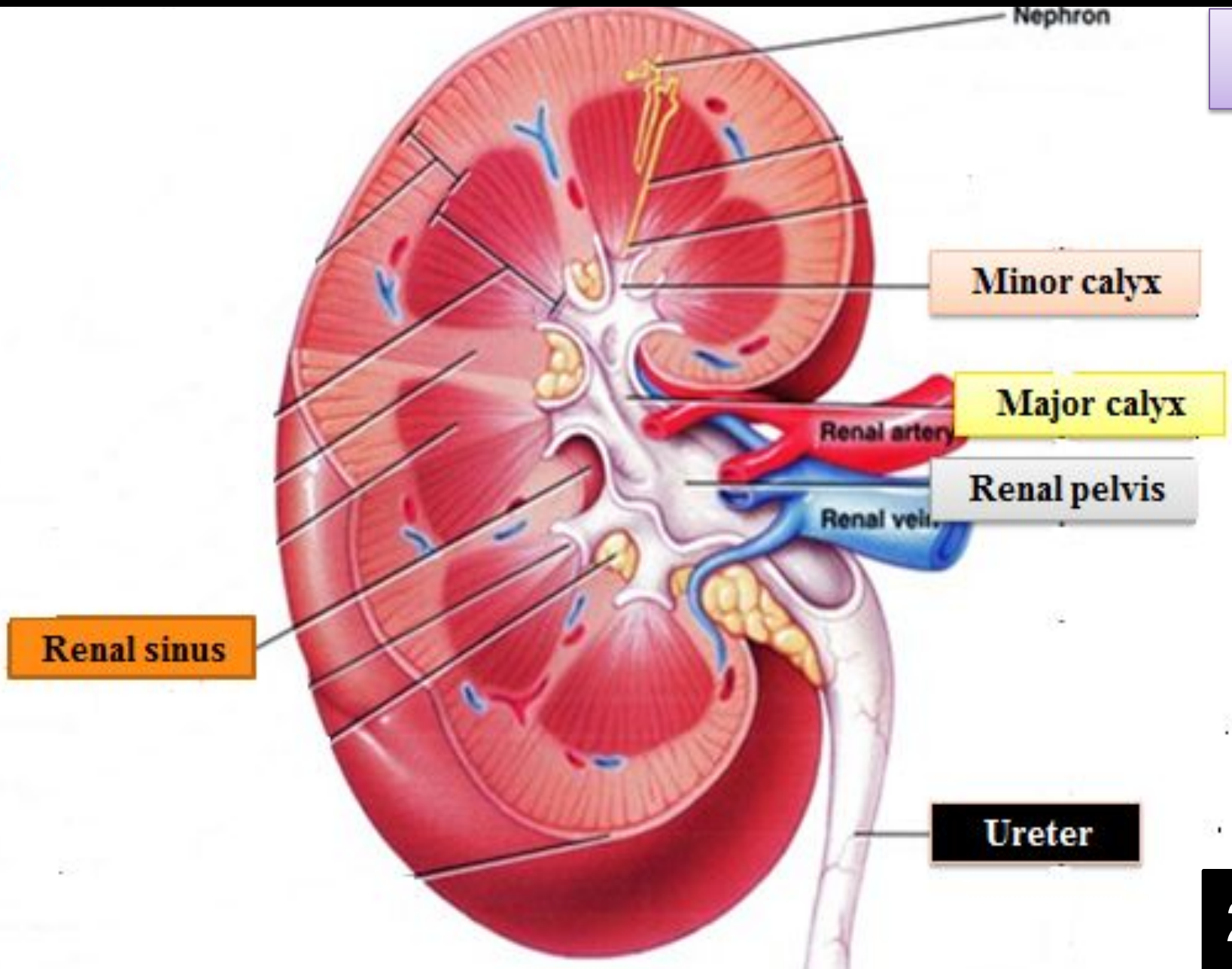
- **The renal sinus is occupied by the renal pelvis, (the dilated upper part of ureter).**
- **Renal pelvis is divided into 2 – 3 major calyces, each of which divides into 2 – 3 minor calyces.**
- **Each minor calyx receives from 1 – 3 renal papillae.**

Sagittal section through kidney

A



Sagittal section through kidney

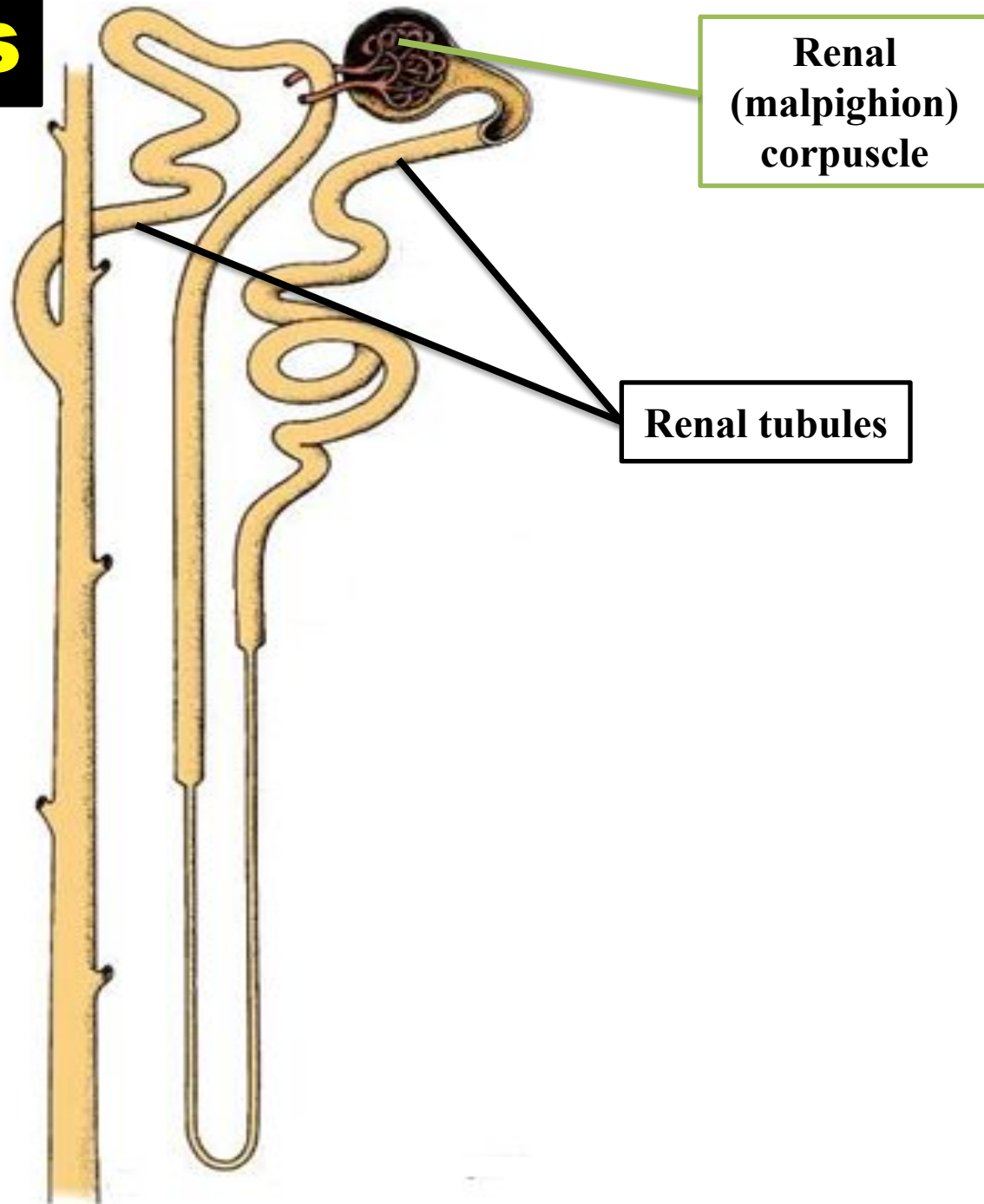


B

Nephrons

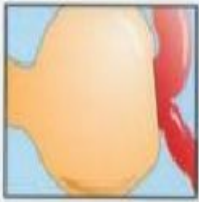- **Each kidney is composed of 1 – 4 million nephrons.**
- **The nephron is the functional unit of the kidney.**
- **It consists of renal (malpighion) corpuscle and renal tubules.**

Nephrons



a. Renal (Malpighion) corpuscle

- **Is the dilated proximal portion of the nephron.**
- **It consists of tuft capillaries, the glomerulus, surrounded by a double layer of epithelial capsule called glomerular (Bowmans) capsule.**
- **The external layer (parietal layer) of the glomerular capsule consists of simple flattened squamous epithelium supported by basement membrane.**
- **The internal layer (visceral layer) of the Bowman's capsule envelops the glomerulus.**



Renal corpuscle (external view)

Parietal layer

Afferent arteriole

Mesangial cell

Juxtaglomerular cell

Capsular space

Macula densa

Proximal convoluted tubule

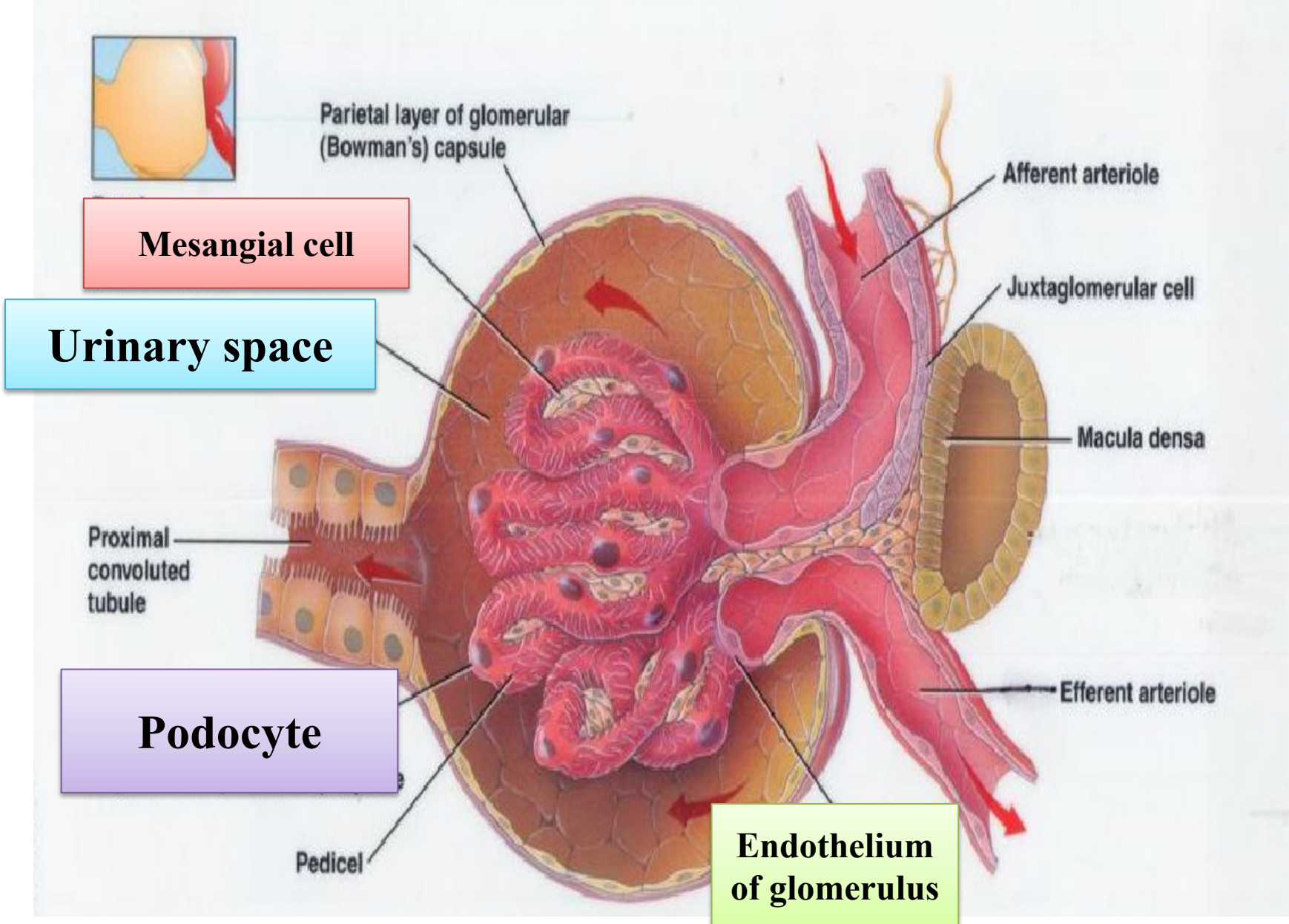
Visceral layer

Efferent arteriole

Pedicle

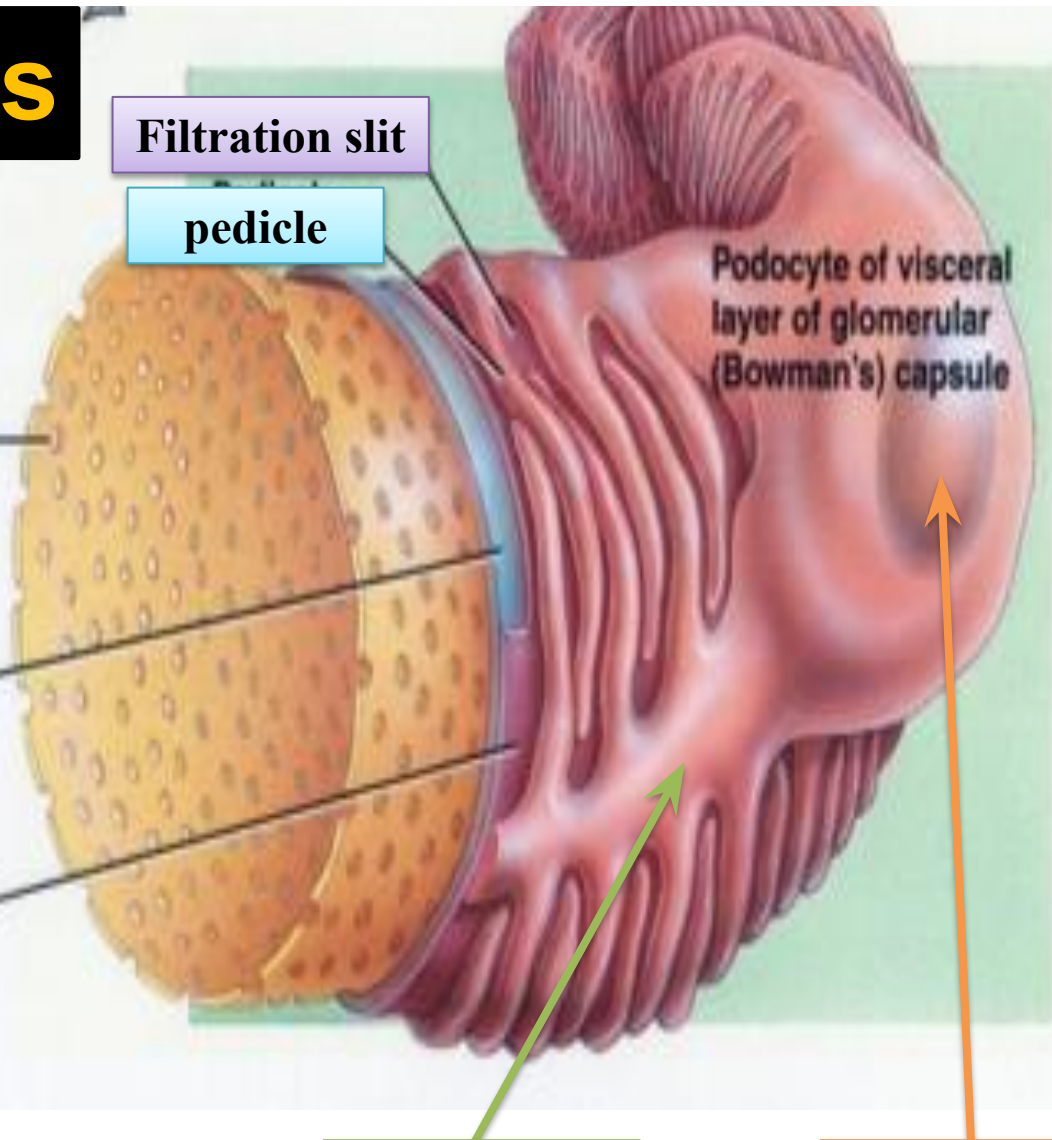
Endothelium of glomerulus

- **This layer is made up of very specialized epithelial cells called the podocytes, have a cell body from which arise several primary processes.**
- **Each primary process gives rise to numerous secondary processes called pedicles.**
- **The pedicles interdigitate, defining elongated spaces, the filtration slits.**



The podocytes

- 1 Fenestration (pore) of glomerular endothelial cell: prevents filtration of blood cells but allows all components of blood plasma to pass through
- 2 Basal lamina of glomerulus: prevents filtration of larger proteins
- 3 Slit membrane between pedicels: prevents filtration of medium-sized proteins



Primary process

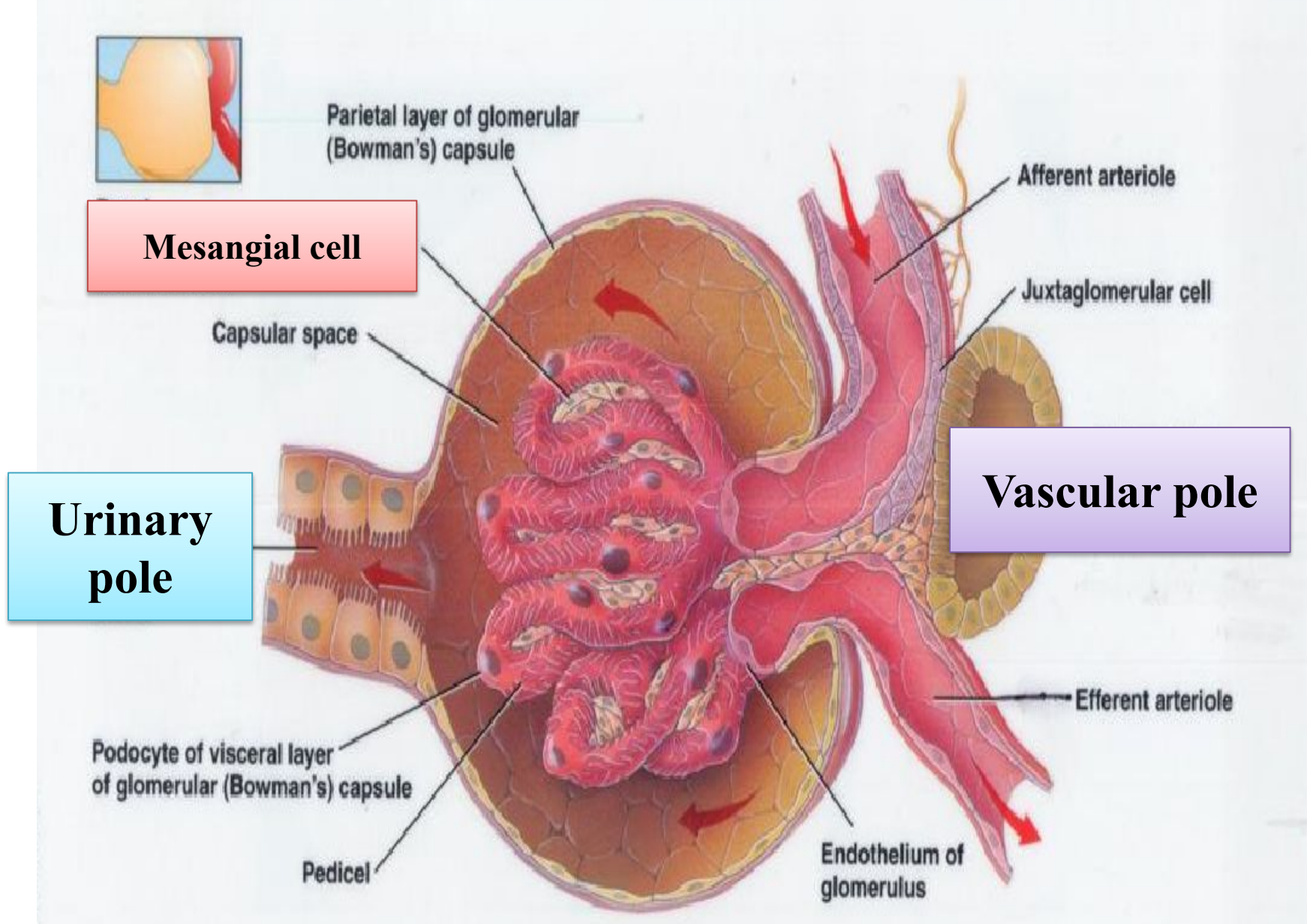
Body of pedicle

- **Between the two layers of the glomerular capsule is the urinary space, which receives fluid filtrated through the capillary wall and the visceral layer.**
- **Between endothelial cells of glomerular capillaries and podocytes that cover their external surface is a thick basement membrane.**
- **This membrane is believed to be the filtration barrier that separates urinary space and blood in the capillaries.**

- **This basement membrane has a selective macromolecular filter.**
- **Particles greater than 10 nm in diameter do not readily pass through the basal lamina.**
- **The glomeruli are composed of arterial capillaries in which hydrostatic pressure—about 4.5 mm Hg— which is higher than that found in other capillaries.**
- **The endothelial cells of glomerular capillaries are of fenestrated capillaries.**

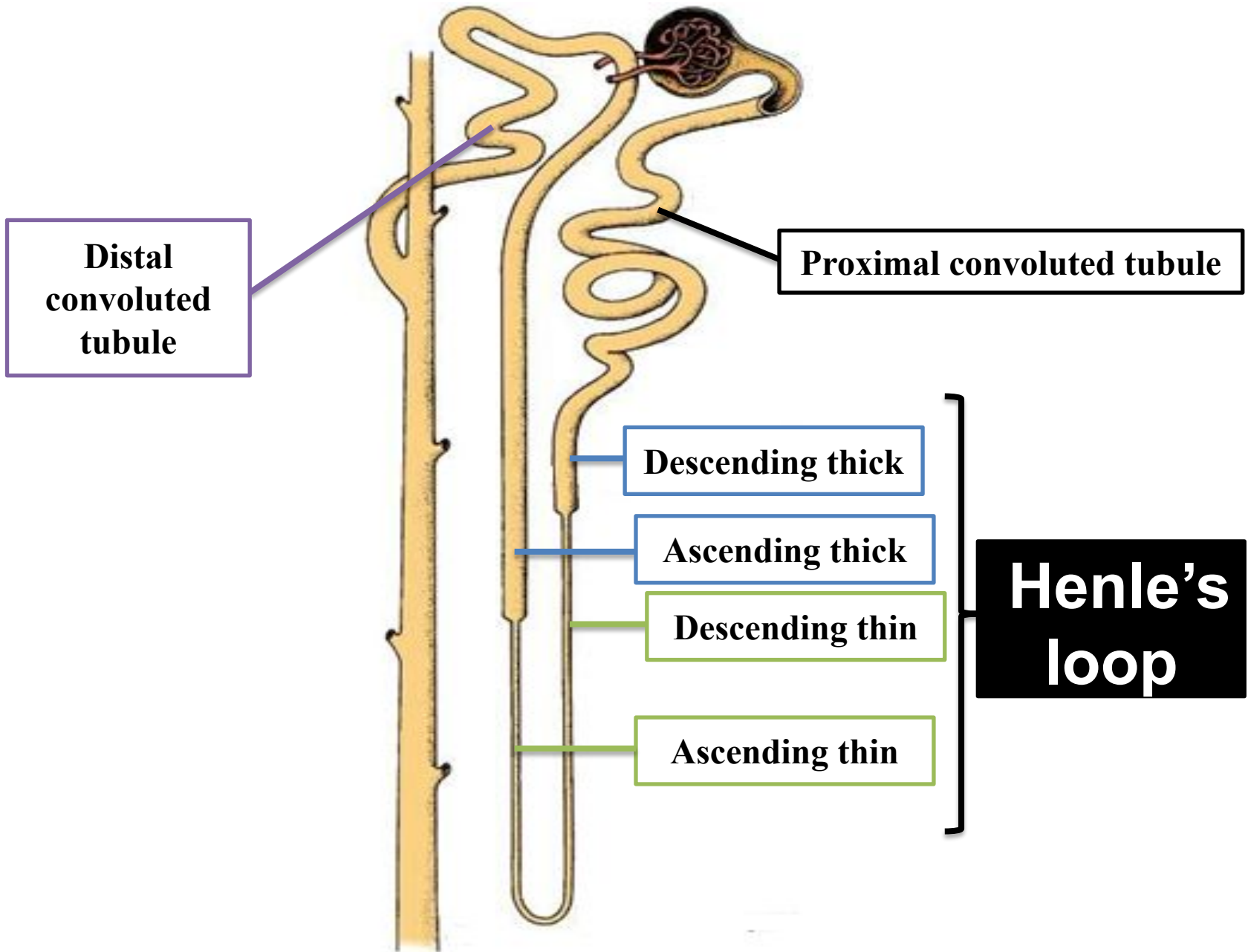
- In addition to endothelial cells and podocytes, the glomerular capillaries have mesangial cells adhering to their walls.
- These cells are contractile and have receptors for angiotensin II.
- When these receptors are activated, the glomerular flow is reduced.
- Mesangial cells also have receptors for natriuretic factor produced by cardiac atrial cells.
- This factor is a vasodilator and relaxes. 35

- **The mesangial cells, probably increasing the blood flow and the effective surface area available for filtration.**
- **The renal corpuscle has a vascular pole, where the afferent arteriole enters and the efferent arteriole leaves, and a urinary pole, where the proximal tubule begins.**



b. Renal tubules:

- **These are tubules into which the filtered fluid passes.**
- **It is concerned with the selective resorption of substances from the glomerular filtrate until it approaches the composition of urine.**
- **It consists: The proximal convoluted tubule, the Henle's loop, and the distal convoluted tubule.**



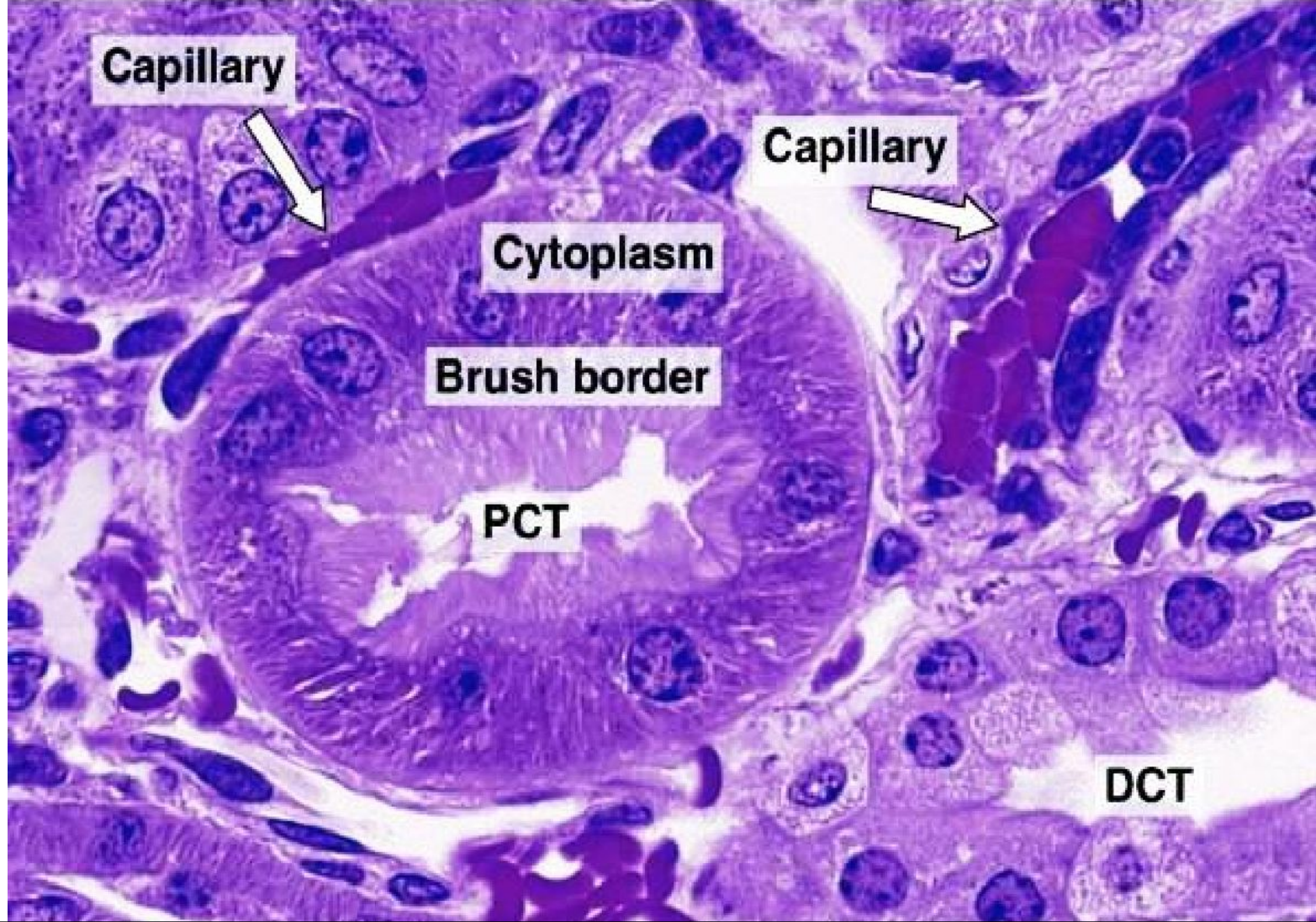
Renal Tubules

(1) Proximal convoluted tubule:

- **Is lined by simple cuboidal or low columnar epithelium.**
- **The upper border of these cells has abundant microvilli, which form a brush border, indicating that these cells have a resorptive function.**
- **Substances resorbed actively in this part of the tubule include glucose, amino acid, sodium, chloride, and phosphate.**

- **Because the cells are large, each transverse section of a proximal tubule contains only 3 – 5 spherical nuclei.**

41



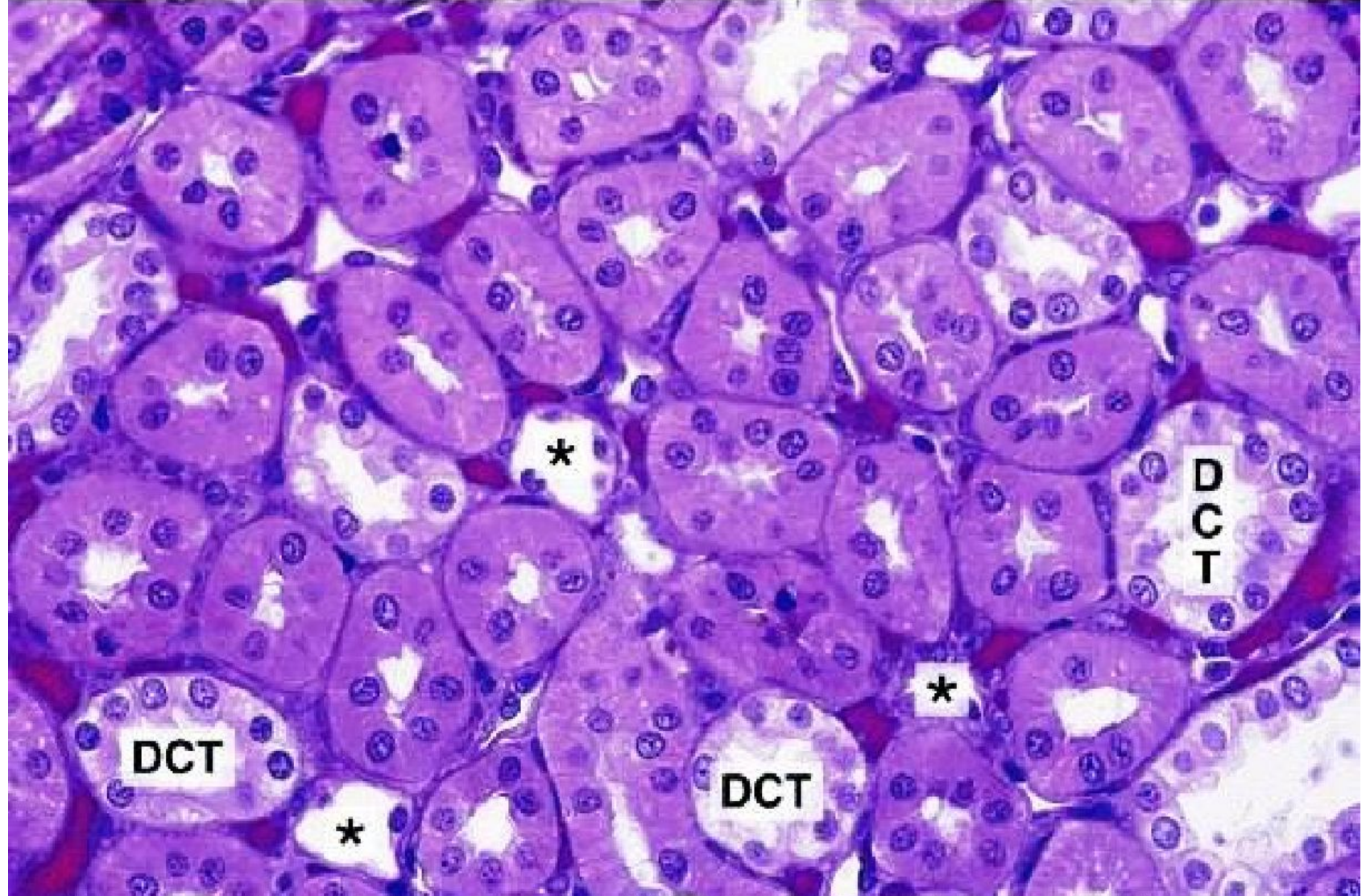
Section through the cortex region of the kidney showing the proximal and distal convoluted tubules (PCT and DCT, respectively).

(2) Henle's loop:

- Is a U-shaped structure consisting of: descending thick limb, descending thin limb, ascending thin limb, and ascending thick limb.**
- The thick limbs of the Henle's loop are very similar in structure to the distal convoluted tubules.**
- Whereas the thin segments are lined by simple squamous epithelium whose nuclei bulge into the lumen.**

(3) Distal convoluted tubule:

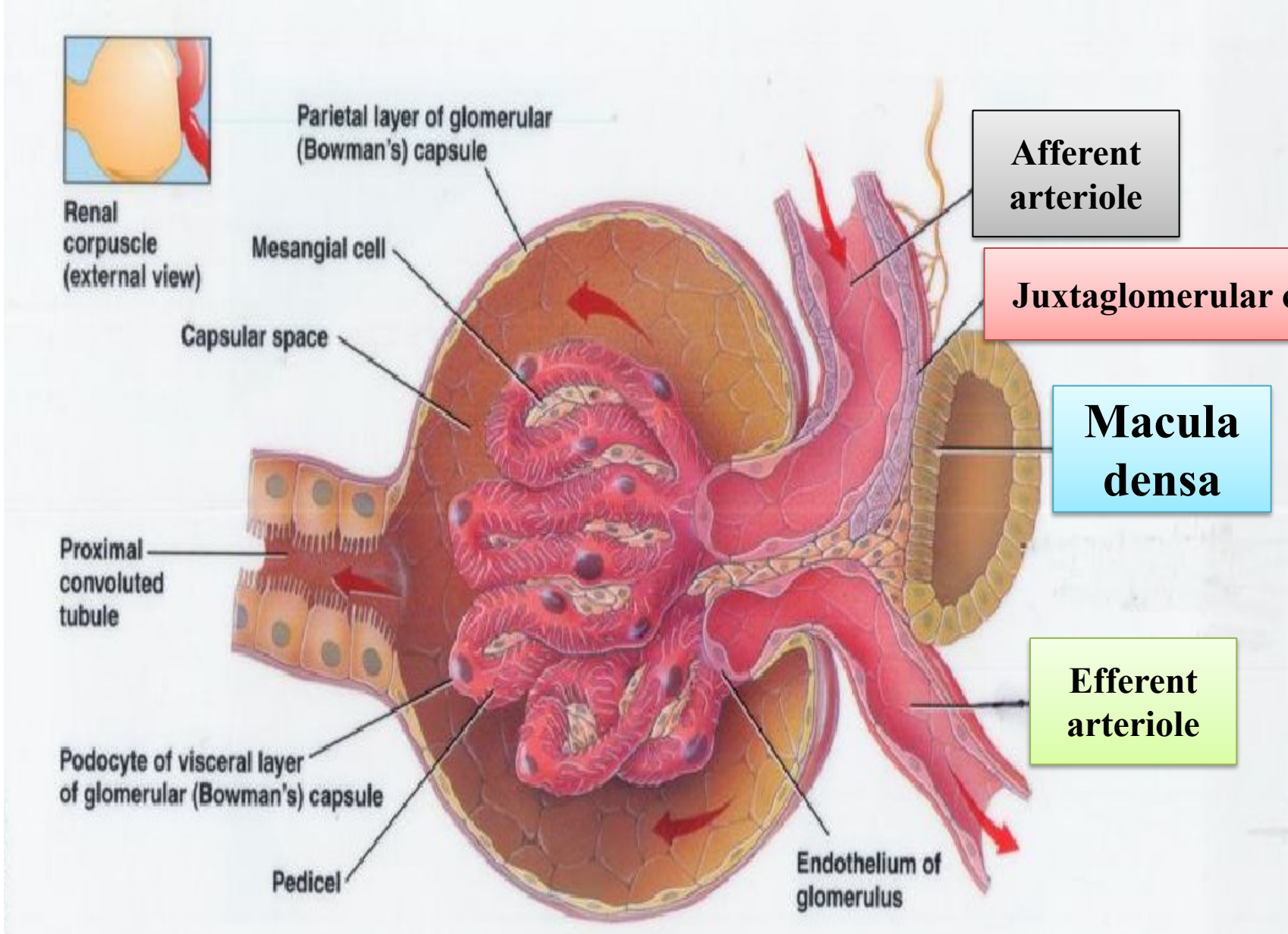
- Is shorter than the proximal convoluted tubule and differ from it (both found in cortex).
- The lining epithelium has no brush border and the cells are smaller.
- Since the distal convoluted tubule cells are flatter and smaller than those of the proximal tubule, more nuclei are seen in transverse section of a distal convoluted tubule.



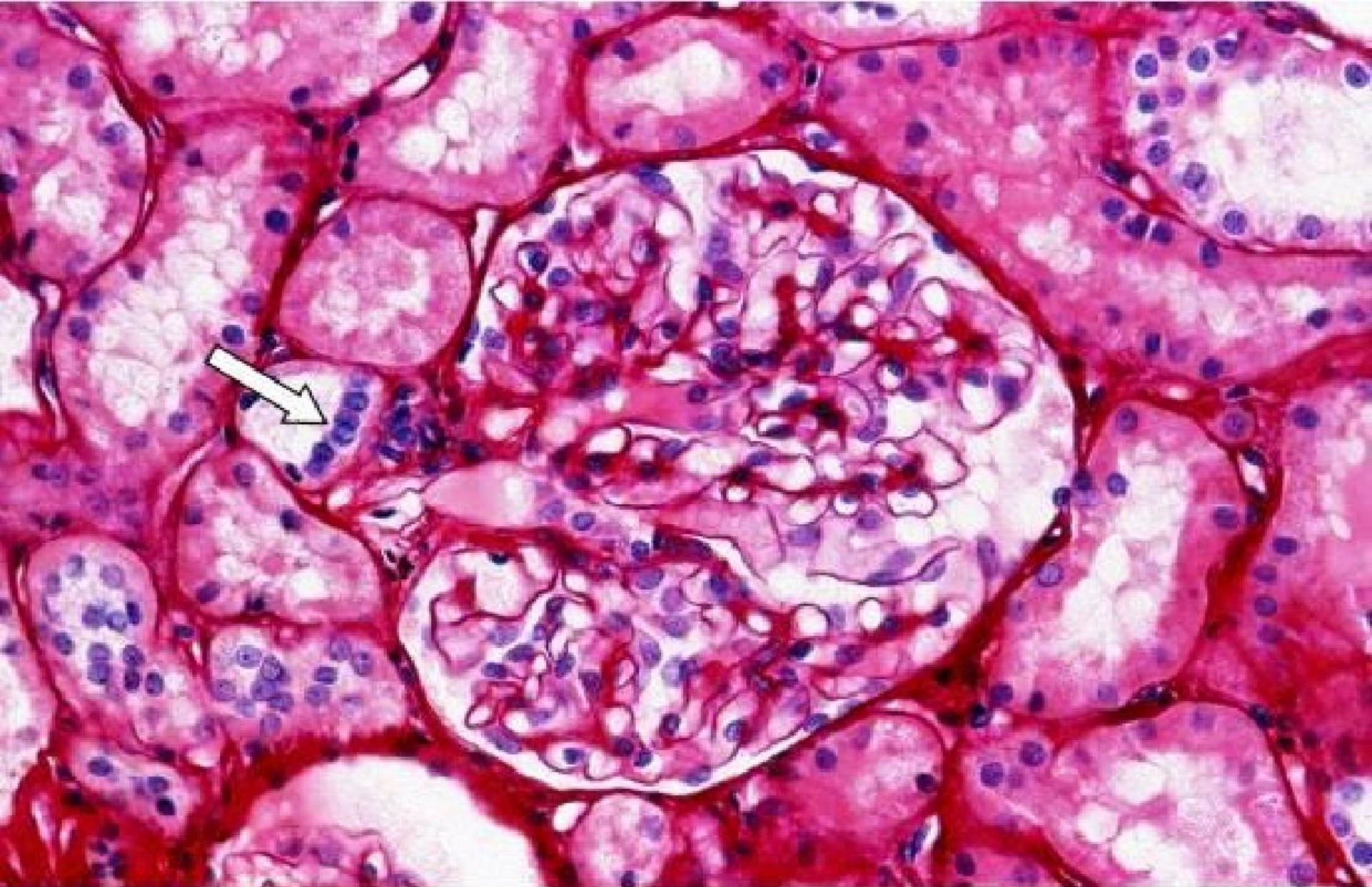
Section through the cortex region of the kidney showing the proximal, distal convoluted tubules (DCT) and thin segments of Henle's loop (*). 45

- **The first coil of distal convoluted tubule lies in angle between afferent and efferent arterioles.**
- **The cells of the tunica media of the afferent arteriole in this region are differ from the usual smooth muscle fibers in that they are large rounded epithelioid cells containing a large spherical nucleus and a granular cytoplasm.**
- **These cells are called juxta-glomerular cells and they are in close contact with cells of distal convoluted tubule, which in this region approach the columnar form and are aggregated so that the nuclei appear close together.**

- **This region of the tubule is called the macula densa .**
- **The two groups of cells (juxta-glomerular cells and macula densa) constitute juxtaglomerular complex or apparatus of the kidney.**
- **Approximately 1/7 of all nephrons is located near the corticomedullary junction, and are therefore called juxtamedullary nephrons.**
- **The other nephrons are called cortical nephrons.**

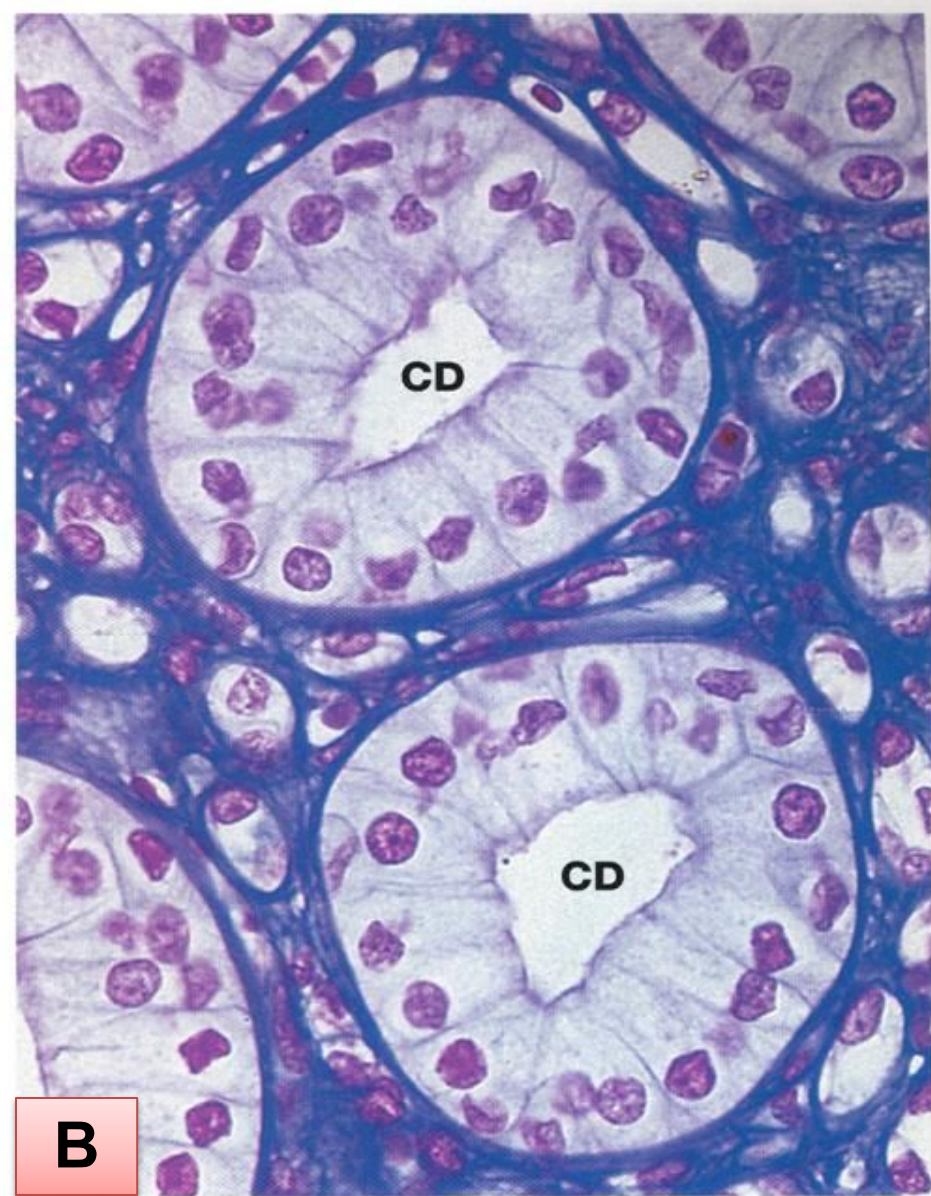
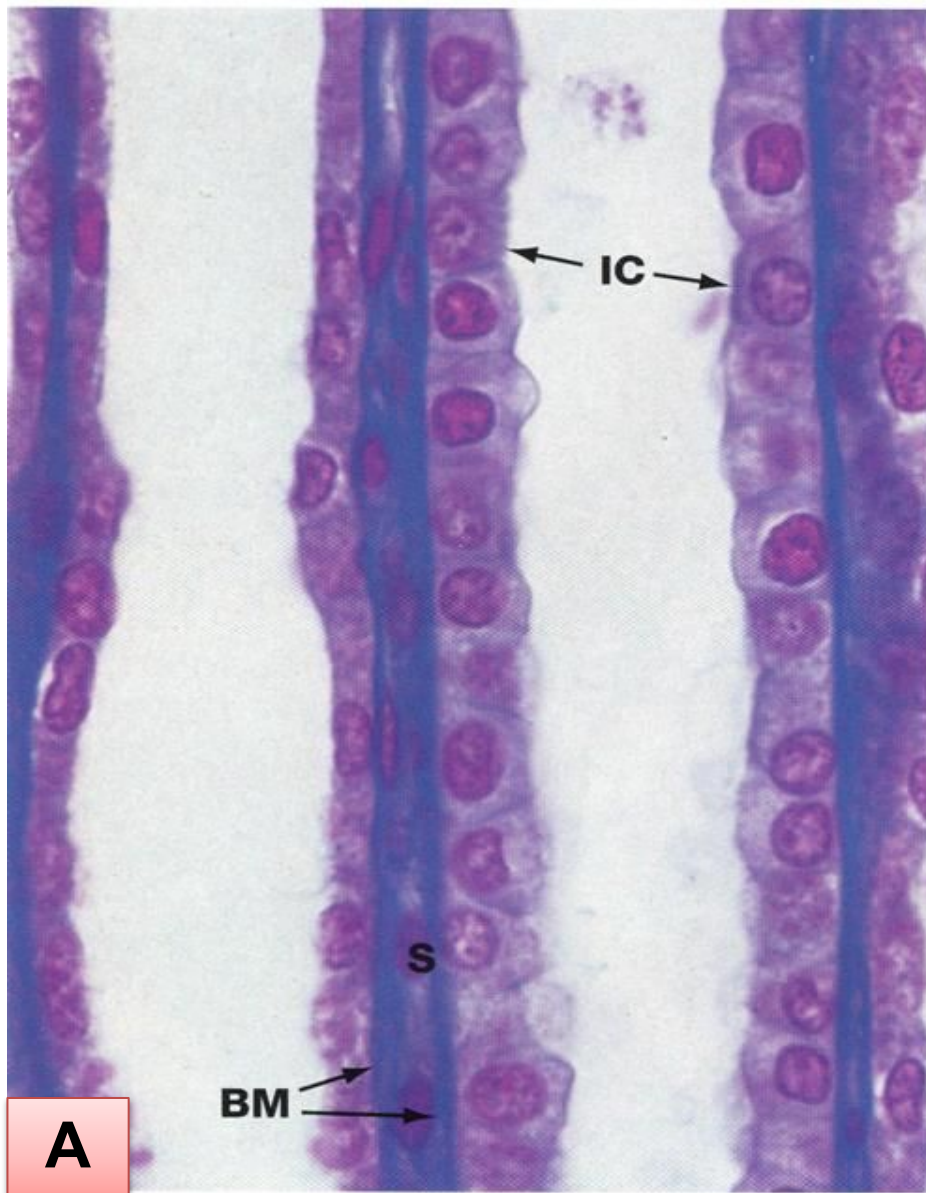


Juxtaglomerular complex (apparatus)



The juxtaglomerular complex, which includes the macula densa (arrow) and the juxtaglomerular cells.

- **The collecting tubules are lined with simple cuboidal epithelium.**
- **The collecting ducts are lined with simple columnar epithelium.**
- **Along their entire extent, collecting tubules and ducts are composed of cells that stain weakly with the usual stains.**
- **They have an electron-lucent cytoplasm with few organelles.**



Section through renal medulla, showing A. Collecting tubules; and B. Collecting ducts (CD).

Blood Supply:

- **Renal artery – Branch of descending abdominal aorta – Opposite L2 vertebra.**
- **Divides into five segmental arteries that enter the hilum of the kidney, four in front and one behind the renal pelvis.**
- **Lobar arteries arise from each segmental artery, one for each renal pyramid.**
- **Before entering the renal lobes, each lobar artery gives off 2 – 3 interlobar arteries, which run through the renal (cortical) column between the renal pyramids.**

- **At the junction of the cortex and the medulla, the interlobar arteries becomes the arcuate arteries, which arch over the bases of the pyramids.**
- **Arcuate arteries give off several interlobular arteries that ascend in the cortex.**
- **These arteries are so named because they pass between lobules of kidney.**
- **A renal lobule is a group of nephrons that open into branches of the same collecting duct.**
- **The afferent glomerular arteries arise as branches of the interlobular arteries.**

- **Each nephron receives one afferent arteriole, which divides into a tangled, ball-shaped capillary network called the glomerulus.**
- **The glomerular capillaries then reunite to form an efferent arteriole that carries blood out of the glomerulus.**
- **The efferent arterioles divide to form the peritubular capillaries, which surround the tubular part of the nephron in the cortex.**

- **Extending from some efferent arterioles are long loop-shaped capillaries called vasa recta that supply the tubular portions of the nephron in the renal medulla.**
- **The peritubular capillaries eventually reunite to form peritubular venules and then interlobular veins, which also receive blood from vasa recta.**
- **Then the blood drains through the arcuate veins to the interlobar veins running between the renal pyramids.**

- **Blood leaves the kidney through a single renal vein that exits at the renal hilum and drains into the inferior vena cava.**

56

Renal capsule

Renal cortex

Renal pyramid
in renal medulla

Interlobular artery

Arcuate artery

Interlobar artery

Segmental artery

Renal artery

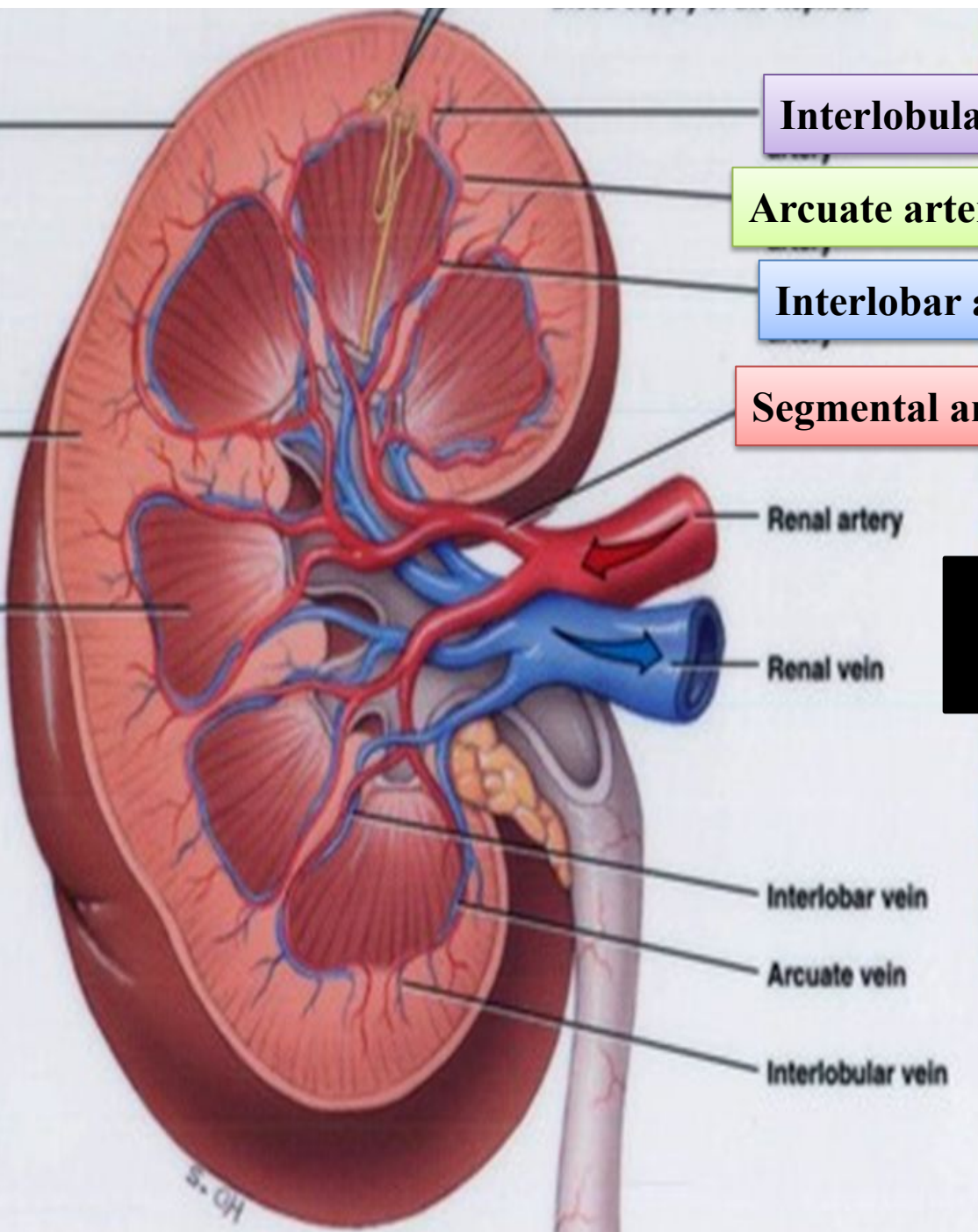
Renal vein

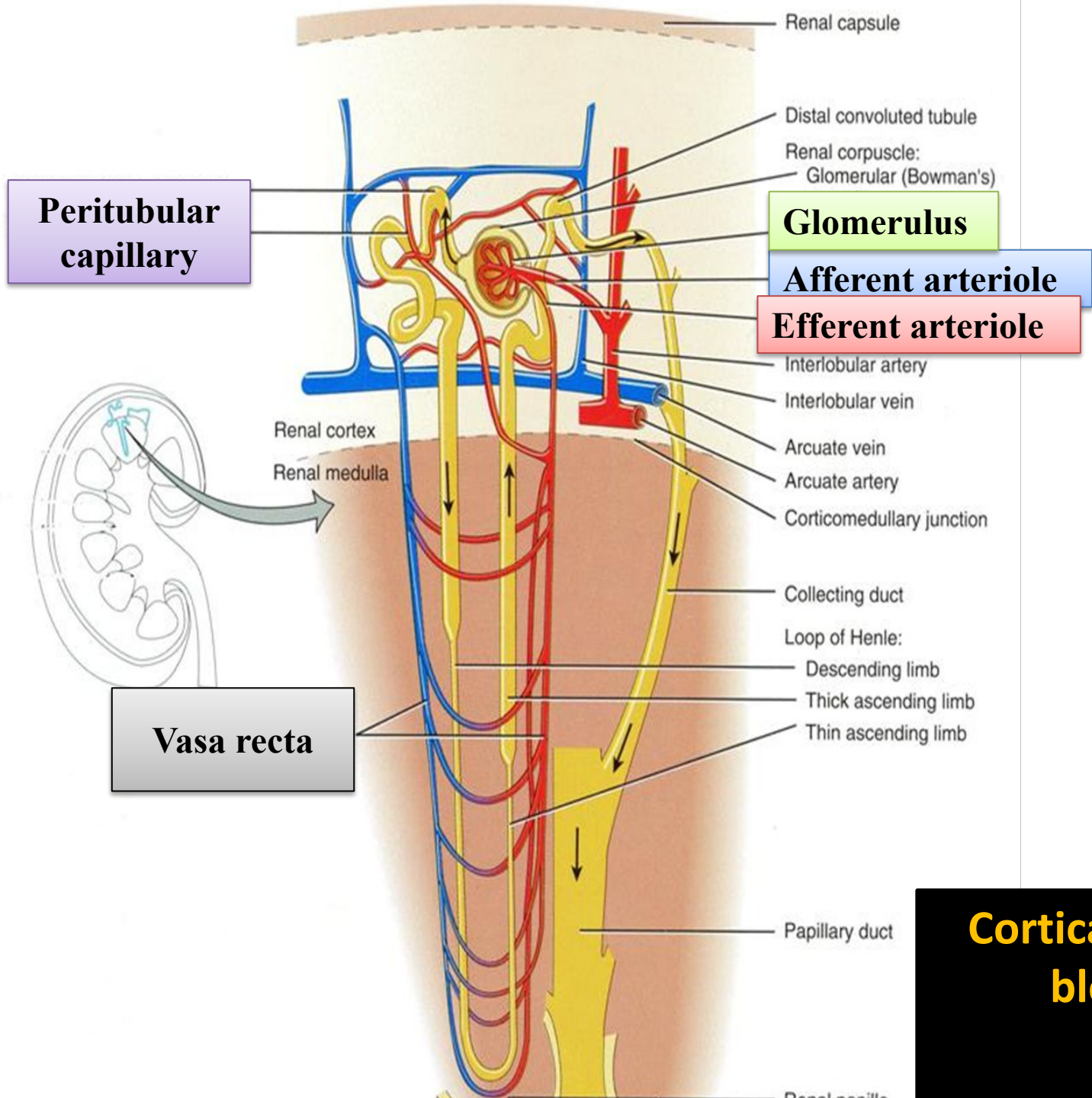
Interlobar vein

Arcuate vein

Interlobular vein

Blood supply of the kidney

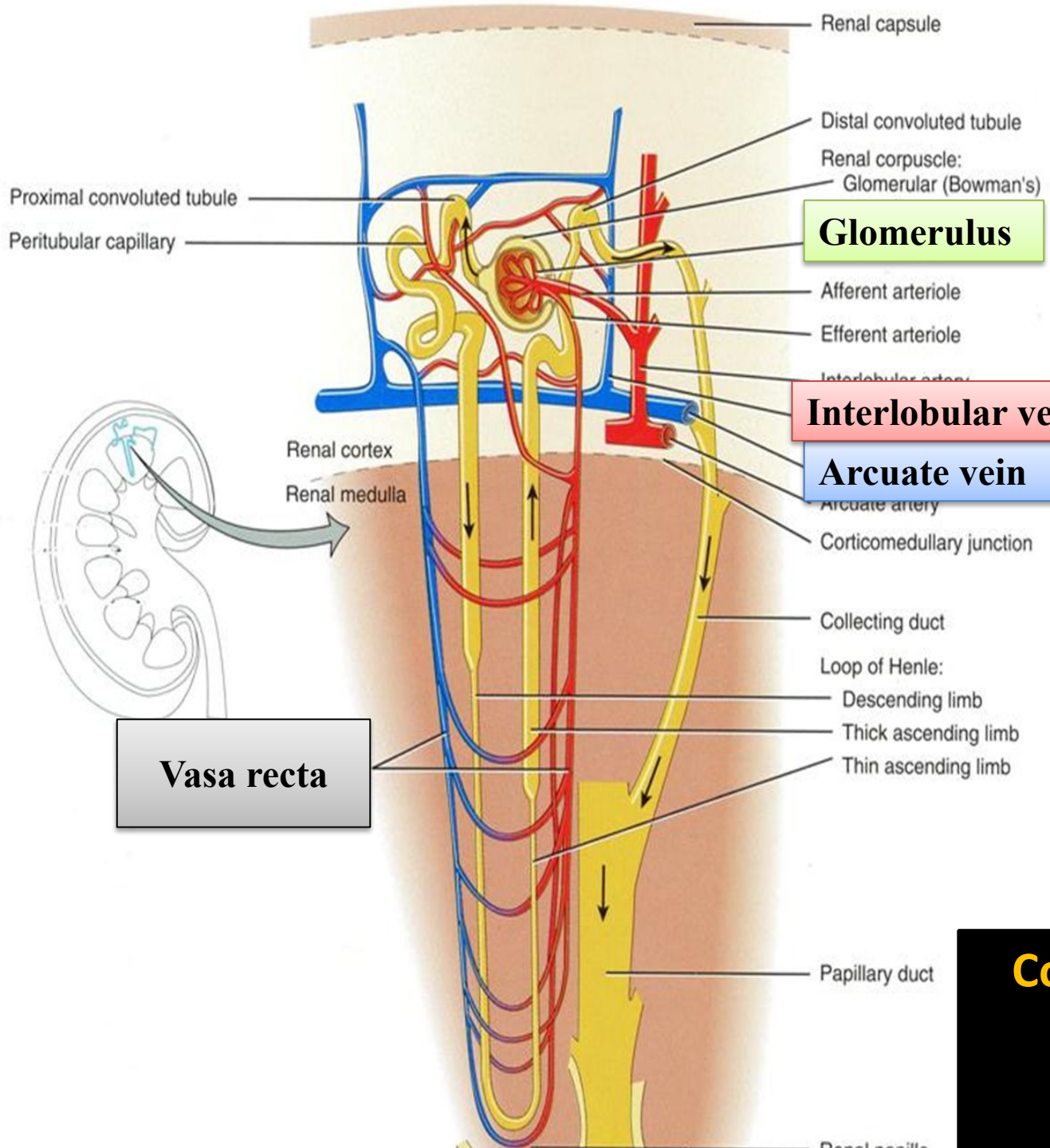




A

Cortical nephron and blood supply

58



B

Cortical nephron and blood supply

59

Nerve Supply of Kidneys

- **Through the renal sympathetic plexus.**
- **The lowest splanchnic nerve is a preganglionic sympathetic fiber from T12 terminates in the celiac ganglia.**
- **Postganglionic sympathetic fibers enter the renal plexus to supply kidney arterioles and the smooth muscle of the renal pelvis.**
- **Visceral afferent fibers that travel through the renal plexus enter the spinal cord in the T10, 11, and 12 spinal nerves.**

Renal Pain

- **Visceral afferent fibers ascend to T12 segment of the spinal cord through the lowest splanchnic nerve.**
- **Pain is commonly referred along the distribution of the subcostal nerve (T12) to the flank and the anterior abdominal wall.**
- **Pain varies from a dull to severe pain, and can result from stretching of renal capsule or spasm of the smooth muscle in renal pelvis.**