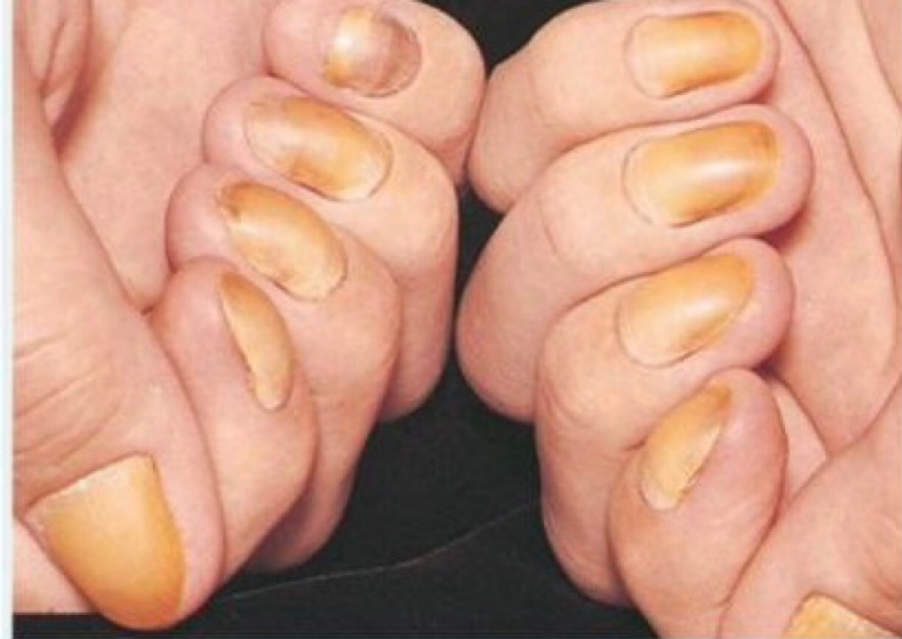

TEST BANK



Done by: Volunteer

Reviewed by:



A 35 year old lady came with SOB on examination confirmed the presence of pleural effusion
?and this image finding,what is your diagnosis
(1 نقطة)

yellow nail syndrome

palmer erythema

spider nevi

erythema nodosum

clipping

?The vital sign consist of all the following except
(1 نقطة)

heart rate

respiratory rate

temperature

O2 saturation

bowel sound

32 years old married female presents to emergency medicine department complaining of abdominal discomfort, during your examination of her you noticed that her abdomen is distended, all of the following are common causes of abdominal distension except (1 نقطة)

Fat

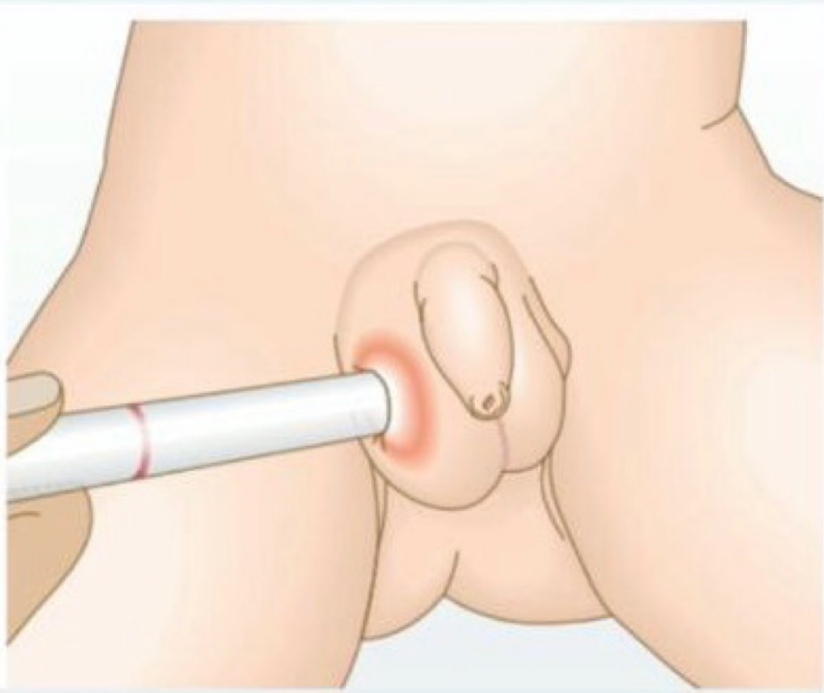Faeces

Fluid

Fetus

Foreign bodies

?Name this test
(1 نقطة)



Transillumination test

light source test

Testes exam

Scrotal support test

Urine test

:Renal colic is characterized by all of the following except
(1 نقطة)

Sudden on onset

Usually bilateral

Radiates to iliac fossa and the groin

May last for several hours

Relived by NSAID

:All the following terms are correct EXCEPT
(1 نقطة)

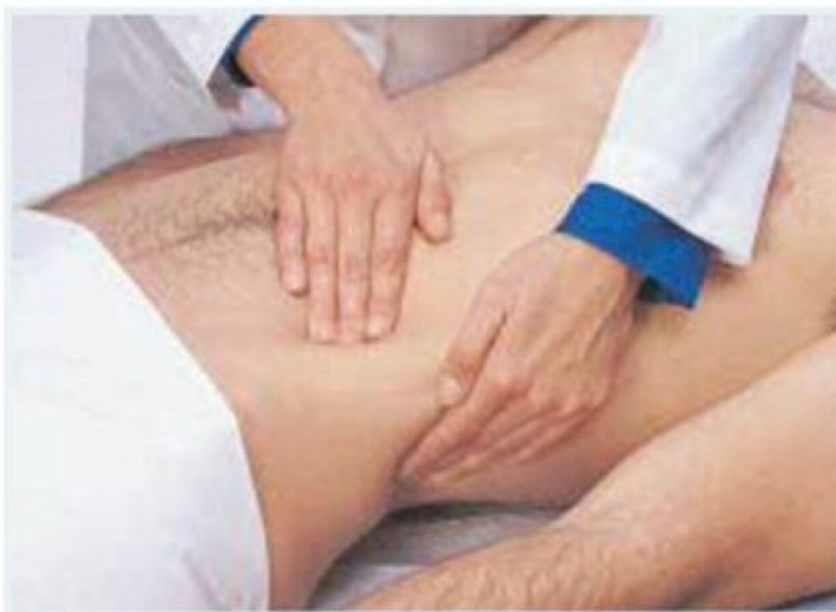Newborn: from birth to 14 days old

Neonate: from birth to 28 day old

Infant: from 1 month to 1 year

Toddler: from 2 to 3 years old

Preschool: from 1 to 4 year old



?What is the name of this physical examination technique
(1 نقطة)

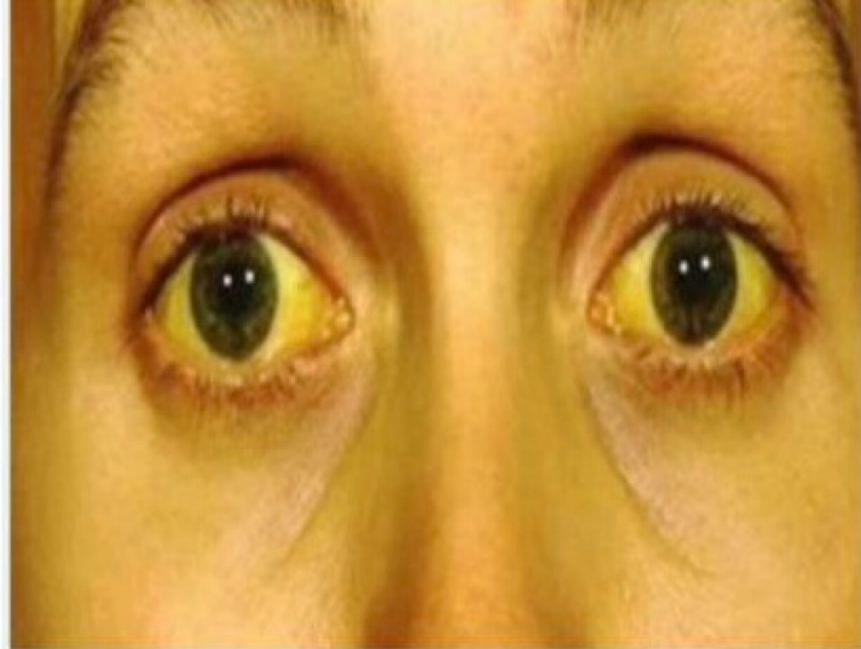
Superficial palpation

Ballotting technique

Deep palpation

Auscultation

Transmitted thrill



?What is the name of the abnormal sign shown in the picture
(1 نقطة)

- Yellow eye
- Jaundice
- Sunset eye
- Round pupil syndrome
- Horner's syndrome

:All are causes of constipation except
(1 نقطة)

Mechanical intestinal obstruction

Hypothyroidism

Impaired colonic motility

Opioids analgesia

Rich fiber diet