



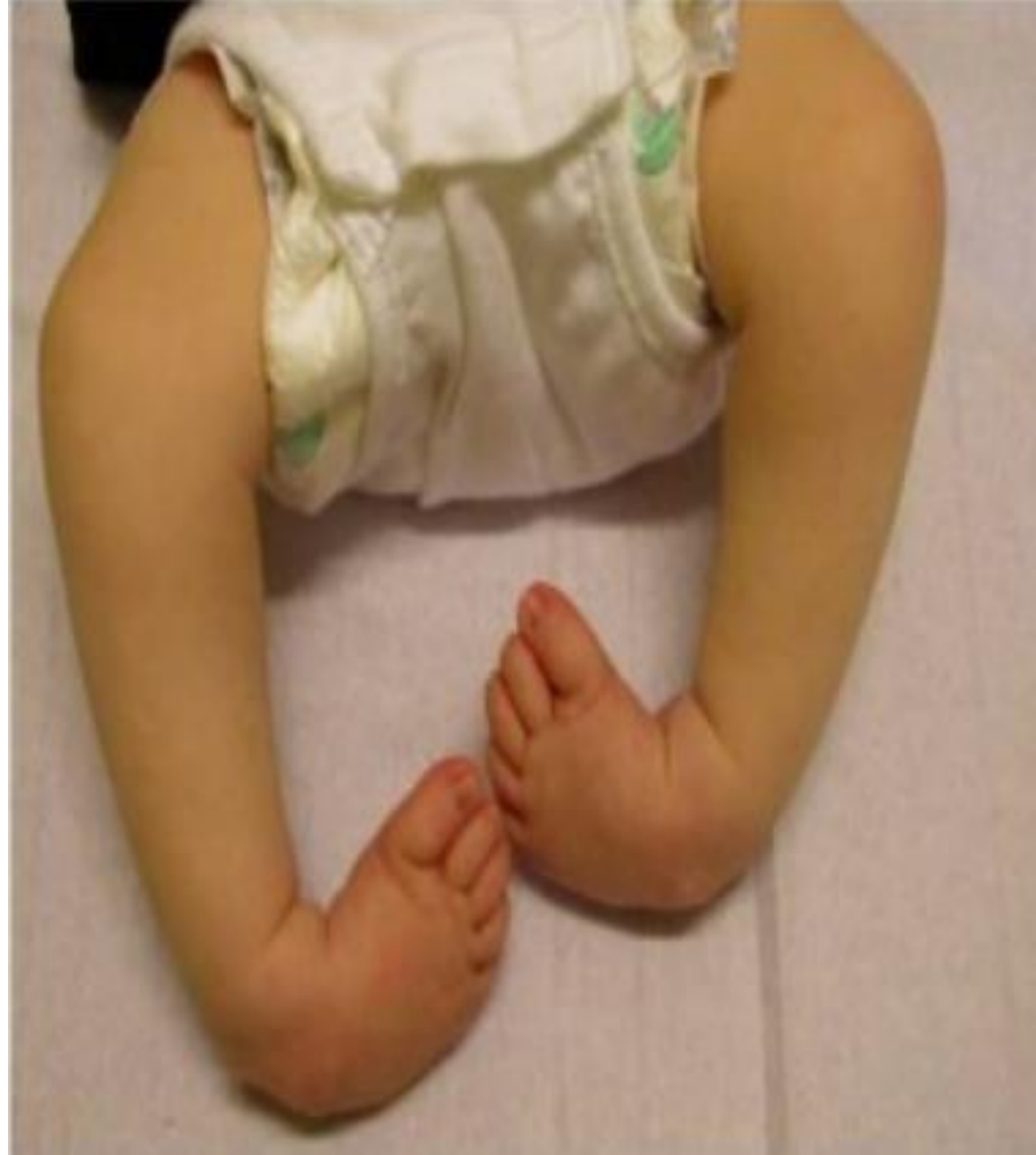Orthopaedics MINI OSCE

Soul batch

B groups

what is the diagnosis of this condition?

Talipes equinovarus (club-foot)



1) what is name of line C and line B?

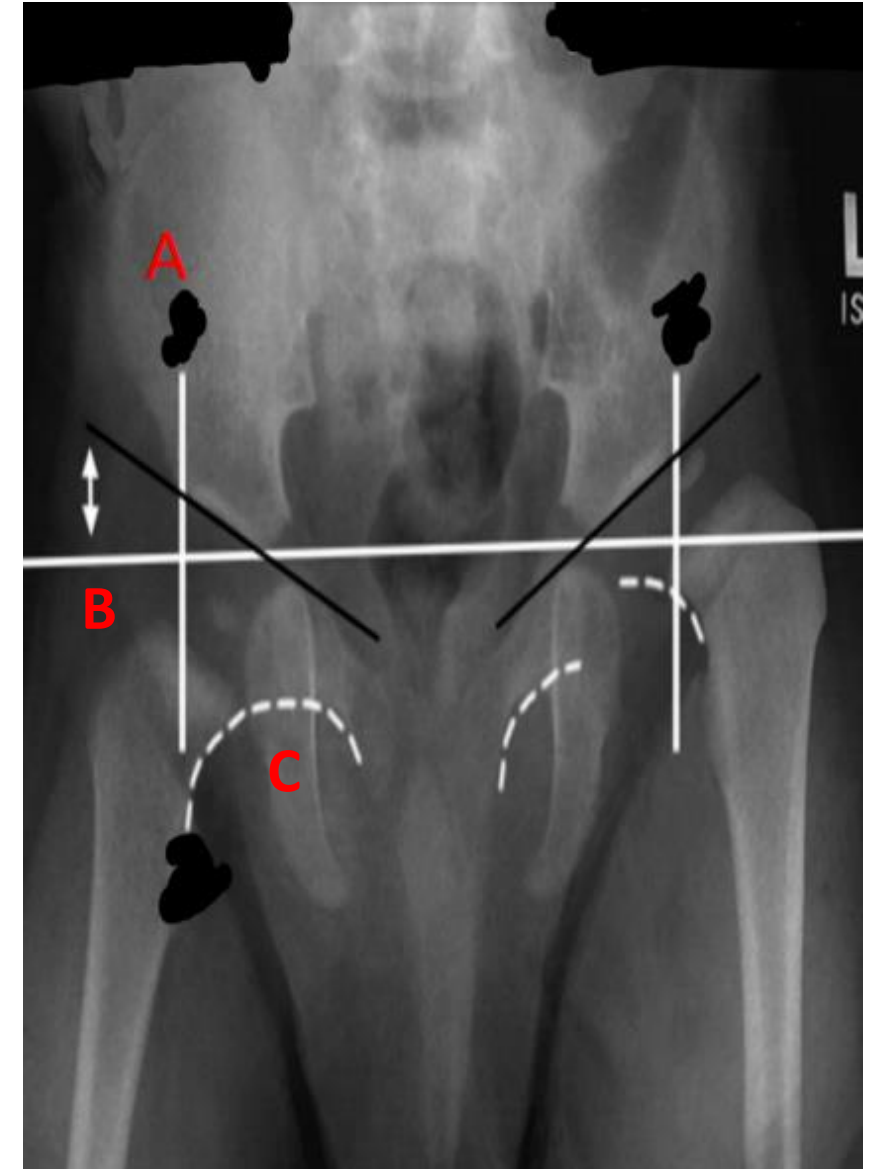
B: Hilgenreiner line

C: Shenton line

2) what is the diagnosis of this patient in right and left hips?

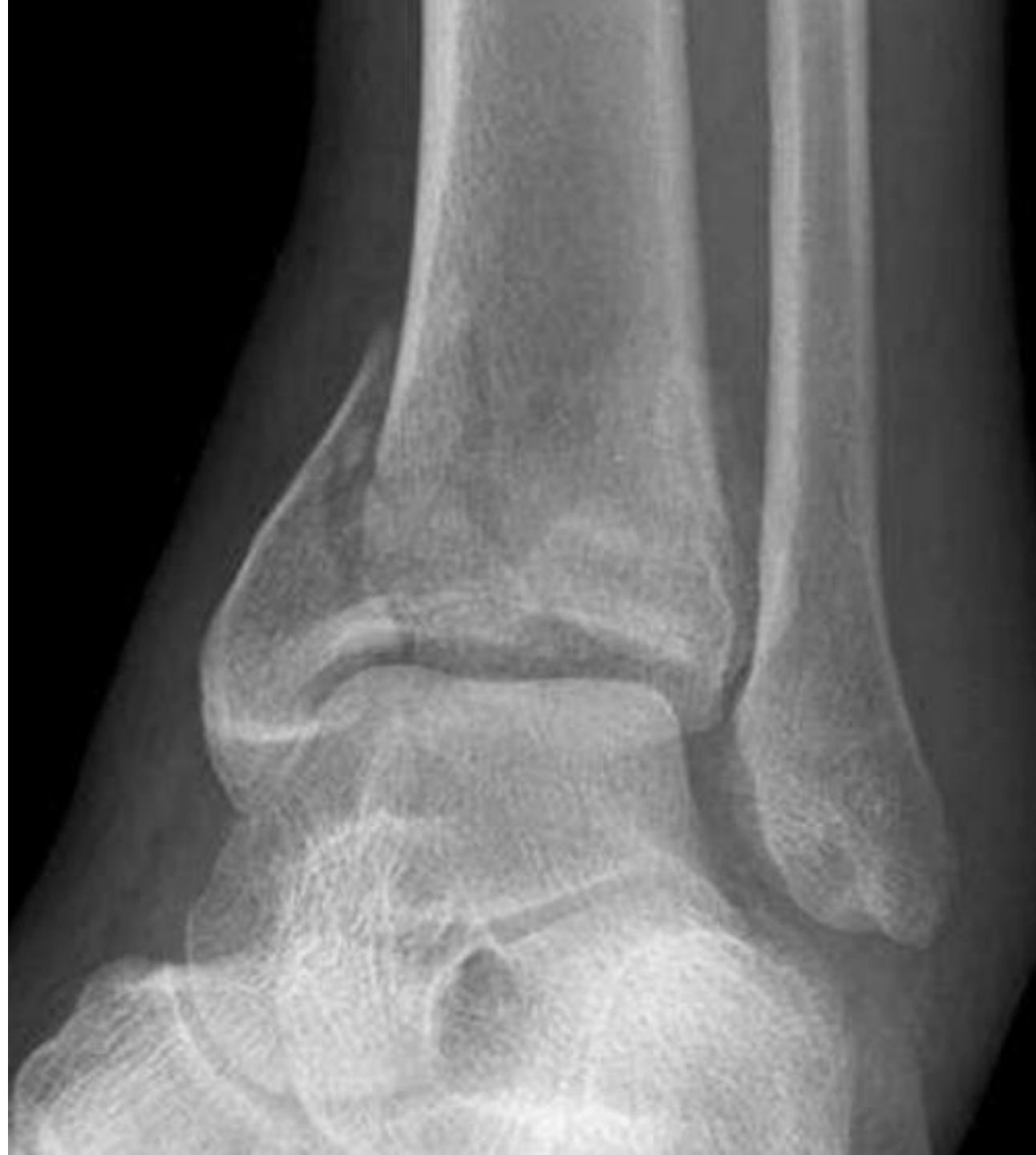LEFT → Developmental dysplasia of the hip (DDH)

RIGHT → normal



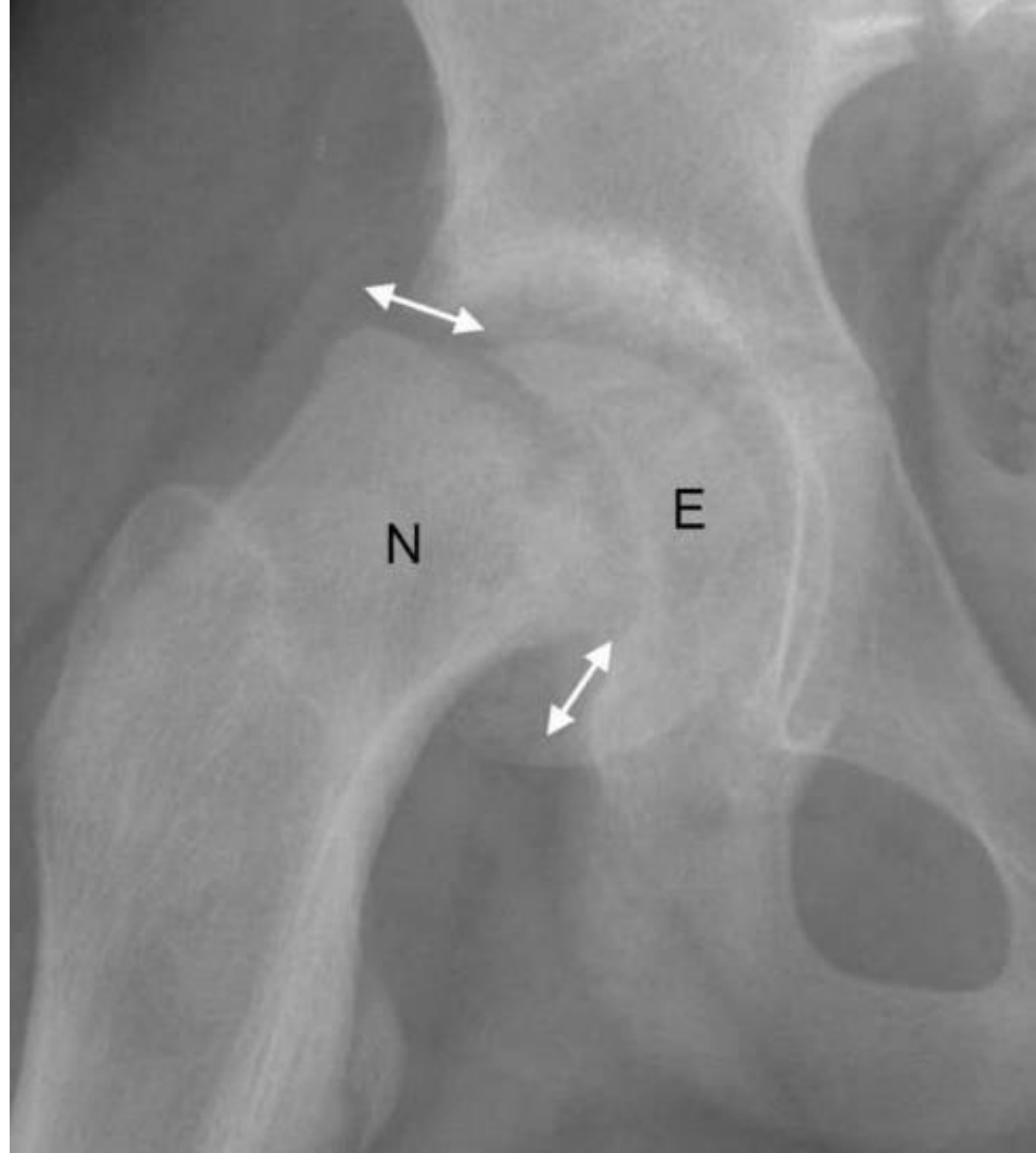
Dx?

Pilon Fracture



Ddx?

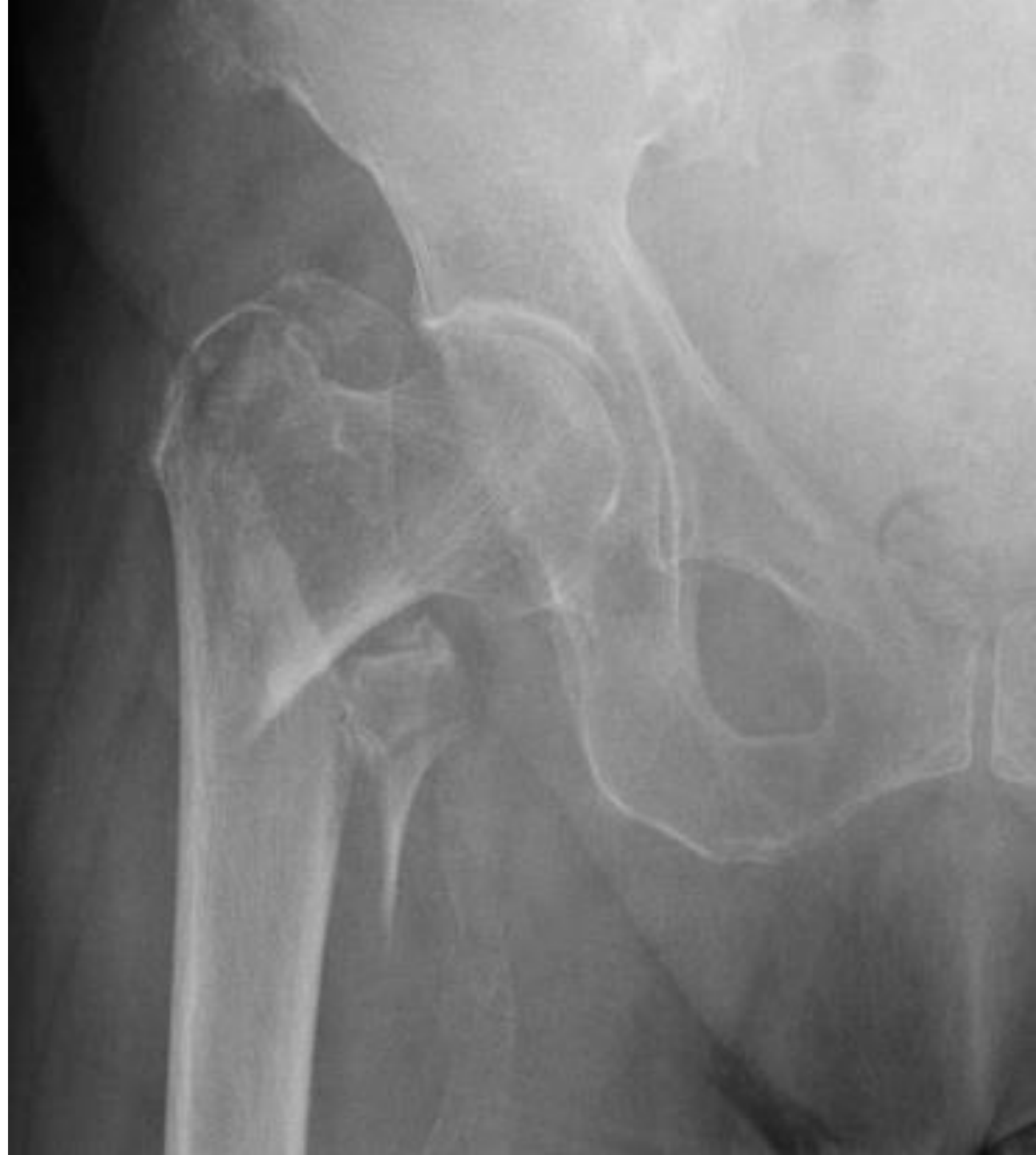Right Slipped Capital Femoral
Epiphysis
abbreviations are not excepted



- **Ddx?**

Right Femur Intertrochanteric fracture (Type 2)

- **Most common Complication?**
Malunion

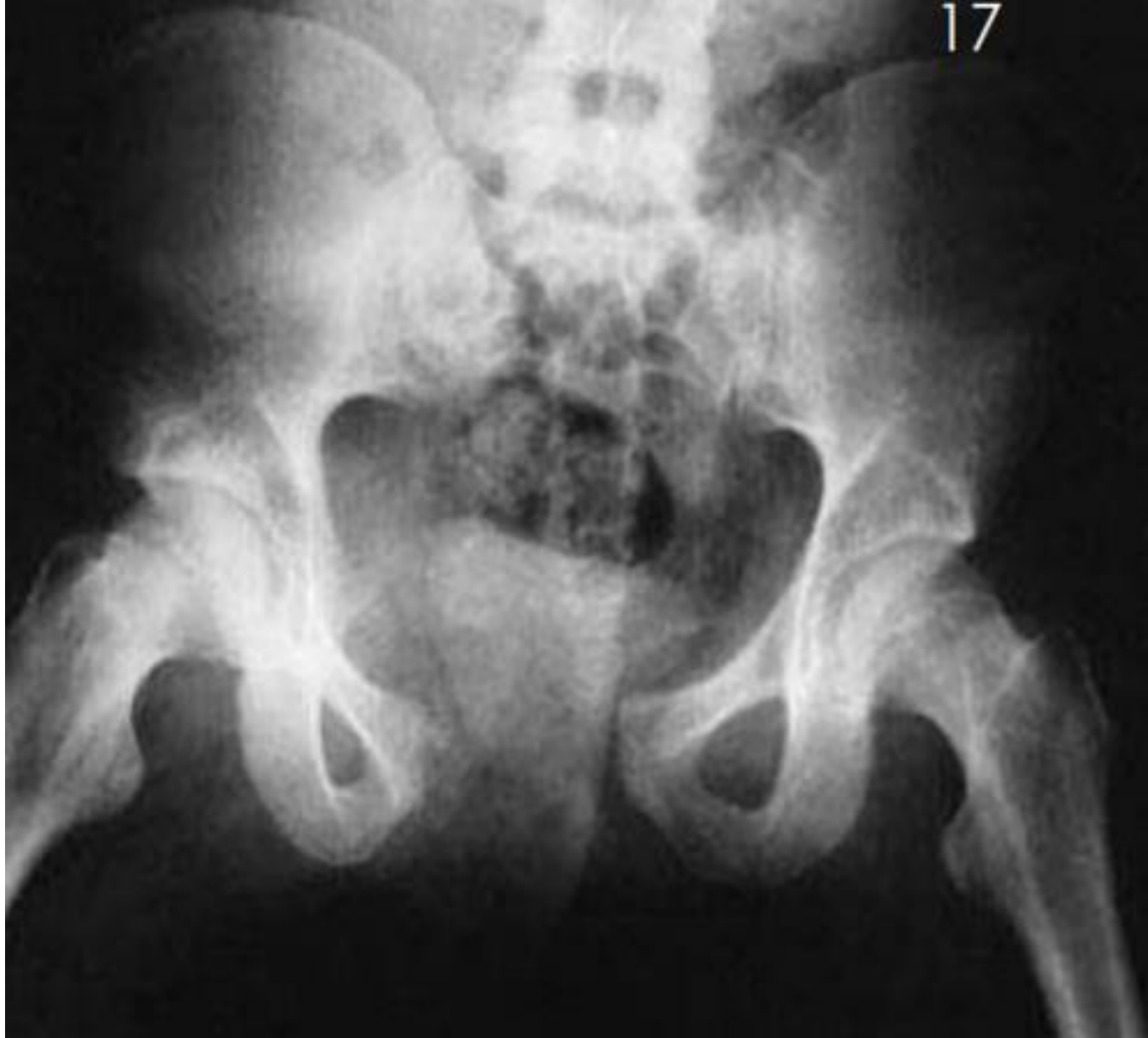

- **Type of the fracture?**

Open book fracture

- **what is the direction of the force causing this?**

Anteroposterior
compression

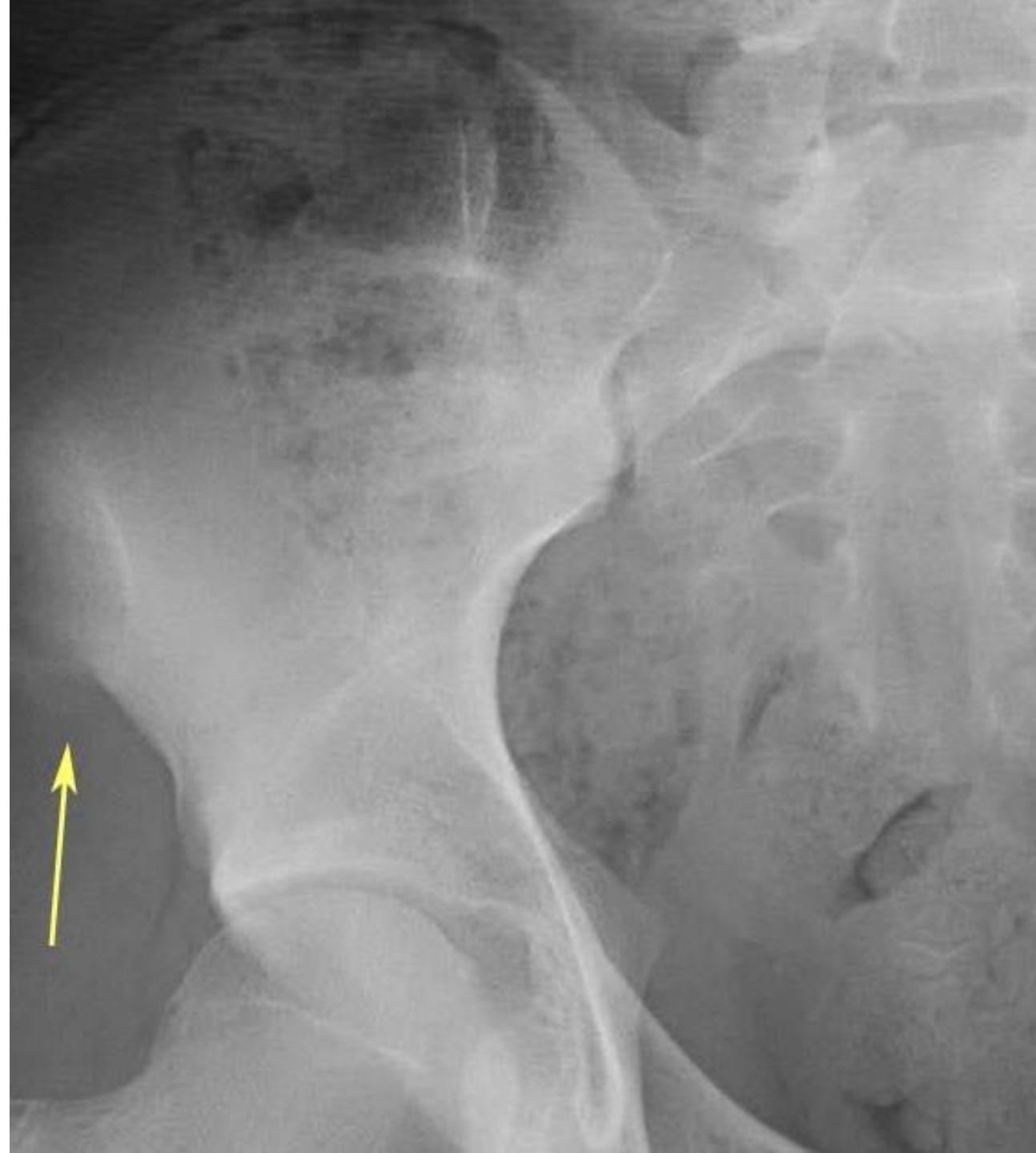

- **DDX?**

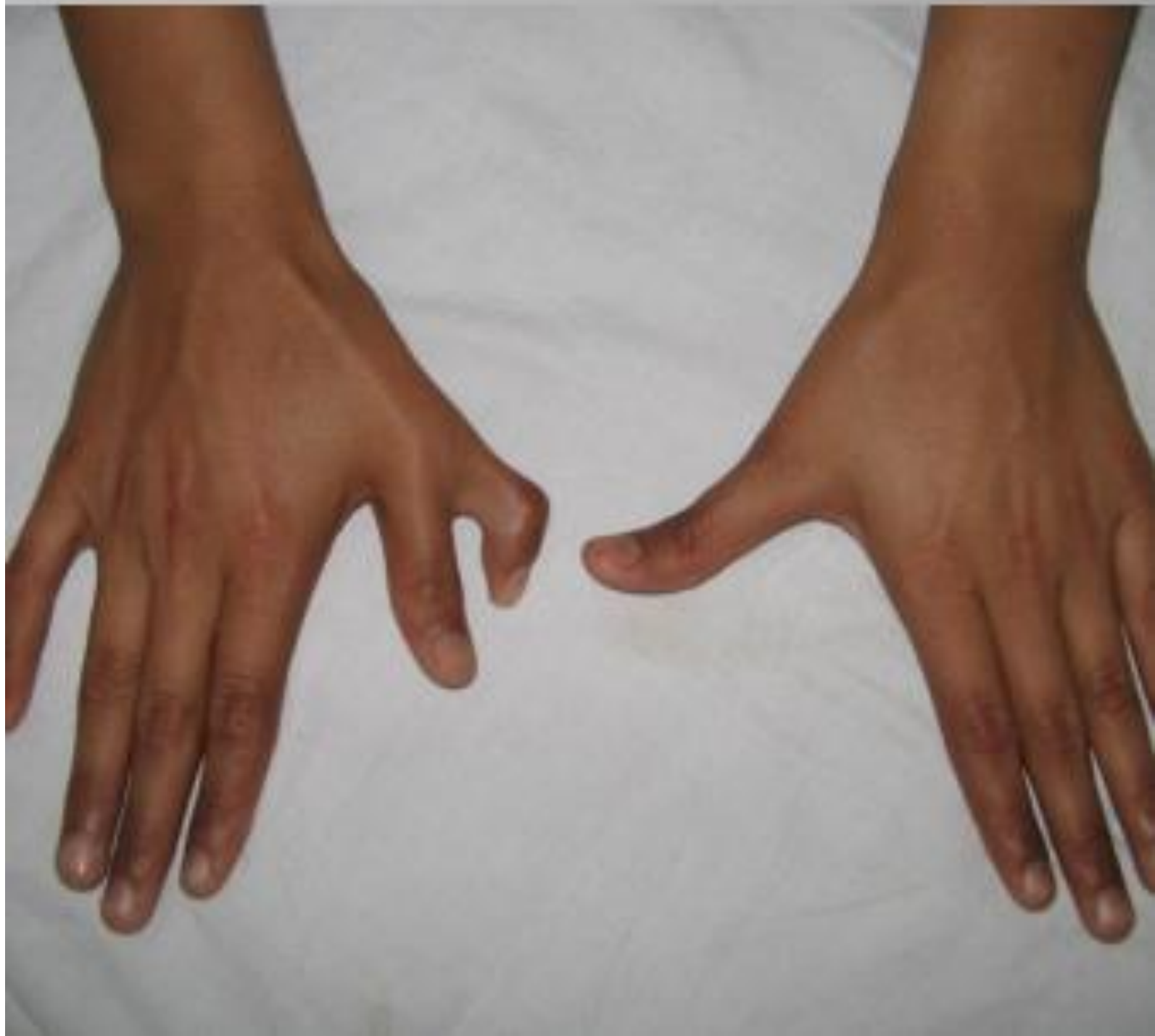ASIS avulsion fracture

- **Contraction of which muscle can cause this fracture?**

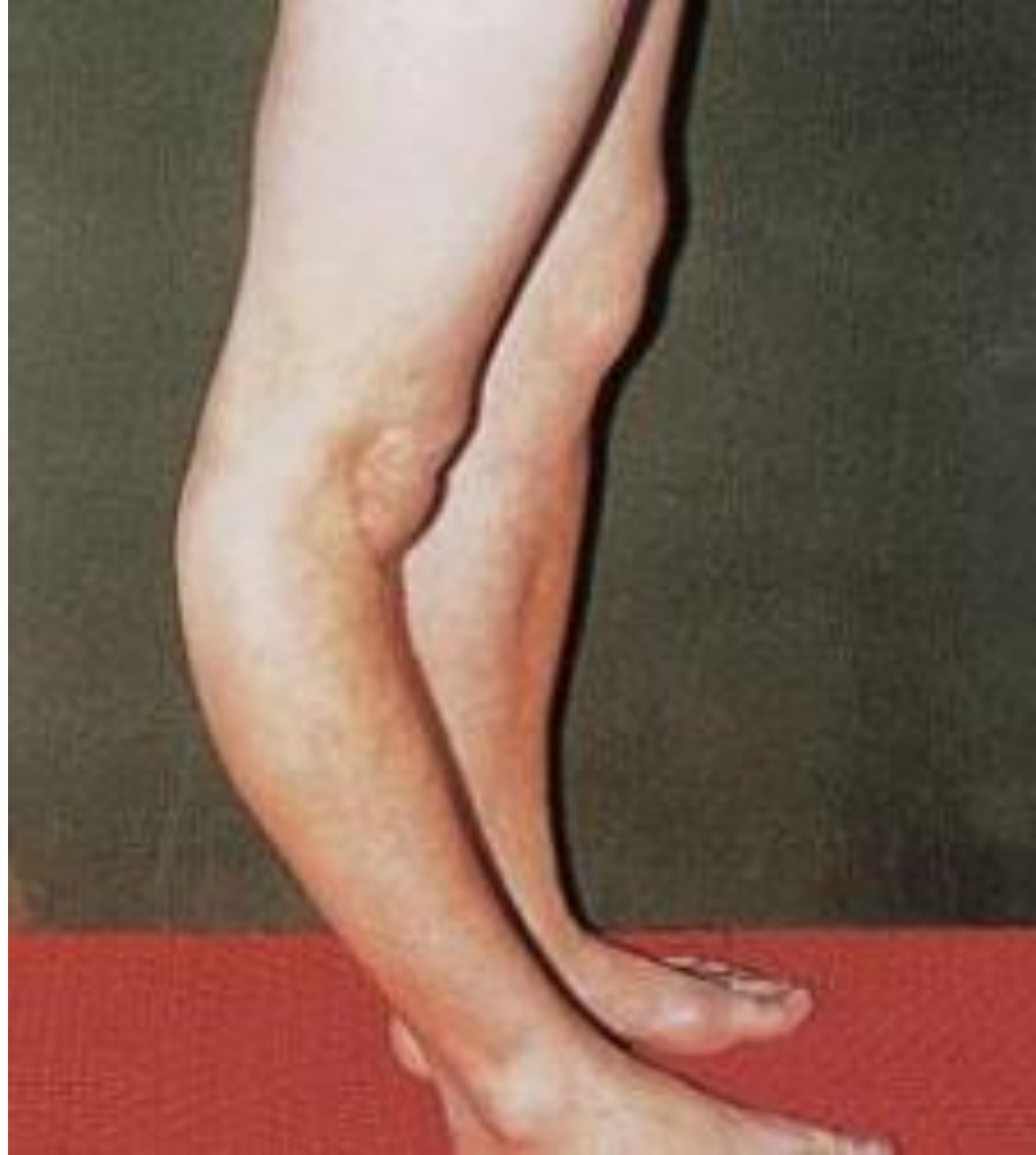Sartorius



- **Name the deformity ?**
polydactyly

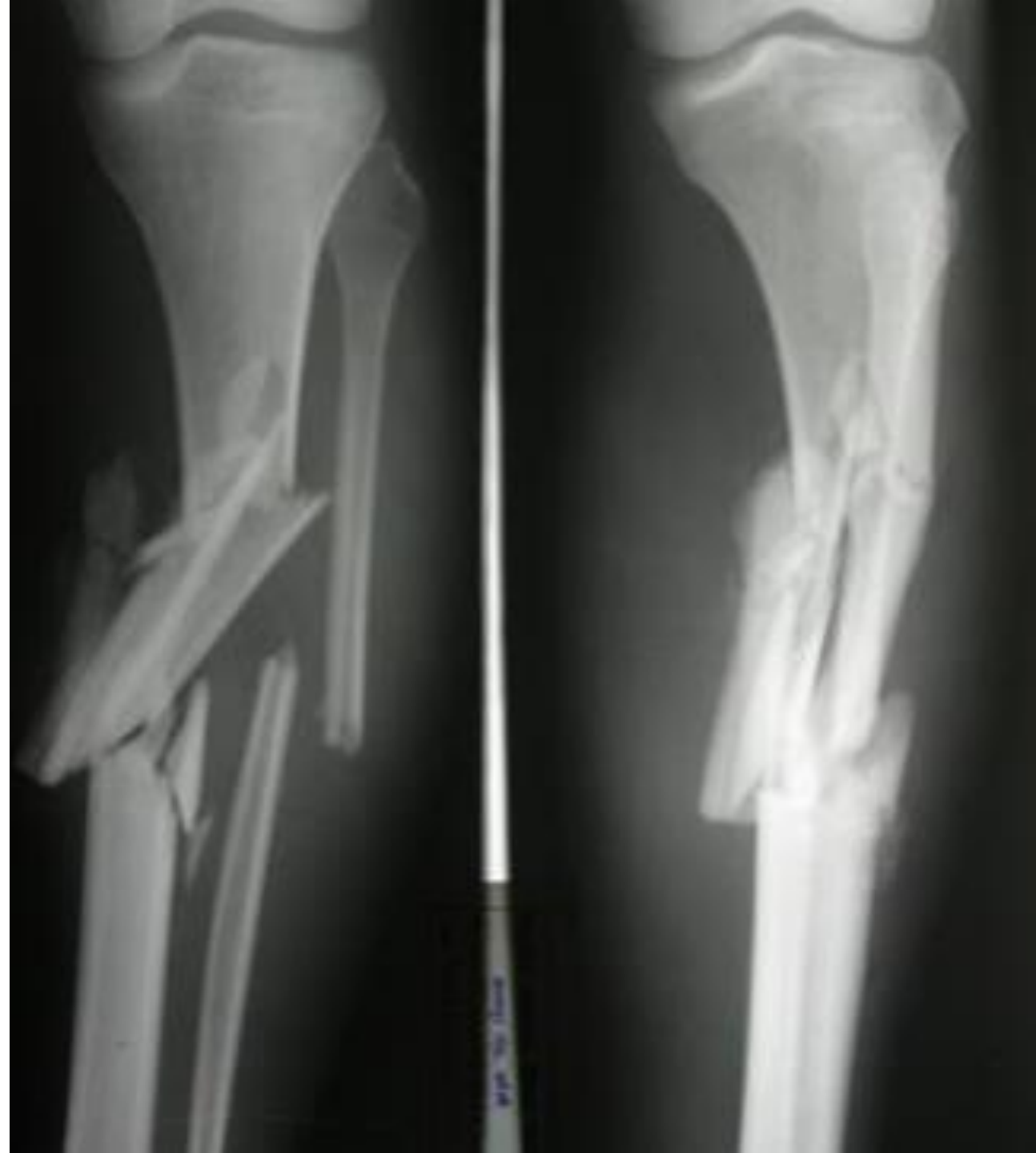

- **What is the name of this deformity?**
-genu recurvatum



- **Determine the site and the pattern of this fracture ?**

comminuted mid shaft
fracture of tibia with fibular
Fracture

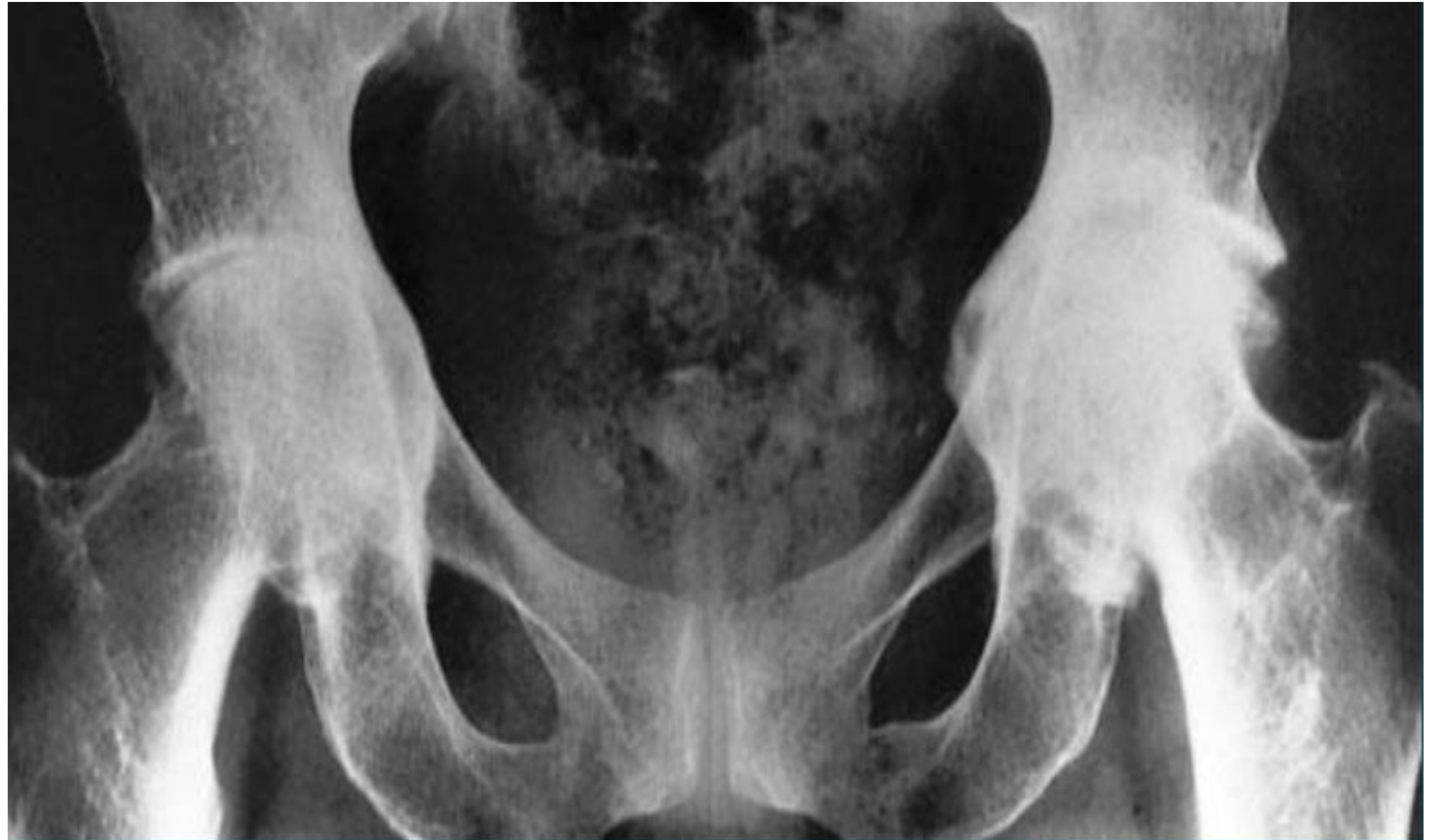

- What is the diagnosis ?

Bilateral protrusion acetabuli

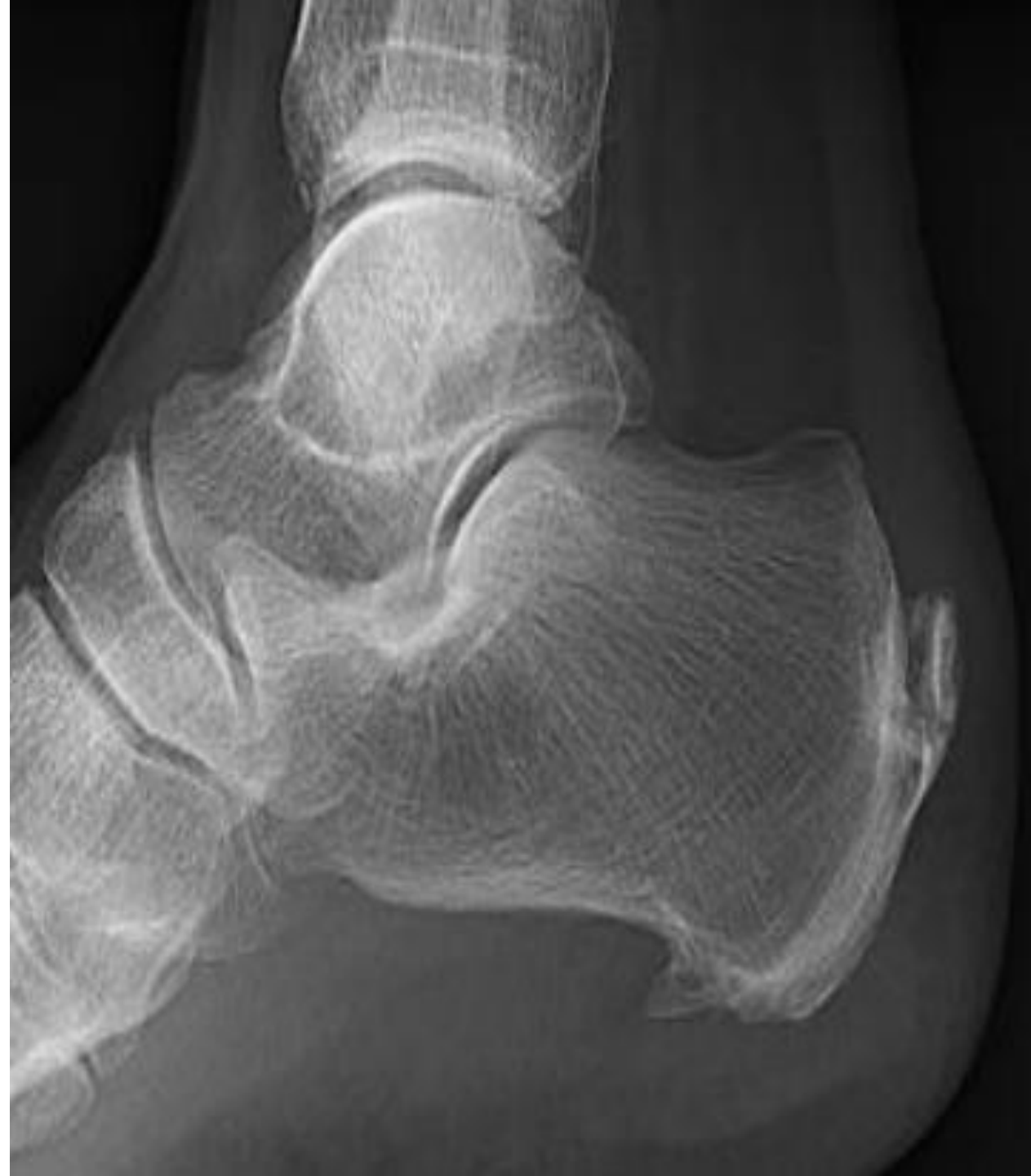- Mention two causes?

RA and osteomalacia



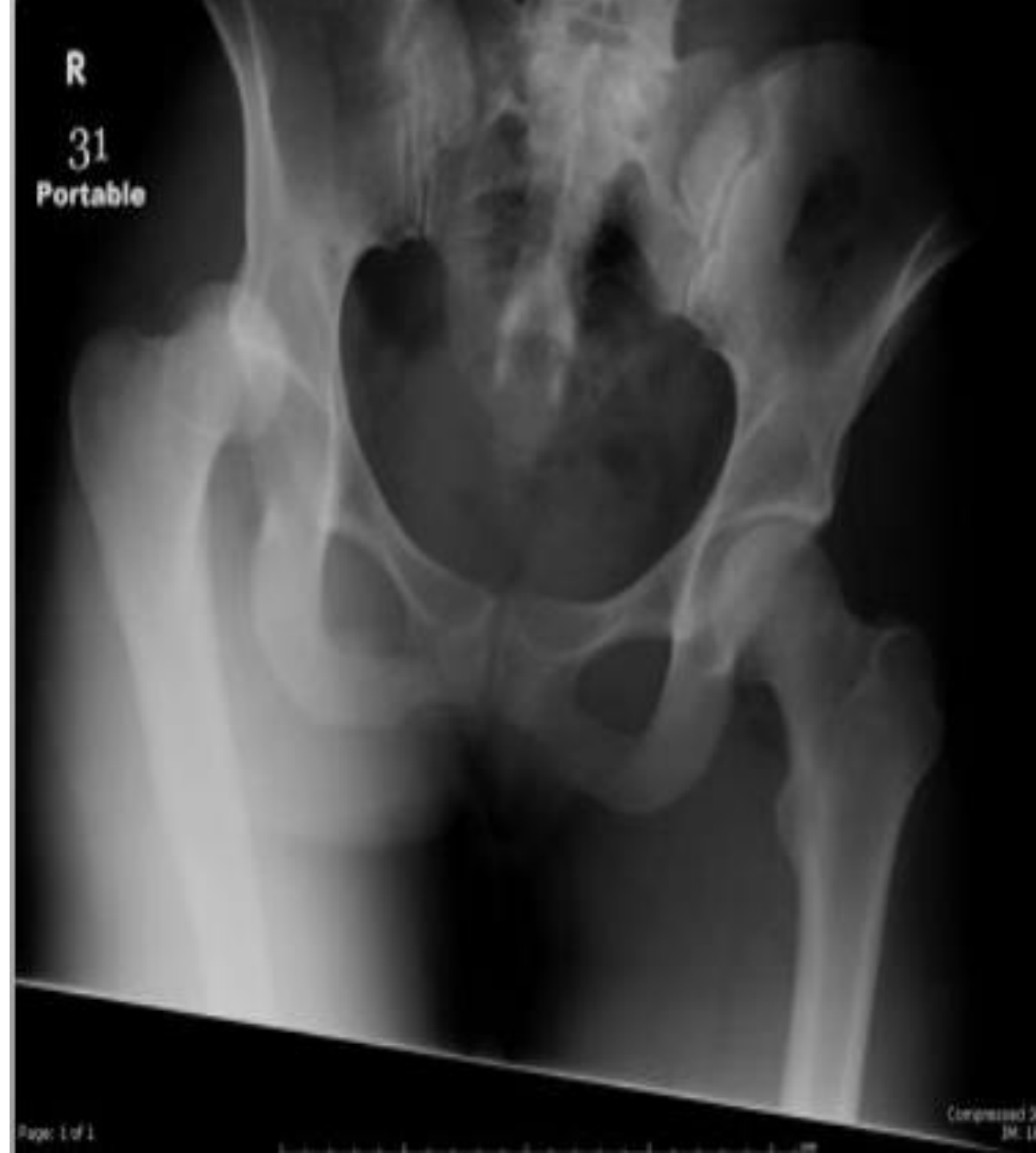- **What is the name of this condition?**

Calcaneal apophysitis (sever disease)



- **What is nerve that is commonly injured according to the pic ?**

Sciatic nerve

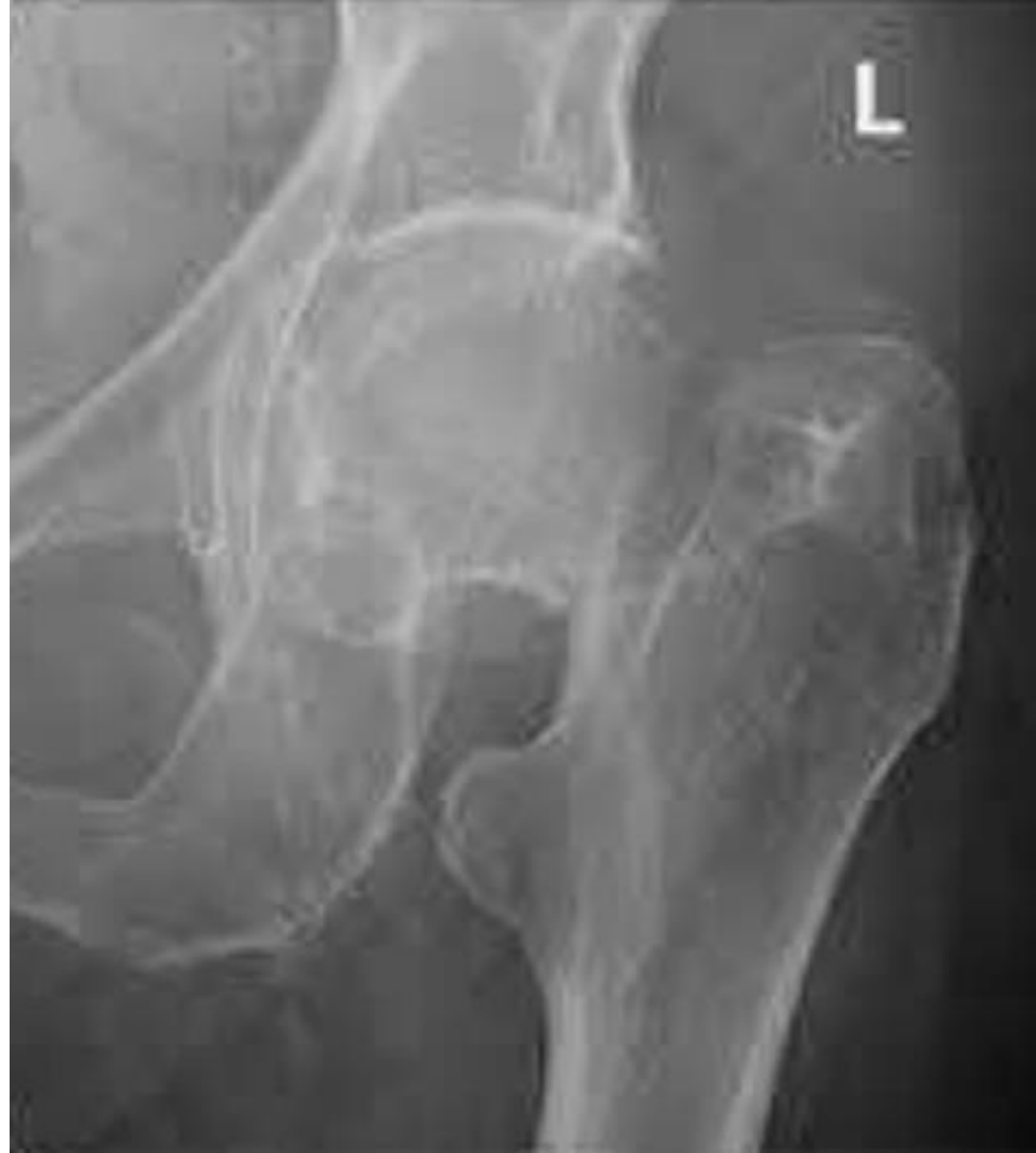

- **Ddx?**

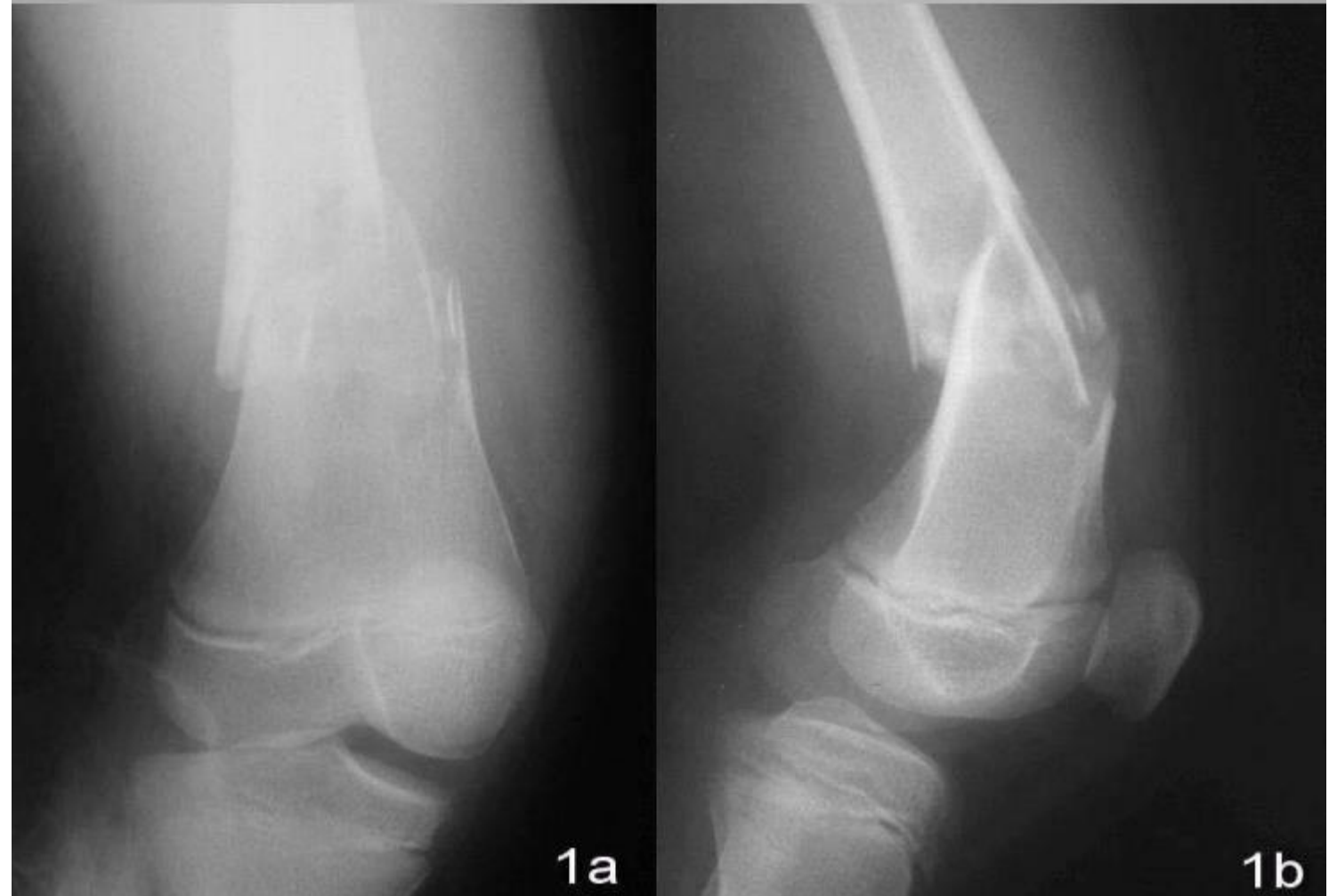Femur neck fracture

- **Complication?**

- Non union
- AVN

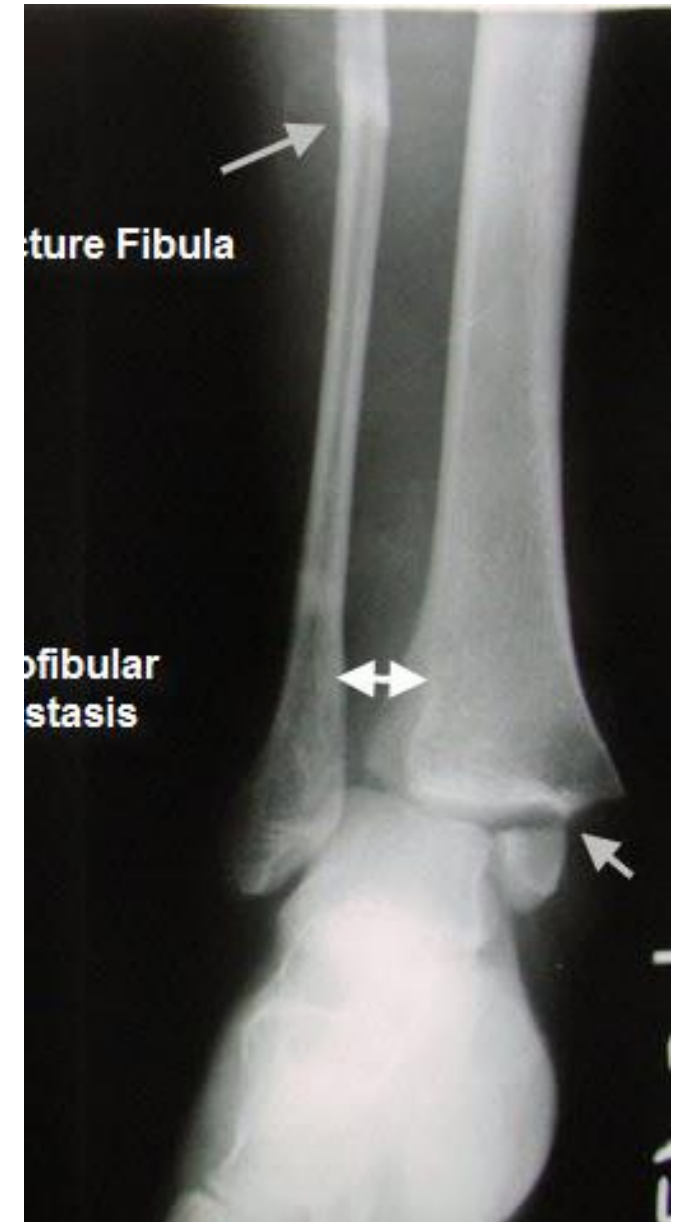

- **Ddx?** Supracondylar femur fracture
- **Displacement?** Translation, Angulation
- **What vessel at risk?** Popliteal artery

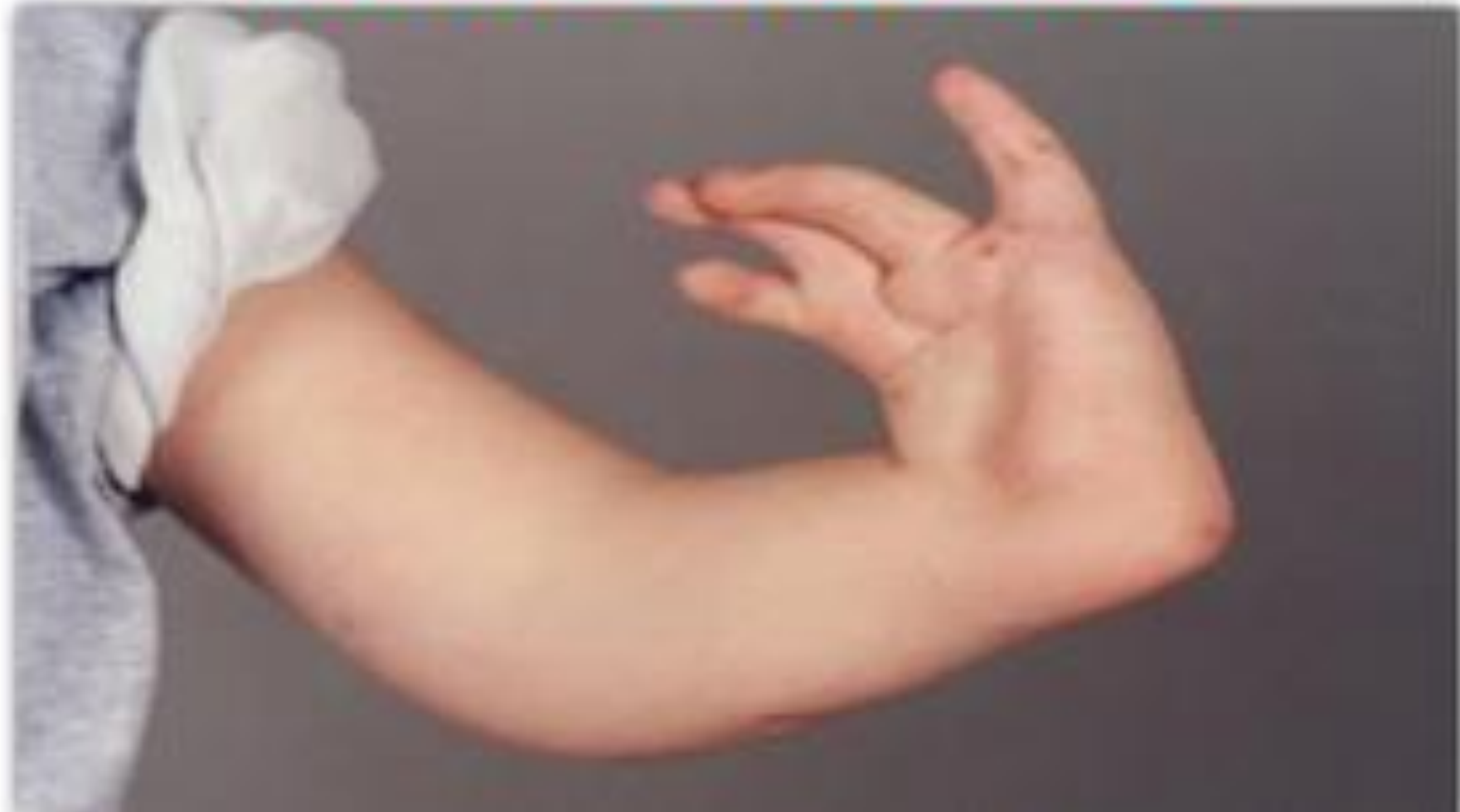

Not same pic but same location
of fracture

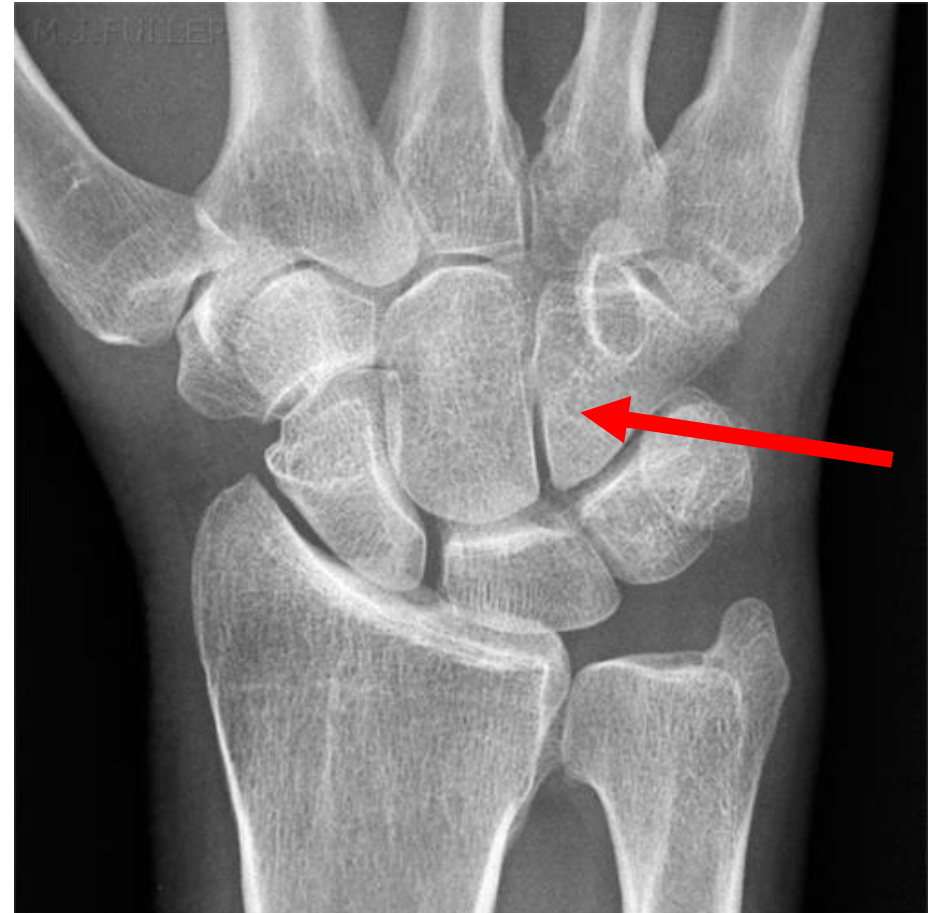Bimalleolar
fracture type c



Radial Club Hand



Name this bone:
hamate

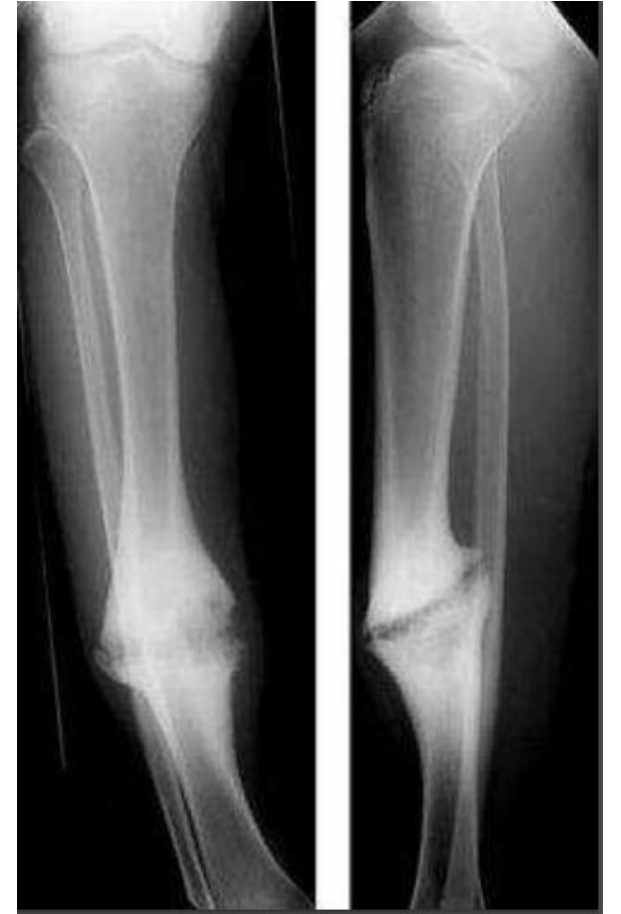

A 45 y sustained a tibial fracture 9 months ago,
this is the x ray now

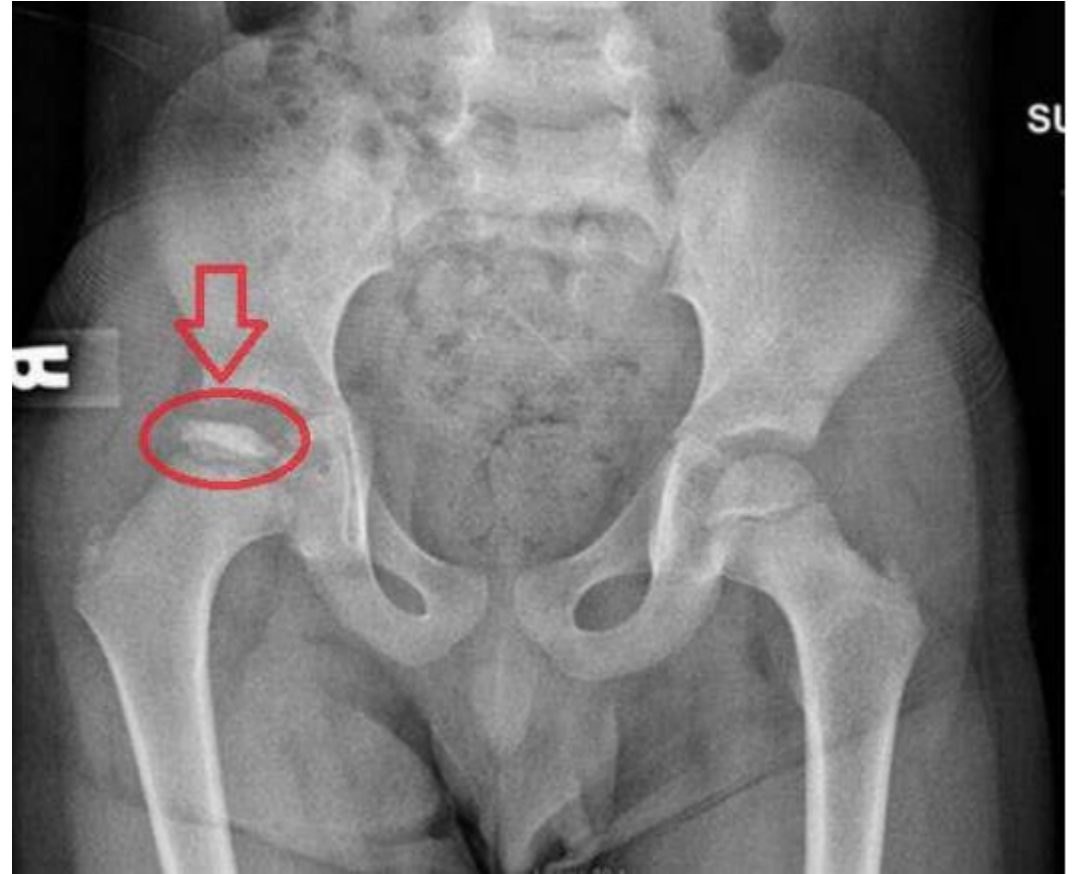-what is the ddx?

Hypertrophied non union

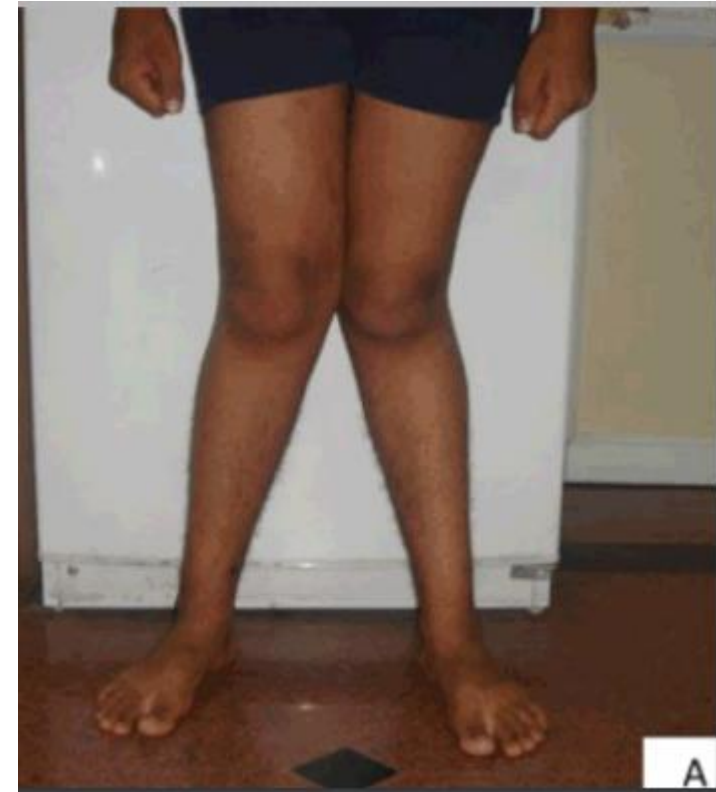- what is the cause of this condition?



DDX? Perthes disease

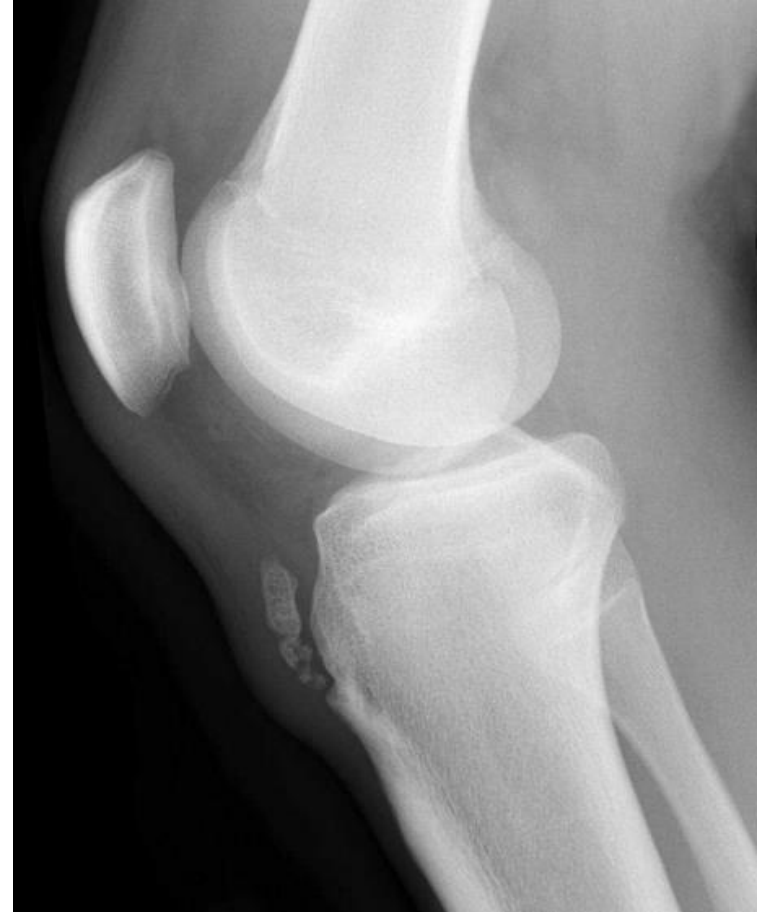

Ddx? Genu valgum
mention one cause

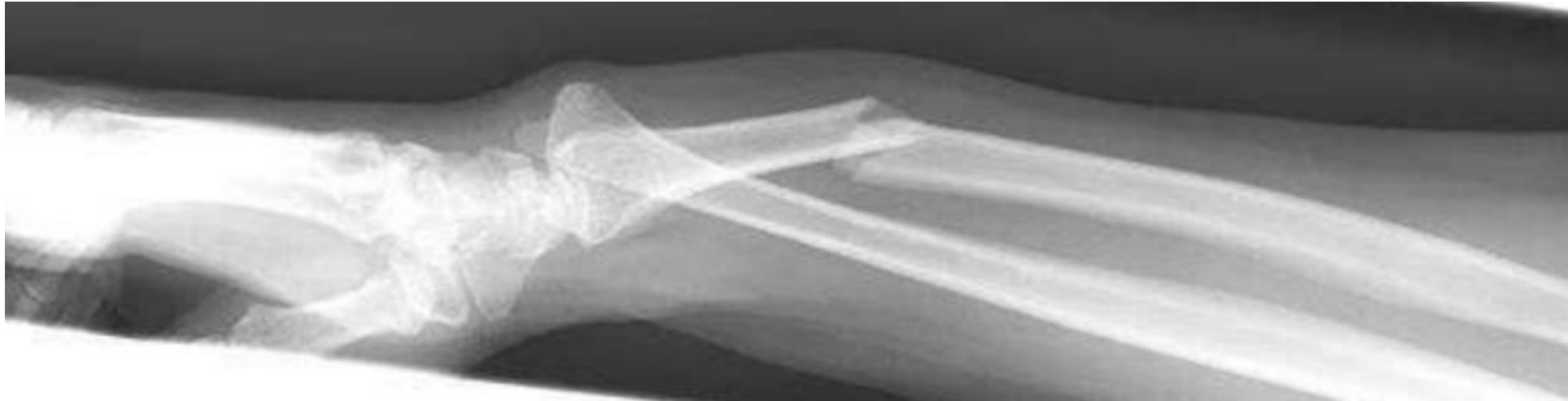

Ddx?

OsgoodSchlatter Disease (OSD)



What is your Dx? Galeazzi fracture



What is the diagnosis?

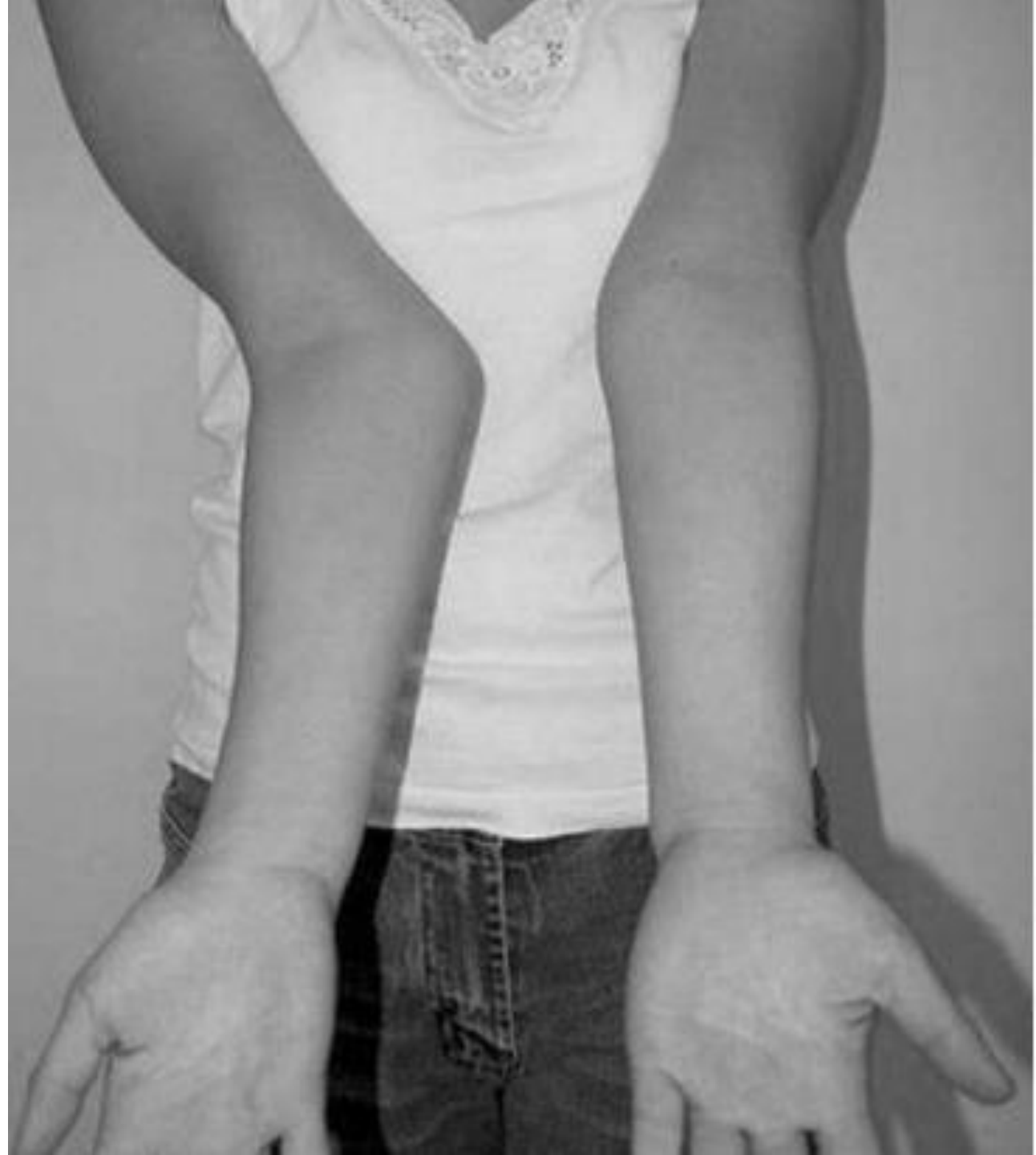Cubitus valgus

What is the cause?

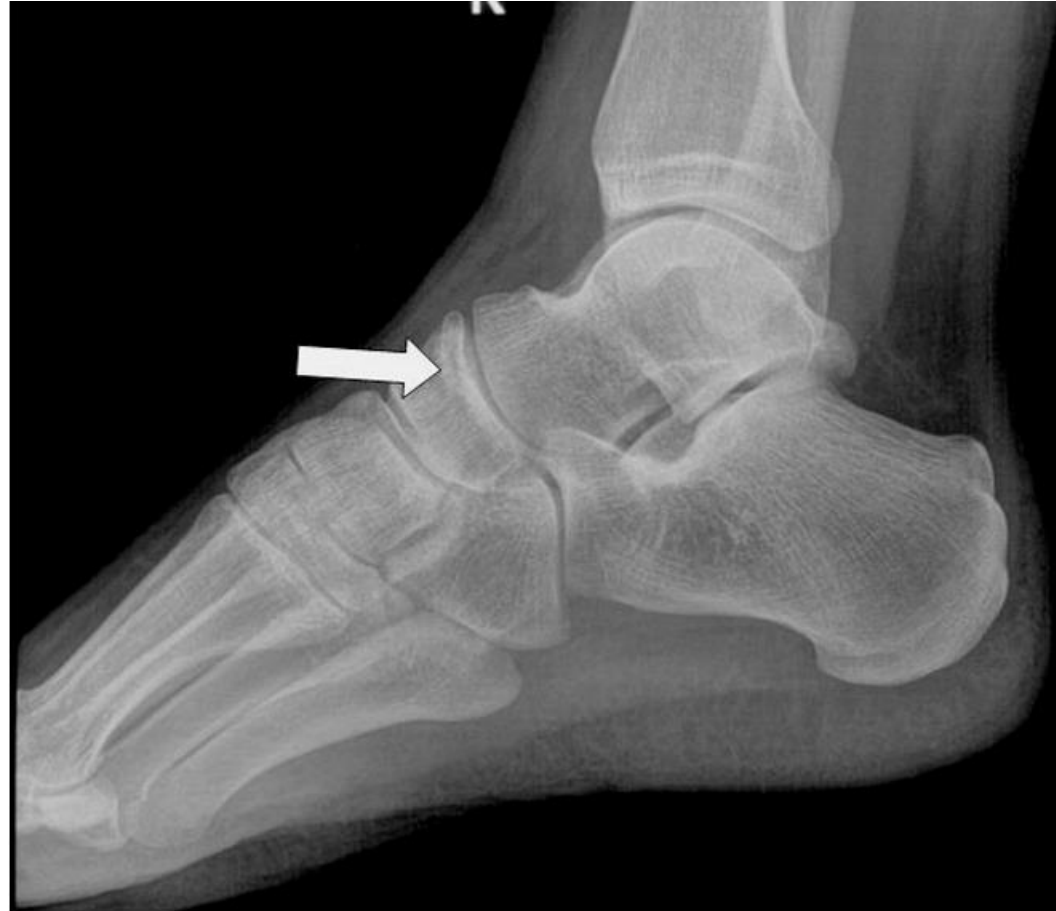Non union of lateral condyle

Most Common complication:

Ulnar nerve



What is this bone? Navicular

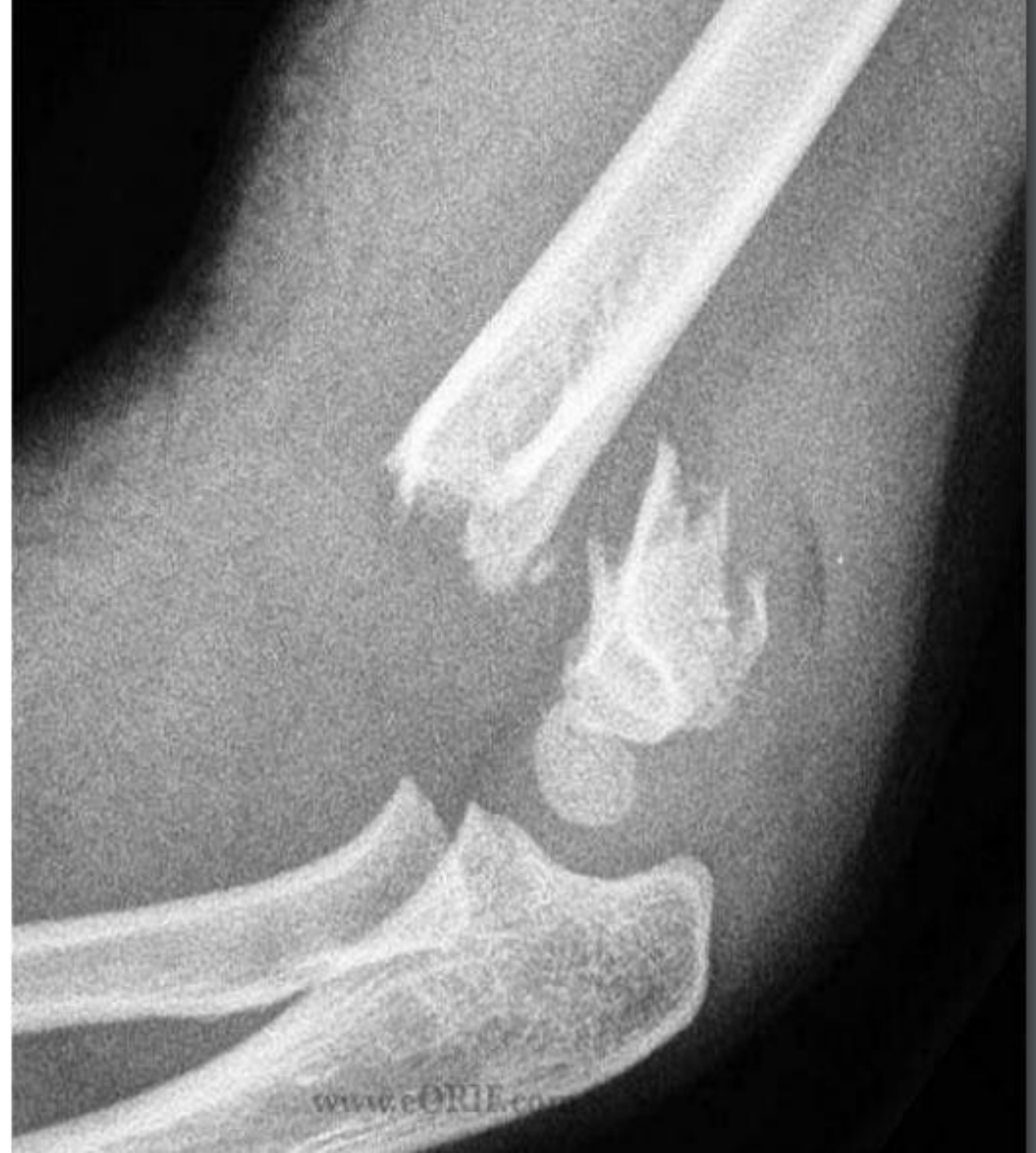

- **Diagnosis:**

Humeral Supracondylar Fracture

- **What is the most commonly injured structure:**

Median nerve

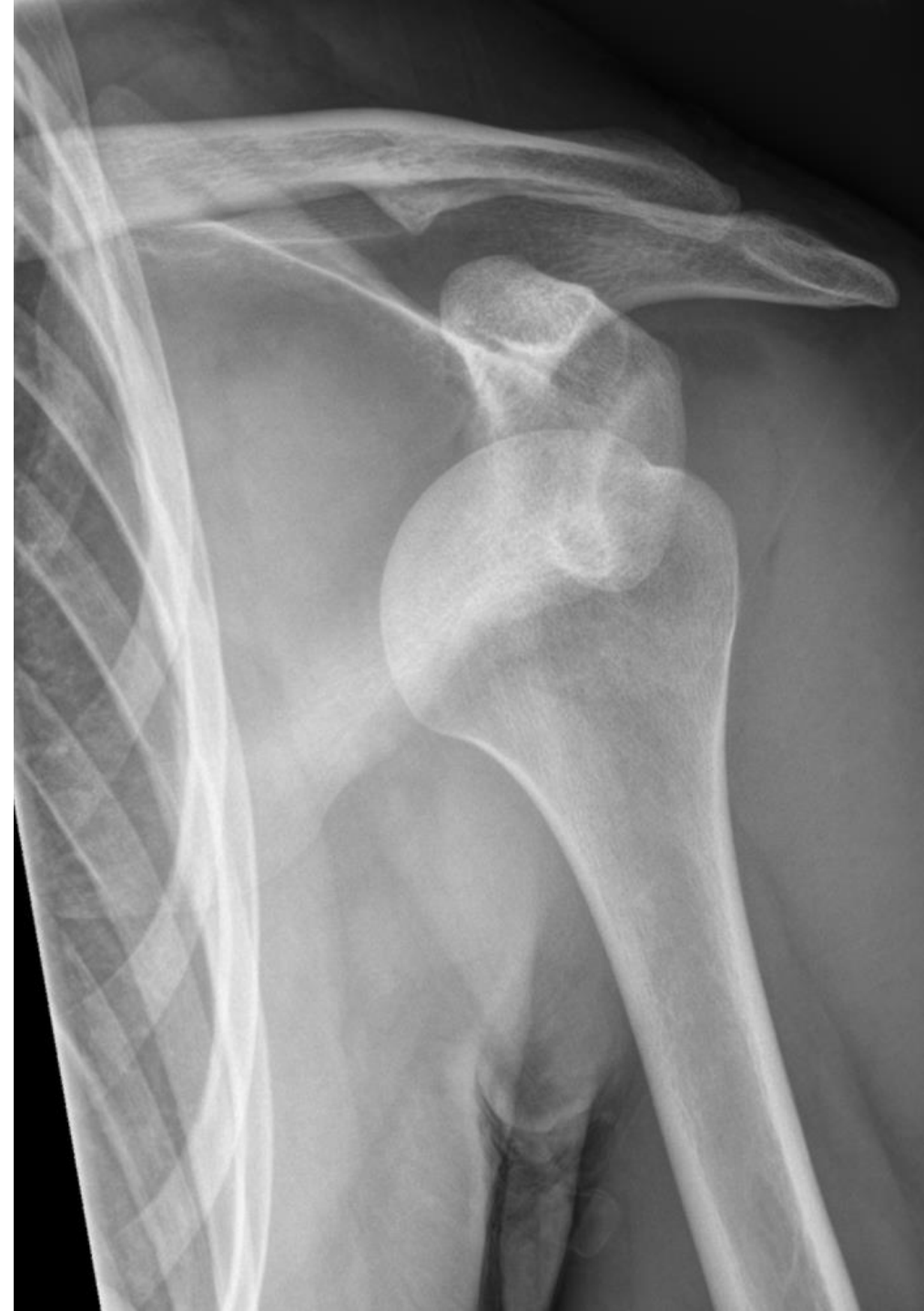

- **Ddx?**

Anterior shoulder dislocation

- **Injury to what nerve?**

Axillary nerve



في كان سؤال describe the displacement ناسية
الصورة

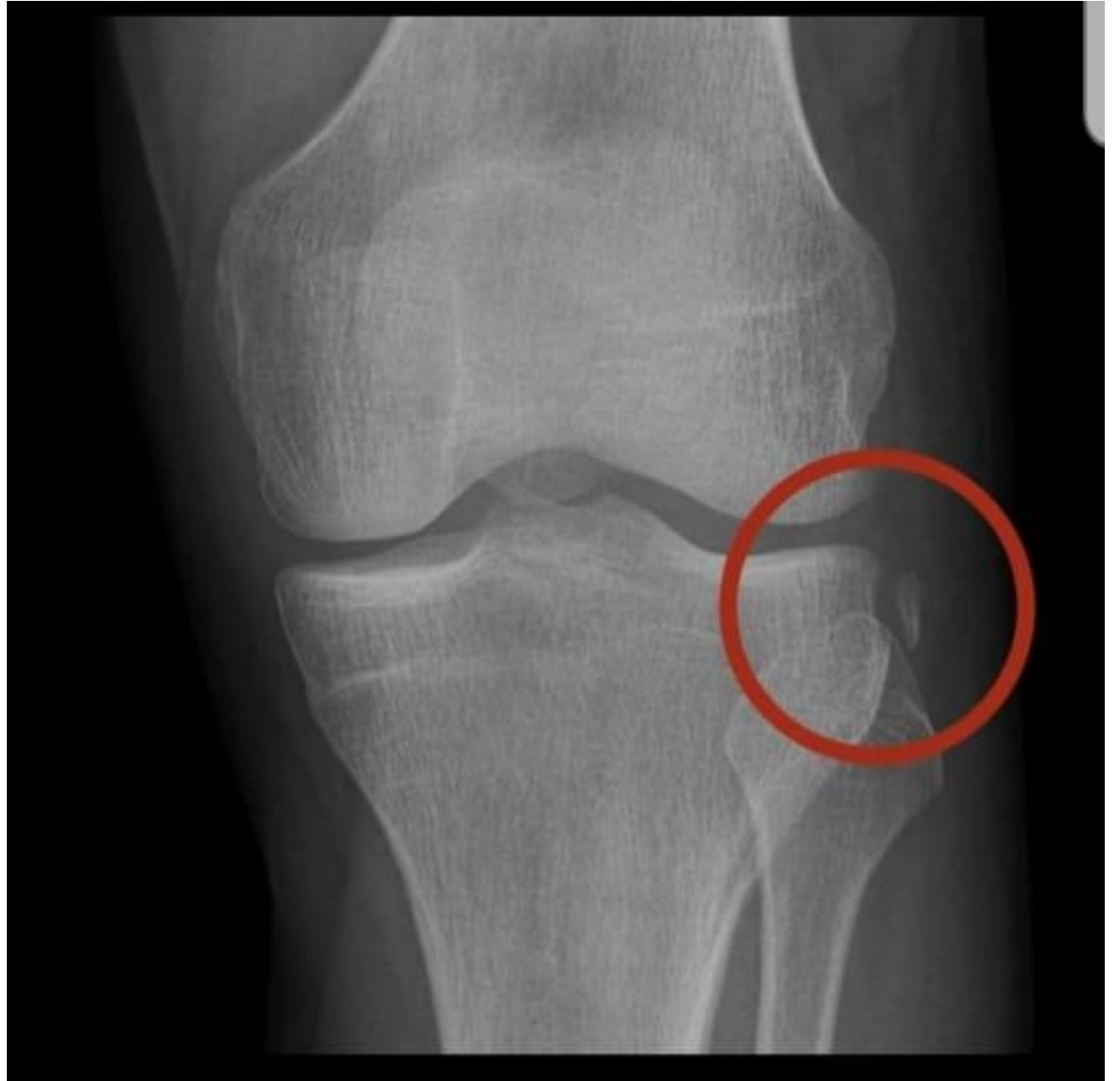- translation
- angulation
- lengthening
- rotation

1- classification : Type 2

2- Complication : risk for infection



ACL injury \ segnod fracture



1- Diagnosis?
Patellar dislocation

2- Cause?
Patellar tendon injury

