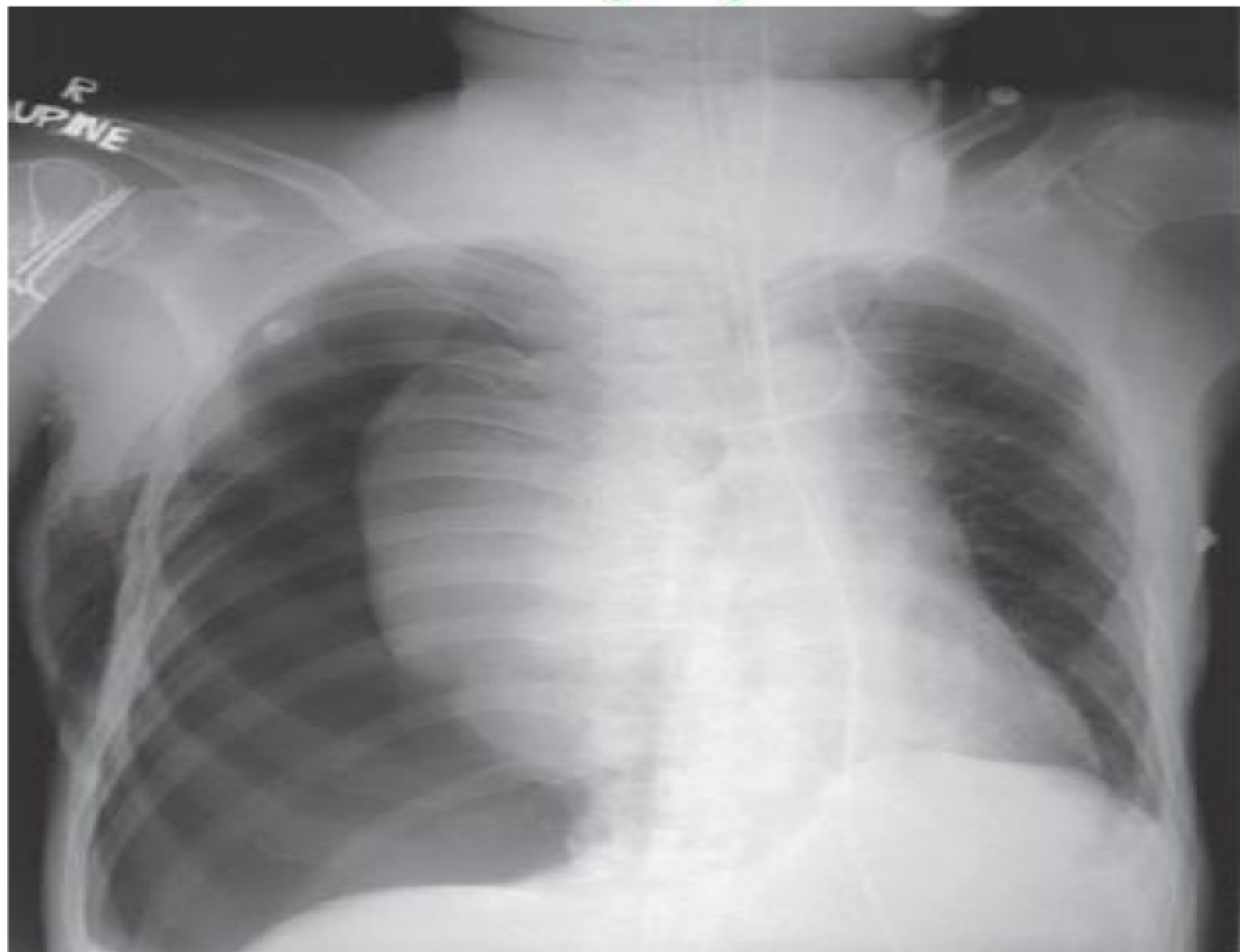
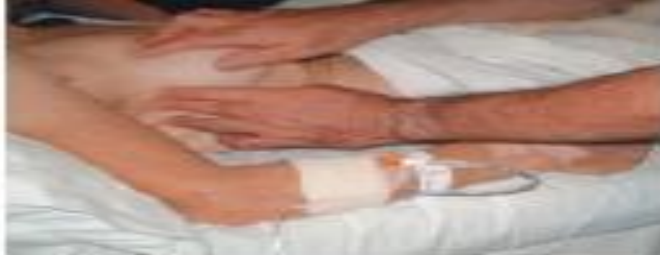
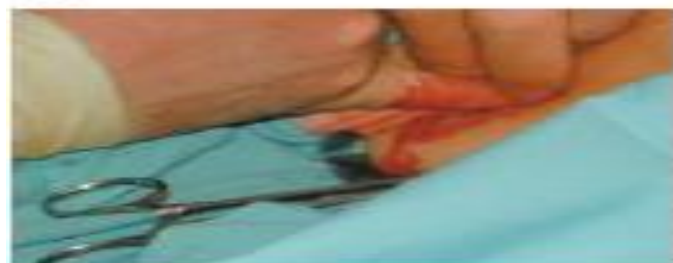
22.21 Left-sided tension pneumothorax



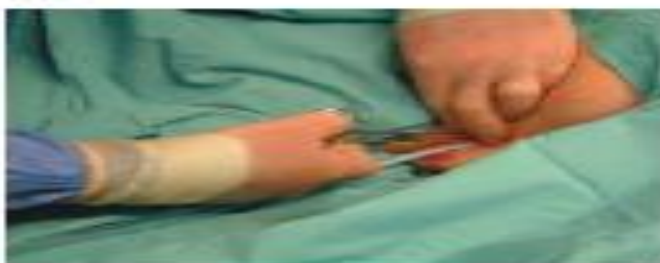(a)



(b)



(c)



(d)

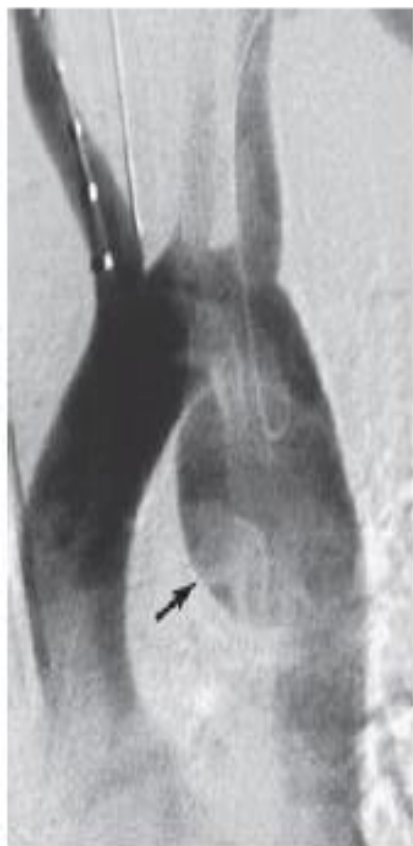


(e)

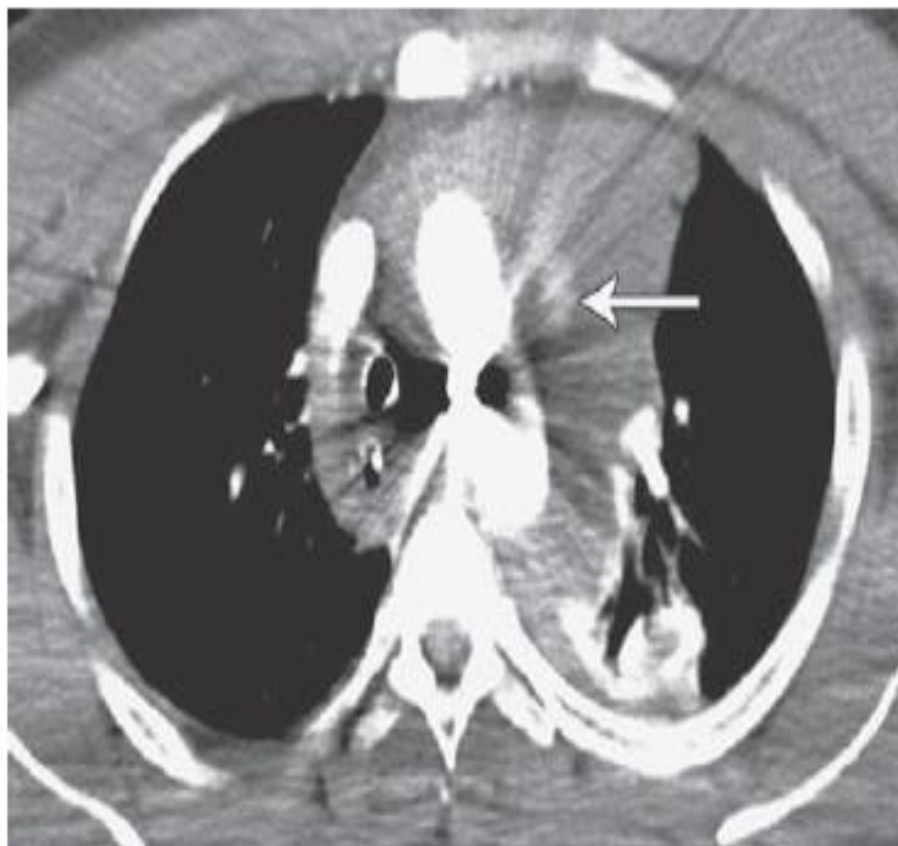


(f)

**22.22 Chest drain insertion sequence** (a) Chest x-ray to confirm correct side. (b) Identify the fifth intercostal space, just anterior to the mid-axillary line on affected side. (c) Insert gloved little finger through the incision into the chest cavity and finger sweep to ensure cavity is empty and the incision is above the diaphragm (no viscus is felt). (d) Grasp the tip of an appropriately sized thoracostomy tube between tips of forceps and introduce through incision into chest cavity. Unclamp forceps and slide tube posteriorly along inside of chest wall. (e) Attach tube to underwater drain or Heimlich valve and observe for tube fogging and underwater bubbling. (f) Check lung reinflation with chest x-ray.

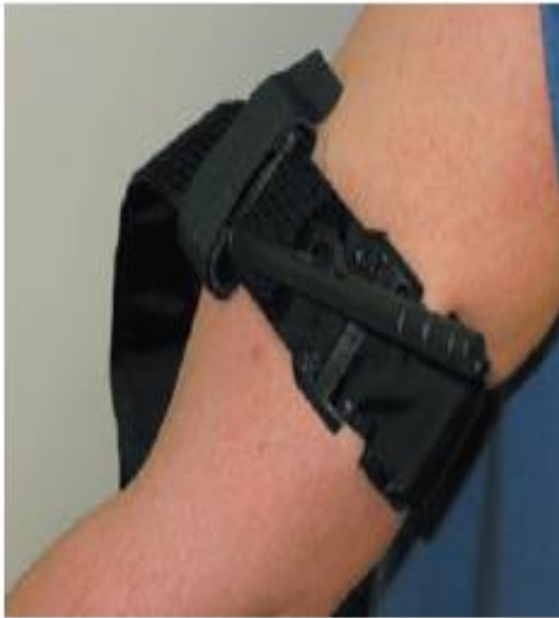

(a)



(b)

**22.23 Ruptured aorta**  
(a) Angiogram showing a rupture of the arch of the aorta. (b) CT scan showing the haematoma around the rupture.

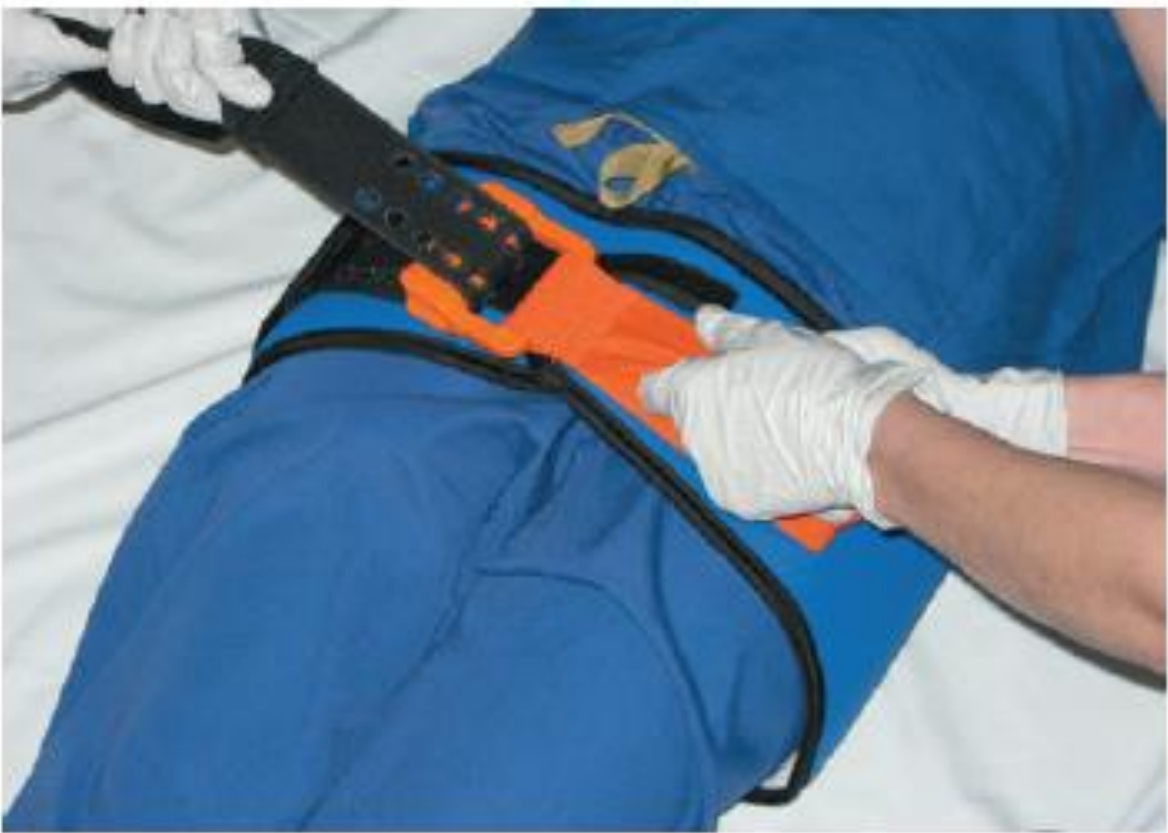

(a)



(b)

**22.24 The C-A-T™ tourniquet**  
(a) Tourniquet in use. (b) Tourniquet components.

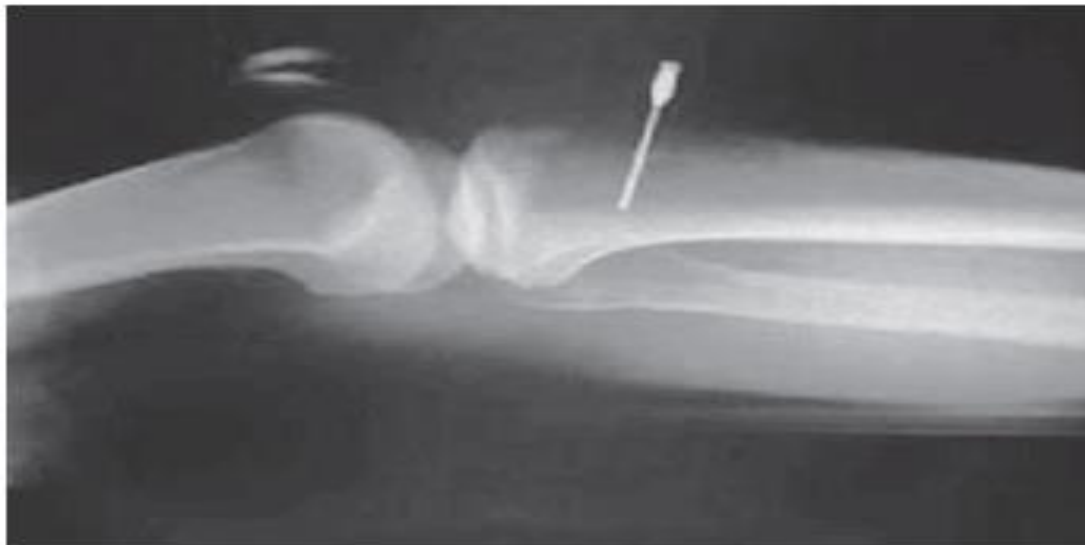


22.25 SAM Sling™ ratcheted compression belt in use



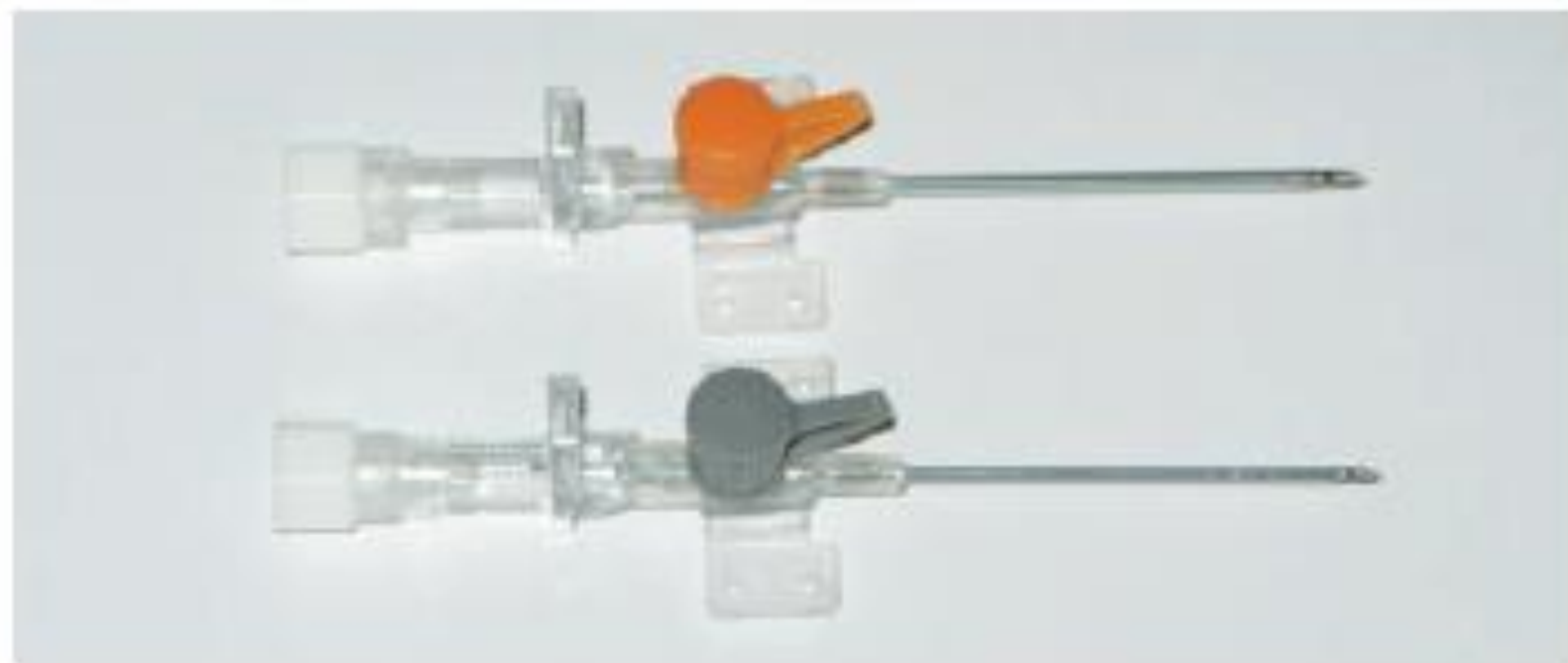

(a)

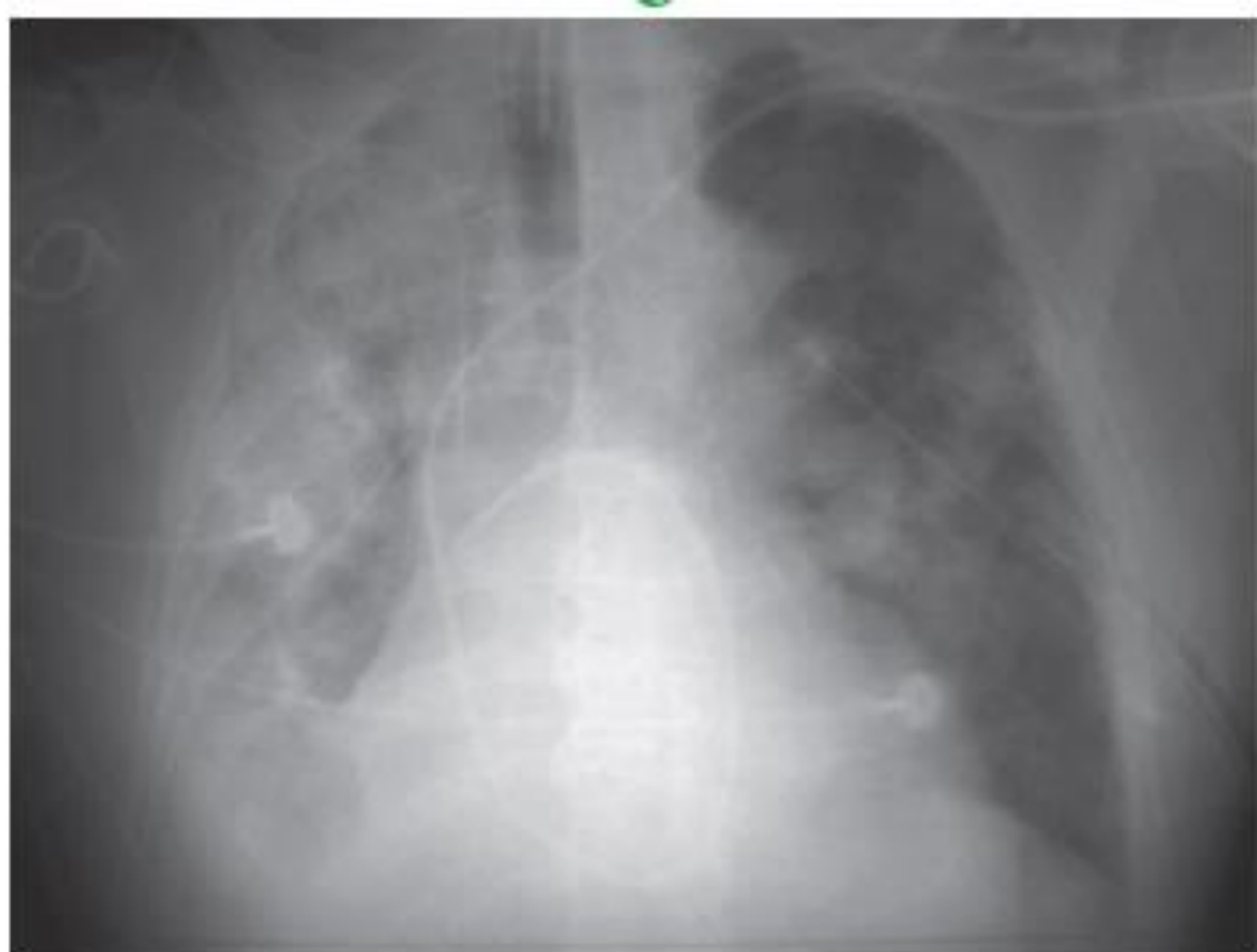

(b)

**22.27 Intraosseous cannulation.** (a) The Cook paediatric intraosseus needle. (b) Intraosseous needle in place in the medial proximal tibia.

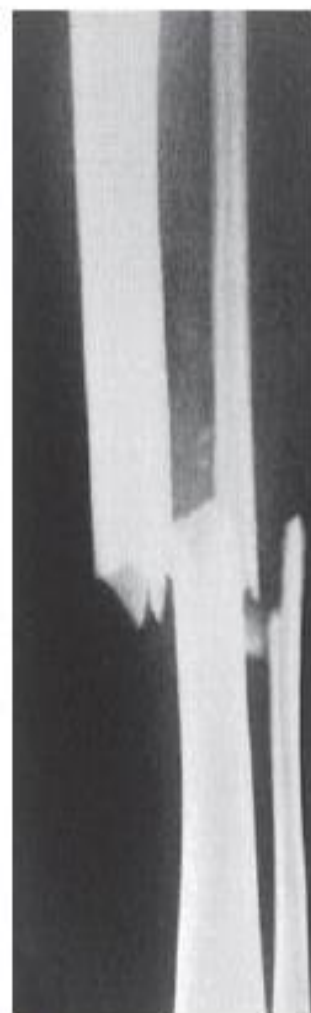

**22.26 Cannulas** A 16-gauge cannula (grey tap) has a 20 per cent smaller diameter but 40 per cent less flow than a 14-gauge cannula (orange tap).

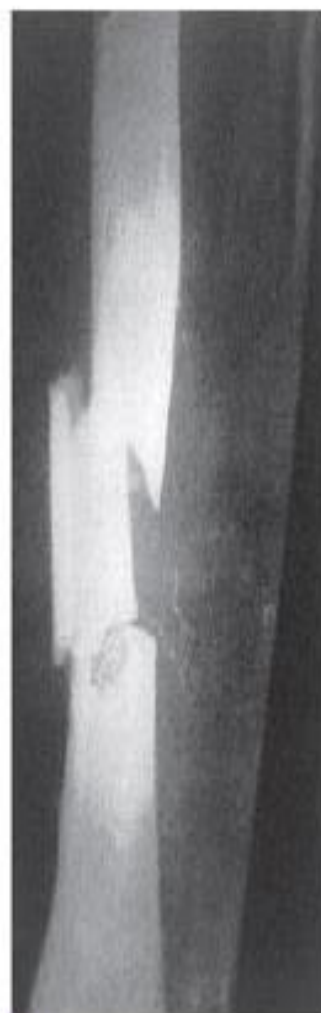


**22.38 ARDS – x-ray** Chest radiograph of a patient with ARDS following pulmonary contusion. Infiltrates and patchy consolidation are typical features. Note the pulmonary artery catheter in situ.

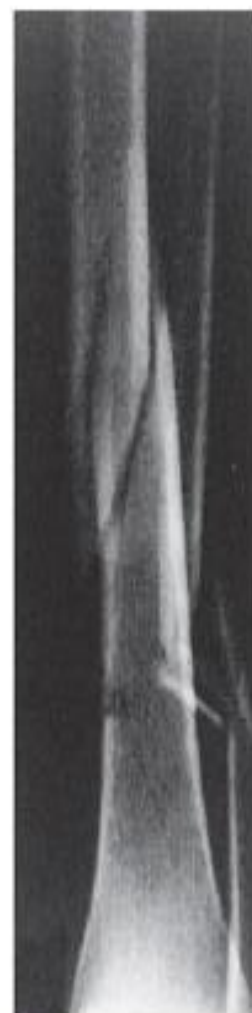



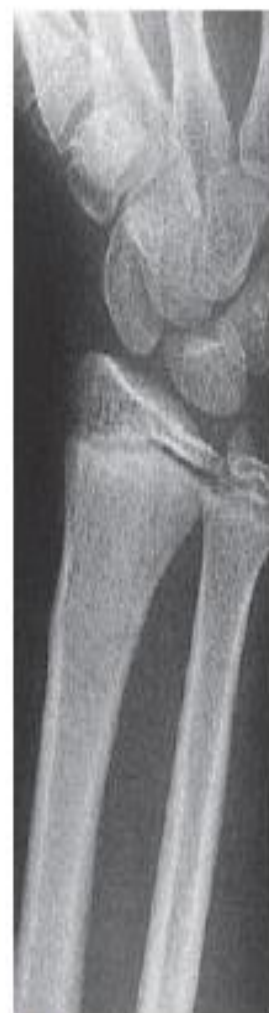(a)



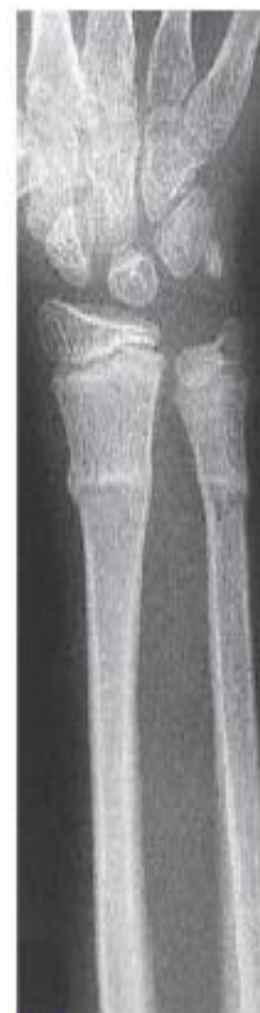(b)



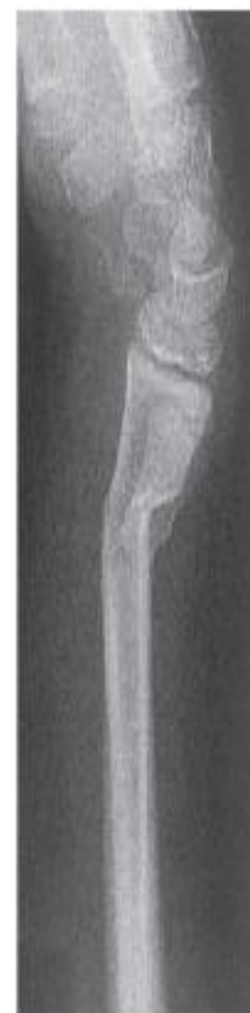(c)



(d)

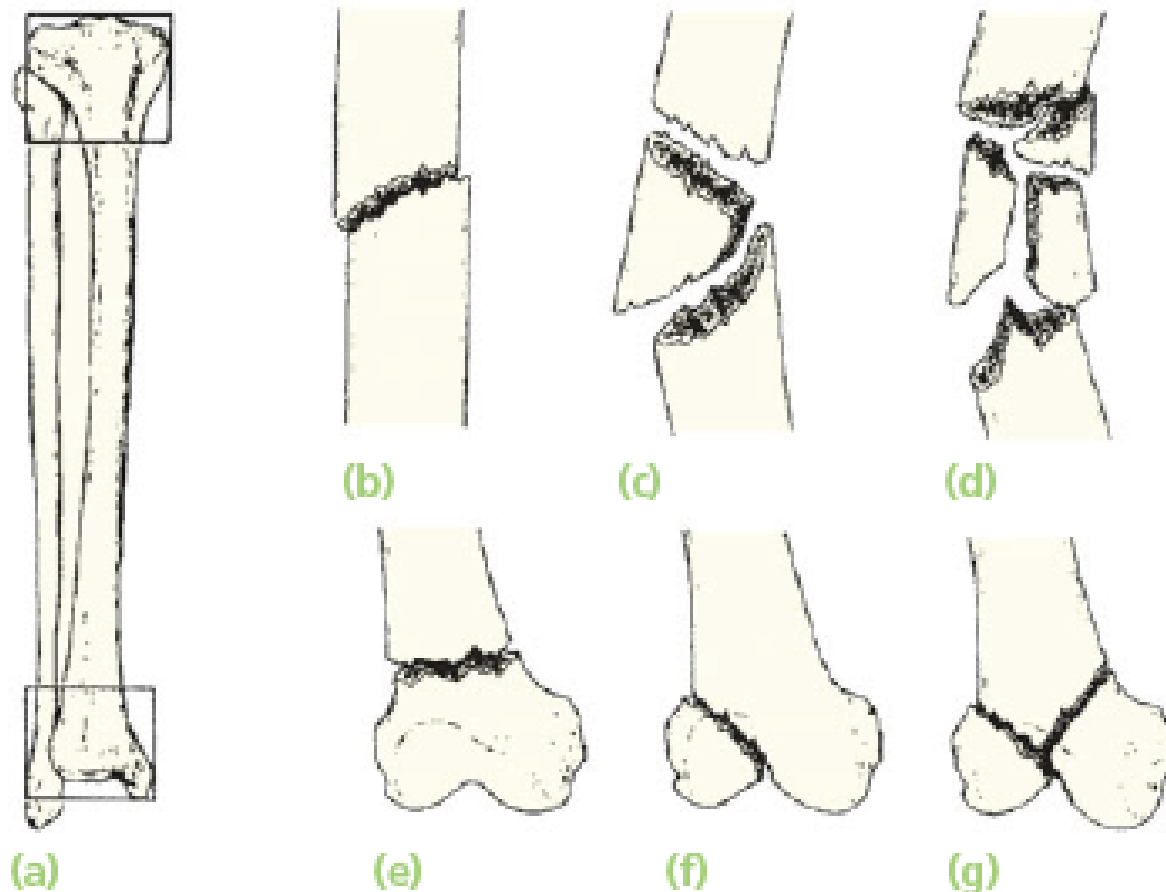


(e)

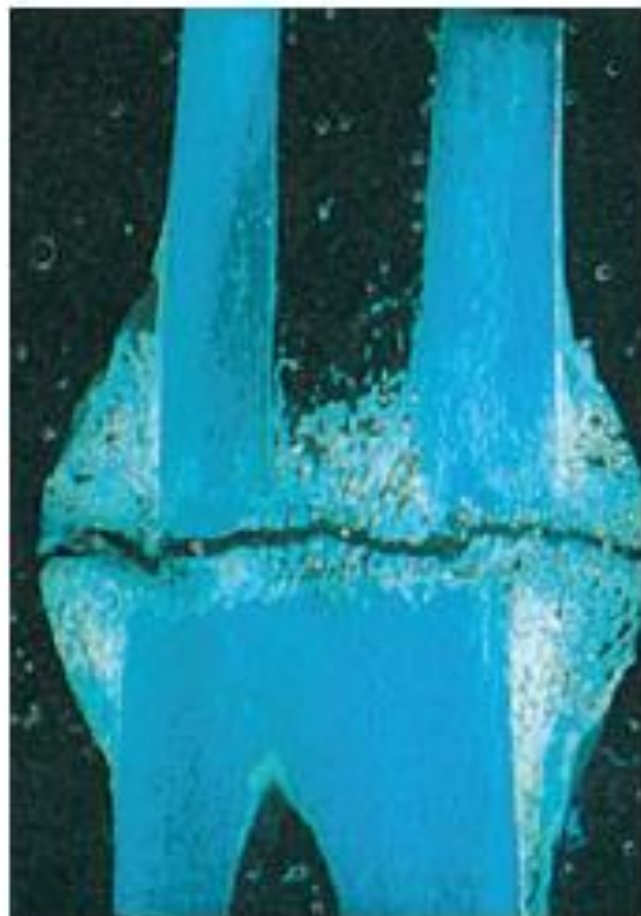


(f)

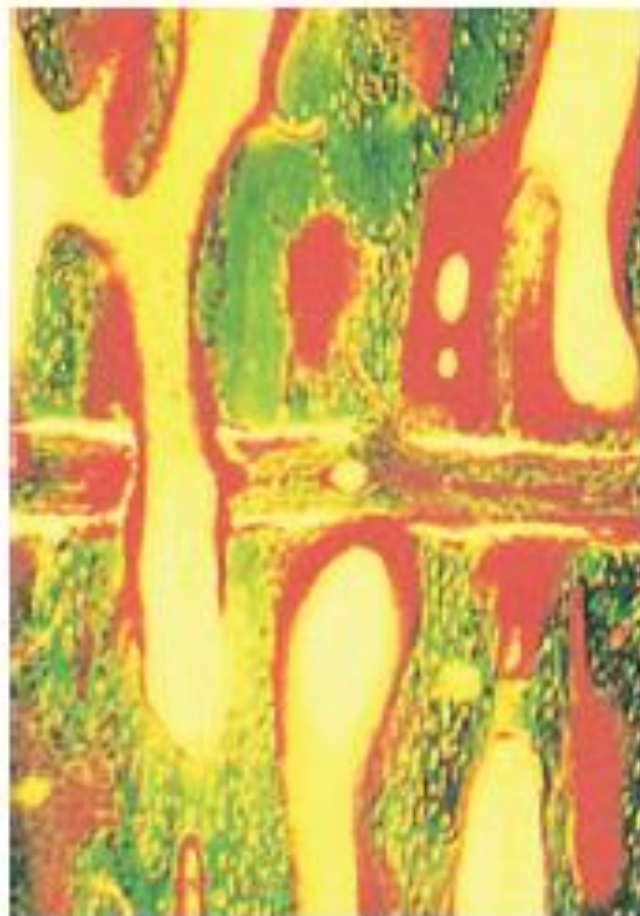
**23.2 Varieties of fracture** Complete fractures: (a) transverse; (b) segmental and (c) spiral. Incomplete fractures: (d) buckle or torus and (e,f) greenstick.



**23.3 Müller's classification** (a) Each long bone has three segments – proximal, diaphyseal and distal; the proximal and distal segments are each defined by a square based on the widest part of the bone. (b,c,d) Diaphyseal fractures may be simple, wedge or complex. (e,f,g) Proximal and distal fractures may be extra-articular, partial articular or complete articular.

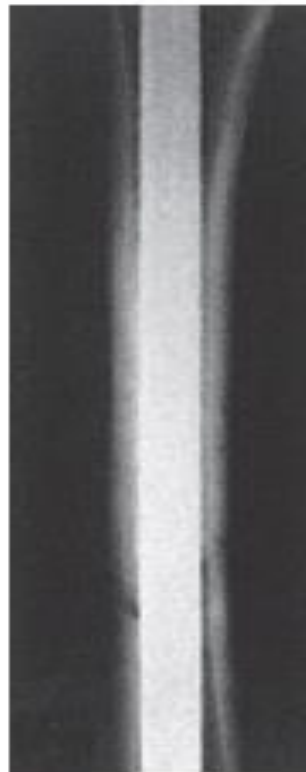


(a)

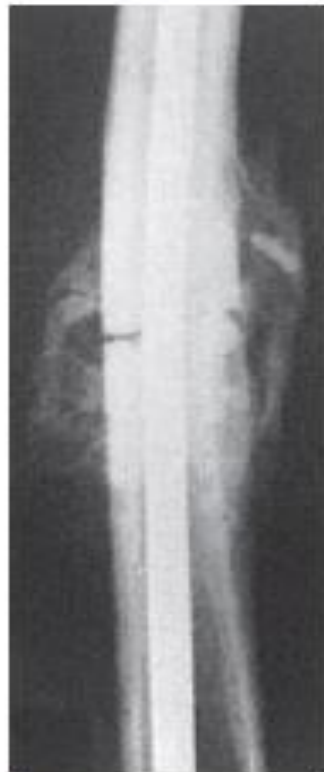


(b)

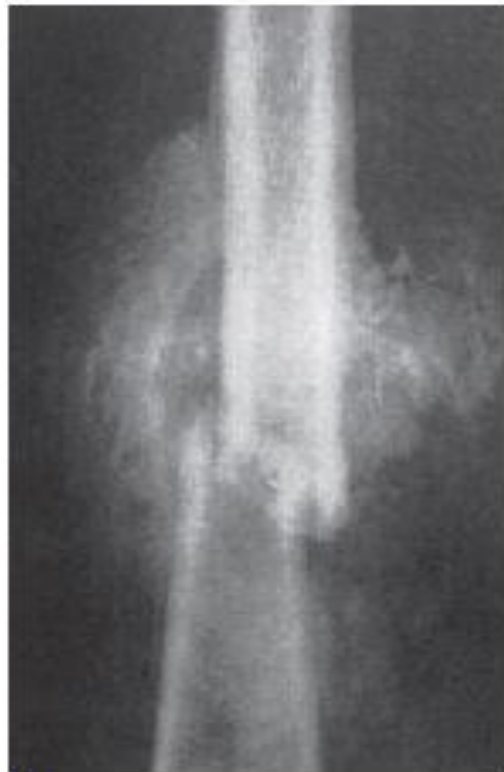**23.5 Fracture healing – histology** Experimental fracture healing: (a) by bridging callus and (b) by direct penetration of the fracture gap by a cutting cone.



(a)

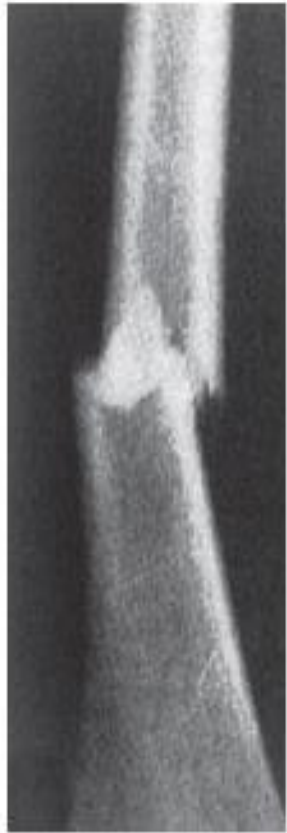

(b)

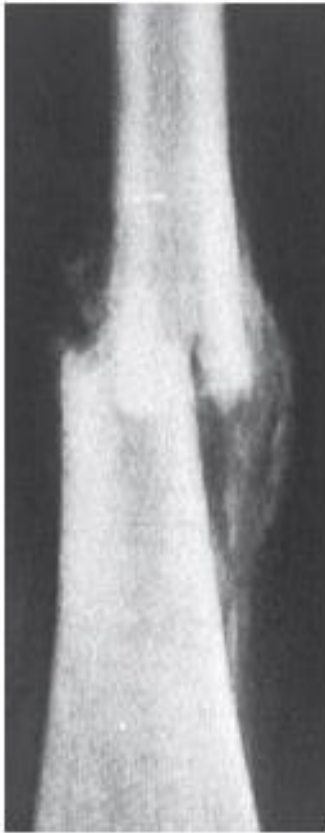

(c)

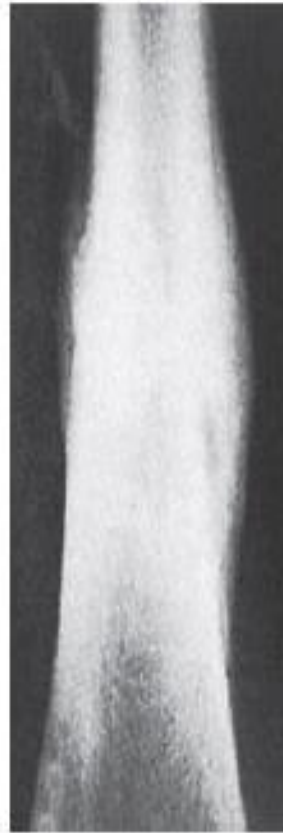
**23.6 Callus and movement** Three patients with femoral shaft fractures. (a) and (b) are both 6 weeks after fixation: in (a) the Kuntscher nail fitted tightly, preventing movement, and there is no callus; in (b) the nail fitted loosely, permitting some movement, so there is callus. (c) This patient had cerebral irritation and thrashed around wildly; at 3 weeks callus is excessive.



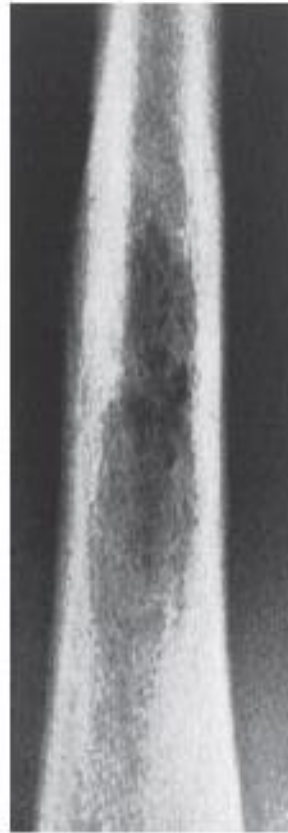
(a)



(b)



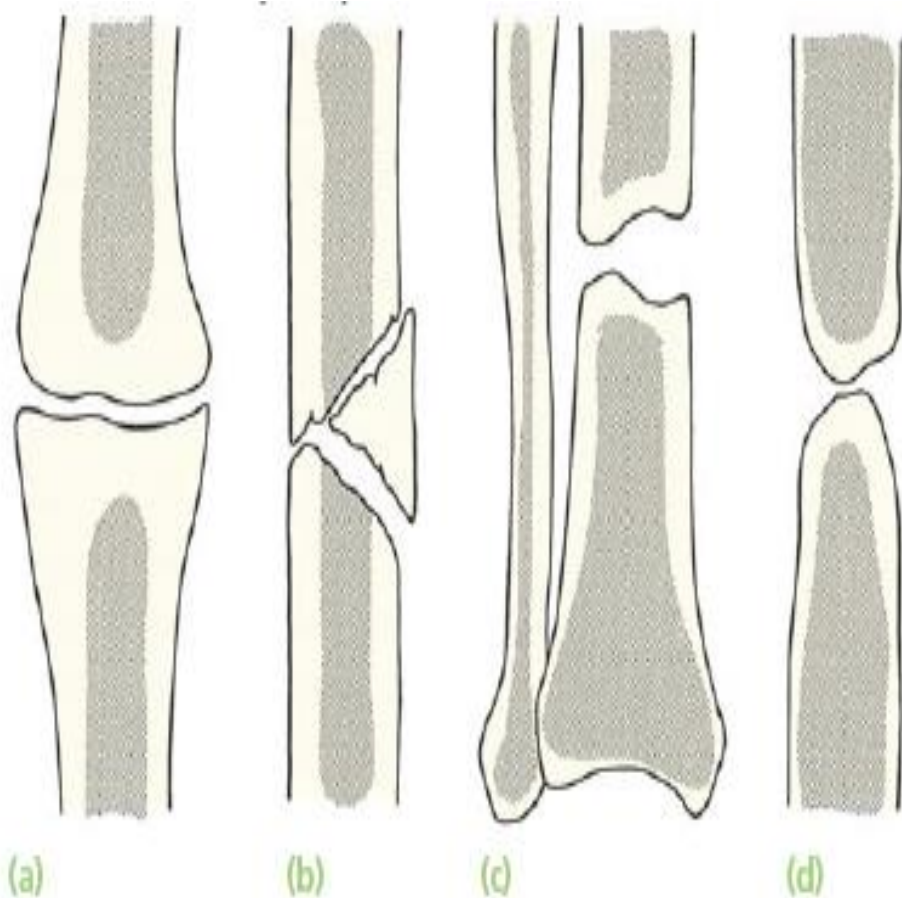
(c)



(d)

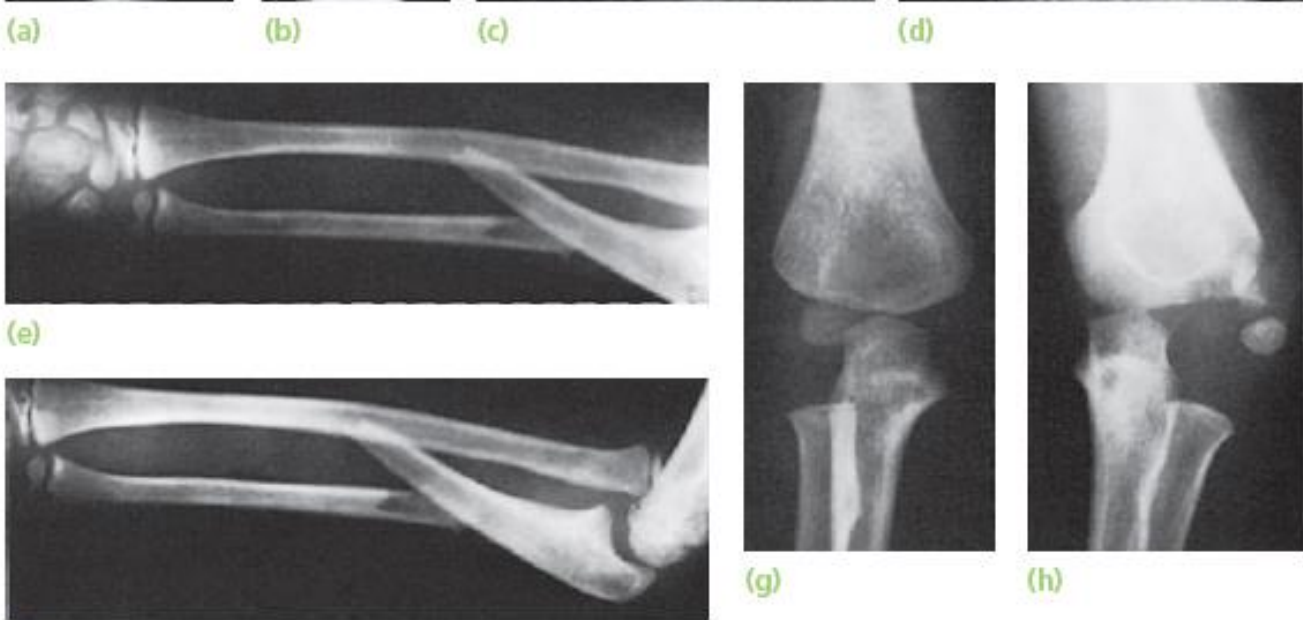
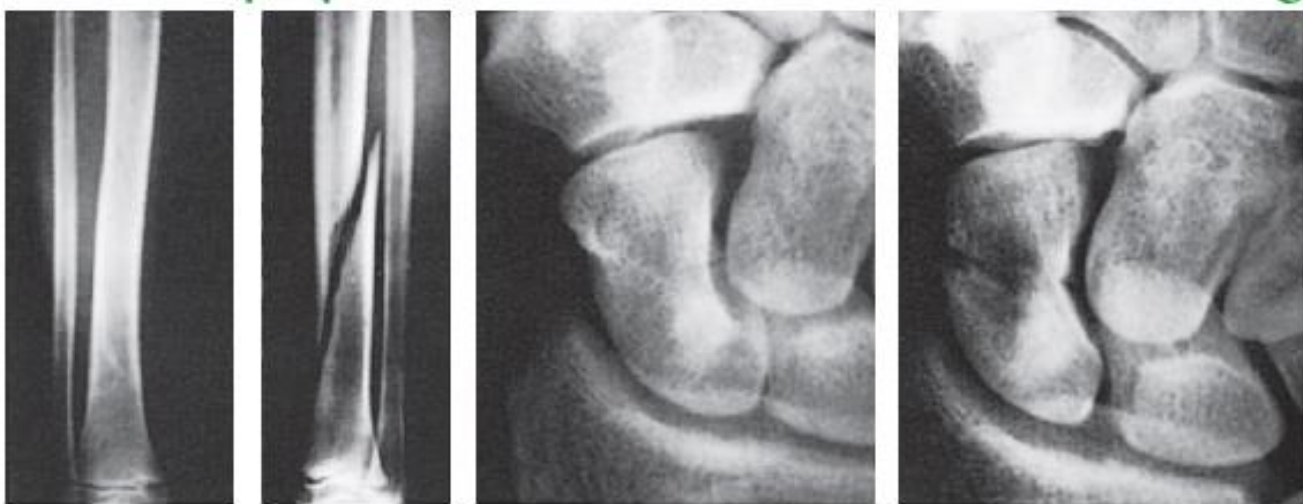
**23.7 Fracture repair** (a) Fracture; (b) union; (c) consolidation; (d) bone remodelling. The fracture must be protected until consolidated.



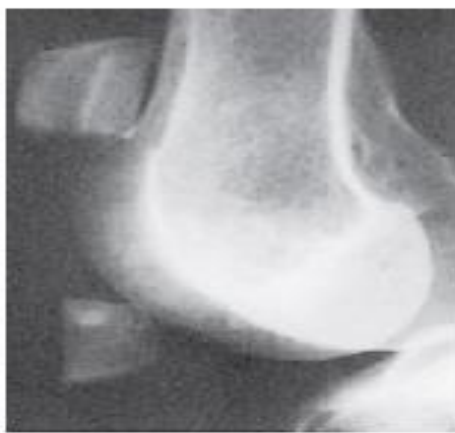

**23.8 Non-unions** Aseptic non-unions are generally divided into hypertrophic and atrophic types. Hypertrophic non-unions often have florid streams of callus around the fracture gap – the result of insufficient stability. They are sometimes given colourful names, such as: (a) elephant's foot. In contrast, atrophic non-unions usually arise from an impaired repair process; they are classified according to the x-ray appearance as (b) necrotic, (c) gap and (d) atrophic.

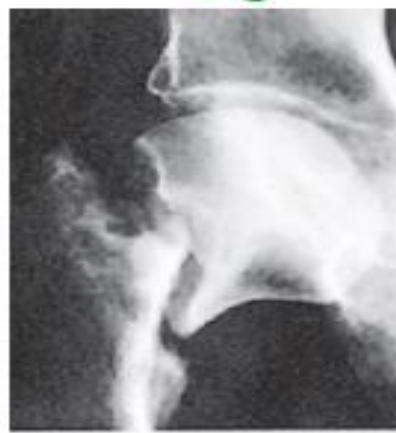



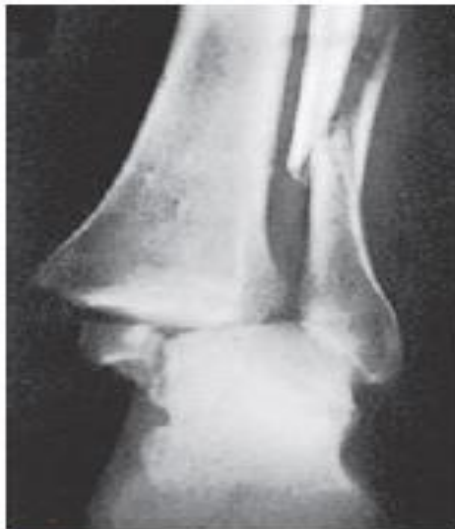**23.9 X-ray examination must be 'adequate'** (a,b) Two films of the same tibia: the fracture may be 'invisible' in one view and perfectly plain in a view at right angles to that. (c,d) More than one occasion: A fractured scaphoid may not be obvious on the day of injury, but clearly seen 2 weeks later. (e,f) Two joints: The first x-ray (e) did not include the elbow. This was, in fact, a Monteggia fracture – the head of the radius is dislocated; (f) shows the dislocated radiohumeral joint. (g,h) Two limbs: Sometimes the abnormality can be appreciated only by comparison with the normal side; in this case there is a fracture of the lateral condyle on the left side (h).



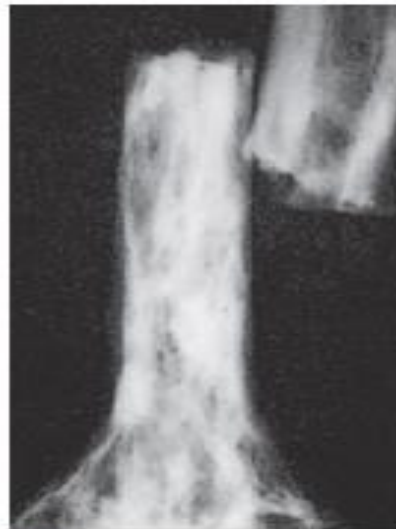(a)



(b)

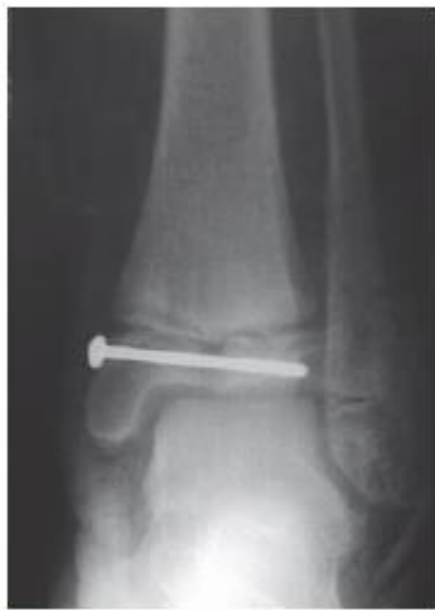

(c)

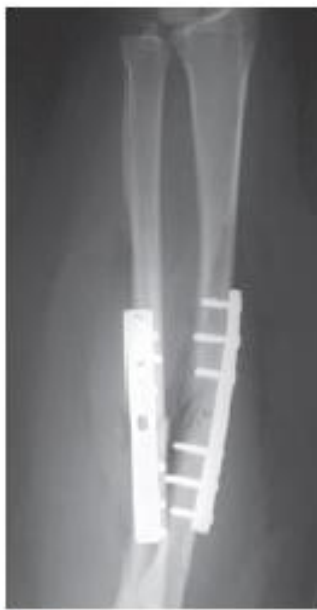

(d)

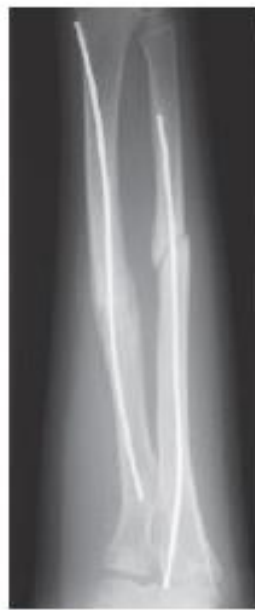**23.20 Indications for internal fixation** (a) This patella has been pulled apart and can be held together only by internal fixation. (b) Fracture dislocation of the ankle is often unstable after reduction and usually requires fixation. (c) This patient was considered to be too ill for operation; her femoral neck fracture has failed to unite without rigid fixation. (d) Pathological fracture in Paget bone; without fixation, union may not occur.



(a)

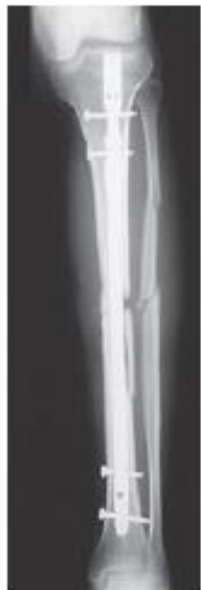

(b)

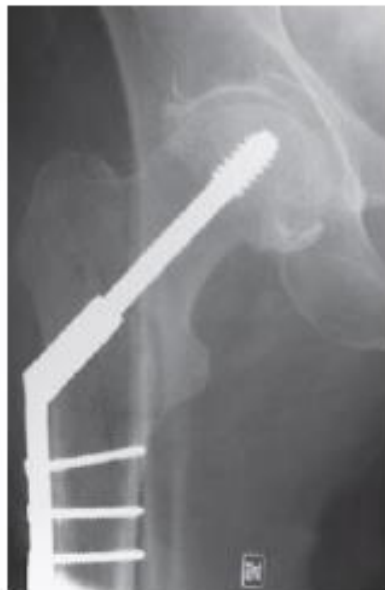

(c)

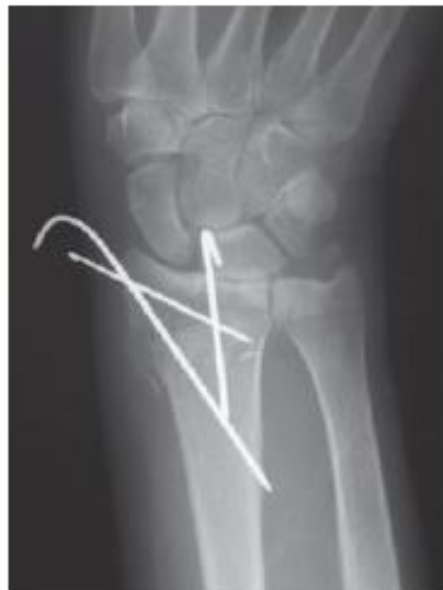**23.21 Internal fixation** The method used must be appropriate to the situation:  
**(a)** screws – interfragmentary compression;  
**(b)** plate and screws – most suitable in the forearm or around the metaphysis; **(c)** flexible intramedullary nails – for long bones in children, particularly forearm bones and the femur; **(d)** interlocking nail and screws – ideal for the femur and tibia; **(e)** dynamic compression screw and plate – ideal for the proximal and distal ends of the femur; **(f)** simple K-wires – for fractures around the elbow and wrist and **(g)** tension-band wiring – for olecranon or fractures of the patella.



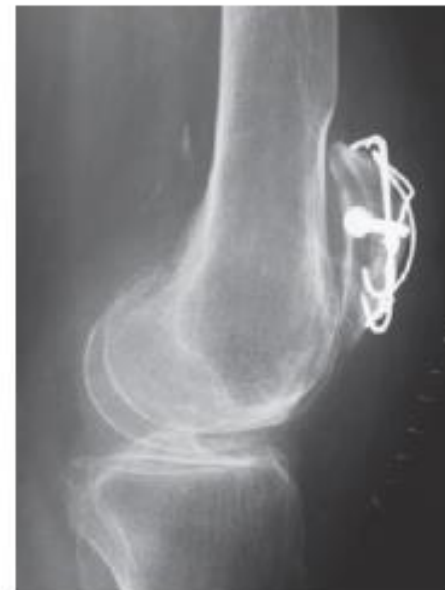(d)



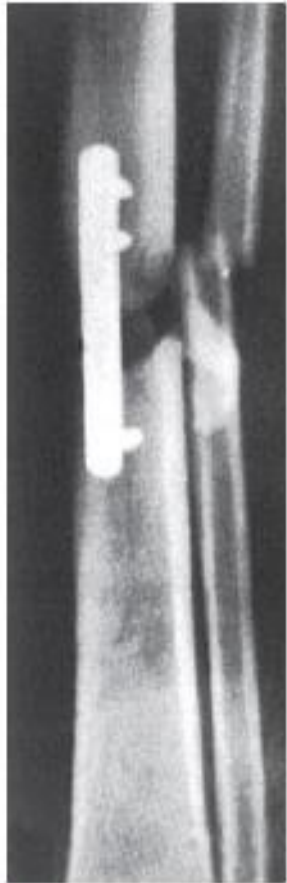(e)



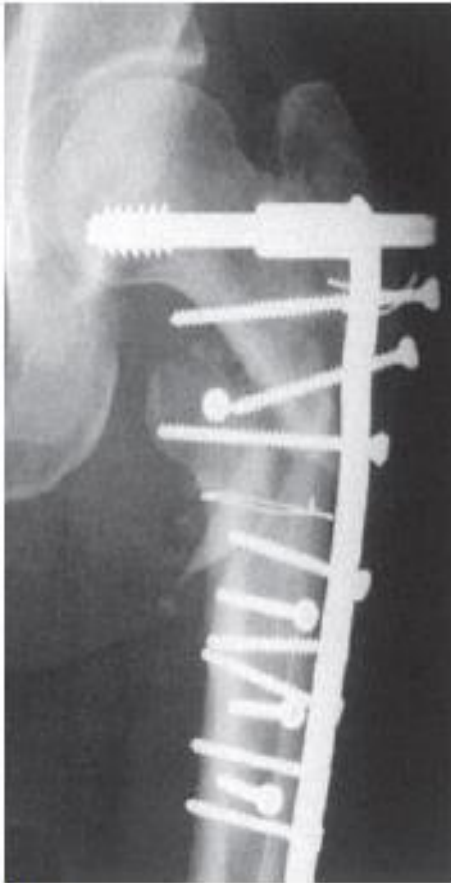
(f)



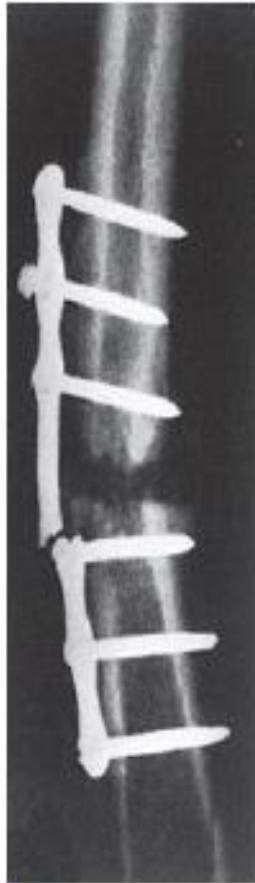(g)



(a)



(b)



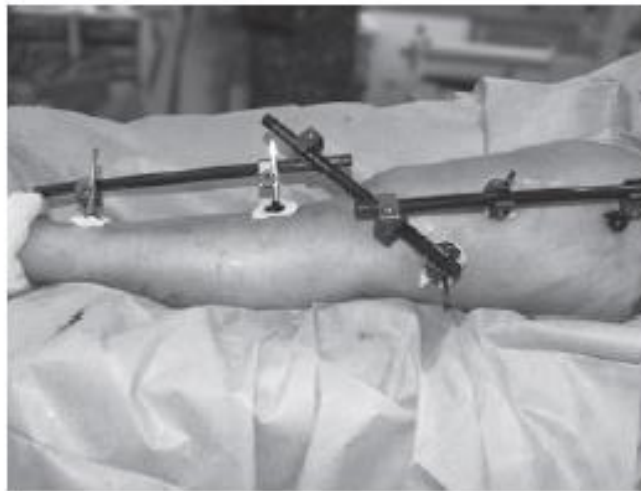
(c)

23.22 Bad fixation (how not to do it)  
(a) Too little. (b) Too much. (c) Too weak.

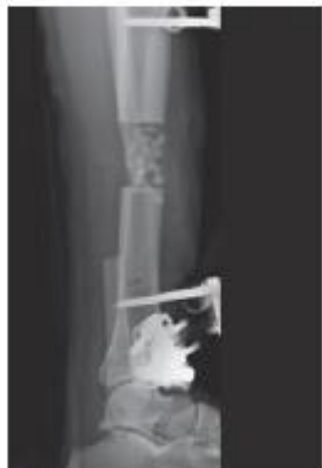



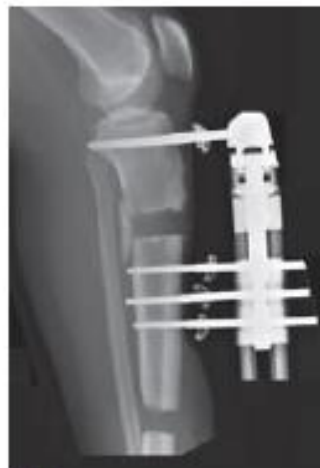(a)



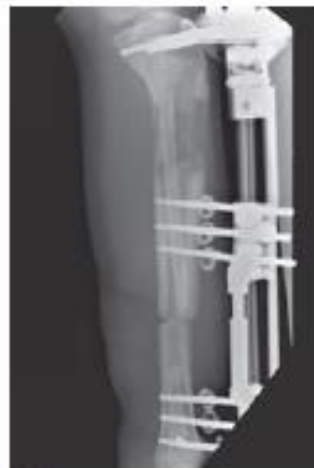(b)



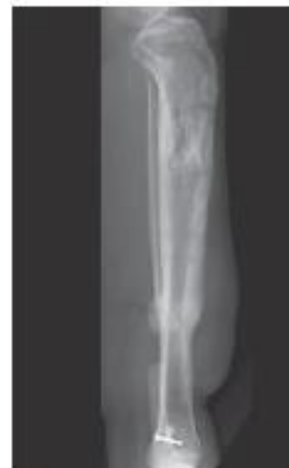(c)



(d)

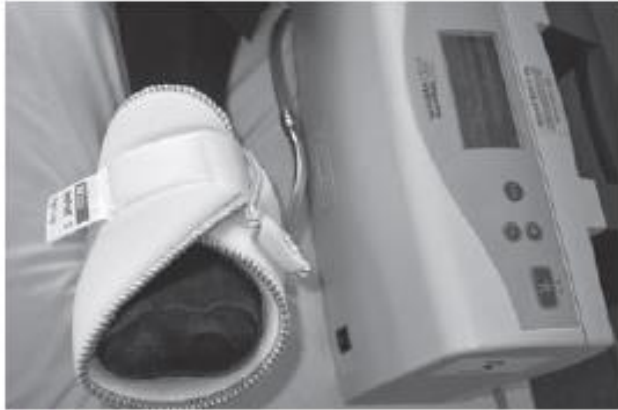

(e)

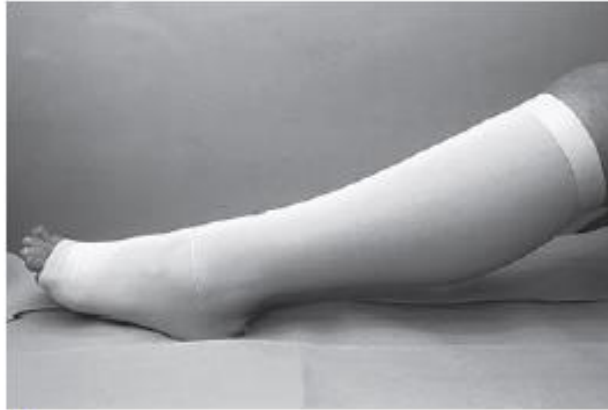

(f)

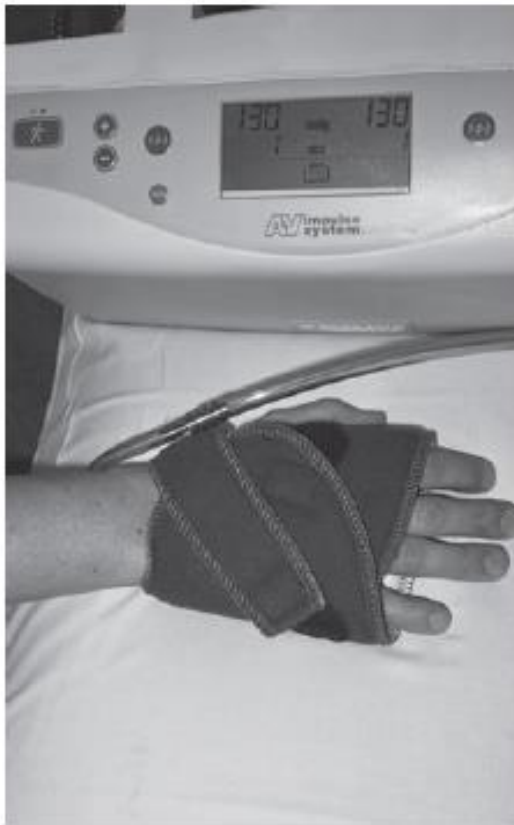**23.23 External fixation of fractures** External fixation is widely used for 'damage control' (a,b) temporary stabilization of fractures in order to allow the patient's general condition or the state of soft tissues to improve prior to definitive surgery or (c-f) reconstruction of limbs using distraction osteogenesis. (c) A bone defect after surgical resection with gentamicin beads used to fill the space temporarily. (d) Bone transport from a more proximal osteotomy. (e) 'Docking' of the transported segment and (f) final union and restoration of structural integrity.



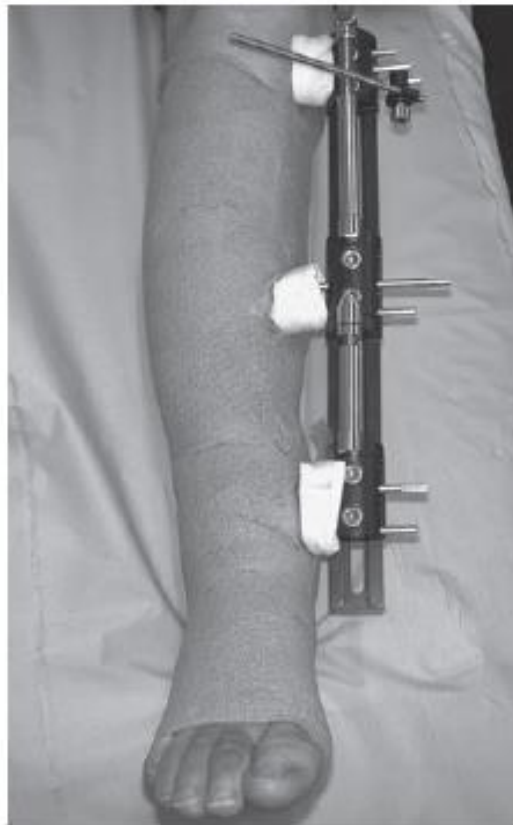(a)



(b)



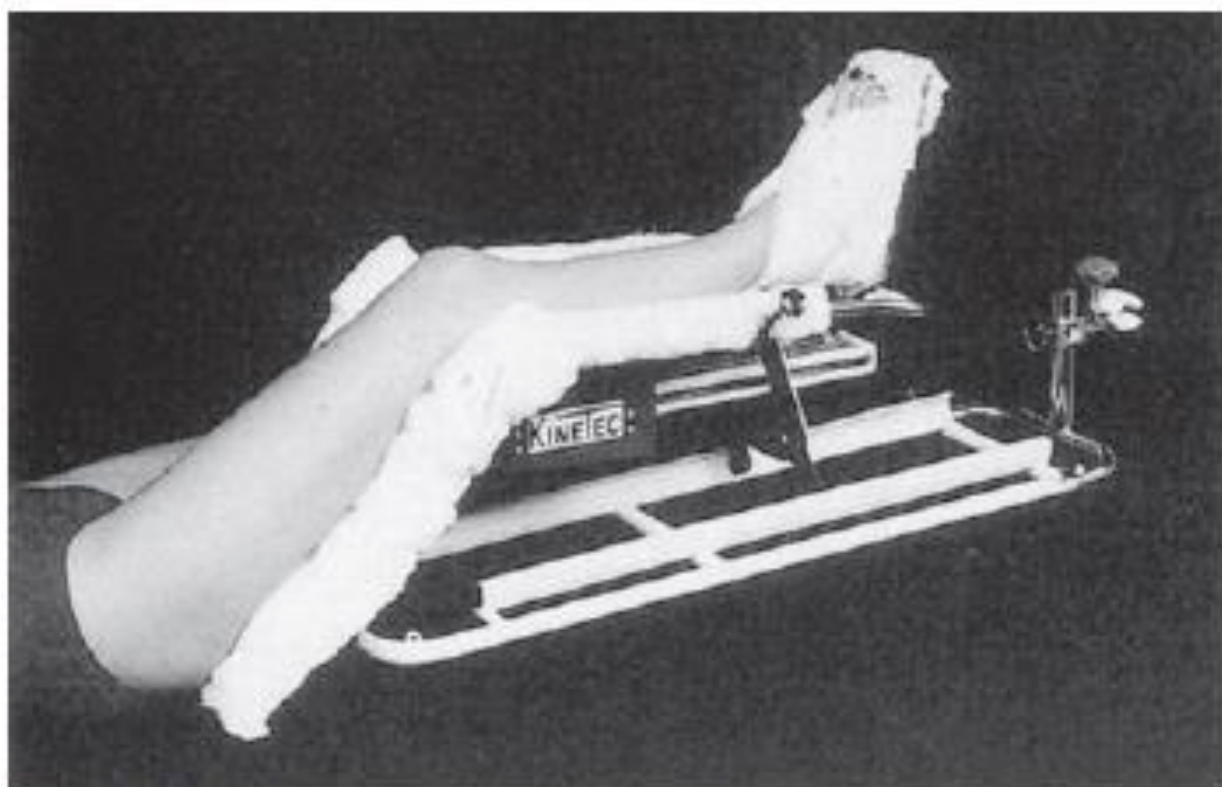
(c)



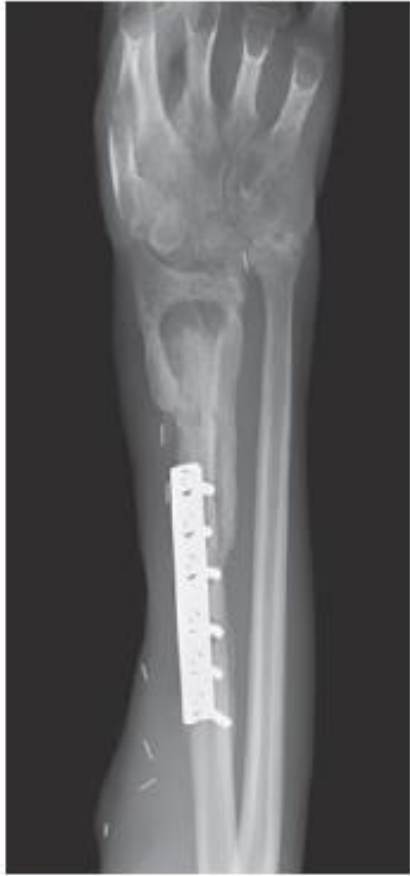(d)

**23.24 Some aspects of soft tissue treatment** Swelling is minimized by improving venous drainage. This can be accomplished by: (1) elevation and (2) firm support. Stiffness is minimized by exercise. (a,c) Intermittent venous plexus pumps for use on the foot or palm to help reduce swelling. (b) A made-to-measure pressure garment that helps reduce swelling and scarring after treatment. (d) Coban wrap around a limb to control swelling during treatment.

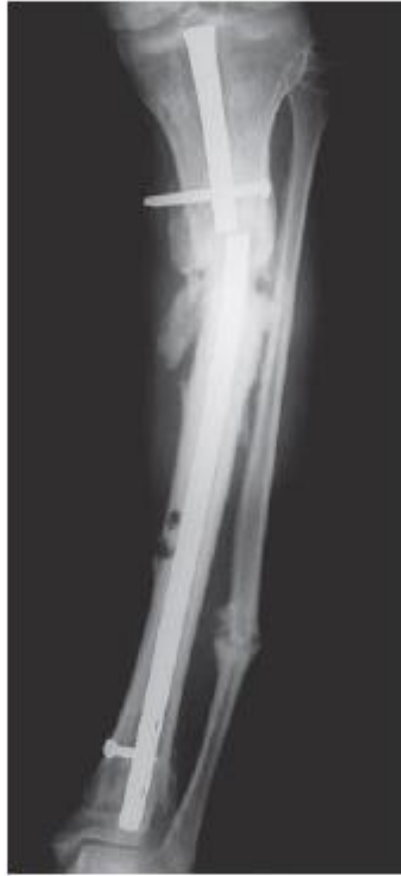



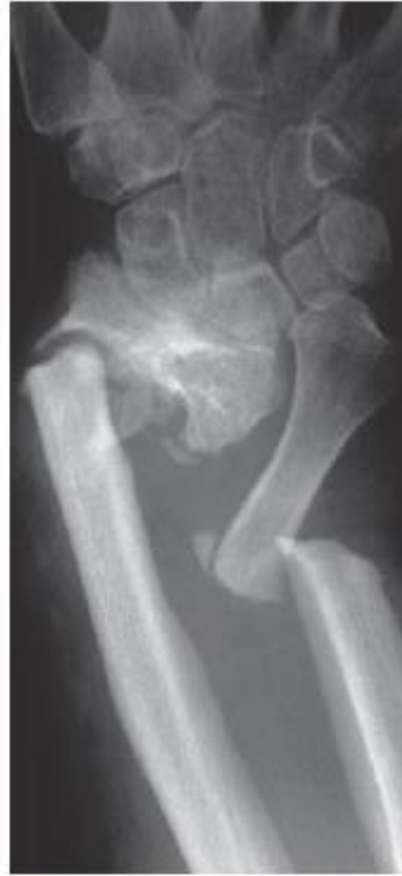**23.25 Continuous passive motion** The motorized frame provides continuous flexion and extension to pre-set limits.



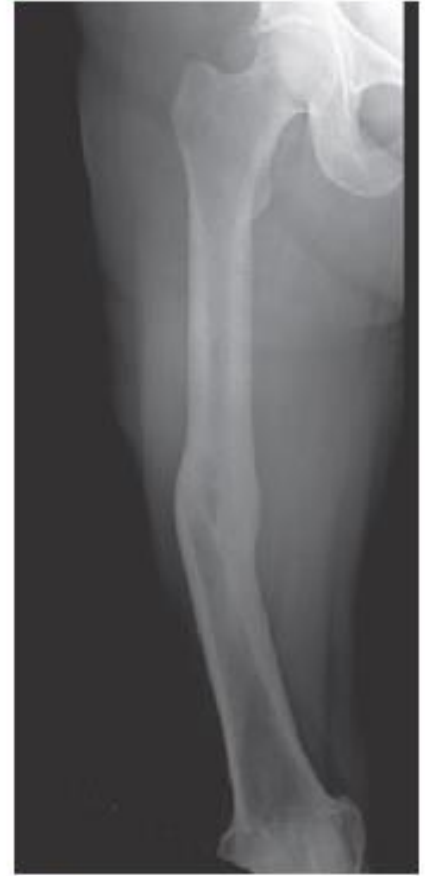(a)



(b)

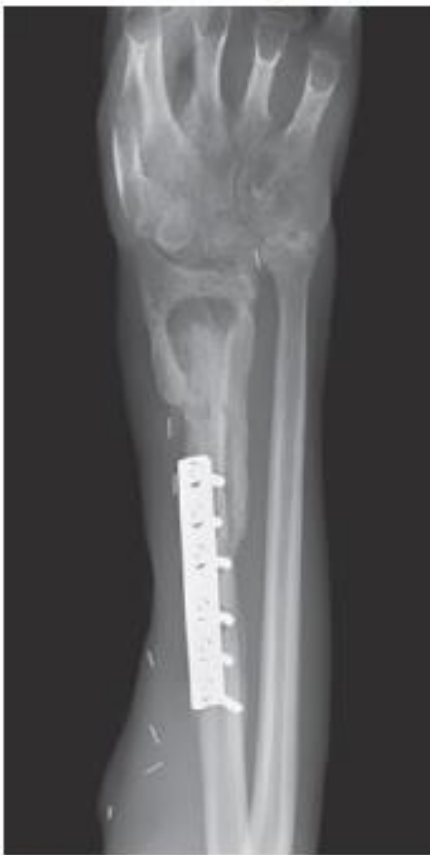

(c)

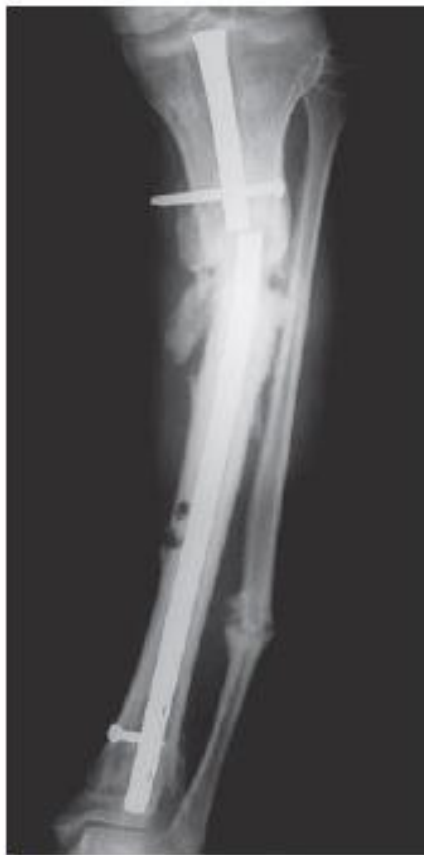

(d)

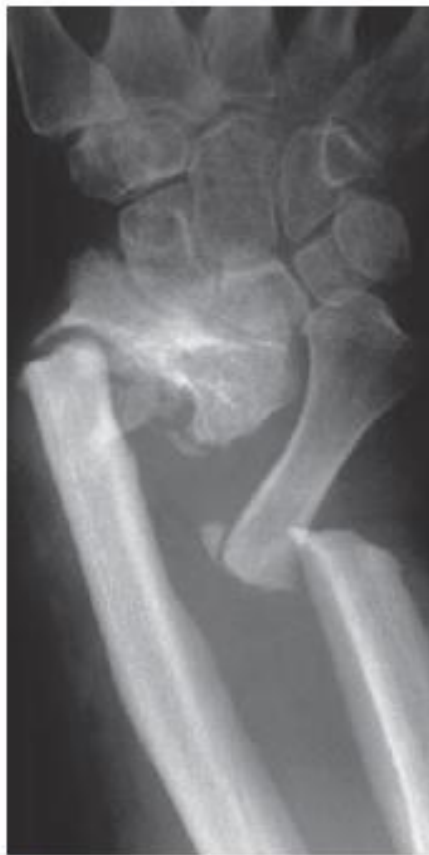**23.30 Complications of fractures** Fractures can become infected (a,b), fail to unite (c) or (d) unite in poor alignment.



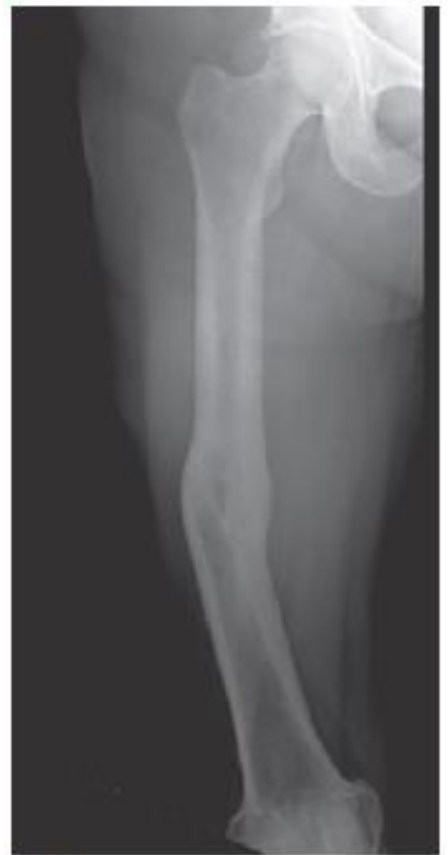(a)



(b)

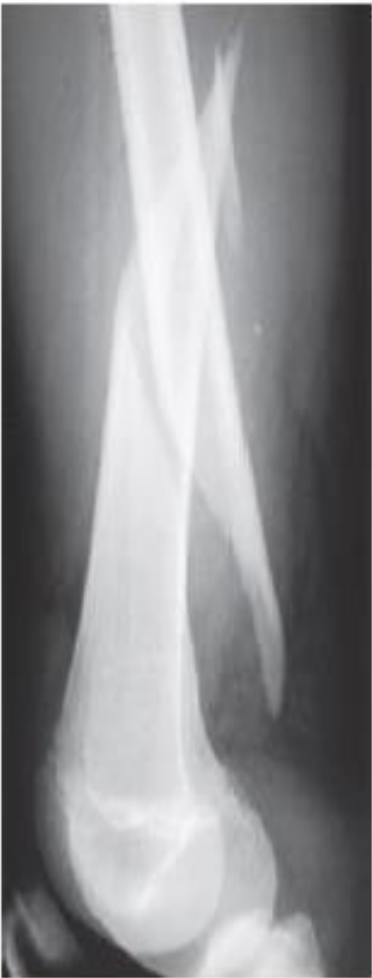

(c)

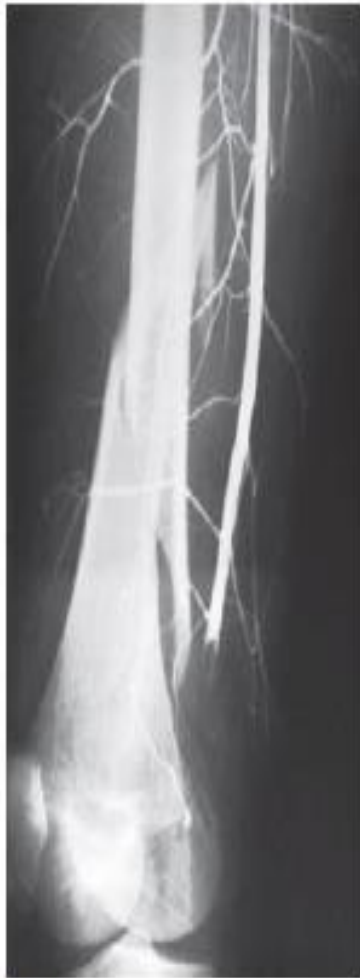

(d)

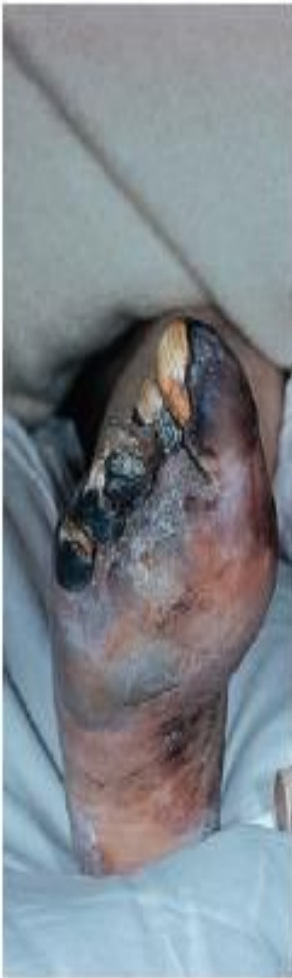**23.30 Complications of fractures** Fractures can become infected (a,b), fail to unite (c) or (d) unite in poor alignment.



(a)

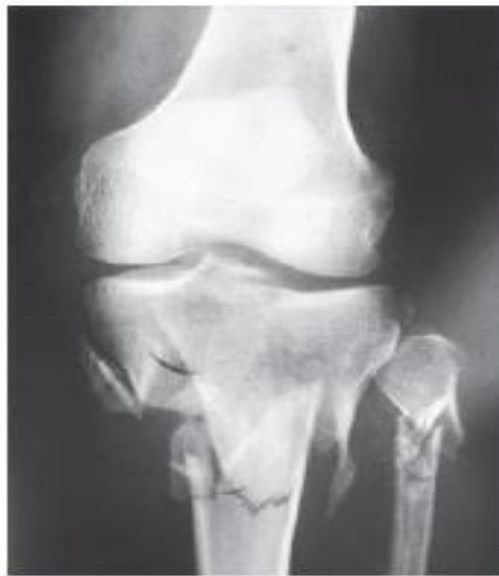

(b)

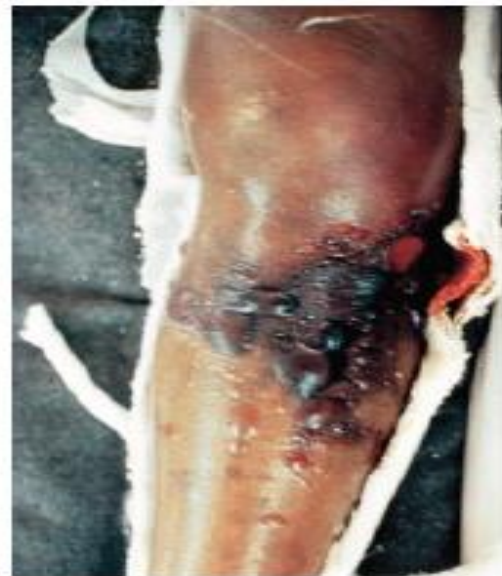

(c)

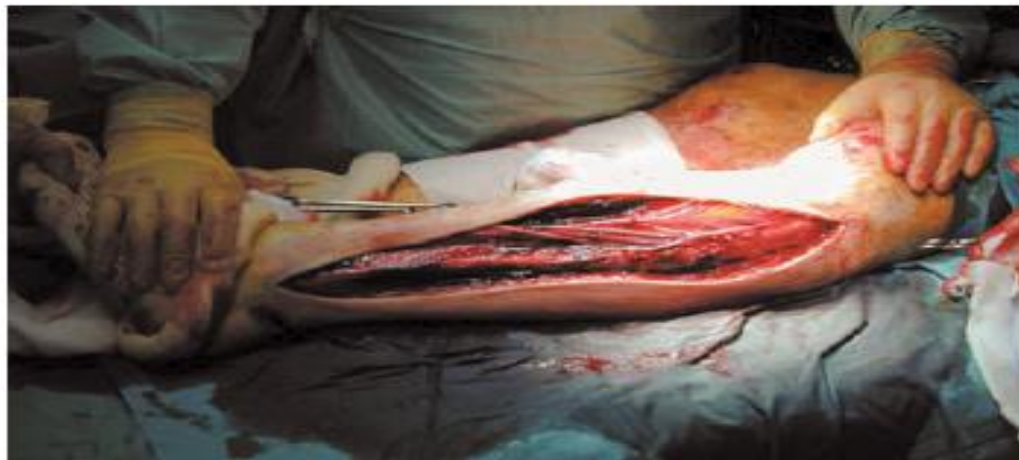**23.32 Vascular injury** This patient was brought into hospital with a fractured femur and early signs of vascular insufficiency. The plain x-ray (a) looked as if the proximal bone fragment might have speared the popliteal artery. The angiogram (b) confirmed these fears. Despite vein grafting the patient developed peripheral gangrene (c).



(a)



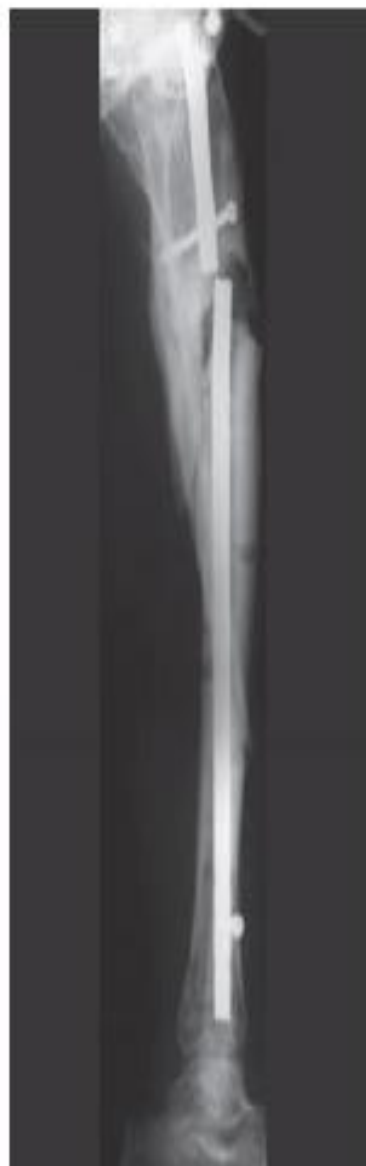(b)



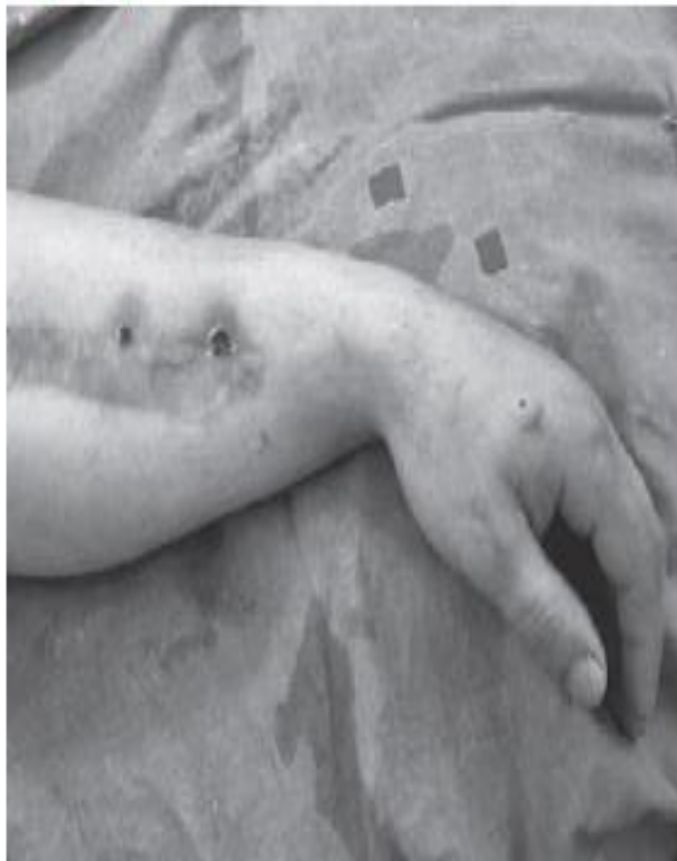(c)

**23.33 Compartment syndrome** (a) A fracture at this level is always dangerous. This man was treated in plaster. Pain became intense and when the plaster was split (which should have been done immediately after its application), the leg was swollen and blistered (b). Tibial compartment decompression (c) requires fasciotomies of *all* the compartments in the leg.

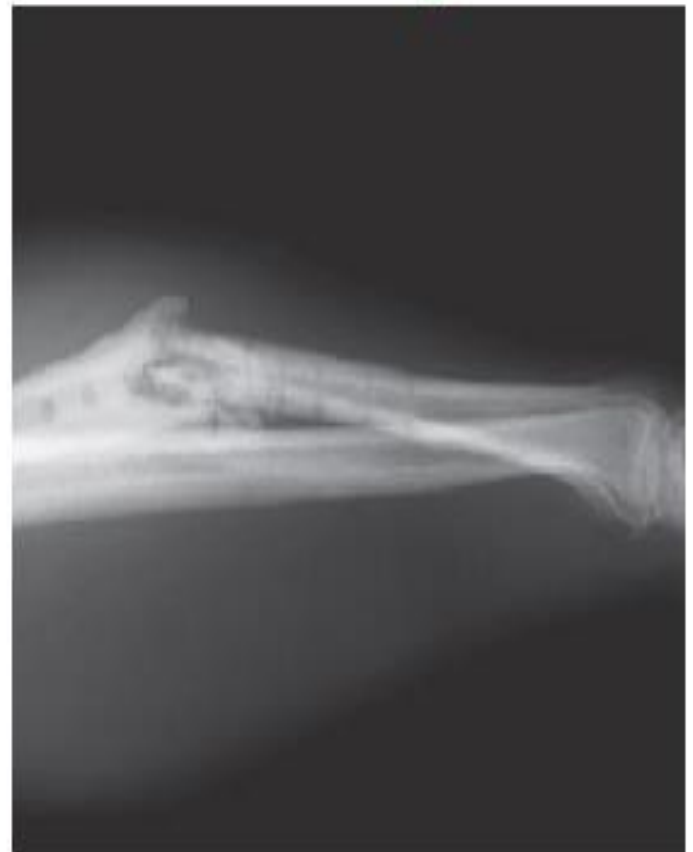



(a)



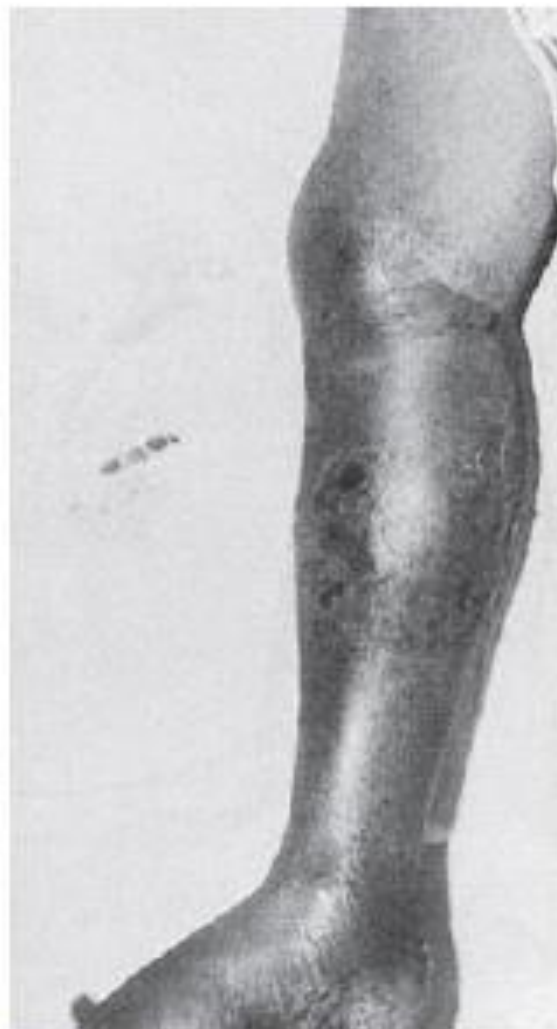(b)



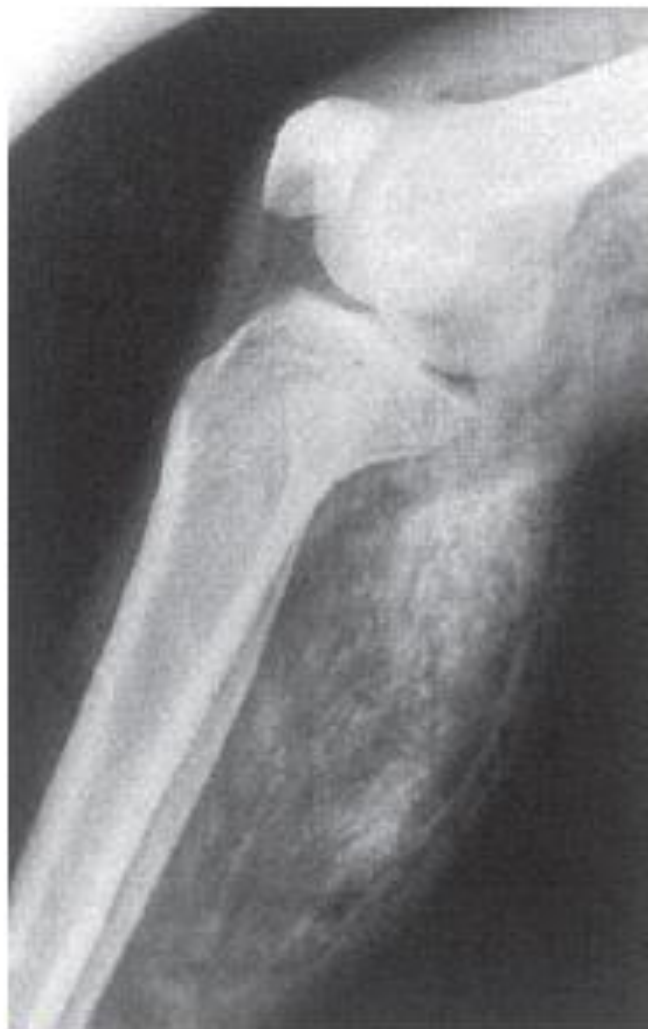(c)

**23.34 Infection after fracture treatment** Operative fixation is one of the commonest causes of infection in closed fractures. Fatigue failure of implants is inevitable if infection hinders union (a). Deep infection can lead to development of discharging sinuses (b,c).



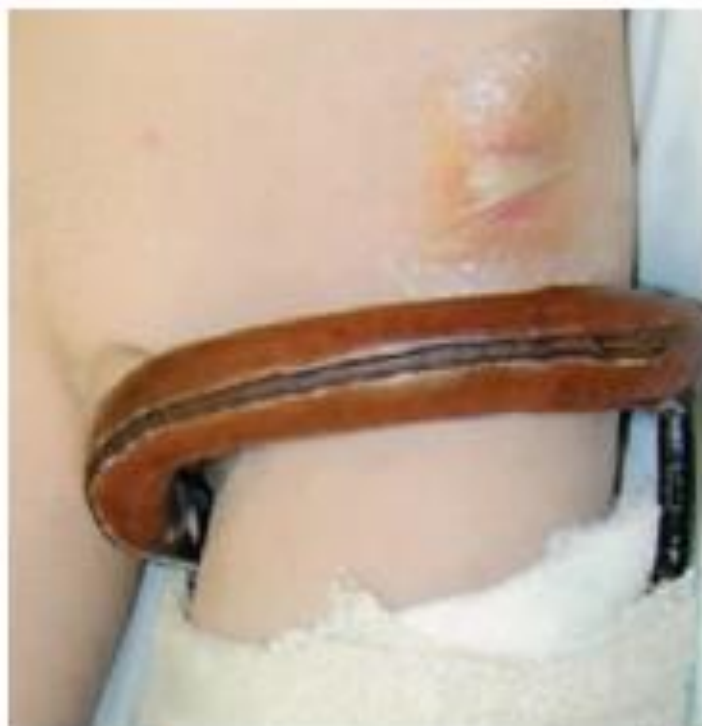

(a)

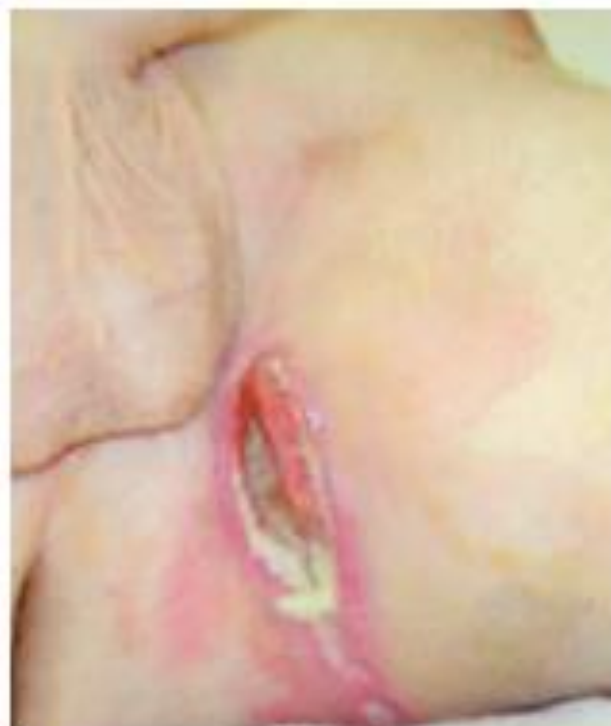

(b)

**23.35 Gas gangrene** (a) Clinical picture of gas gangrene.  
(b) X-rays show diffuse gas in the muscles of the calf.

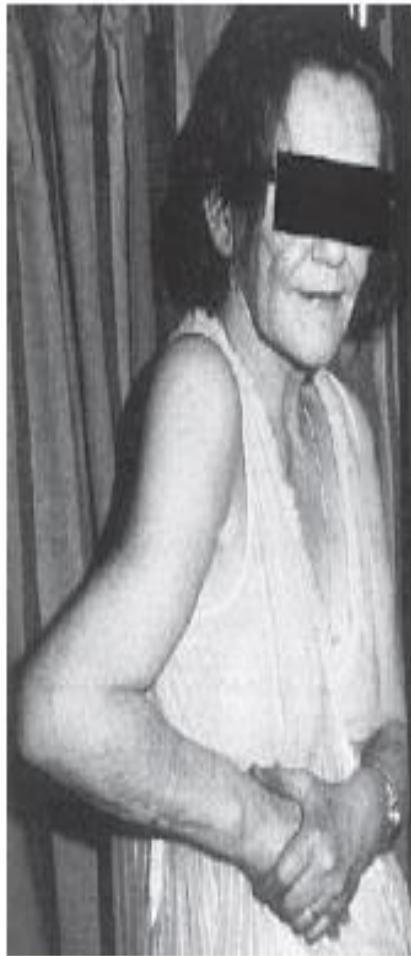

(a)

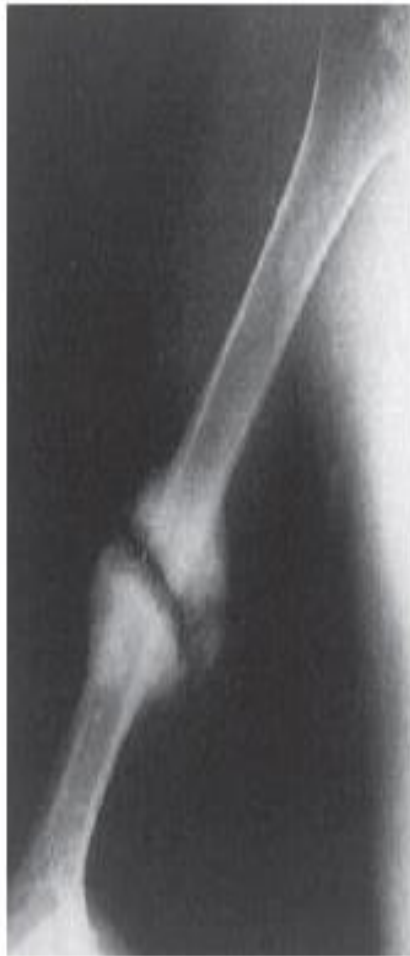

(b)

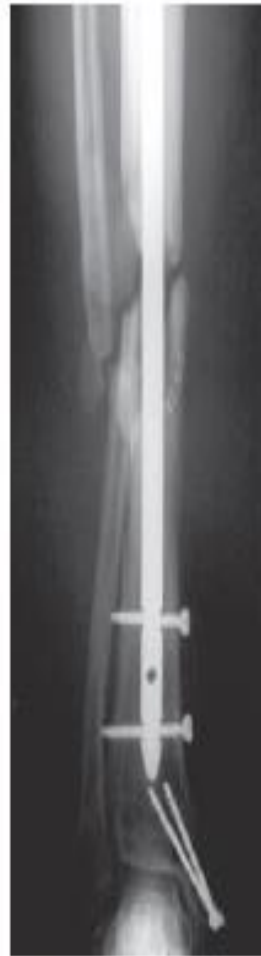**23.36 Pressure sores** Pressure sores are a sign of carelessness. (a,b) Sores from poorly supervised treatment in a Thomas splint.



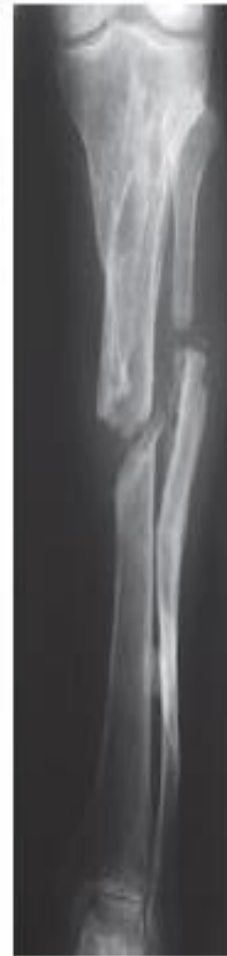(a)



(b)



(c)

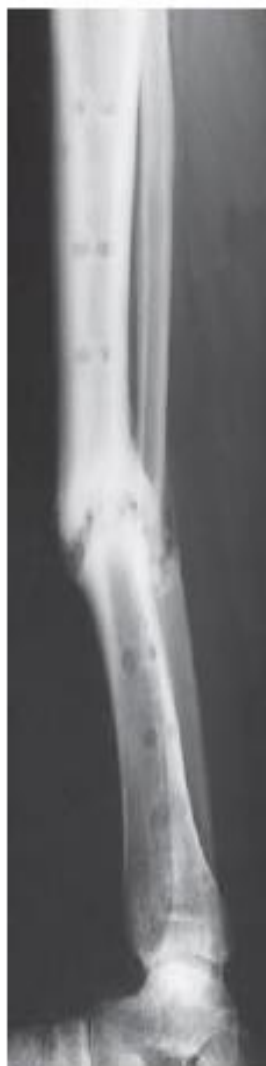

(d)

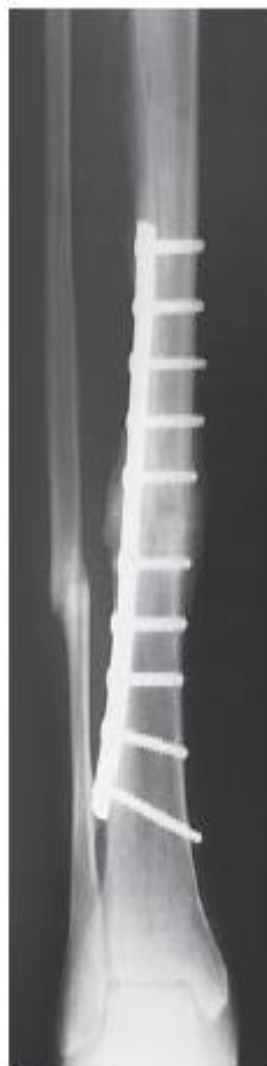### 23.37 Non-union

(a) This patient has an obvious pseudarthrosis of the humerus. The x-ray (b) shows a typical hypertrophic non-union.

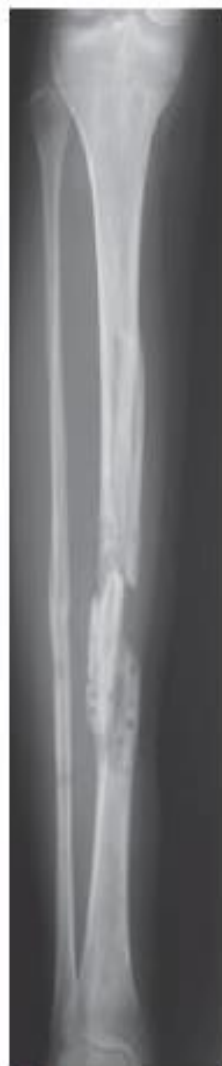(c,d) Examples of atrophic non-union.



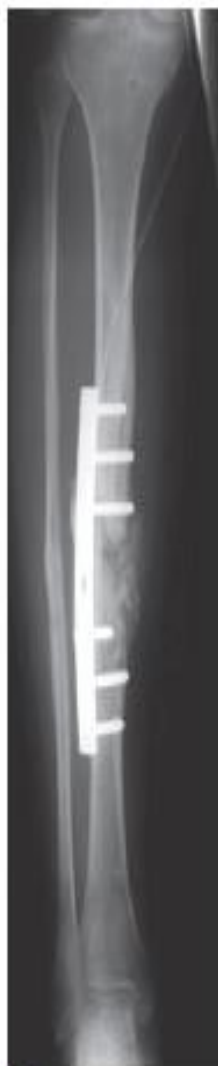(a)



(b)



(c)



(d)

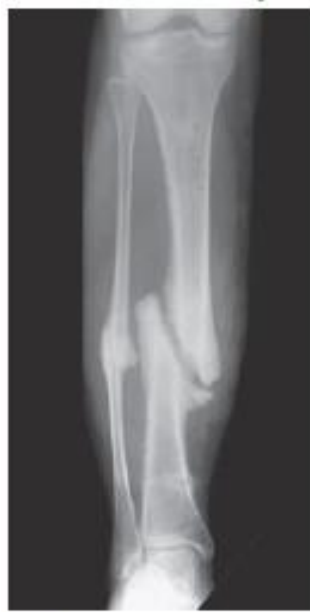

(e)

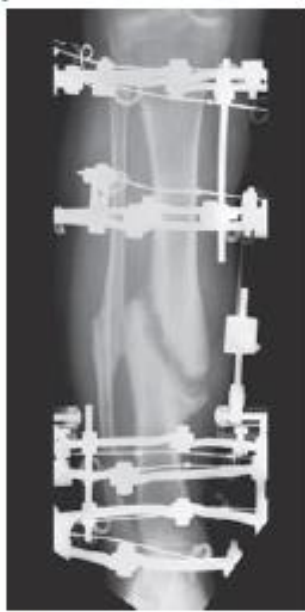### 23.38 Non-union – treatment (a)

This patient with fractures of the tibia and fibula was initially treated by internal fixation with a plate and screws. The fracture failed to heal, and developed the typical features of hypertrophic non-union.

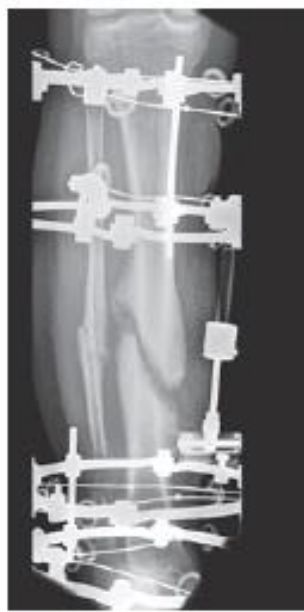(b) After a further operation, using more rigid fixation (and no bone grafts), the fractures healed solidly. (c,d) This patient with atrophic non-union needed both internal fixation and bone grafts to stimulate bone formation and union (e).



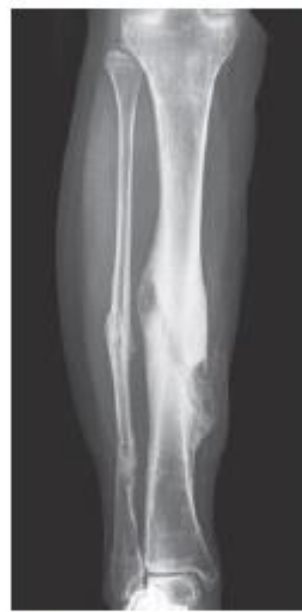(a)



(b)



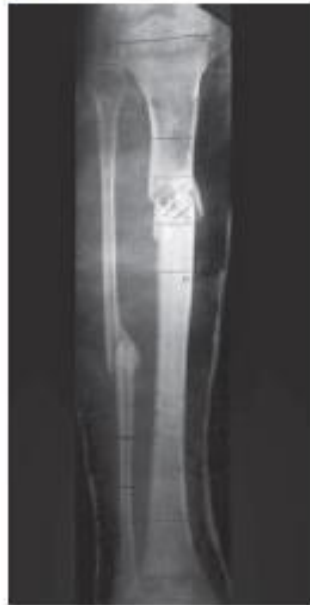(c)



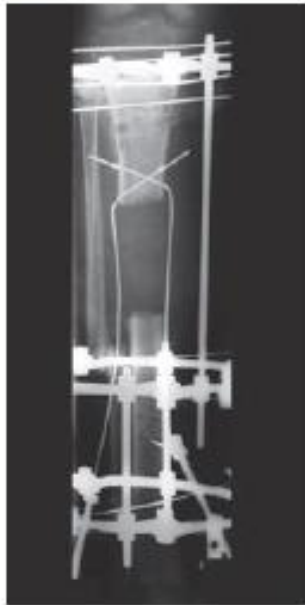(d)

### 23.39 Non-union – treatment by the Ilizarov technique

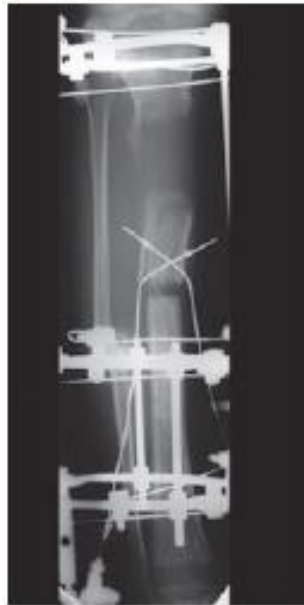Hypertrophic non-unions can be treated by gradual distraction and realignment in an external fixator (a-d). Atrophic non-unions will need more surgery; the poor tissue is excised (e,f) and replaced through bone transport (g,h).



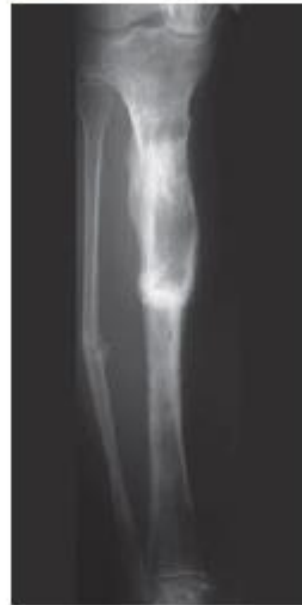(e)



(f)

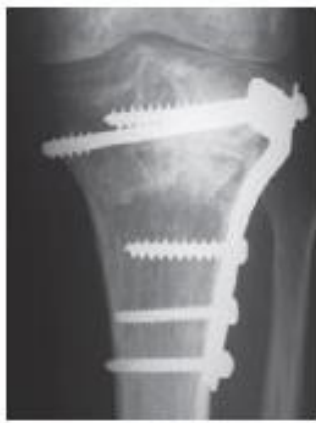

(g)

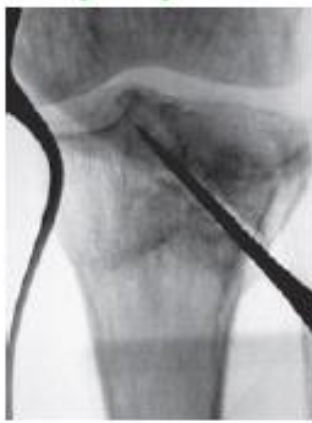

(h)

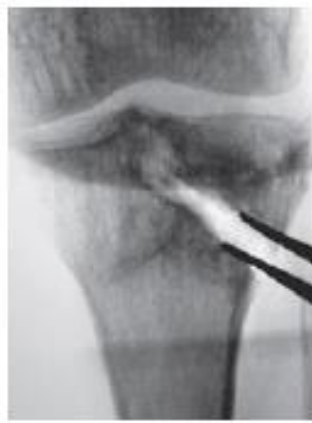



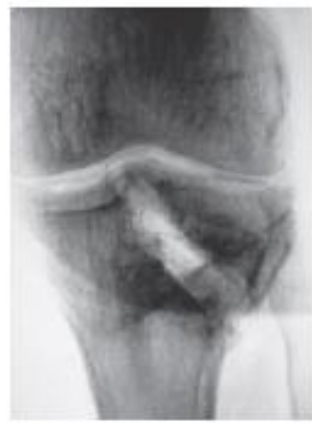(a)



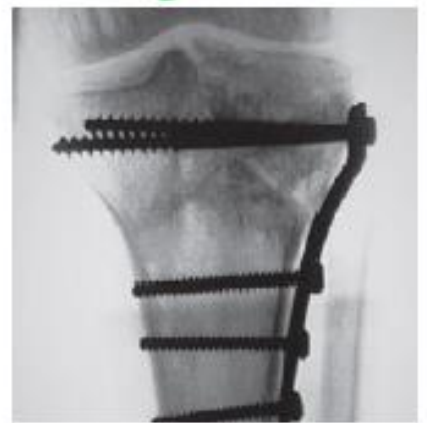(b)



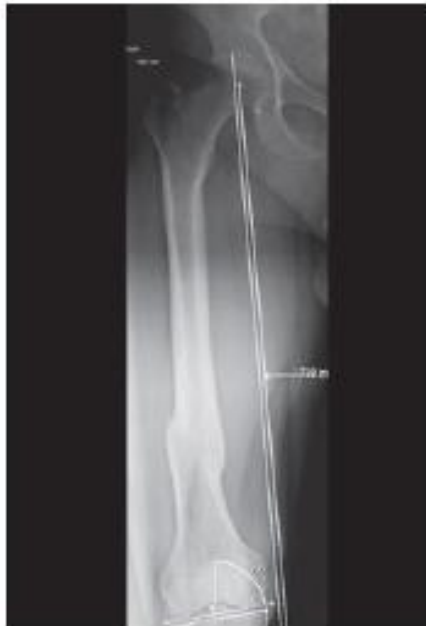(c)



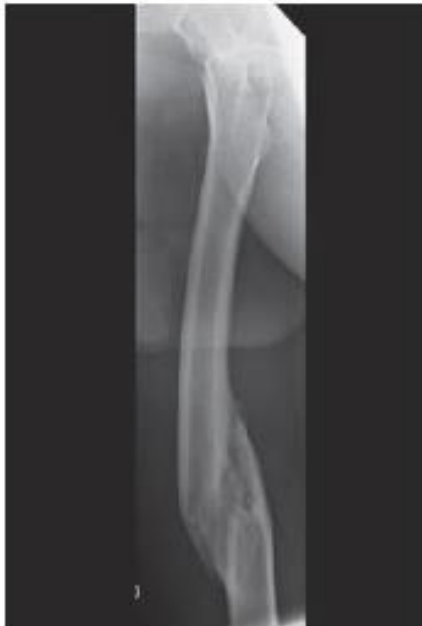(d)



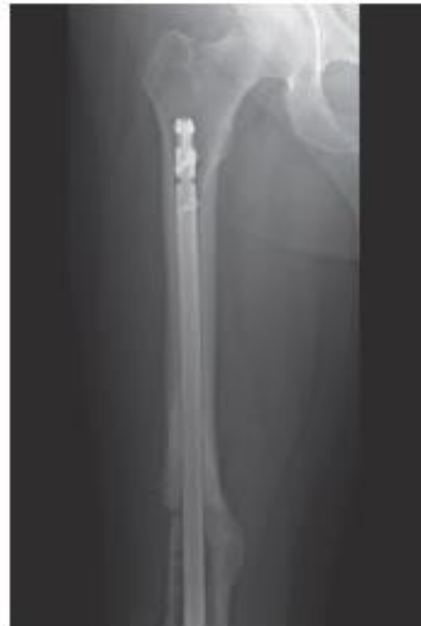(e)



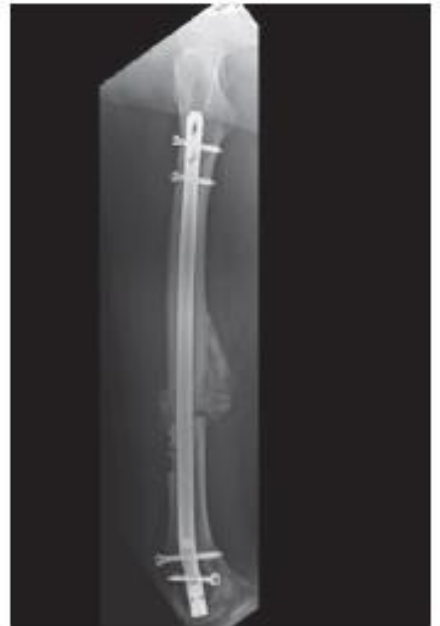(f)



(g)



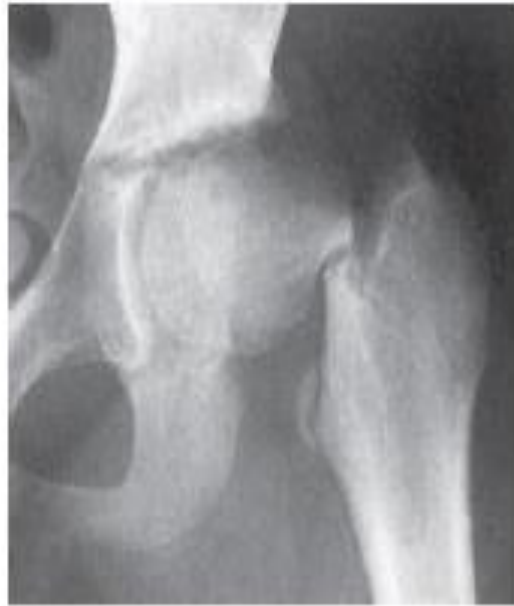(h)



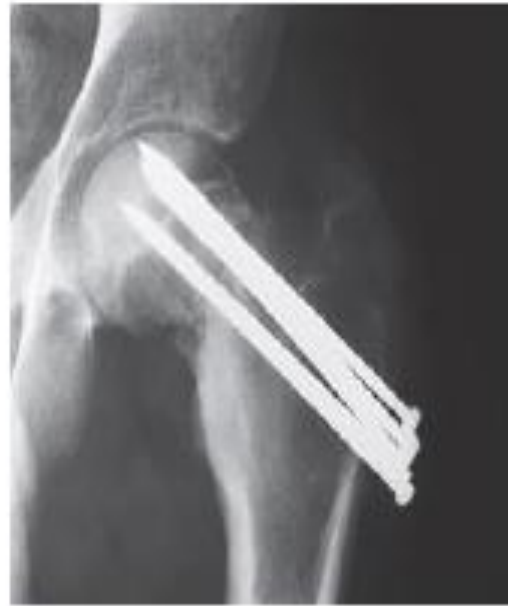(i)

**23.40 Malunion – treatment by internal fixation** An osteotomy, correction of deformity and internal fixation can be used to treat both intra-articular deformities (a–e) and those in the shaft of a long bone (f–i).

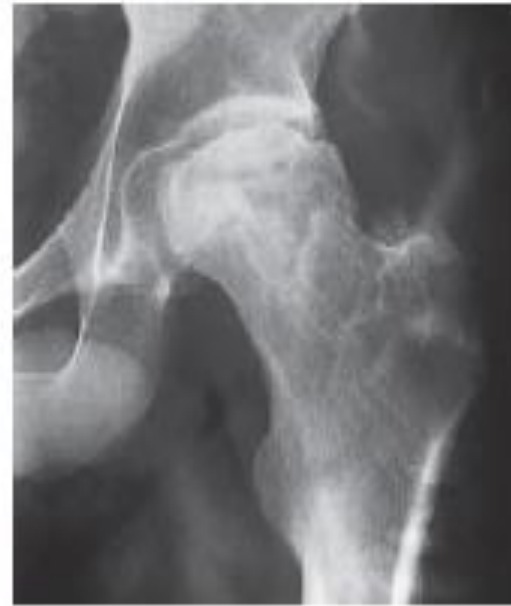



(a)

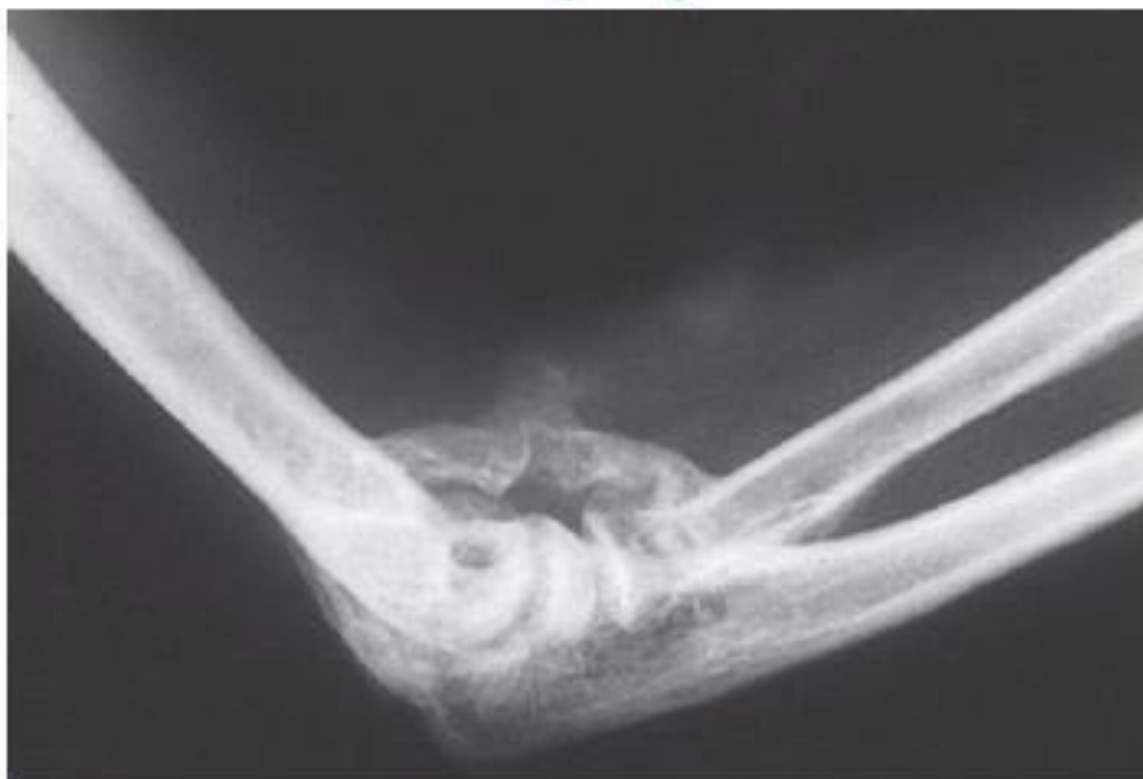

(b)

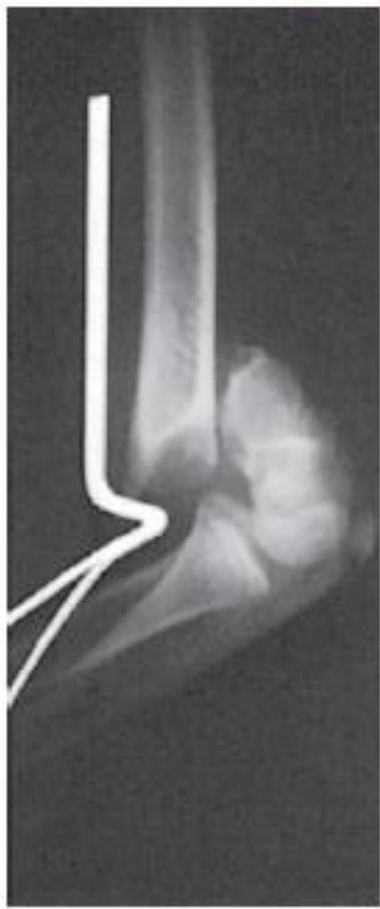

(c)

**23.41 Avascular necrosis** (a) Displaced fractures of the femoral neck are at considerable risk of developing avascular necrosis. Despite internal fixation within a few hours of the injury (b), the head-fragment developed avascular necrosis. (c) X-ray after removal of the fixation screws.



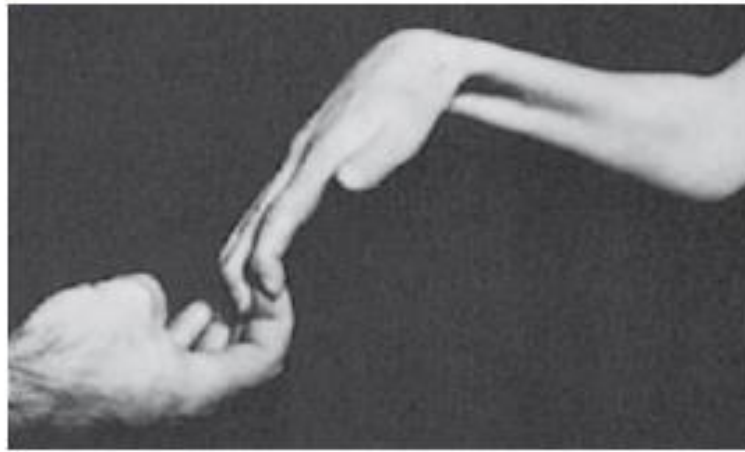**23.43 Myositis ossificans** This followed a fractured head of the radius.



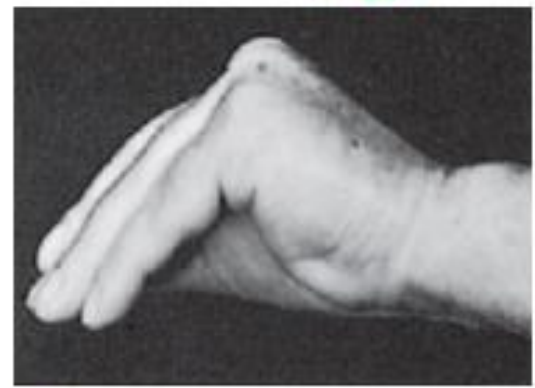(a)



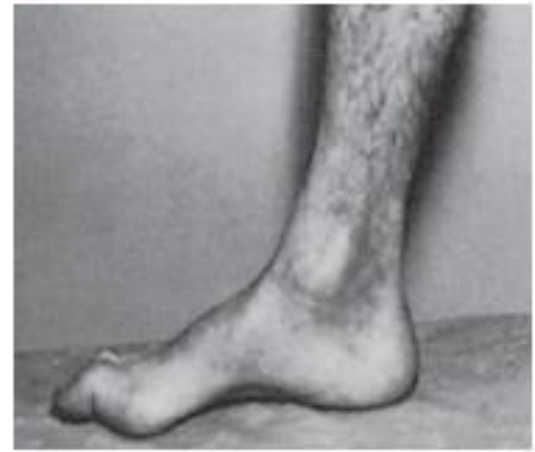(b)



(c)



(d)

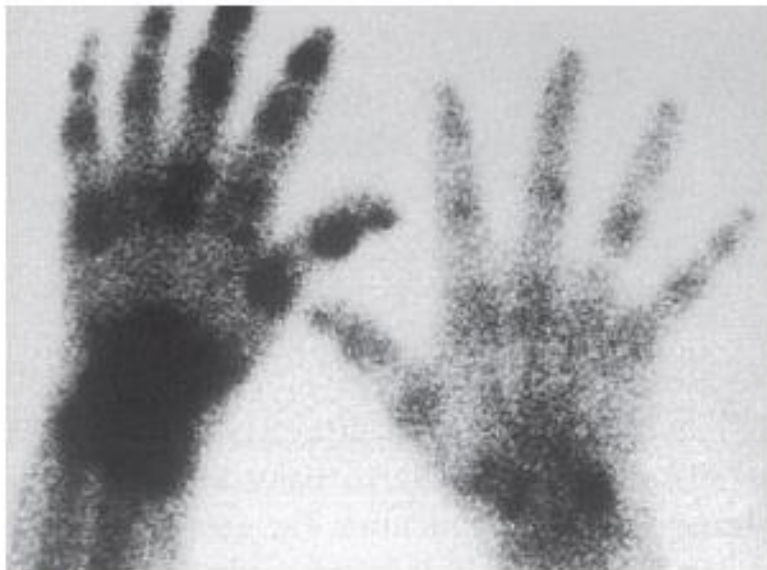
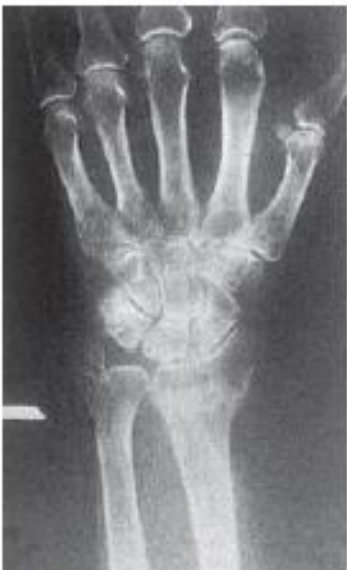
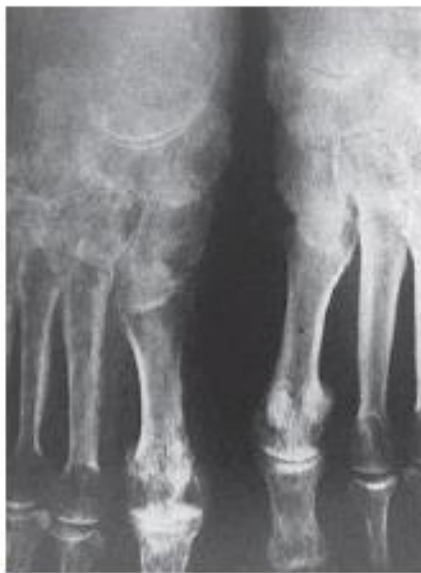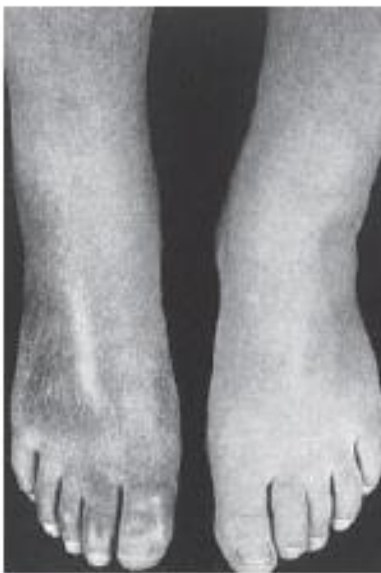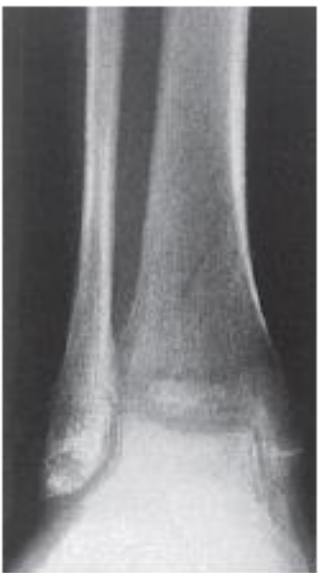(e)

**23.44 Volkmann's ischaemia** (a) Kinking of the main artery is an important cause, but intimal tears may also lead to blockage from thrombosis. A delayed diagnosis of compartment syndrome carries the same sorry fate. (b,c) Volkmann's contracture of the forearm. The fingers can be straightened only when the wrist is flexed (the constant length phenomenon). (d) Ischaemic contracture of the small muscles of the hand. (e) Ischaemic contracture of the calf muscles with clawing of the toes.

### 23.45 Complex regional pain syndrome

(a) Regional osteoporosis is common after fractures of the extremities. The radiolucent bands seen here are typical. (b) In algodystrophy the picture is exaggerated and the soft tissues are also involved: here the right foot is somewhat swollen and the skin has become dusky, smooth and shiny. (c) In the full-blown case, x-rays show a typical patchy osteoporosis. (d) Similar changes may occur in the wrist and hand; they are always accompanied by (e) increased activity in the radionuclide scan.



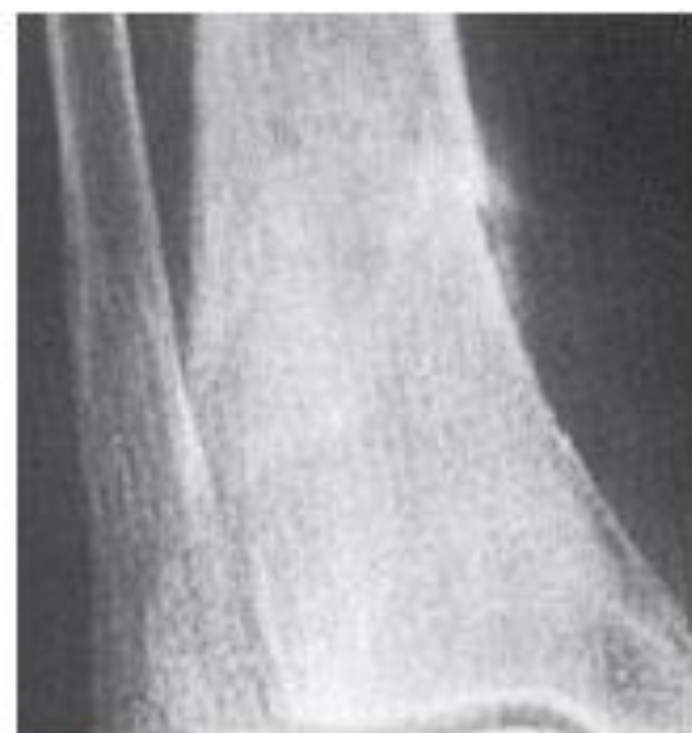(a)

(b)

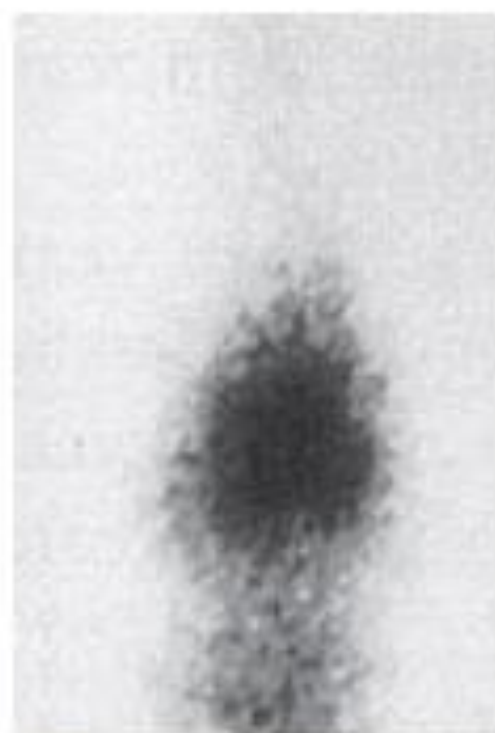
(c)

(d)

(e)



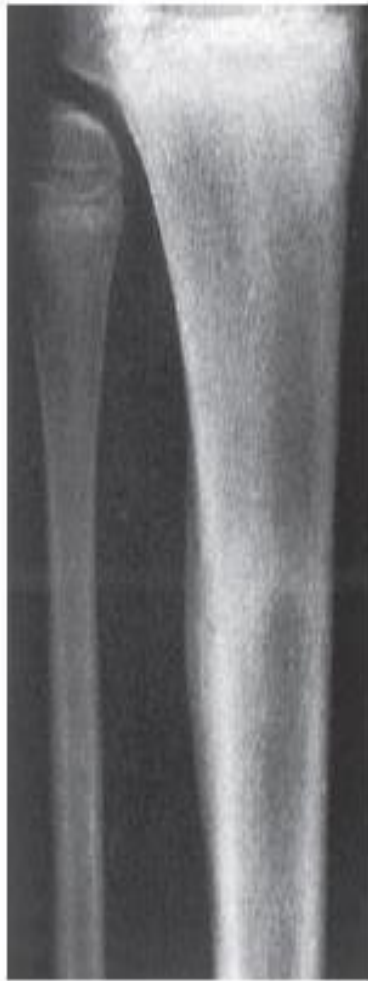
(a)



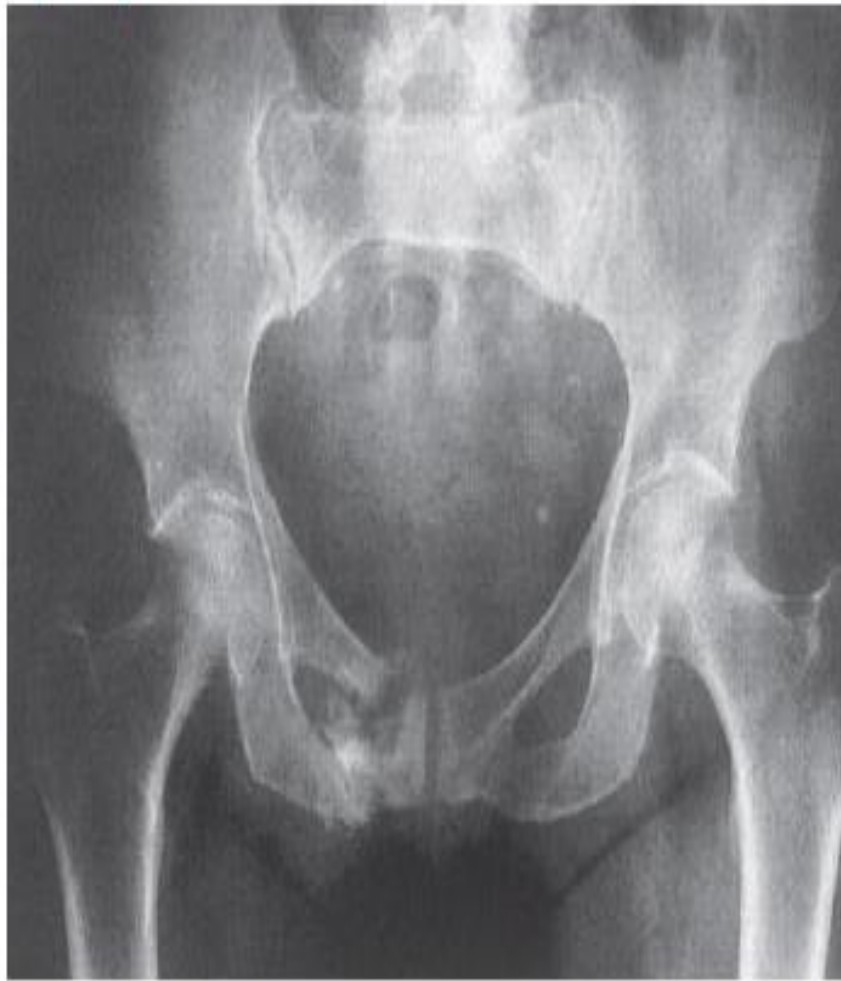(b)

**23.46 Stress fracture** (a) The stress fracture in this tibia is only just visible on x-ray, but it had already been suspected 2 weeks earlier when the patient first complained of pain and a radioisotope scan revealed a 'hot' area just above the ankle (b).



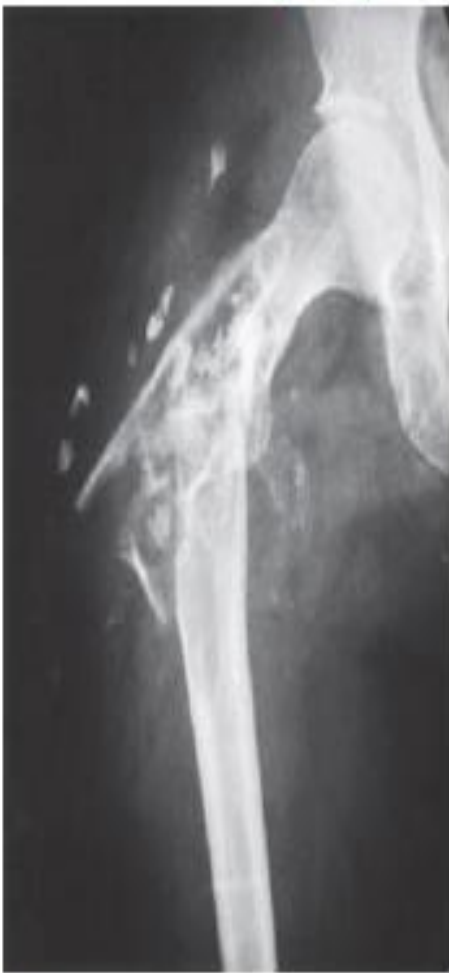

(a)

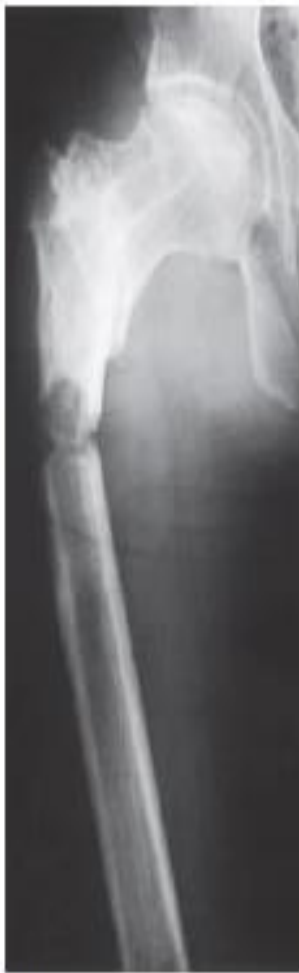

(b)

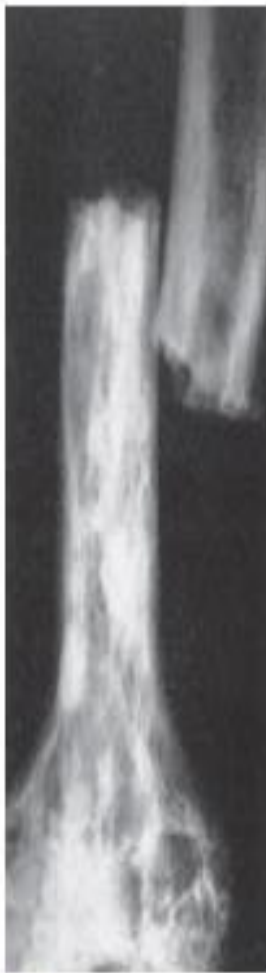**23.47 Stress fractures** Stress fractures are often missed or wrongly diagnosed. (a) This tibial fracture was at first thought to be an osteosarcoma. (b) Stress fractures of the pubic rami in elderly women can be mistaken for metastases.



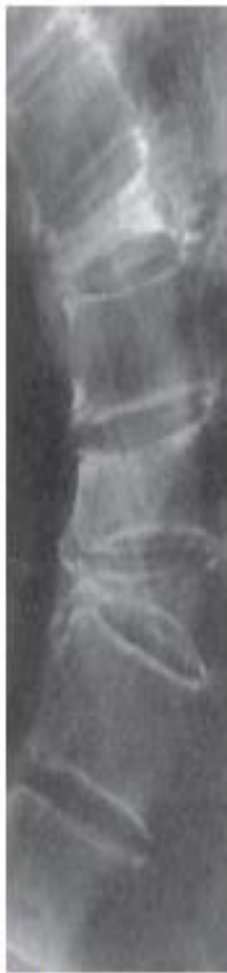(a)



(b)



(c)



(d)

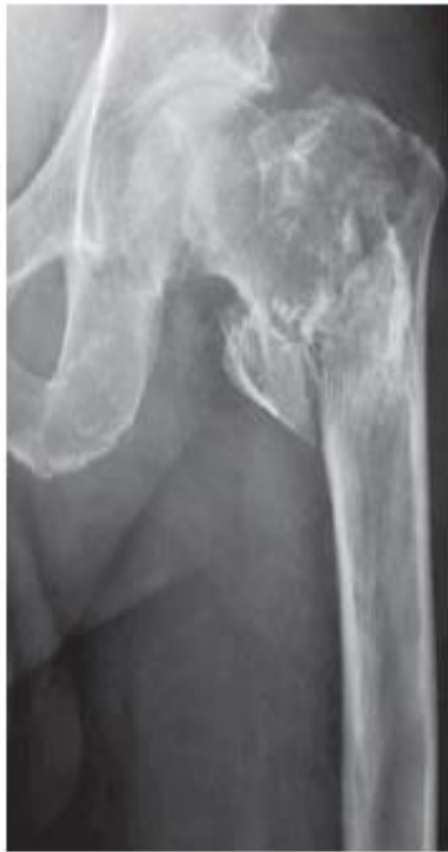

(e)

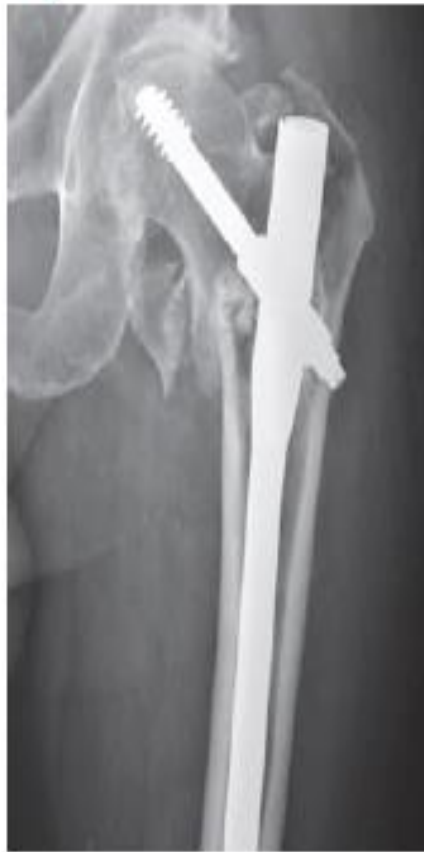

(f)

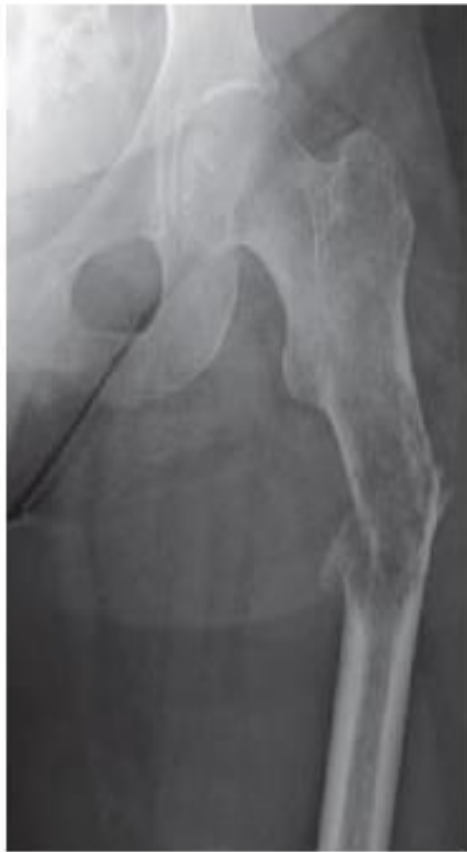**23.48 Pathological fractures** Six examples of pathological fractures, due to: (a) primary chondrosarcoma; (b) postoperative bone infection at a screw-hole following plating of an intertrochanteric fracture; (c) Paget's disease; (d) vertebral metastases; (e) metastasis from carcinoma of the breast and (f) myelomatosis.



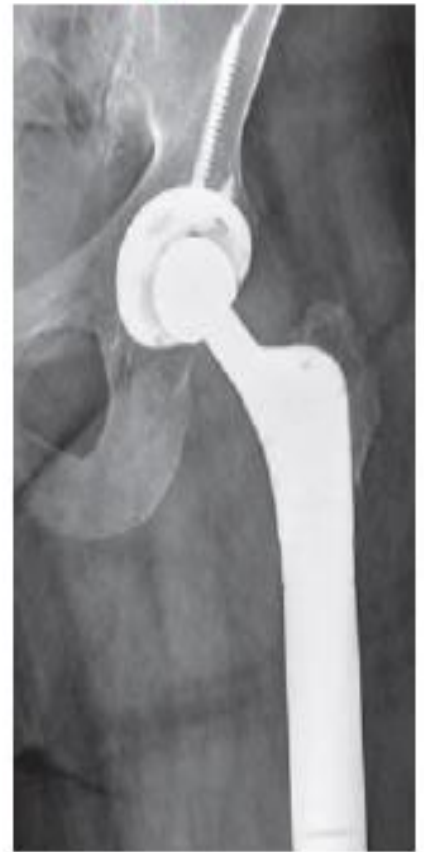(a)



(b)

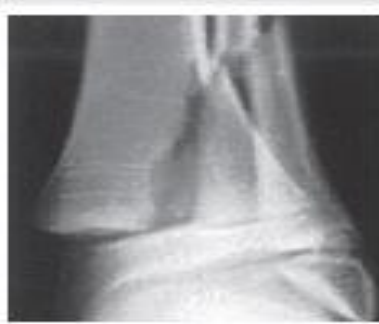


(c)

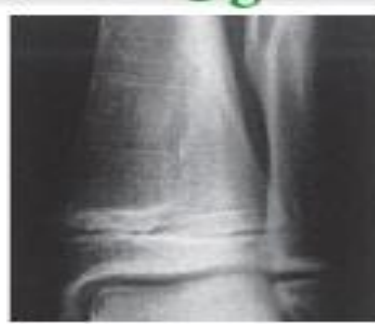

(d)

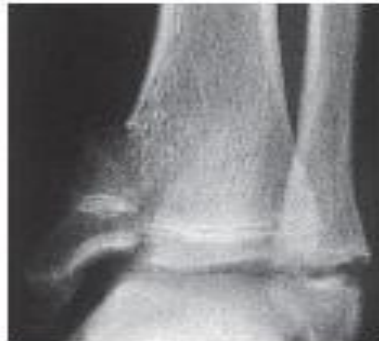**23.49 Pathological fractures – treatment** (a,b) Paget's disease of the femur increases the brittleness of bone, making it more likely to fracture. Intramedullary fixation allows the entire femur to be supported. (c,d) A fracture through a solitary metastasis from a previously excised renal cell carcinoma can be resected in order to achieve cure. In this case replacement of the proximal femur with an endoprosthesis is needed.



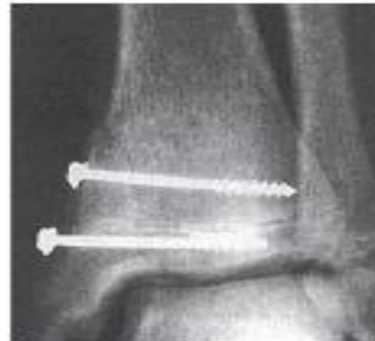(a)



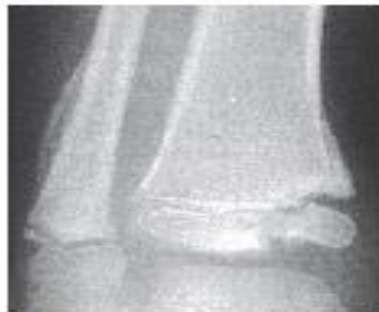(b)



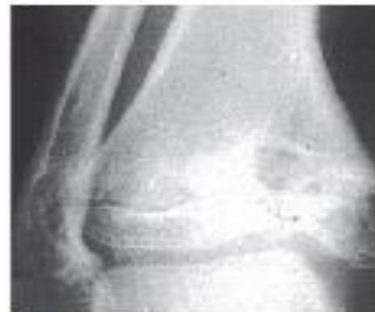(c)



(d)

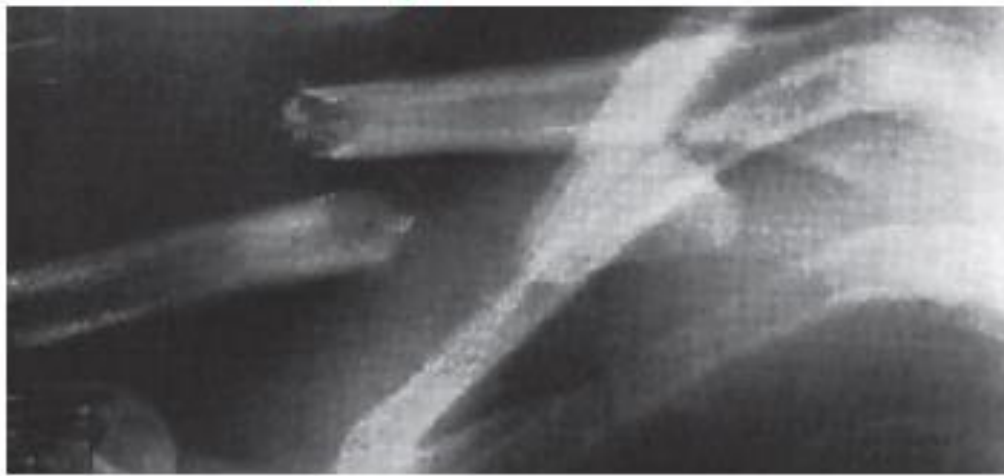

(e)



(f)

**23.52 Physeal Injuries** (a) Type 2 injury. The fracture does not traverse the width of the physis; after reduction (b) bone growth is not distorted. (c,d) This type 4 fracture of the tibial physis was treated immediately by open reduction and internal fixation and a good result was obtained. (e,f) In this case accurate reduction was not achieved and the physeal fragment remained displaced; the end result was partial fusion of the physis and severe deformity of the ankle.



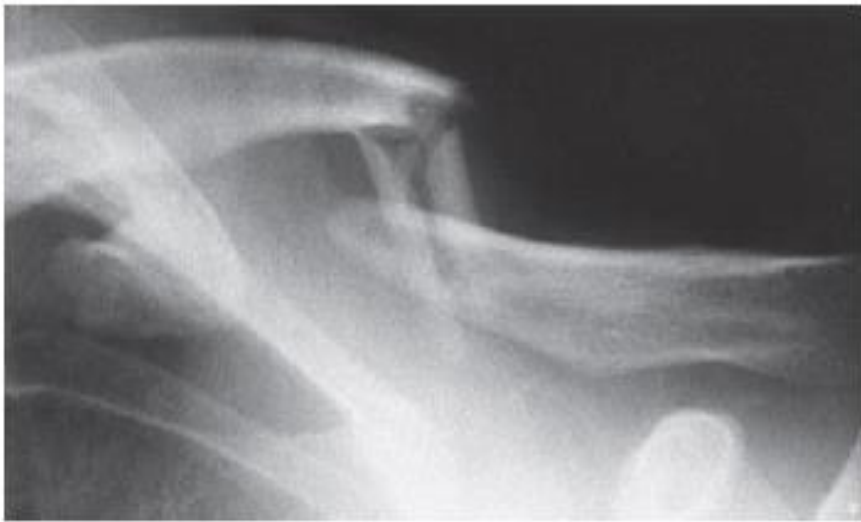(a)



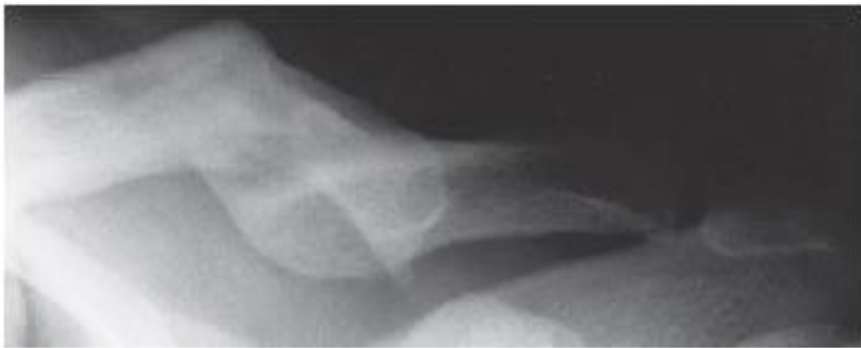
(b)

**24.1 Fracture of the clavicle** (a) Displaced fracture of the middle third of the clavicle – the most common injury. (b) The fracture usually unites in this position, leaving a barely noticable 'bump'.



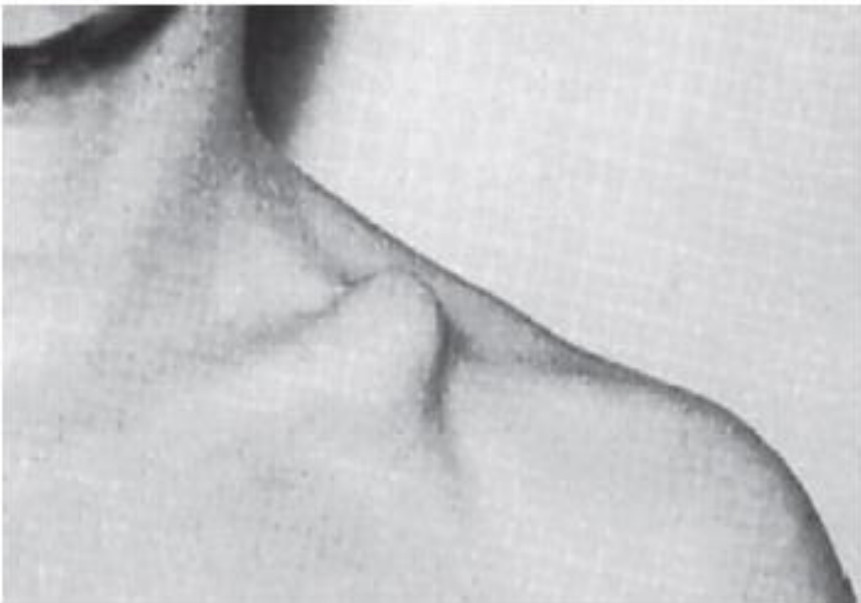


(a)

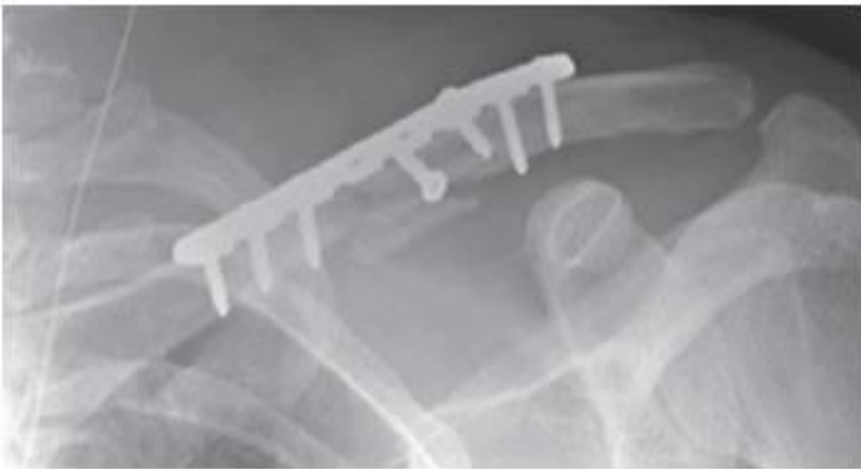


(b)

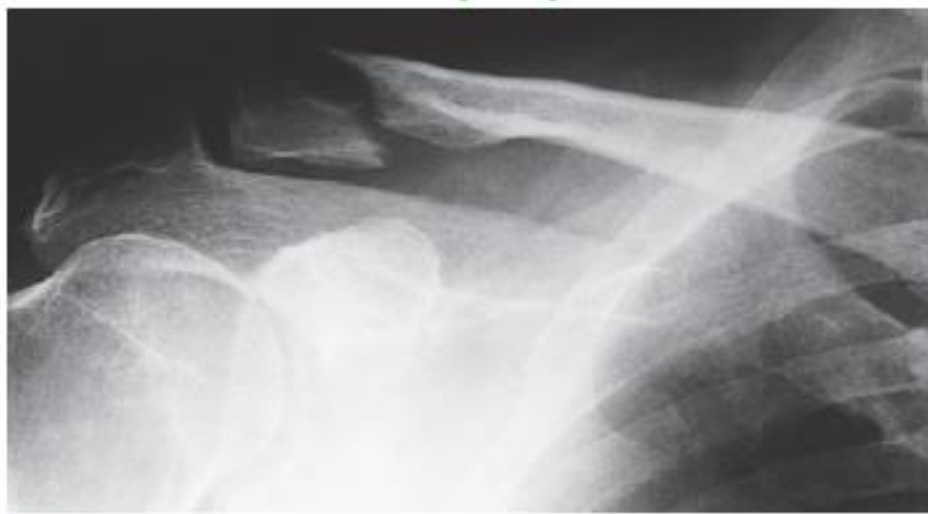**24.2 Severely displaced fracture** (a) A comminuted fracture which united in this position (b) leaving an unsightly deformity (c). This fracture would have been better managed by (d) open reduction and internal fixation.



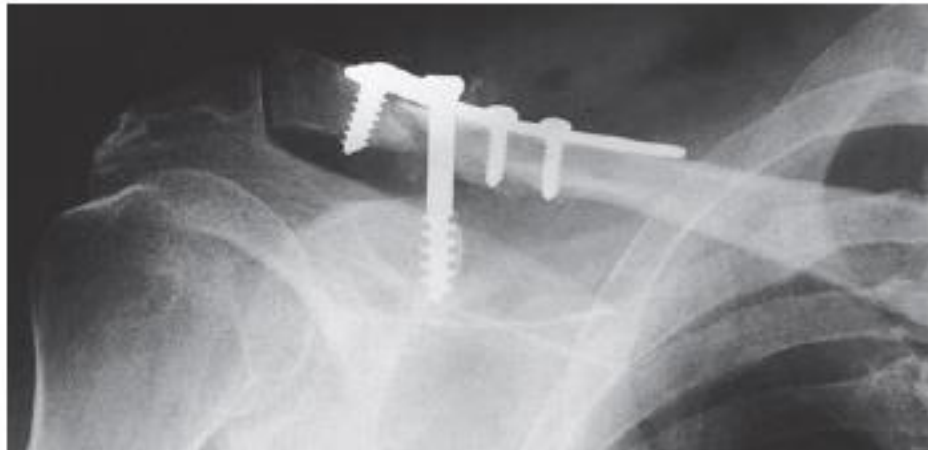
(c)



(d)

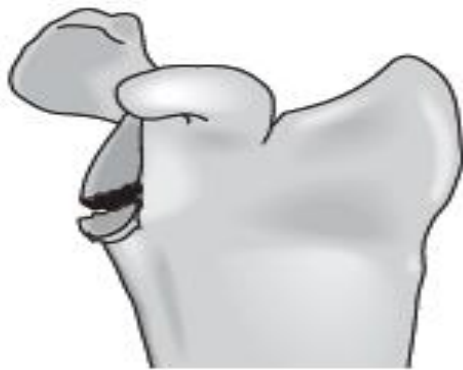

(a)

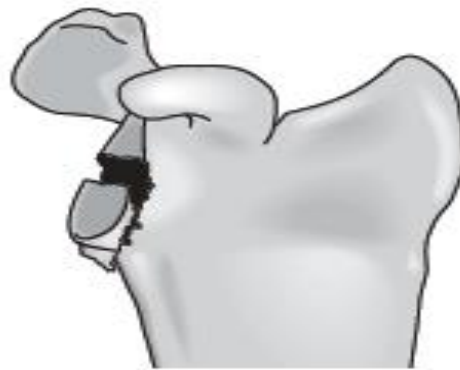


(b)

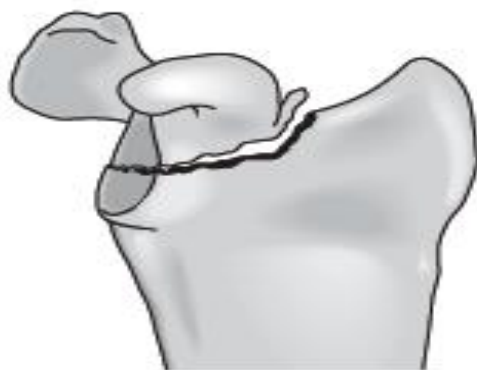**24.3 Fracture of the outer (lateral) third** (a) The shaft of the clavicle is elevated, suggesting that the medial part of the coracoclavicular ligament is ruptured. (b) This was treated by open reduction and internal fixation, using a long screw to fix the clavicle to the coracoid process temporarily while the soft tissues healed.



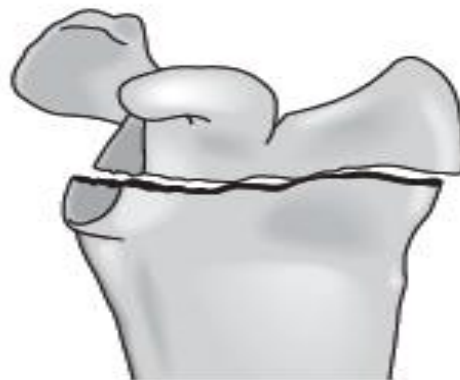Type I



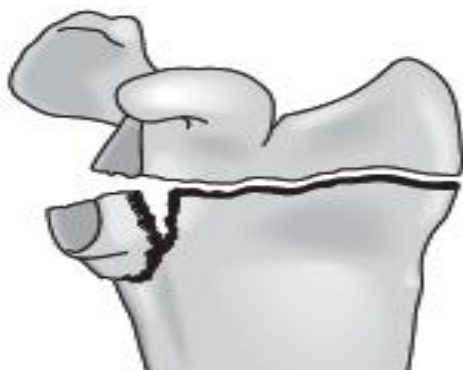Type II



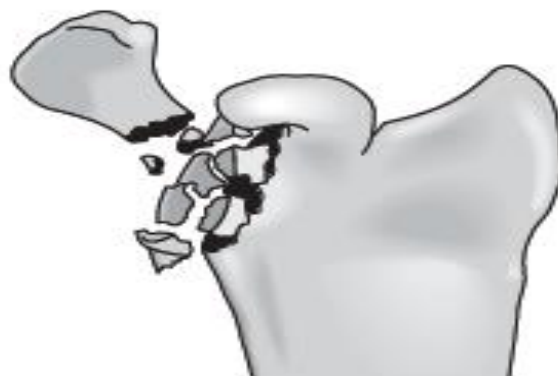Type III



Type IV



Type V

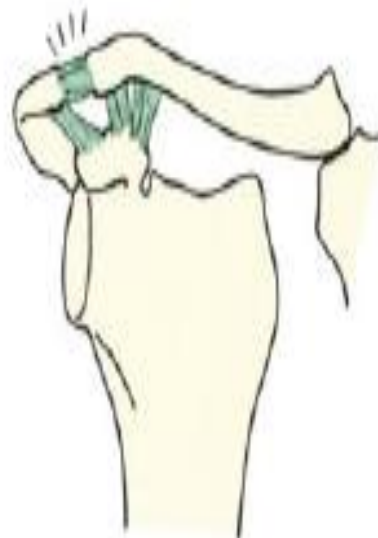

Type VI

**24.4 Fractures of the glenoid – classification** Diagrams showing the main types of glenoid fracture.



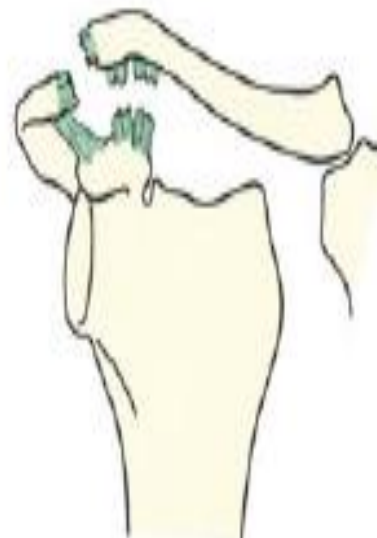(a)



(b)

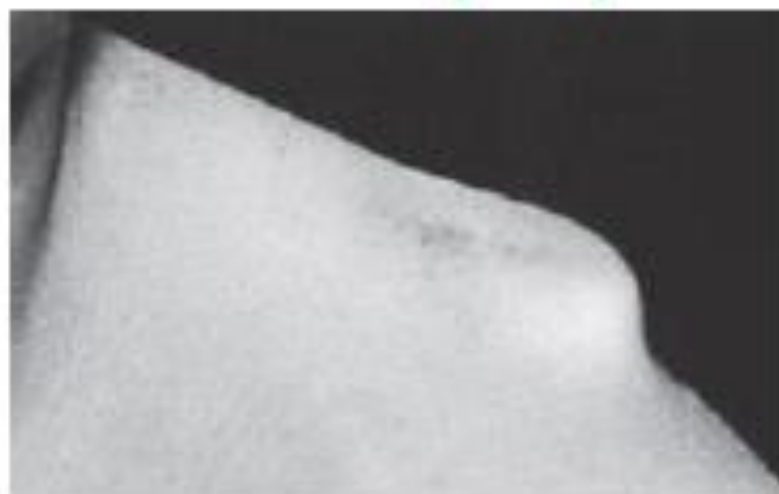

(c)

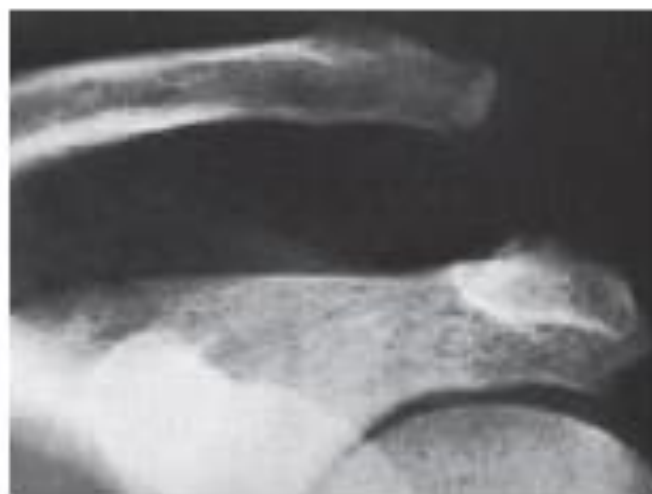


(d)

**24.6 Acromioclavicular joint injuries** (a) Normal joint. (b) Sprained acromioclavicular joint; no displacement. (c) Torn capsule and subluxation but coracoclavicular ligaments intact. (d) Dislocation with torn coracoclavicular ligaments.



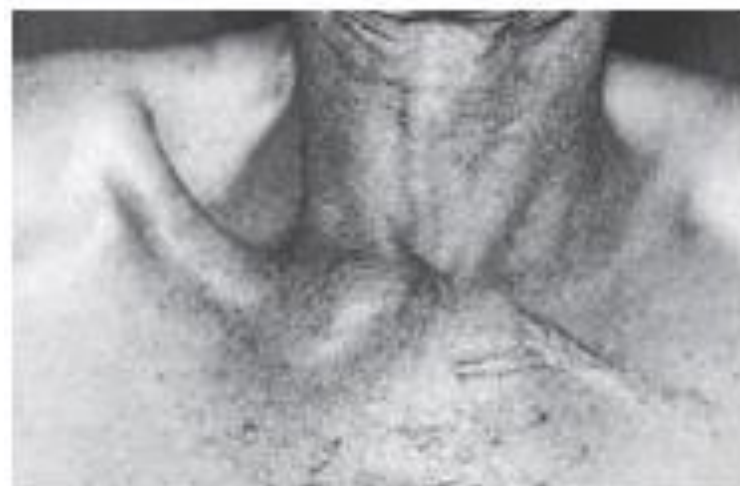(a)



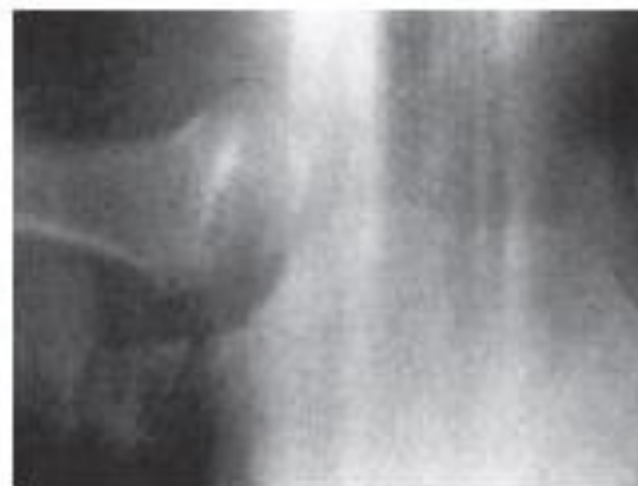(b)

**24.7 Acromioclavicular dislocation** (a) Clinically one sees a definite 'step' in the contour at the lateral end of the clavicle. (b) The x-ray shows complete separation of the acromioclavicular joint.



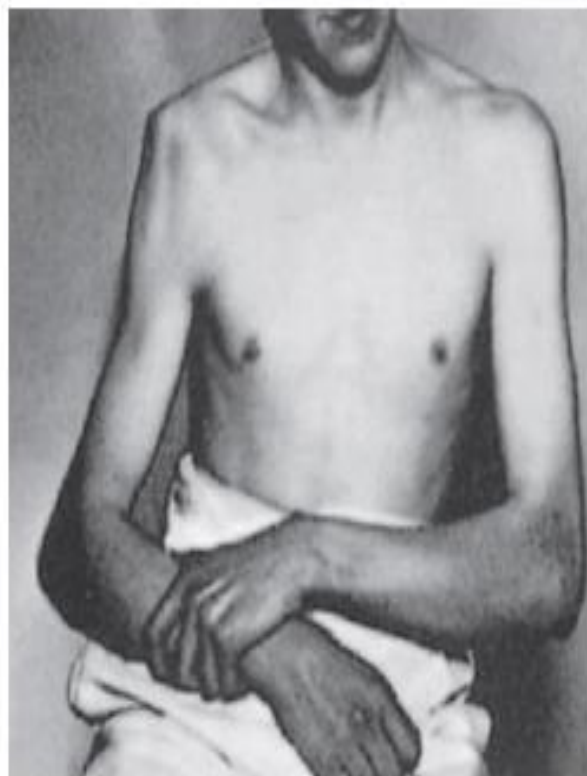

(a)

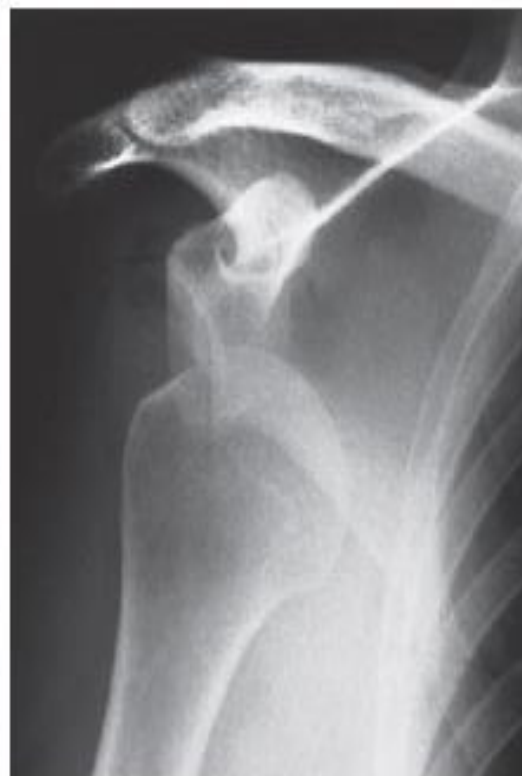

(b)

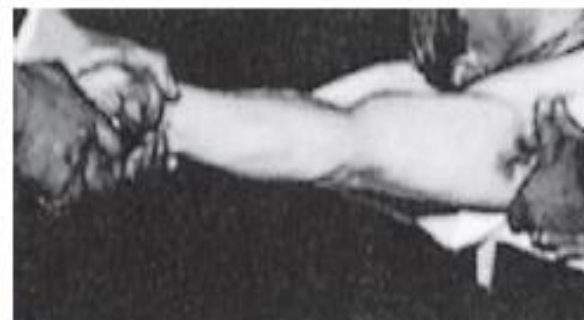**24.9 Sternoclavicular dislocation** (a) The bump over the sternoclavicular joint may be obvious, though this is difficult to demonstrate on plain x-ray. (b) Tomography (or, better still, CT) will show the lesion.



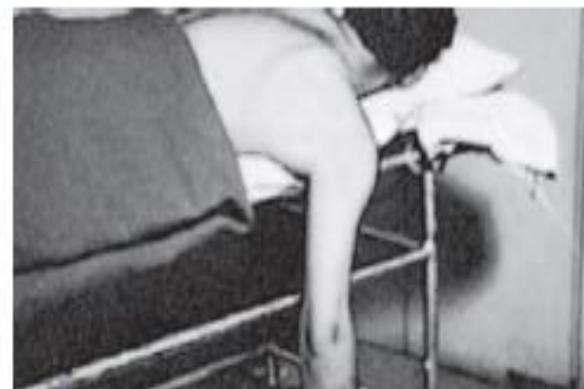(a)



(b)

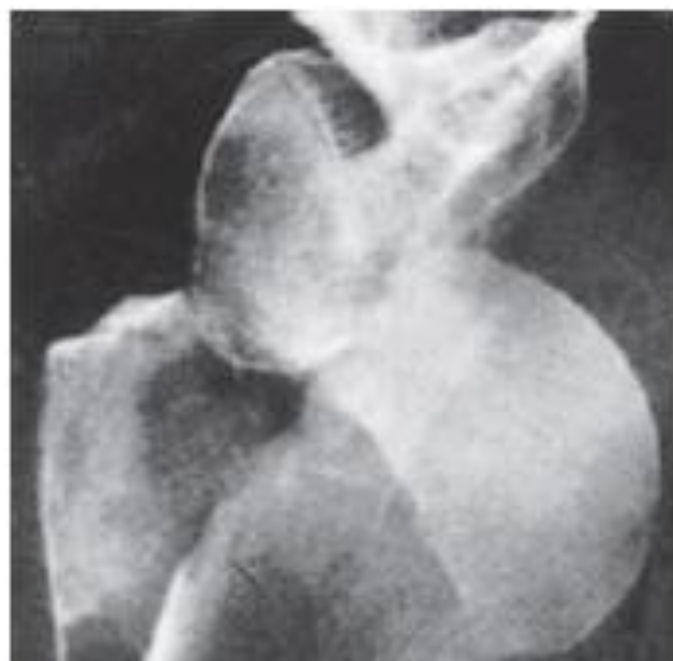

(c)

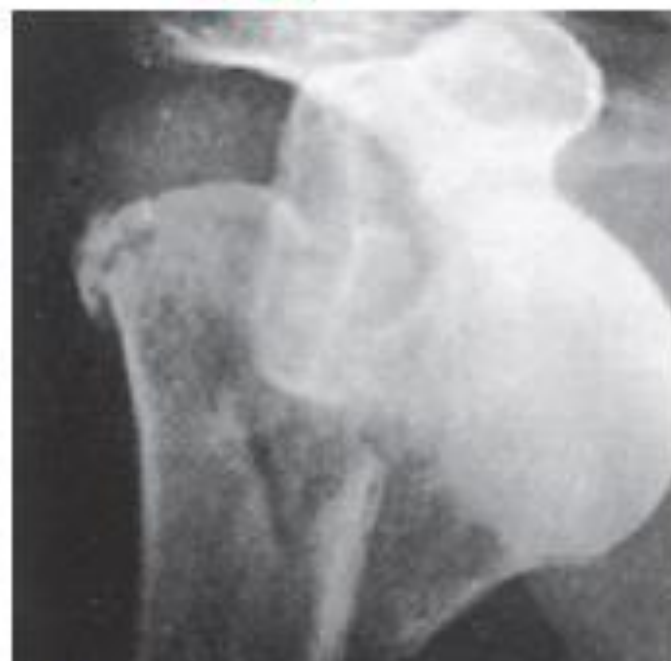

(d)

**24.10 Anterior dislocation of the shoulder** (a) The prominent acromion process and flattening of the contour over the deltoid are typical signs. (b) X-ray confirms the diagnosis of anterior dislocation. (c,d) Two methods of reduction.

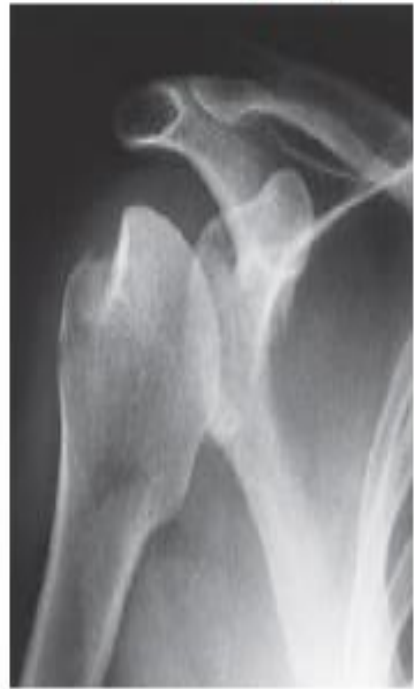

(a)

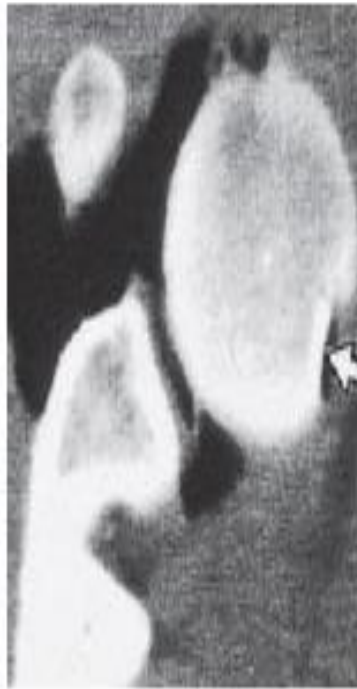

(b)

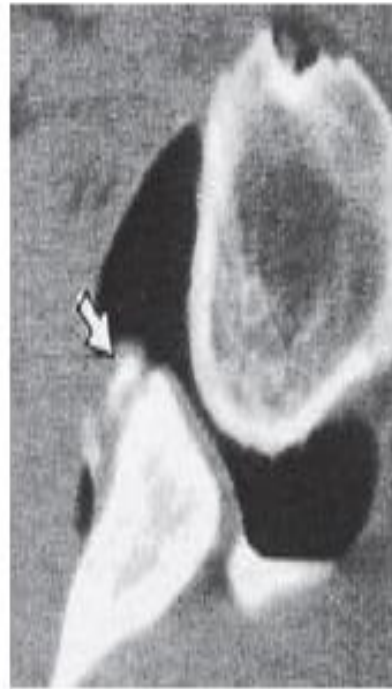**24.11 Anterior fracture-dislocation** Anterior dislocation of the shoulder may be complicated by fracture of (a) the greater tuberosity or (b) the neck of the humerus – this often needs open reduction and internal fixation.



(a)



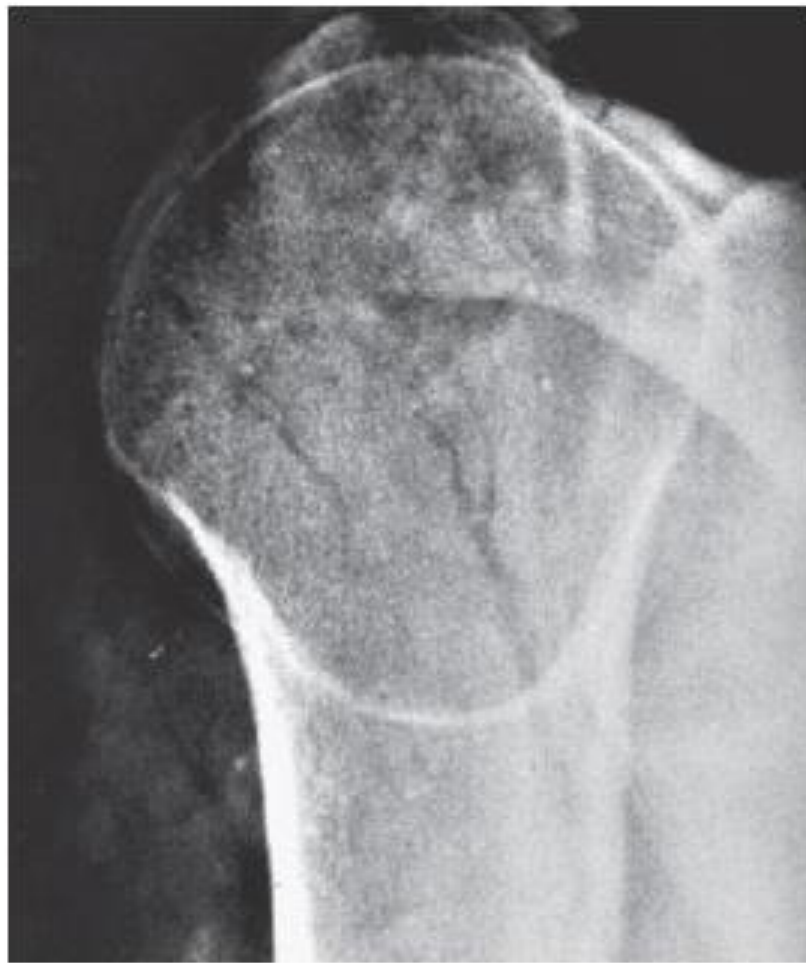(b)



(c)

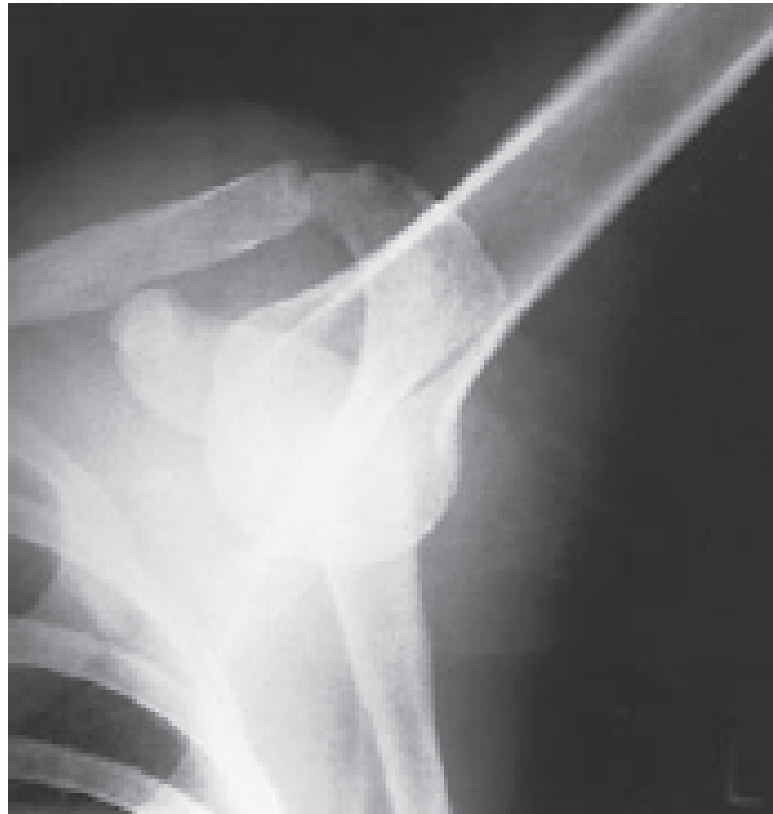## 24.12 Recurrent dislocation of the shoulder

(a) The classic x-ray sign is a depression in the posterosuperior part of the humeral head (the Hill-Sachs lesion). (b,c) MRI scans showing both the Hill-Sachs lesion and a Bankart lesion of the glenoid rim (arrows).

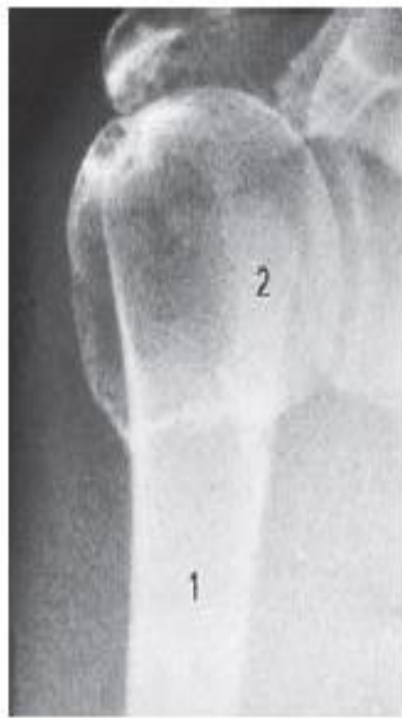

**24.13 Posterior dislocation of the shoulder** The characteristic x-ray image. Because the head of the humerus is internally rotated, the anteroposterior x-ray shows a head-on projection giving the classic 'electric light-bulb' appearance.

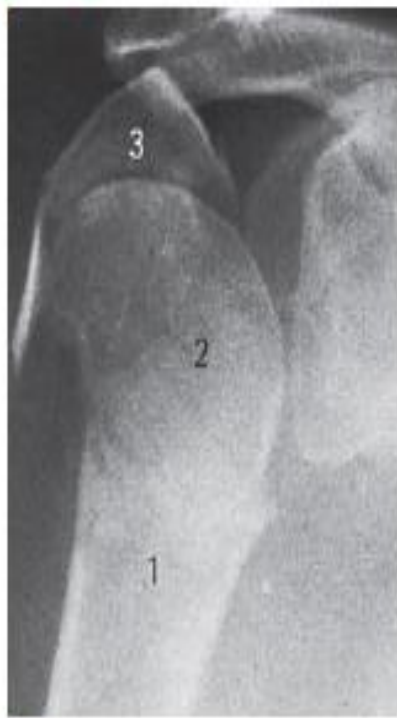



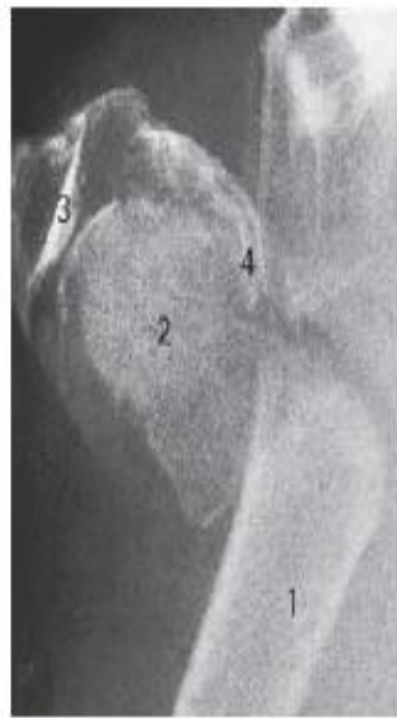**24.14 Inferior dislocation of the shoulder** You can see why the condition is called *luxatio erecta*. The shaft of the humerus points upwards and the humeral head is displaced downwards.



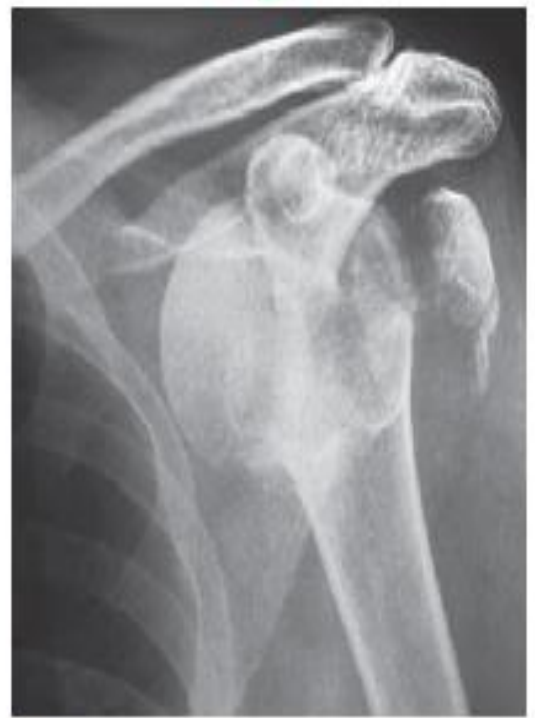(a)



(b)

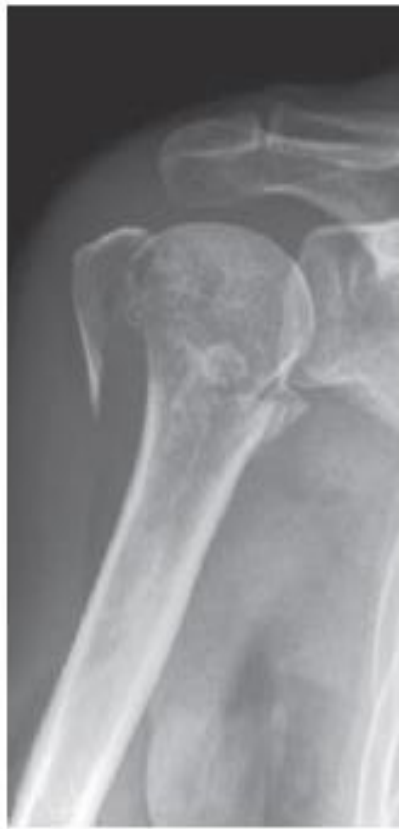

(c)

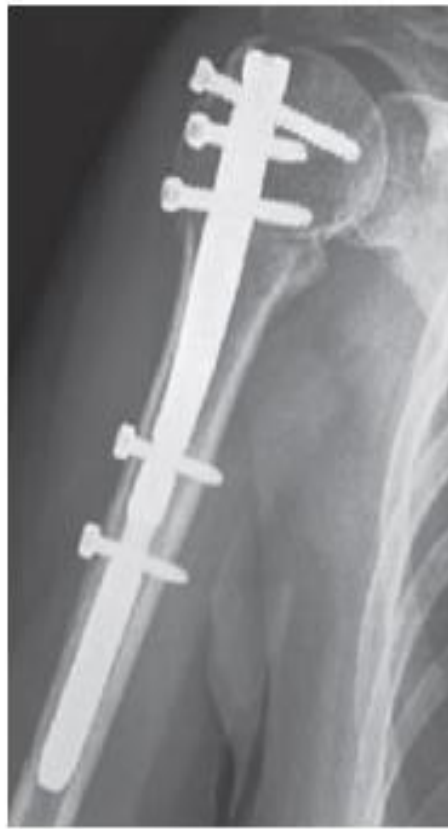

(d)

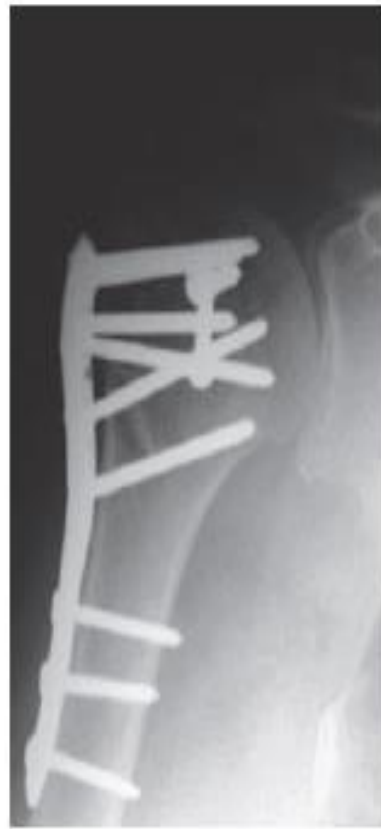**24.16 X-rays of proximal humeral fractures** Classification is all very well, but x-rays are more difficult to interpret than line drawings. (a) Two-part fracture. (b) Three-part fracture involving the neck and the greater tuberosity. (c) Four-part fracture. (1=shaft of humerus; 2=head of humerus; 3=greater tuberosity; 4=lesser tuberosity). (d) X-ray showing fracture-dislocation of the shoulder.



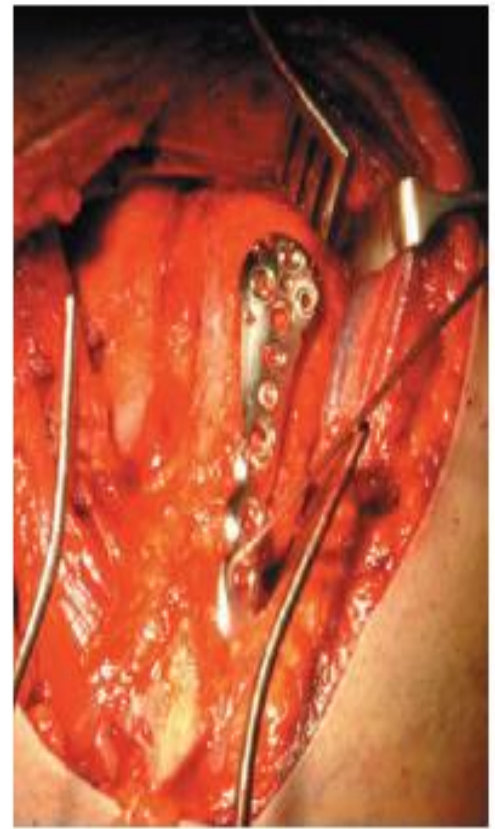
(a)



(b)

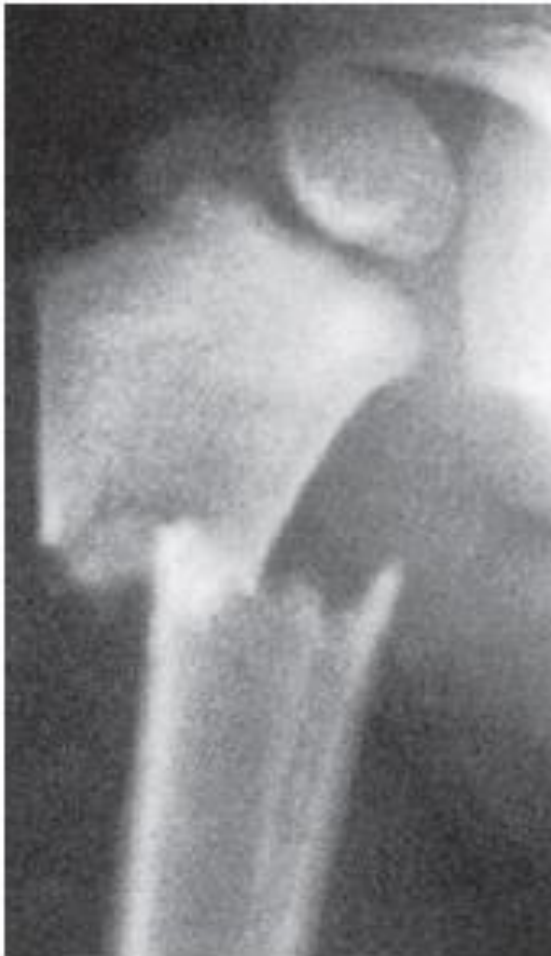

(c)

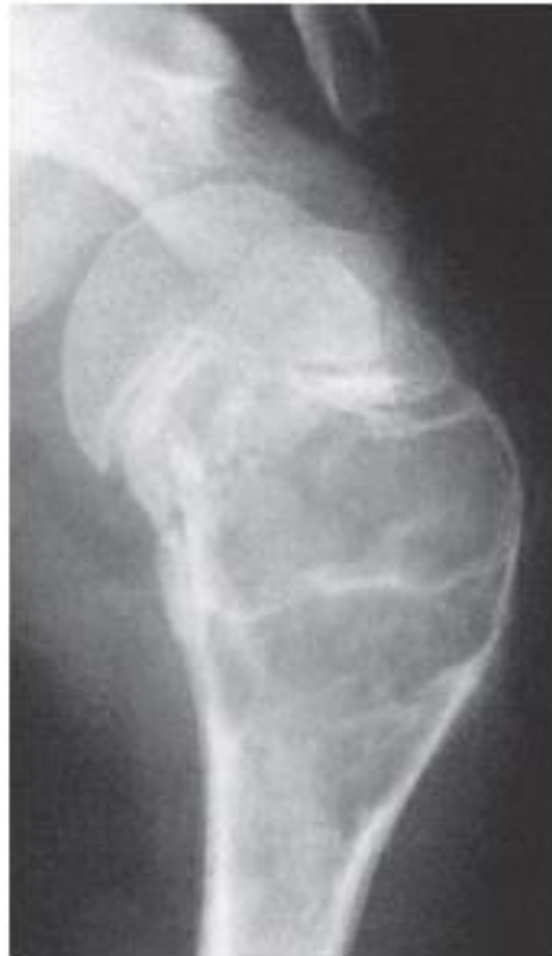

(d)

**24.18 Proximal humerus fractures – treatment** (a) Three-part fracture, treated by (b) locked nail fixation. (c) Four-part fracture fixed with a locked plate; the intra-operative picture (d) shows how the plate was positioned.



(a)

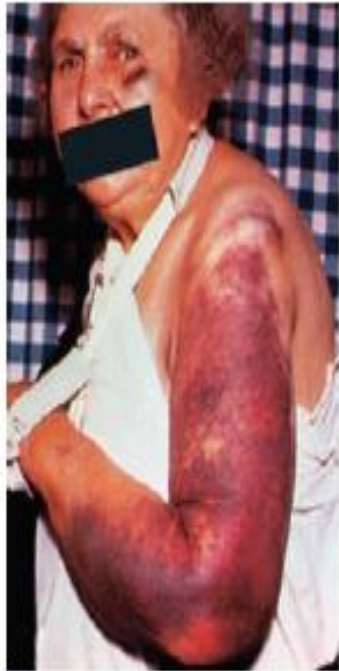

(b)

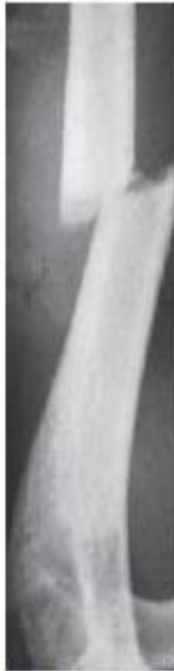**24.19 Fractures of the proximal humerus in children**

(a) The typical metaphyseal fracture. Reduction need not be perfect as remodelling will compensate for malunion.

(b) Fracture through a benign cyst.



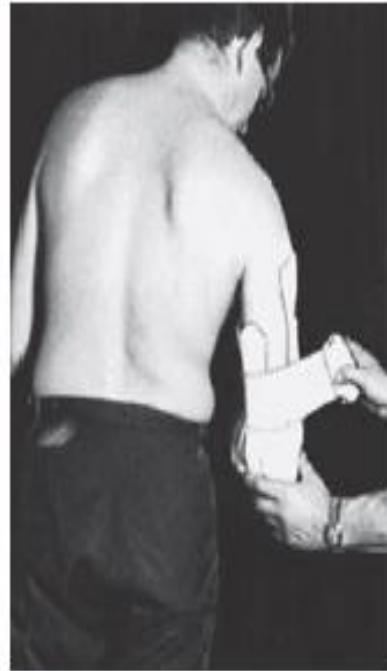(a)



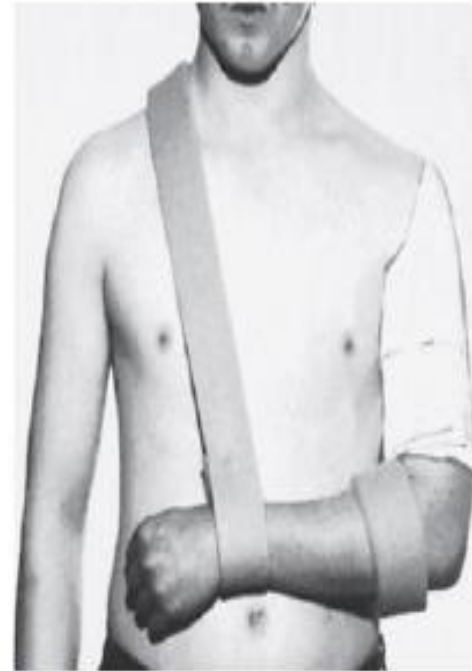(b)



(c)



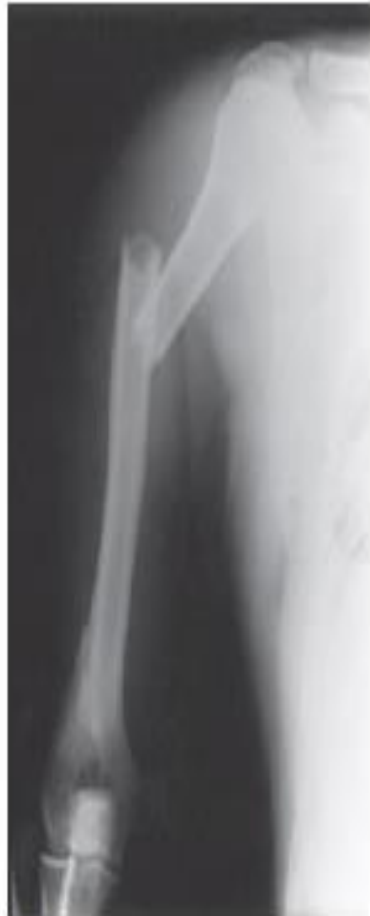(d)



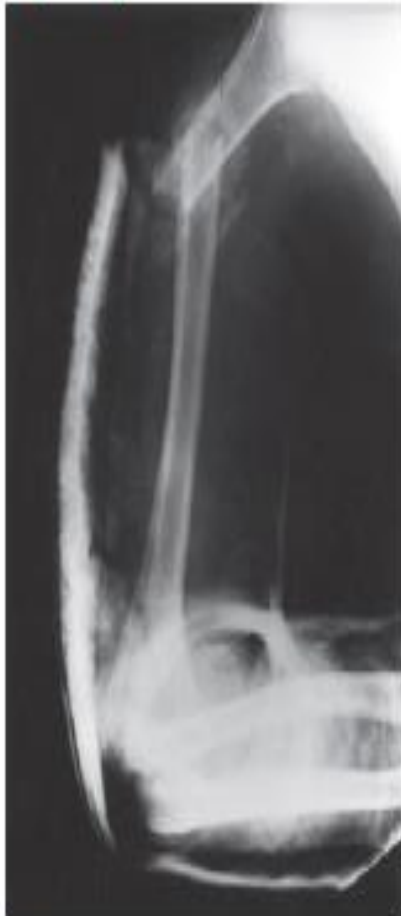(e)

**24.20 Fractured shaft of humerus** (a) Bruising is always extensive. (b,c) Closed transverse fracture with moderate displacement. (d) Applying a U-slab of plaster (after a few days in a shoulder-to-wrist hanging cast) is usually adequate. (e) Ready-made braces are simpler and more comfortable, though not suitable for all cases. These conservative methods demand careful supervision if excessive angulation and malunion are to be prevented.

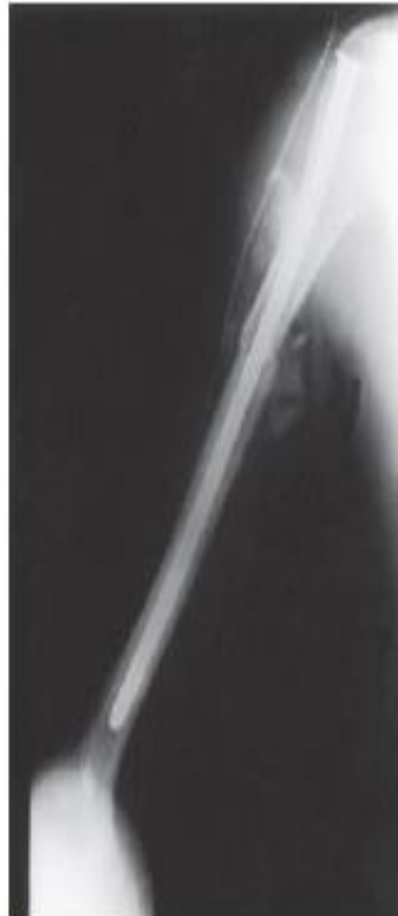



(a)

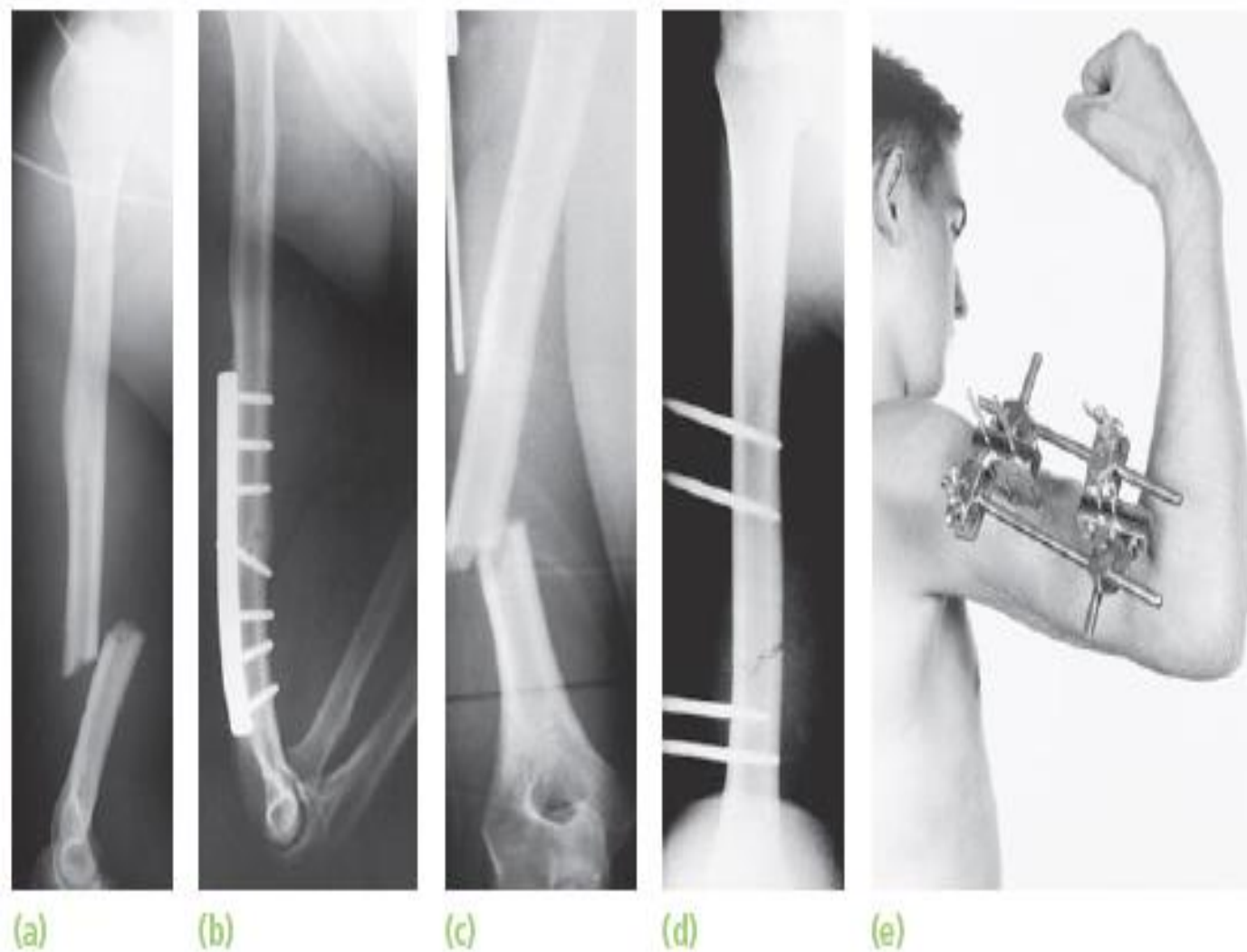


(b)

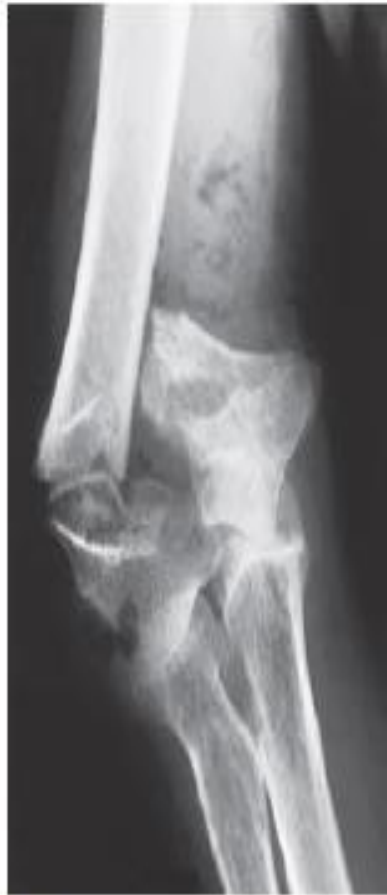

(c)

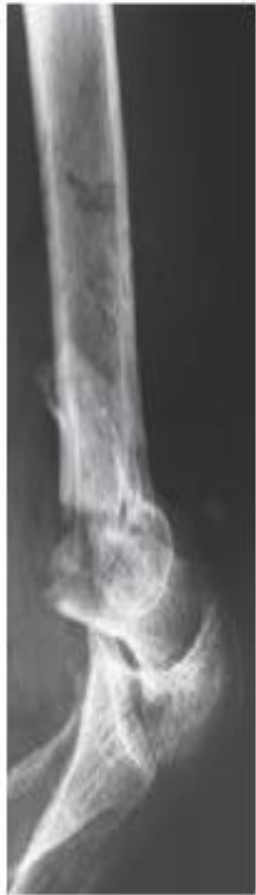**24.21 Fractured shaft of humerus – treatment (a,b)** Most shaft fractures can be treated in a hanging cast or functional brace, but beware the upper third fracture which tends to angulate at the proximal border of a short cast. This fracture would have been better managed by **(c)** intramedullary nailing (and better still with a locking nail).



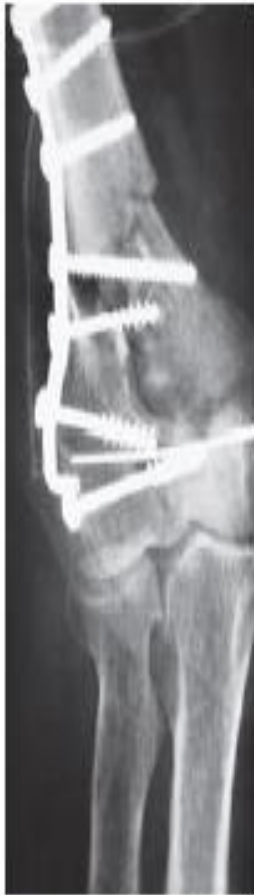24.22 Fractured humerus –  
other methods of fixation  
(a,b) Compression plating,  
and (c,d,e) external fixation.



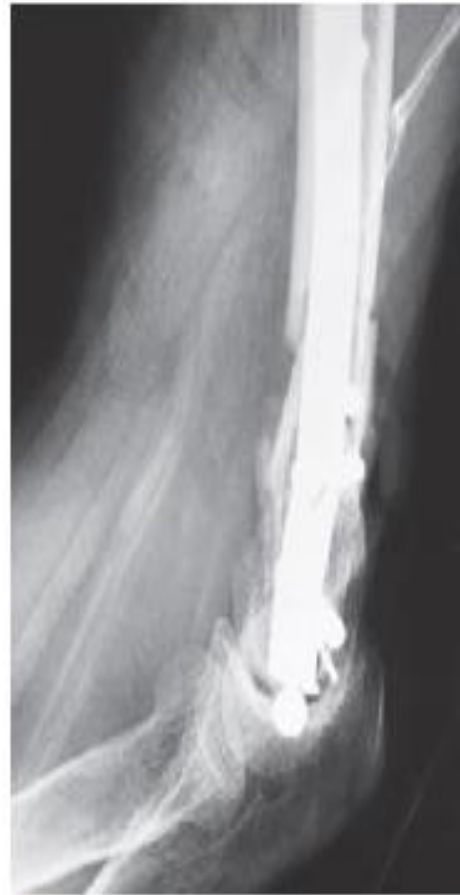
(a)



(b)

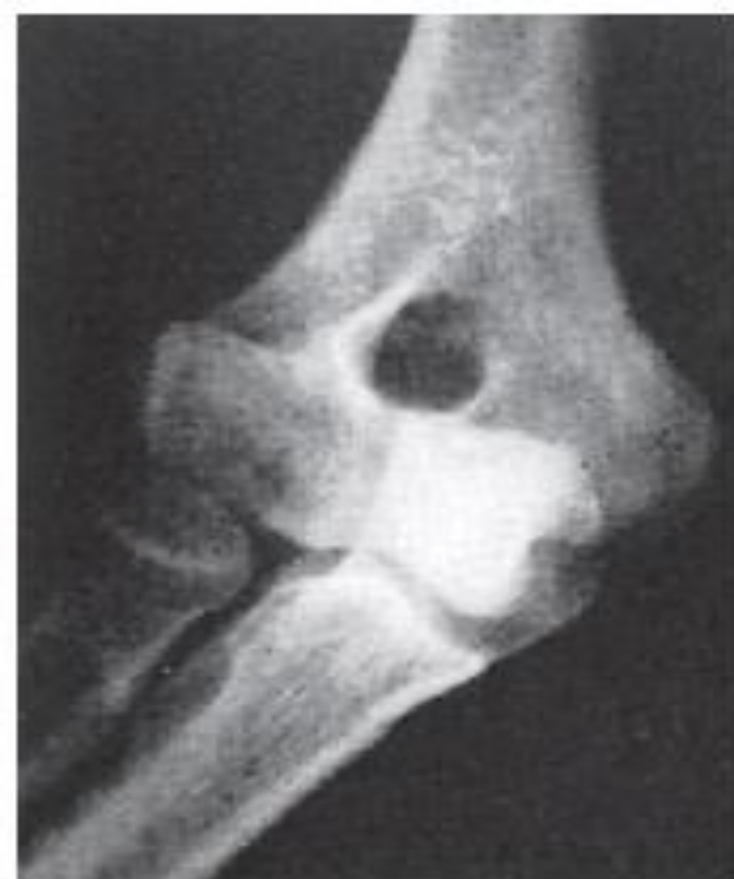

(c)

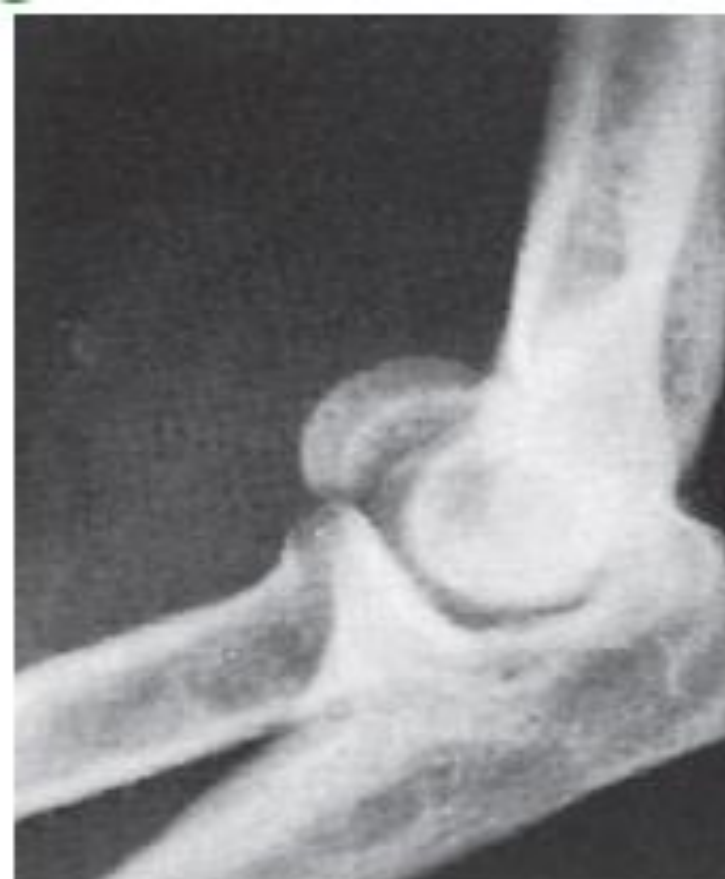

(d)

**24.23 Bicondylar fractures** X-rays taken (a,b) before and (c,d) after open reduction and internal fixation. An excellent reduction was obtained in this case; however, the elbow sometimes ends up with considerable loss of movement even though the general anatomy has been restored.

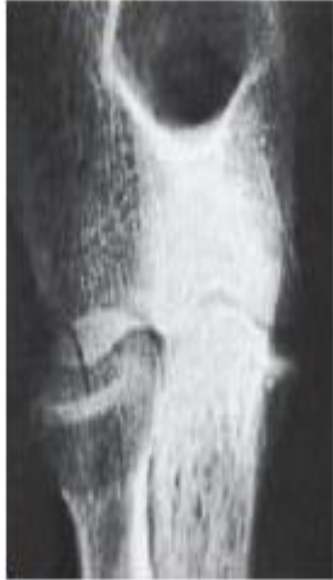
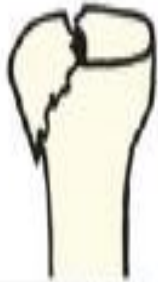
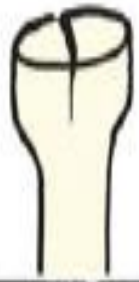(a)

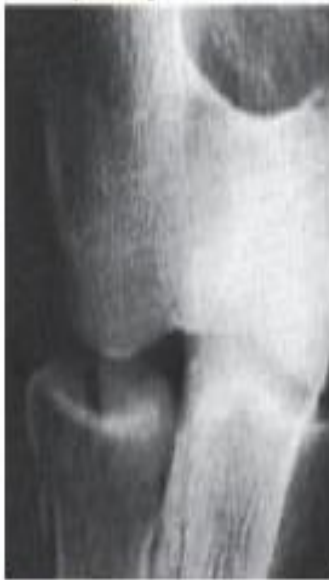

(b)

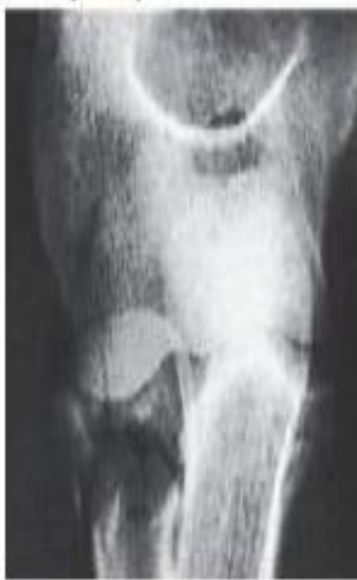**24.24 Fractured capitulum** Anteroposterior and lateral x-rays showing proximal displacement and tilting of the capitular fragment.



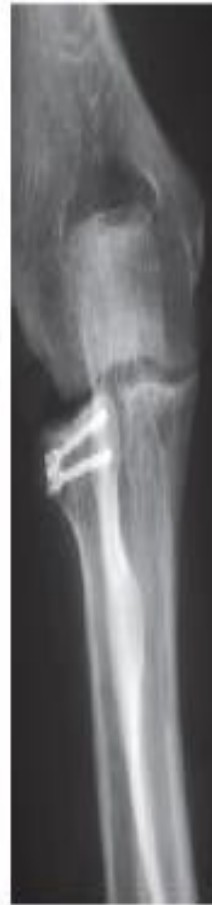(a)



(b)



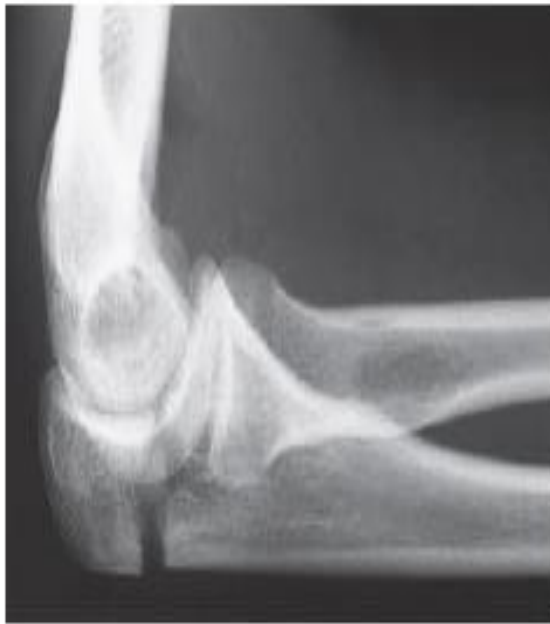(c)



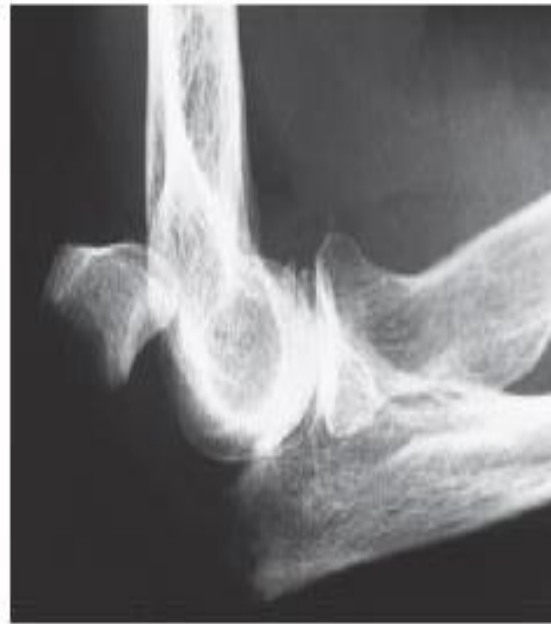(d)

**24.25 Fractured head of radius** There are three main types of adult radial head fracture: (a) a chisel-like split of head, (b) a marginal fracture or (c) a comminuted fracture. Displaced marginal fractures can often be treated by (d) internal fixation.

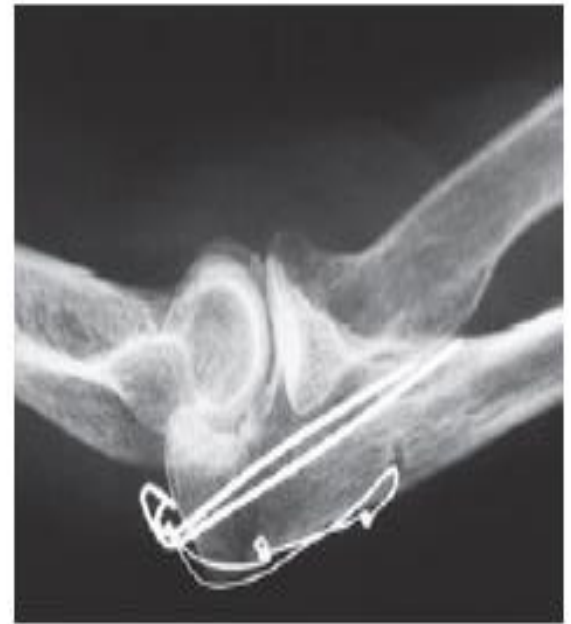



(a)

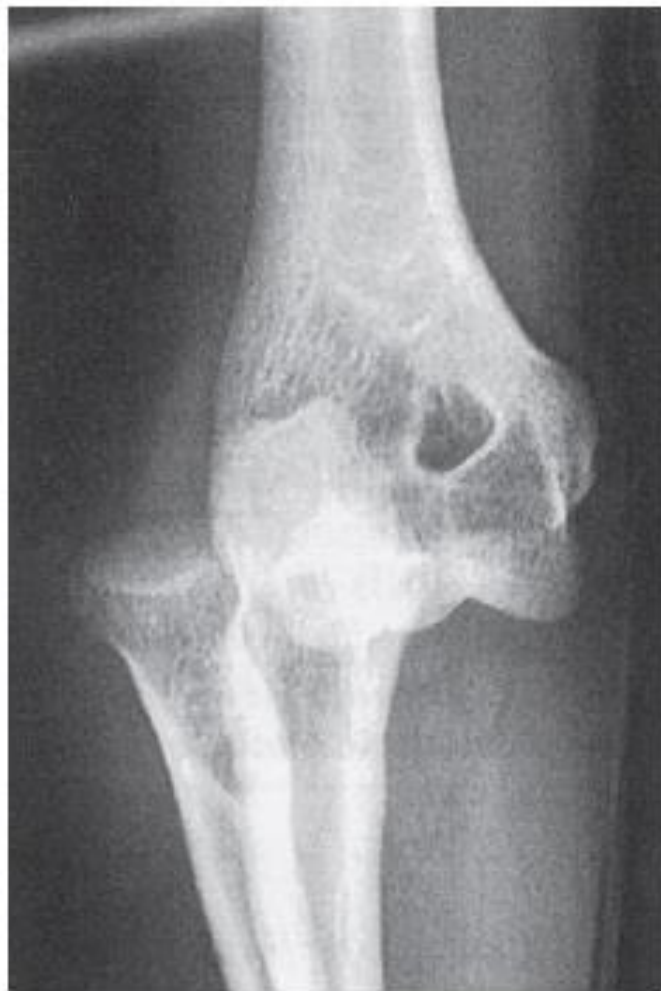

(b)

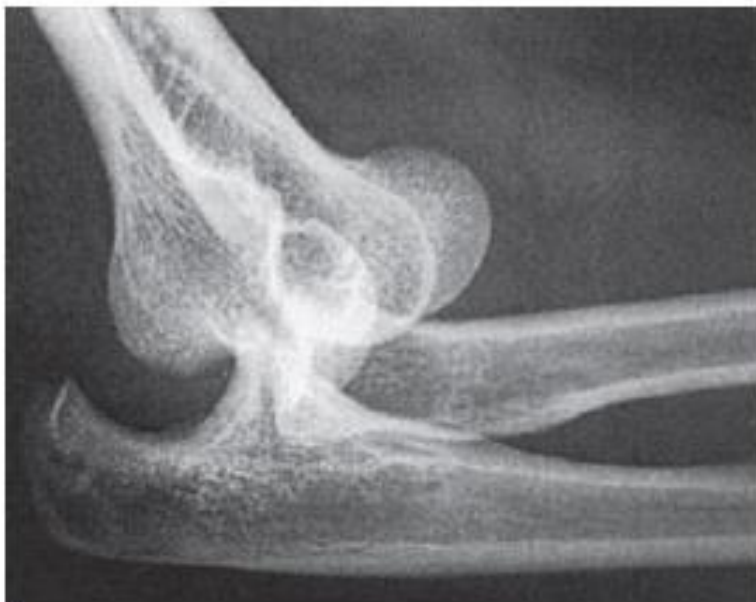

(c)

**24.27 Fractured olecranon** (a) Slightly displaced transverse fracture. (b) Markedly displaced transverse fracture – the extensor mechanism is no longer intact. Treatment in this case was by open reduction and tension-band wiring (c).

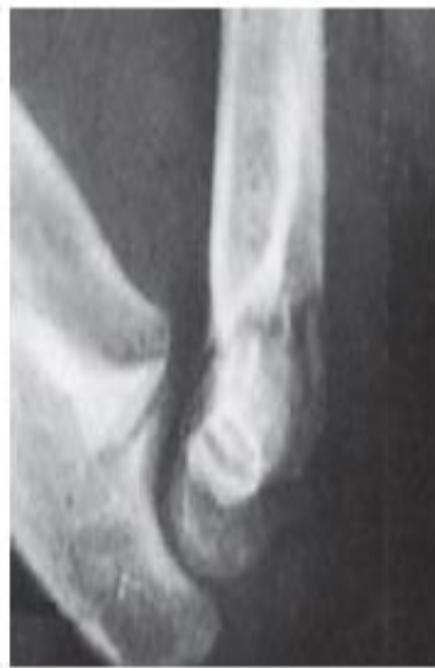

(a)

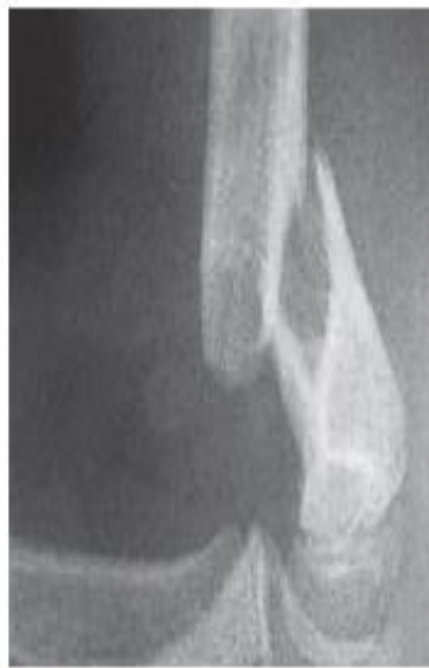

(b)

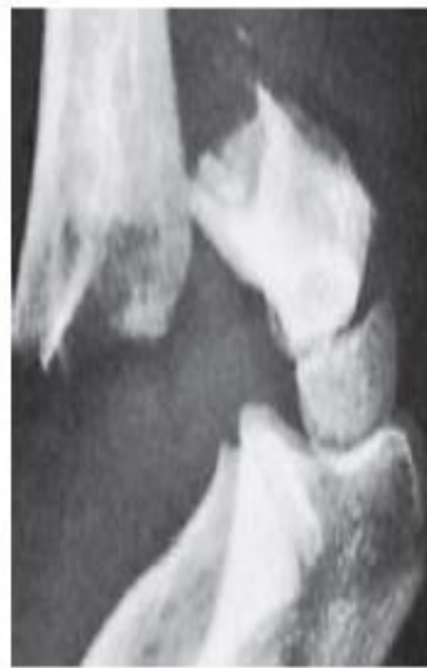**24.28 Dislocation of the elbow** X-rays showing (a) lateral and (b) posterior displacement.



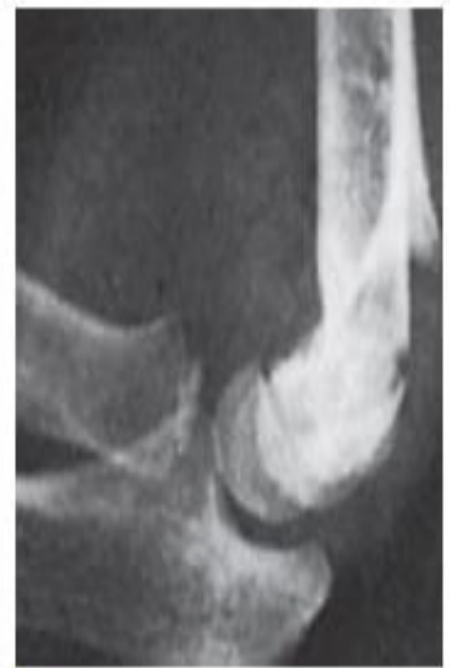(a)



(b)

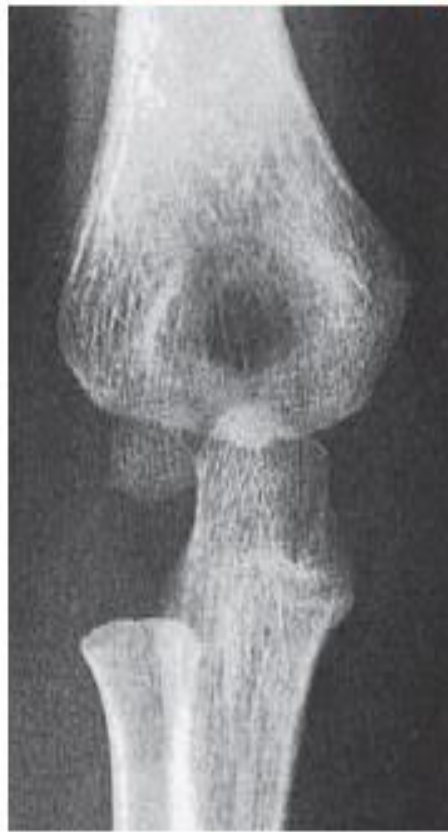

(c)

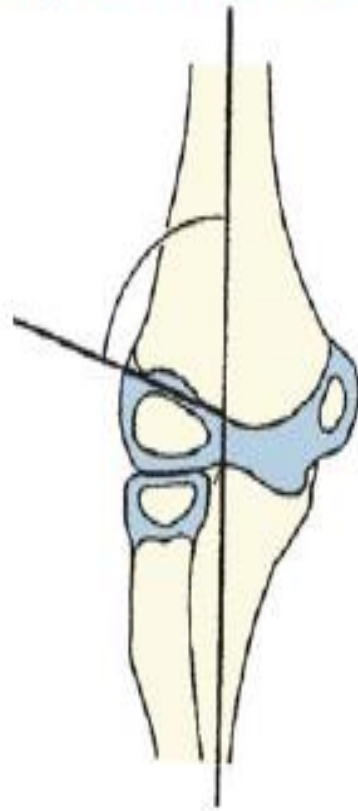


(d)

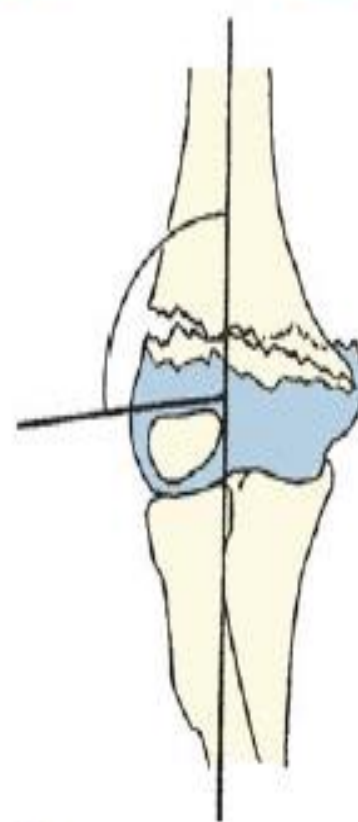
**24.29 Supracondylar fractures** X-rays showing supracondylar fractures of increasing severity. (a) Undisplaced. (b) Distal fragment posteriorly angulated but in contact. (c) Distal fragment completely separated and displaced posteriorly. (d) A rarer variety with anterior angulation.



(a)



(b)

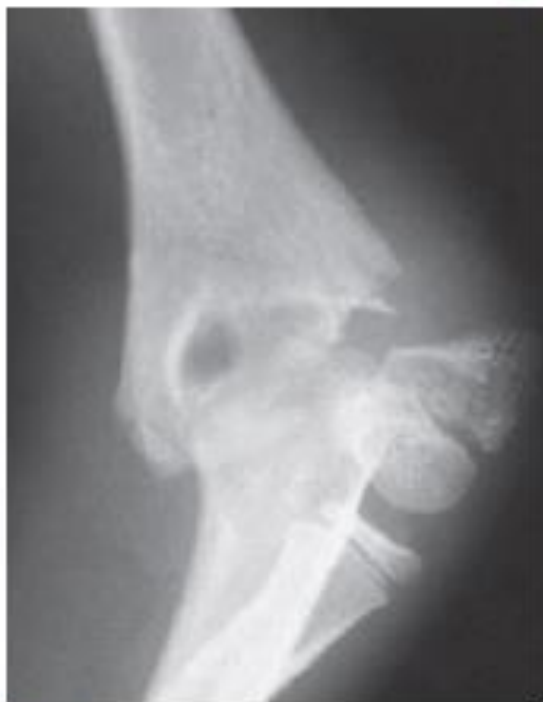

(c)

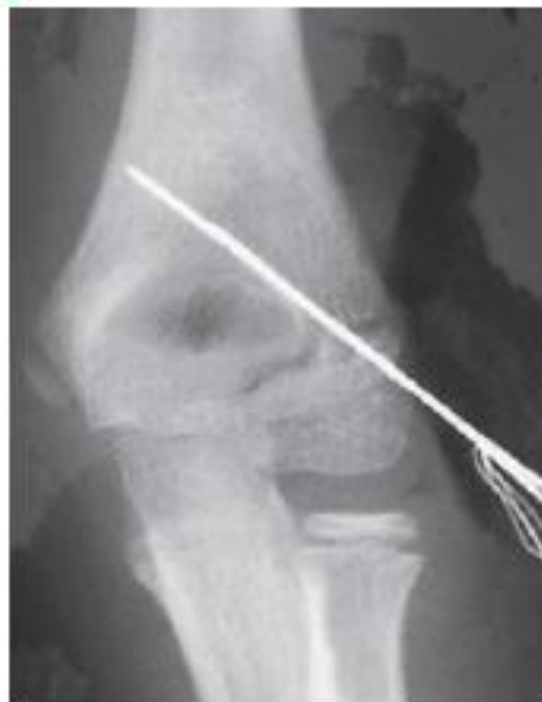### 24.30 Baumann's angle

Anteroposterior x-rays are sometimes difficult to make out, especially if the elbow is held flexed after reduction of the supracondylar fracture.

Measurement of Baumann's angle is helpful. This is the angle subtended by the longitudinal axis of the humeral shaft and a line through the coronal axis of the capitellar physis, as shown in (a) the x-ray of a normal elbow and the accompanying diagram (b). Normally this angle is less than 80 degrees. If the distal fragment is tilted in varus, the increased angle is readily detected (c).



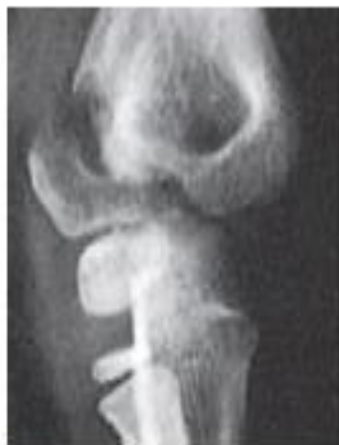(a)



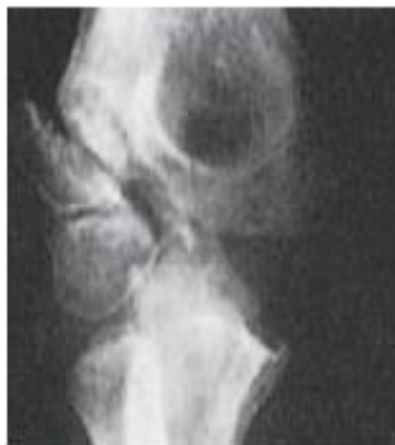(b)

**24.34 Fractured lateral condyle** If displacement is more than 2 mm, open reduction and internal fixation is the treatment of choice.

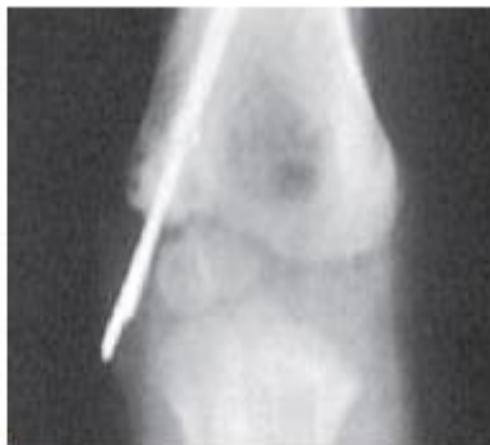



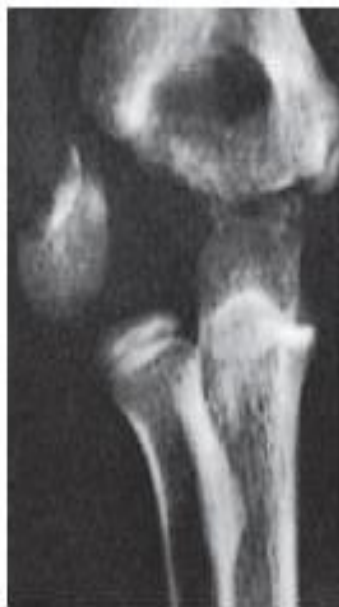(a)



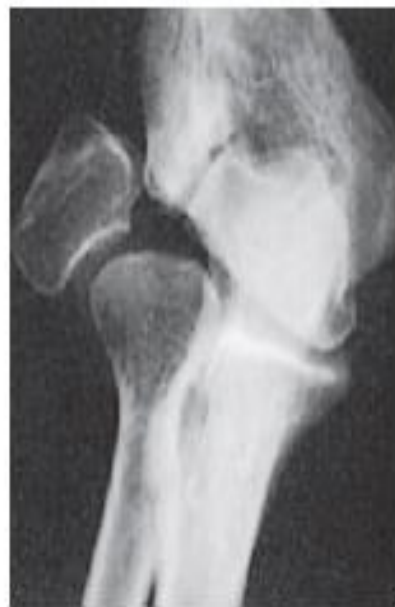(b)



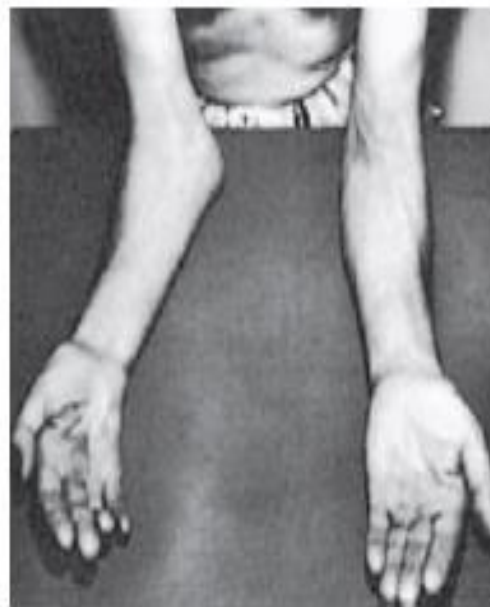(c)



(d)



(e)



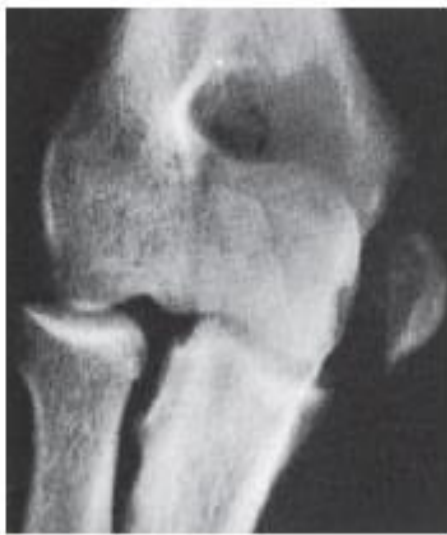(f)

**24.35 Fractured lateral condyle – complications** (a,b) A large fragment of bone and cartilage is avulsed; even with reasonable reduction, union is not inevitable. (c) Open reduction with fixation is often wise. (d) Sometimes the condyle is capsized; if left unreduced non-union is inevitable (e) and a valgus elbow with delayed ulnar palsy (f) the likely sequel.

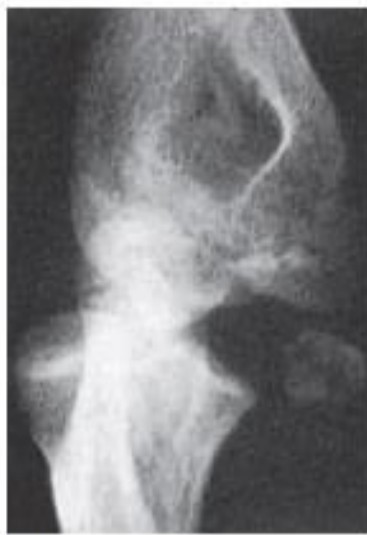**24.36 Fractured medial epicondyle** (a) Avulsion of the medial epicondyle following valgus strain.

(b) Avulsion associated with dislocation of the elbow; (c) after reduction.

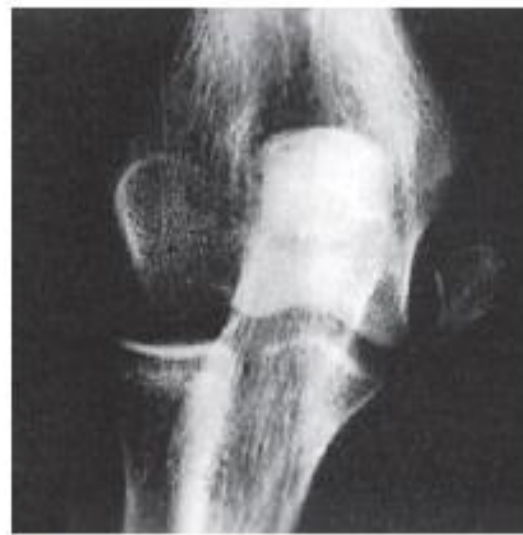Sometimes the epicondylar fragment is trapped in the joint (d,e); the serious nature is then liable to be missed unless the surgeon specifically looks for the trapped fragment, which is emphasized in the tracings (f,g).



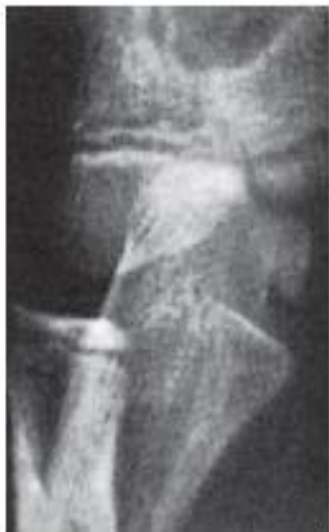(a)



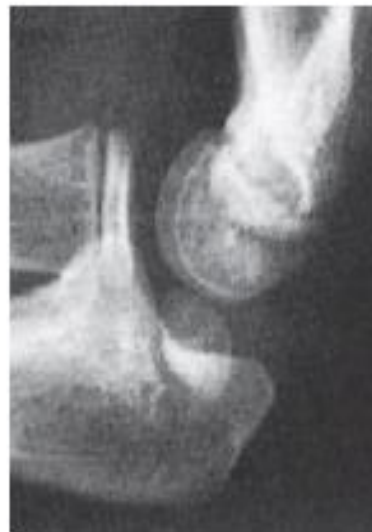(b)



(c)



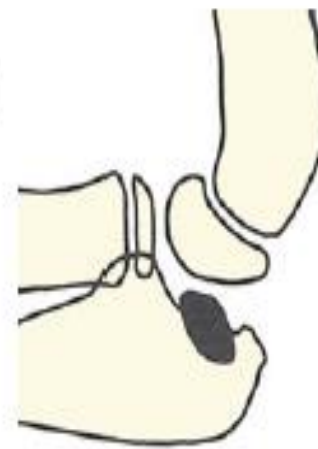(d)



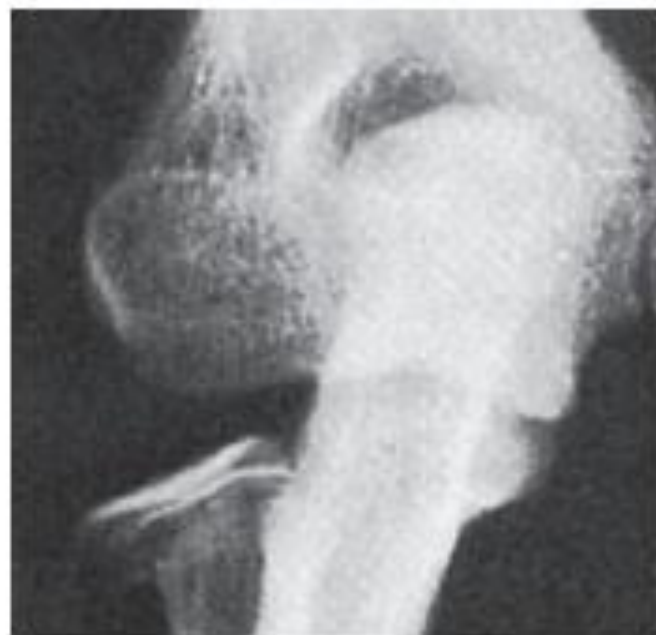(e)



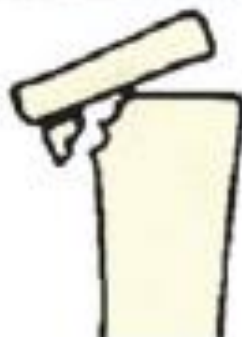(f)

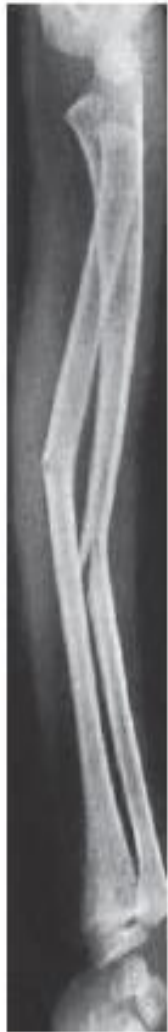

(g)

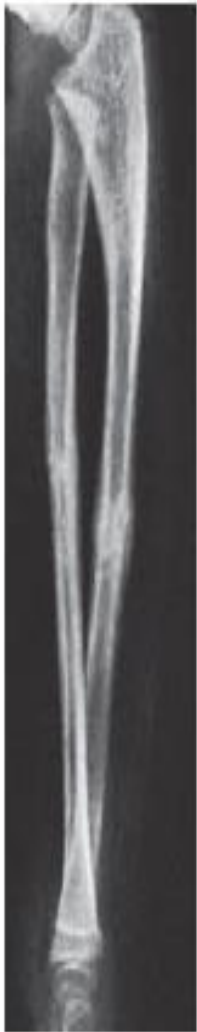

**24.37 Fractured neck of radius in a child** Up to  $30^{\circ}$  of tilt is acceptable. Greater degrees of angulation should be reduced; never excise the radial head in a child.

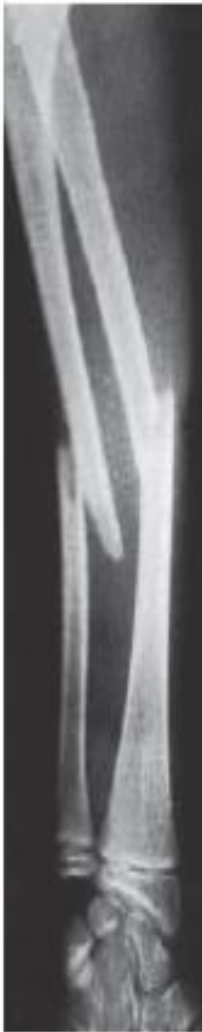



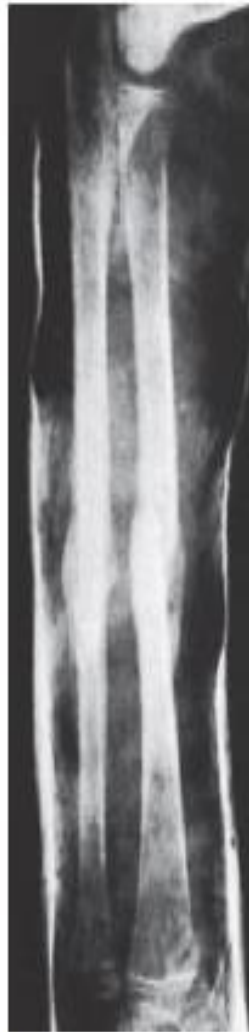(a)



(b)



(c)



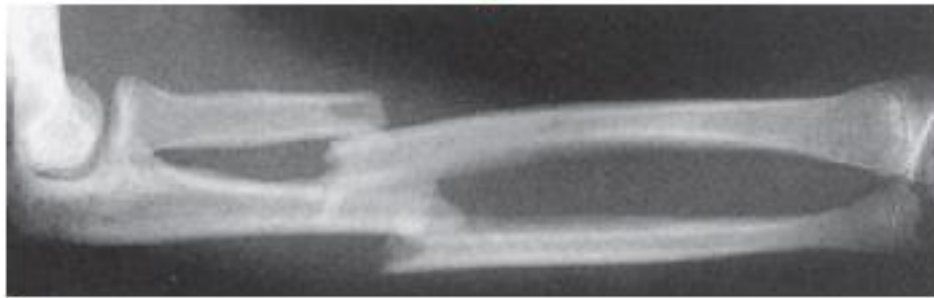
(d)




(e)

### 25.1 Fractured radius and ulna in children

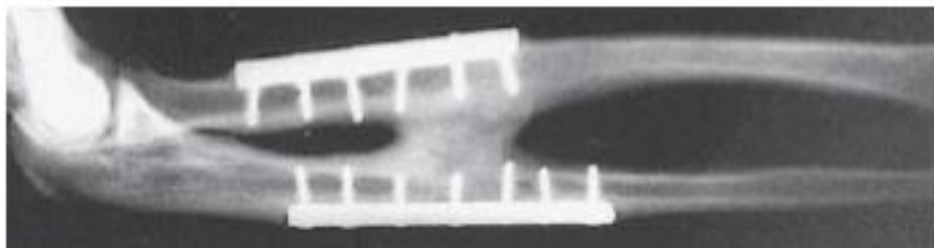
Greenstick fractures (a) need only correction of angulation (b), and plaster splintage. Complete fractures (c) are harder to reduce; but provided alignment is corrected and held in plaster (d), slight lateral shift remodels with growth (e).



(a)



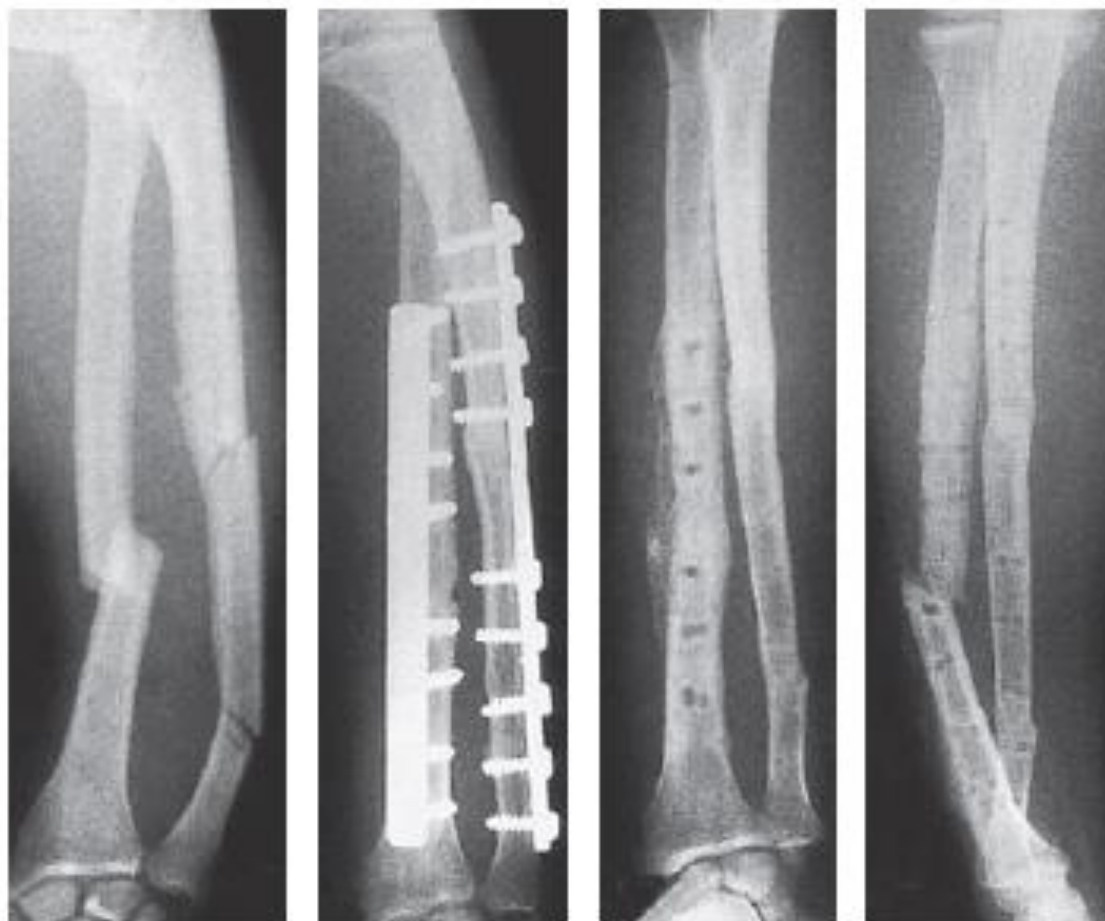
(b)



(c)

**25.3 Fractured radius and ulna – cross-union** If the interosseous membrane is severely damaged, even successful plating (a,b) cannot guarantee that cross-union will not occur (c).





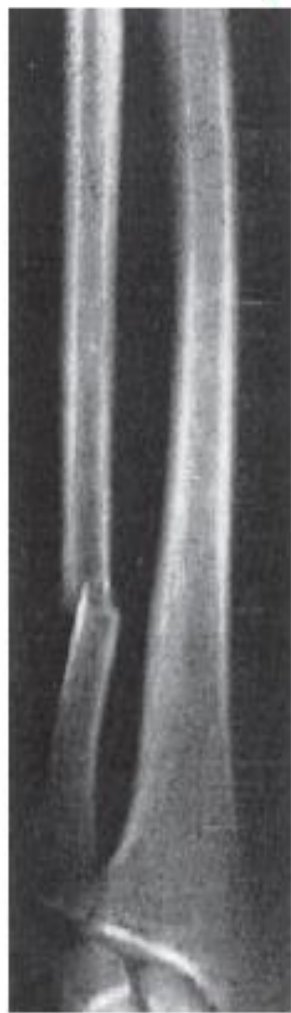(a)

(b)

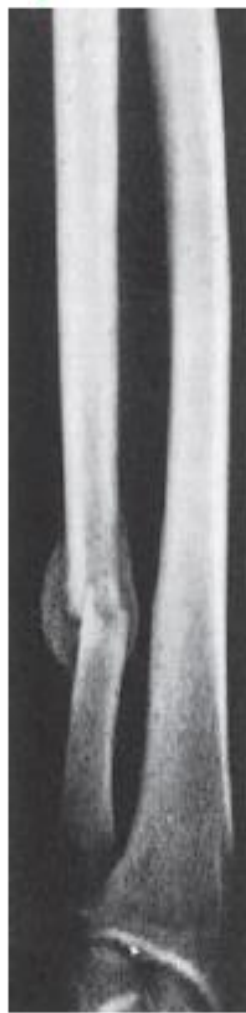(c)

(d)

**25.2 Fractured radius and ulna in adults (a, b)** These fractures are usually treated by internal fixation with sturdy plates and screws. However, removal of the implants is not without risk. **(c,d)** In this case, the radius fractured through one of the screw holes.



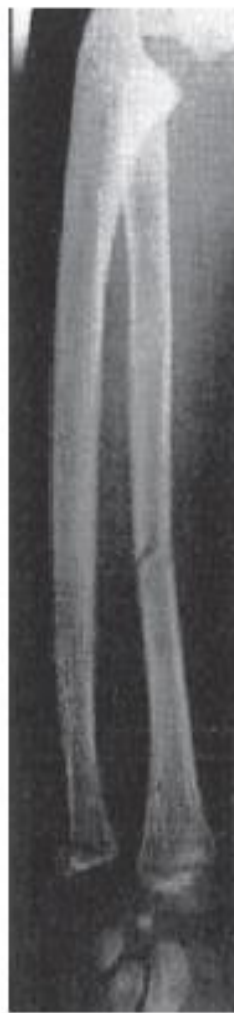(a)



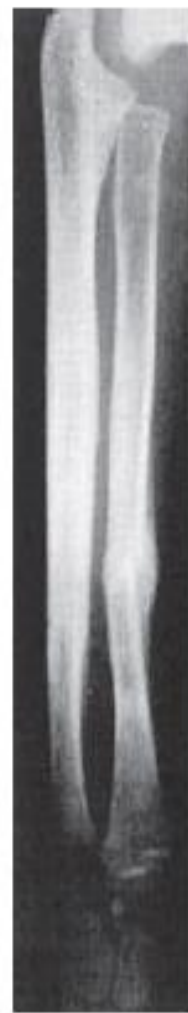(b)



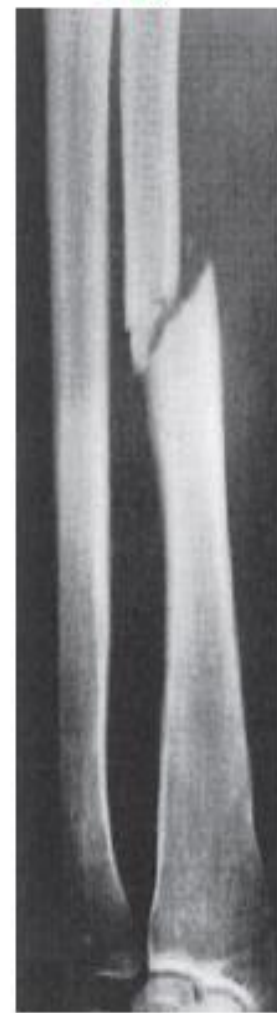
(c)



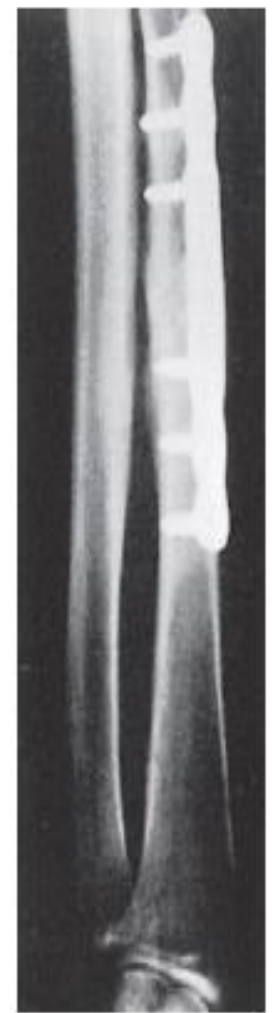(d)



(e)

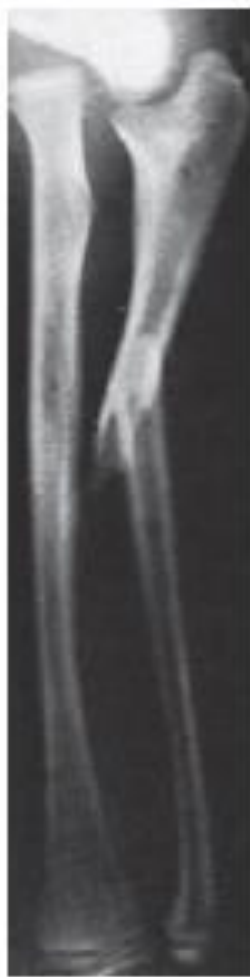

(f)

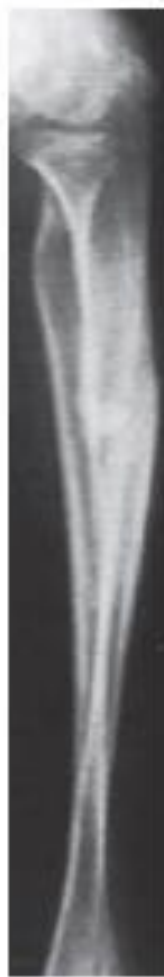

(g)

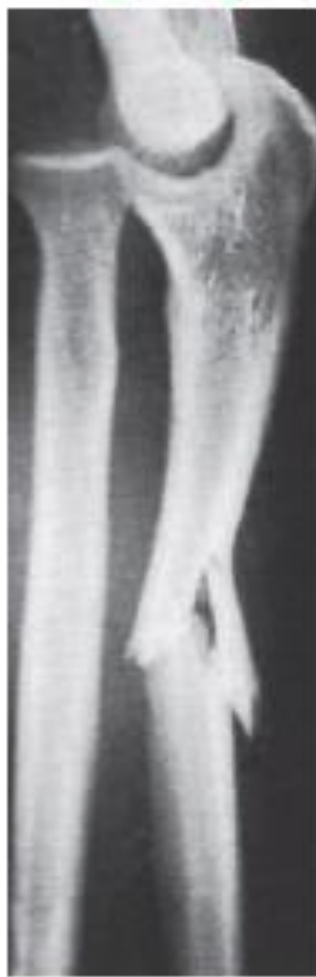**25.5 Fracture of one forearm bone** *Fracture of the ulna:* A fracture of the ulna alone (a) usually joins satisfactorily (b); in children the intact radius may be bowed (c). *Fracture of the radius:* In a child, fracture of the radius alone (d) may join in plaster (e), but in adults a fractured radius (f) is better treated by plating (g).



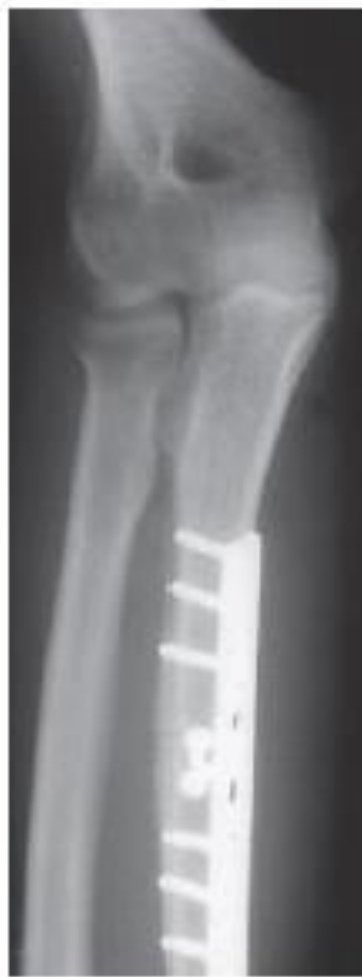(a)



(b)

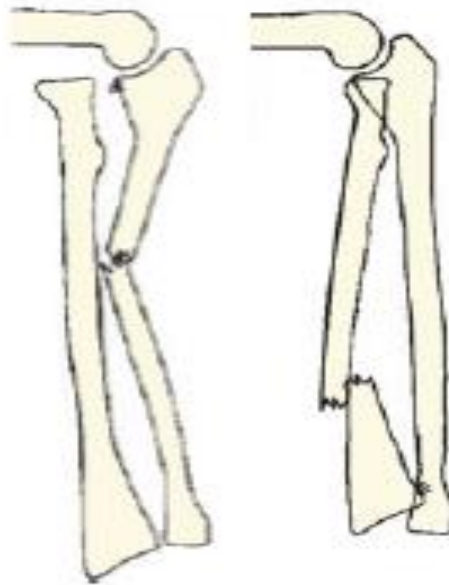


(c)



(d)

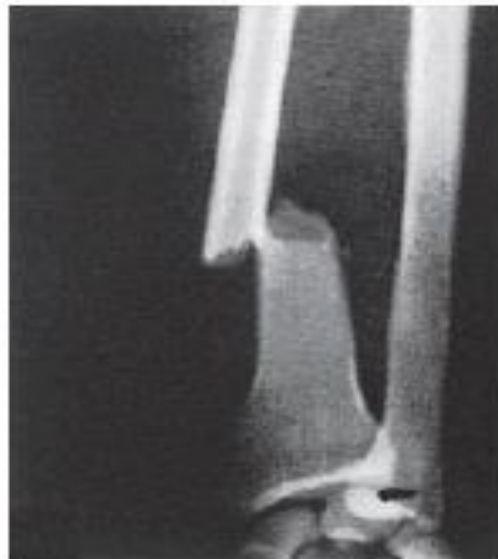**25.6 Monteggia fracture-dislocation** (a) The ulna is fractured and the head of the radius no longer points to the capitulum. In a child, closed reduction and plaster (b) is usually satisfactory; in the adult (c) open reduction and plating (d) is preferred.



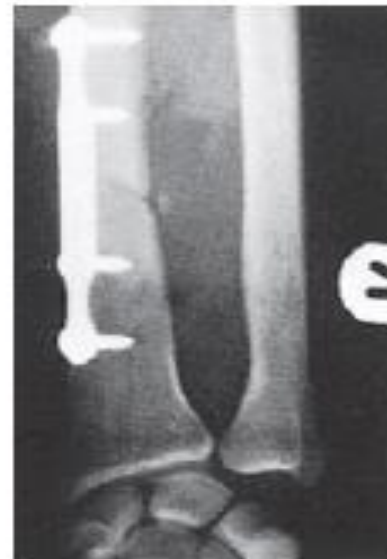
(a)

(b)

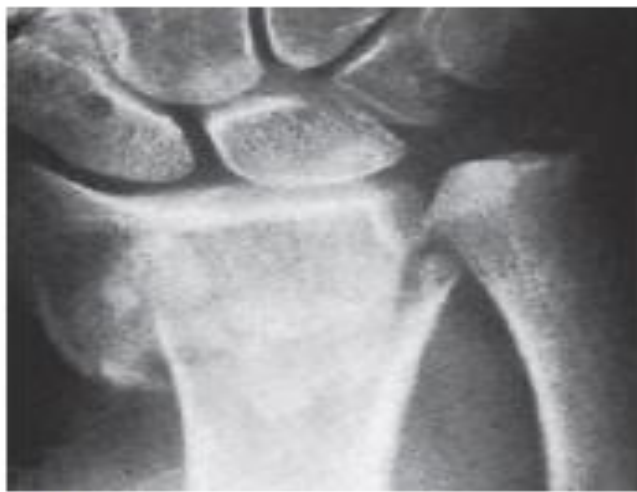**25.7 Galeazzi fracture-dislocation** The diagrams show the contrast between (a) Monteggia and (b) Galeazzi fracture-dislocations. (c,d) Galeazzi type before and after reduction and plating.



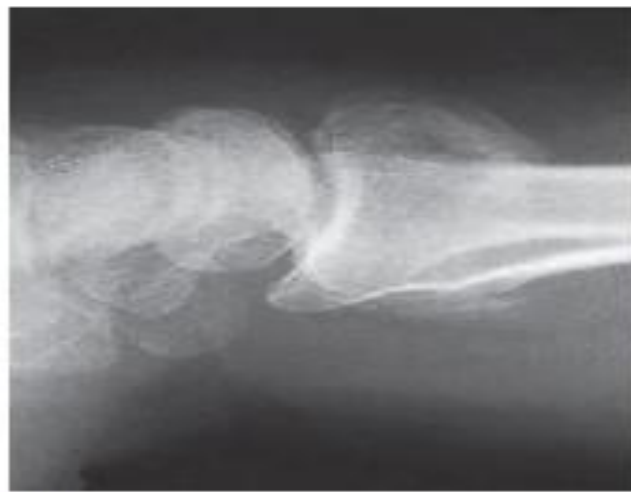(c)



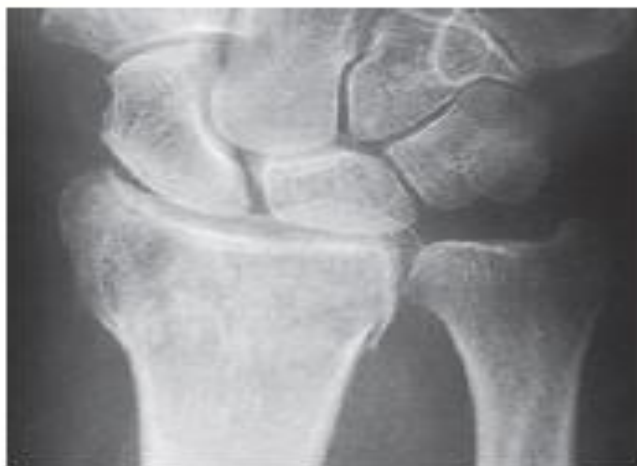(d)



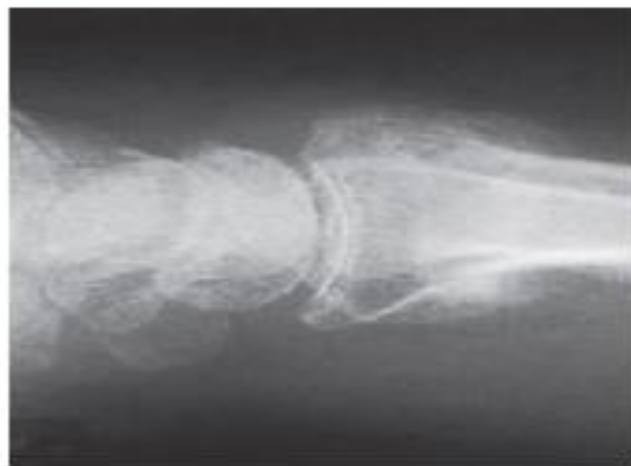(a)



(b)



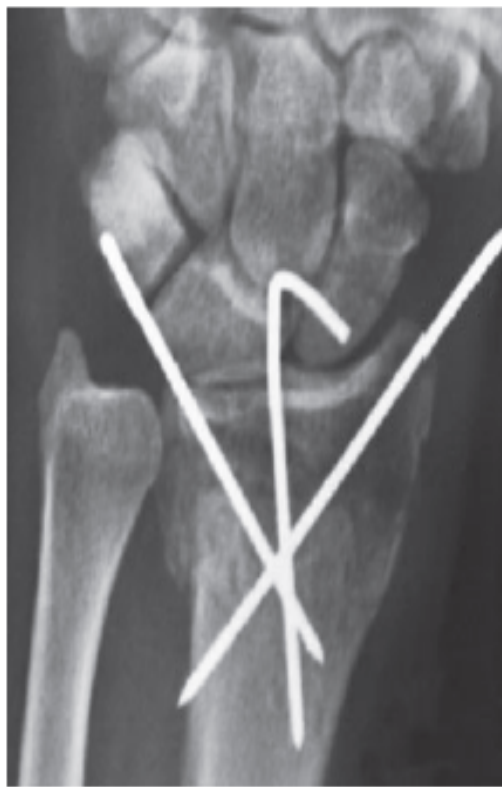(c)



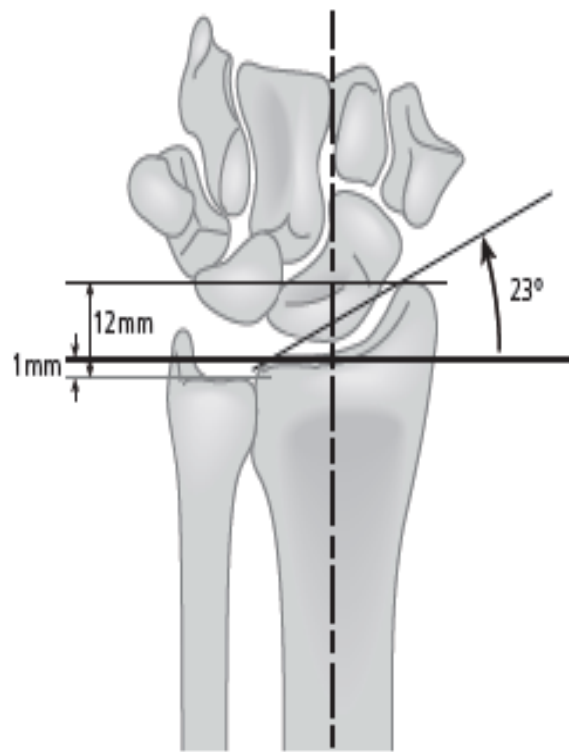
(d)

**25.8 Colles' fracture (a,b)** The typical Colles' fracture is both displaced and angulated towards the dorsum and towards the radial side of the wrist. **(c,d)** Note, how, after successful reduction, the radial articular surface faces correctly both distally and slightly volarwards.

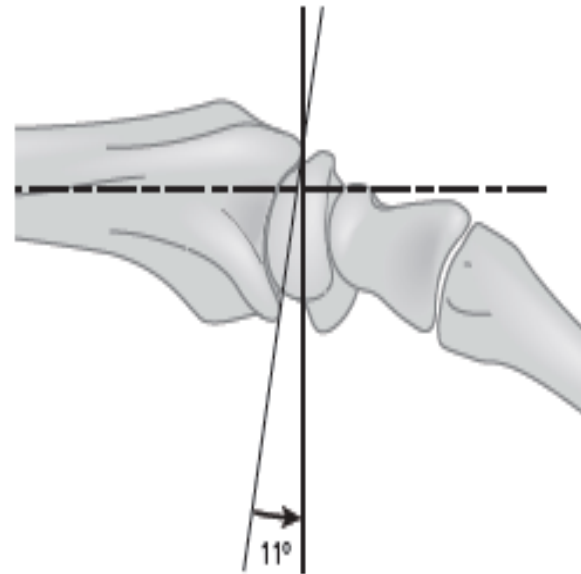




(a)

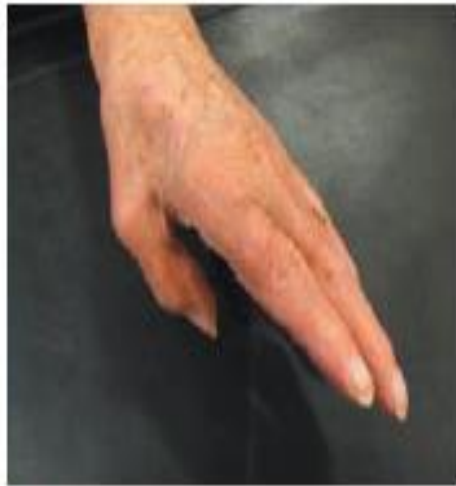

(b)

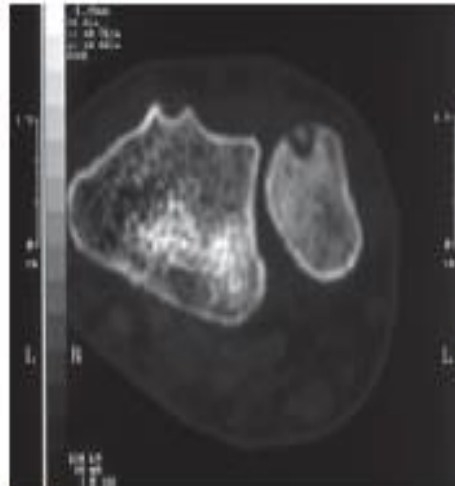


(c)

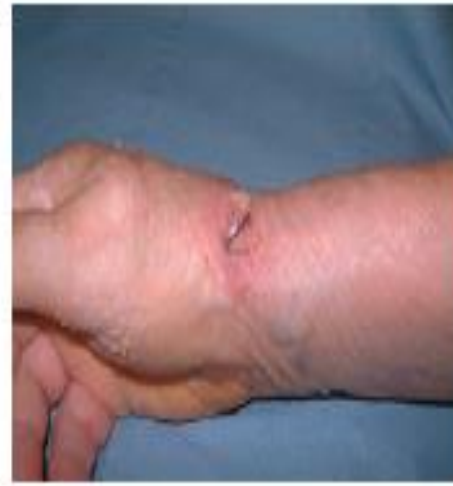**25.9 Colles' fracture – operative fixation** (a) Comminuted Colles' fracture reduced and held with percutaneous wires. Make sure that the articular surface angles are correctly restored (b,c).



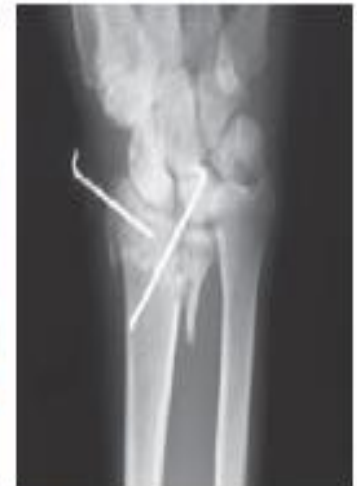(a)



(b)

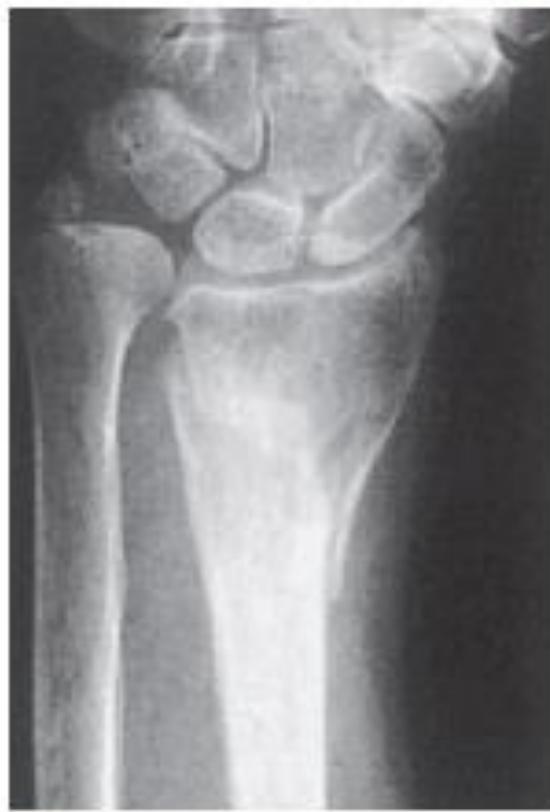

(c)

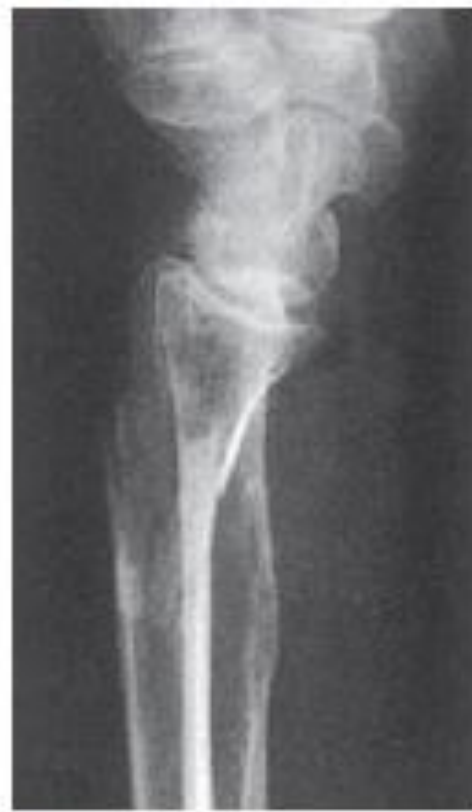

(d)

**25.10 Colles' fracture-complications** (a) Rupture of extensor pollicis longus; (b) malunion – CT scan showing incongruity of the distal radio-ulnar joint; (c) infected K-wire; (d) failed fixation as the wires have cut through the osteoporotic bone.

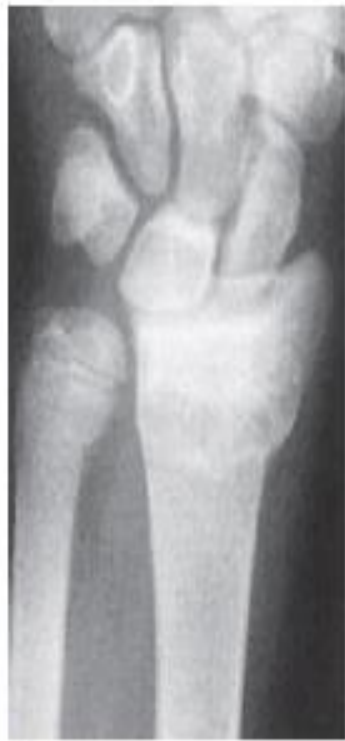

(a)

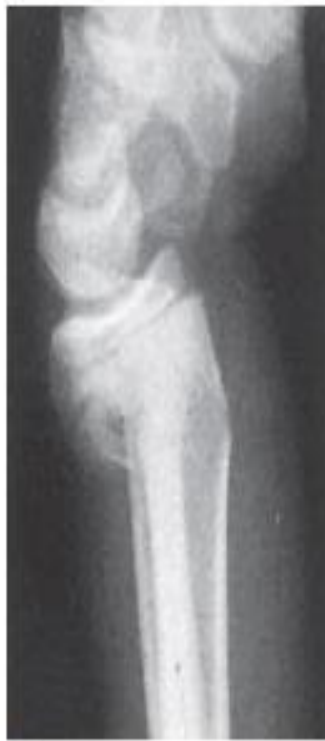

(b)

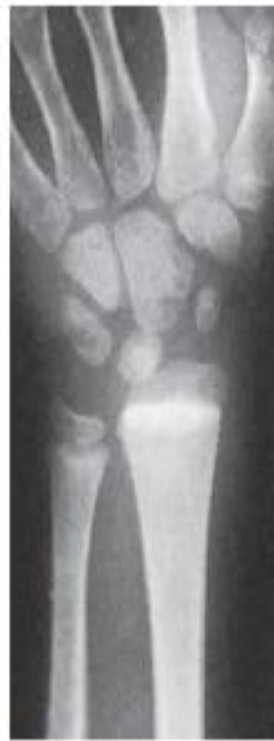**25.11 Smith's fracture (a,b)** Here, in contrast to Colles' fracture, the displacement of the lower radial fragment is forwards – not backwards.



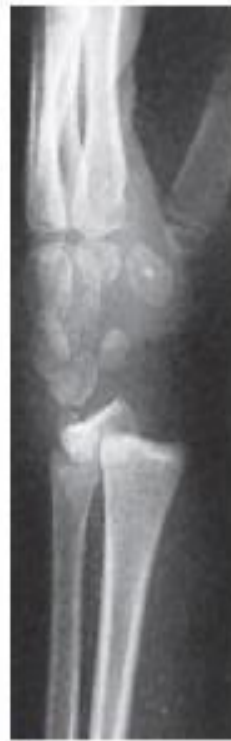(a)



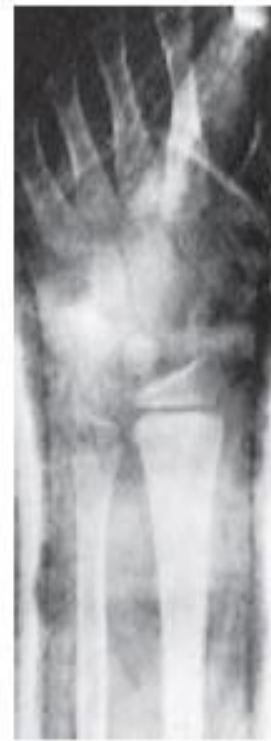(b)



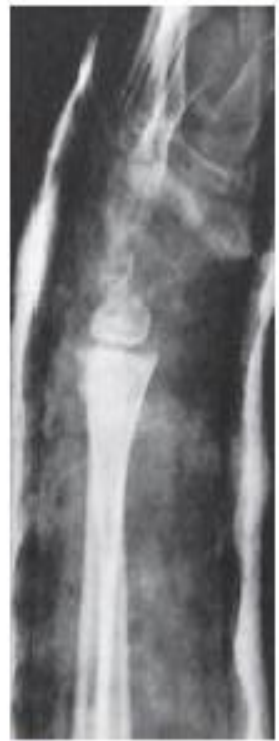(c)



(d)

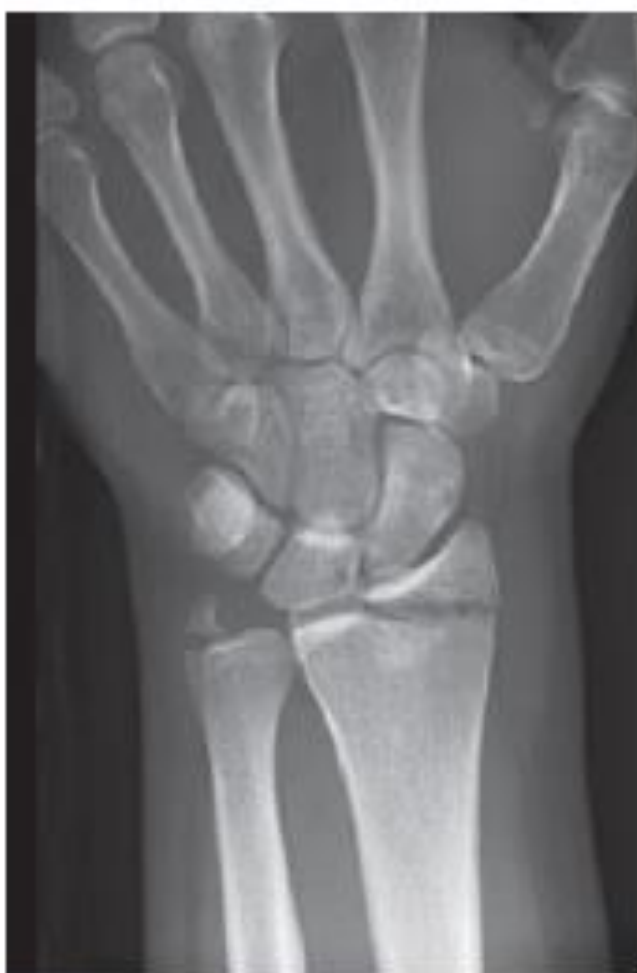

(e)

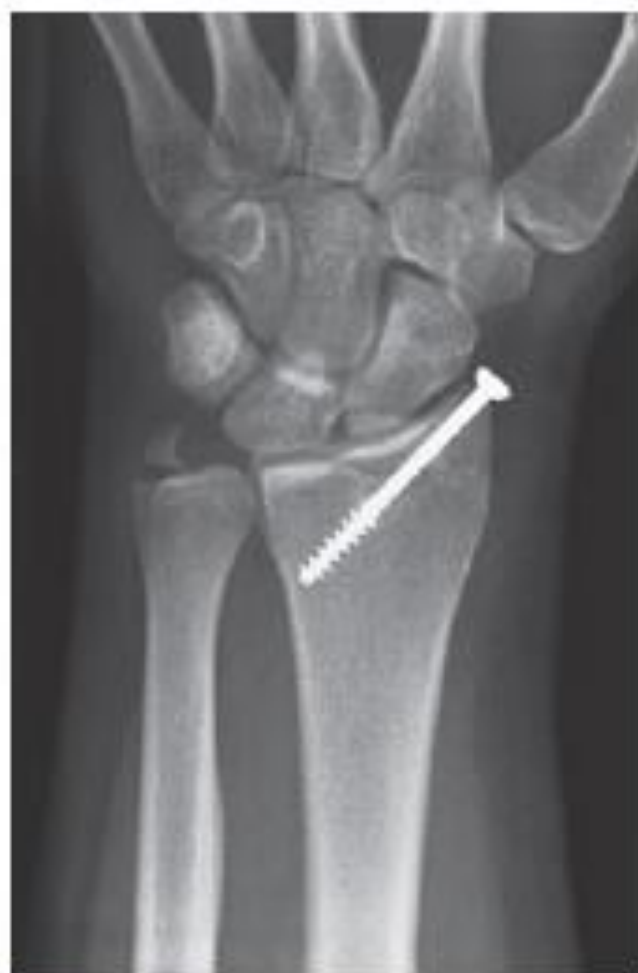

(f)

**25.12 Distal forearm fractures in children** (a,b) In older children the fracture is usually slightly more proximal than a true Colles', and often merely a greenstick or buckling injury. (c,d) In young children physeal fractures are usually Salter-Harris type I or II. In this case, accurate reduction has been achieved (e,f).



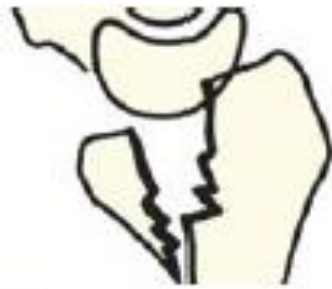(a)



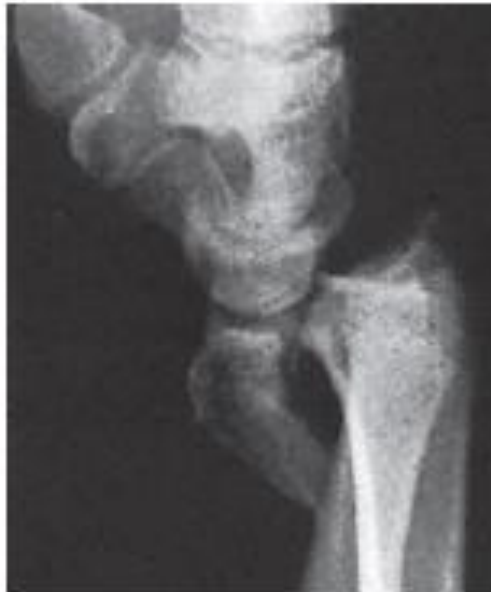(b)

**25.13 Fractured radial styloid** (a) X-ray; (b) fixation with cannulated percutaneous screw.

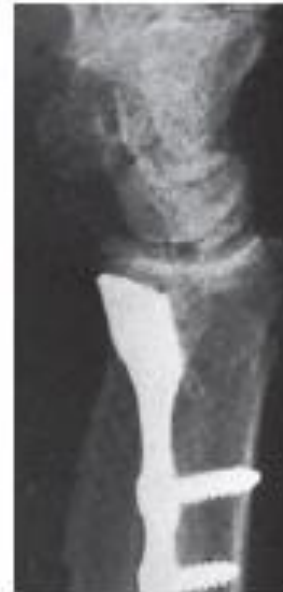



(a)



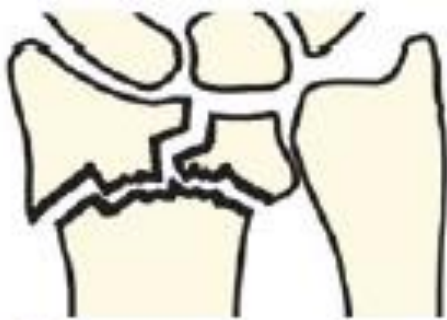
(b)



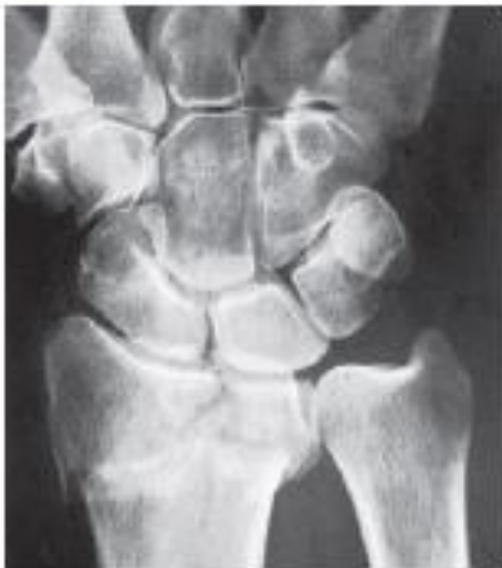(c)

#### 25.14 Fracture-subluxation (Barton's fracture)

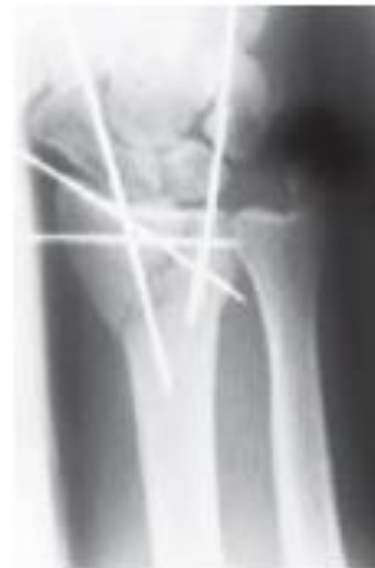(a,b) The true Barton's fracture is a split of the volar edge of the distal radius with anterior (volar) subluxation of the wrist. This has been reduced and held (c) with a small anterior plate.



(a)

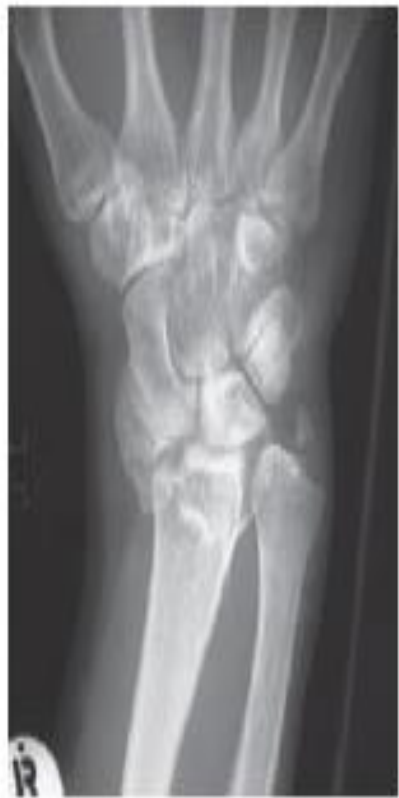

(b)

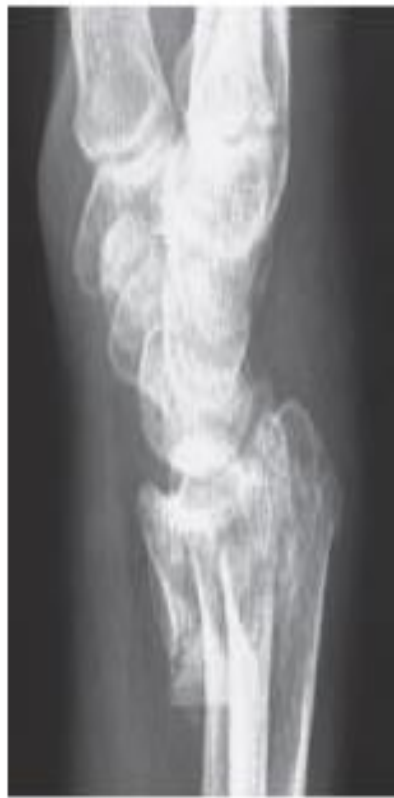

(c)

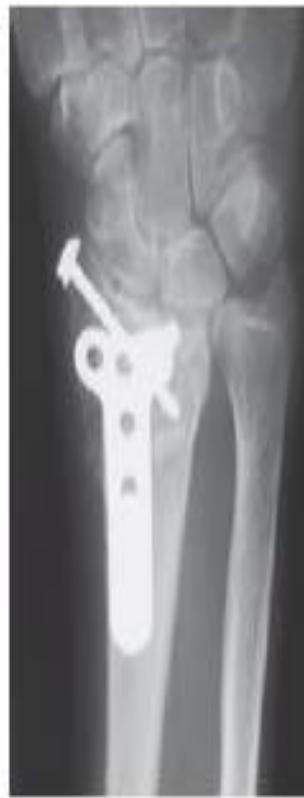**25.15 Comminuted fracture of the distal radius** The 'die punch fragment' of the lunate fossa of the distal radius (a,b) must be perfectly reduced and fixed; here this has been achieved by closed reduction and percutaneous K-wire fixation (c). The wires can be used as 'joy sticks' to manipulate the fragment back before fixation.



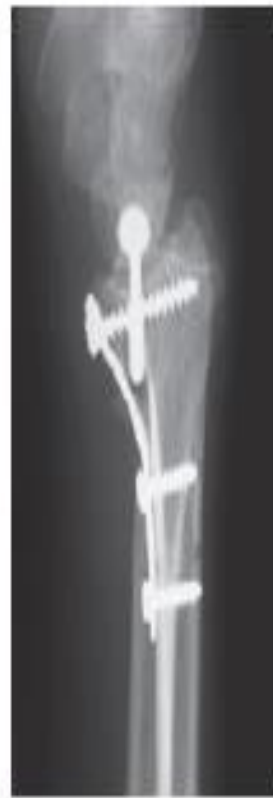(a)



(b)

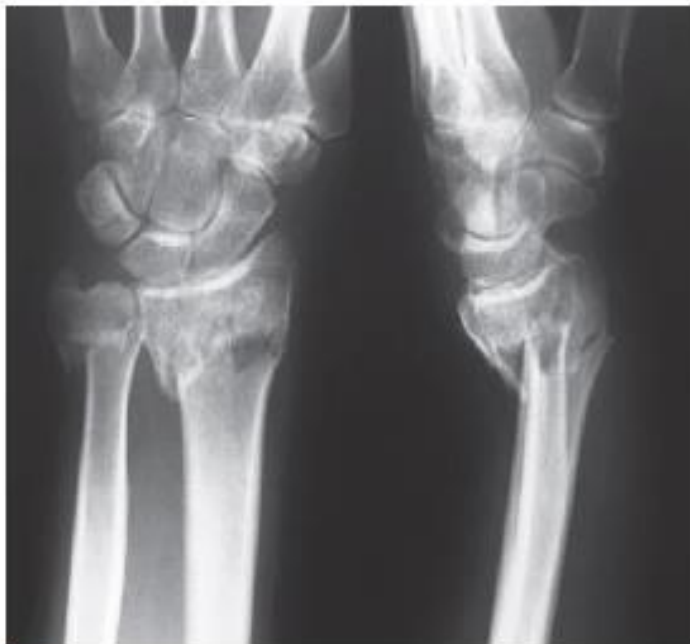


(c)

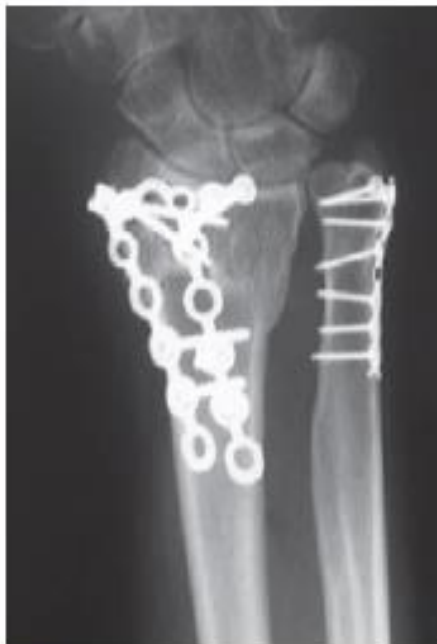

(d)

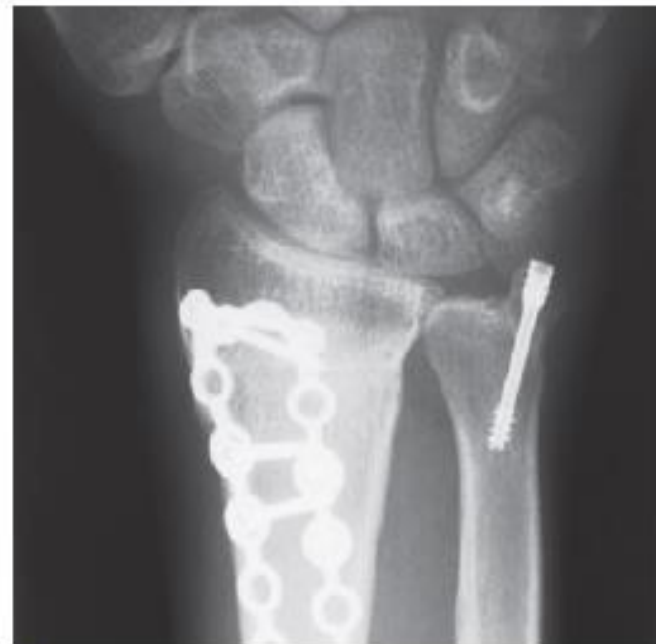25.16 High energy injuries in younger patients Perfect reduction is required.



(a)

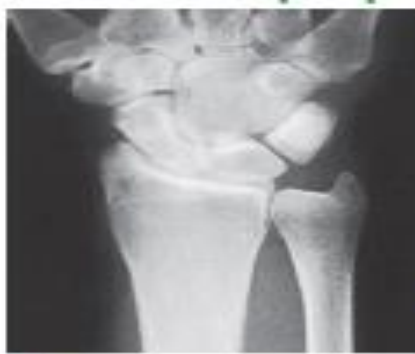

(b)

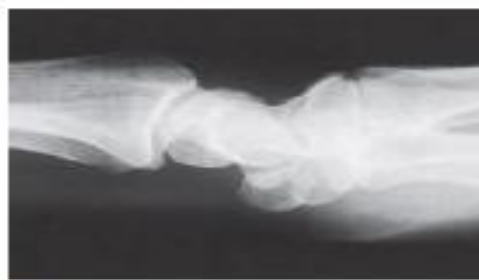

(c)

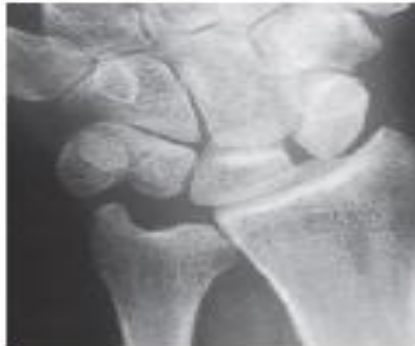**25.18 Don't forget the ulna** (a) Fracture of radius and ulna, both unstable. (b) Both bones fixed. (c) Ulnar styloid fracture fixed to prevent instability of distal radio-ulnar joint.



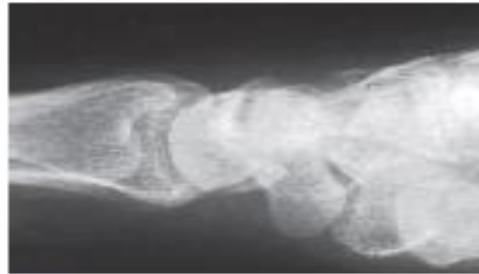
(a)



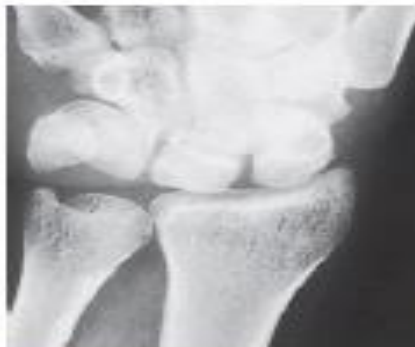(b)



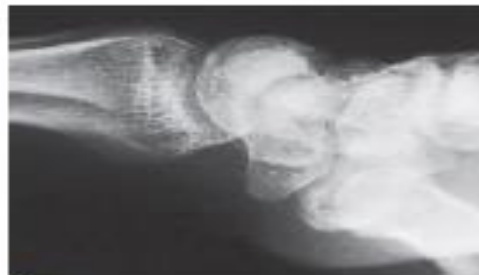(c)



(d)



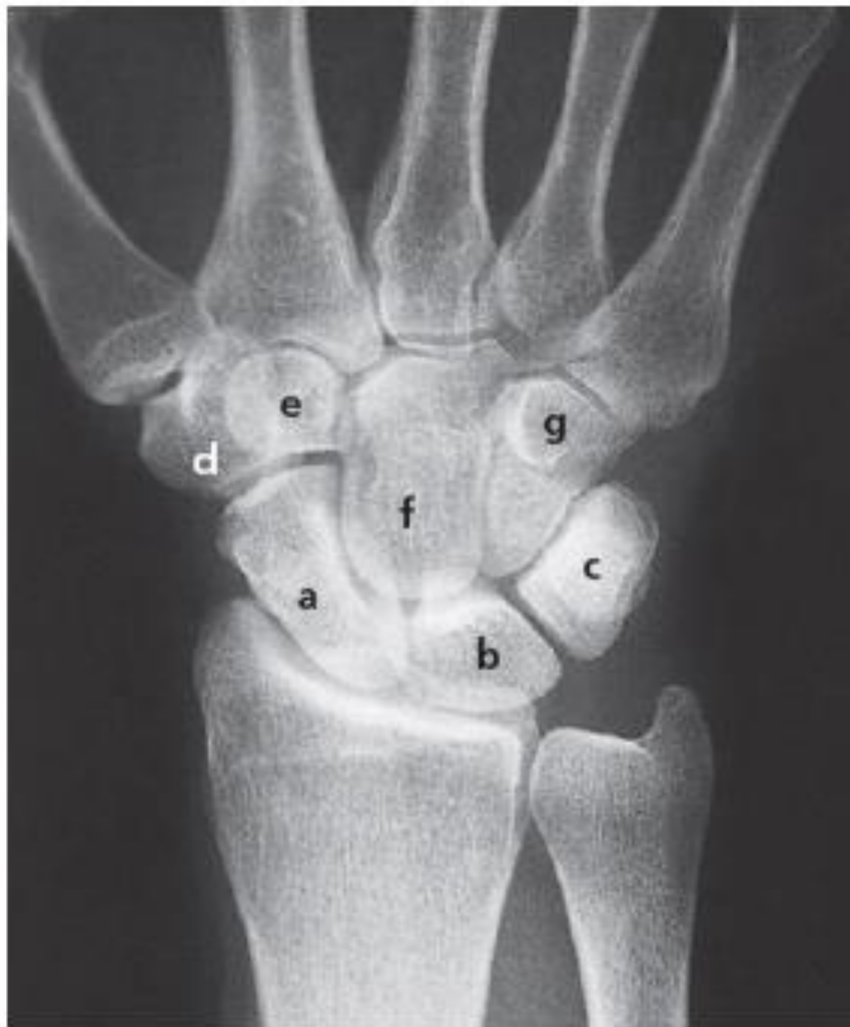(e)



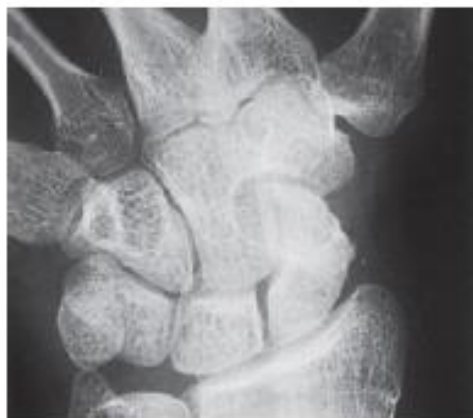(f)

**25.20 Carpal Injuries** (a,b) Normal appearances in antero-posterior and lateral x-rays. (c,d) Following a 'sprained wrist' this patient developed persistent pain and weakness. X-rays showed (c) scapho-lunate dissociation and (d) dorsal rotation of the lunate (the typical DISI pattern). (e,f) This patient, too, had a sprained wrist. The anteroposterior and lateral x-rays show foreshortening of the scaphoid and volar rotation of the lunate (VISI).

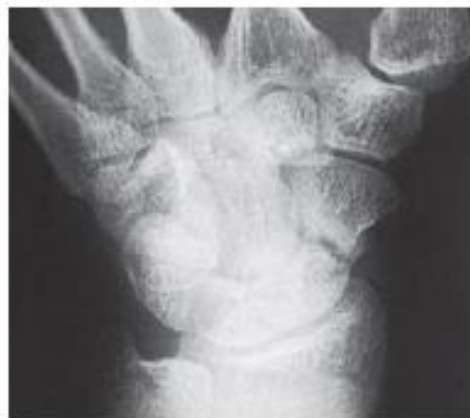



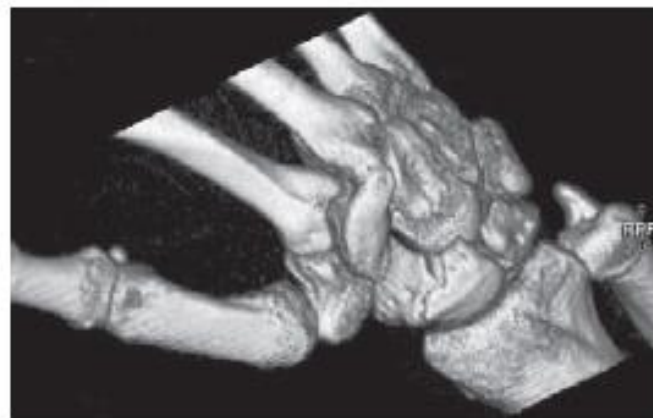
**25.21 X-ray appearance of the normal carpus** X-ray of a normal wrist showing the shape and disposition of the eight carpal bones: **(a)** scaphoid; **(b)** lunate; **(c)** triquetrum overlain by pisiform; **(d)** trapezium; **(e)** trapezoid; **(f)** capitate; and **(g)** hamate.



(a)



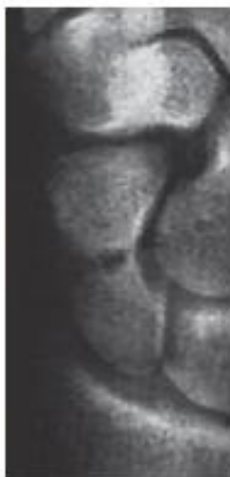(b)



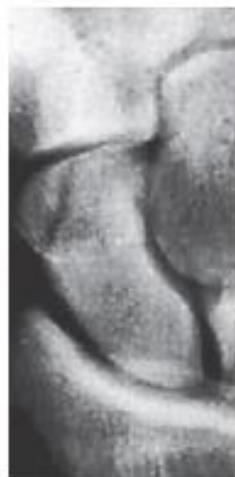(c)



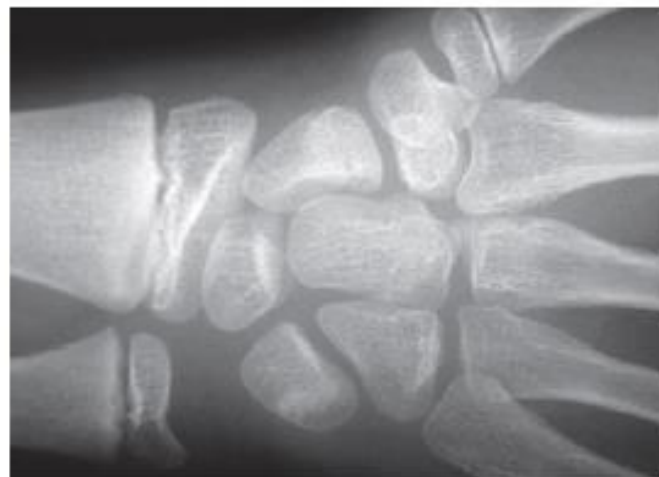
(d)



(e)

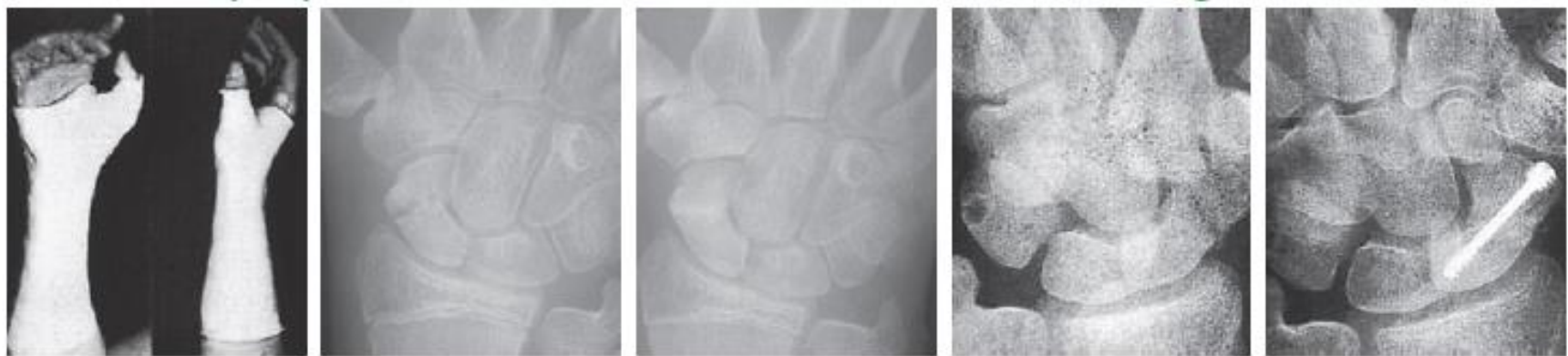

(f)



(g)

**25.22 Fractures of the scaphoid – diagnosis** (a) The initial anteroposterior view often fails to show the fracture; (b) always ask for a 'scaphoid series', including two oblique views. If the clinical features are suggestive of a fracture, then immobilize the wrist and repeat the x-ray 2 weeks later when the fracture is more likely to be apparent. (c) A CT scan is useful for showing the fracture configuration. The fracture may be (d) through the proximal pole, (e) the waist, or (f) the scaphoid tubercle. Occasionally these fractures are seen in children (g).



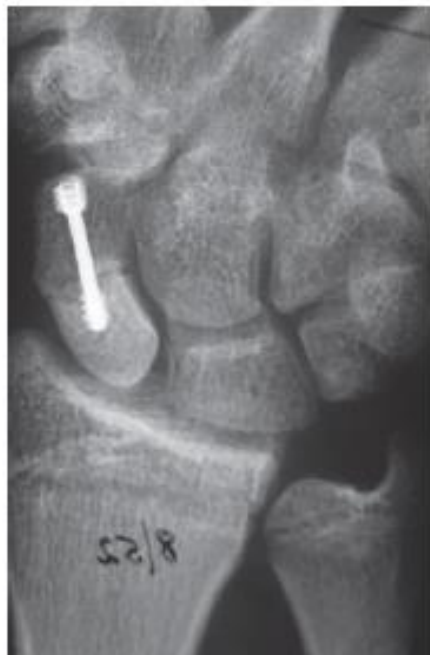(a)

(b)

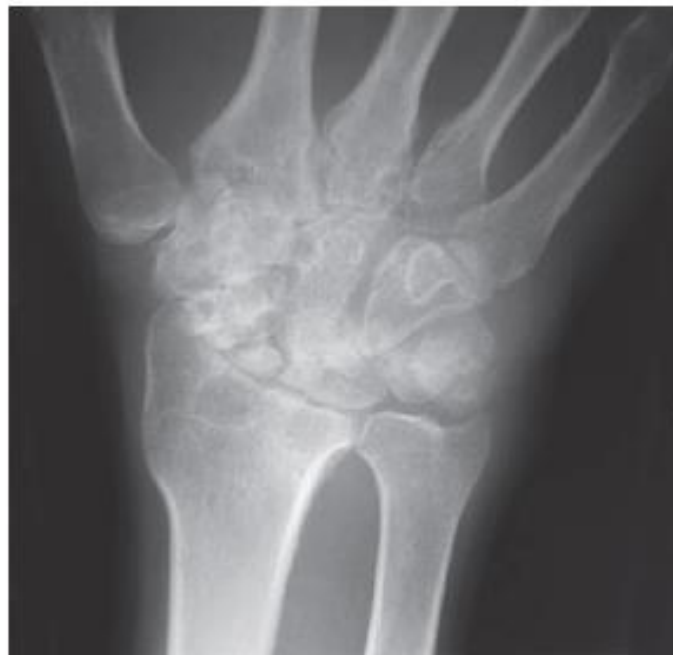(c)

(d)

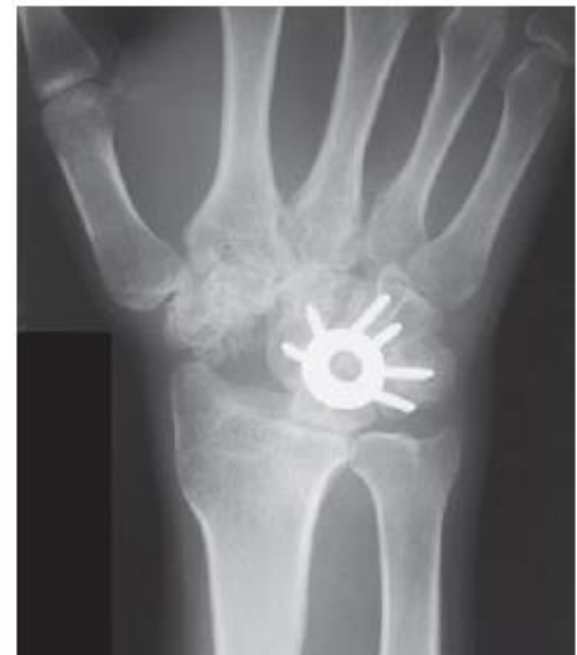(e)



(f)

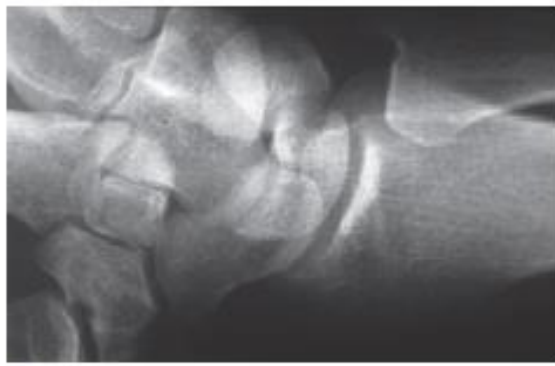

(g)

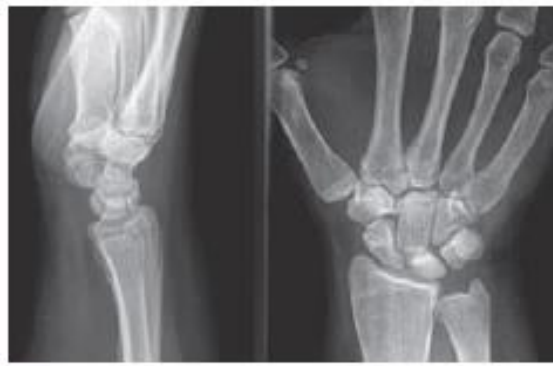

(h)

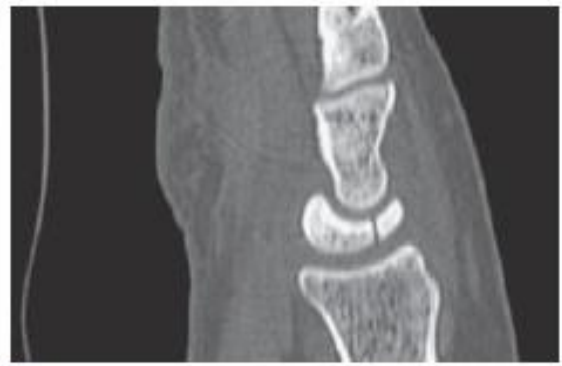
**25.23 Fractures of the scaphoid –treatment** (a) Scaphoid plaster – position and extent. (b,c) Before and after treatment: in this case radiological union was visible at 10 weeks. (d) Delayed union, treated successfully by (e) bone grafting and screw fixation. (f) Long-standing stable non-union. (g) Non-union with avascular necrosis and secondary osteoarthritis treated by (h) scaphoid excision and four-corner fusion.



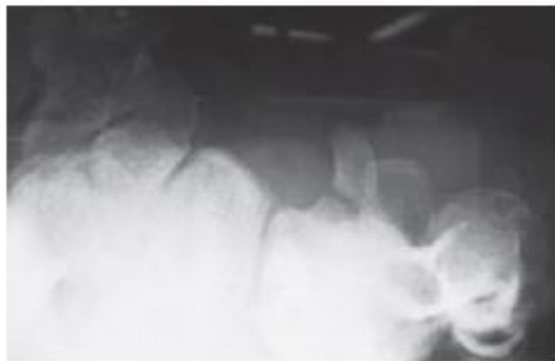(a)



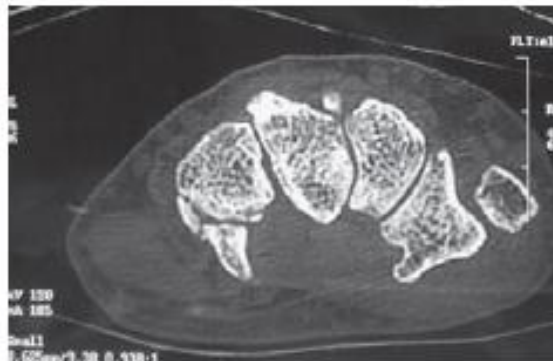
(b)



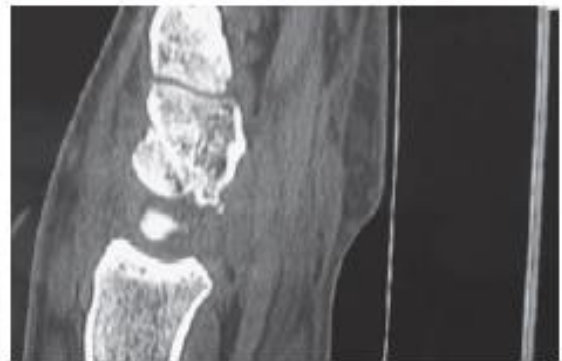
(c)



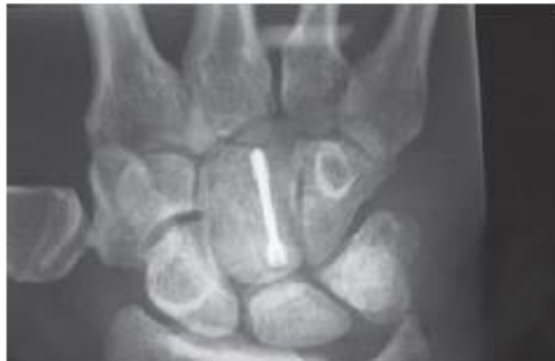(d)



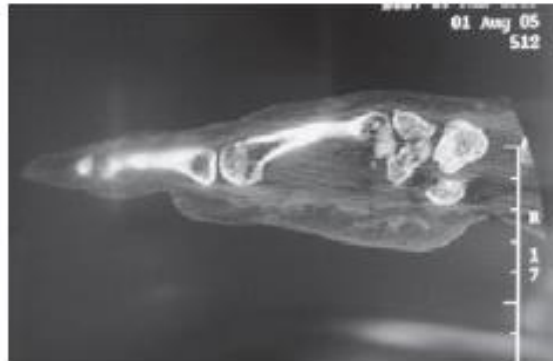(e)



(f)



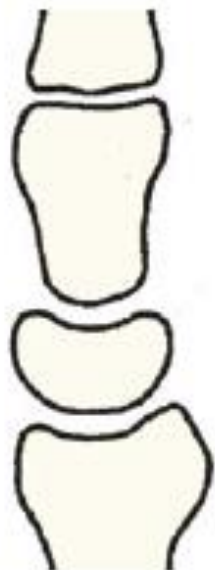(g)



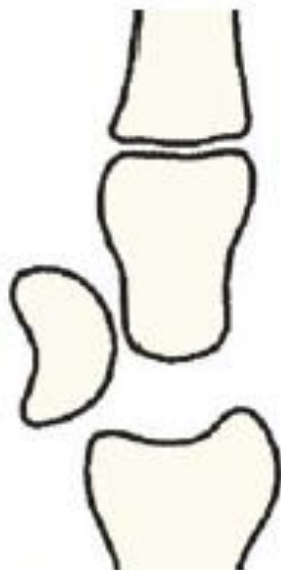(h)

**25.24 Fractures of other carpal bones** (a) Fracture of body of trapezium; (b) lunate fracture; (c) lunate fracture; (d) hook of hamate; (e) hook of hamate CT; (f) capitate fracture fixed (g) with a screw; (h) fracture of body of hamate.

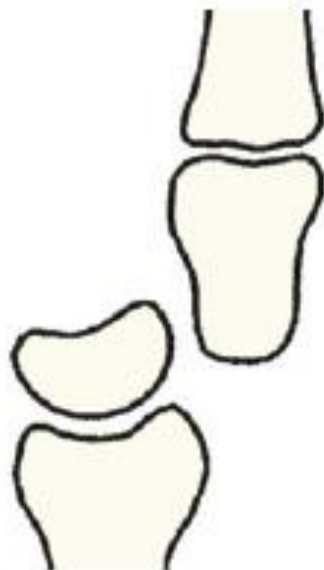




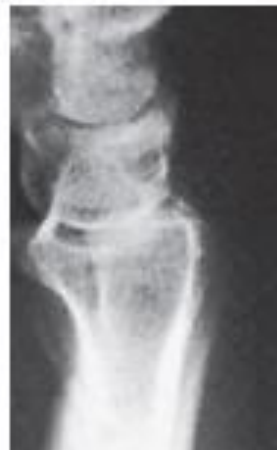(a)



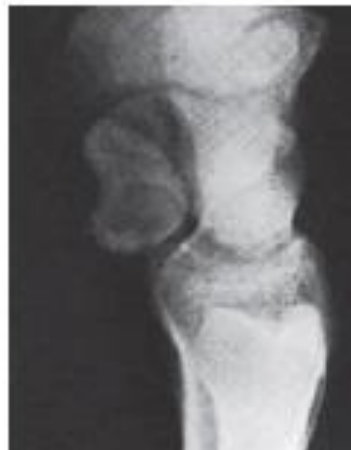(c)



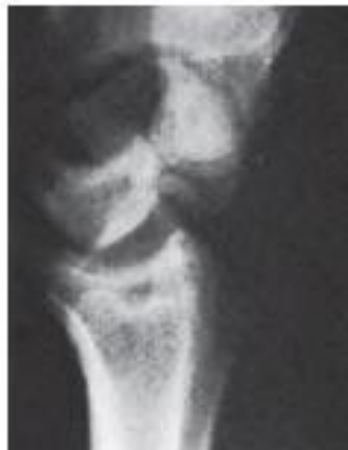(e)



(b)



(d)

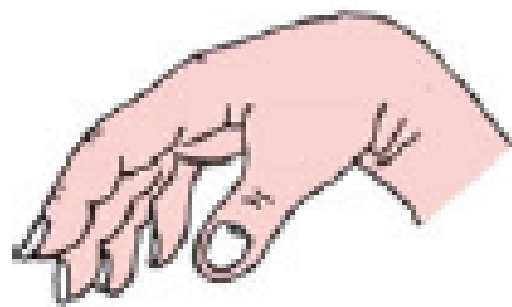


(f)

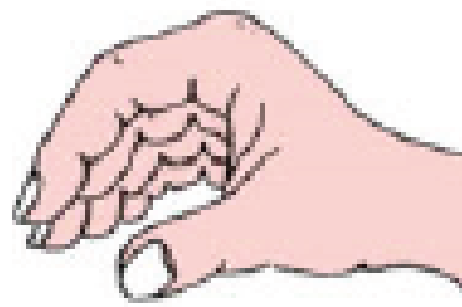
### 25.25 Lunate and perilunate dislocations.

(a,b) Lateral x-ray of normal wrist; (c,d) lunate dislocation; (e,f) perilunate dislocation.





(a)

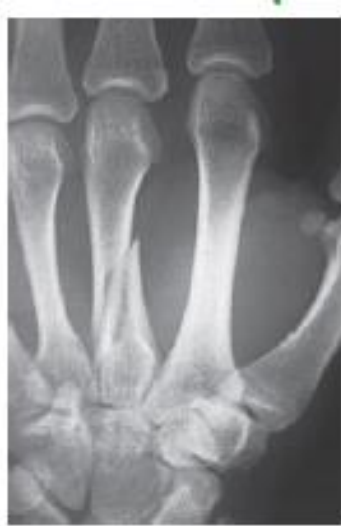

(b)

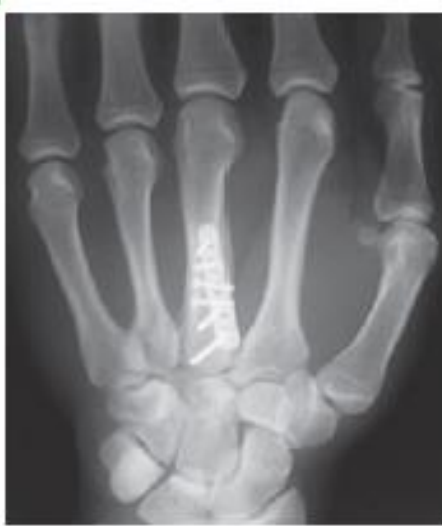

(c)

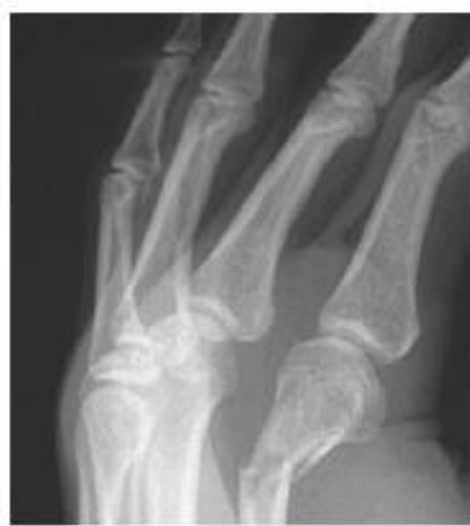**26.1 Splintage of the hand** Three positions of the hand:  
(a) The position of relaxation, (b) the position of function (ready for action) and (c) the position of safe immobilization, with the ligaments taut.



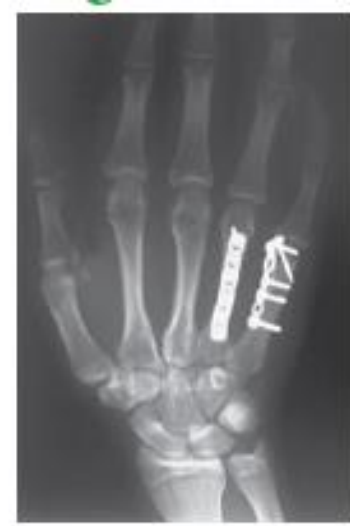(a)



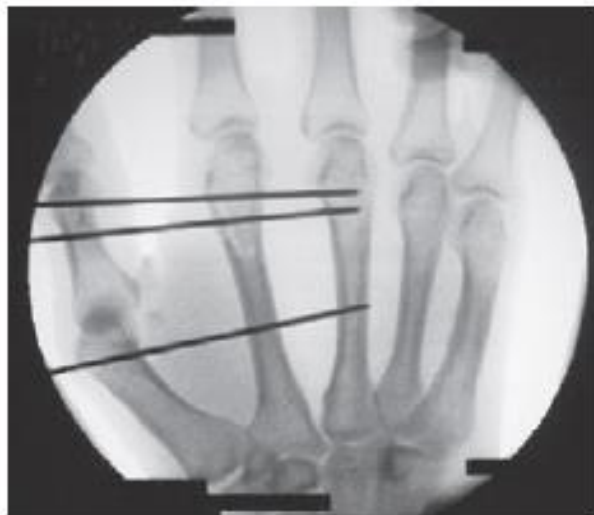(b)



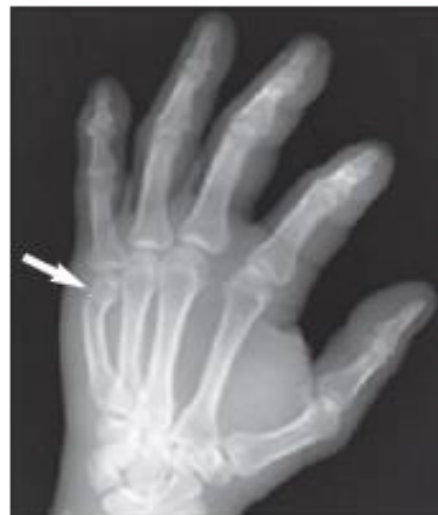(c)



(d)

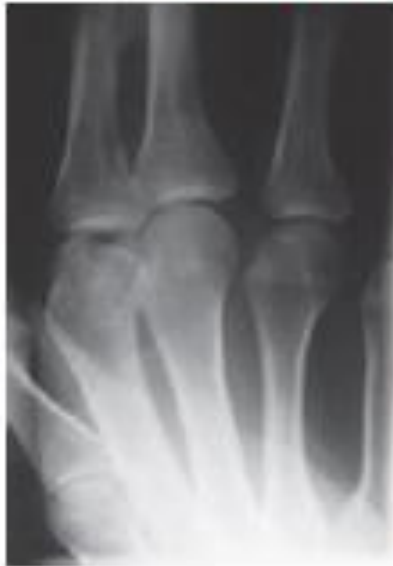

(e)

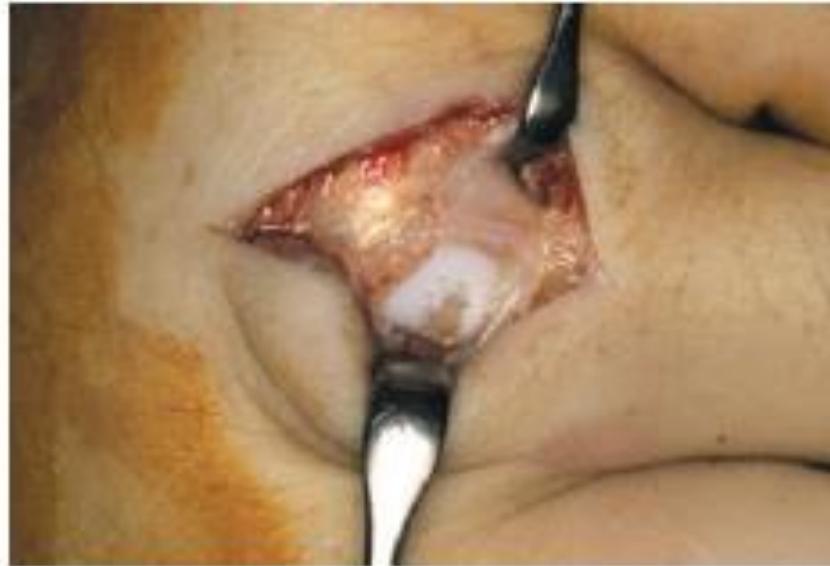

(f)

**26.2 Metacarpal fractures** (a) A spiral fracture (especially an 'inboard' one) can be adequately held by the surrounding muscles and ligaments but internal fixation (b) allows early mobilization. A displaced fracture (c), especially an 'outboard' one, can be held by a plate or transverse wires to allow early mobilization (d); multiple metacarpal fractures should be fixed with rigid plates for wires (e). A boxer's fracture (f) should be treated by early mobilization.

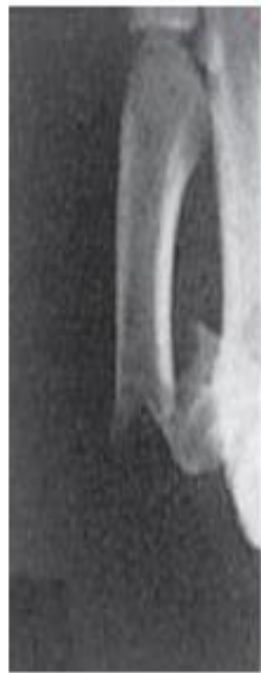

(a)

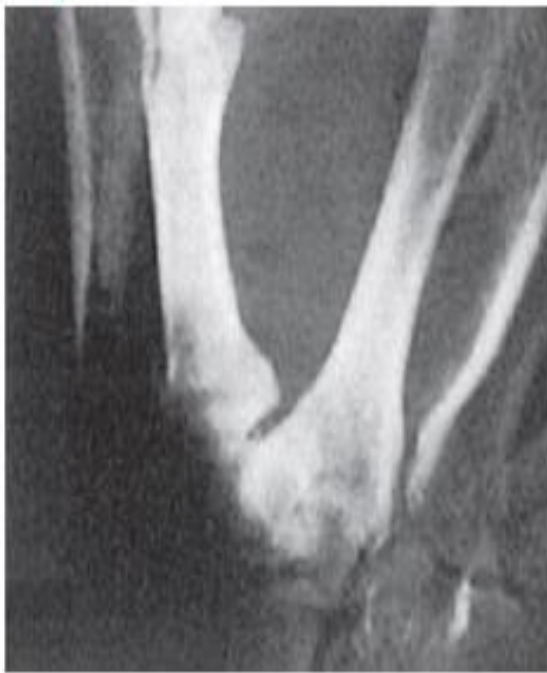

(b)

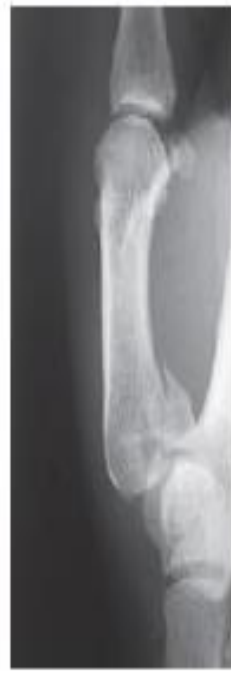**26.3 Fracture of the metacarpal head** (a) Depressed head fracture which was reduced and held with buried mini-screws. (b) A 'fight-bite', with metacarpal head damage from an opponent's tooth.



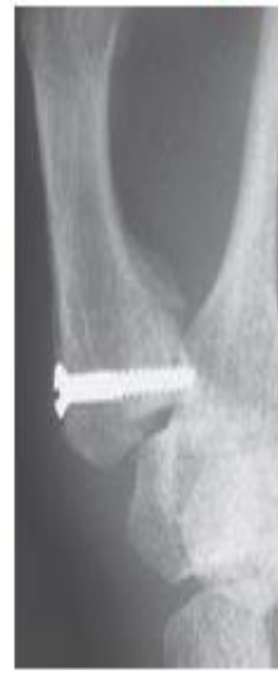(a)



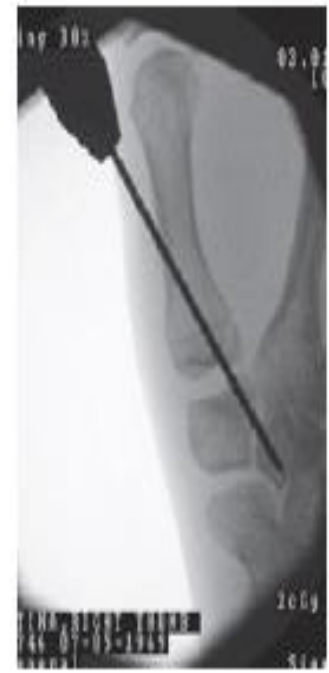(b)



(c)

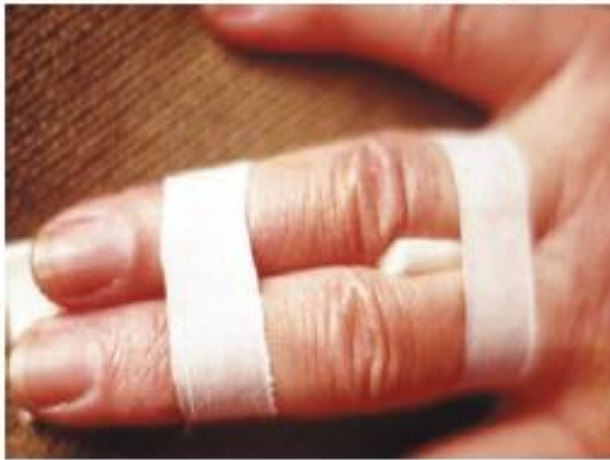

(d)

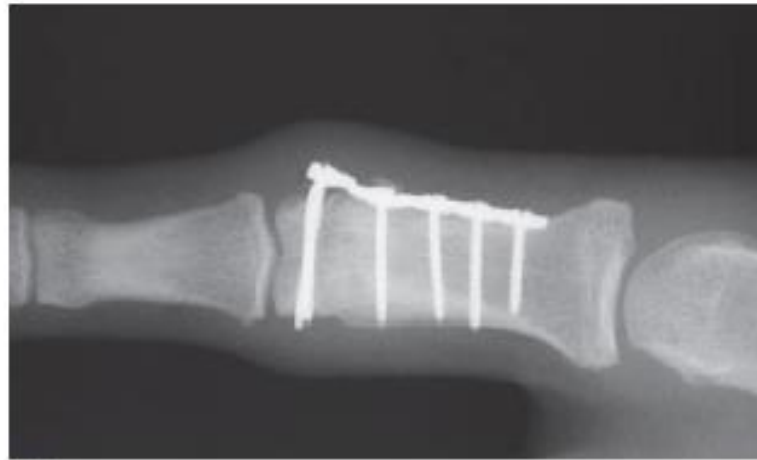


(e)

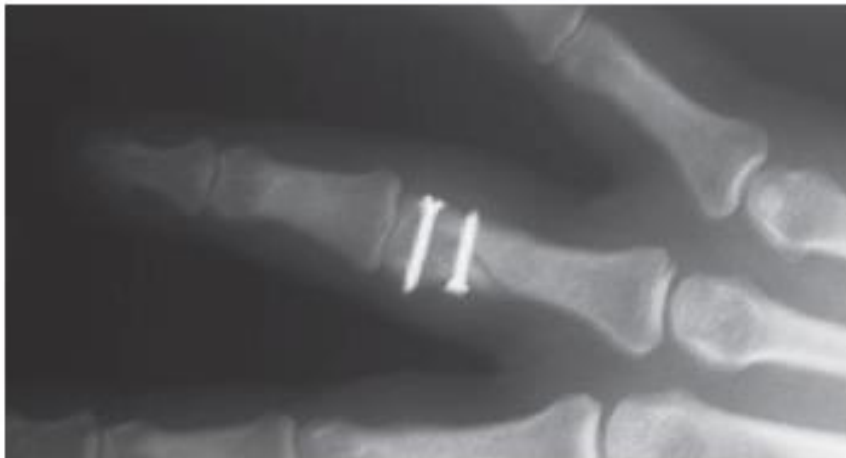**26.4 Fractures of the first metacarpal base** A transverse fracture (a) can be reduced and held in plaster (b). Bennett's fracture-dislocation (c) is best held with a small screw (d) or a percutaneous K-wire (e).



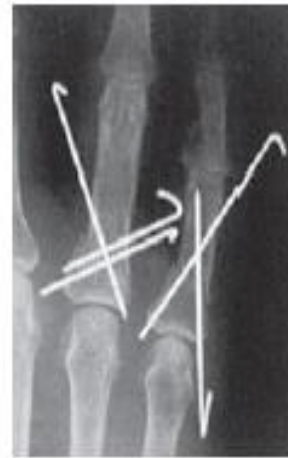(a)



(b)



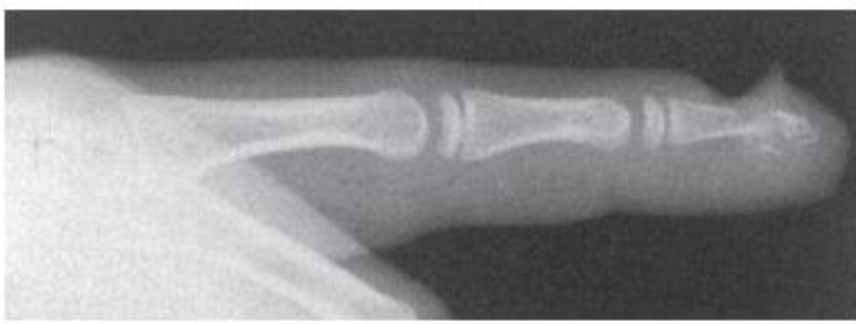(c)



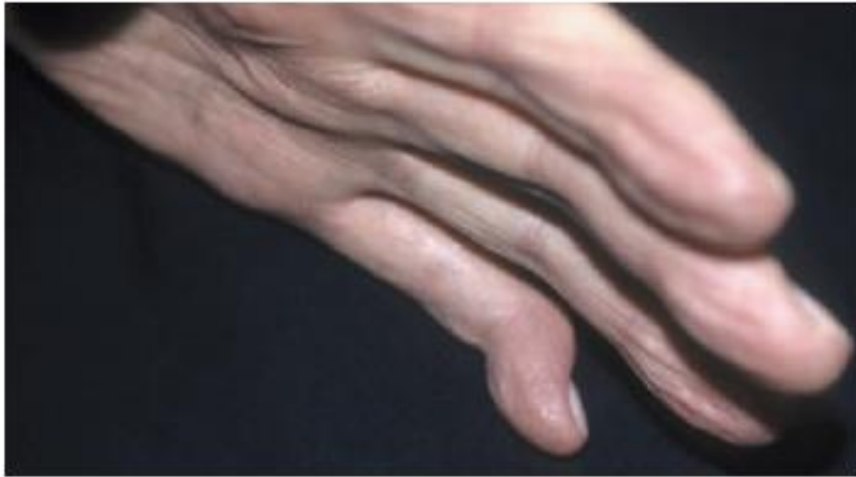(d)

**26.5 Phalangeal fractures** These can be treated, depending on the 'personality' of the fracture, experience of the surgeon and equipment available, with neighbour strapping (a), plate fixation (b), percutaneous screw fixation (c) or percutaneous wires (d).

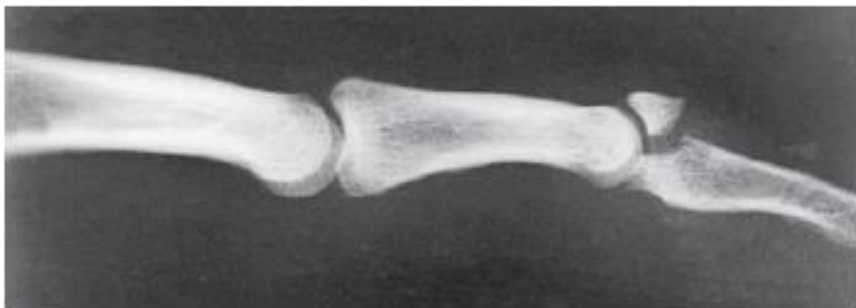



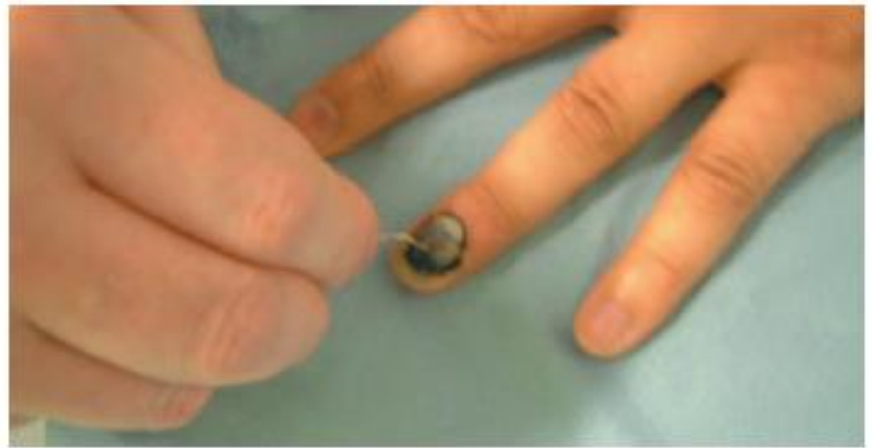(a)



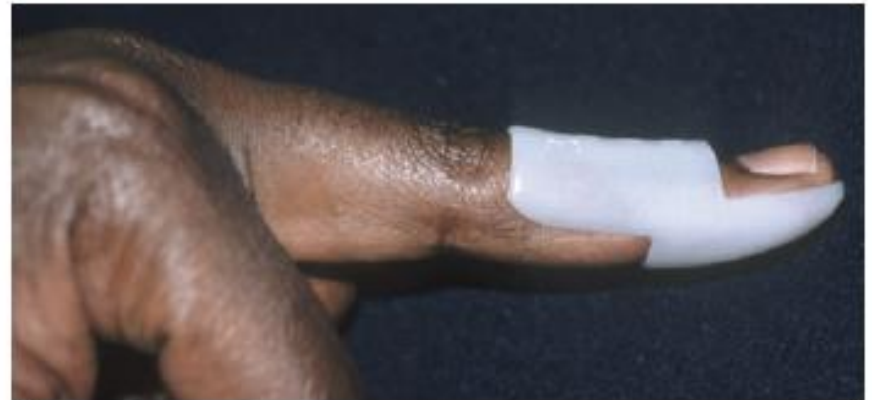(c)



(e)

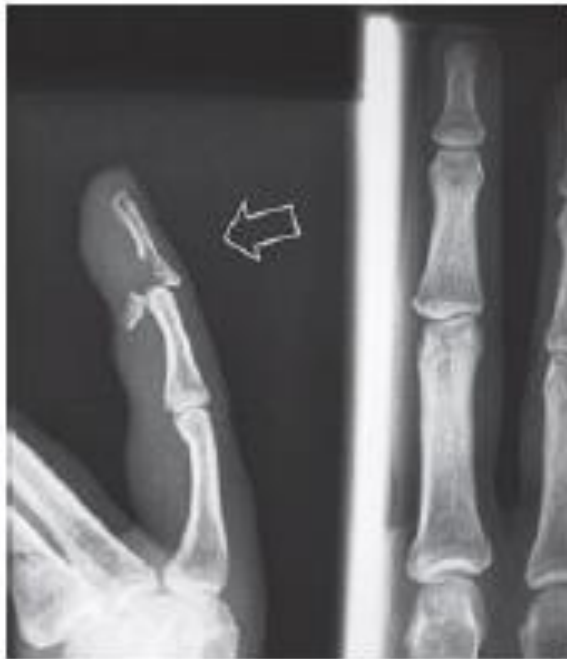

(b)

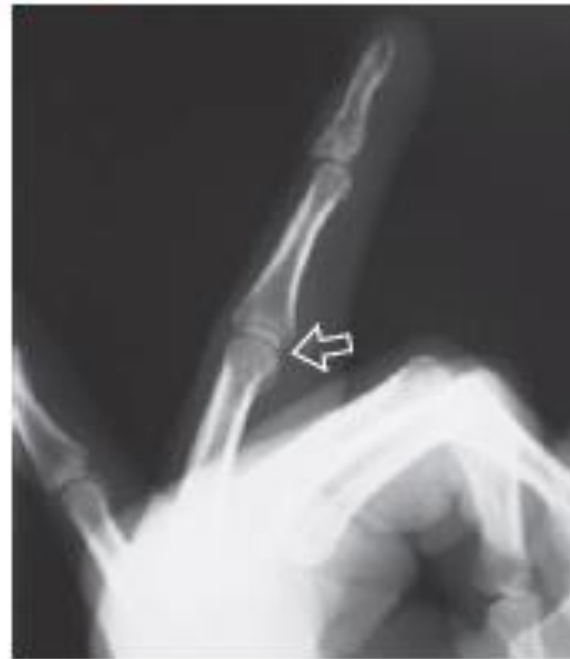

(d)

**26.6 Distal phalangeal injury** A fracture of the tuft (a), caused by a hammer blow, is treated by a protective dressing. The subungual haematoma should be evacuated using a red-hot paper clip tip (b) or a small drill. A mallet finger (c) is best treated with a splint for 6 weeks (d). Mallet fractures (e) are also better splinted – surgery can make the outcome worse.

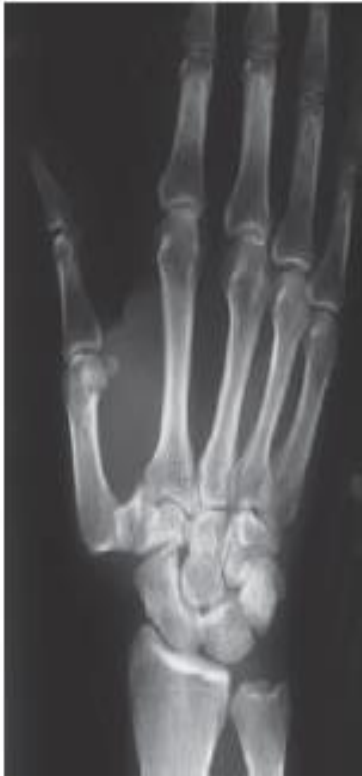

(a)

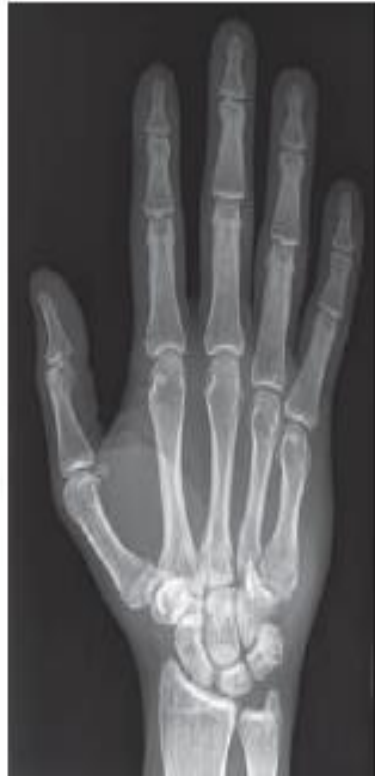

(b)

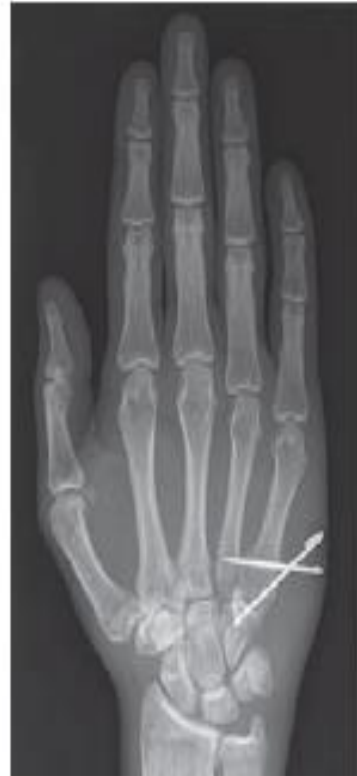**26.7 Flexor tendon avulsion** (a) Large fragment and (b) smaller fragment lodged in front of the PIP joint.



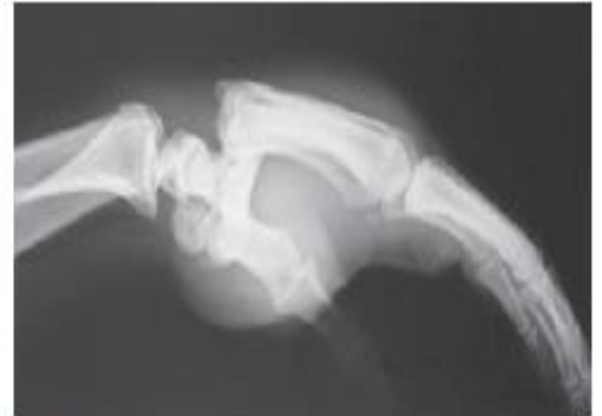(a)



(b)



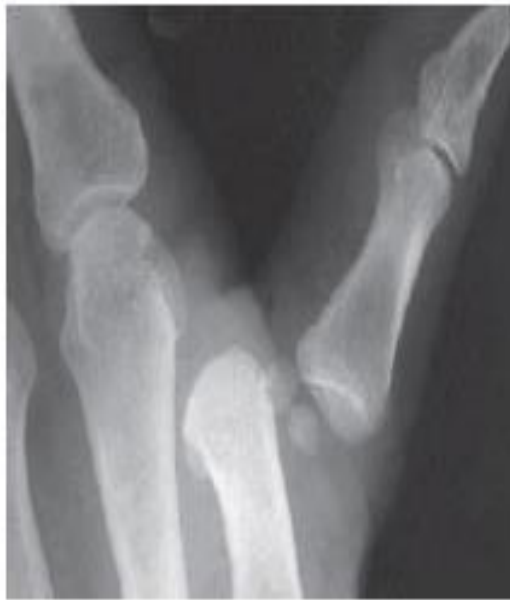(c)



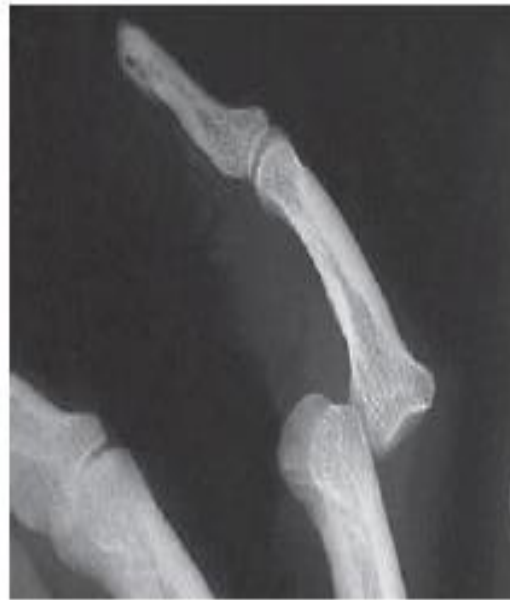(d)

### 26.8 Carpo-metacarpal dislocation

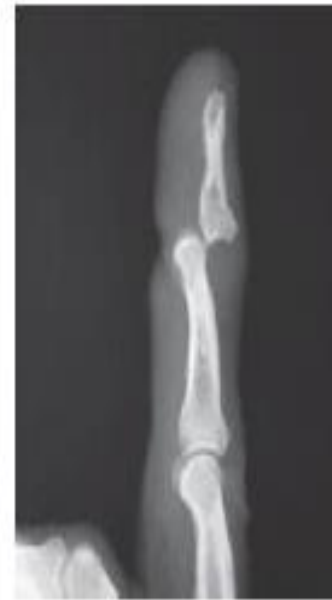(a) Thumb dislocation. (b) Dislocation of the fourth and fifth CMC joints treated by closed reduction and K-wires (c). Complete carpo-metacarpal dislocation (d).



(a)



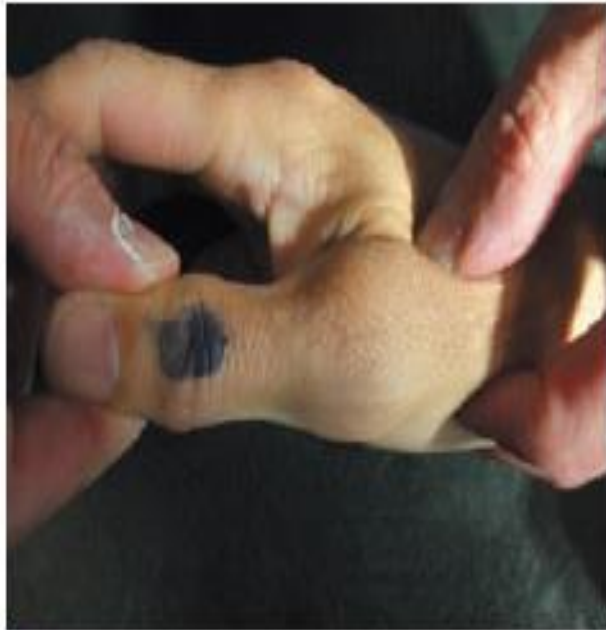(b)



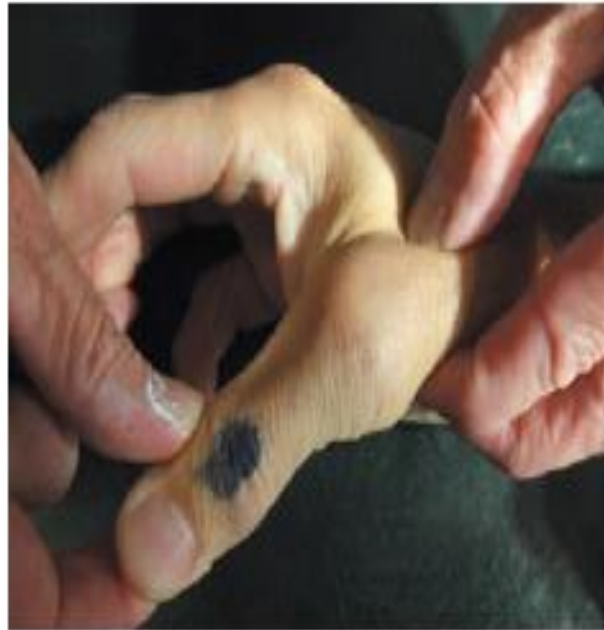(c)

## 26.9 Finger dislocation (a)

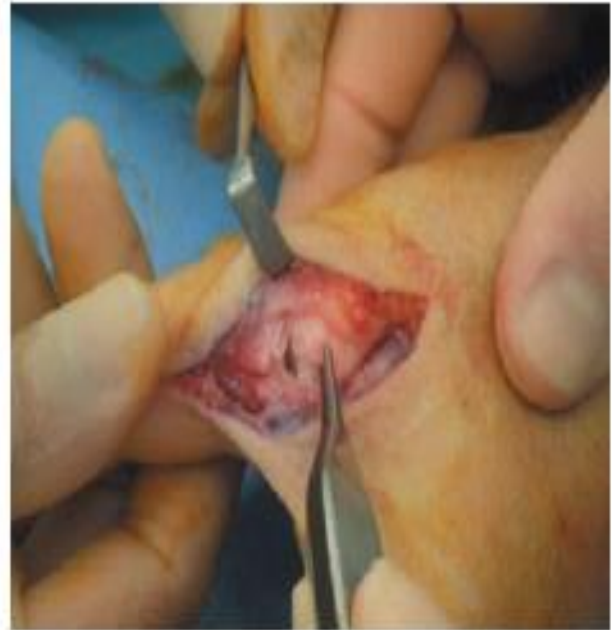Metacarpo-phalangeal dislocation in the thumb occasionally buttonholes and needs open reduction; (b,c) interphalangeal dislocations are easily reduced (and easily missed if not x-rayed!).



(a)



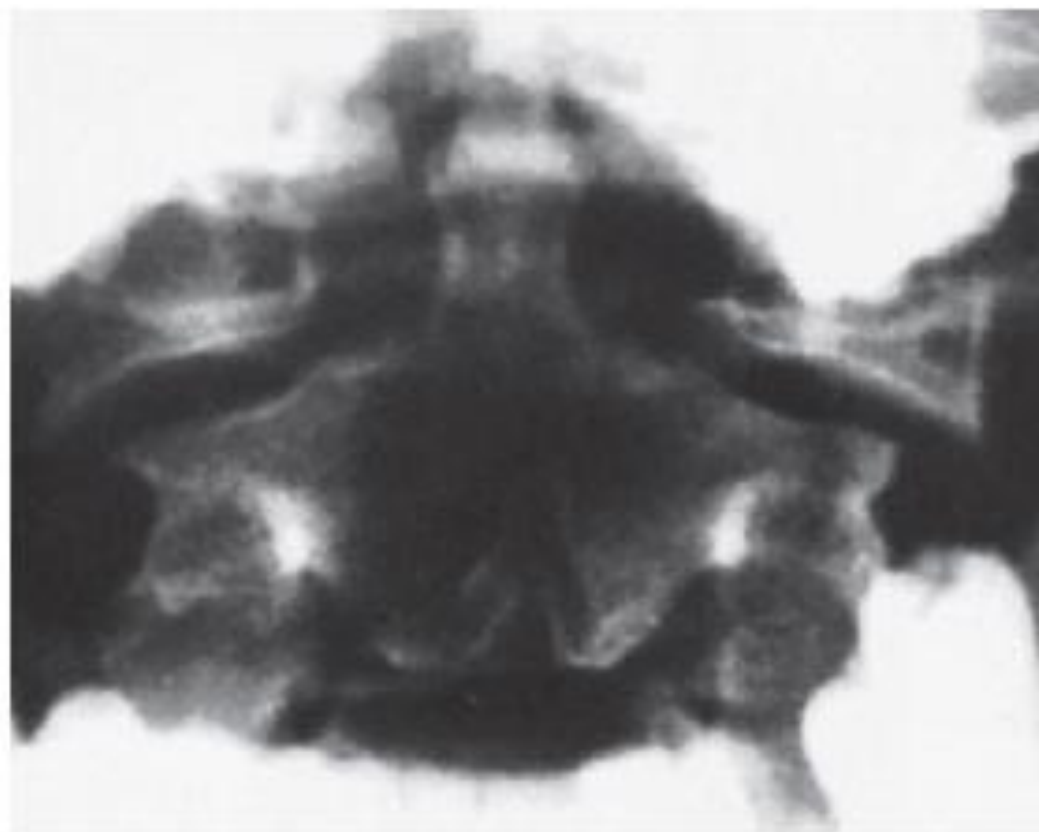
(b)



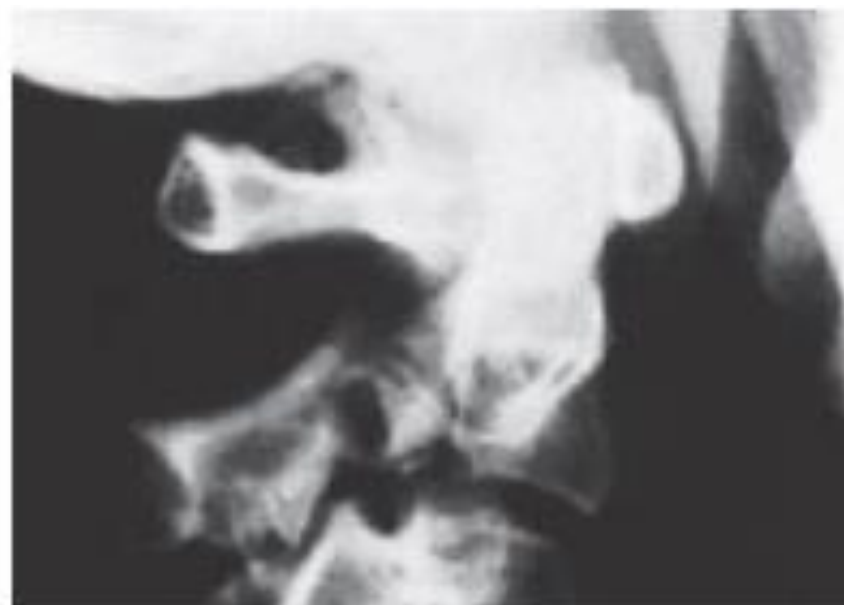(c)

**26.10 Skier's thumb** (a,b) The ulnar collateral ligament has ruptured. Urgent repair is indicated (c).

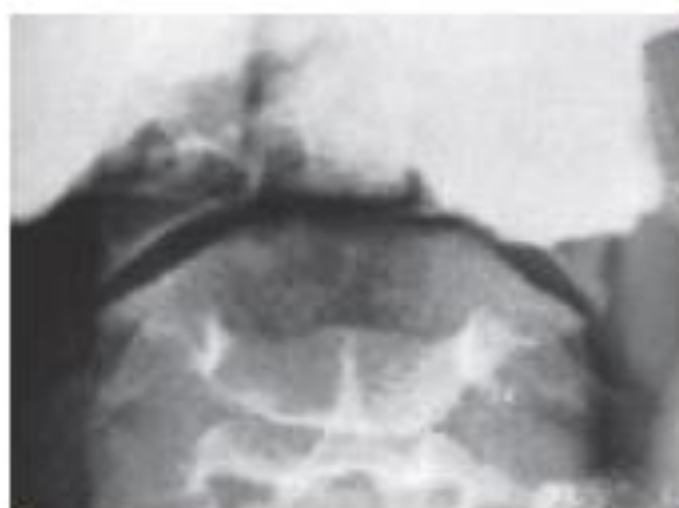



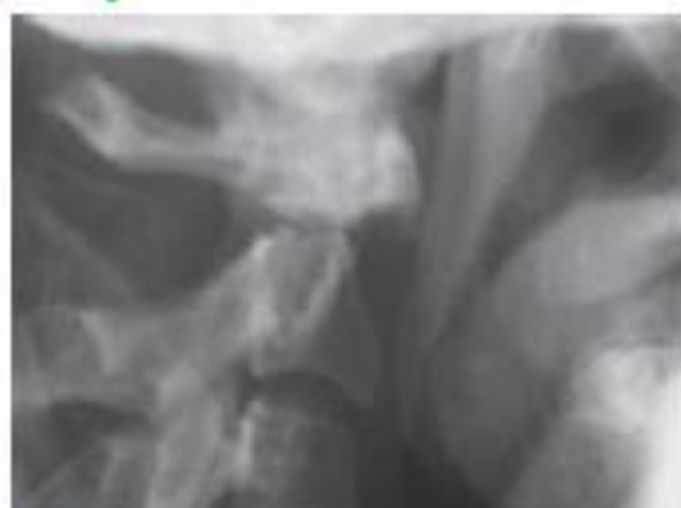**27.12 Fracture of C1 ring** Jefferson's fracture – bursting apart of the lateral masses of C1.



**27.13 Fracture of C2** 'Hangman's fracture' – fracture of the pars interarticularis of C2.

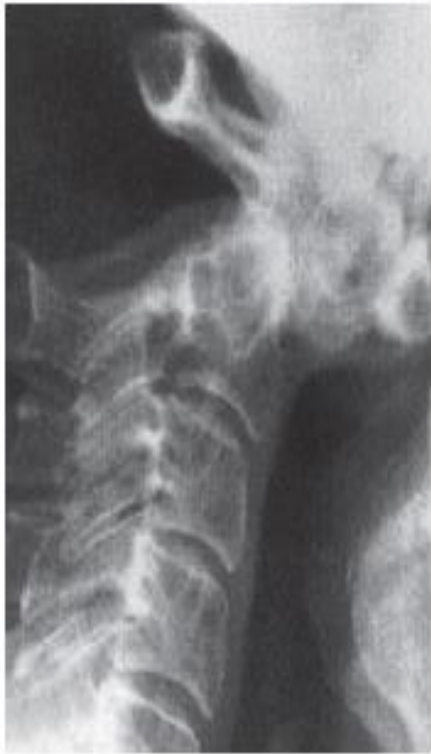

(a)

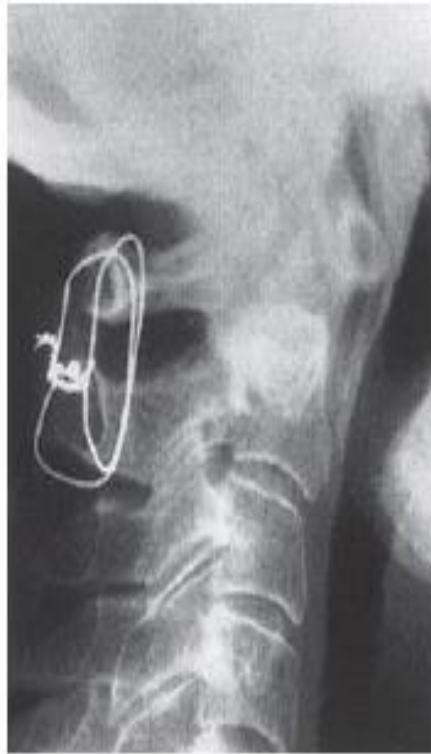

(b)

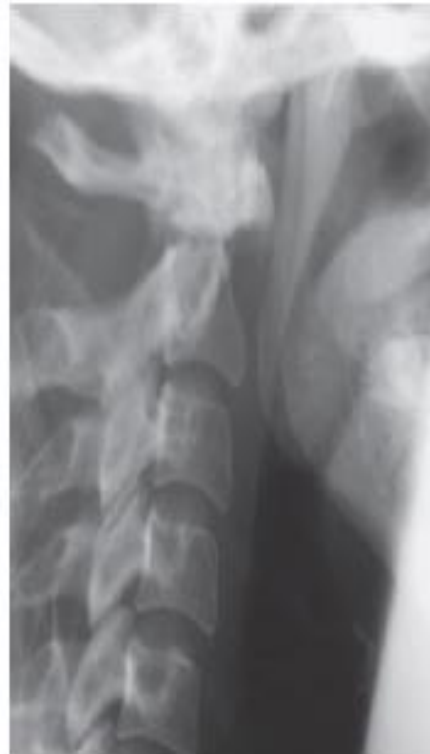**27.15 Fractured odontoid process** (a) Anteroposterior 'open-mouth' x-ray showing a Type II odontoid fracture. (b) Lateral x-ray of the same patient.



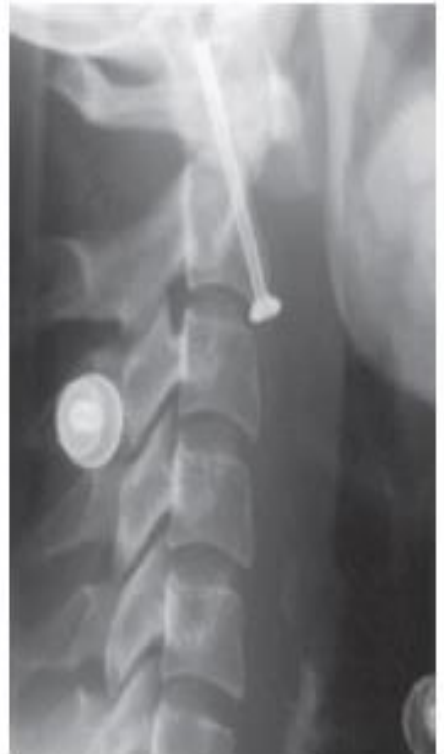(a)



(b)

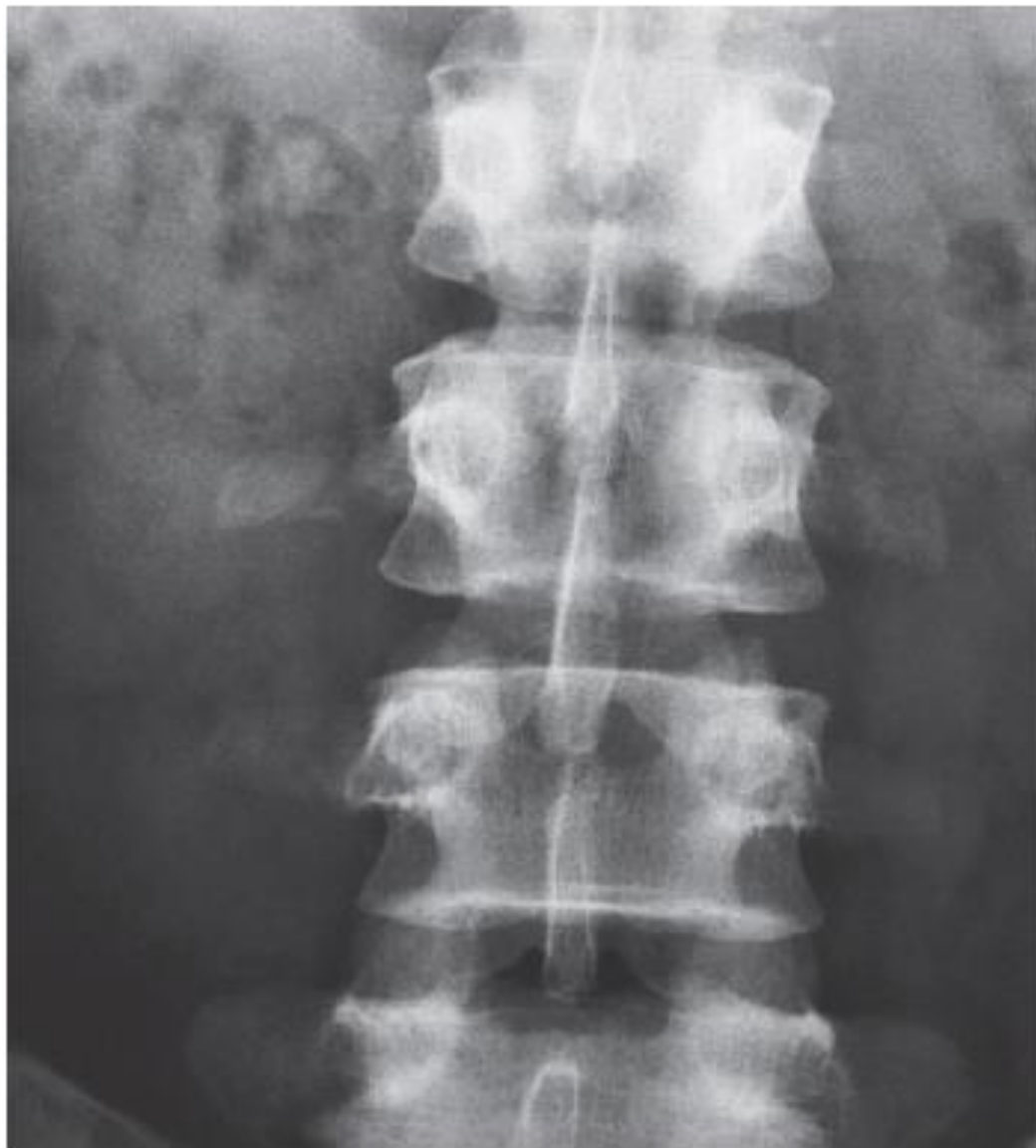

(c)



(d)

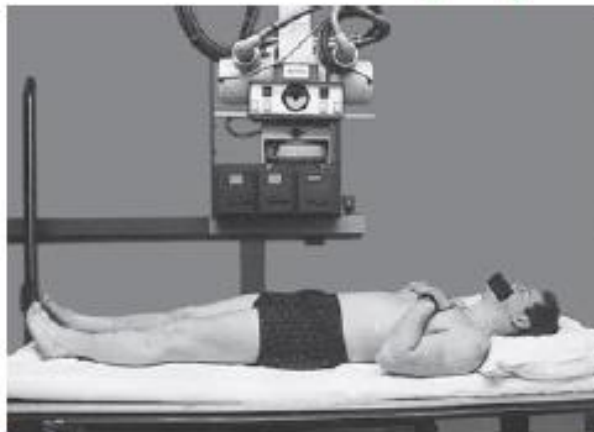
**27.16 Fractured odontoid – treatment** (a) A severely displaced Type II odontoid fracture. (b) The fracture was reduced by skull traction and held by fixing the spinous process of C1 to that of C2 with wires. (c) An undisplaced Type II fracture, which was suitable for (d) anterior screw fixation.



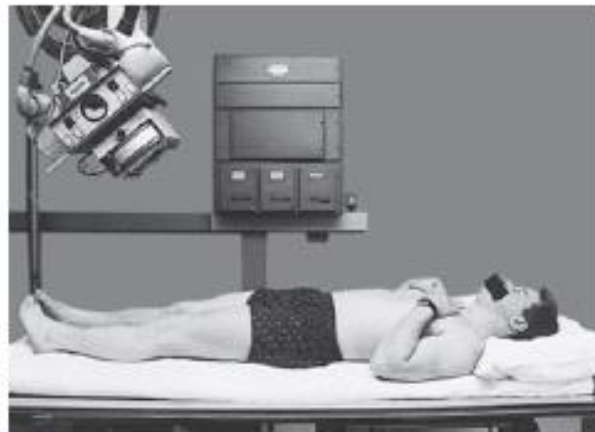
**27.24 Thoracolumbar injuries – minor fractures**

Fracture of the transverse processes on the right at L3 and L4.

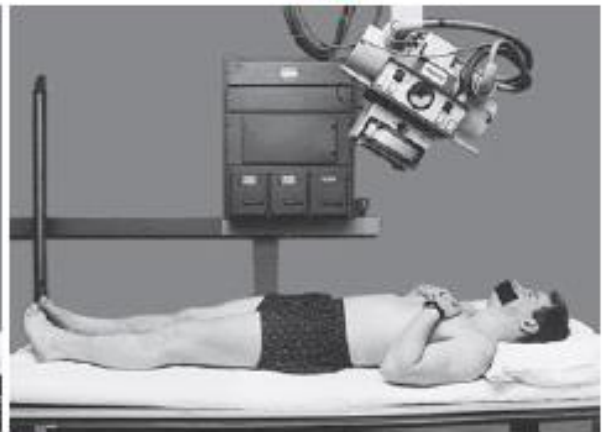




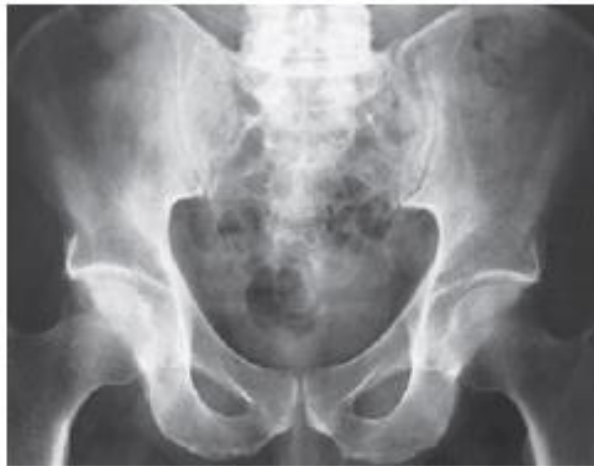(a)



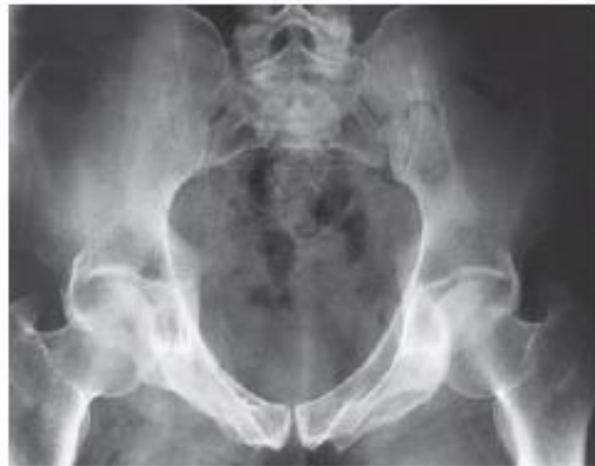(c)



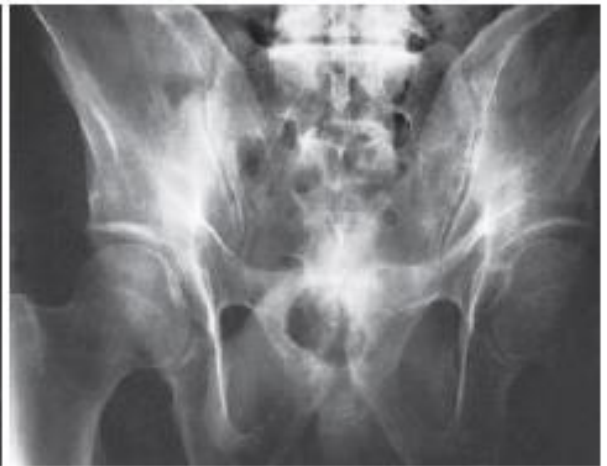(e)



(b)

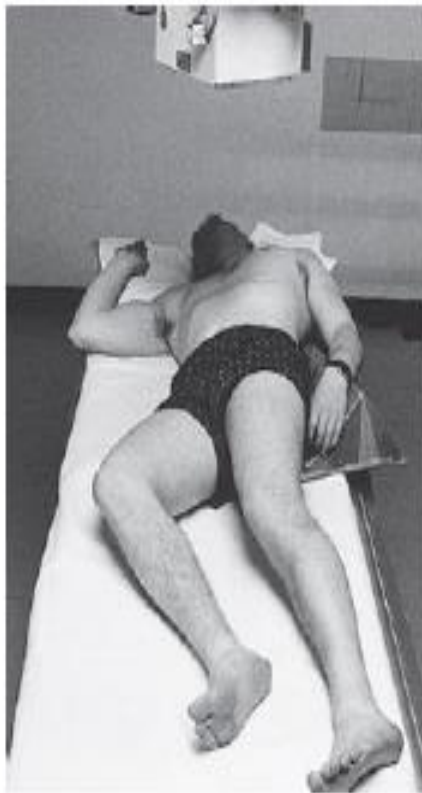

(d)

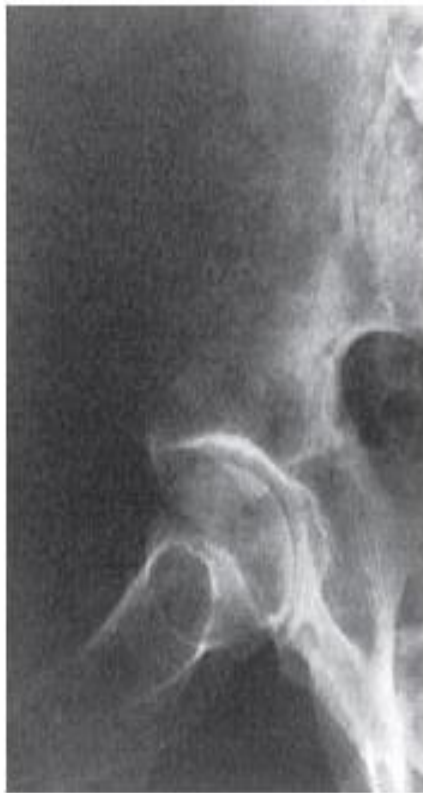

(f)

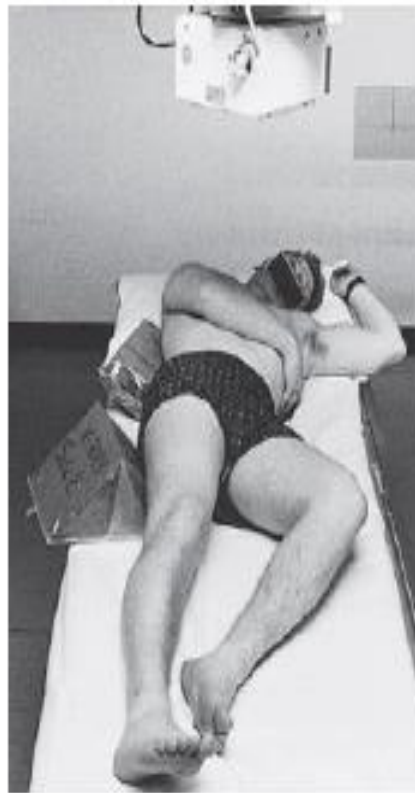**28.3 Pelvic fractures – x-ray diagnosis (1)** (a,b) The anteroposterior view is usually taken during the initial assessment of the multiply-injured patient as part of a 'trauma series'. It is useful in quickly diagnosing gross disruptions or fractures. The x-ray should be read systematically: Is the picture well centred? Look for asymmetry in the pubic symphysis, the pubic rami, the iliac blades, the sacroiliac joints and the sacral foramina. If the patient's condition permits, at least two additional views should be obtained: (c,d) an *inlet* view with the tube titled 30° downwards and (e,f) an *outlet* view with the tube titled 40° upwards.



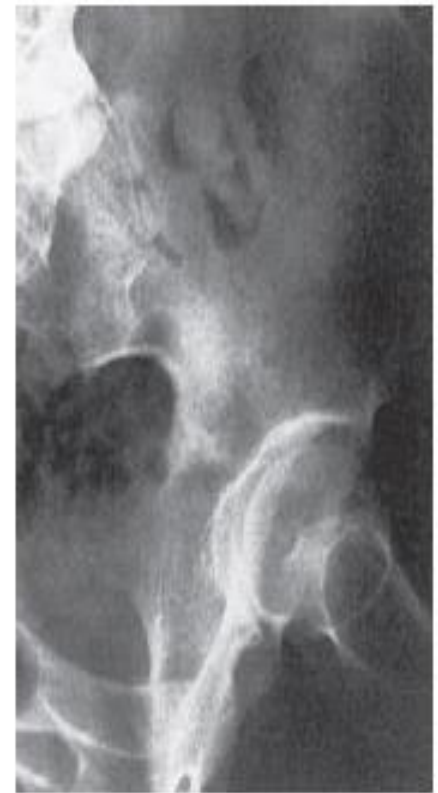(a)



(b)

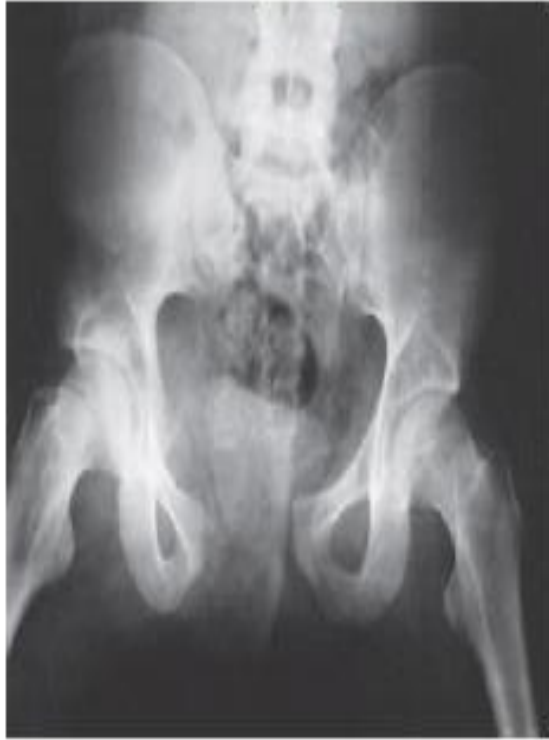

(c)

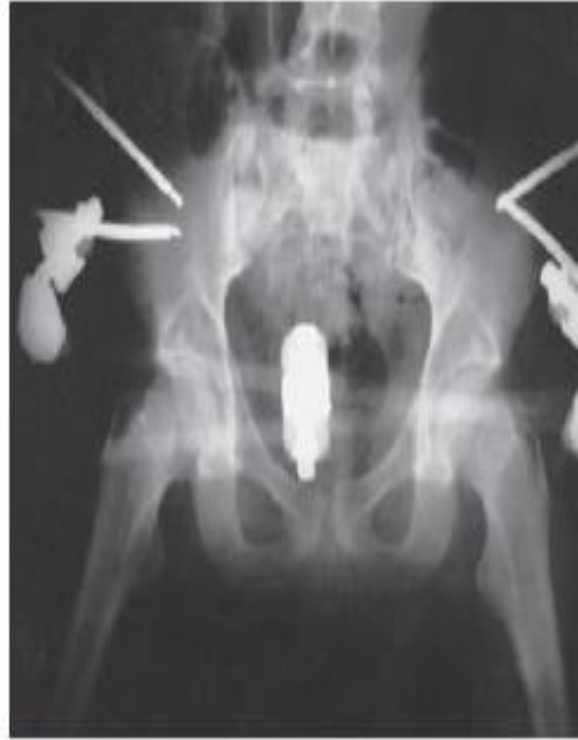

(d)

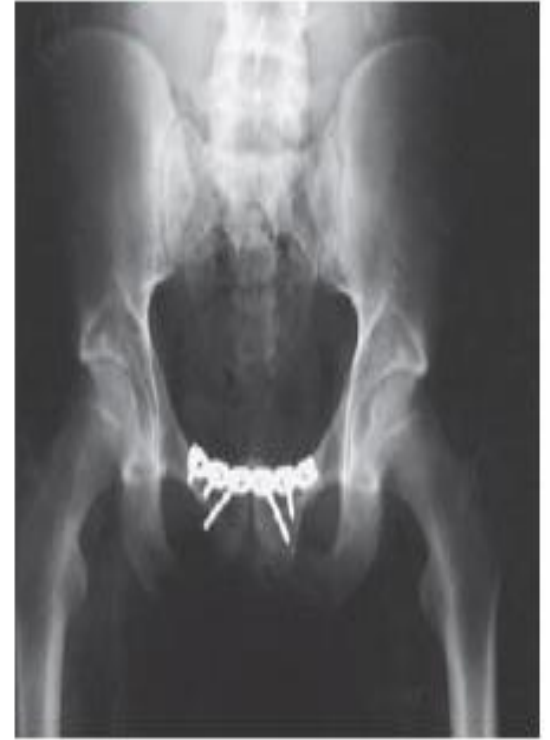**28.4 Pelvic fractures – x-ray diagnosis (2)** Oblique views are helpful for defining the ilium and acetabulum on each side. (a,b) the *right oblique* view; and (c,d) the *left oblique* view. These can be omitted if facilities for CT are available.



(a)

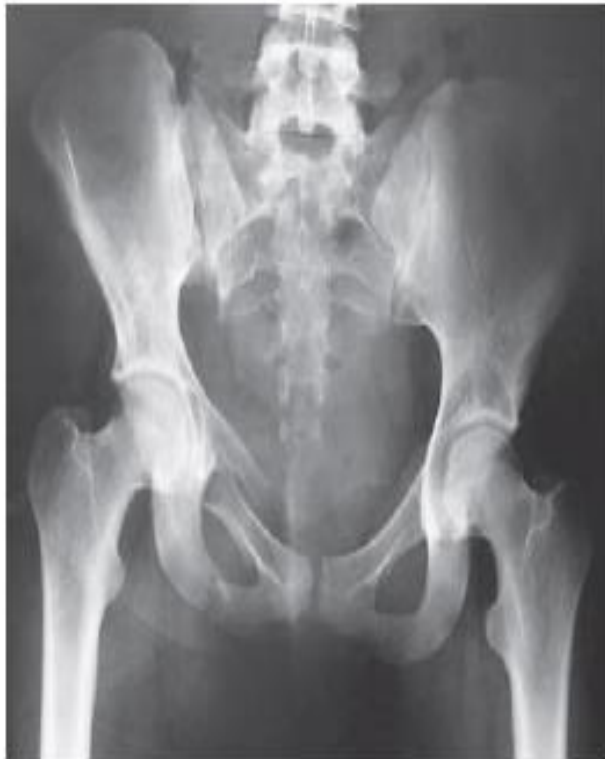

(b)

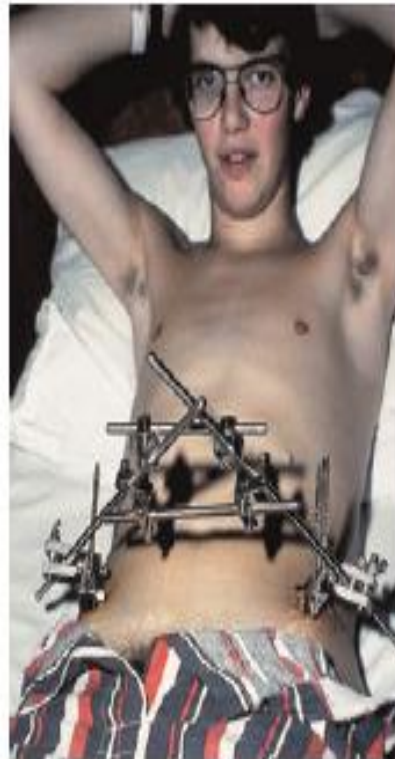

(c)

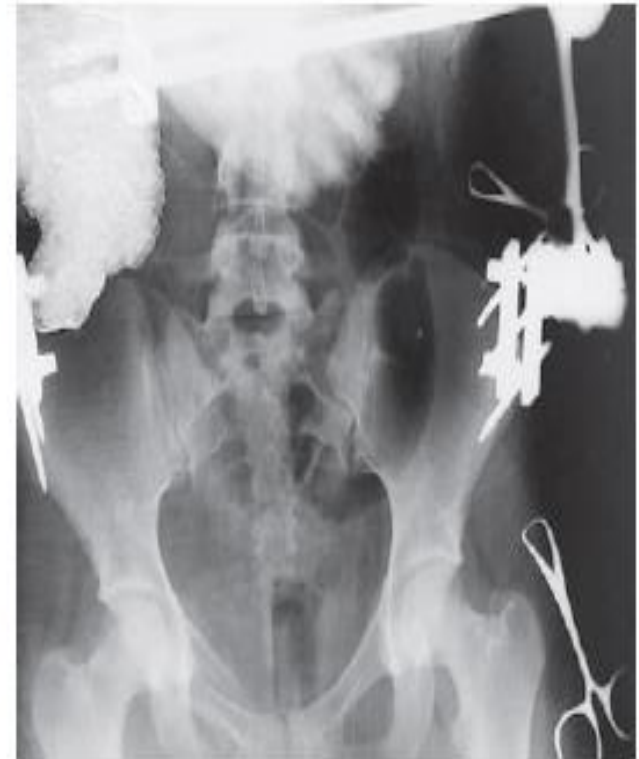**28.8 Internal fixation** (a) Severe open-book injury with complete disruption of the symphysis pubis. (b) Reduction and stabilization by external fixator. (c) The symphysis was then firmly held by internal fixation with a plate and screws.



(a)



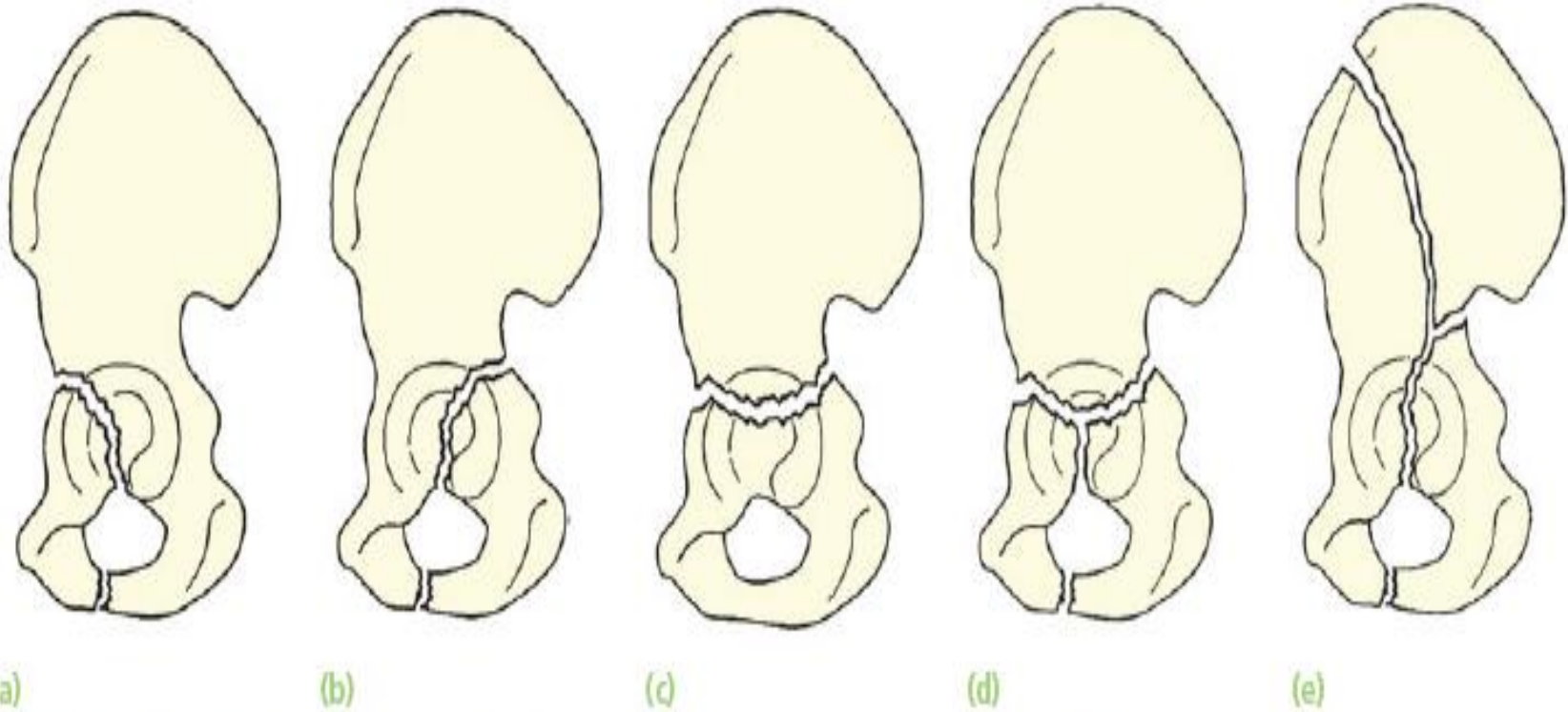
(b)



(c)

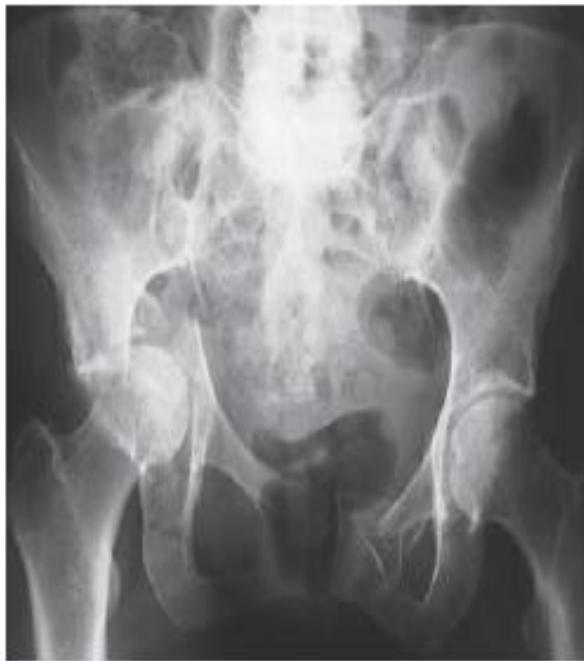**28.9 Treatment of vertical shear fracture** (a) X-ray showing a fractured superior pubic ramus and disruption of the right sacroiliac joint. (b) This was initially treated by traction and external fixation. (c) X-ray showing the pelvic ring restored. Thereafter, the sacroiliac joint was stabilized with plates and screws.



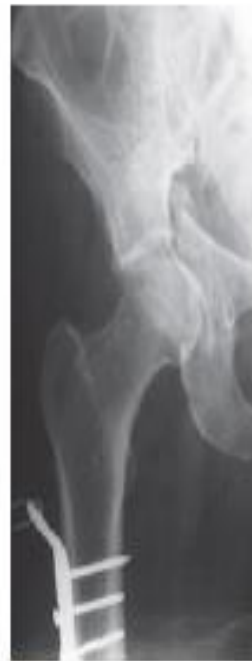

**28.11 The classification of acetabular fractures** There are four types of injury: (a,b) a simple fracture involving either the anterior or the posterior wall or column; (c) a transverse or (d) a T-type fracture involving two columns; (e) the both-column fracture, resulting in a 'floating' acetabulum with no part of the socket attached to the ilium (compare this with the transverse or T-type fractures).

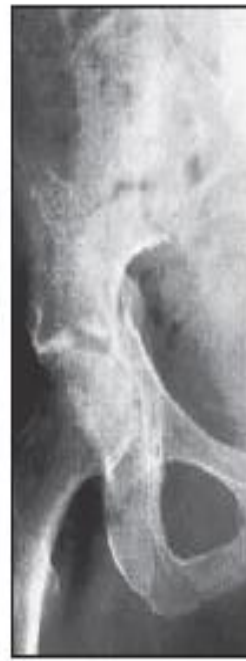



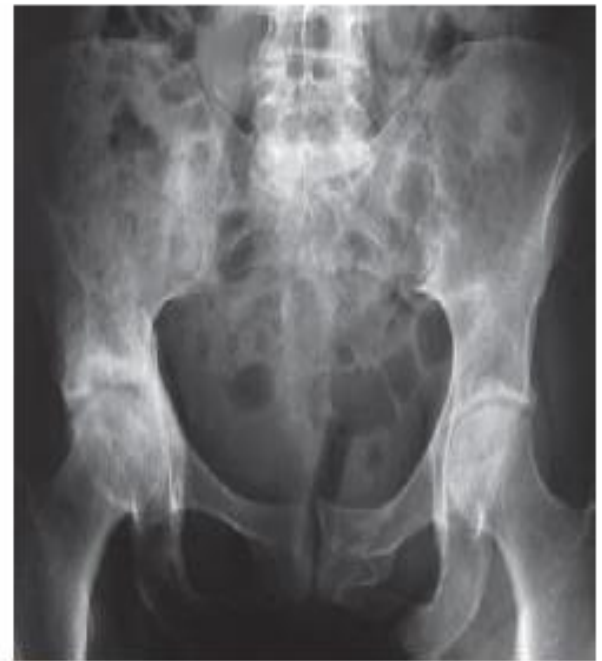(a)



(b)

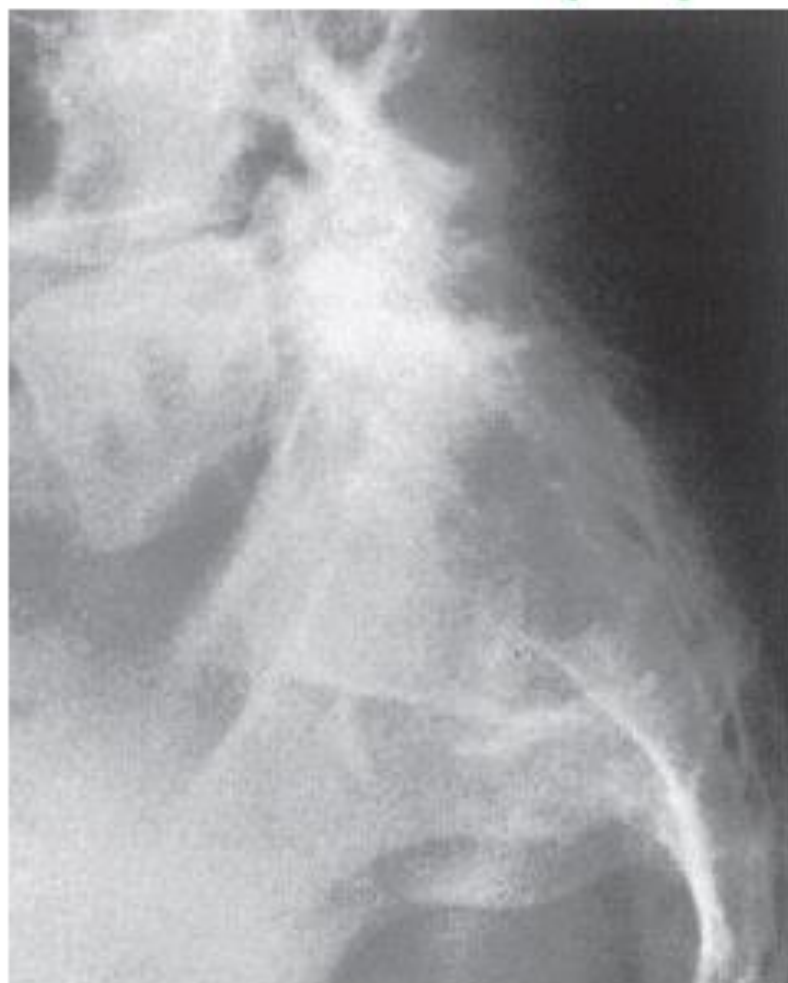

(c)

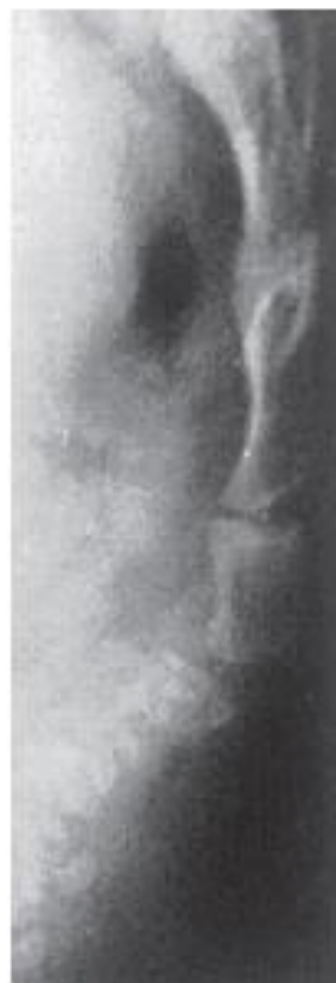

(d)

**28.13 Fractured acetabulum – conservative treatment** This severely displaced acetabular fracture (a) was almost completely reduced by (b) longitudinal and lateral traction. (c) The fracture healed and the patient regained a congruent joint with a fairly good range of movement. (d) X-ray two years later.

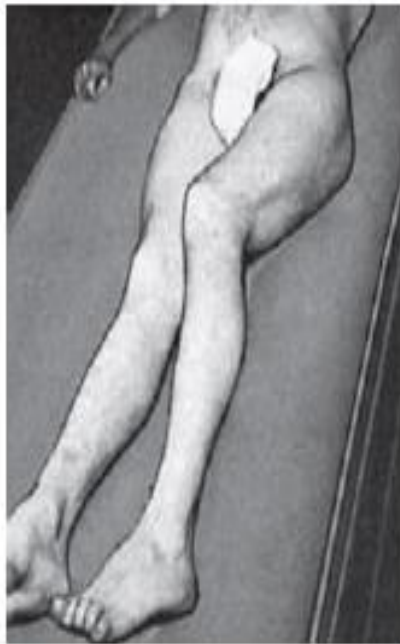

(a)

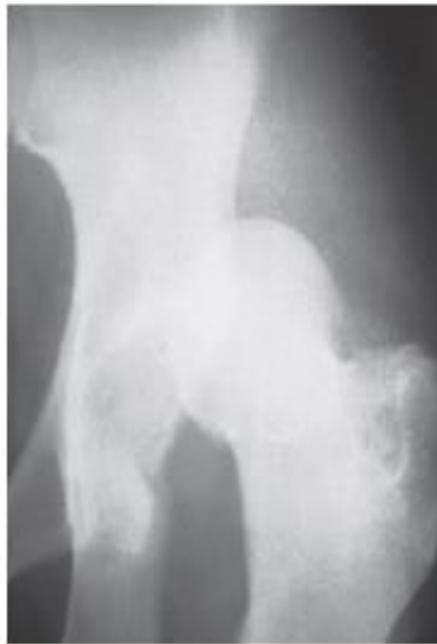

(b)

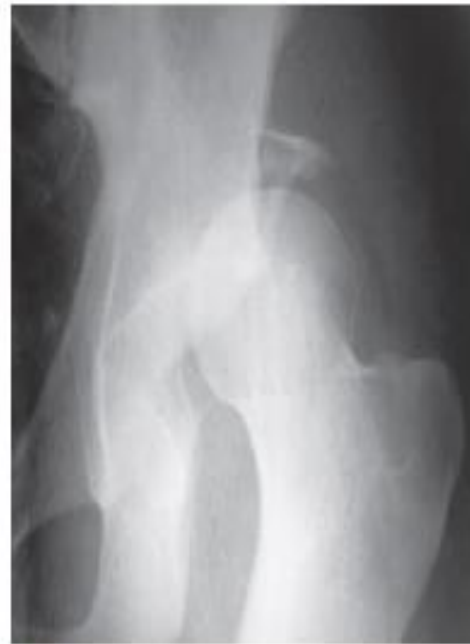**28.15 Sacrococcygeal fractures** (a) Fractured sacrum;  
(b) fractured coccyx.



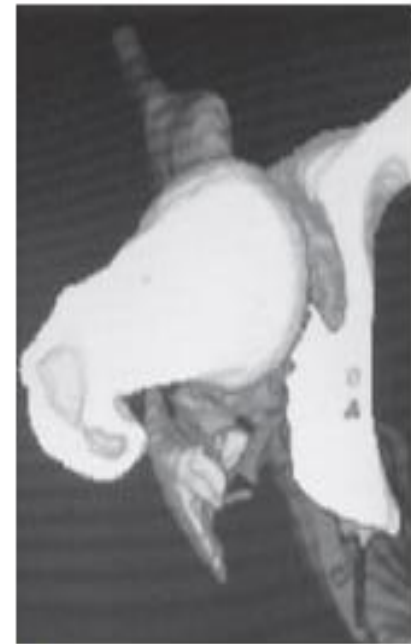(a)



(b)





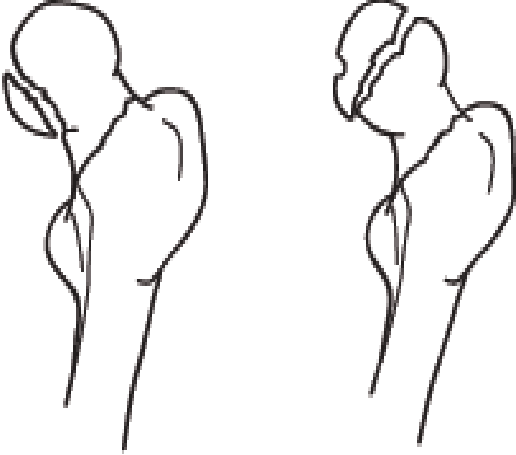
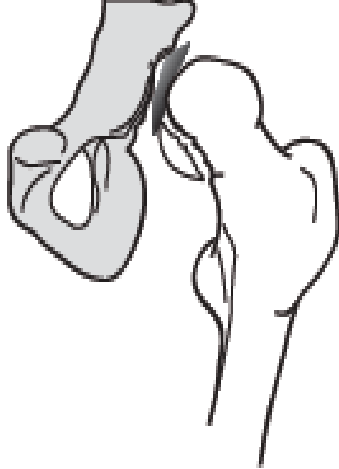
(c)

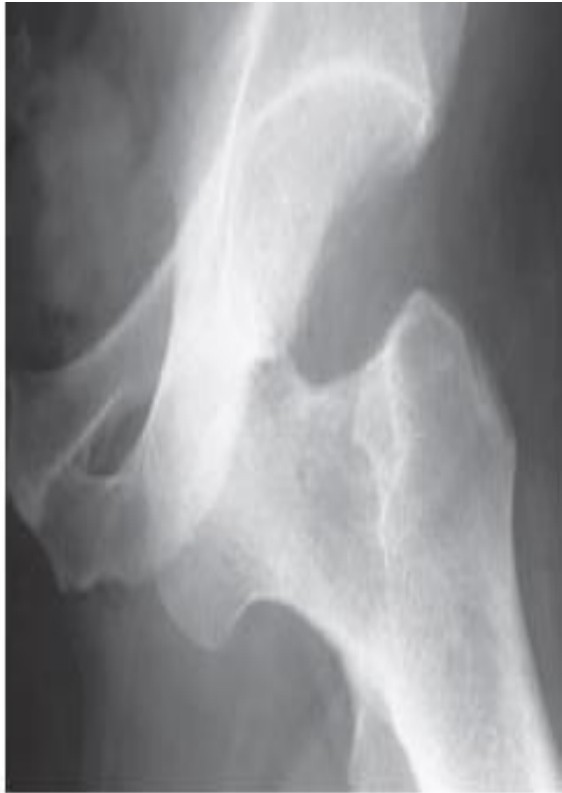

(d)

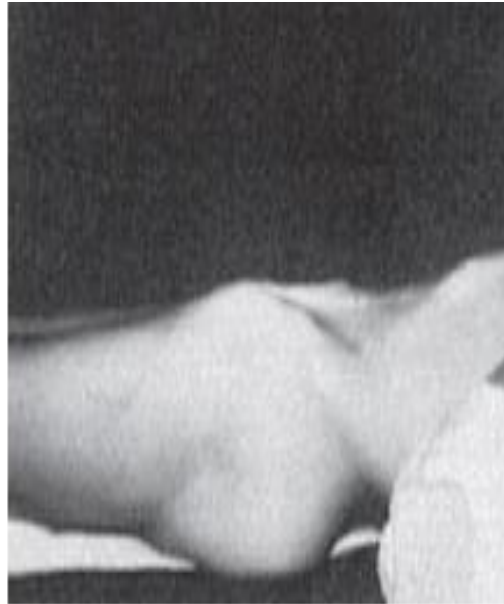**29.1 Posterior dislocation of the hip** (a) This is the typical posture in a patient with posterior dislocation: the left hip is slightly flexed and internally rotated. (b) The x-ray in this case showed a simple dislocation, with the femoral head lying above and behind the acetabulum. (c) Another patient with dislocation and an associated acetabular rim fracture. However, in some cases it may need a CT scan and three-dimensional image reconstruction to appreciate the full extent of the associated acetabular injury (d).

## Pipkin classification of femoral head fractures

			
Type I	Type II	Type III	Type IV
The fracture line is inferior to the fovea	The fracture fragment includes the fovea	As with types I and II but with an associated femoral neck fracture	Any pattern of femoral head fracture and an acetabular fracture (coincides with Thompson and Epstein's type V)



(a)

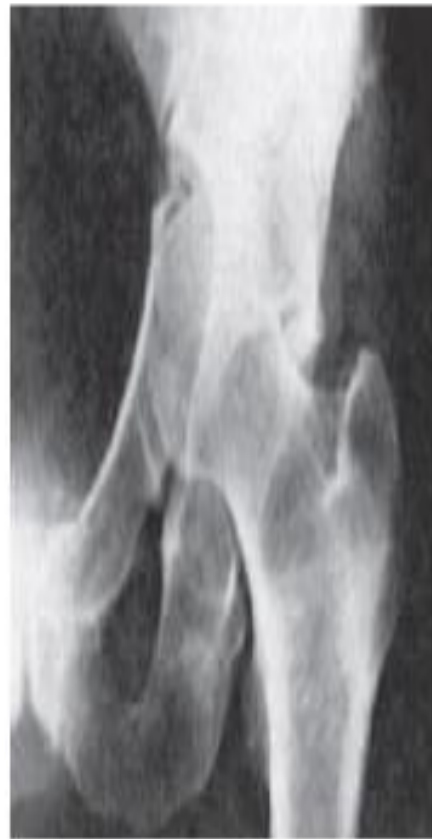

(b)

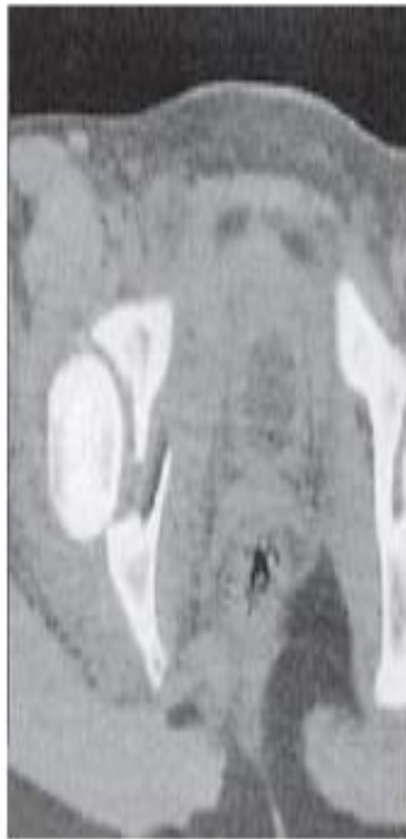
### 29.3 Anterior hip dislocation (a,b)

The usual appearance of an anterior dislocation: the hip is only slightly abducted and the head shows clinically as a prominent lump.

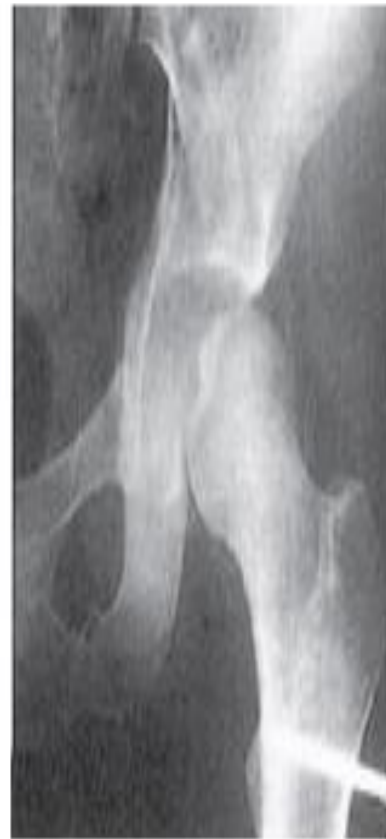



(a)



(b)

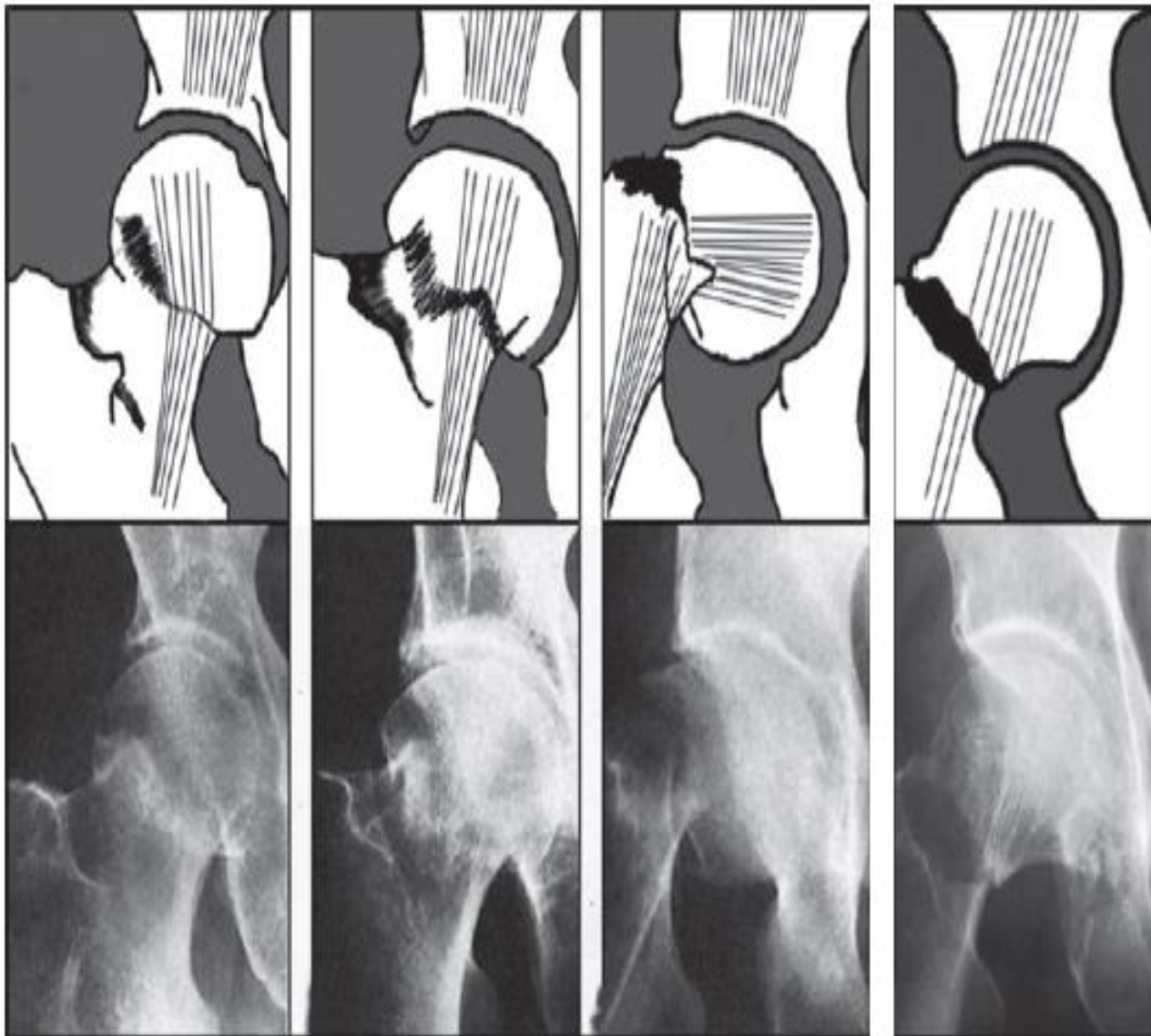


(c)

## 29.4 Central dislocation

(a) The plain x-ray gives a good picture of the displacement, but (b) a CT scan shows the pelvic injury more clearly.

(c) Skeletal traction, which often needs both longitudinal and lateral vectors, is an effective method of reduction.



(a)

(b)

(c)

(d)

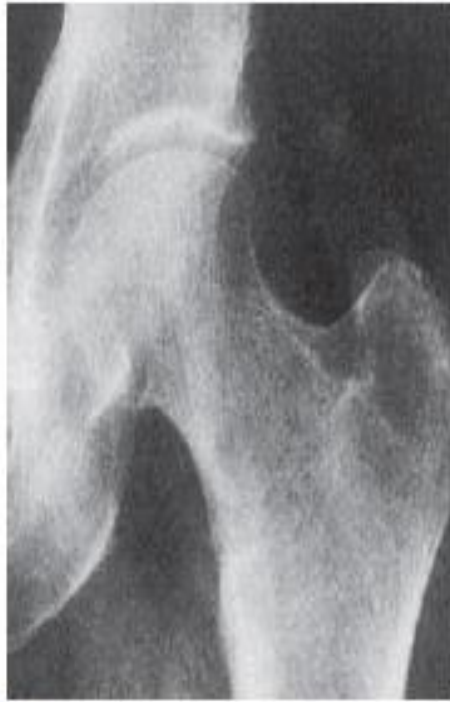## 29.5 Garden's classification of femoral neck fractures

(a) *Stage I*: incomplete (so-called abducted or impacted) – the femoral head in this case is in slight valgus.

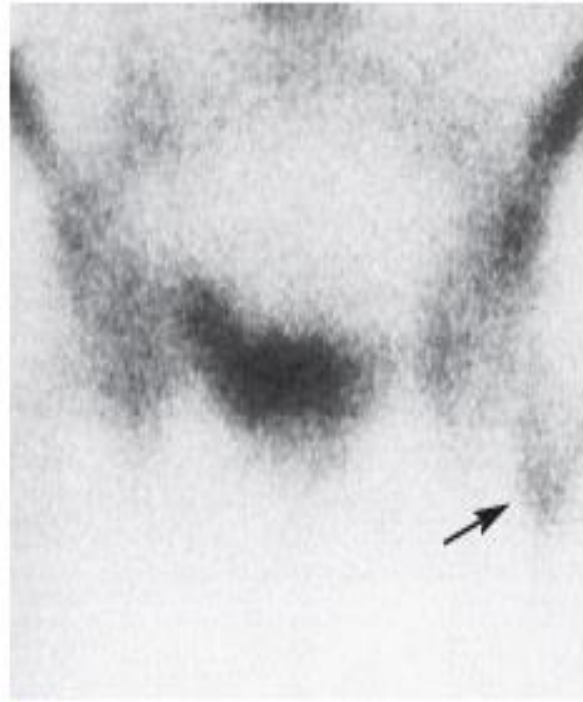(b) *Stage II*: complete without displacement.

(c) *Stage III*: complete with partial displacement – the fragments are still connected by the posterior retinacular attachment; the femoral head trabeculae are no longer in line with those of the innominate bone.

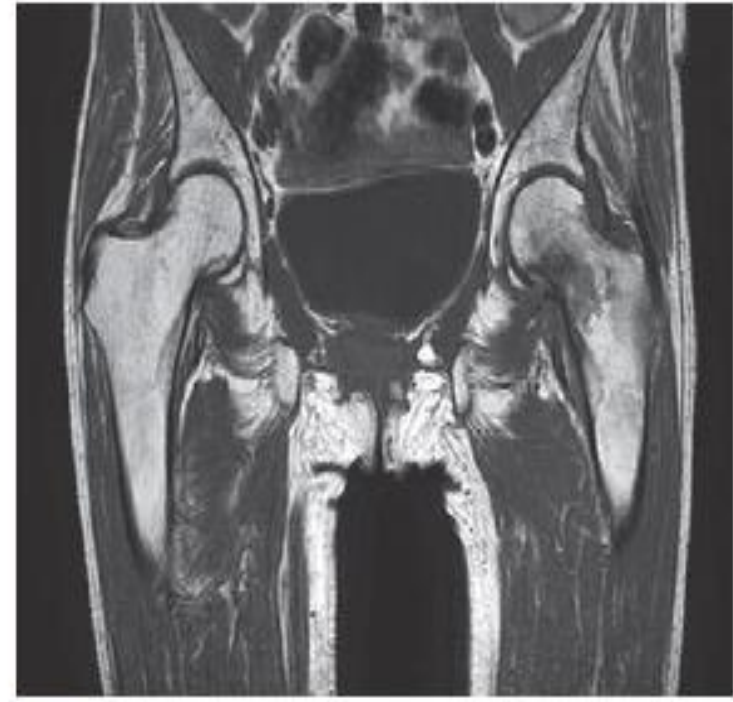
(d) *Stage IV*: complete with full displacement – the proximal fragment is free and lies correctly in the acetabulum so that the trabeculae appear normally aligned with those of the innominate.



(a)

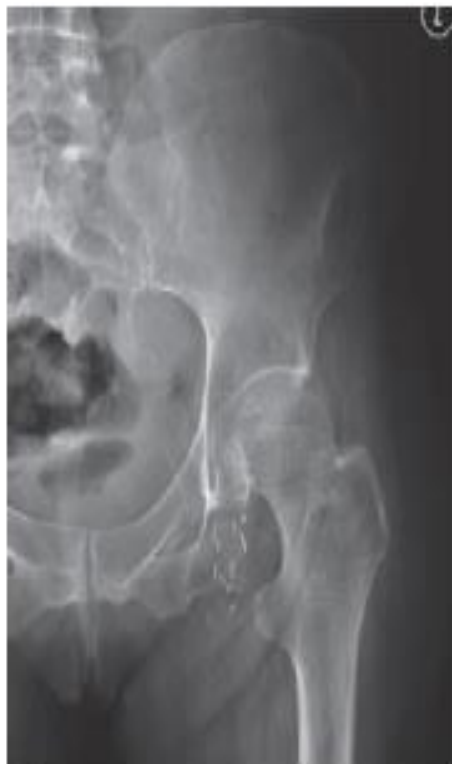

(b)

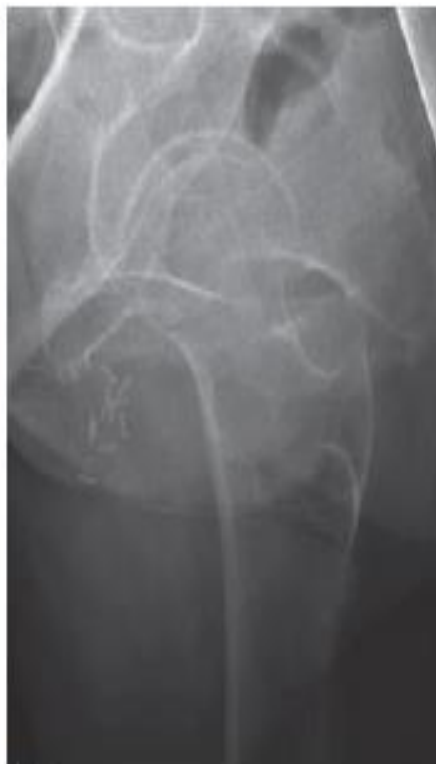

(c)

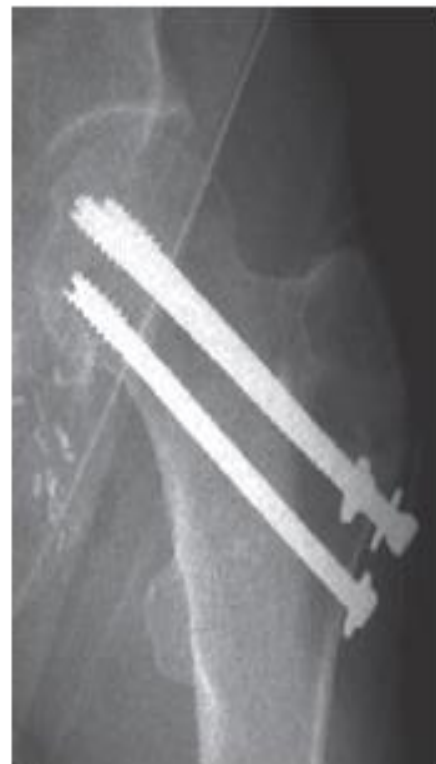
**29.6 Fractures of the femoral neck – diagnosis** (a) An elderly woman tripped on the pavement and complained of pain in the left hip. The plain x-ray showed no abnormality. Two weeks later she was still in pain; (b) a bone scan showed a 'hot' area medially at the base of the femoral neck. MRI, if available, is an alternative investigation to confirm suspicions of a femoral neck fracture (c).



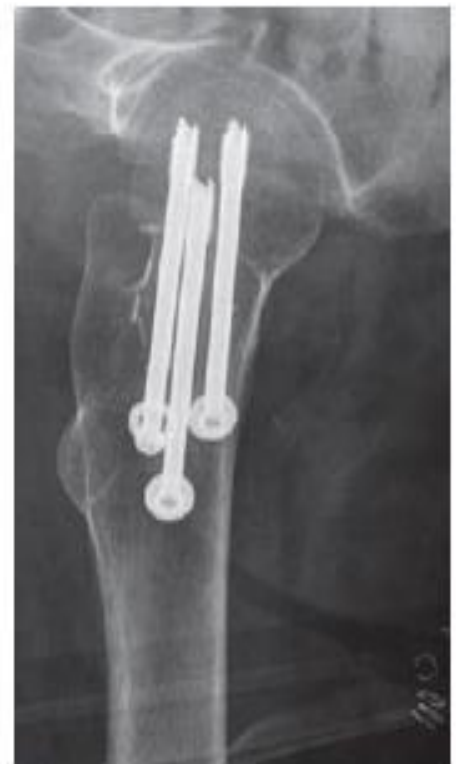(a)



(b)



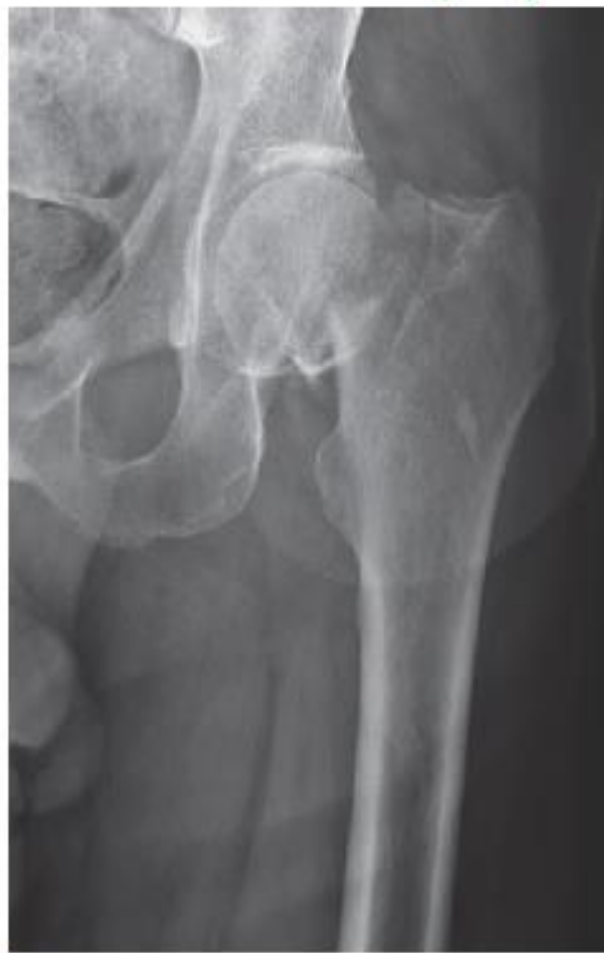(c)



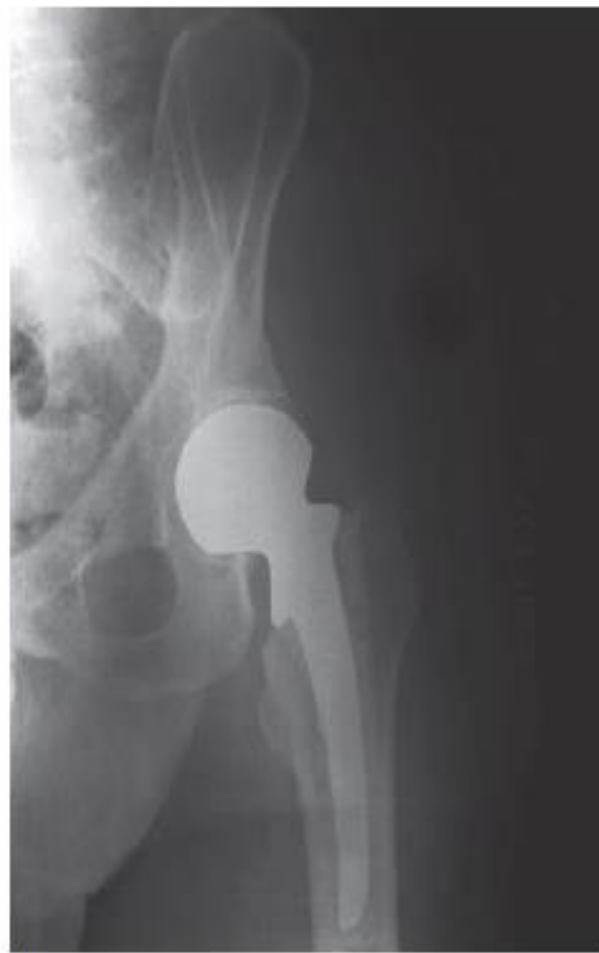(d)

**29.8 Femoral neck injuries – treatment** (a,b) This Garden stage II fracture has been stabilized with 3 cannulated screws. (c,d) An optimum position for the screws is: one to support the inferior portion of the neck (centrally); and another two, central in level, skirting the anterior and posterior cortices of the femoral neck on the lateral x-ray. It is important the most inferior screw enters the lateral cortex of the femur proximal to the level of the inferior margin of the lesser trochanter.

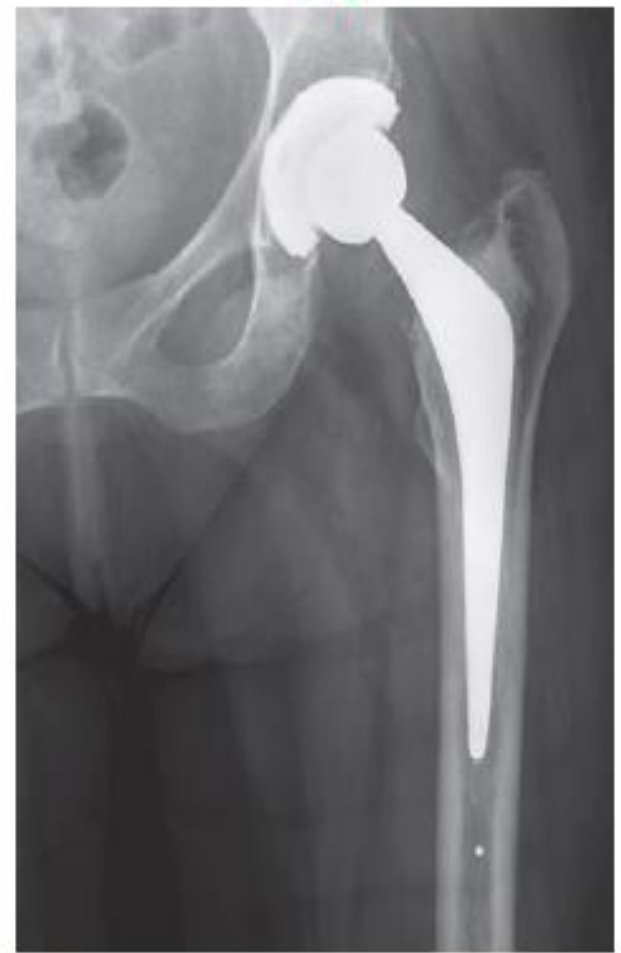



(a)



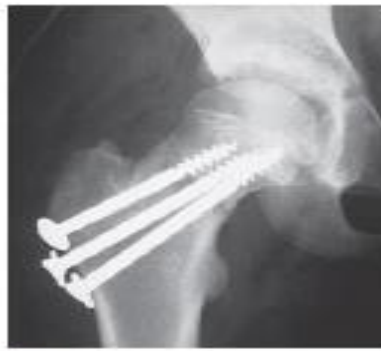(b)



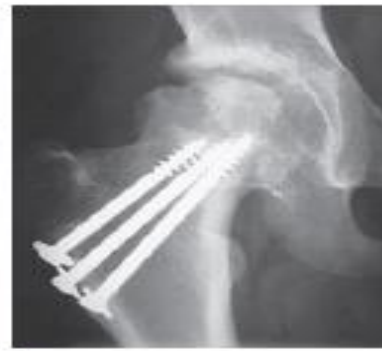(c)

**29.9 Fracture of the femoral neck – treatment** (a) A fracture as severely displaced as this (Stage IV), if treated by reduction and internal fixation, will probably end up needing revision surgery; instead it could be treated by performing a hemiarthroplasty using a cemented femoral prostheses (b). A total hip replacement (c) provides a better outcome for younger patients (50–60 year olds) with this type of fracture.





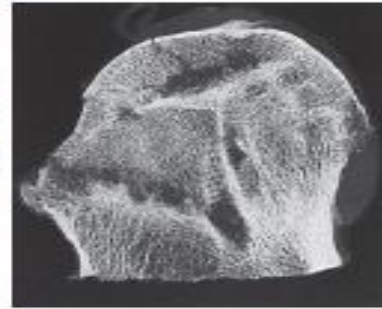
(a)



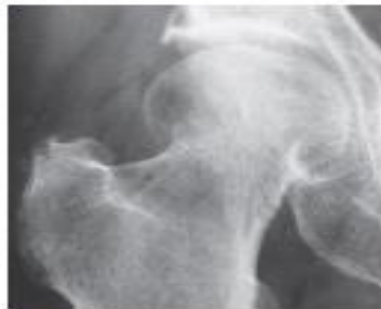(b)



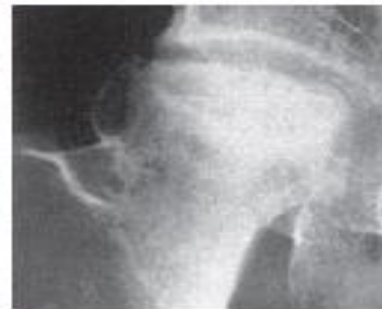(c)



(d)



(e)

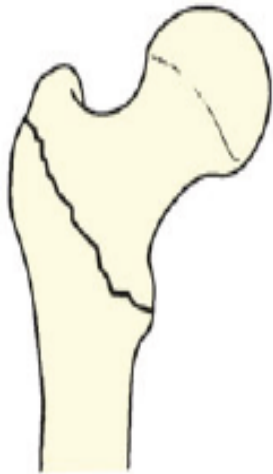

(f)

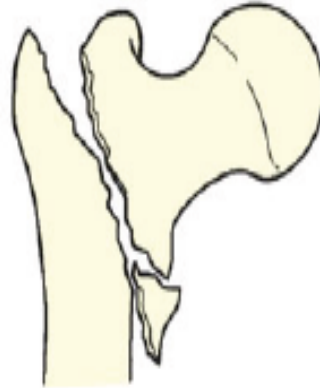
#### 29.10 Fracture of the femoral neck – avascular necrosis

(a) The post-reduction x-ray may look splendid but the blood supply is compromised and 6 months later (b) there is obvious necrosis of the femoral head.

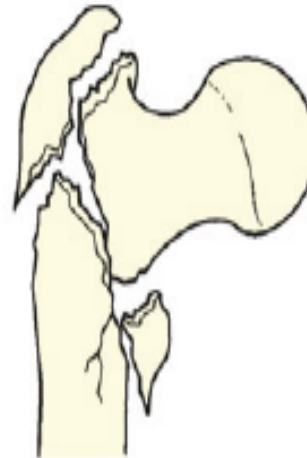(c) Section across the excised femoral head, showing the large necrotic segment and splitting of the articular cartilage. (d) Fine detail x-ray of the same. (e,f) Even an impacted fracture, if it is displaced in valgus, can lead to avascular necrosis.



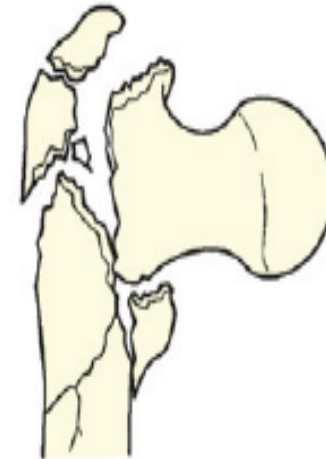
TYPE 1  
Undisplaced  
Uncomminuted



TYPE 2  
Displaced  
Minimal comminuted  
Lesser trochanter fracture  
Varus

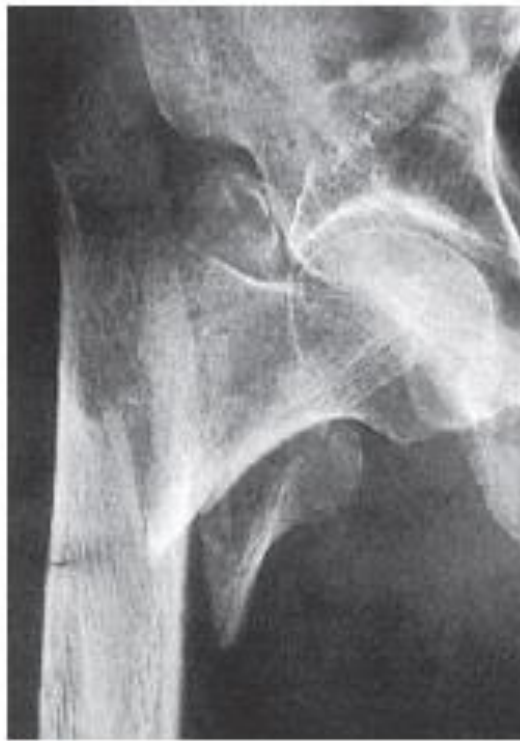

TYPE 3  
Displaced  
Greater trochanter fracture  
Comminuted  
Varus

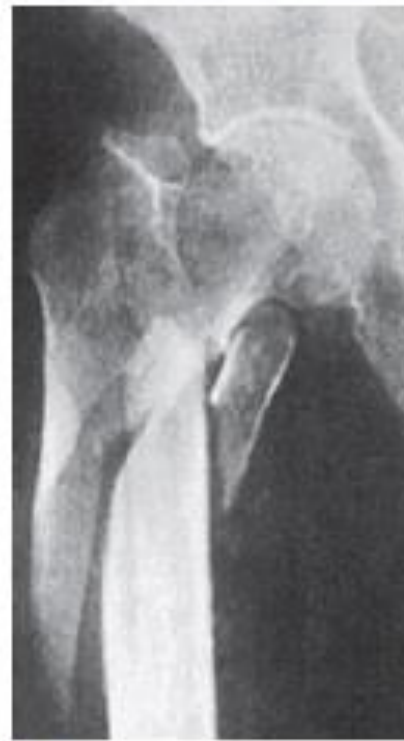

TYPE 4  
Severely comminuted  
Subtrochanter extension  
(Also reverse oblique)

**29.11 Intertrochanteric fractures – classification** Types 1 to 4 are arranged in increasing degrees of instability and complexity. Types 1 and 2 account for the majority (nearly 60 per cent). The reverse oblique type of intertrochanteric fracture represents a subgroup of Type 4; it causes similar difficulties with fixation.

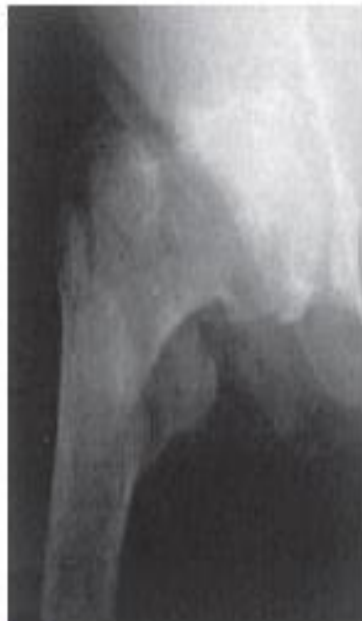

(a)

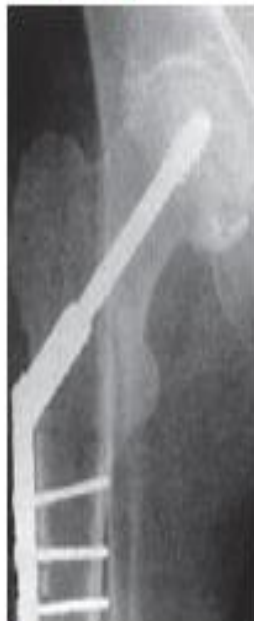

(b)

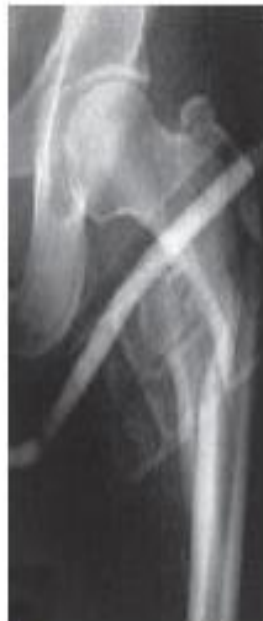**29.12 Intertrochanteric features** Two contrasting types of intertrochanteric fracture. (a) Type 2 fracture: the fracture runs obliquely downwards from the lateral to medial cortex, in this case associated with a lesser trochanter fracture and resulting in a typical varus deformity. This is an unstable fracture. (b) Type 4 'reverse oblique' fracture: here the fracture line runs downwards from medial to lateral cortex, to give an even more unstable geometry.



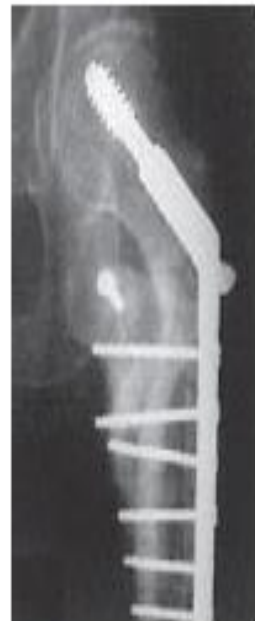(a)



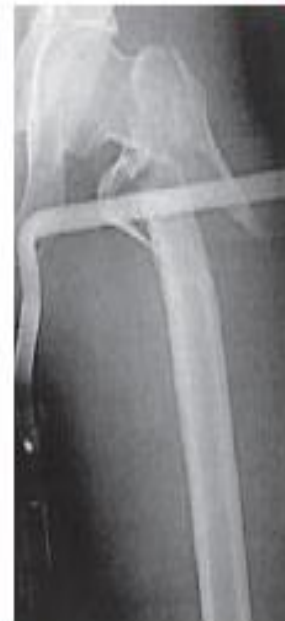(b)



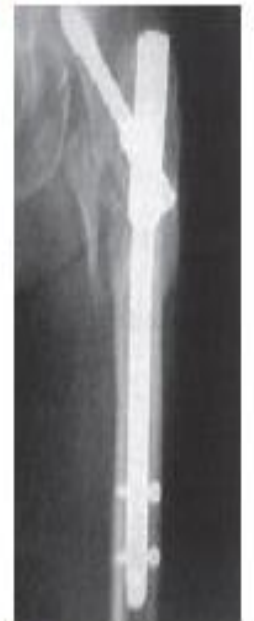(c)



(d)

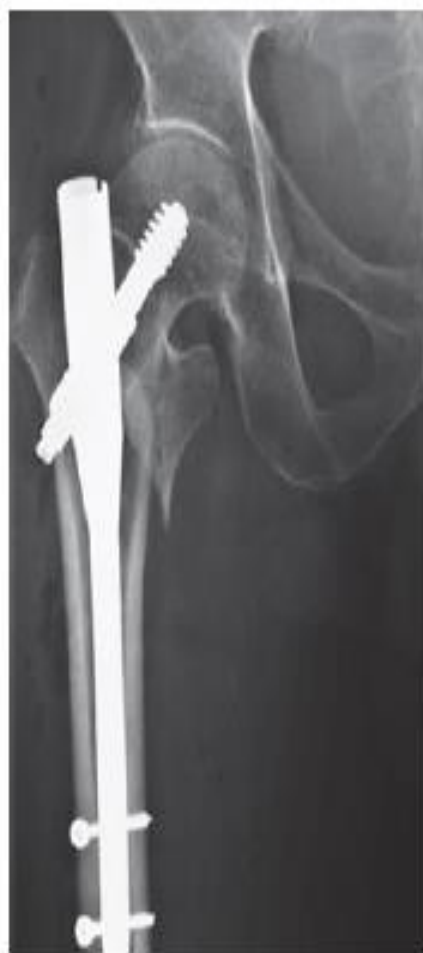

(e)

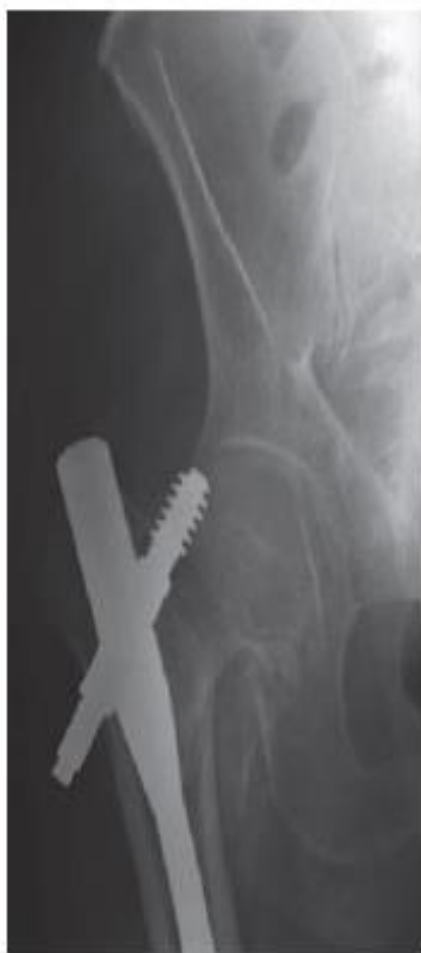

(f)

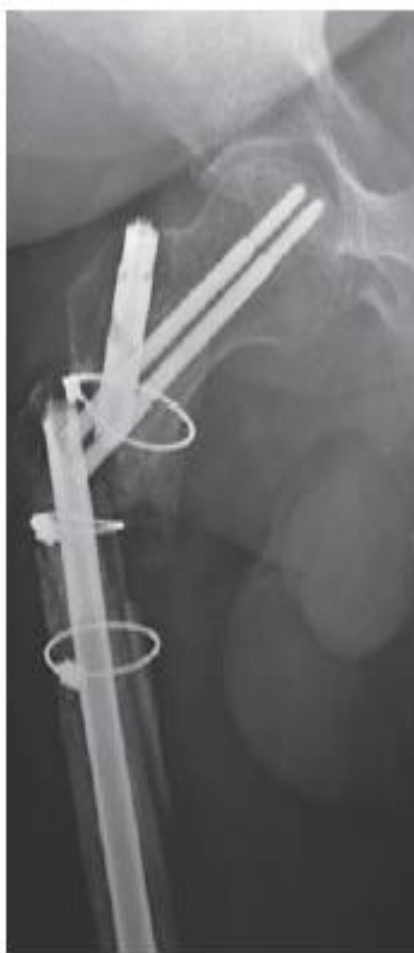**29.14 Intertrochanteric fractures – treatment** Anatomic reduction is the ideal; but stable fixation is equally important. Types 1 and 2 fractures (a,b) can usually be held in good position with a compression screw and plate. If this is not possible, an osteotomy of the lateral cortex (c,d) will allow a screw to be inserted up to the femoral neck and into the head of the femur; this can be used as a lever to reduce the fracture so that the medial spike of the proximal fragment engages securely into the femoral canal; fixation is completed with a side plate. Reverse oblique fractures (e,f) are inherently unstable even after perfect reduction; here one can use an intramedullary device with an oblique screw that engages the femoral head. (Courtesy of Mr M Manning and Mr JS Albert).



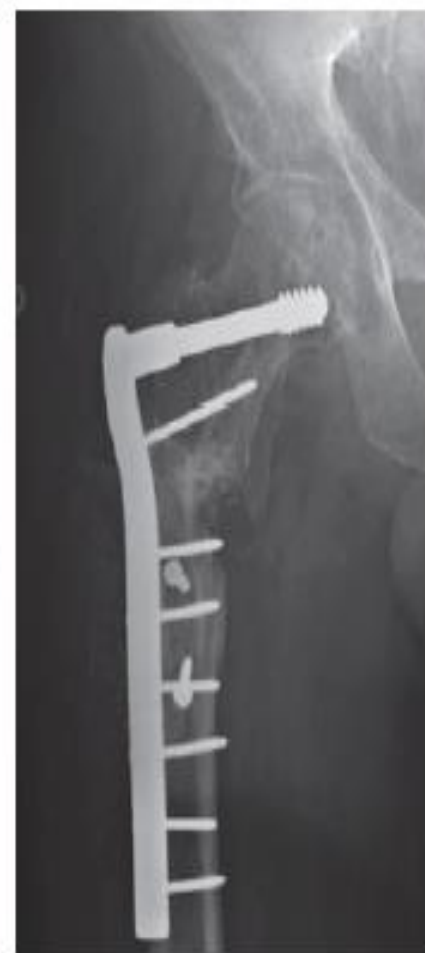(a)



(b)



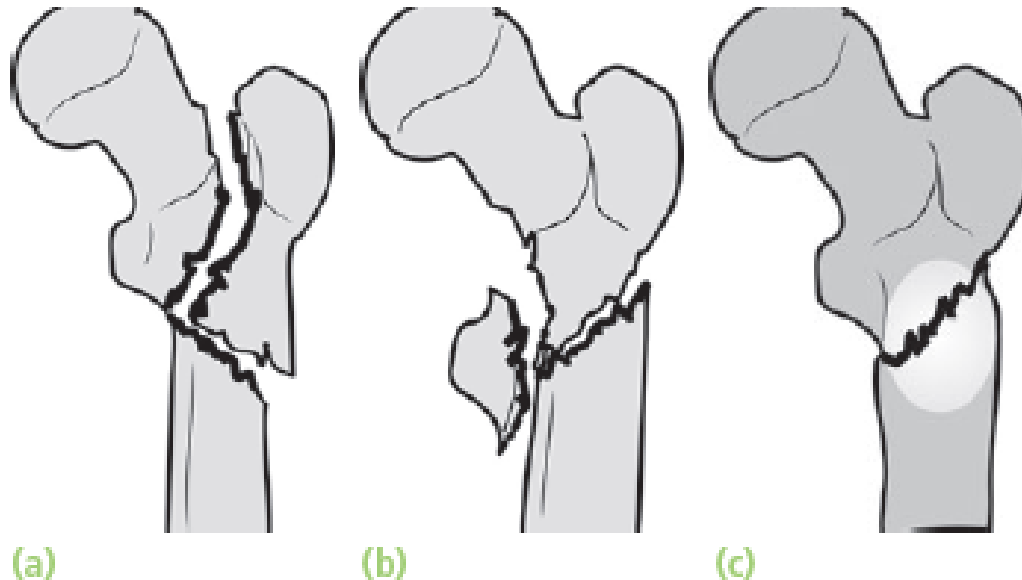
(c)



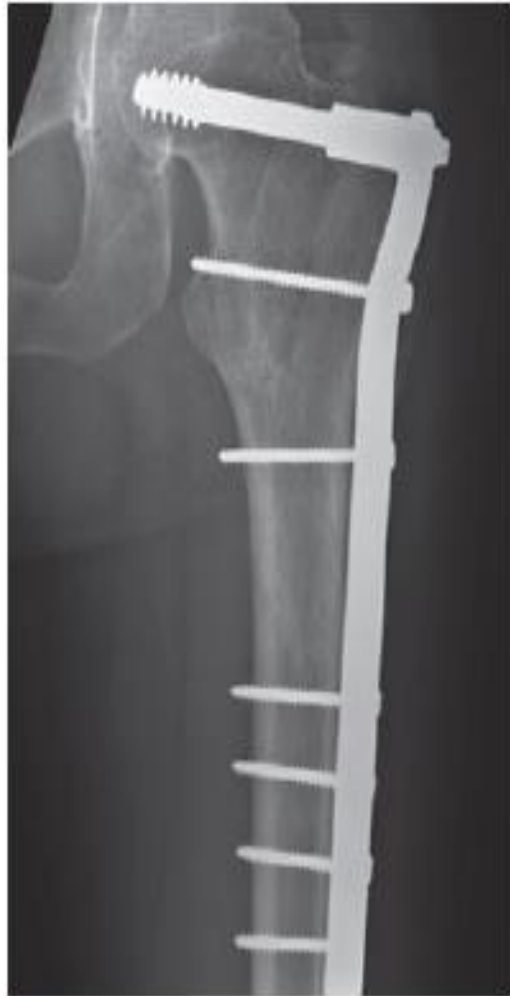(d)

**29.15 Complications of treatment of intertrochanteric fractures** (a,b) Failure to maintain reduction, which can be early – usually in osteoporotic bone or from poor implant seating (c,d). The implant may fracture if union is not timely. Revision surgery is complex and may involve bone grafts and a new implant.

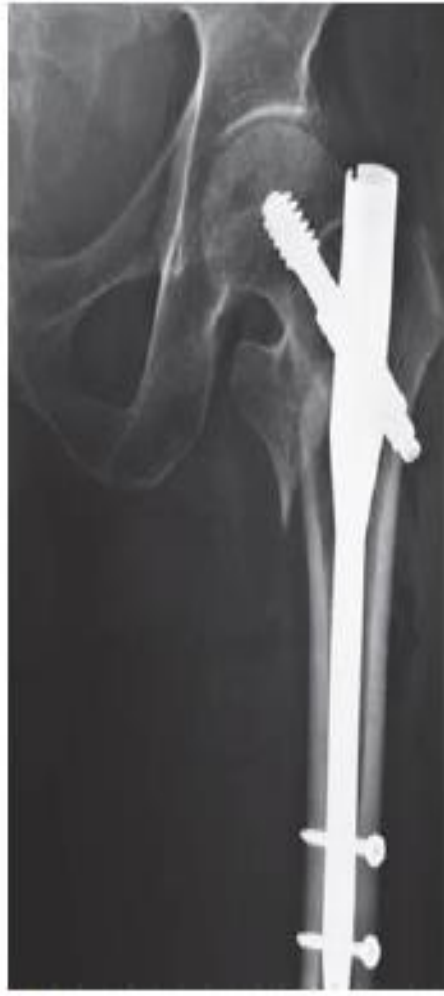



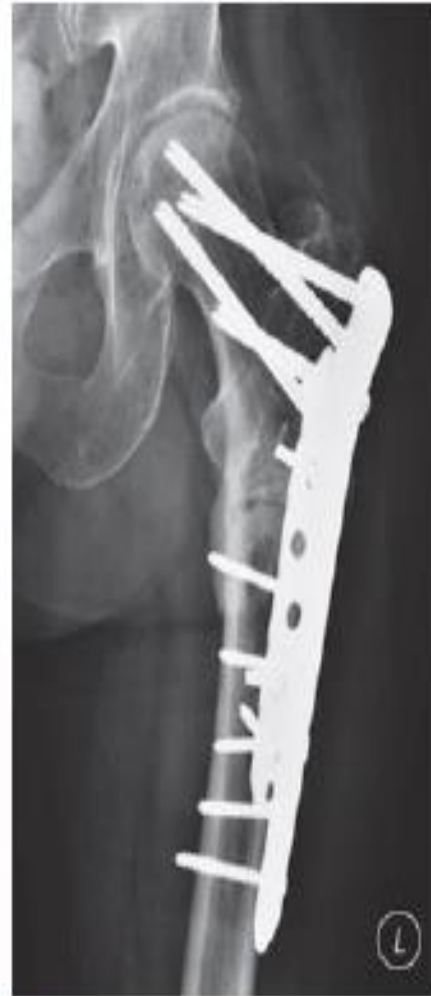**29.18 Subtrochanteric fractures of the femur – warning signs on the x-ray** X-ray findings that should caution the surgeon: **(a)** comminution, with extension into the piriform fossa; **(b)** displacement of a medial fragment including the lesser trochanter and, **(c)** lytic lesions in the femur.



(a)

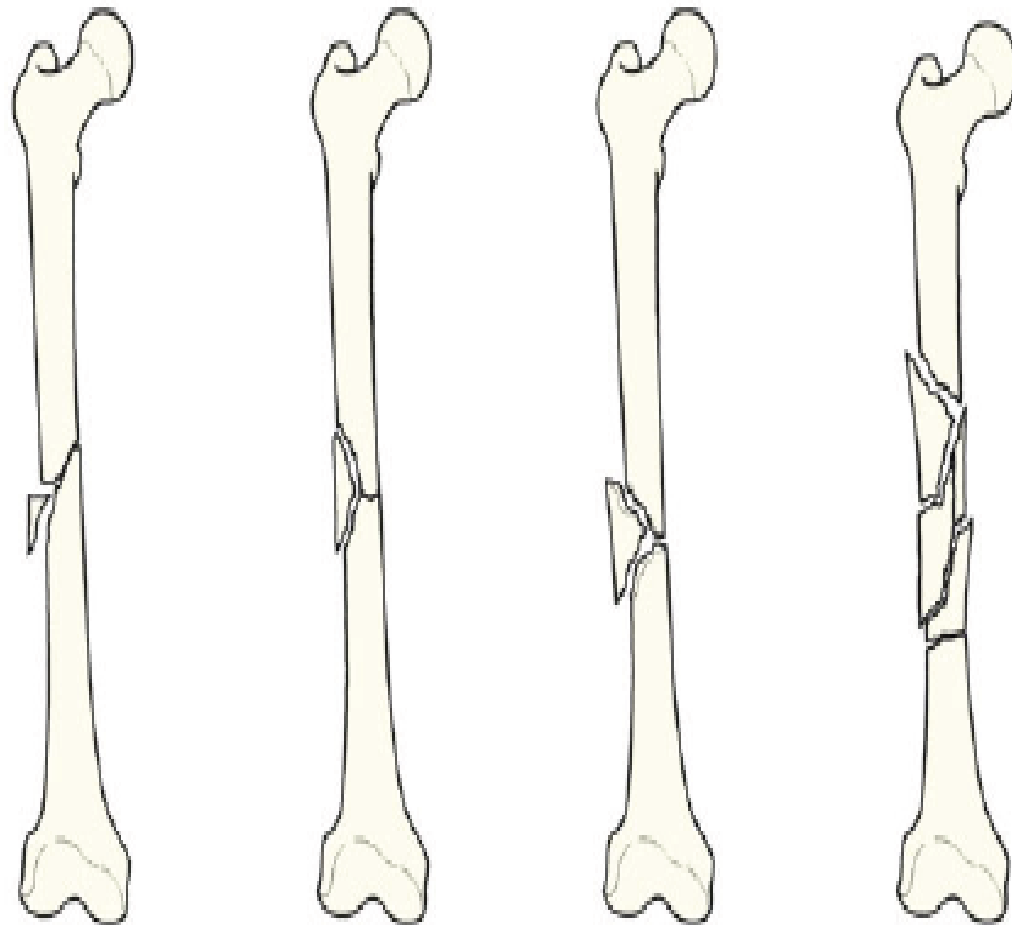


(b)

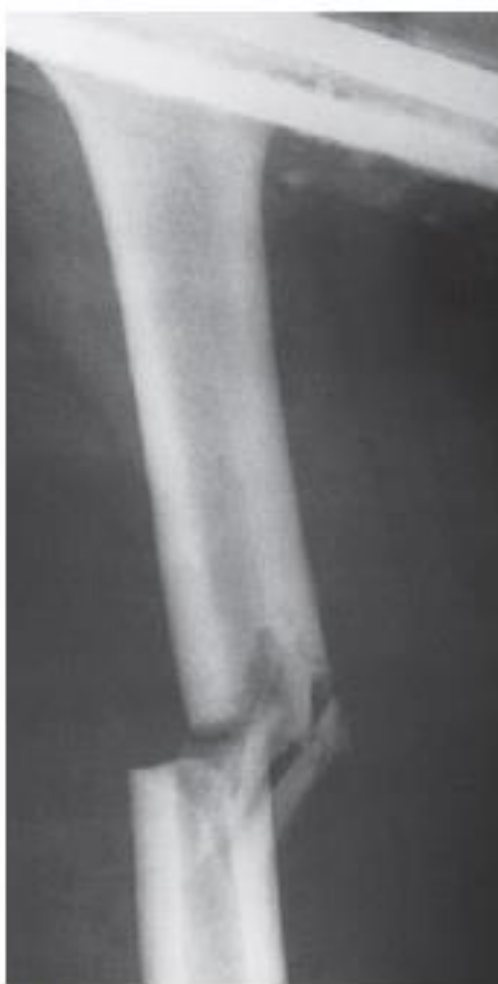

(c)

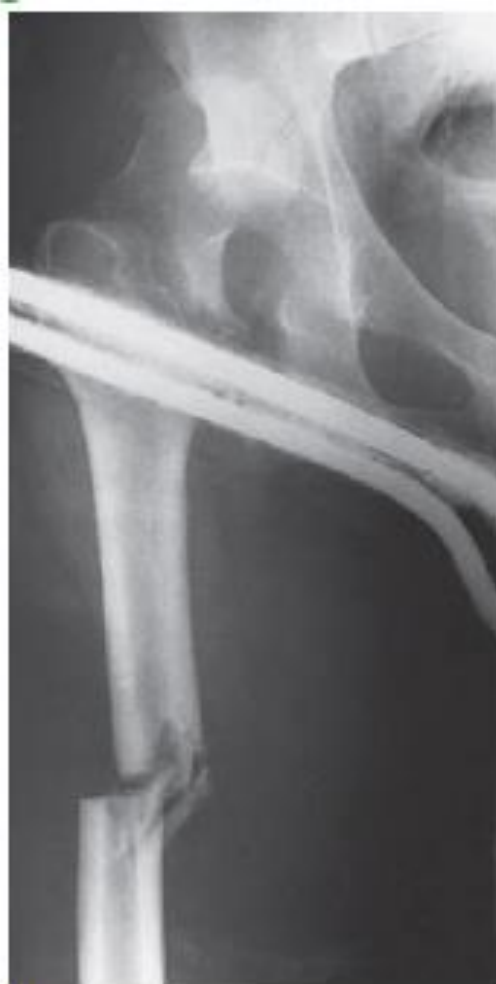**29.19 Subtrochanteric fractures – internal fixation** Several methods of fixation are in use: (a) a 95° screw and plate device; (b) an intramedullary nail with proximal interlocking screw into the femoral head; and (c) a proximal femoral plate with locking screws.



**29.20 Femoral shaft fractures – classification** Winquist's classification reflects the observation that the degrees of soft-tissue damage and fracture instability increase with increasing grades of comminution. In *Type 1* there is only a tiny cortical fragment. In *Type 2* the 'butterfly fragment' is larger but there is still at least 50 per cent cortical contact between the main fragments. In *Type 3* the butterfly fragment involves more than 50 per cent of the bone width. *Type 4* is essentially a segmental fracture.

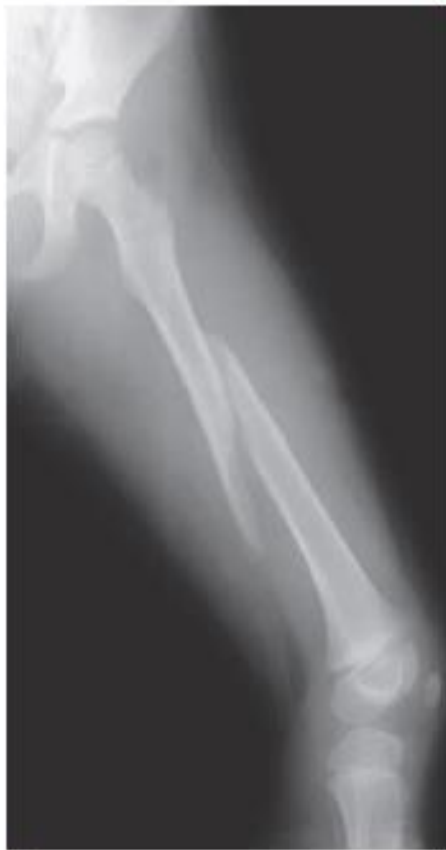

(a)

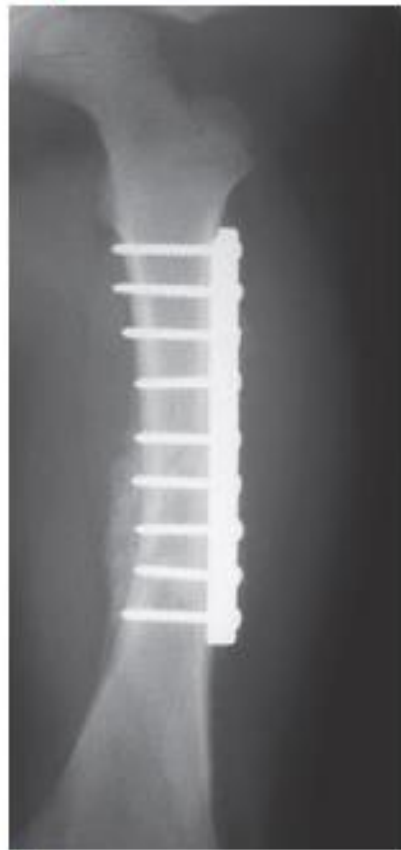


(b)

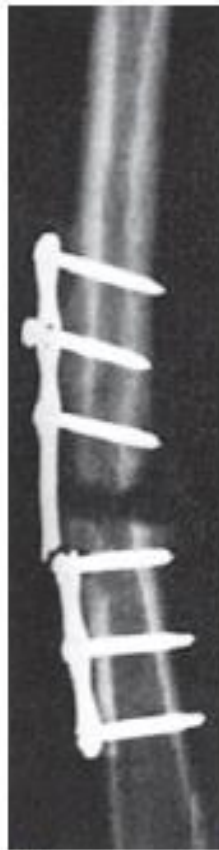**29.21 Femoral shaft fractures – diagnosis** (a) The upper fragment of this femur is adducted, which should alert the surgeon to the possibility of (b) an associated hip dislocation. With this combination of injuries the dislocation is frequently missed; the safest plan is to *x-ray the pelvis with every fracture of the femoral shaft*.



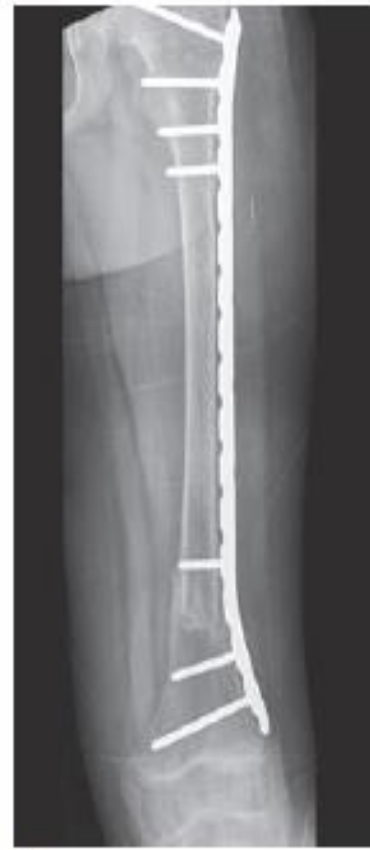(a)



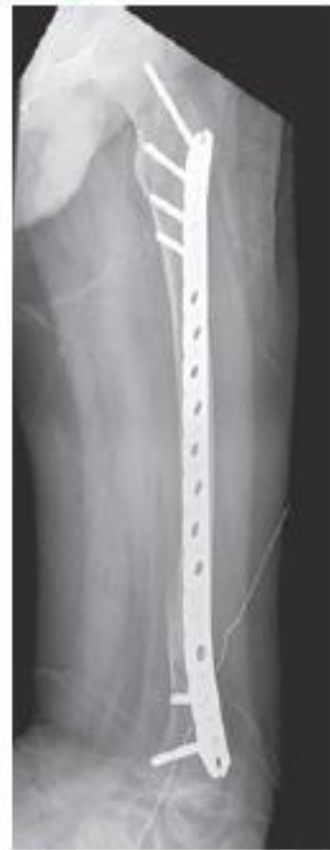(b)



(c)



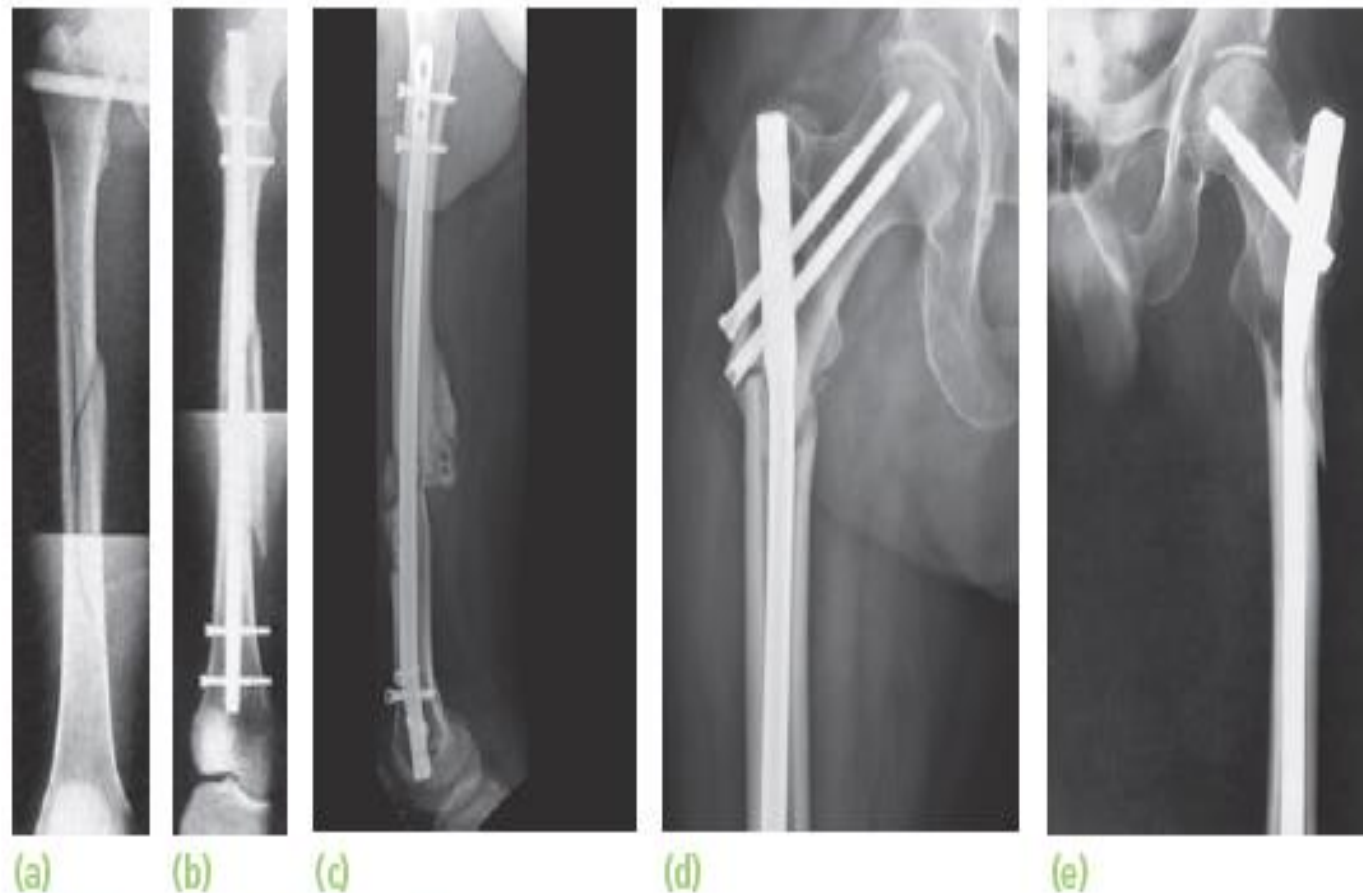(d)



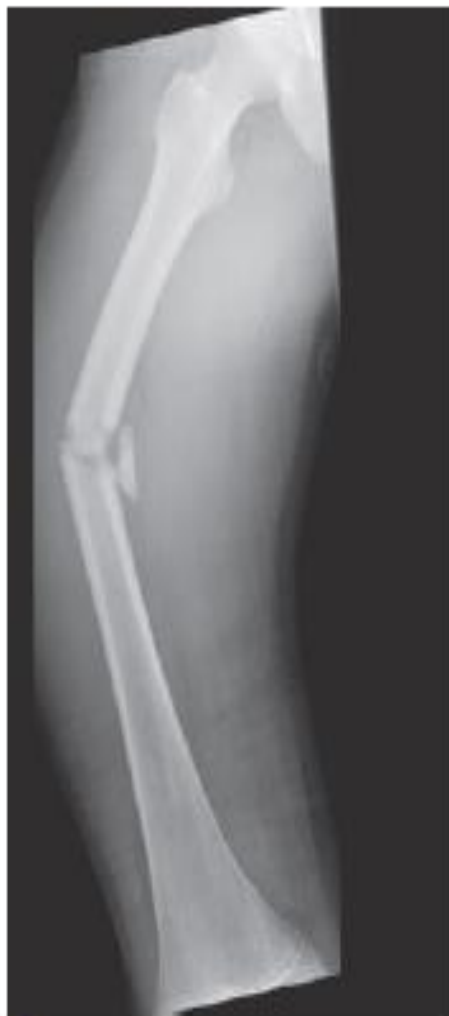(e)

**29.24 Plate fixation – past and present (a,b)** Plate fixation was popular in the past, but it fell out of favour because of the high complication rate (c). Modern techniques of minimally invasive plate osteosynthesis (d,e) have shown that it still has place in the treatment of certain types of femoral shaft fracture.

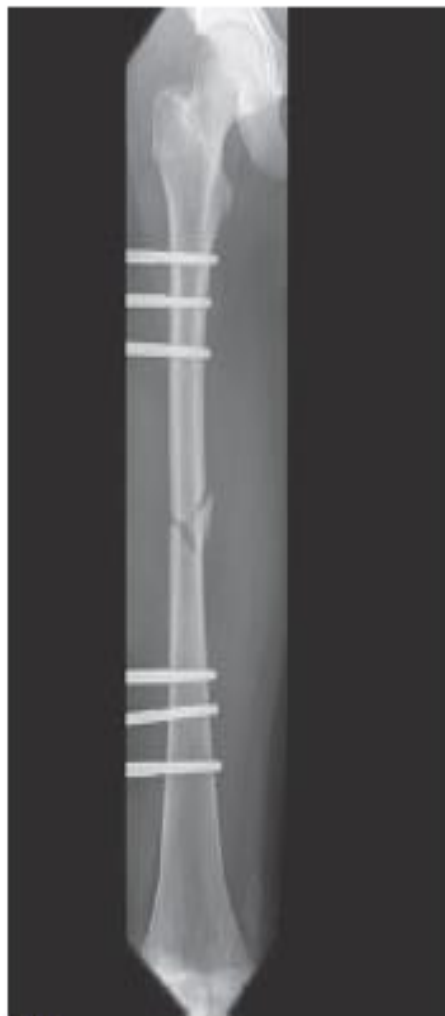



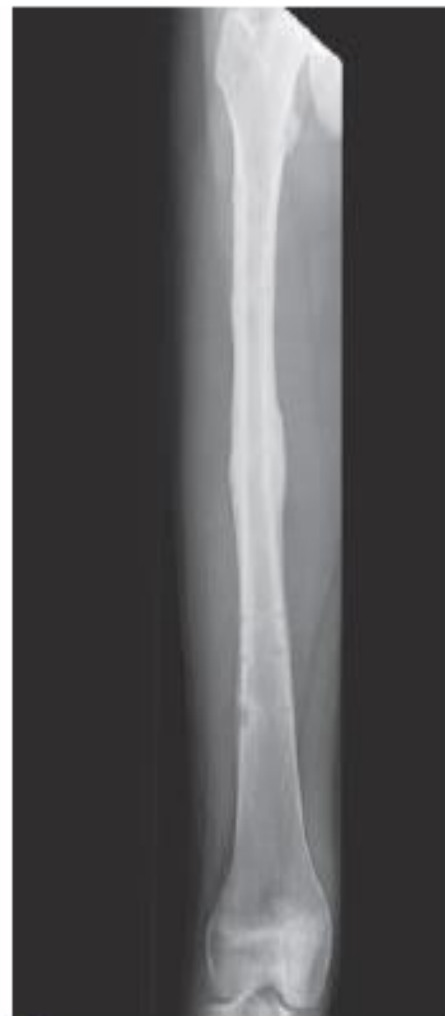**29.25 Intramedullary nailing** Nowadays this is the commonest way of treating femoral shaft fractures. Ideally a range of designs to suit different types of fracture should be available. **(a,b)** Antegrade nailing with insertion of the nail through the piriform fossa and transverse locking screws proximally and distally. **(c)** Retrograde nailing with insertion of the nail through the intercondylar notch at the knee – useful for obese patients and those with bilateral femoral fractures. **(d,e)** Proximal locking can be achieved in other ways e.g. by using parallel screws or a sliding hip screw.



(a)



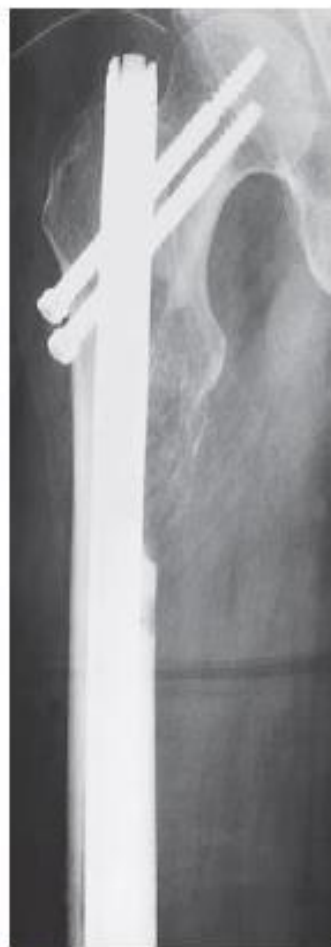(b)



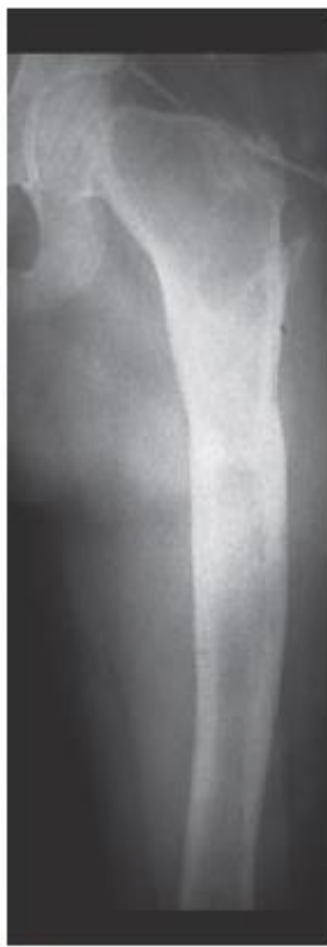(c)

### 29.26 External fixation for femoral shaft fractures in older children (a-c)

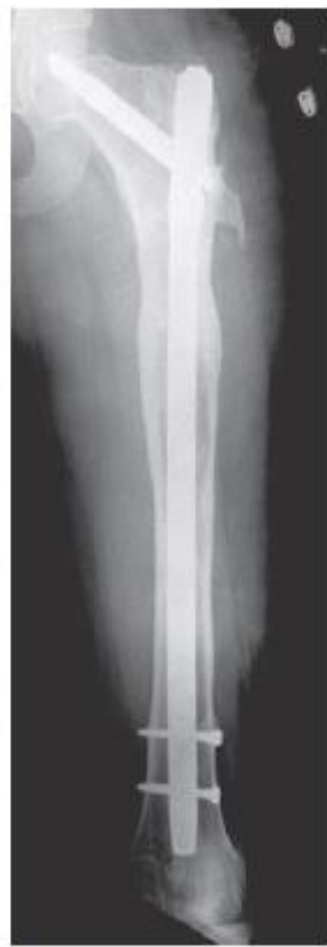External fixation is an option for treating femoral shaft fractures in adolescents. Elastic stable intramedullary nails shown in Fig 29.31 may not be strong enough for this heavier group of teenagers.



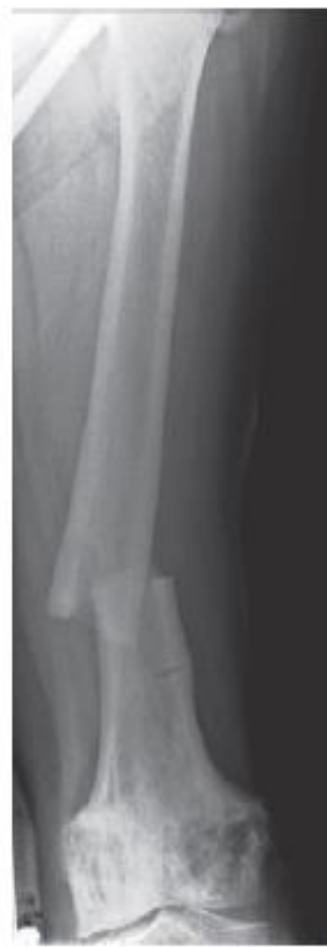(a)



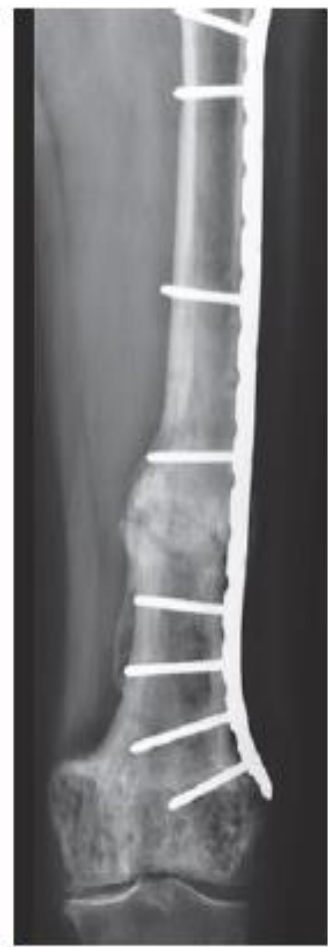(b)



(c)

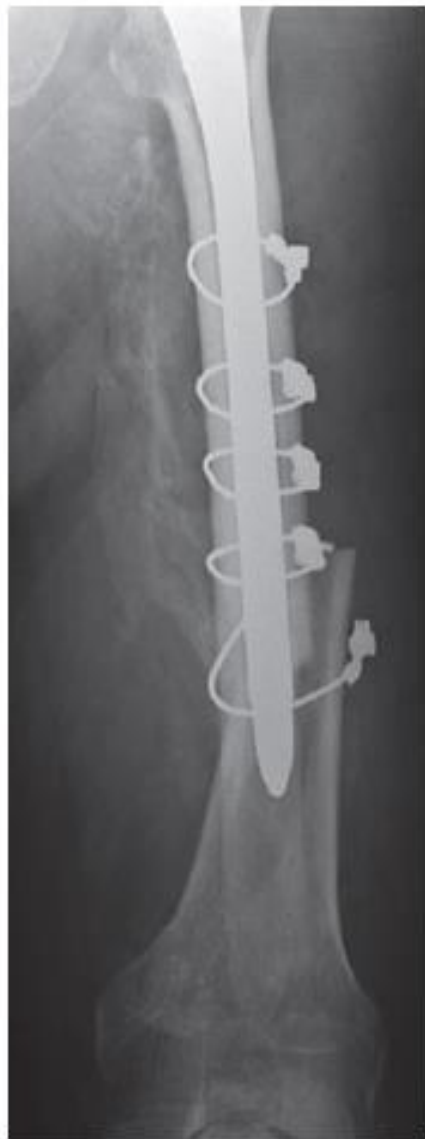

(d)

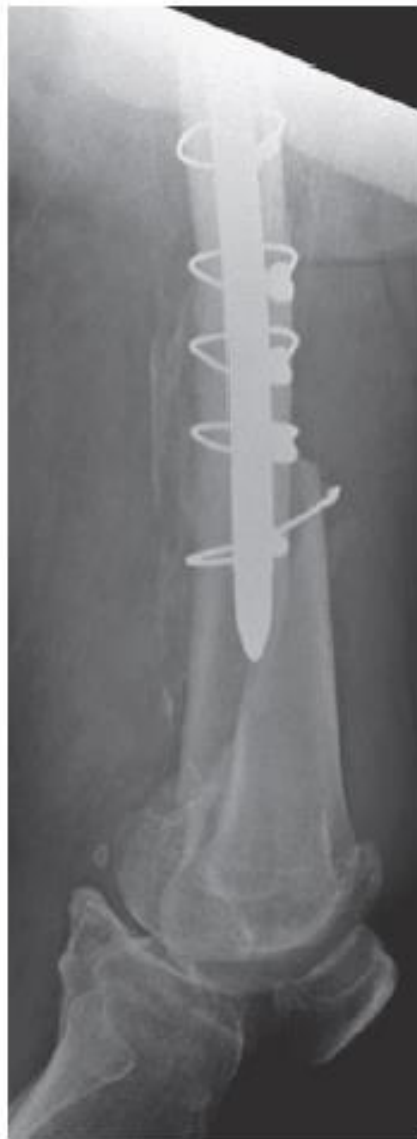

(e)

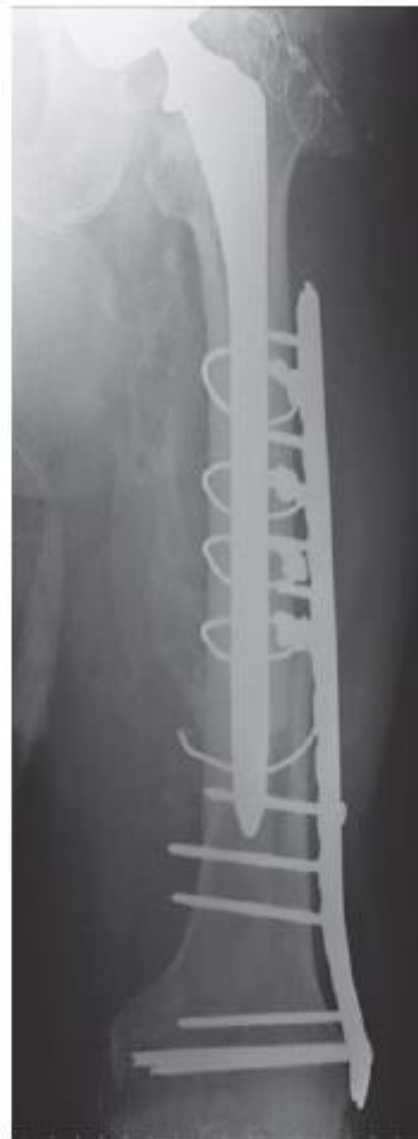**29.27 Pathological fractures – internal fixation** (a) Metastatic tumour, nailed before it actually causes a fracture. (b) Fibrous dysplasia with a stress fracture; (c) nailing provided the opportunity to correct the deformity. (d,e) Paget's disease, with a fracture; in this case (because of its site) treated by fixation with a plate and screws.



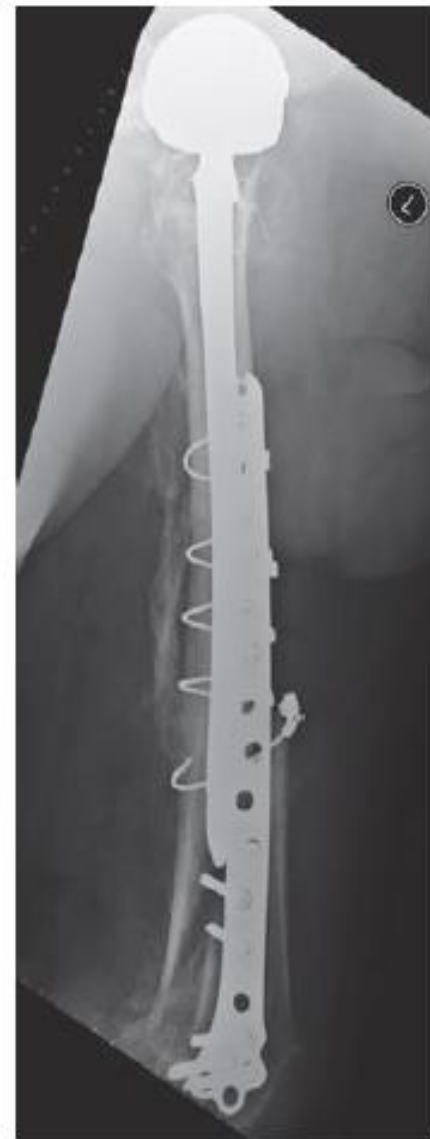(a)



(b)

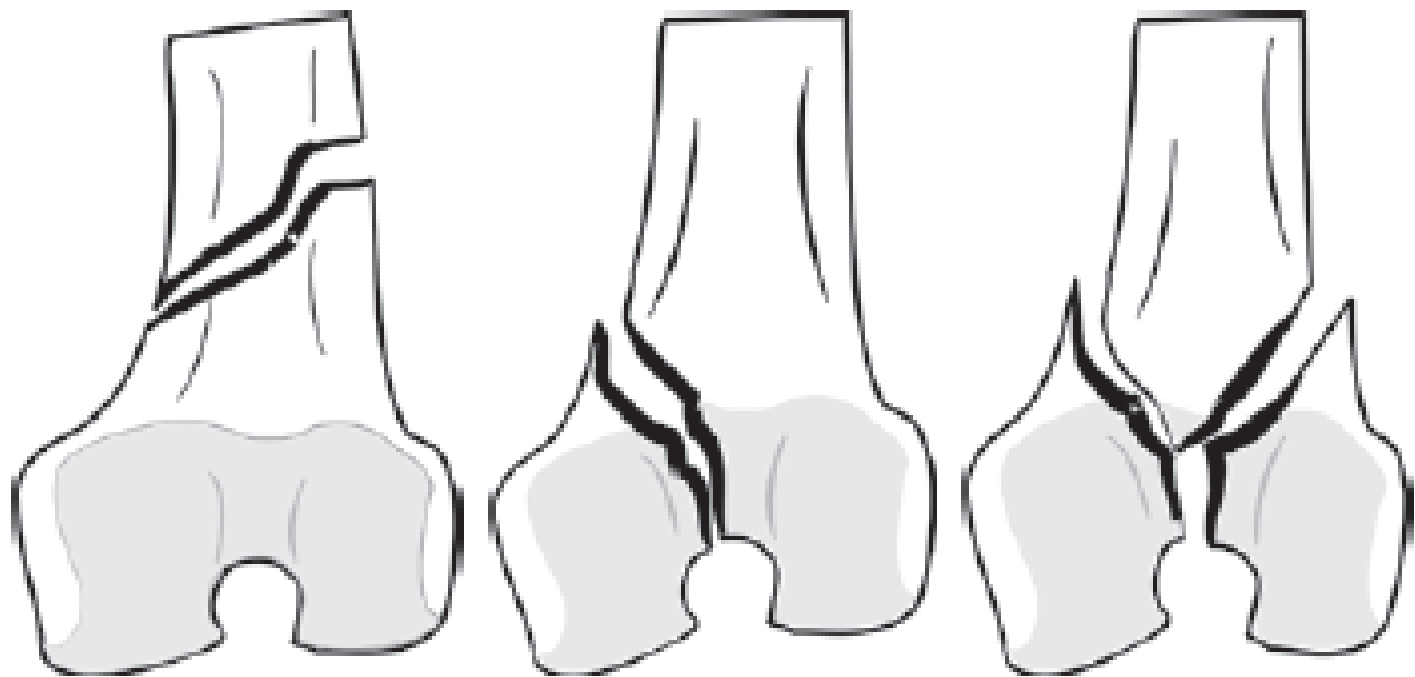


(c)



(d)

**29.28 Periprosthetic fracture** This patient had two successive fractures around his hip prosthesis. The first was held with cerclage wires (a,b). As the prosthesis was secure in the femur the second fracture was fixed with a plate and screws (c,d).



(a)

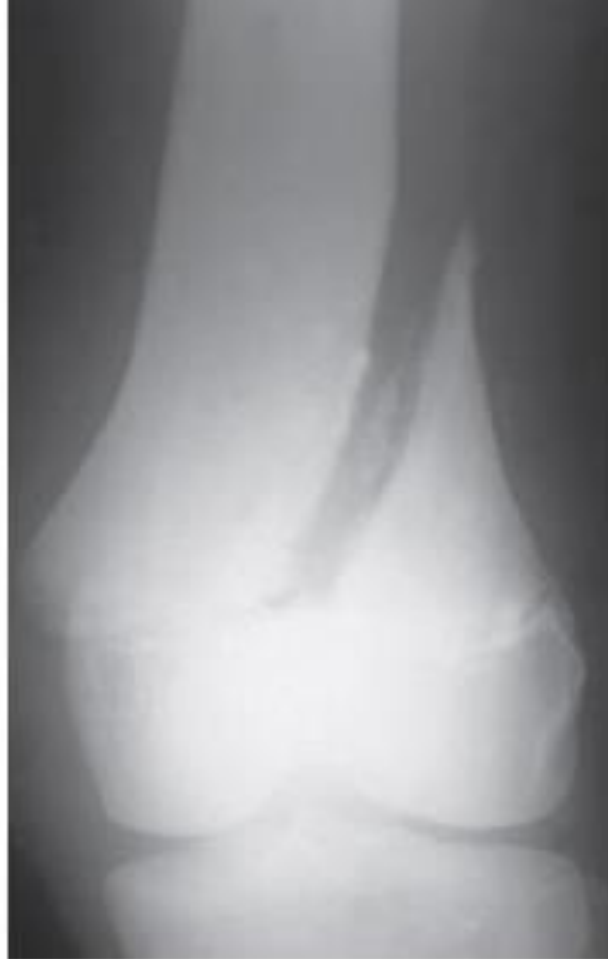(b)

(c)

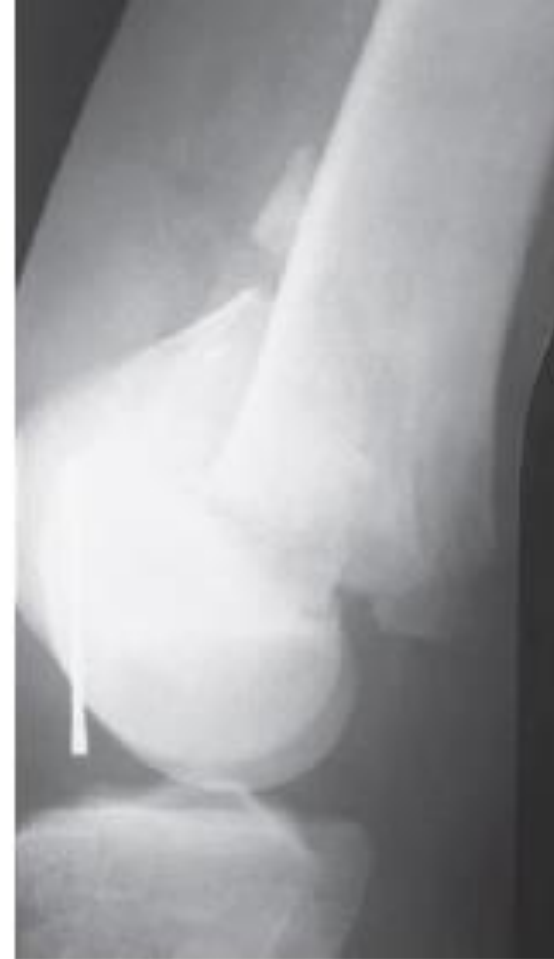### 29.32 The AO classification of supracondylar fractures

(a) Type A fractures do not involve the joint surface; (b) type B fractures involve the joint surface (one condyle) but leave the supracondylar region intact; (c) type C fractures have supracondylar and condylar components.



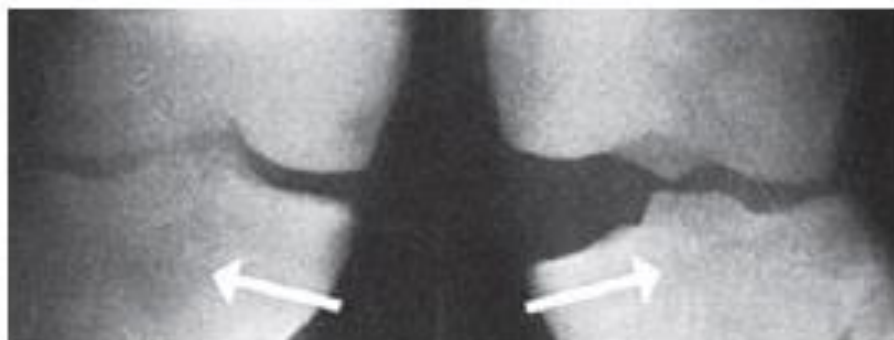

(a)

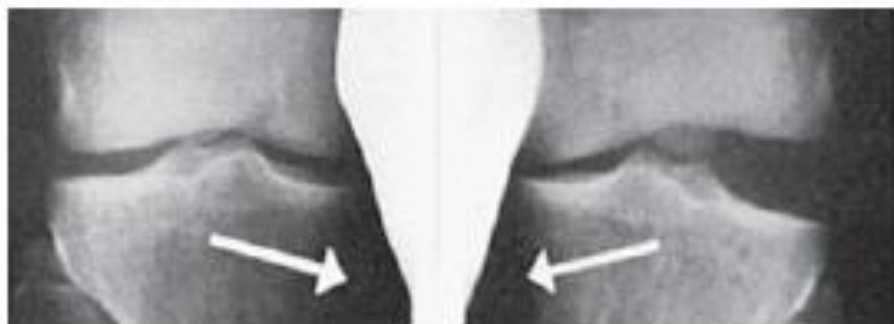


(b)

**29.35 Fracture-separation of the epiphysis** These fractures are not difficult to reduce and can usually be held adequately in plaster, but they must be watched carefully for several weeks.

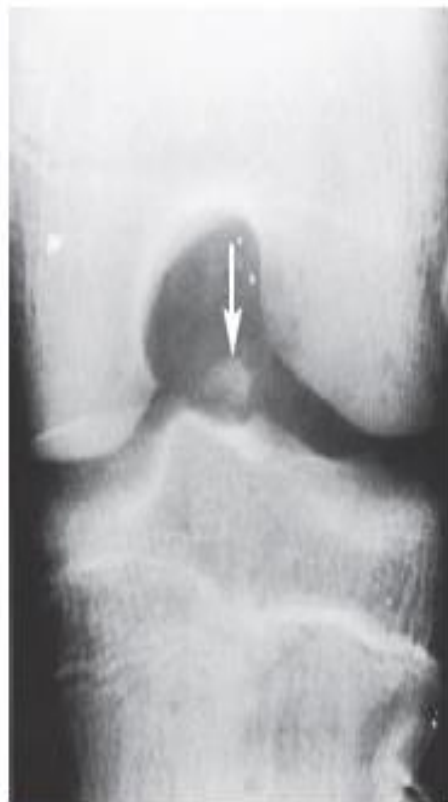

(a)

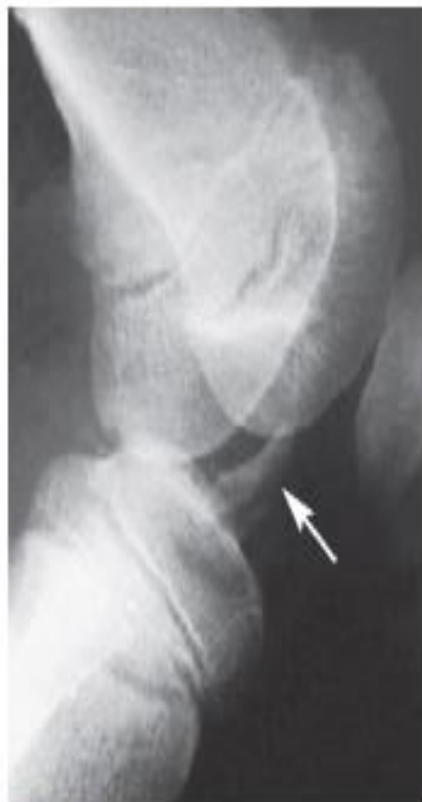

(b)

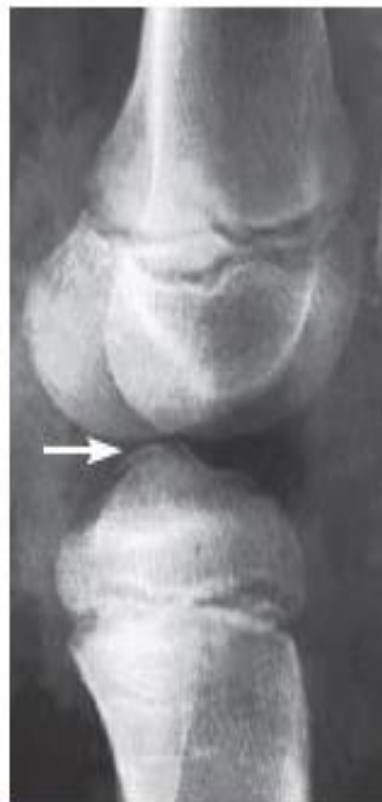**30.3 Stress x-rays** Stress films show: (a) complete tear of medial ligament, left knee; (b) complete tear of lateral ligament. In both, the anterior cruciate also was torn.



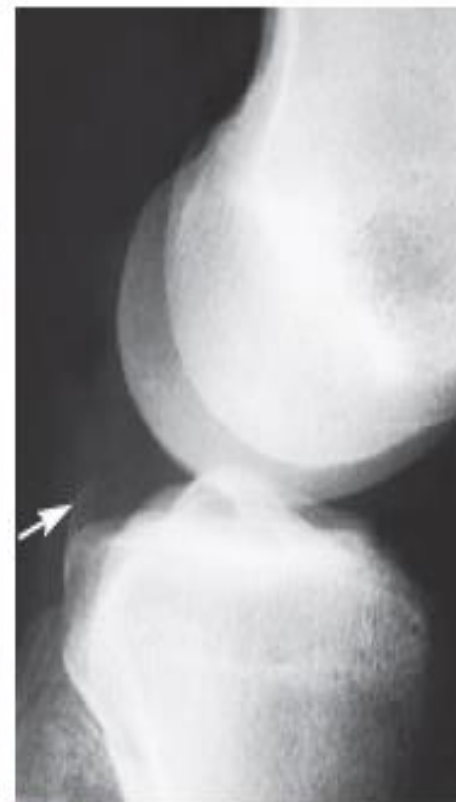
(a)



(b)

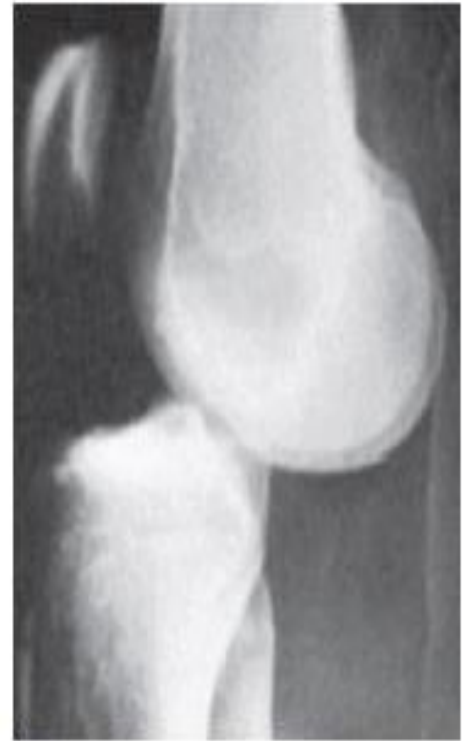
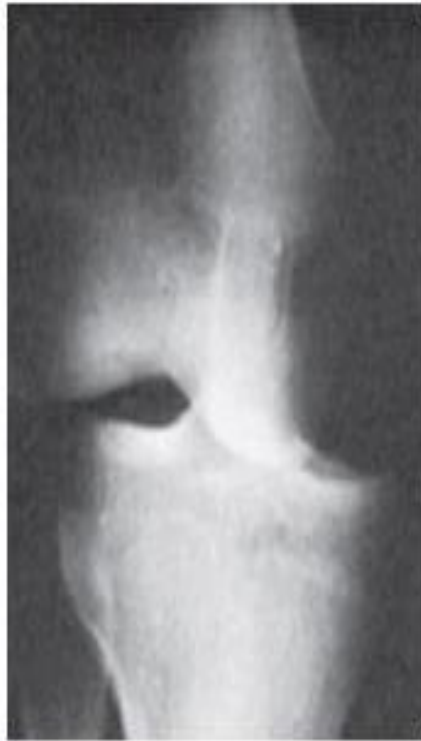
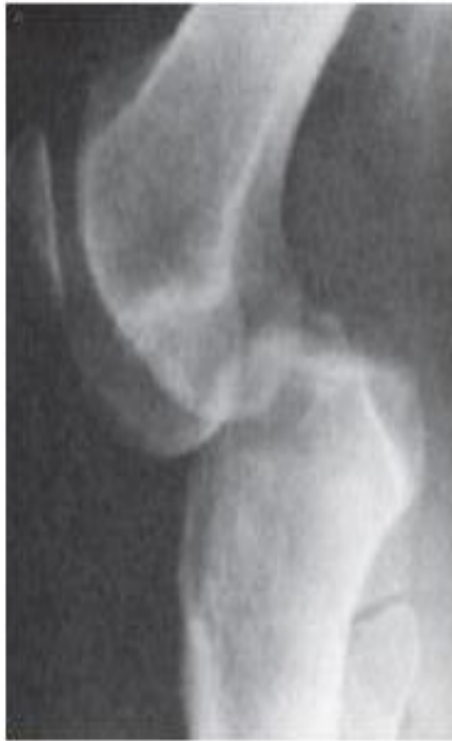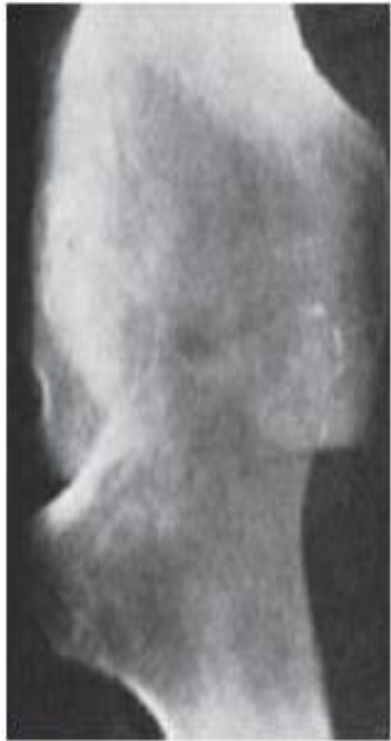(c)



(d)

**30.10 Tibial spine fracture** (a,b) This young man injured his knee while playing football; x-rays showed a large, displaced avulsion fracture of the tibial spine. (c) An undisplaced tibial spine fracture. (d) Posterior fractures, with avulsion of the posterior cruciate ligament, are often missed.



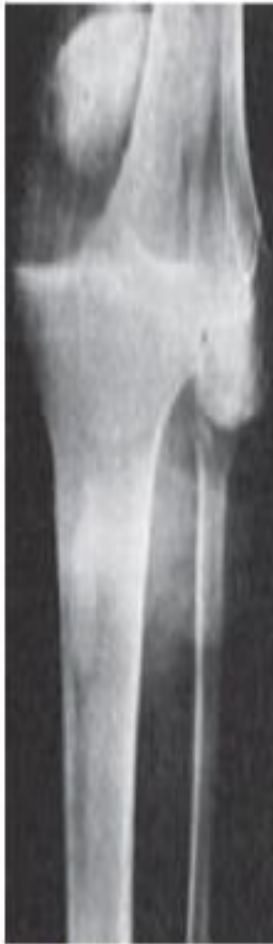(a)

(b)

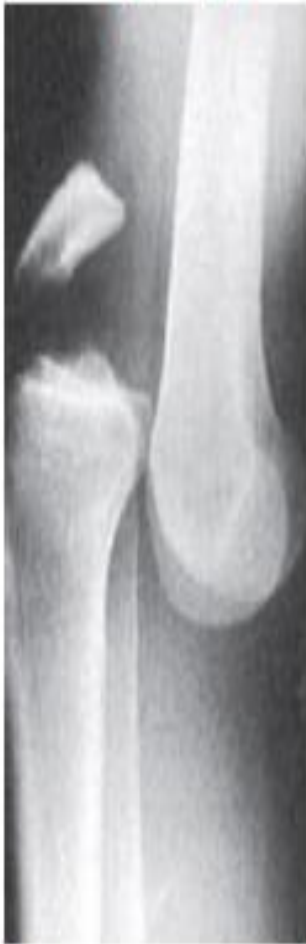(c)

(d)

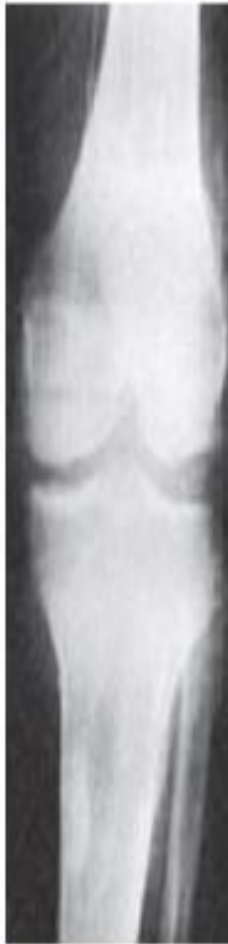30.11 Dislocations of the knee (a,b) Posterolateral dislocation; (c,d) anteromedial dislocation.



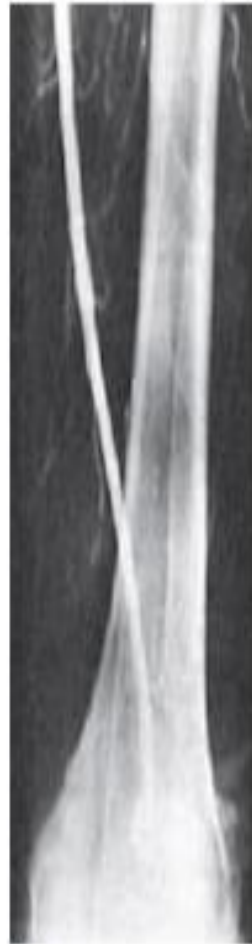(a)



(b)



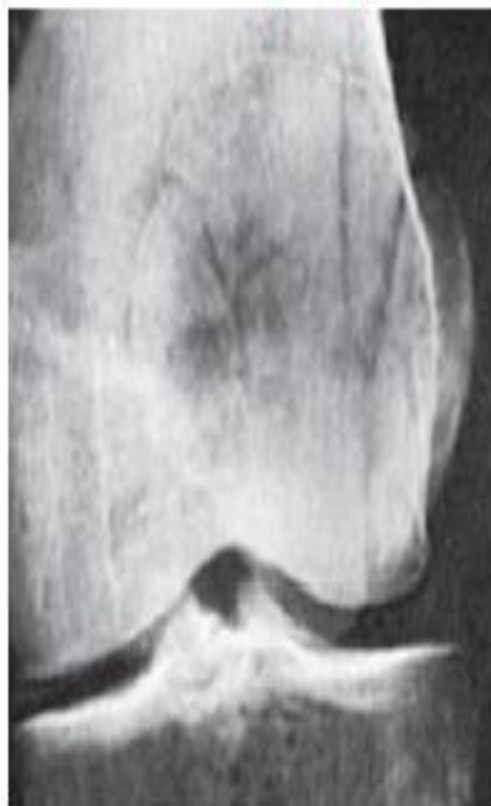(c)



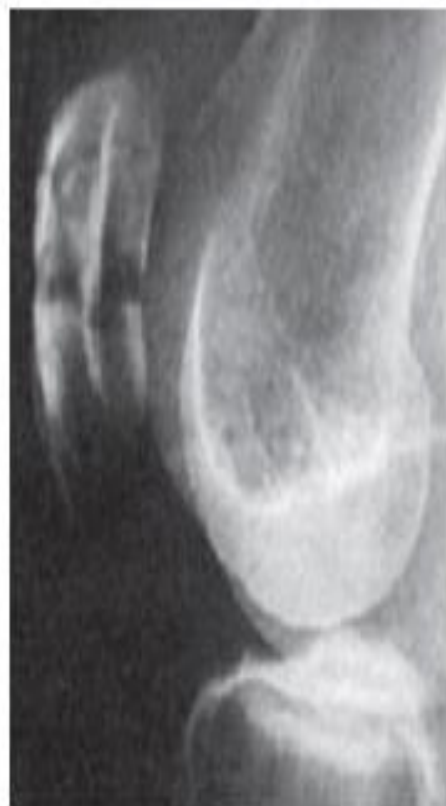
(d)

**30.12 Knee dislocation and vascular trauma (a,b)** This patient was admitted with a dislocated knee. After reduction **(c)** the x-ray looked satisfactory, but the circulation did not. **(d)** An arteriogram showed vascular cut-off just above the knee; had this not been recognized and treated, amputation might have been necessary.

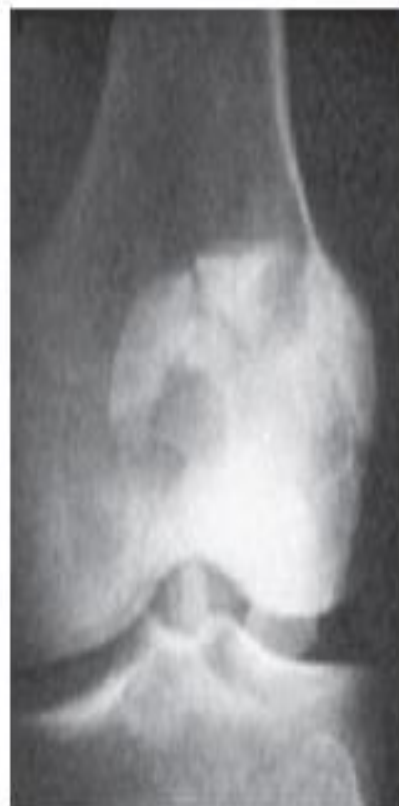




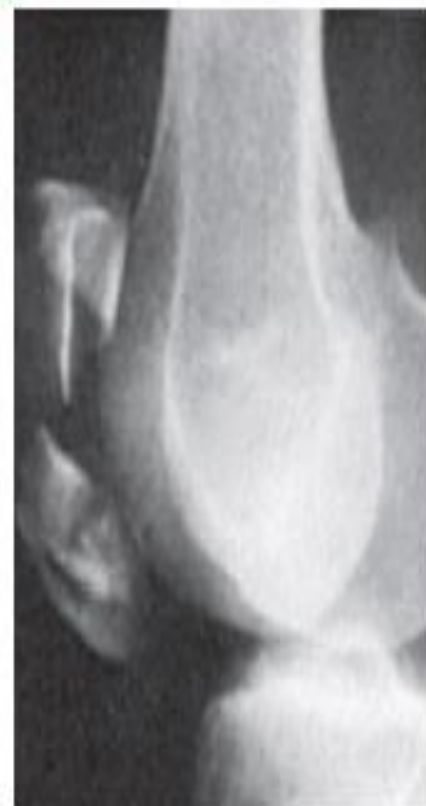
(a)



(b)

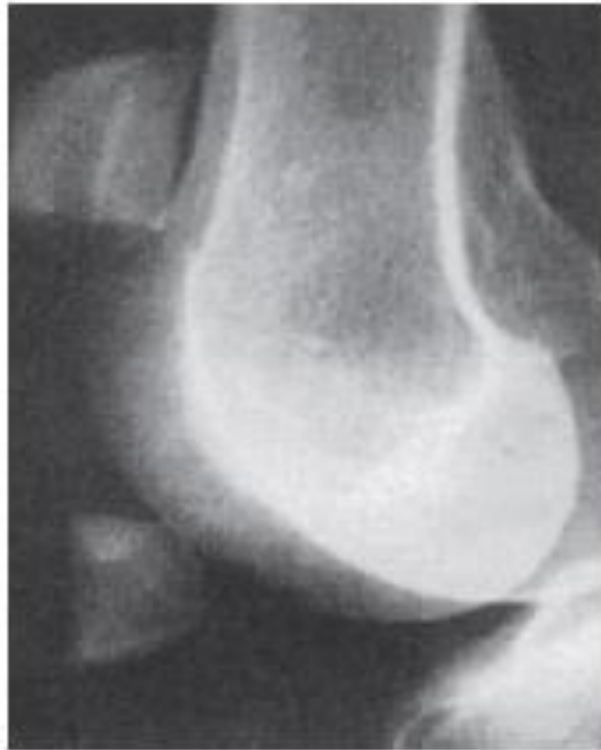

(c)

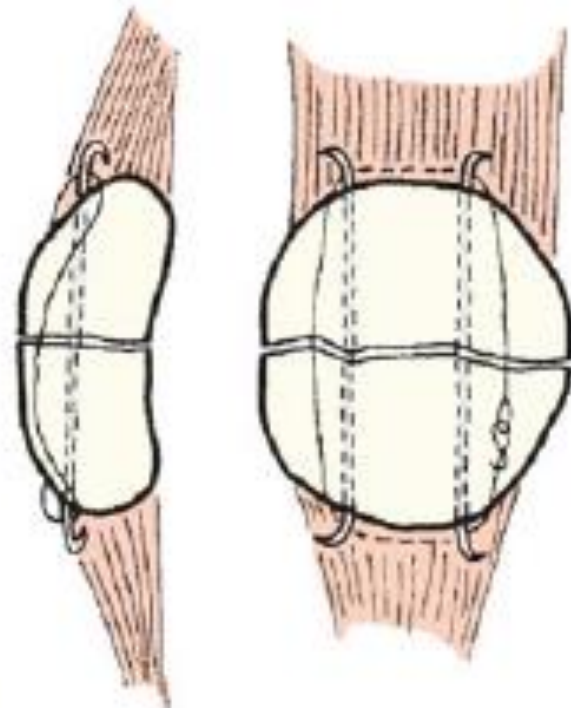


(d)

**30.14 Fractured patella – stellate** (a,b) A fracture with little or no displacement can be treated conservatively by a posterior slab of plaster that is removed several times a day for gentle active exercises. (c,d) With severe comminutions, patellectomy is arguably the best treatment, although some surgeons would consider preserving as many useful fragments as possible.

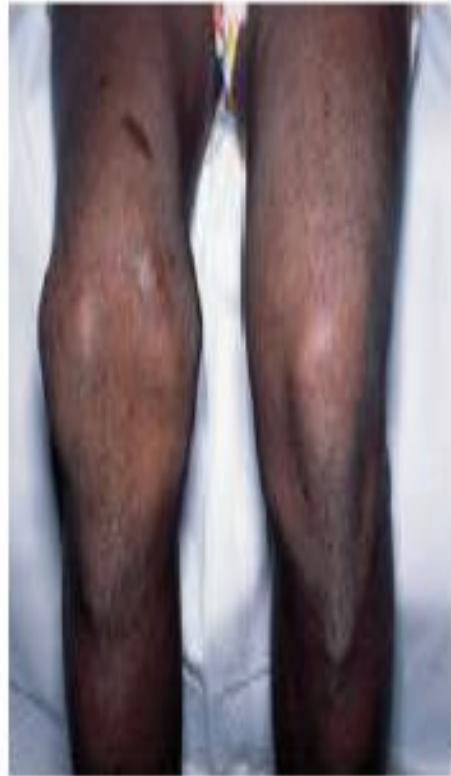

(a)

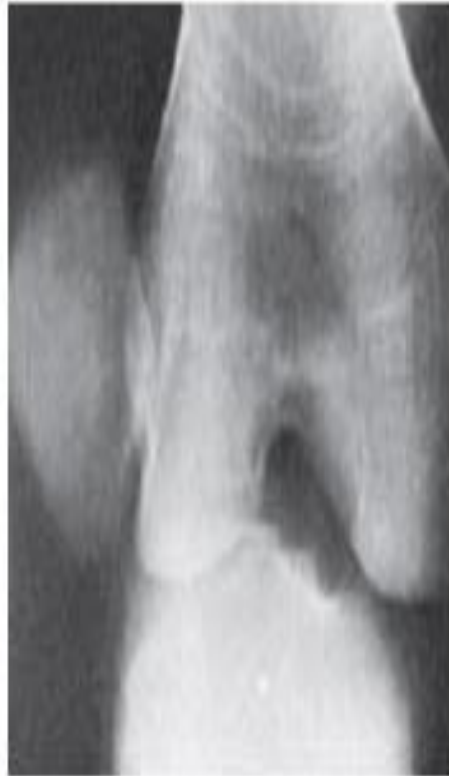

(b)

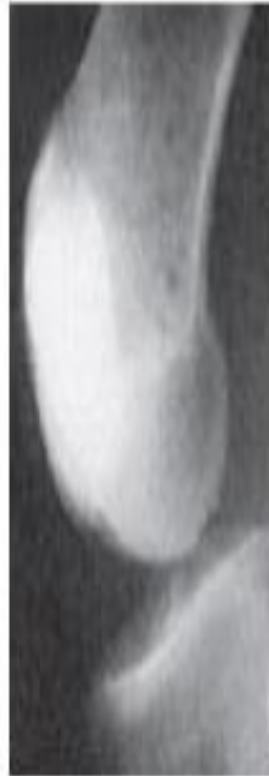**30.15 Fractured patella – transverse** The separated fragments (a) are transfixed by K-wires; (b) malleable wire is then looped around the protruding ends of the K-wires and tightened over the front of the patella.



(a)



(b)

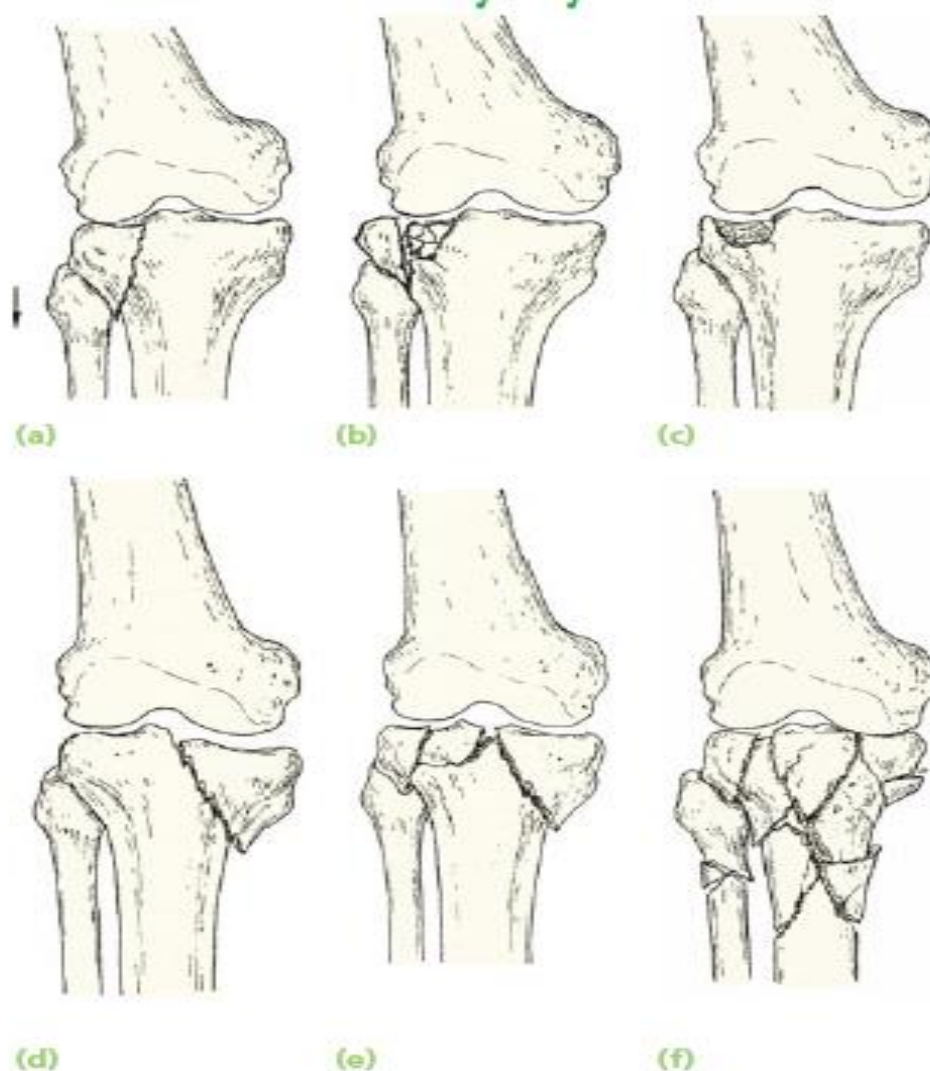


(c)

### 30.16 Dislocation of the patella (a)

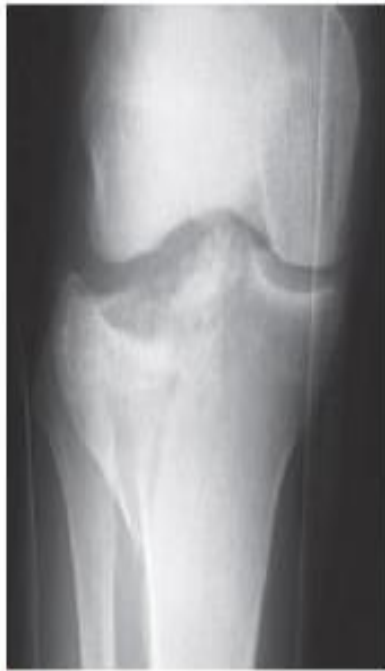The right patella has dislocated laterally; the flattened appearance is typical.

(b,c) Anteroposterior and lateral films of traumatic dislocation of the patella.

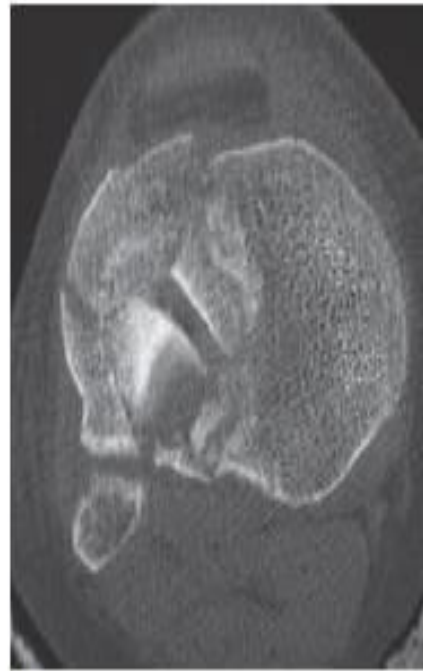

**30.17 Tibial plateau fractures** (a) Type 1 – simple split of the lateral condyle. (b) Type 2 – a split of the lateral condyle with a more central area of depression. (c) Type 3 – depression of the lateral condyle with an intact rim. (d) Type 4 – a fracture of the medial condyle. (e) Type 5 – fractures of both condyles, but with the central portion of the metaphysis still connected to the tibial shaft. (f) Type 6 – combined condylar and subcondylar fractures; effectively a disconnection of the shaft from the metaphysis.

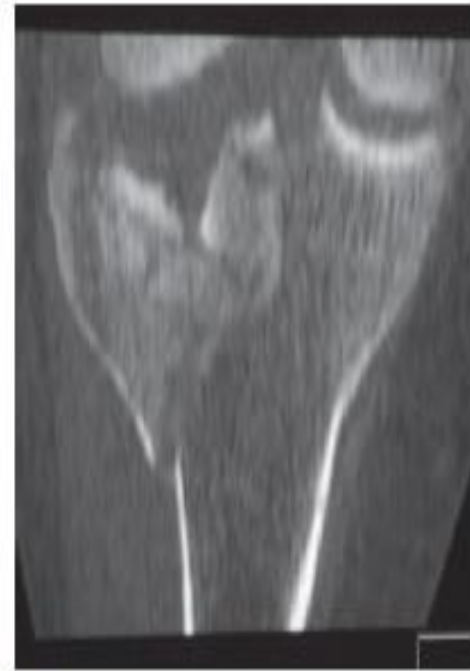



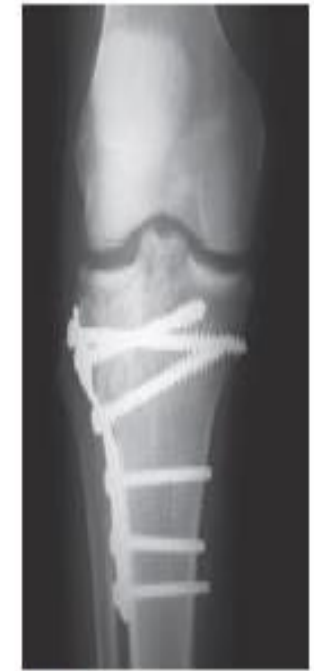(a)



(b)



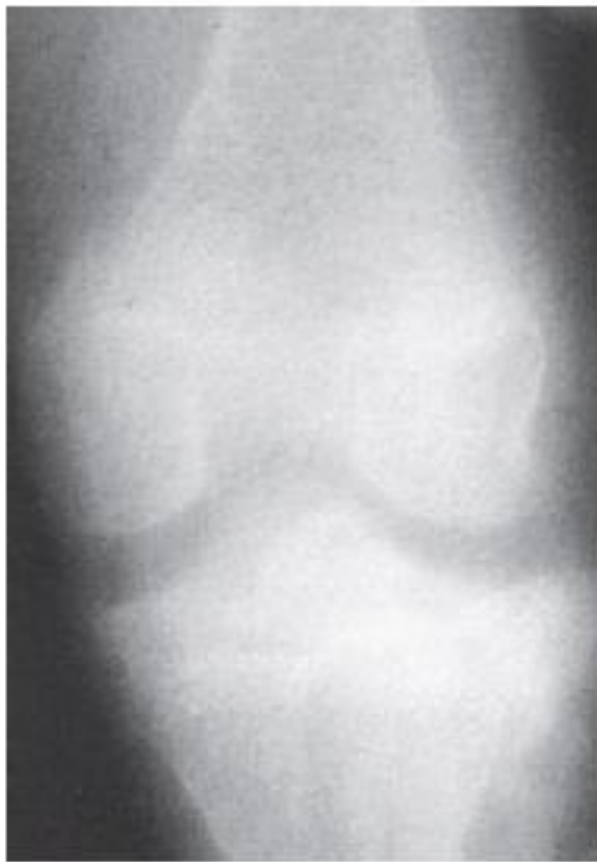(c)



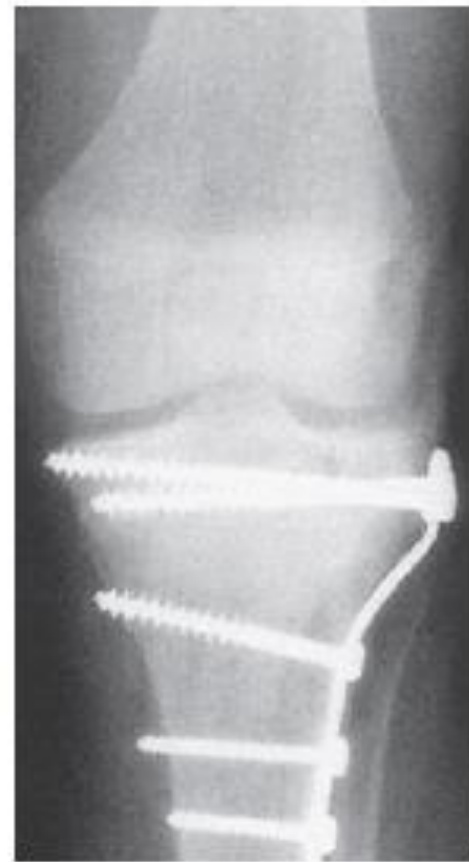
(d)

**30.18 Tibial plateau fractures – imaging** (a) X-rays provide information about the position of the main fracture lines and areas of articular surface depression. (b,c) CT reconstructions reveal the extent and direction of displacements, vital information for planning the operation. (d) The postoperative x-ray shows that perfect reduction has been achieved.



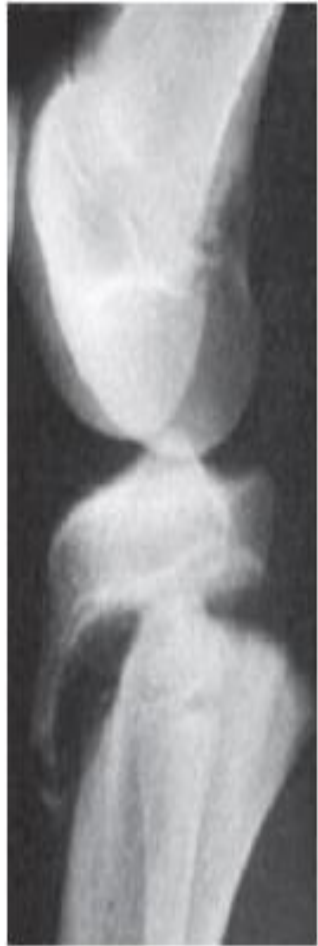


(a)

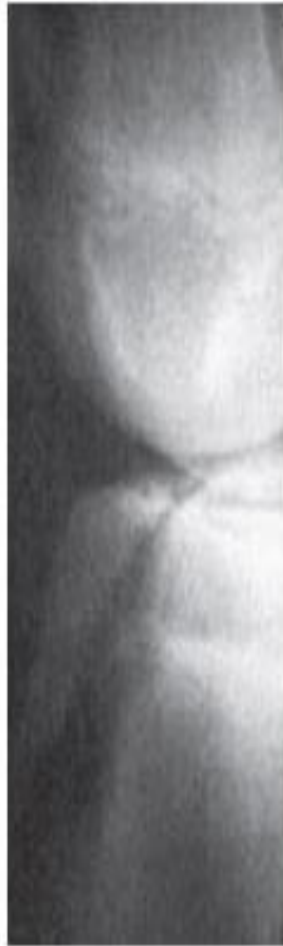

(b)

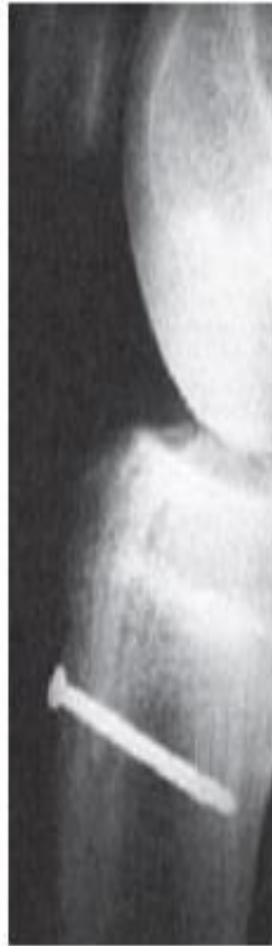**3.19 Tibial plateau fractures – fixation** (a) Tomography showed significant depression and some lateral displacement of the lateral condyle. (b) Open reduction and internal fixation with a buttress plate.



(a)



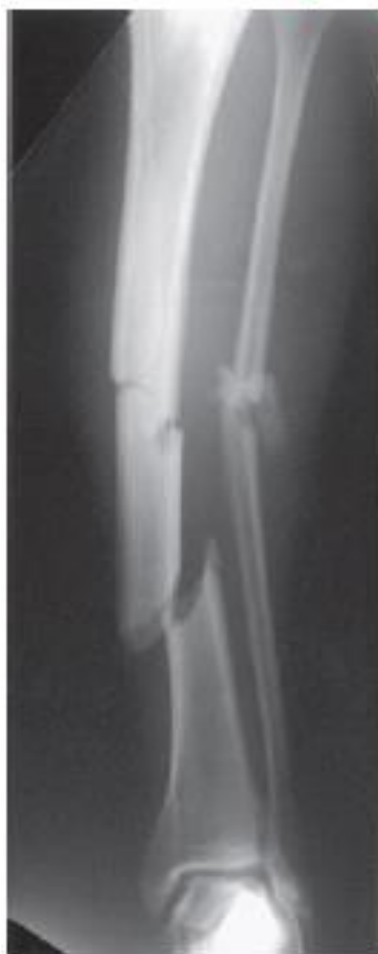(b)



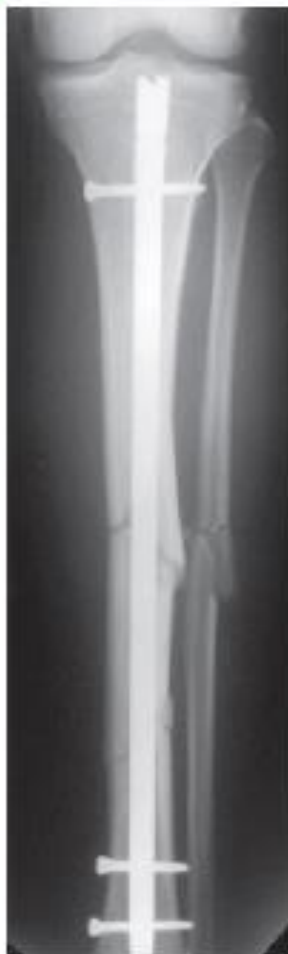(c)

### 30.25 Fracture-separation of proximal tibial epiphysis

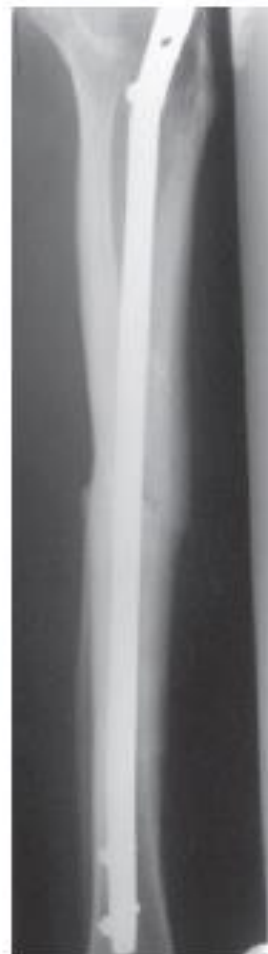(a) This hyperextension type of fracture needs urgent reduction because the popliteal vessels are endangered. (b) A flexion type of fracture-separation, but essentially a Salter-Harris type 4 pattern; in this case reduction was held with internal fixation (c).



(a)



(b)

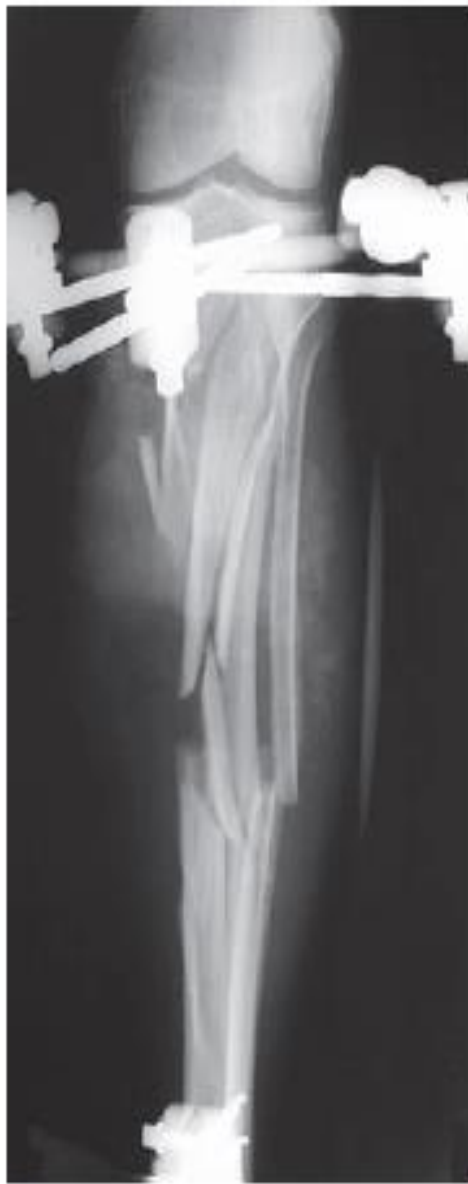

(c)

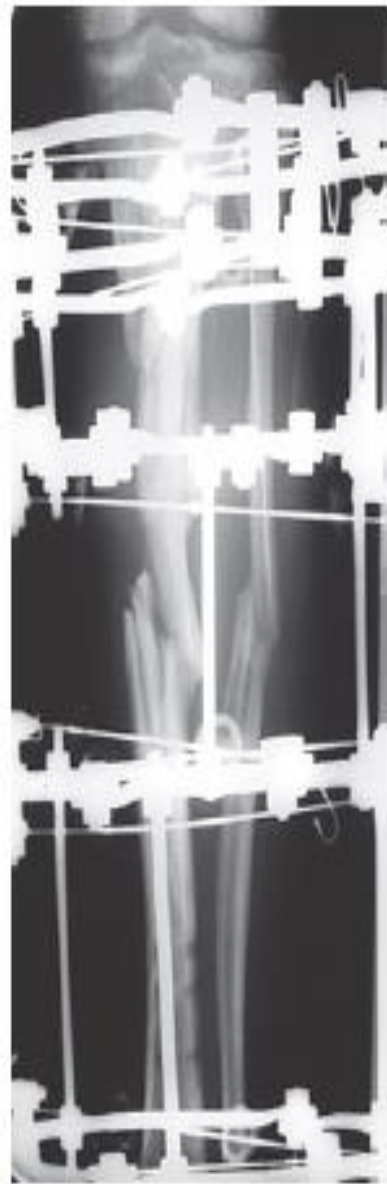### 30.28 Fractured tibia and fibula – intramedullary

**nailing** Closed intramedullary nailing is now the preferred treatment for unstable tibial fractures. This series of x-rays shows the fracture before (a) and after (b,c) nailing.

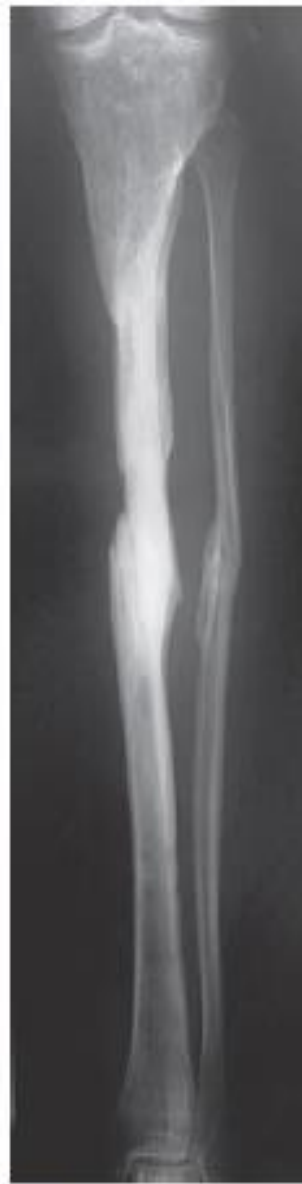Active movements and partial weightbearing were started soon after operation.



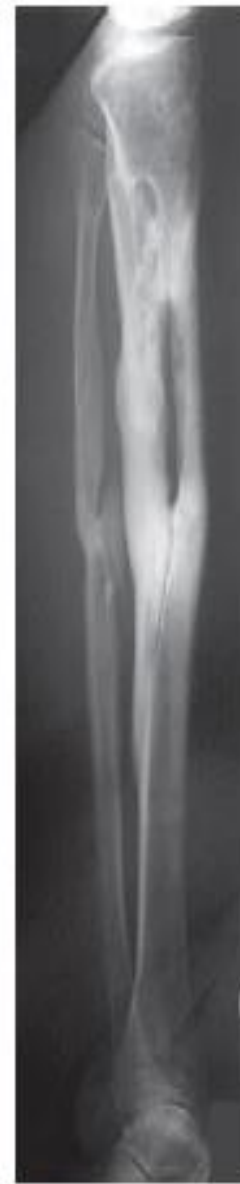(a)



(b)



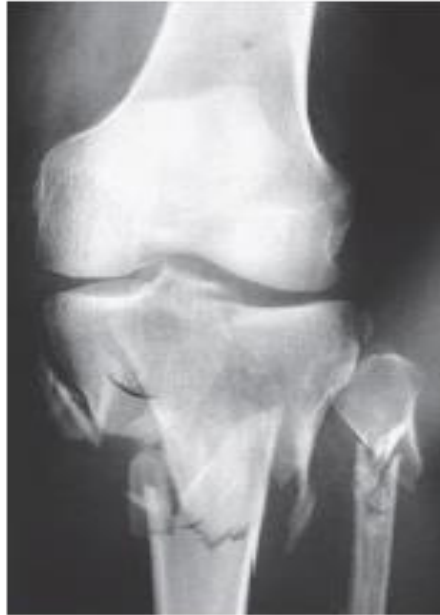(c)



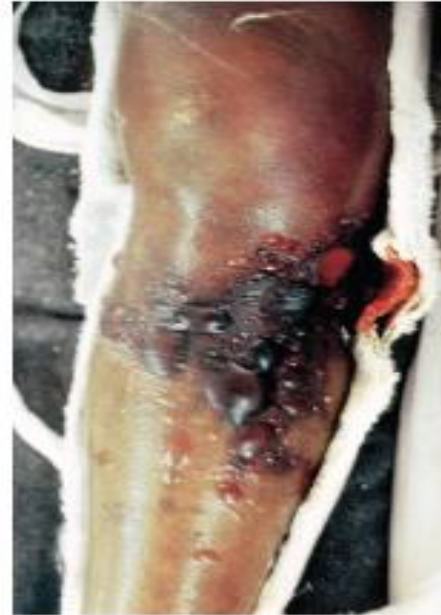(d)

### 30.29 Fixation (a-d)

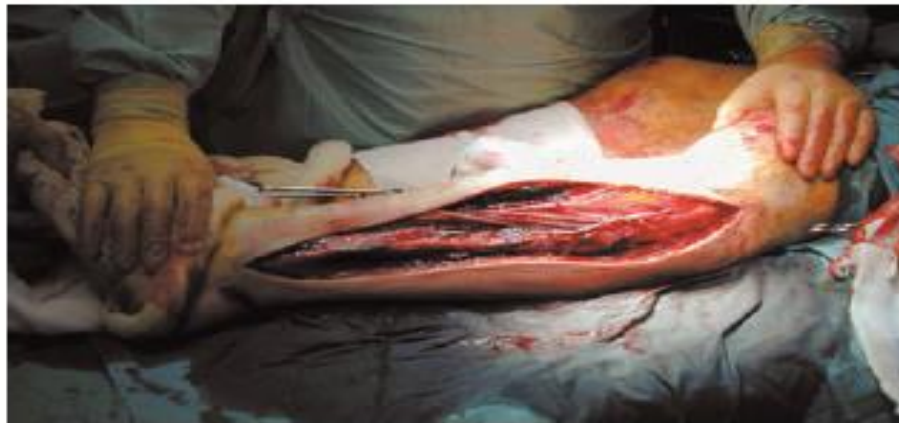This method of fixation offers the benefit of multilevel stability and can be carried out with little additional damage to the soft tissues around the injury.



(a)



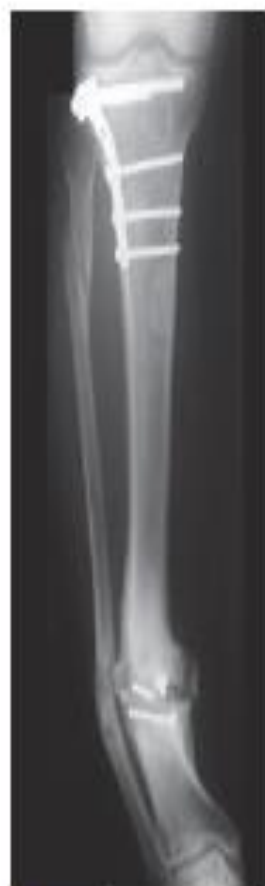(b)



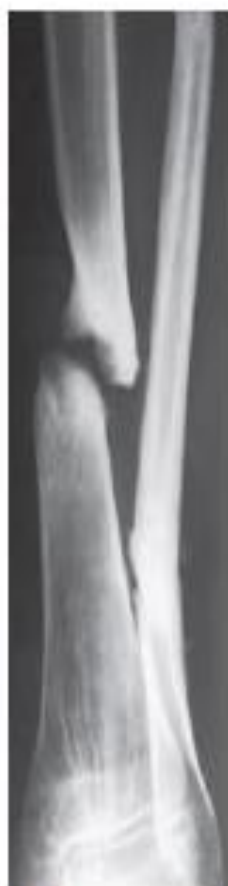(c)

**30.30 Compartment syndrome** (a) With a fracture at this level the surgeon should be constantly on the alert for symptoms and signs of a compartment syndrome. This patient was treated in plaster. Pain became intense and when the plaster was split (which should have been done immediately after its application), the leg was swollen and blistered (b). Tibial compartment decompression (c) requires fasciotomies of all the compartments in the leg.

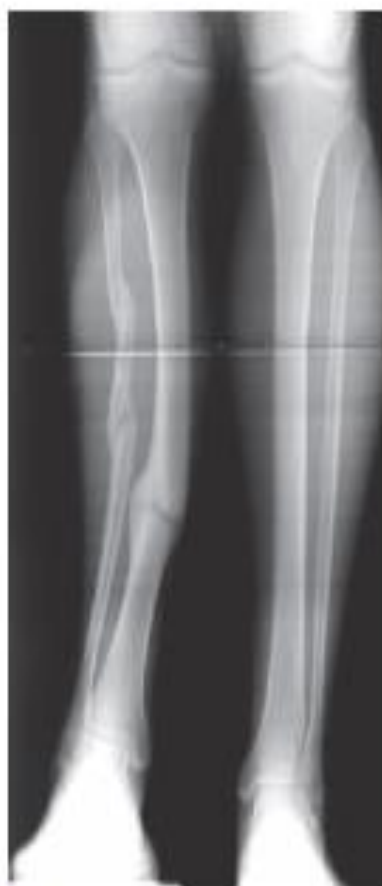



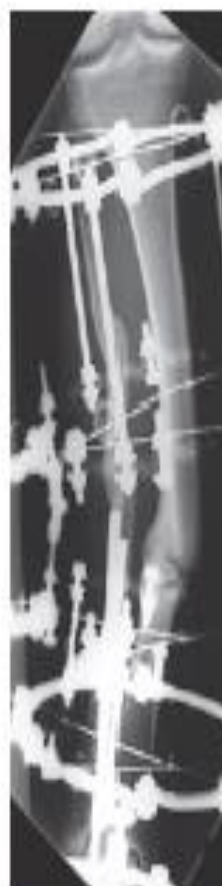(a)



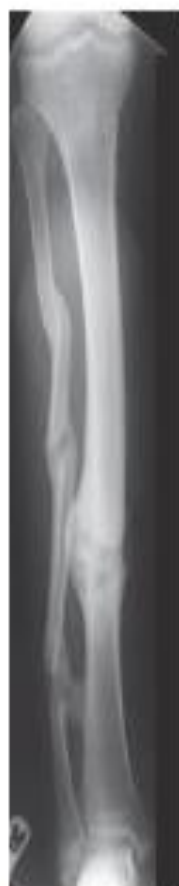(b)



(c)



(d)

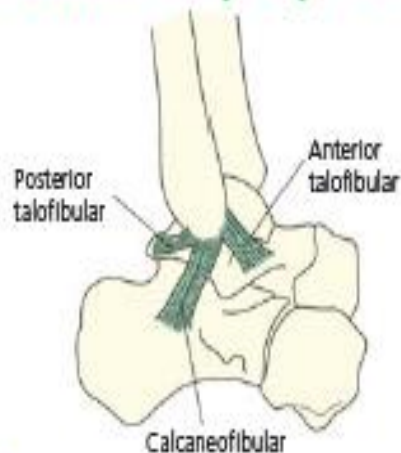


(e)

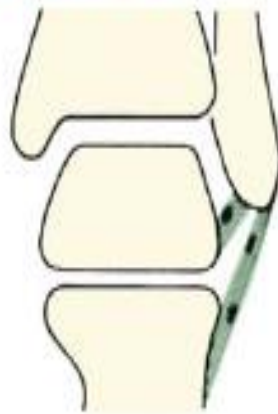
### 30.32 Fractured tibia and fibula – late complications

(a) *Hypertrophic non-union*: the exuberant callus formation and frustrated healing process are typical. (b) *Atrophic non-union*: there is very little sign of biological activity at the fracture site. (c) *Malunion*: treated, in this case, by gradual correction in an Ilizarov fixator (d,e).

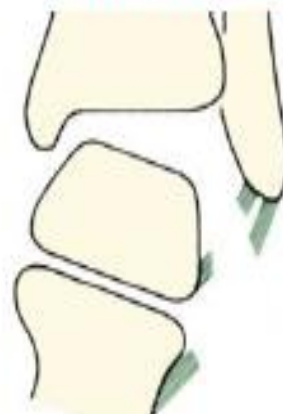
## ANATOMY OF THE ANKLE



(a)



(b)



(c)

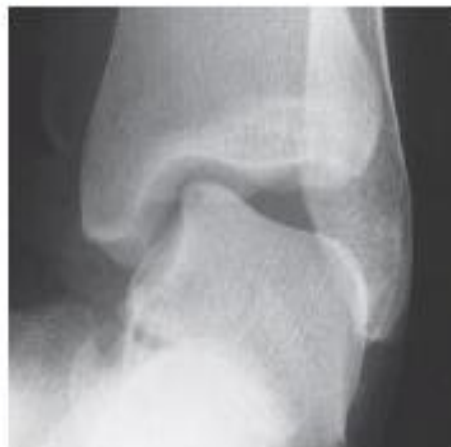## 31.1 Ankle ligament injuries

(a) Schematic diagram showing the mortise-and-tenon articulation and main ligaments of the ankle.

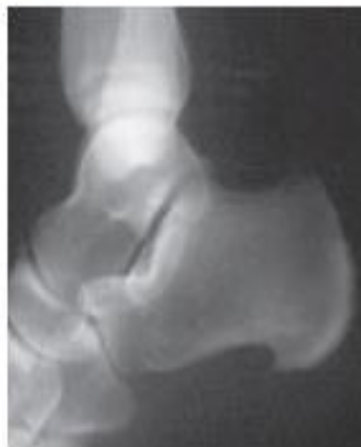(b) The three components of the lateral collateral ligament. (c) The commonest injury is a partial tear of one or other component of the lateral ligament. Following a complete tear, the talus may be displaced in the ankle mortise; the tibiofibular ligament may have ruptured as well, shown here in somewhat exaggerated form.

(d) Stress x-ray showing talar tilt.

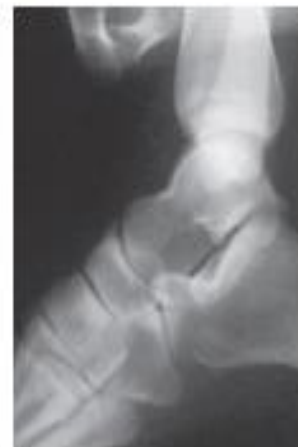(e,f) X-rays demonstrating anteroposterior instability. Pulling the foot forward under the tibia causes the talus to shift appreciably at the ankle joint; this is usually seen after recurrent sprains.



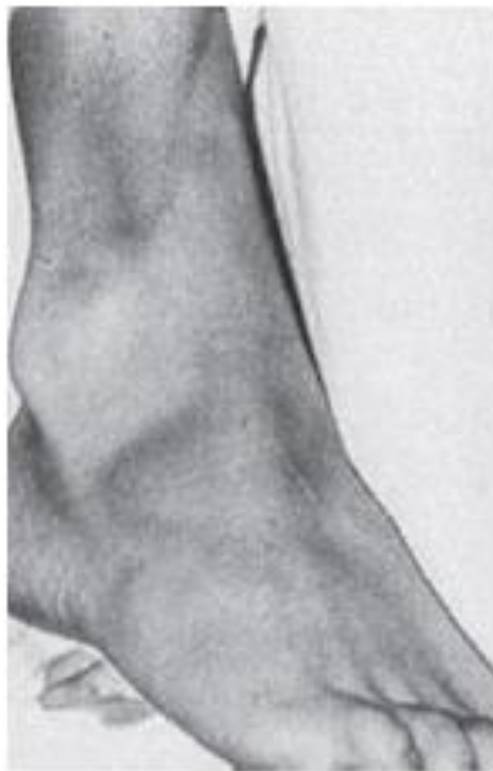(d)



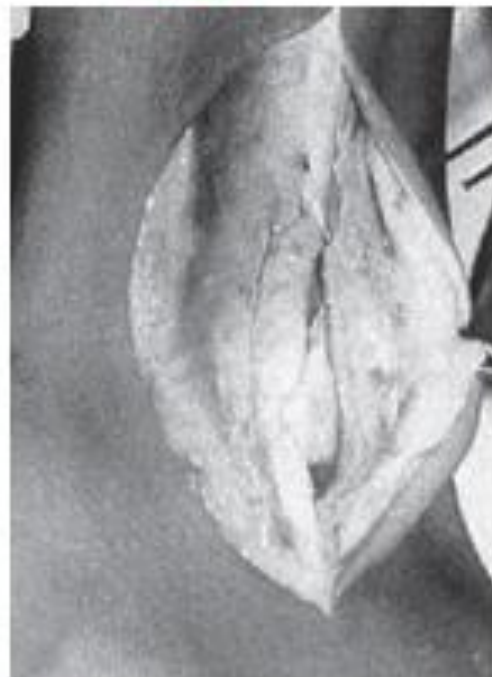(e)



(f)

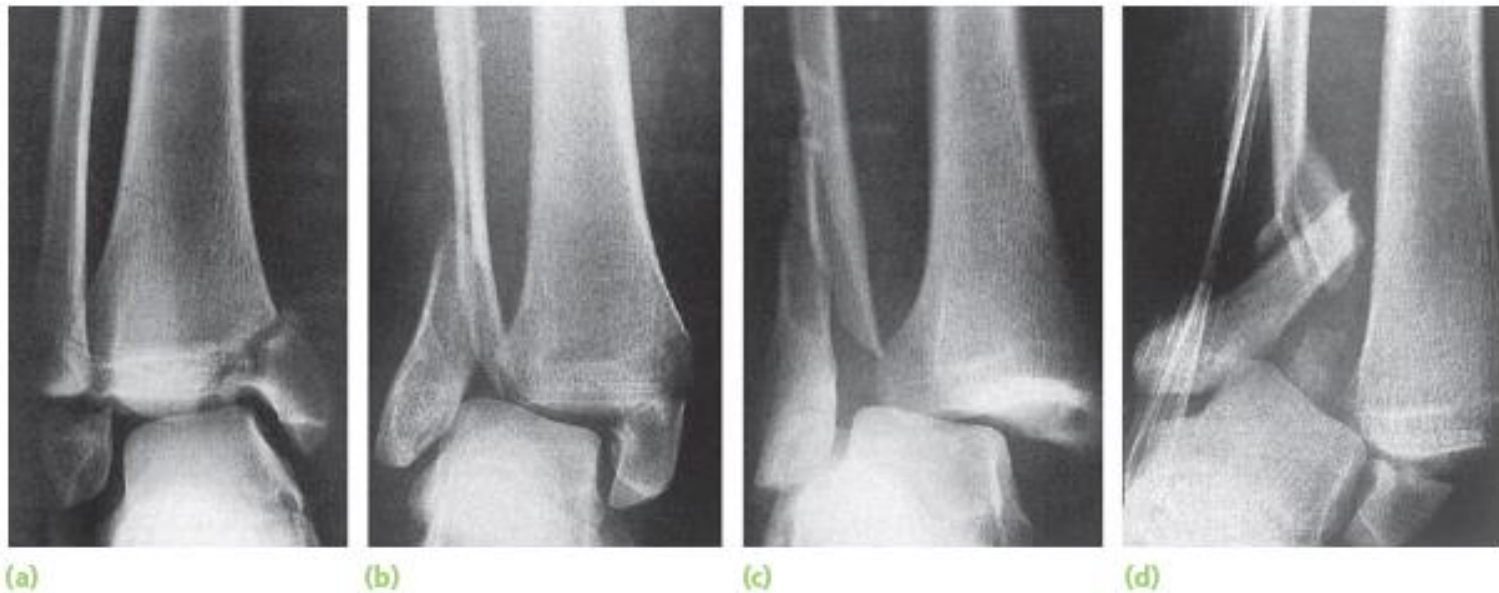
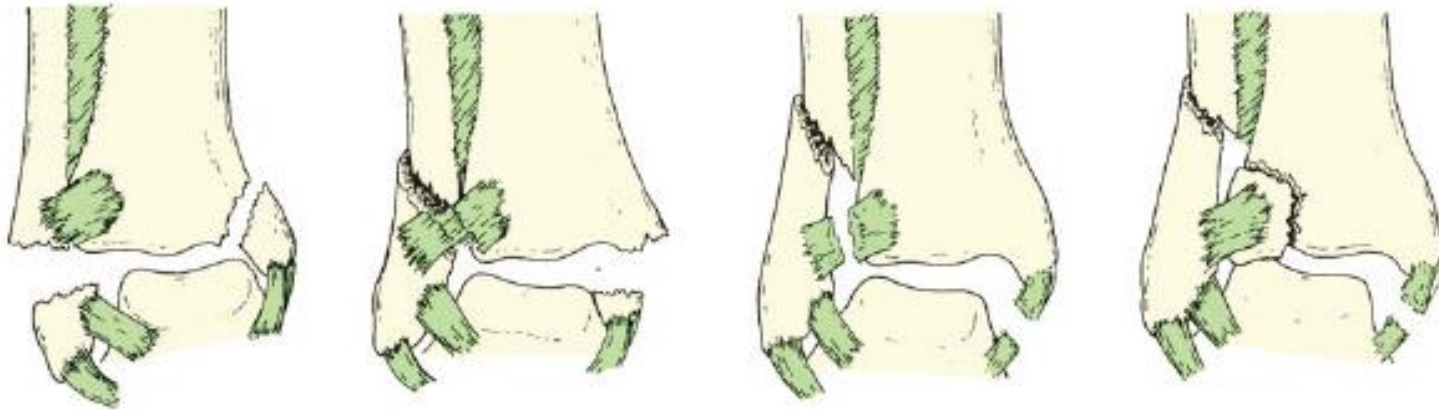


(a)

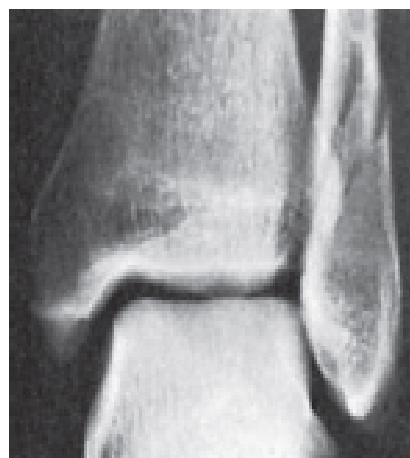

(b)

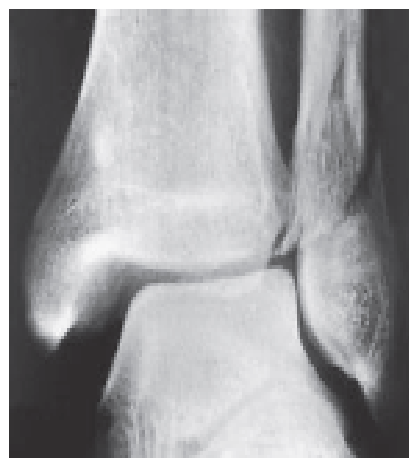**31.4 Dislocation of peroneal tendons** (a) On movement of the ankle, the peroneal tendons slip forwards over the lateral malleolus. (b) The anterior part of the retinaculum is being reconstructed.



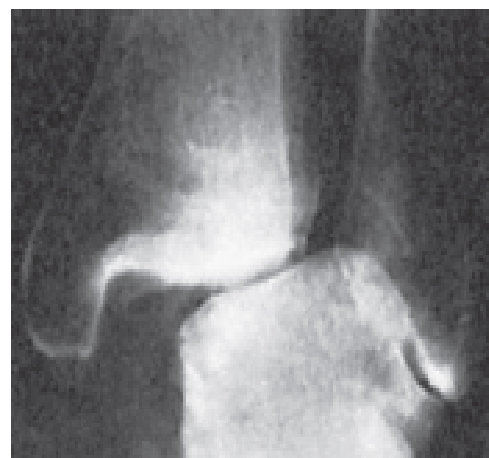**31.5 Ankle fractures – classification** The Danis–Weber classification is based on the level of the fibular fracture. **(a)** Type A – a fibular fracture below the syndesmosis and an oblique fracture of the medial malleolus (caused by forced supination and adduction of the foot). **(b)** Type B – fracture at the syndesmosis, often associated with disruption of the anterior fibres of the tibiofibular ligament and fracture of the posterior and/or medial malleolus, or disruption of the medial ligament (caused by forced supination and external rotation). **(c)** Type C – a fibular fracture above the syndesmosis; the tibiofibular ligament must be torn, or else **(d)** the ligament avulses a small piece of the tibia. Here, again, there must also be disruption on the medial side of the joint – either a medial malleolar fracture or rupture of the deltoid ligament.



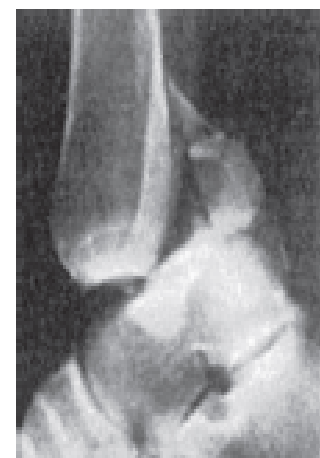(a)



(b)



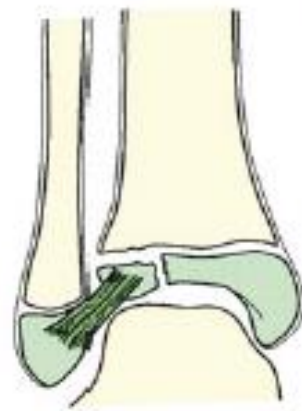
(c)



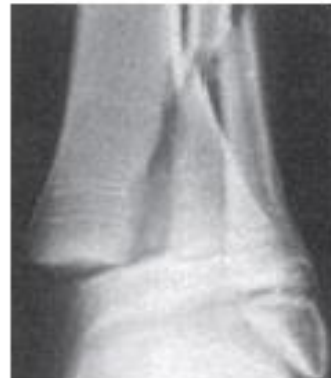(d)

**31.6 Ankle fractures – stable or unstable?** (a) *Stable fracture*: in this Danis–Weber type B fracture the tibiofibular syndesmosis has held; the surfaces of the tibia and talus are precisely parallel and the width of the joint space is regular both superiorly and medially. (b) *Slight subluxation*: the syndesmosis is intact but the talus has moved laterally with the distal fibular fragment; the medial joint space is too wide, signifying a deltoid ligament rupture. It is vital, after reduction of the fibular fracture, to check that the medial joint space is normal; if it is not, the ligament has probably been trapped in the joint and it must be freed so as to allow perfect re-positioning of the talus. (c) *Fracture–dislocation*: in this high fibular fracture the syndesmosis has given way, the medial collateral ligament has been torn and the talus is displaced and tilted. The fibula must be fixed to full length and the tibiofibular joint secured before the ankle can be stabilized. (d) *Posterior fracture–dislocation*: if the posterior margin of the tibia is fractured, the talus may be displaced upwards. The fragment must be replaced and fixed securely.

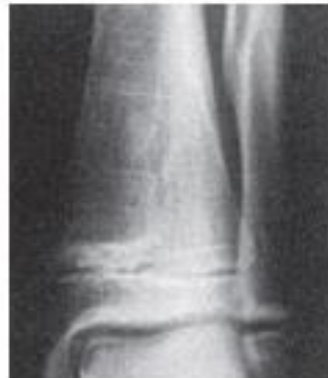



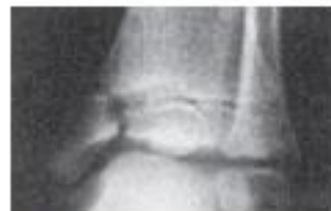**31.13 Tillaux fracture** Diagram illustrating the elements of this unusual injury.



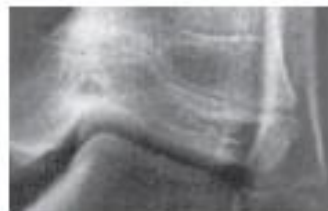(a)



(b)

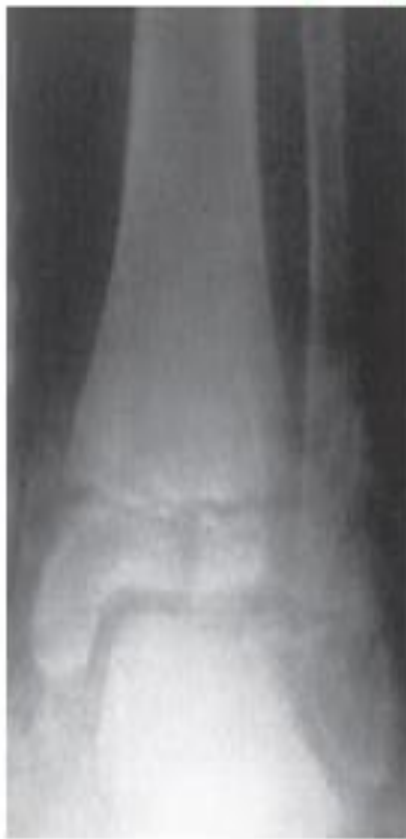

(c)

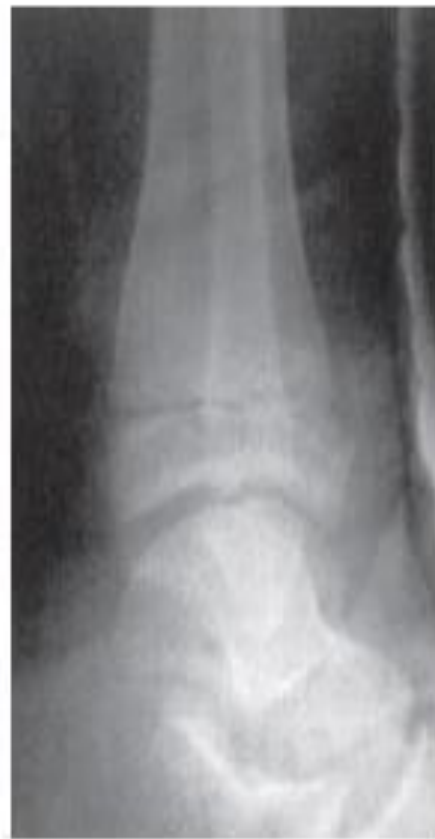

(d)

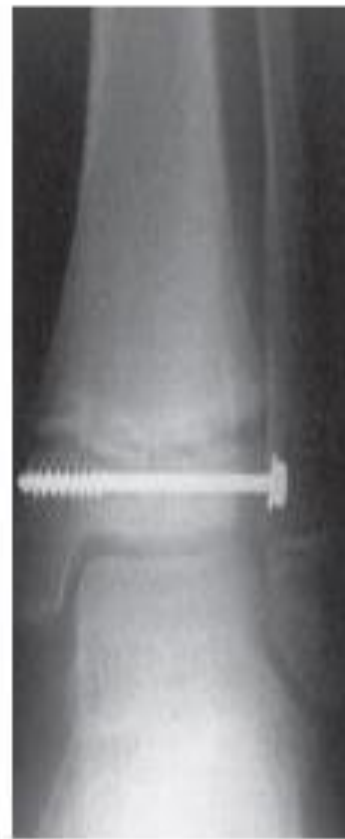**31.14 Ankle fractures in children** (a) Salter-Harris type 2 injury; after reduction (b) growth has proceeded normally. (c) Salter-Harris type 3 injury; (d) the medial side of the physis has fused prematurely, resulting in distorted growth.



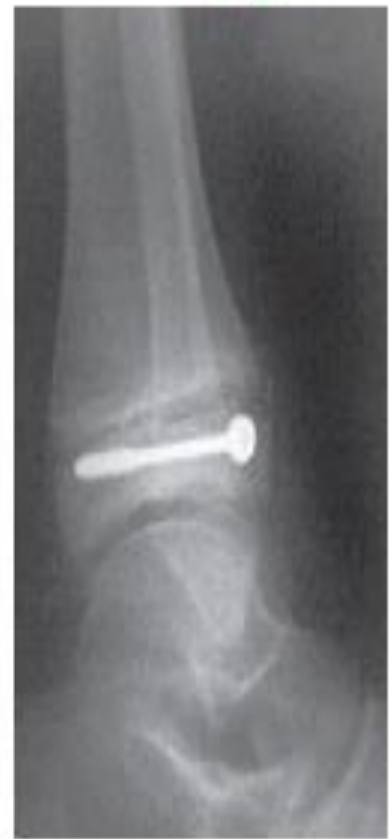(a)



(b)

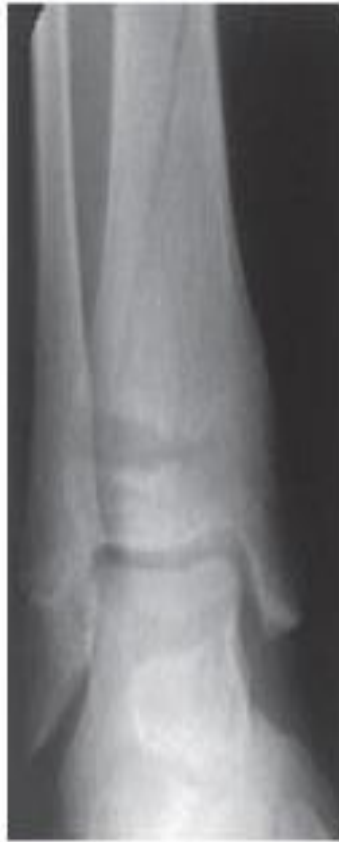

(c)

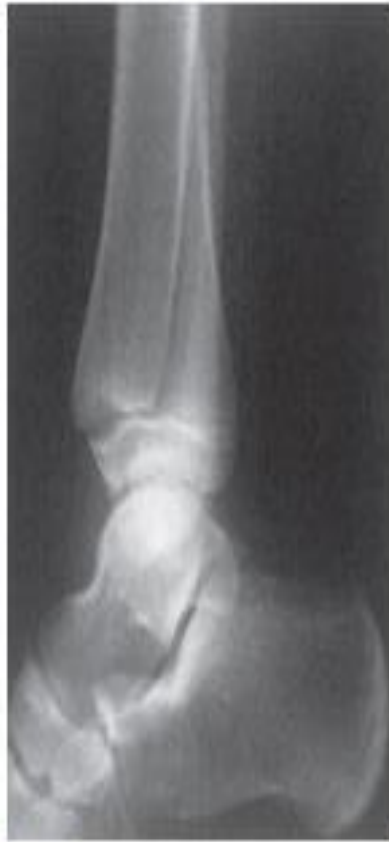

(d)

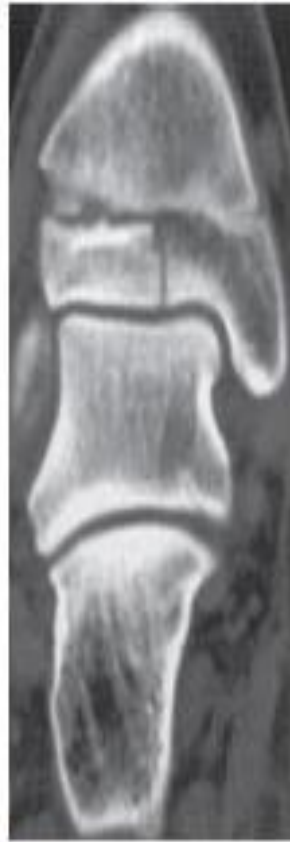**.15 Tillaux fracture (a,b)** This avulsion fracture of the lateral part of the physis was reduced and fixed percutaneously (c,d).



(a)

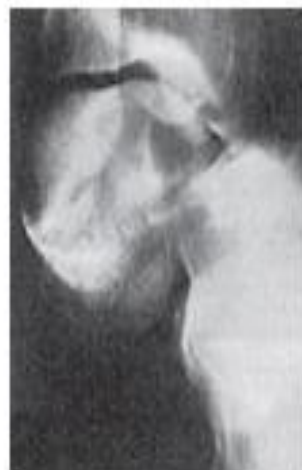

(b)

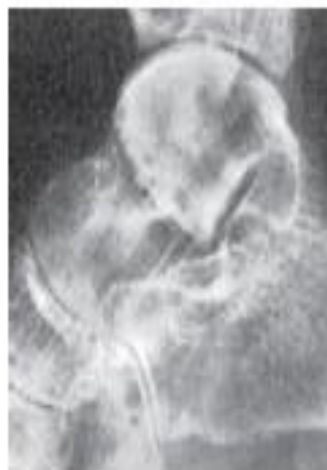

(c)

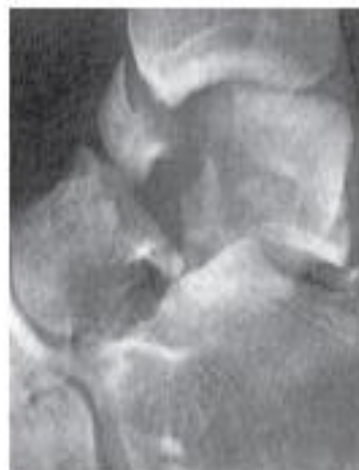**31.16 Triplane fracture** The three fracture planes may not be seen in a single x-ray, but can be visualized from a combination of images. In this case the epiphyseal fracture is clearly seen only in the coronal plane CT scan (c).



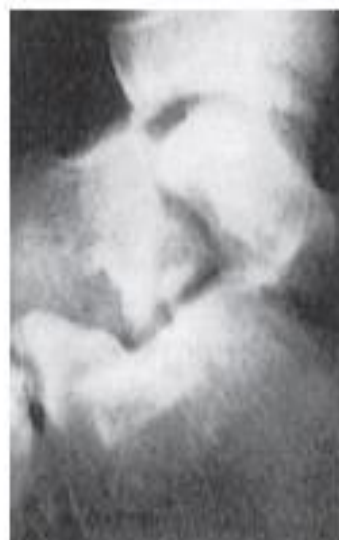(a)



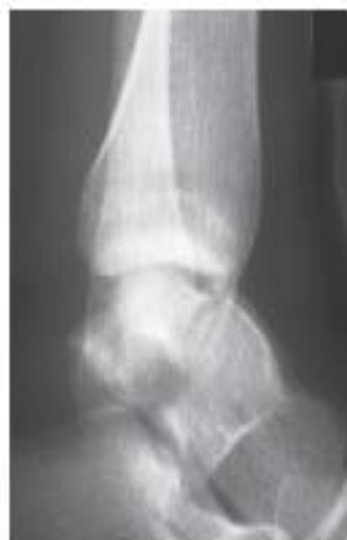(b)



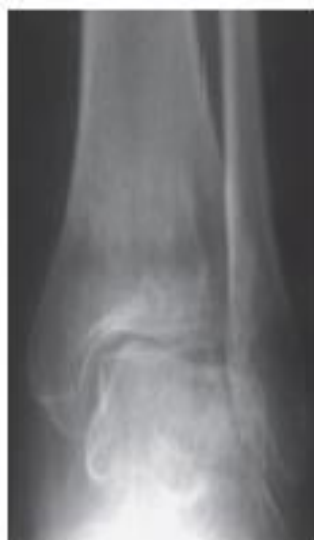(c)



(d)



(e)



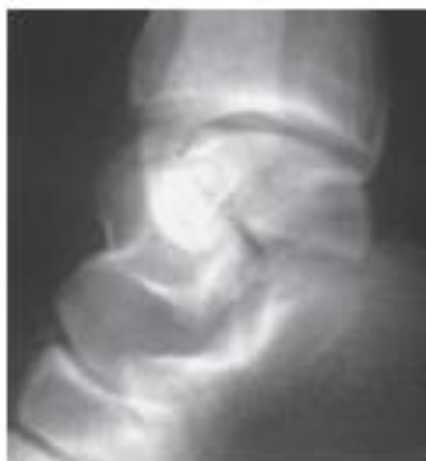(f)

### 31.18 Injuries of the talus-x-rays (a)

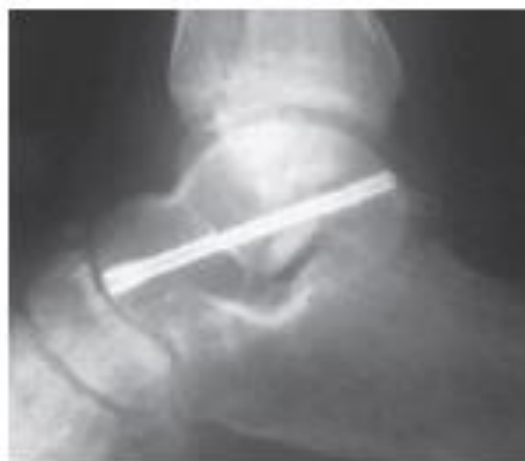Talocalcaneal fracture-dislocation.

(b) Undisplaced fracture of the talar neck.

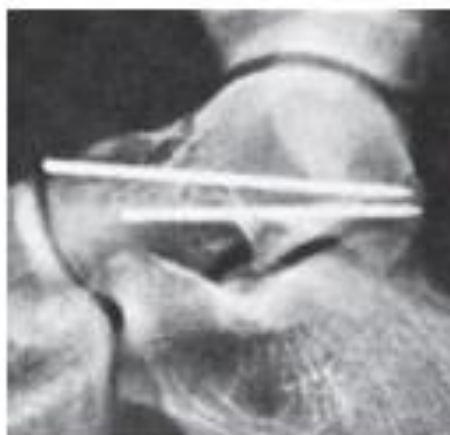(c) Type III fracture of the neck. (d) Displaced fracture of the body of the talus. (e) This fracture of the body was thought to be well reduced; however, in the AP view (f) it is possible to see two overlapping outlines, indicating that the fragments are malrotated.



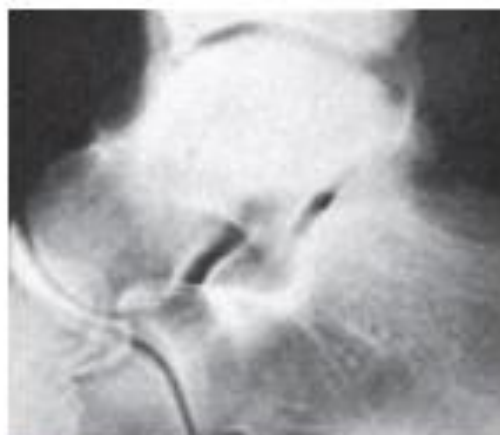
(a)



(b)



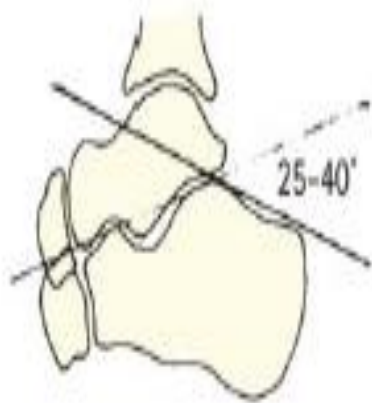
(c)



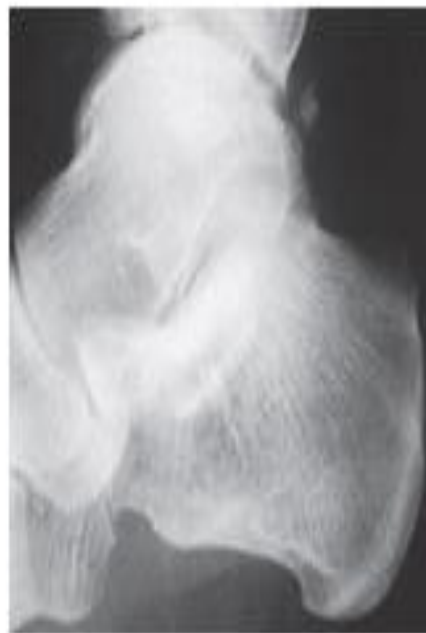
(d)

**31.19 Fractures of the talus – treatment** (a) This displaced fracture of the body was reduced and fixed with a countersunk screw (b), giving a perfect result. Fractures of the neck, even if well reduced (c) are still at risk of developing ischaemic necrosis (d).

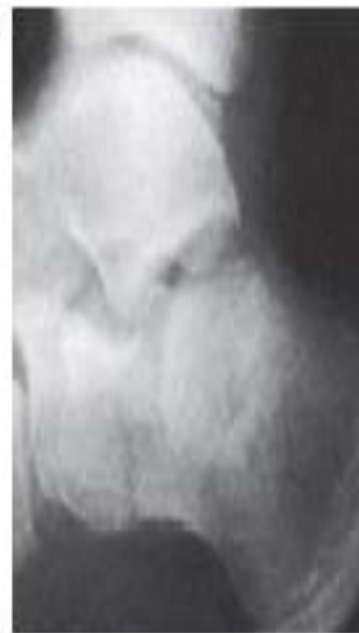



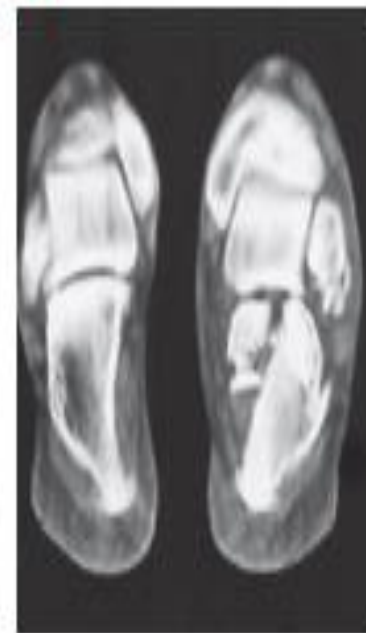(a)



(b)

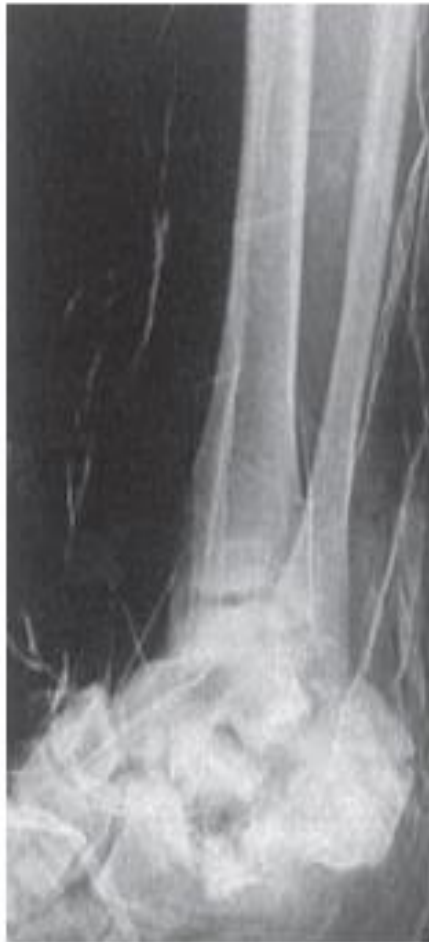

(c)

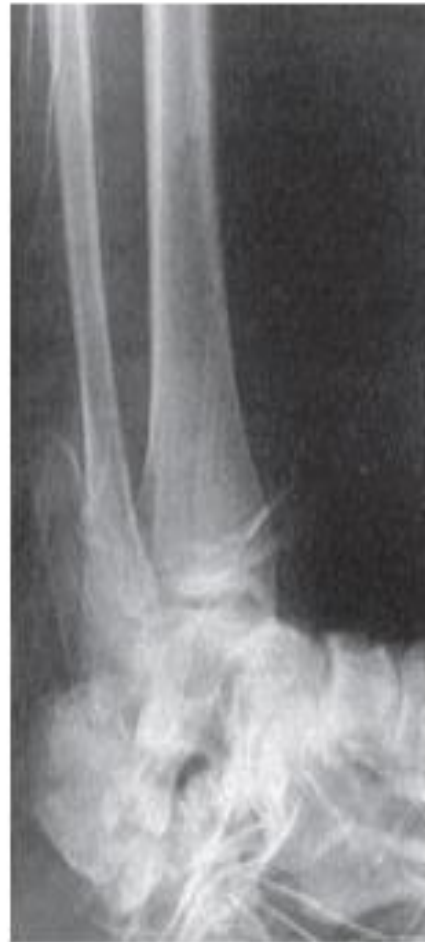

(d)

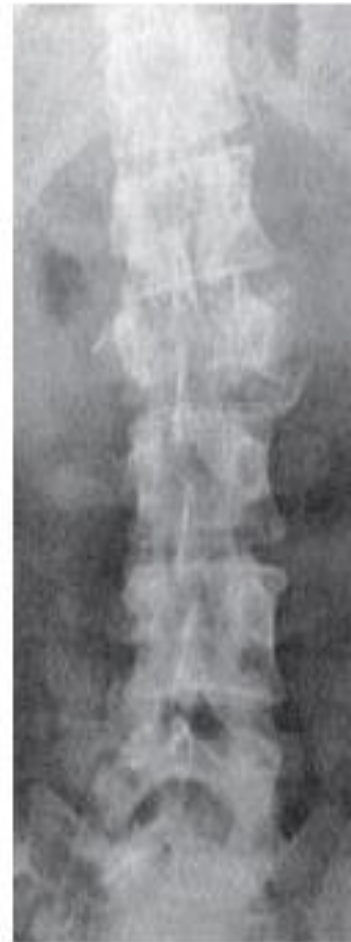**31.23 Fracture of the calcaneum – Imaging** (a,b) Measurement of Böhler's angle and the x-ray appearance in a normal foot. (c) Flattening of Böhler's angle in a fractured calcaneum. (d) The CT scan in this case shows how the articular fragments have been split apart.



(a)

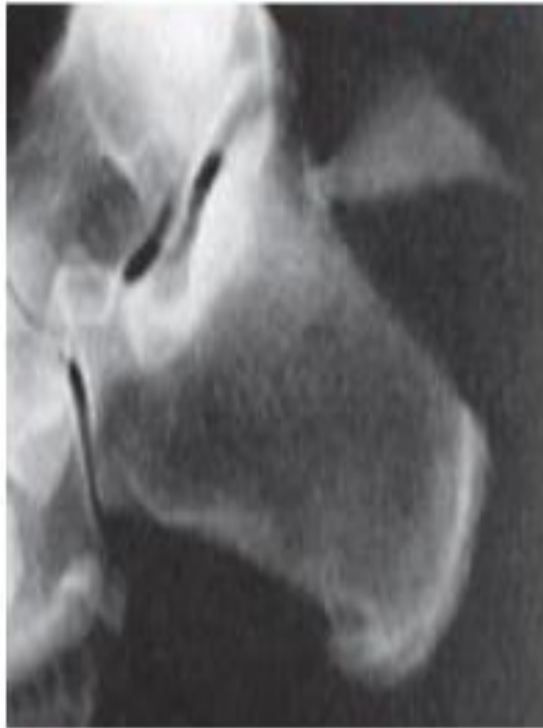

(b)

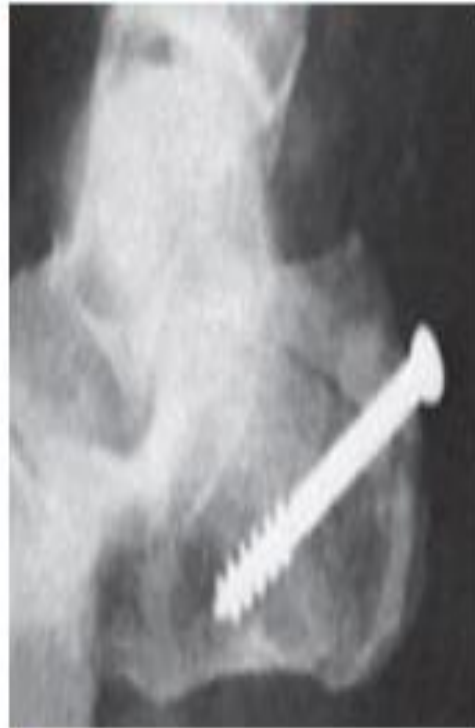

(c)

**31.24 Calcaneal fractures – imaging** Bilateral calcaneal fractures (a,b) are caused by a fall on the heels from a height or by an explosion from below. In either case the spine also may be fractured, as it was in this patient (c). With bilateral heel fractures, always x-ray the spine.

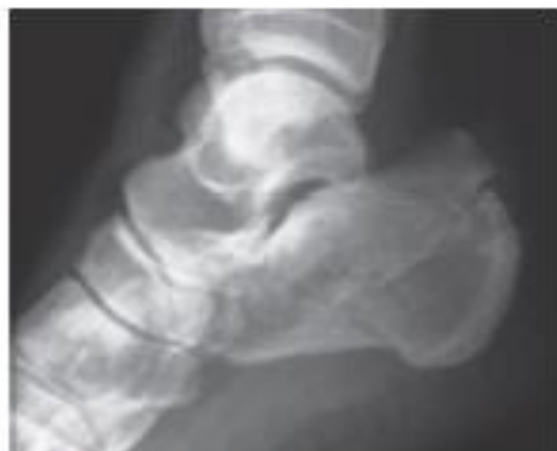

(a)

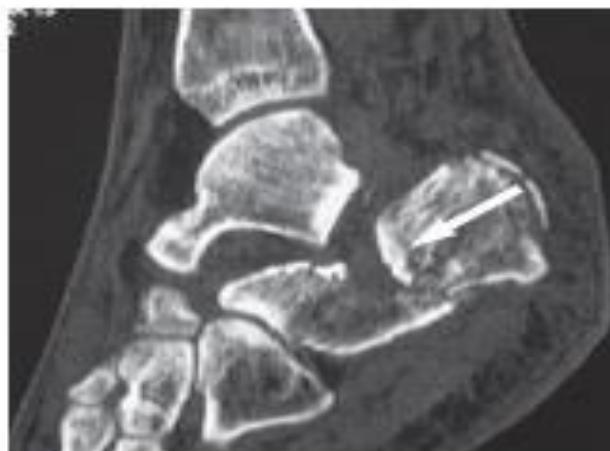

(b)

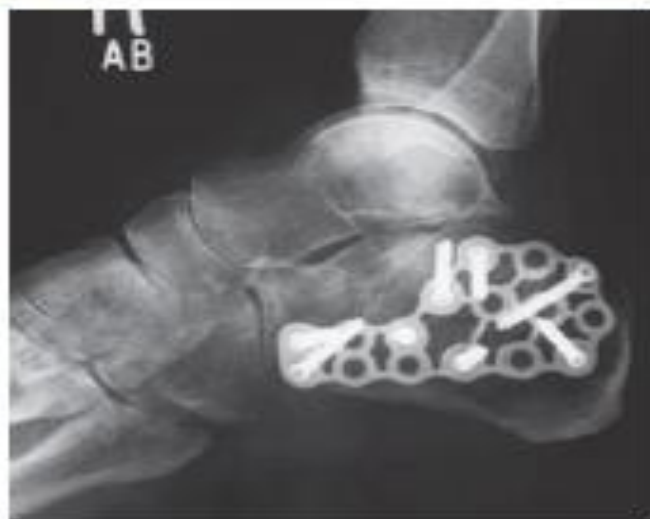31.25 Extra-articular calcaneal fractures -  
treatment (a) Avulsion fracture of posterolateral  
corner (b) fixed by a screw.



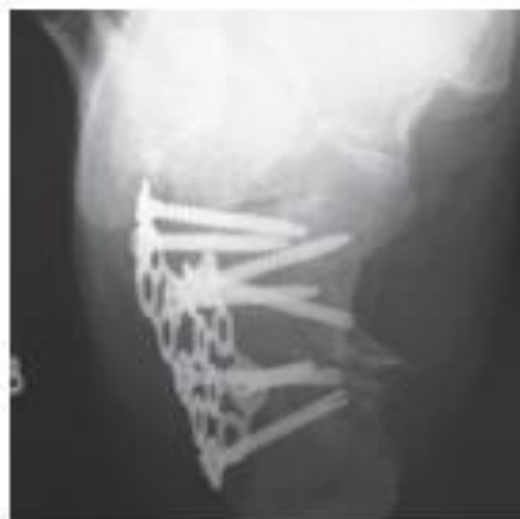(a)



(b)



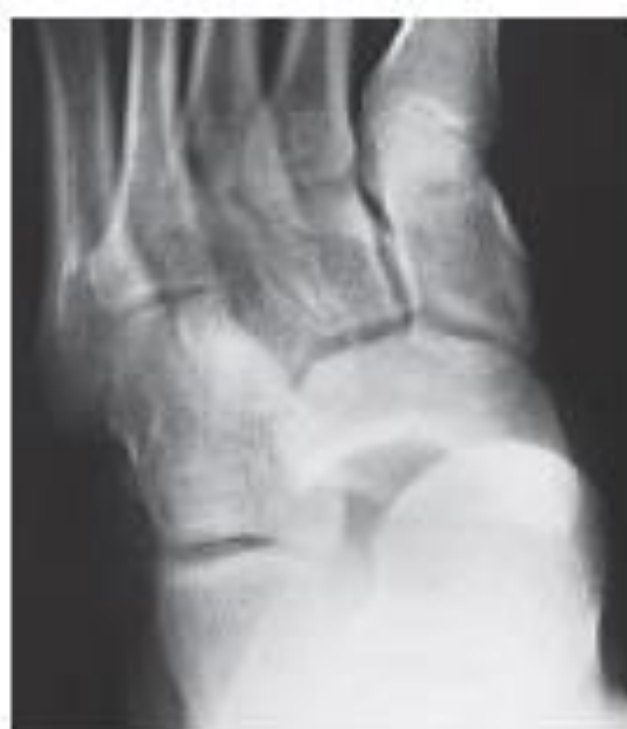(c)



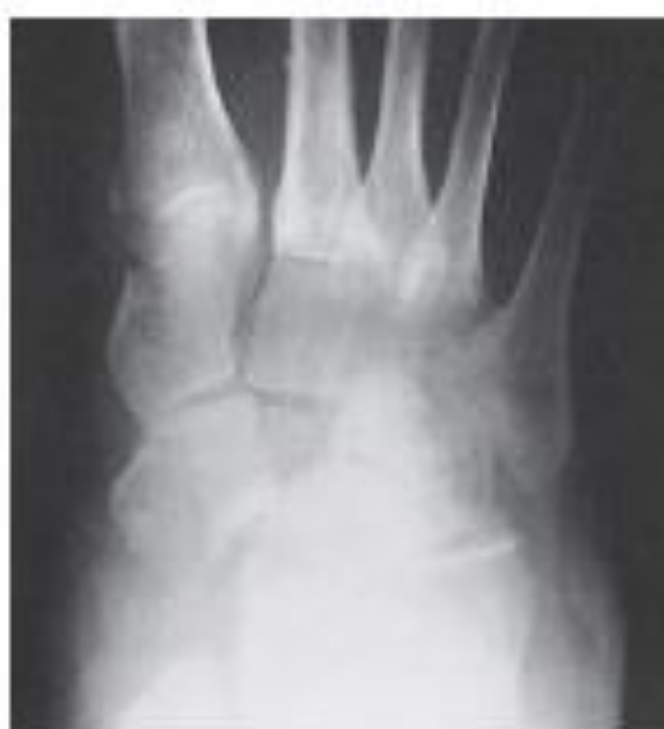(d)

### 31.26 Intra-articular calcaneal fracture – treatment

(a) X-ray gives limited information, but the CT (b) shows the severe depression of the posterior calcaneal facet. This was treated operatively with a calcaneal locking plate, to reconstitute the posterior facet (arrow) and restore the height of the calcaneum (c,d).



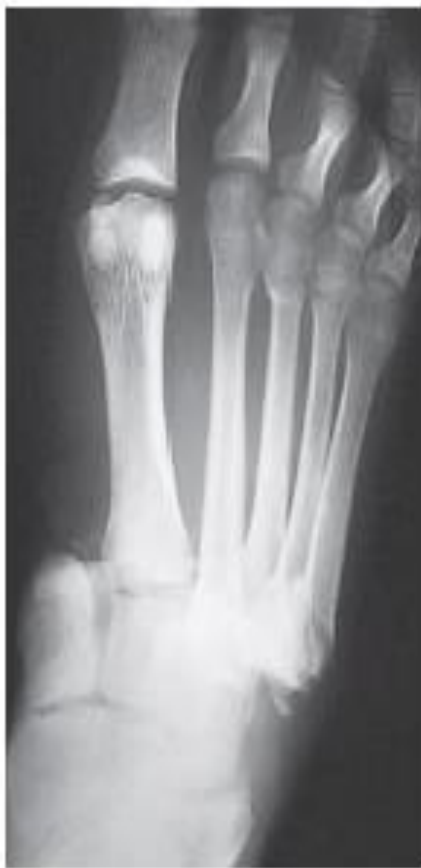(a)



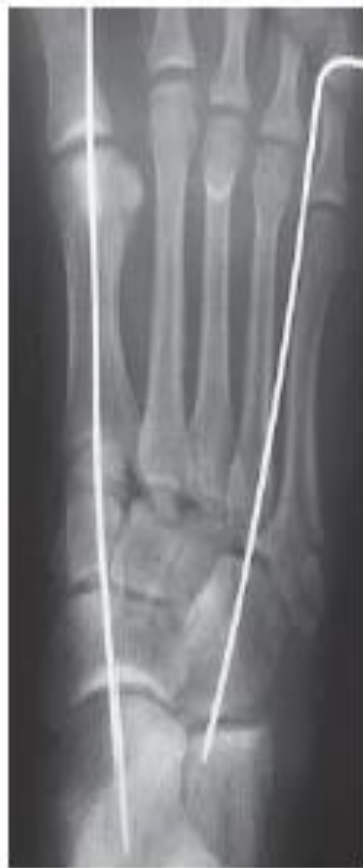(b)

**31.27 Midtarsal Injuries** (a) X-ray showing dislocation of the talonavicular joint. (b) X-ray on another patient showing longitudinal compression fracture of the navicular bone and subluxation of the head of the talus. This injury is often difficult to demonstrate accurately on plain x-ray.

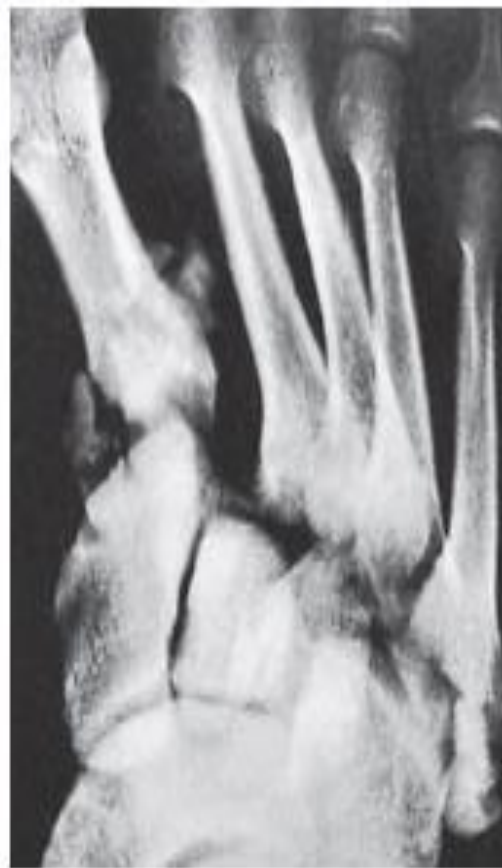



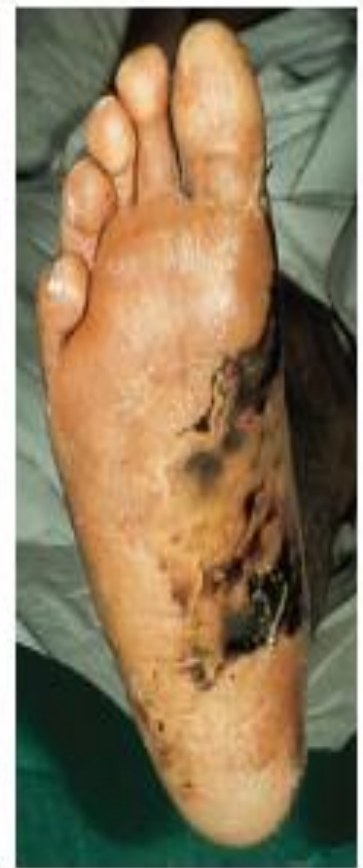(a)



(b)

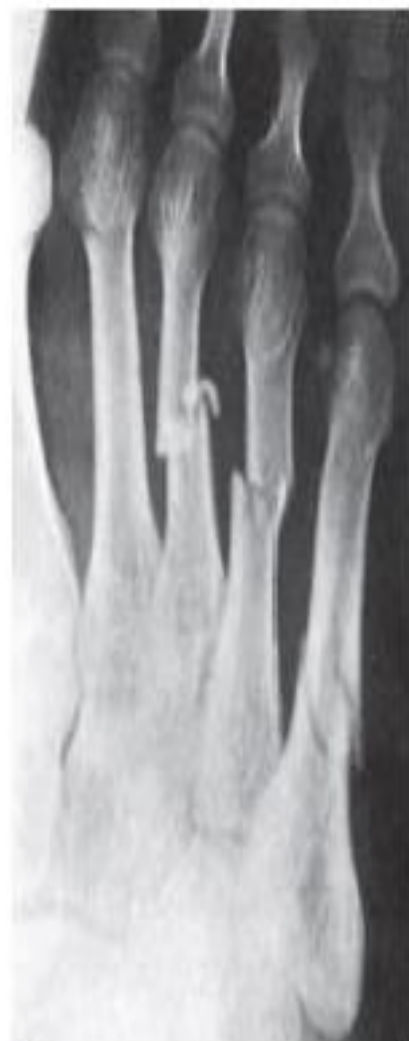

(c)

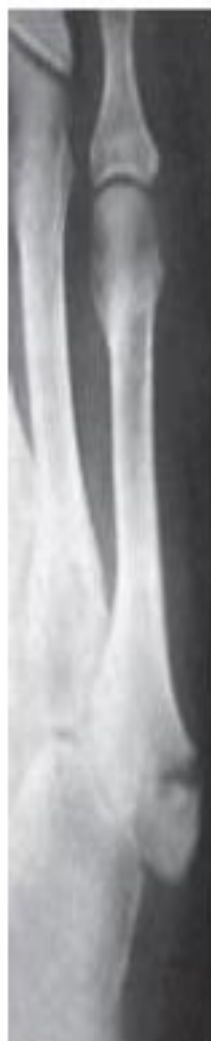

(d)

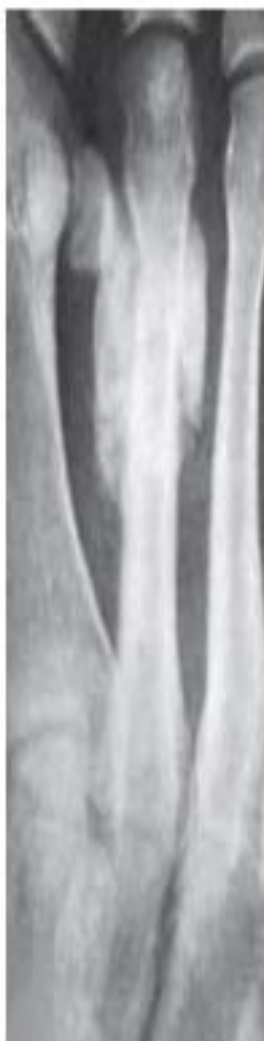**31.29 TMT injuries** (a) Dislocation of the TMT joints. (b) X-ray after reduction and stabilization with K-wires. (c) X-ray showing a high-energy fracture–dislocation involving the TMT joints. These are serious injuries that may be complicated by (d) compartment syndrome of the foot.



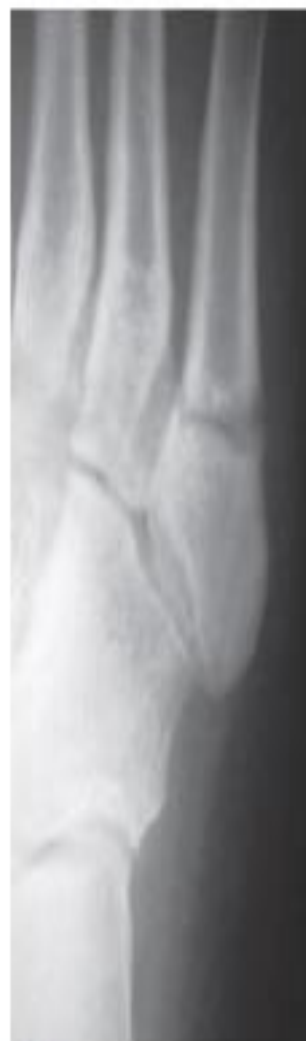(a)



(b)



(c)

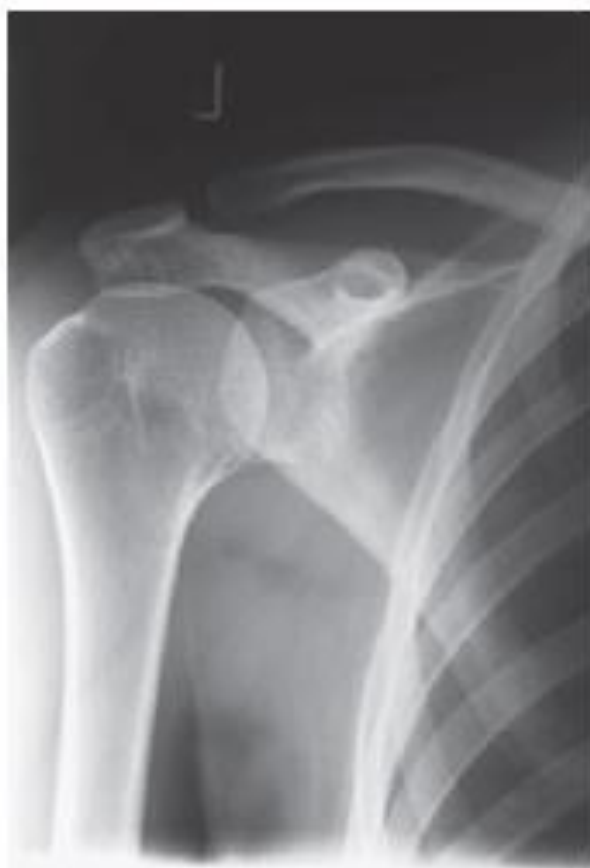

(d)

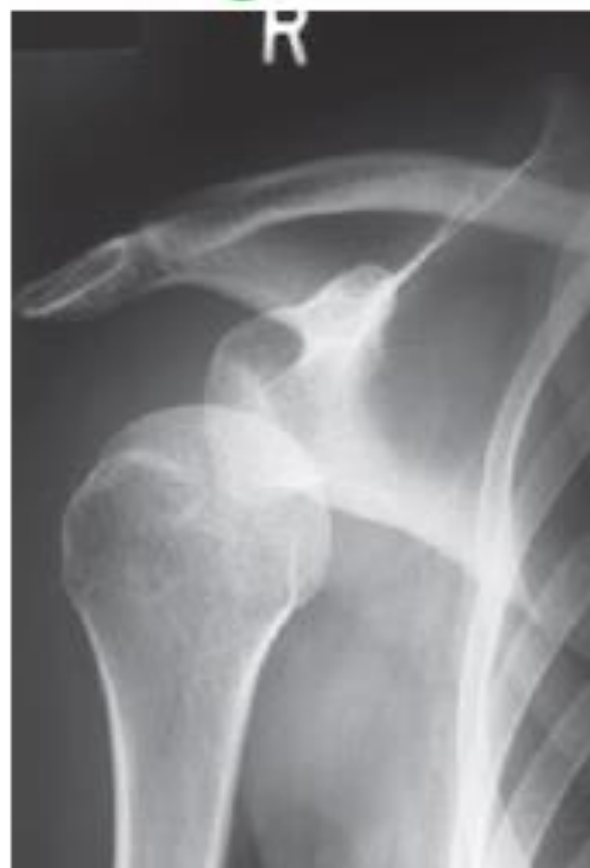### 31.30 Metatarsal Injuries

(a) Transverse fractures of three metatarsal shafts. (b) Avulsion fracture of the base of the fifth metatarsal – the pot-hole injury, or Robert Jones fracture.

(c) Flouid callus in a stress fracture of the second metatarsal. (d) Jones' fracture of the fifth metatarsal.

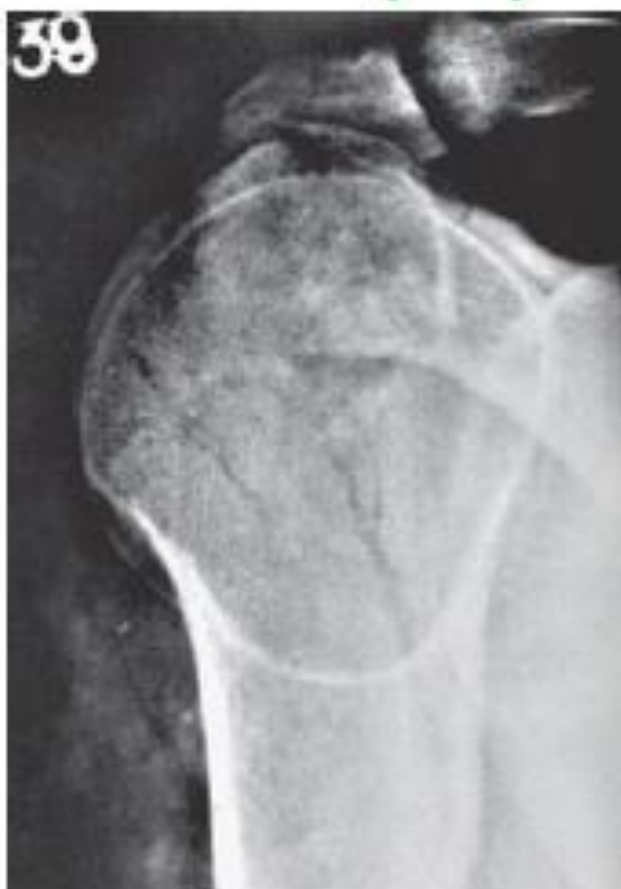

(a)

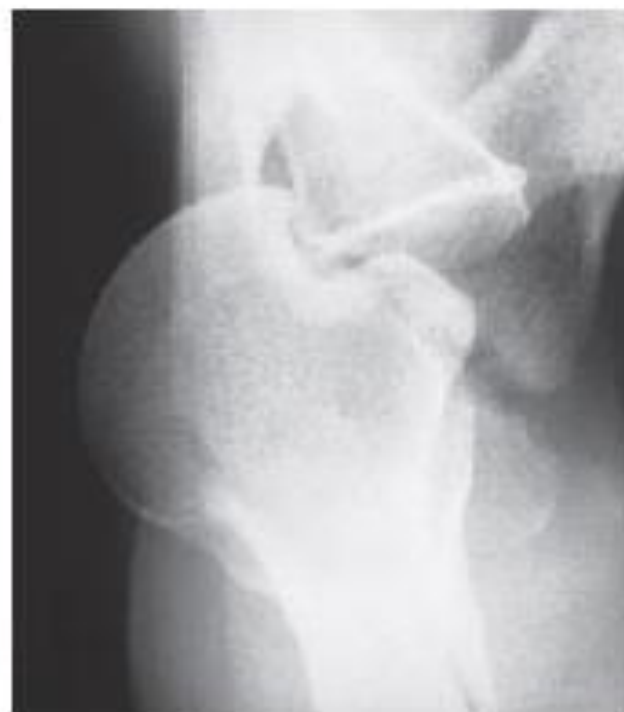

(b)

**13.25 Inferior subluxation** (a) X-ray of a young woman who developed 'clicking' and instability in the right shoulder after recovering from an injury to the neck and right upper limb. Plain x-ray examination showed no abnormality, but when the anteroposterior view was repeated with the patient carrying 15 kg weights in both hands, subluxation due to laxity of the anteroinferior capsule was demonstrated to the right side (b).

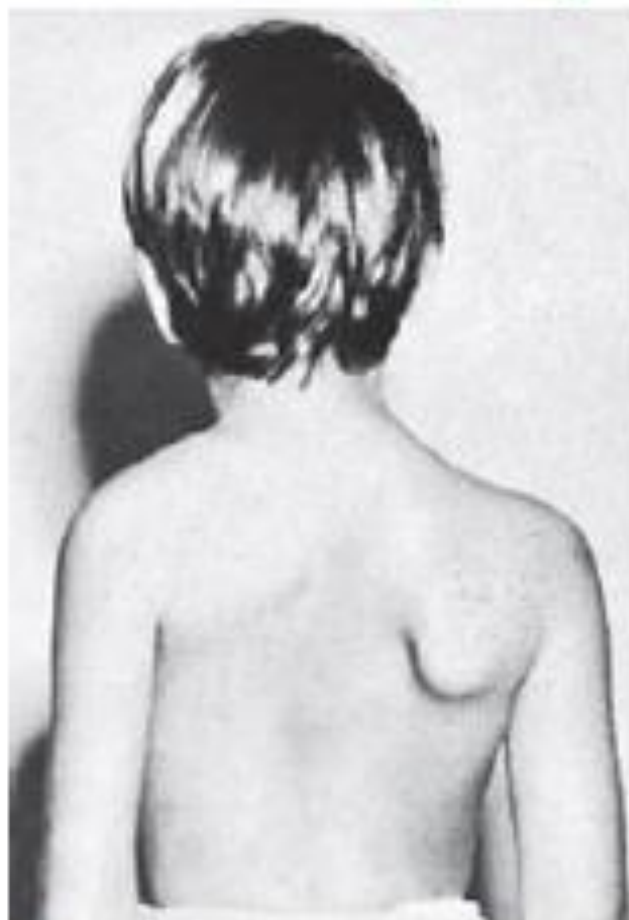


(a)

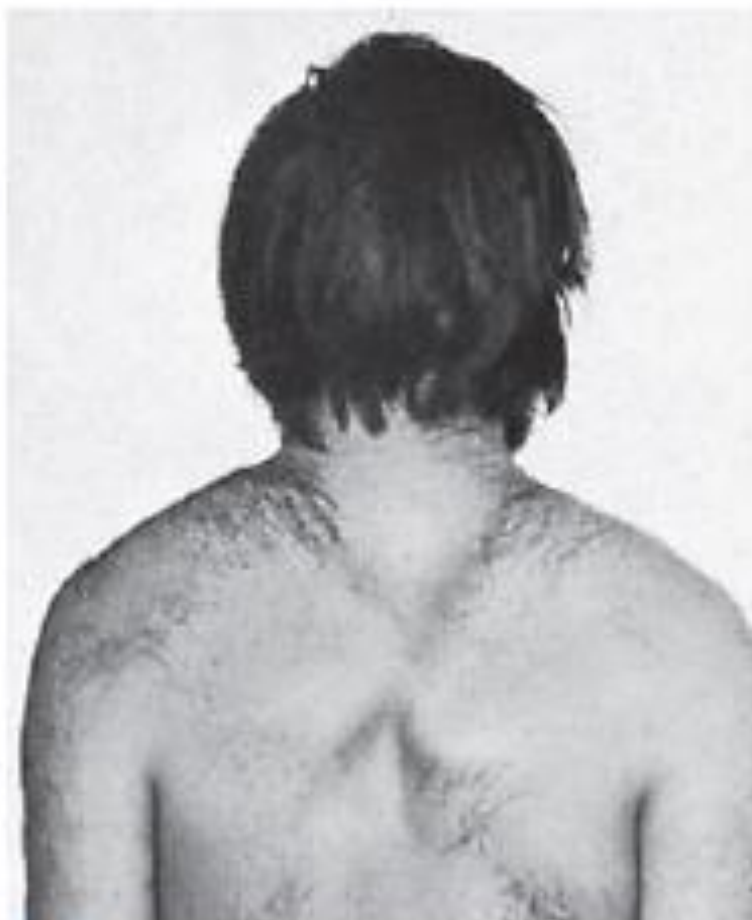

(b)

**13.26 Posterior dislocation** (a) In the anteroposterior view the humeral head looks globular – the so-called 'light bulb' appearance. (b) In the lateral view one can see the humeral head is lying behind the glenoid fossa, with an impaction fracture on the anterior surface of the head.



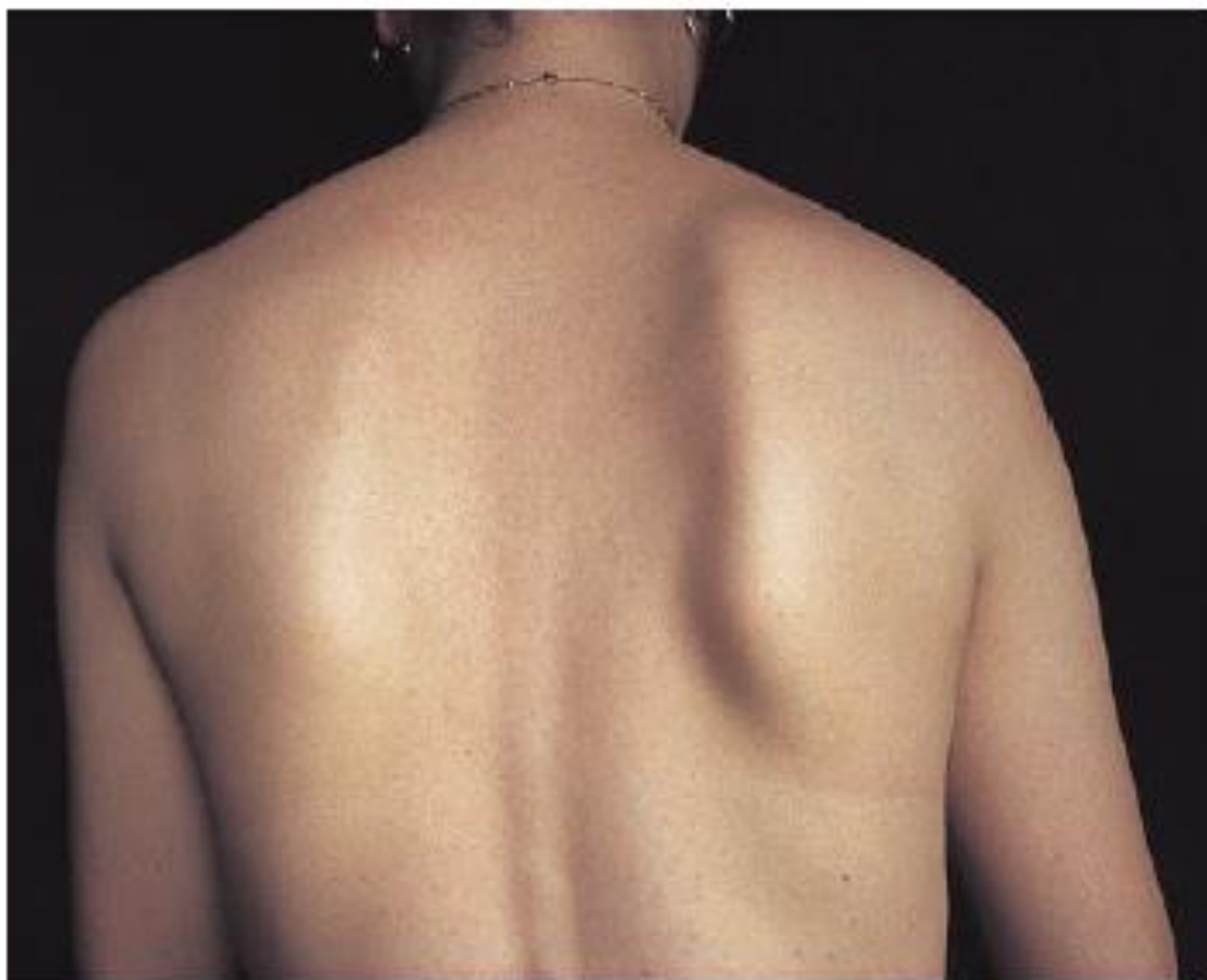
(a)



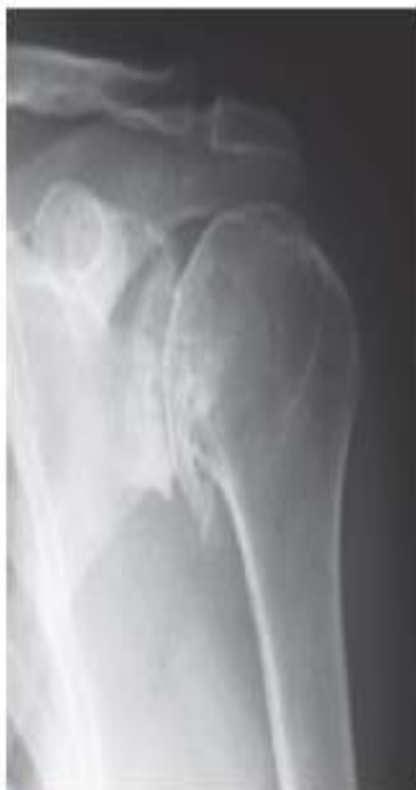(b)

**13.32 Scapular disorders** (a) Sprengel shoulder; (b) Klippel–Feil syndrome.

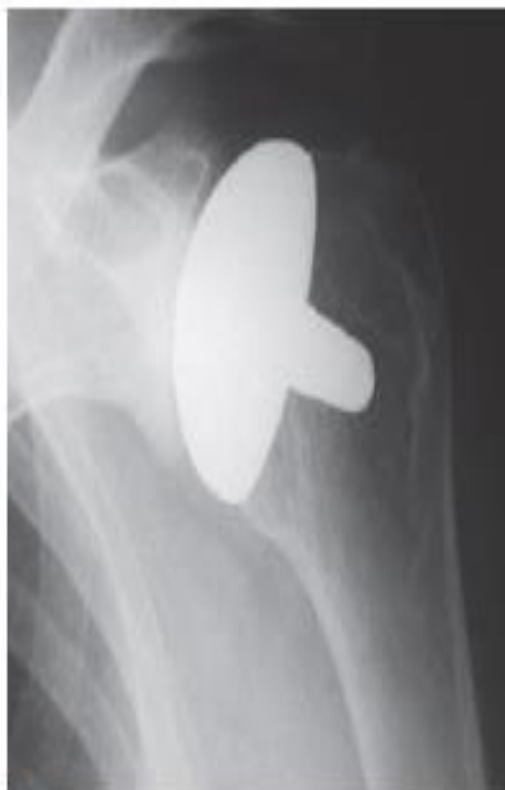



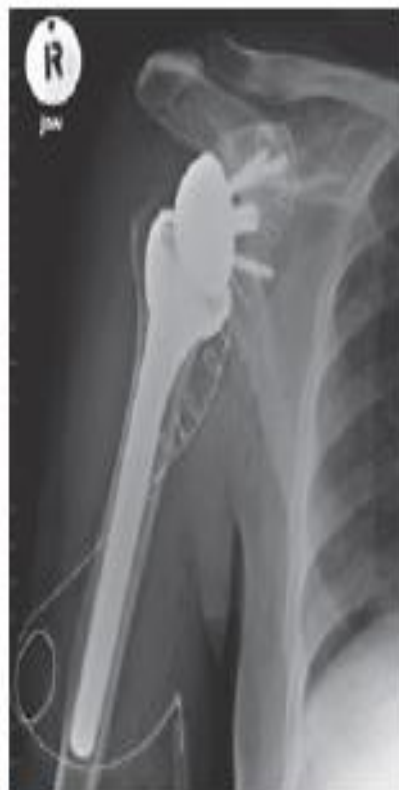**13.33 Winged scapula** This young woman's right scapula was somewhat prominent even at rest, but here the 'winging' is enhanced by having her thrust her arms forcibly against the wall.



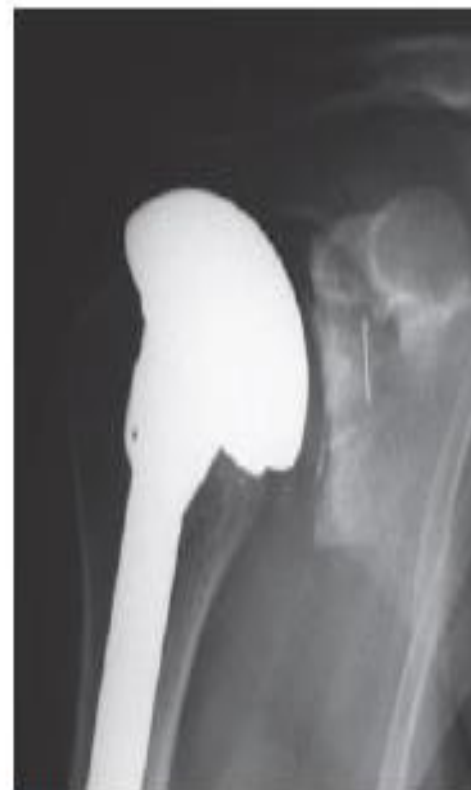(a)



(b)

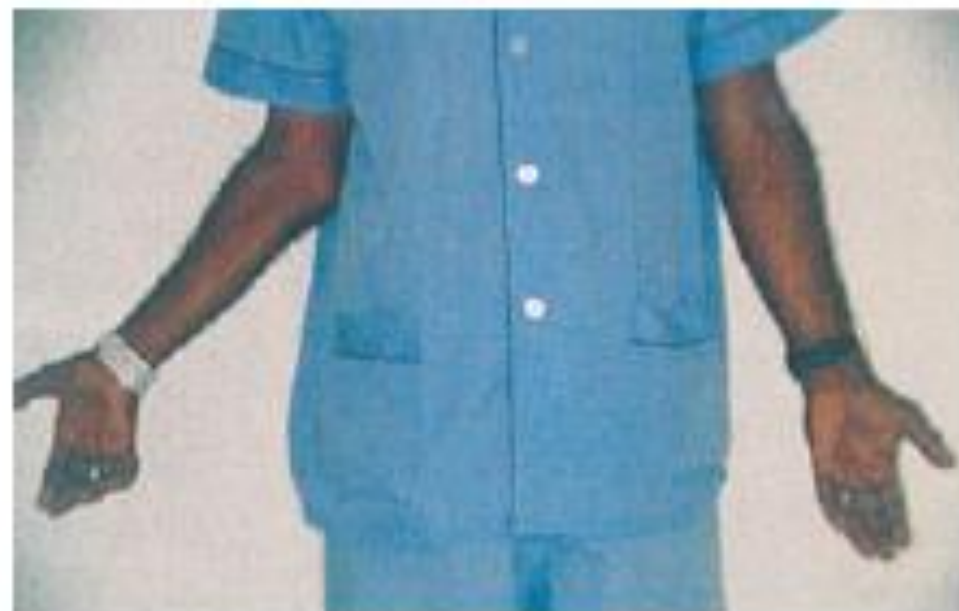

(c)

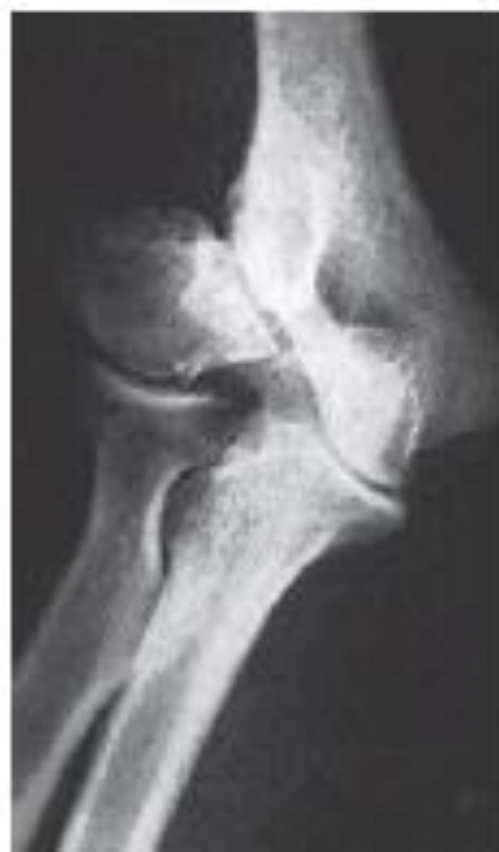

(d)

**13.35 Shoulder replacements** (a,b) Osteoarthritis and a resurfacing arthroplasty. (c) Early postoperative x-ray of a reverse polarity shoulder replacement. (d) Total shoulder replacement with replacement of the glenoid.



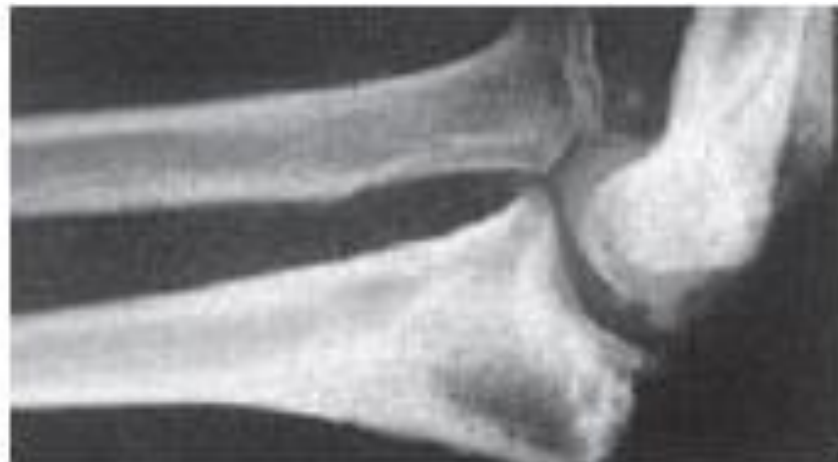(a)



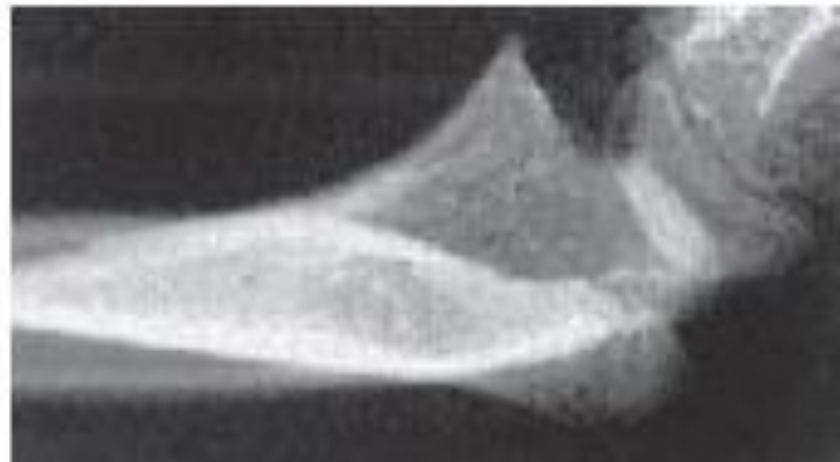(b)

**14.4 Cubitus valgus** (a) This man has excessive valgus of the right elbow. But his main complaint was of weakness and deformity in the hand, which was caused by traction on the ulnar nerve secondary to the elbow deformity.

(b) Valgus deformity from an un-united fracture of the lateral condyle.

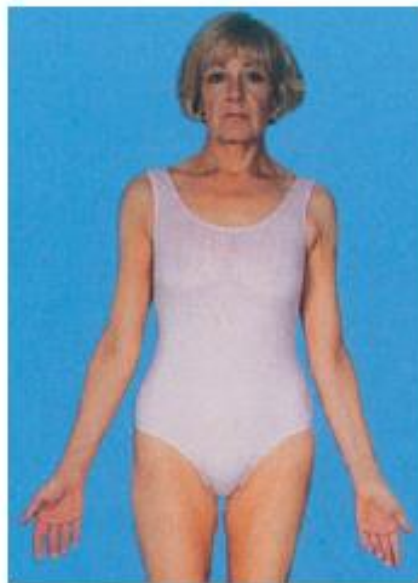

(a)

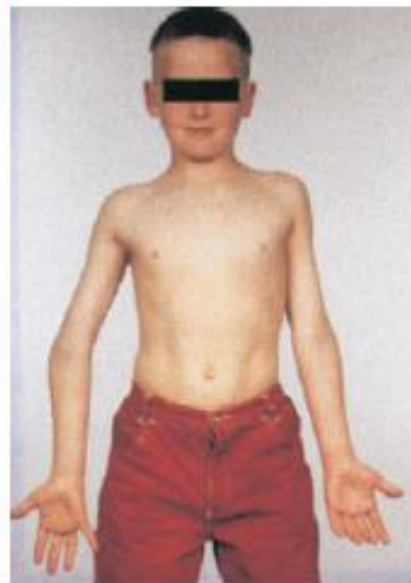

(b)

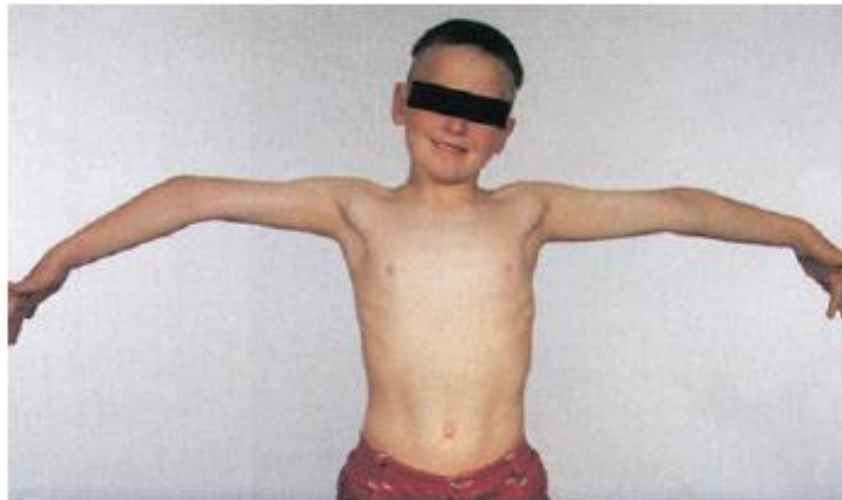**14.6 Dislocated radial head** (a) Anterior dislocation from old Monteggia fracture; (b) posterior dislocation, most likely congenital.



(a)



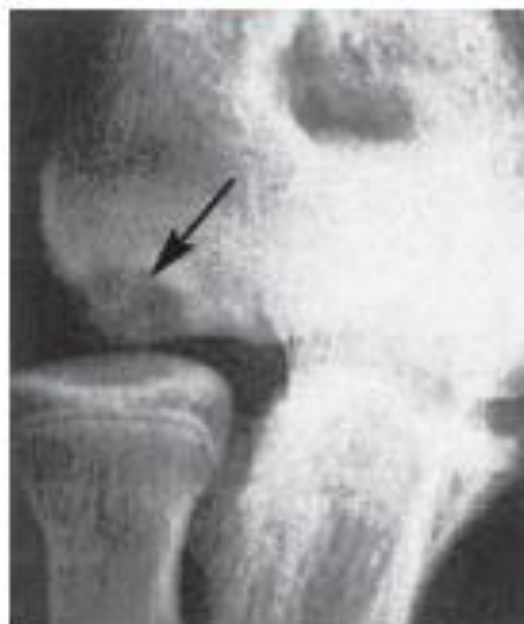(b)



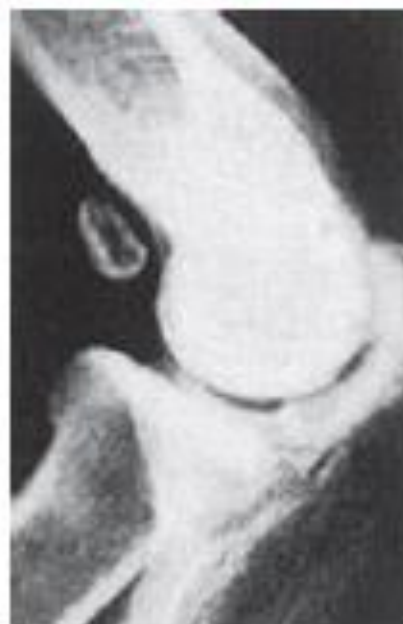(c)

**14.5 Cubitus varus** (a) Note that the elbows are normally held in  $5-10^\circ$  of valgus (the carrying angle). (b) This young boy ended up with slight varus angulation after a supracondylar fracture of the distal humerus. The deformity is much more obvious (c) when he raises his arms (gun-stock deformity).



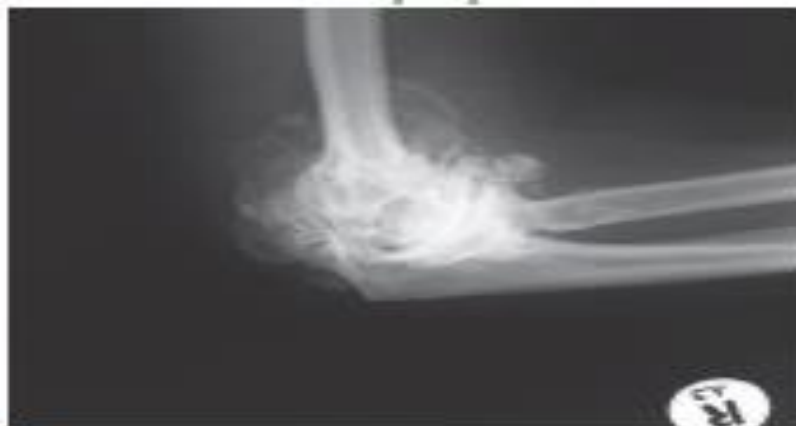

(a)

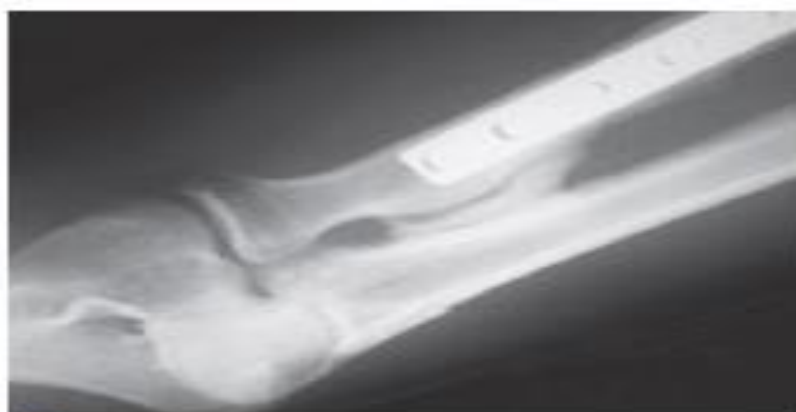

(b)

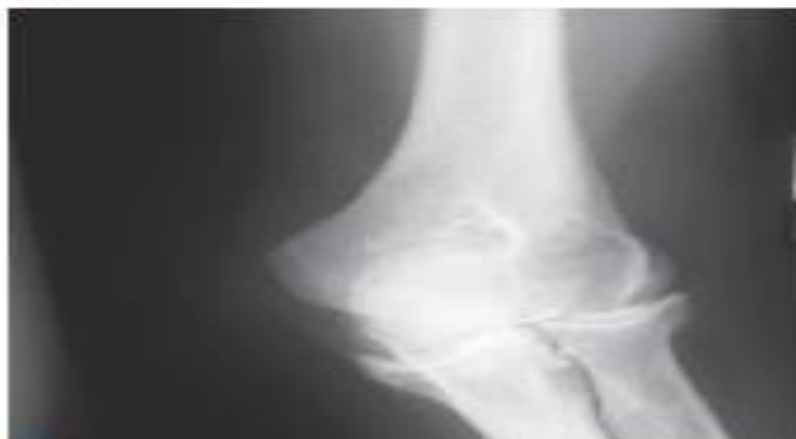**14.7 Osteochondritis dissecans** (a) The capitulum is fragmented and slightly flattened. (b) Sometimes the fragment separates and lies in the joint.



(a)

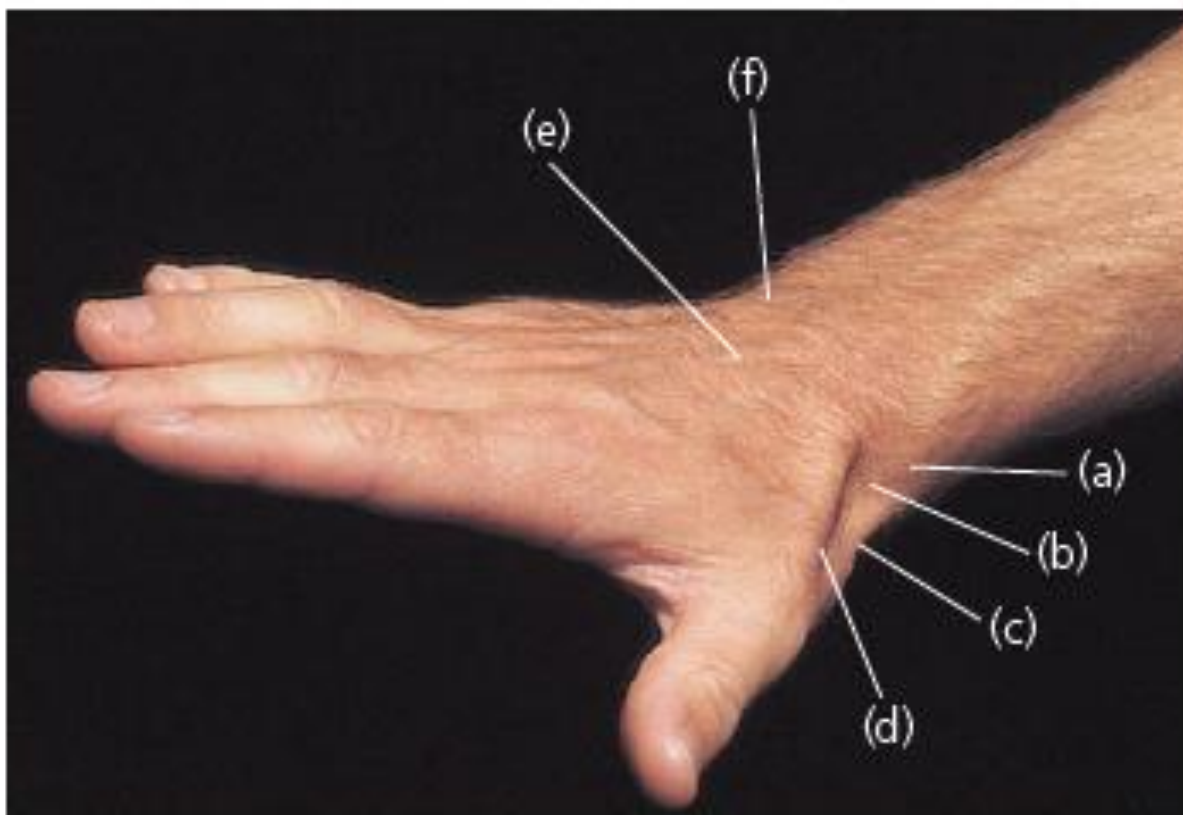


(b)

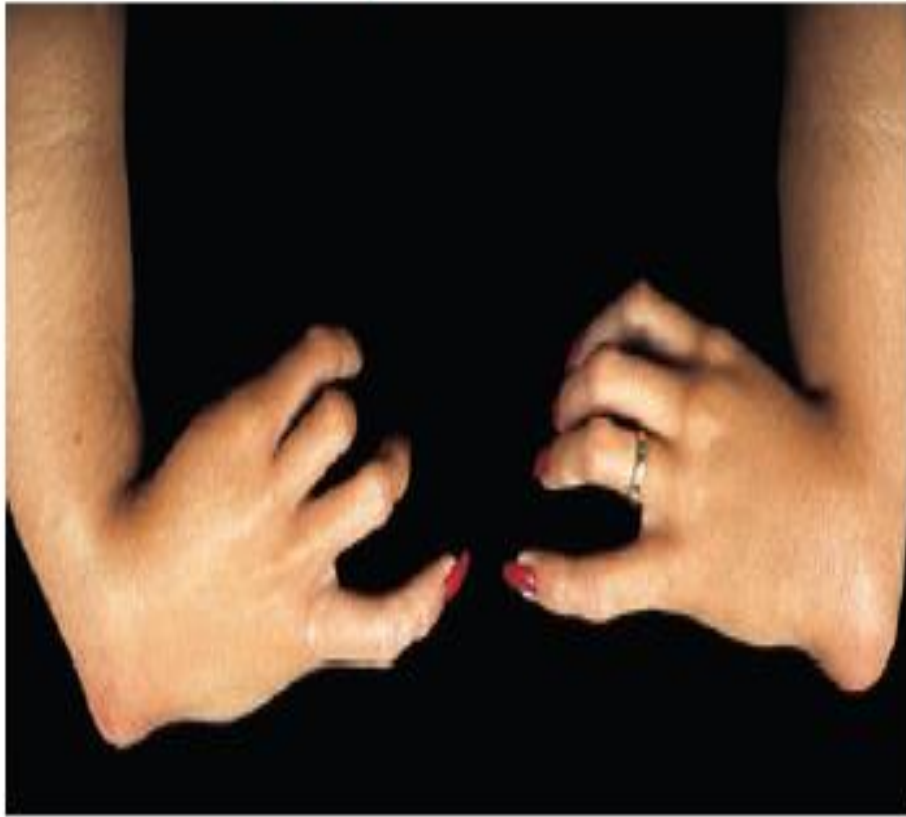

(c)

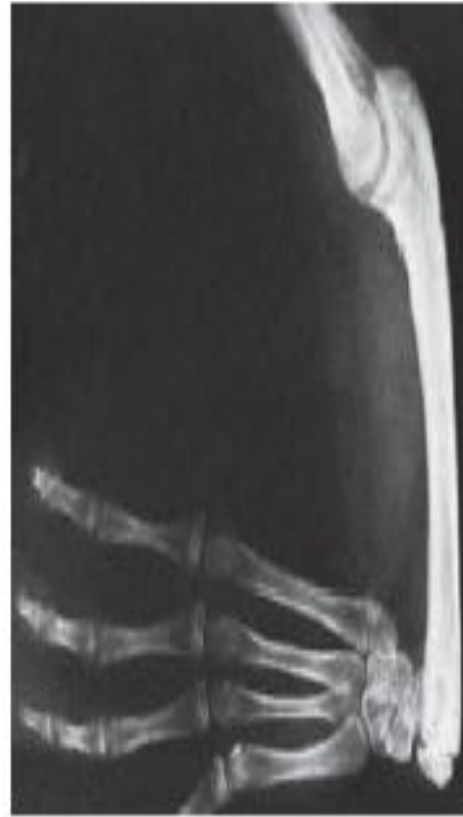14.14 Elbow stiffness (a) Osteochondritis; (b) radio-ulnar synostosis; (c) osteoarthritis.



**15.1 Tender points at the wrist** (a) Tip of the radial styloid process; (b) anatomical snuffbox, bounded on the radial side by (c) the extensor pollicis brevis and on the ulnar side by (d) the extensor pollicis longus; (e) the extensor tendons of the fingers; and (f) the head of the ulna.

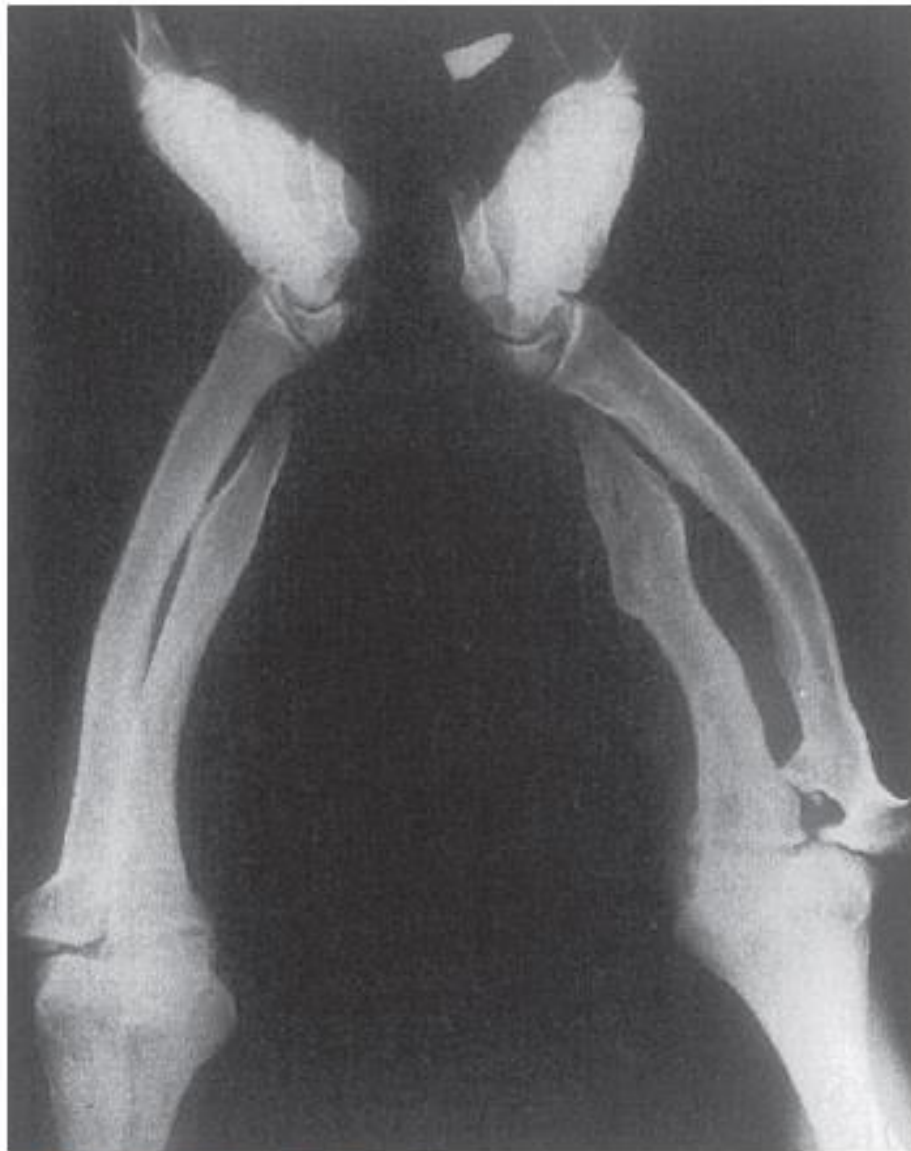

(a)



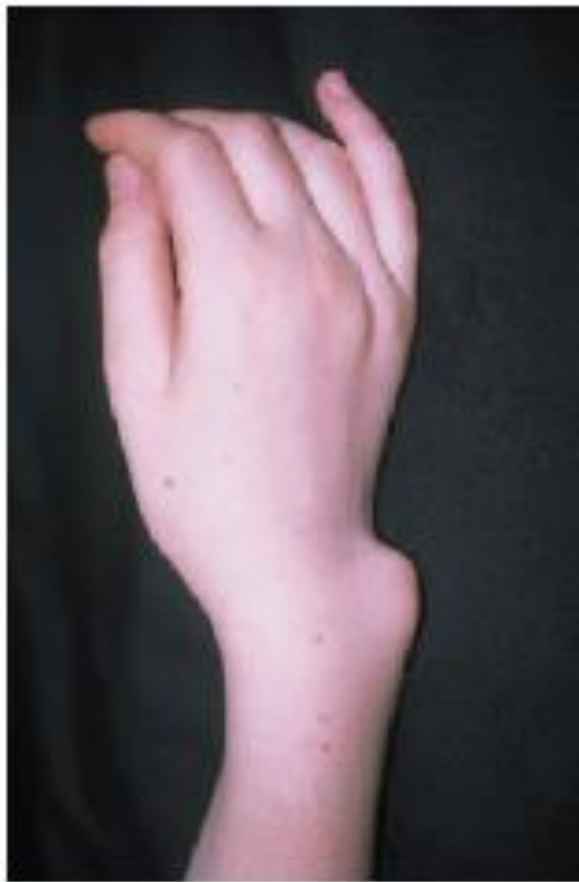(b)

**15.6 Radial dysplasia**  
(a) Bilateral. (b) X-ray showing that the entire radius is absent.

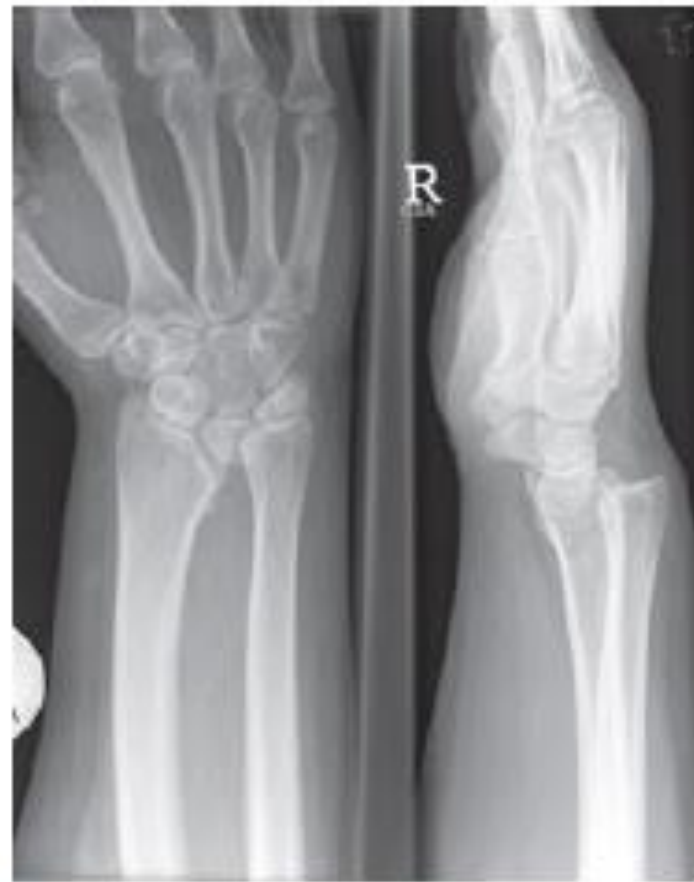

**15.7 Distal ulnar deformity** The x-ray characteristically shows a tapering, carrot-shaped distal end of ulna. This bilateral case was due to hereditary multiple exostoses; there is bilateral bowing of the radius and on the right side the radial head has subluxated.





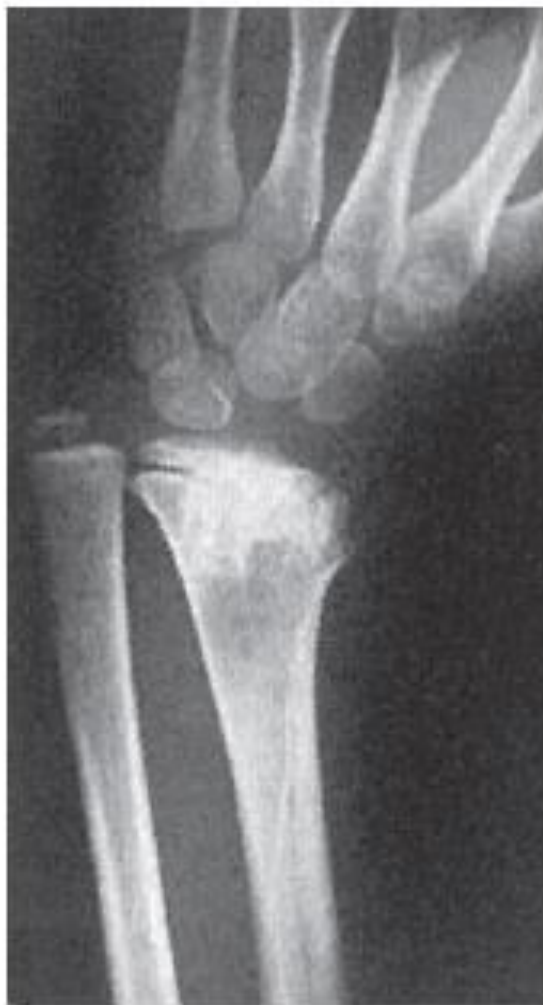(a)



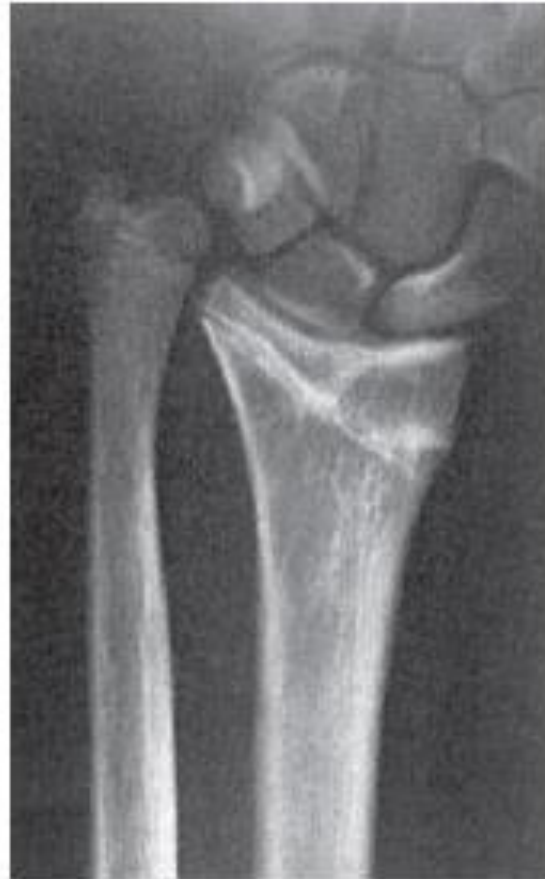(b)

(c)

**15.9 Madelung's deformity** (a) Note prominent ulnar head and radial tilt; (b) characteristic x-ray showing increased slope of radius and (c) subluxation of ulna.

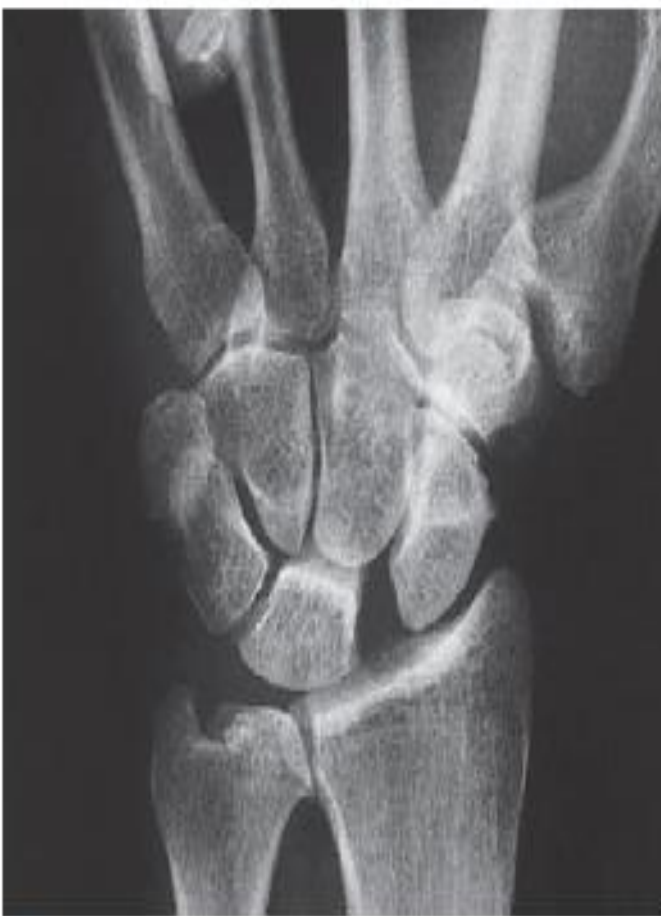

(a)

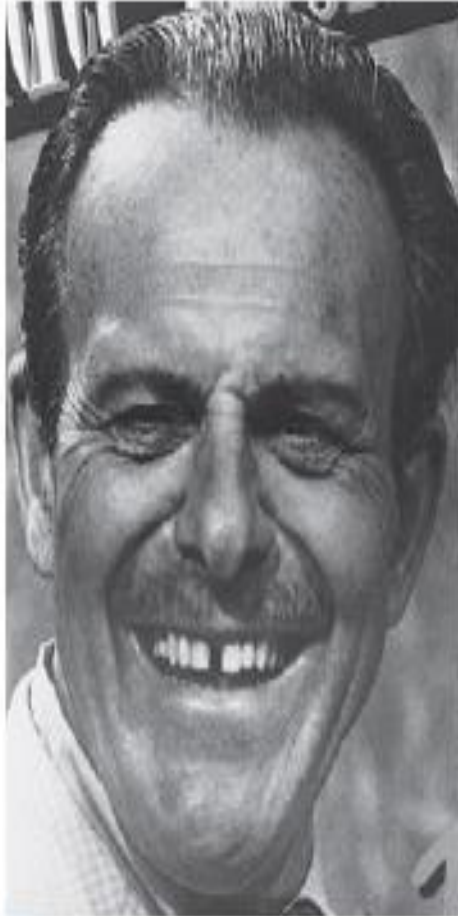


(b)

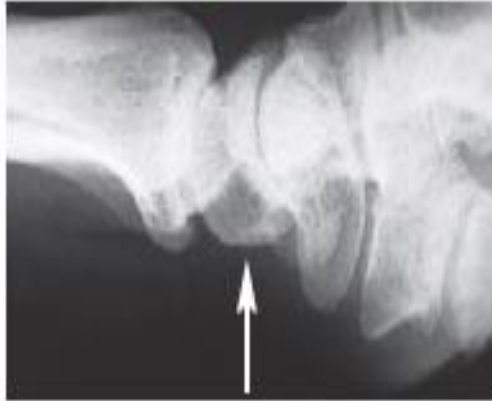**15.10 Growth plate arrest** (a) Impacted physeal fracture; (b) later arrest of radius, relative overgrowth of ulna.



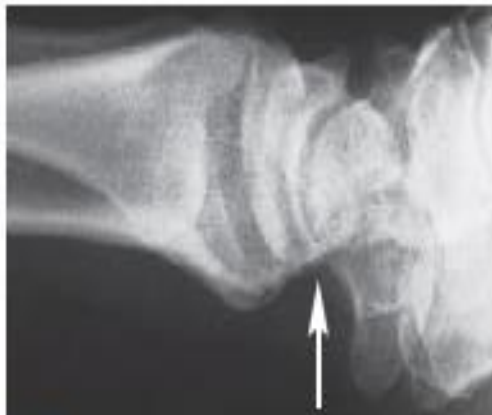(a)



(b)

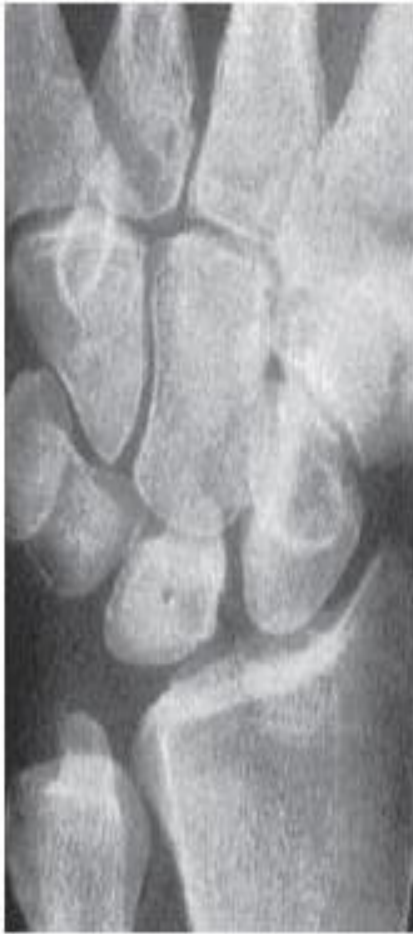

(c)

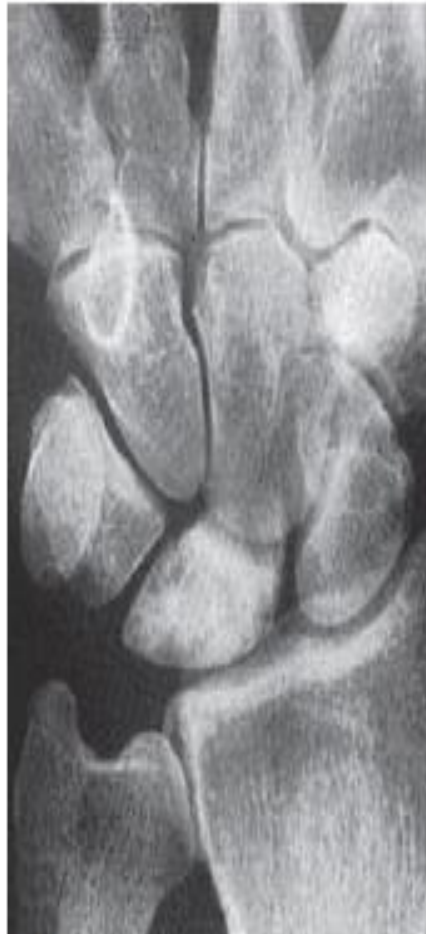

(d)

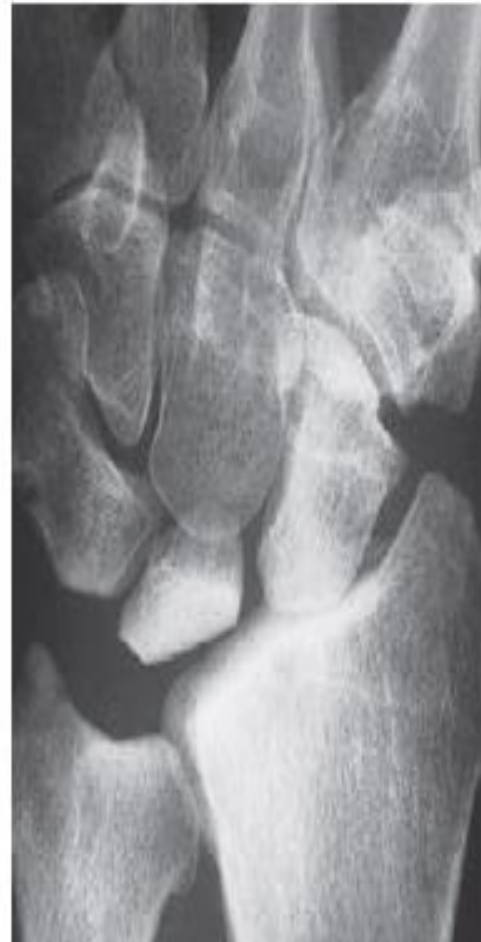**15.17 Carpal instability** (a) A year after 'straining' his wrist this patient was still complaining of pain; the x-ray shows a gap between the scaphoid and lunate (the *Terry-Thomas sign*) and rotation of the scaphoid. (b) The actor Terry Thomas with the trademark gap between his front teeth (reproduced by permission; © United Artists Inc.). (c) In the lateral view the lunate is tilted dorsally and the scaphoid ventrally (DISI); compare this with (d), an example of VISI, showing volar tilt of the lunate.



(a)



(b)

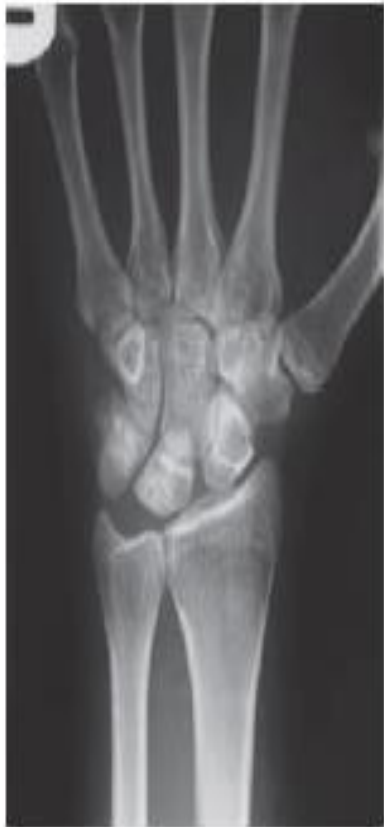

(c)

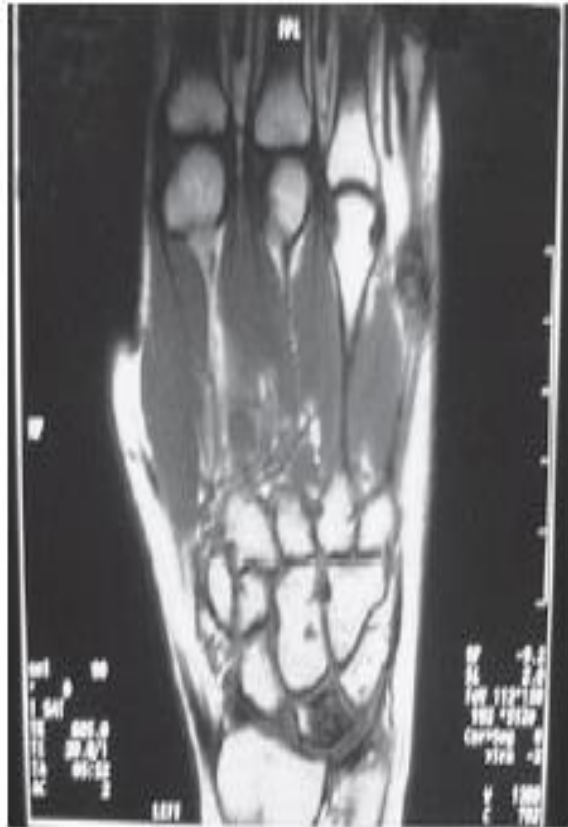### 15.18 Kienbock's disease

(a) In stage 2 the bone shows mottled increase of density, but is still normal in shape. (b) In stage 3 density is more marked and the lunate looks slightly squashed. (c) In stage 4 the bone has collapsed and there is radio-carpal osteoarthritis. In all three the ulna looks disproportionately short.

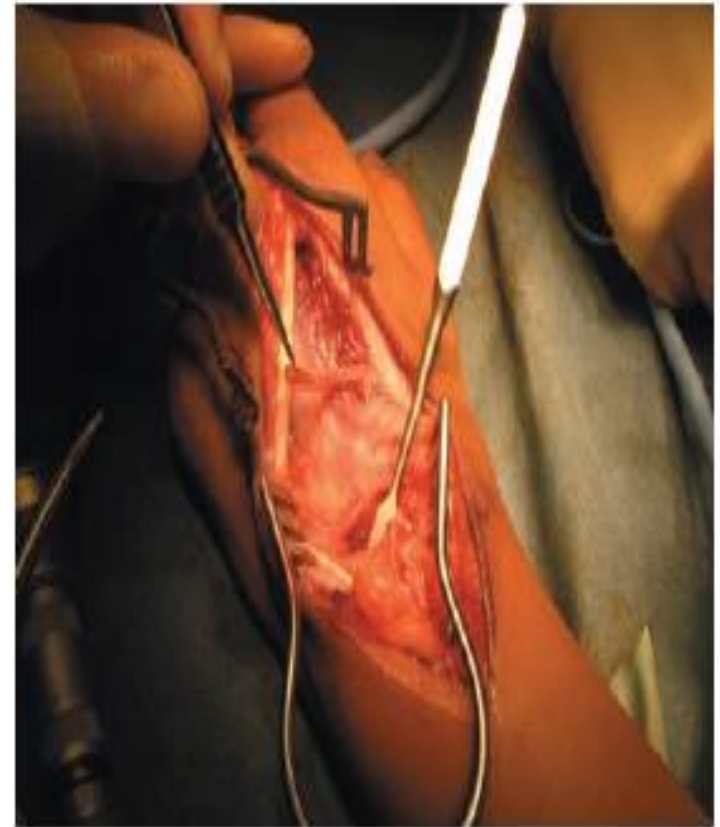




(a)



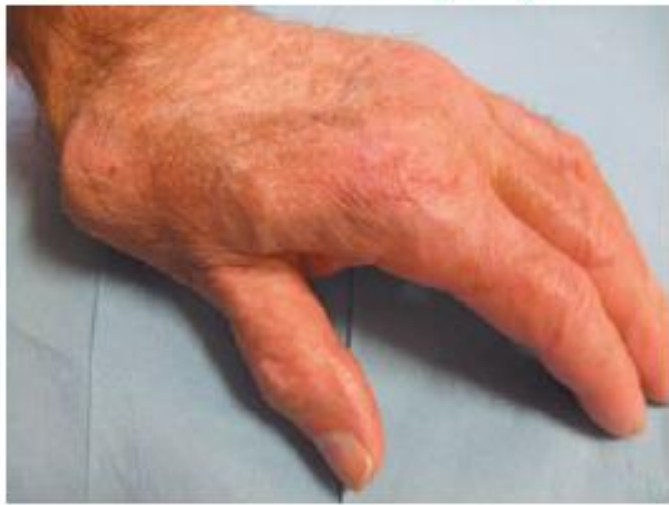(b)



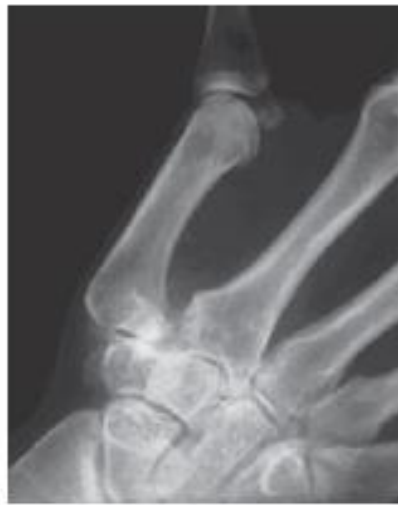(c)

**15.19 Kienbock's disease grade** (a) Not seen on x-ray; (b) seen on MRI scan; (c) treated by vascular bundle implantation.

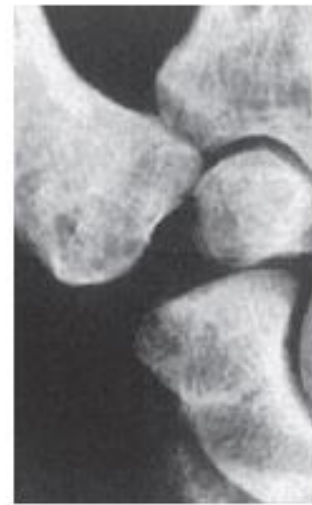



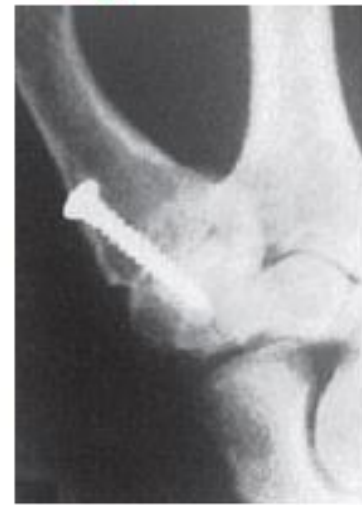(a)



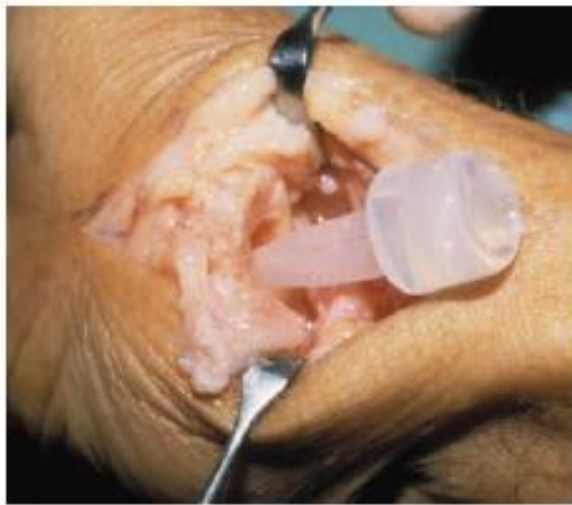(b)



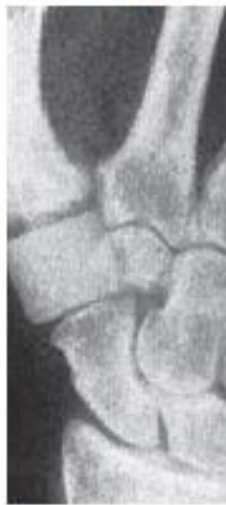(c)



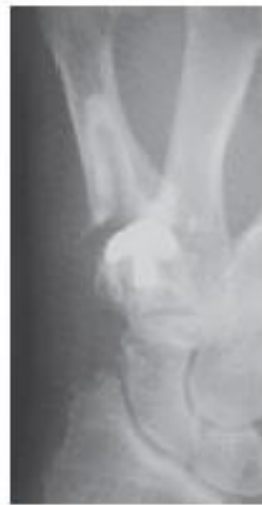(d)



(e)

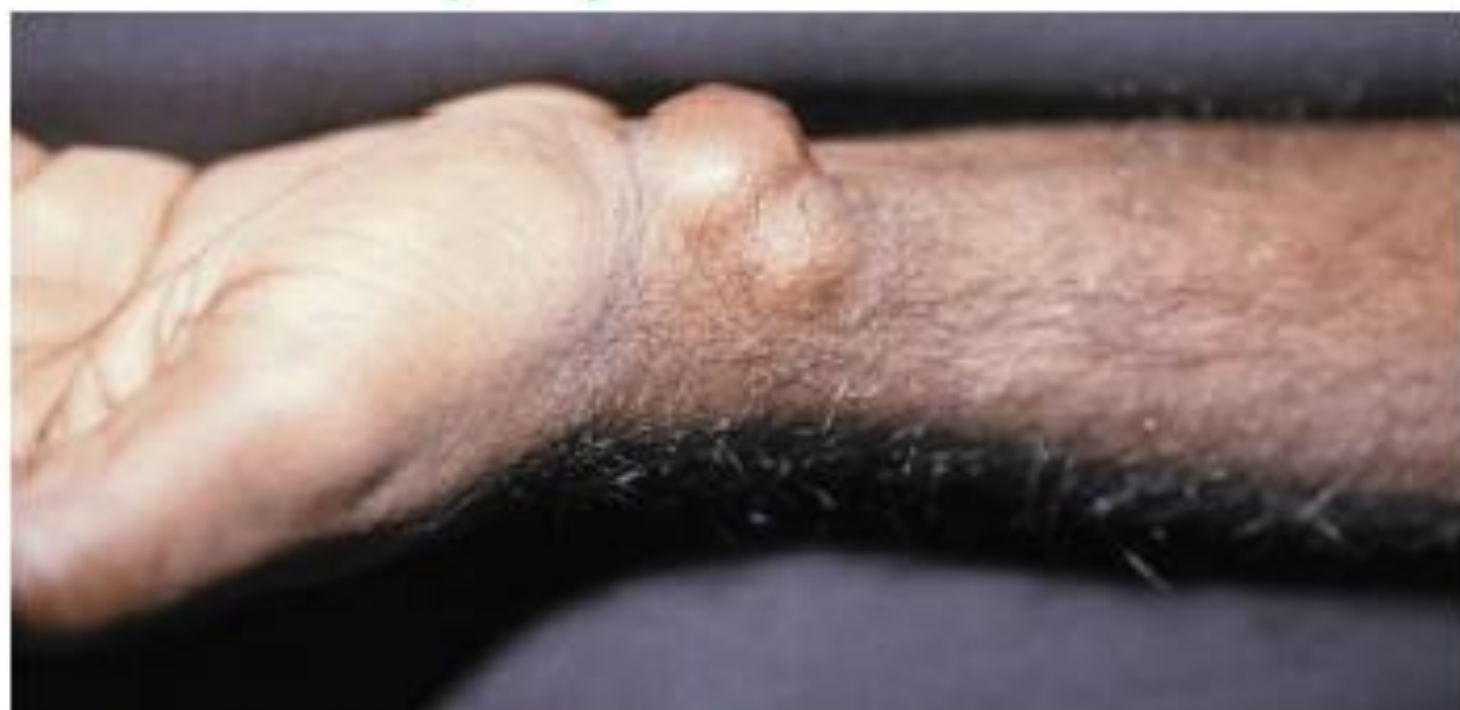

(f)

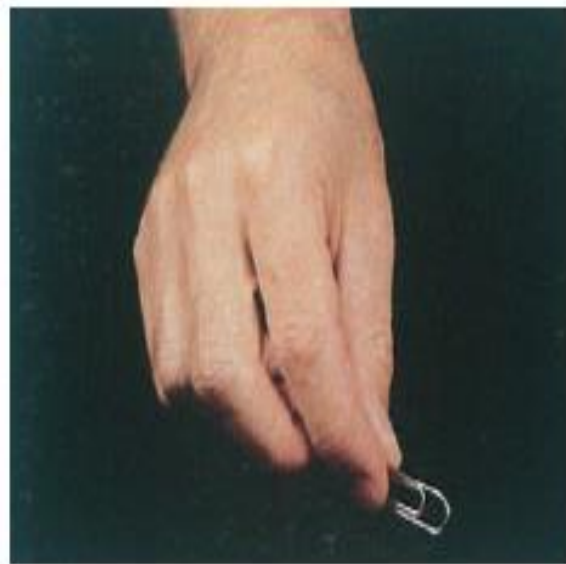

(g)

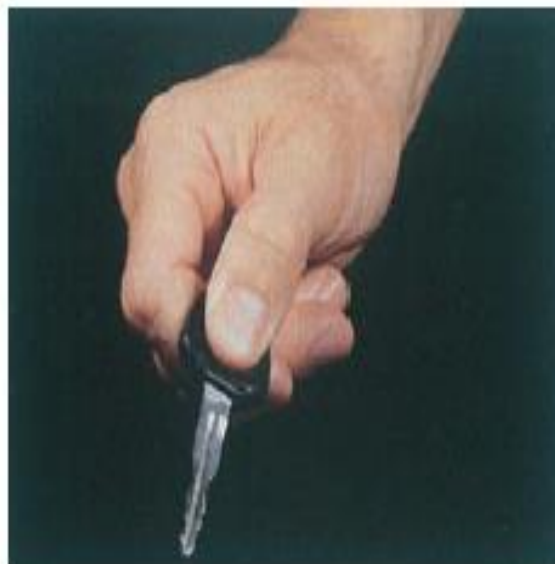**15.30 1st Carpo-metacarpal osteoarthritis** (a) Deformity of the thumb, with fixed carpo-metacarpal flexion and metacarpo-phalangeal hyperextension. (b) X-ray showing articular destruction. Treatment may be by (c) excision of trapezium, (d) arthrodesis, (e,f) silastic replacement or (g) total replacement




15.35 Volar wrist ganglion



(a)



(b)



(c)

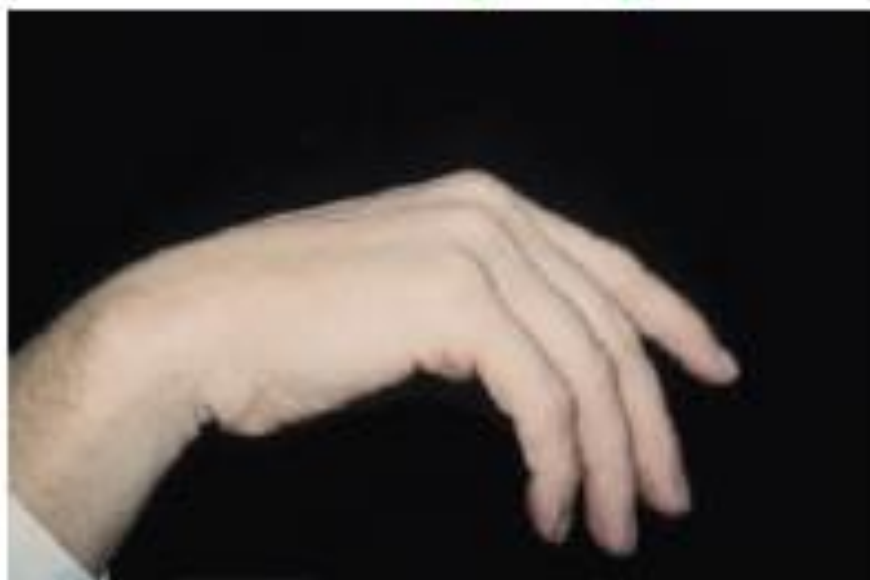

(d)

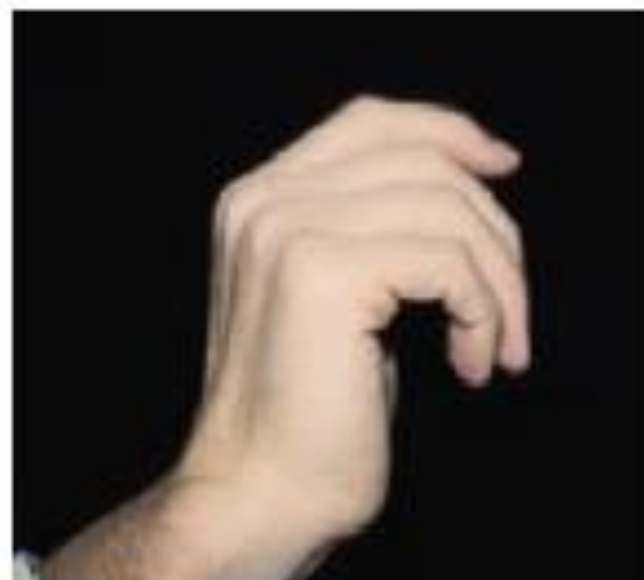

(e)

**16.1 Hand function** (a) Pinch, (b) key, (c) tripod, (d) grasp and (e) power grip.



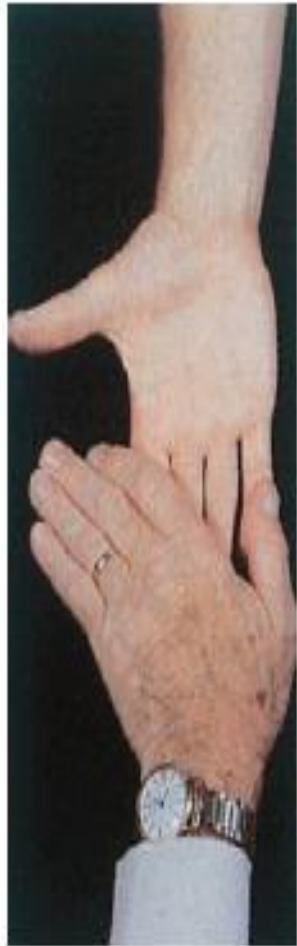(a)



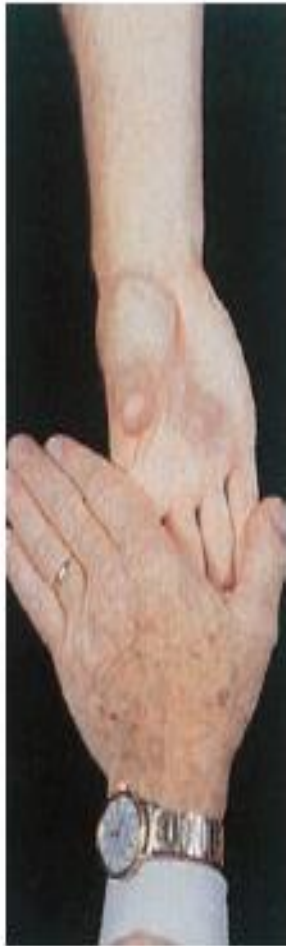(b)

**16.2 Passive tenodesis** Note the resting position of the fingers with the wrist (a) flexed, (b) extended.

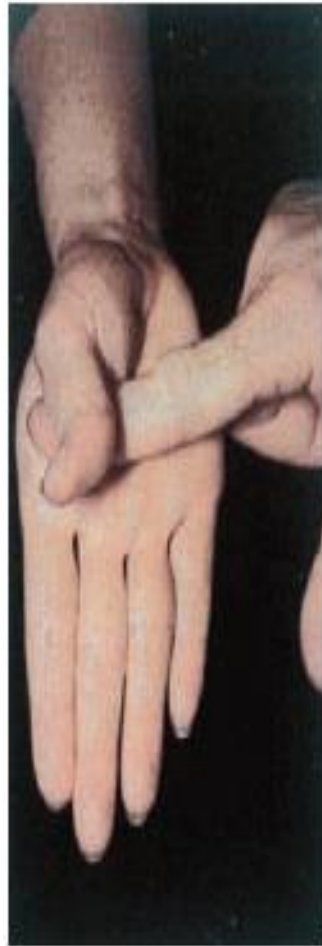



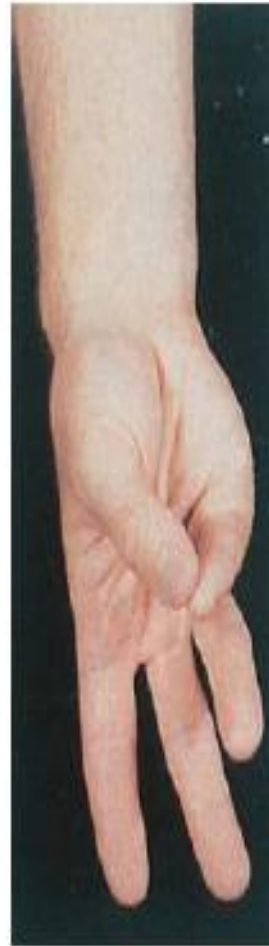(a)



(b)



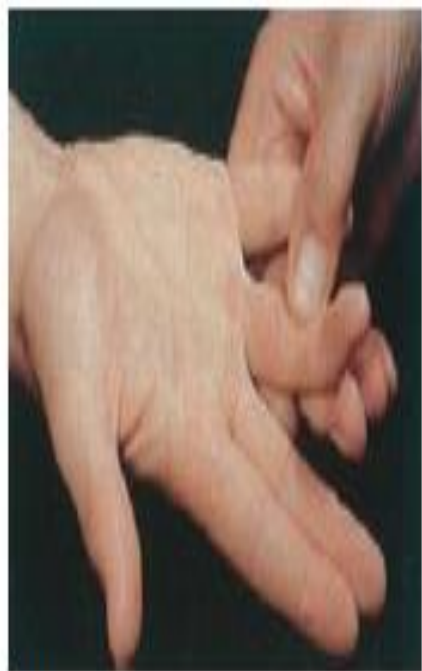(c)



(d)

**16.5 Thumb movements** You should have no difficulty defining the planes of movement if you follow this routine: (a) hold the patient's hand flat on the table and instruct him or her to 'stretch to the side' (extension), (b) 'point to the ceiling' (abduction), (c) 'pinch my finger' (adduction) and (d) 'touch your little finger' (opposition).





(a)



(b)

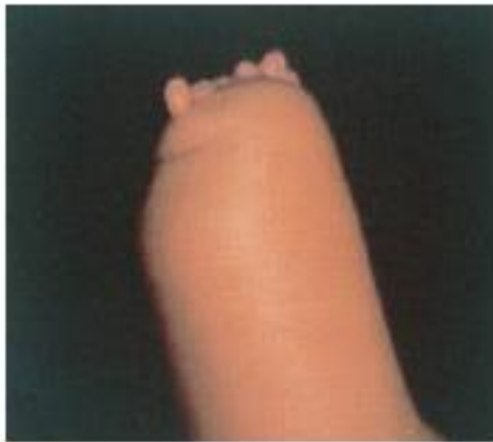

(c)

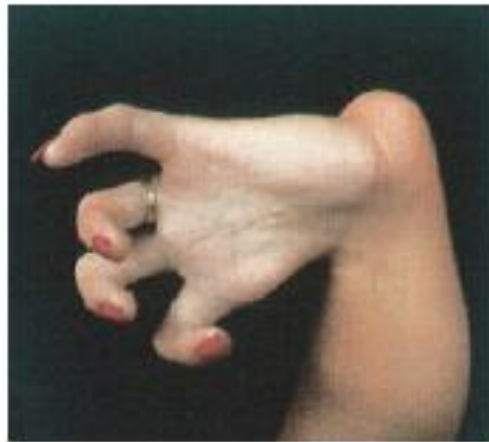

(d)

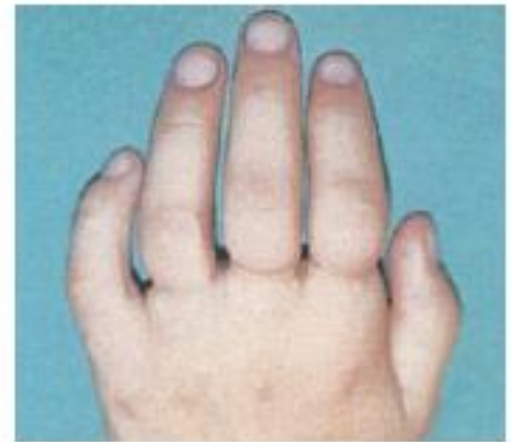**16.6** Testing for (a) FDP lesser fingers, (b) FDS lesser fingers, (c) FDP index, (d) FDS index.



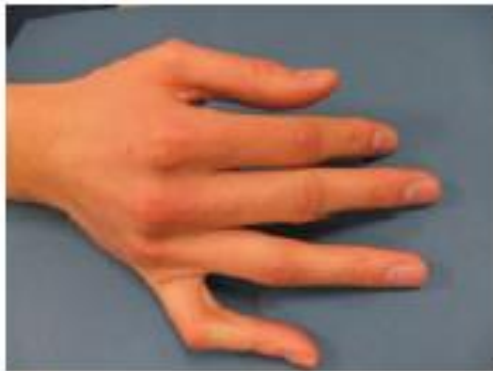(a)



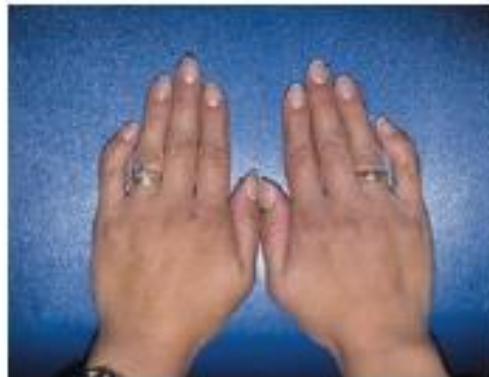(b)



(c)



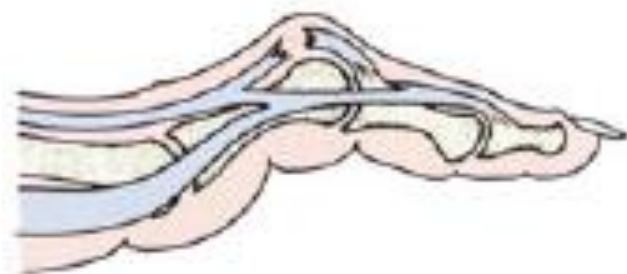
(d)



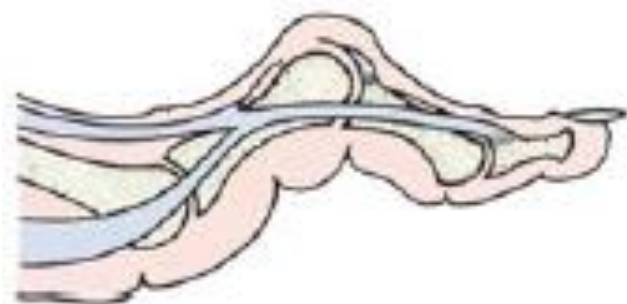
(e)

## 16.8 Congenital variations

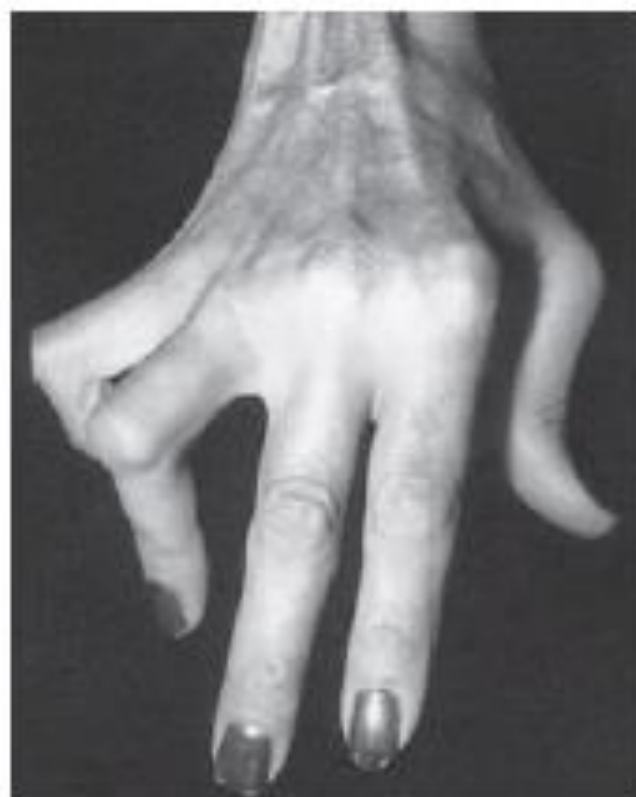- (a) Transverse failure,
- (b) radial club hand and absent thumb,
- (c) constriction rings,
- (d) camptodactyly,
- (e) clinodactyly.



(a)

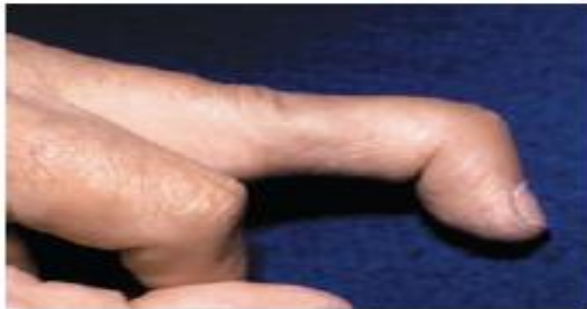

(b)

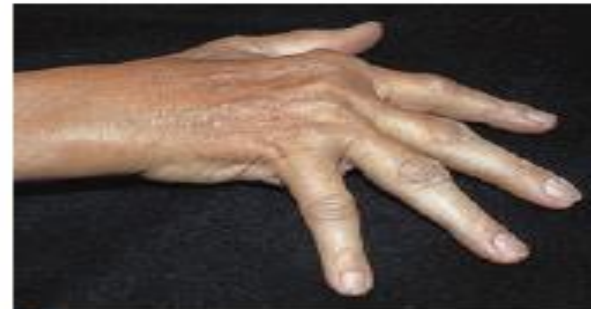

(c)

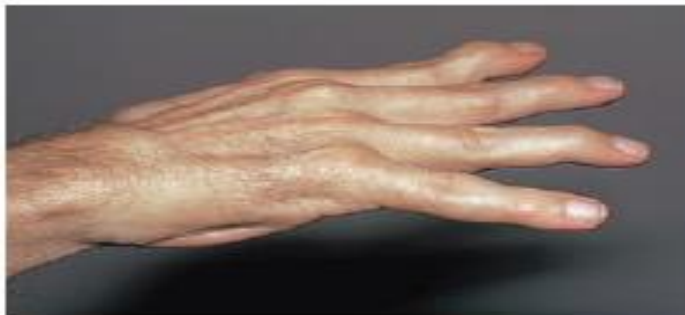**16.9 Boutonnière deformity** (a) When the middle slip of the extensor tendon first ruptures there is no more than an inability to extend the PIP joint. (b) Gradually the lateral slips slide volarwards, the knuckle pops through the 'buttonhole' and the DIP joint is pulled into hyperextension. (c) Clinical appearance.



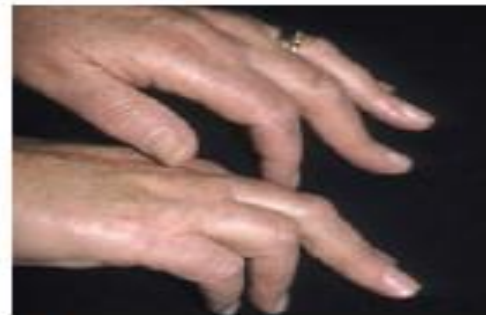(a)



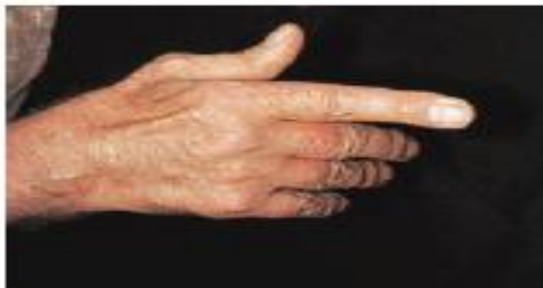(b)



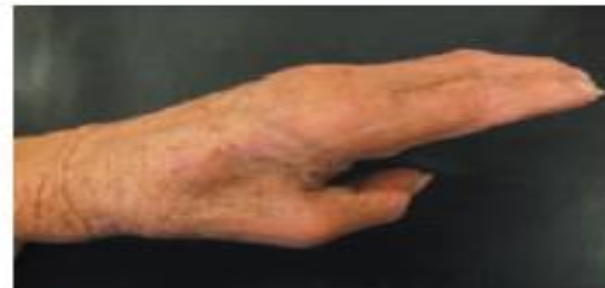(c)



(d)



(e)



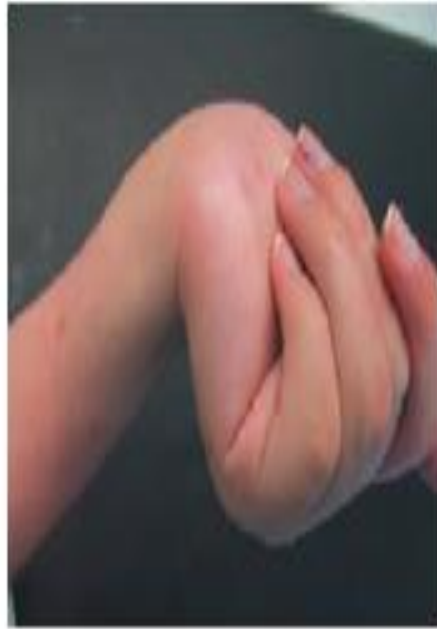(f)

**16.10 Deformities due to tendon lesions** (a) Mallet finger. (b) Dropped fingers due to extensor tendon ruptures at the wrist. (c) Swan-neck deformities. (d) Boutonnière deformities. (e) Rupture of extensor pollicis brevis. (f) Rupture of extensor pollicis longus.

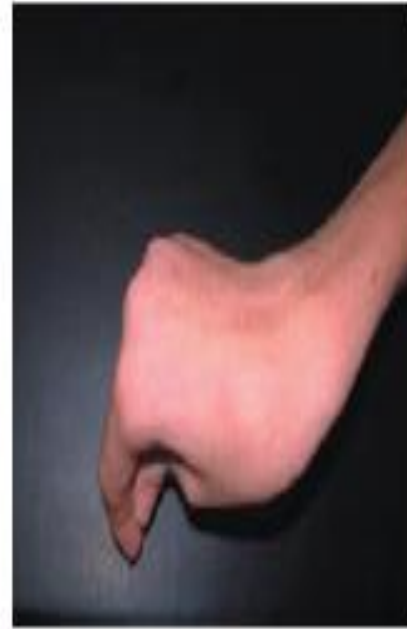



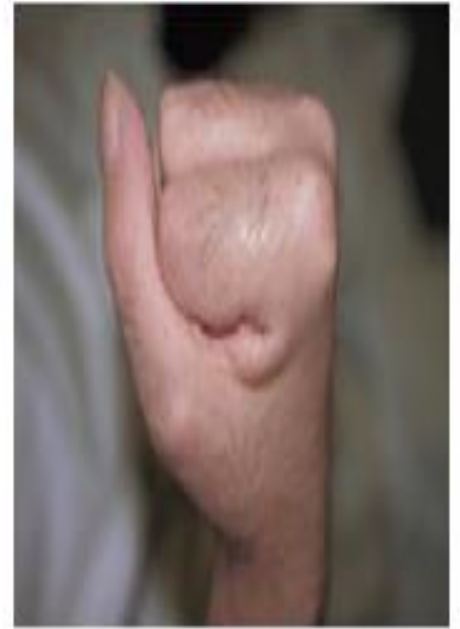
(a)



(b)



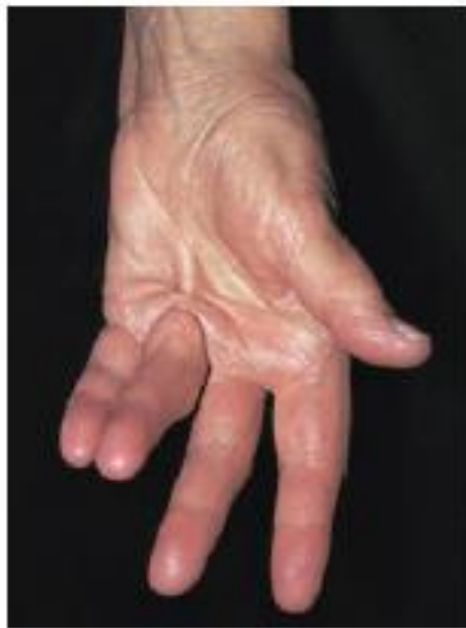(c)



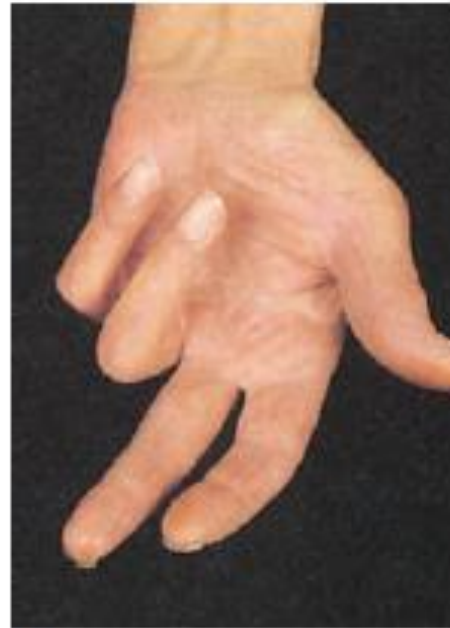(d)

**16.11 Spastic contracture – hand deformities** (a,b,c) cerebral palsy, and (d) head injury with brain damage.

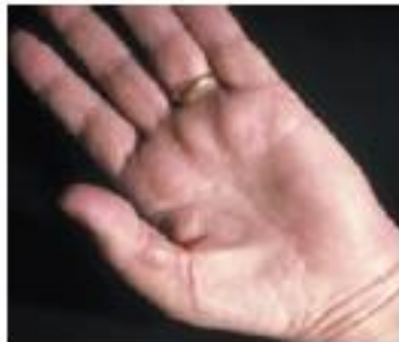



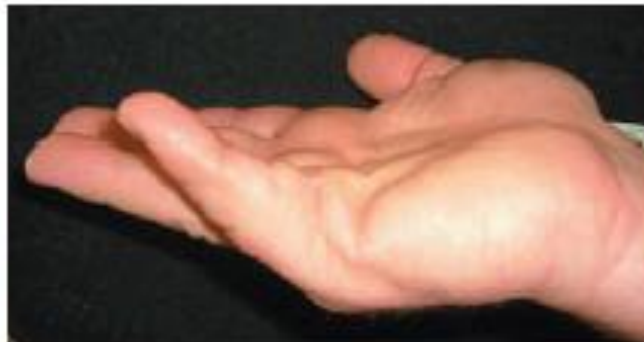(a)



(b)

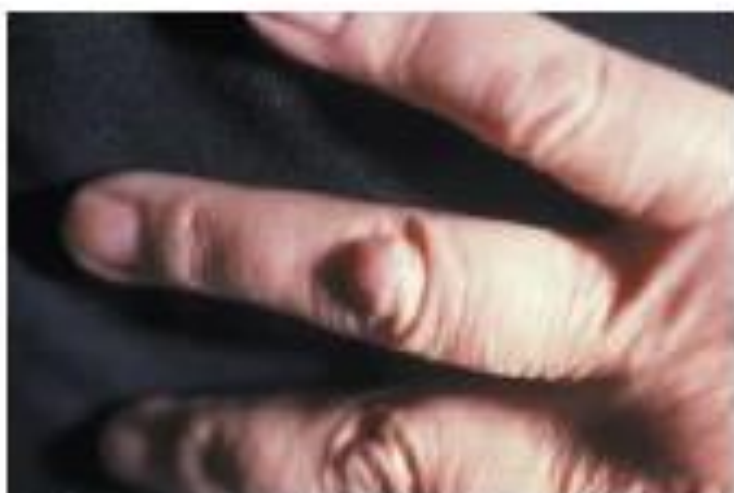

(c)

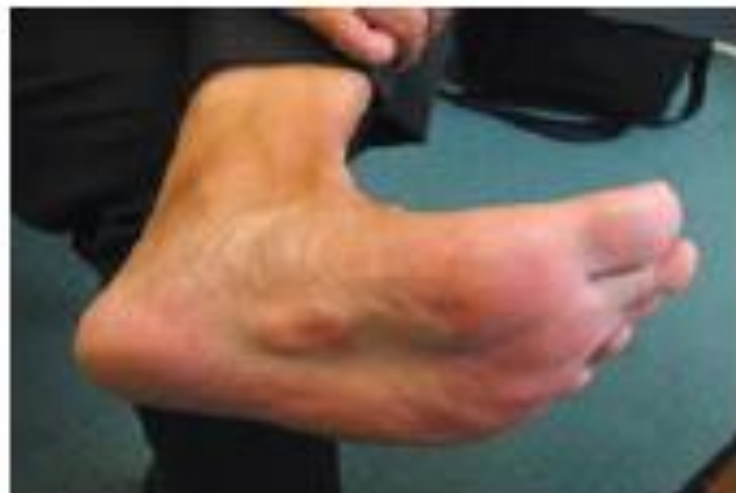

(d)

**16.12 Dupuytren's disease** Contractures may occur at (a) palmar crease, (b) proximal interphalangeal joint, (c) thumb web, (d) little finger.

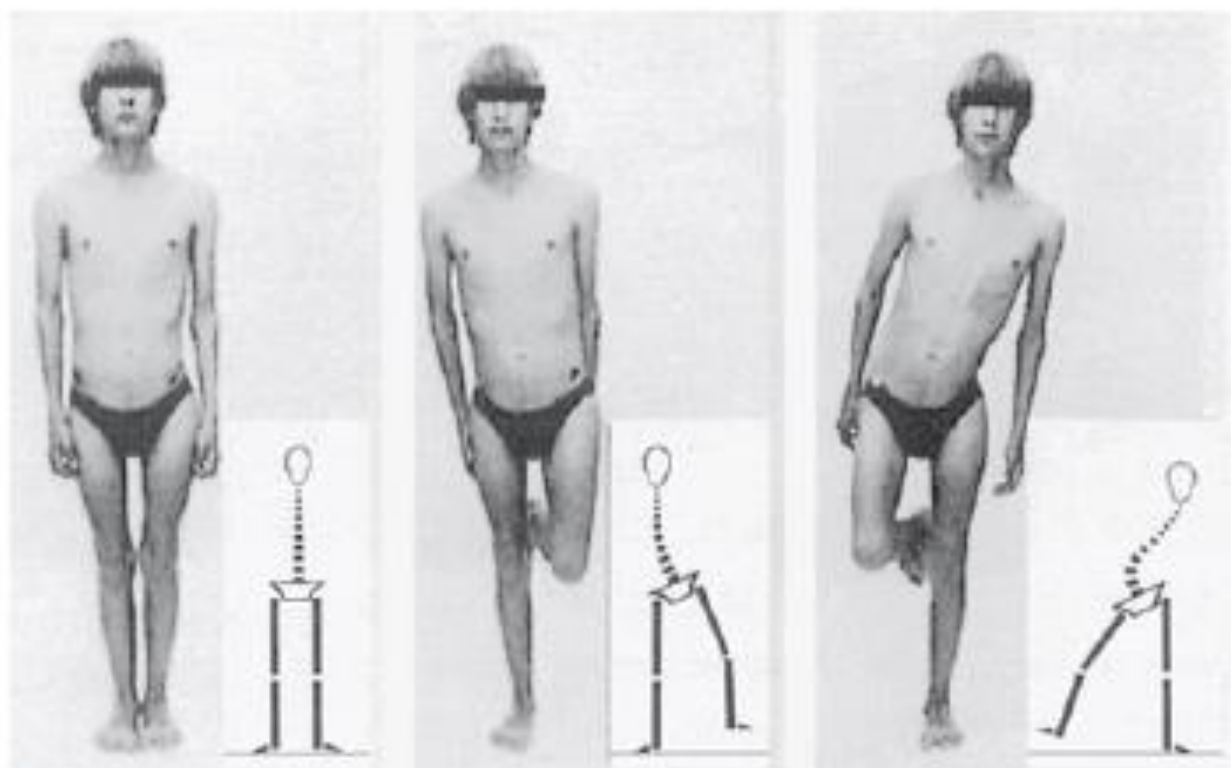


(a)



(b)

**16.13 Dupuytren's disease – other manifestations (a)** Garrod's pads, **(b)** Ledderhose's nodules.

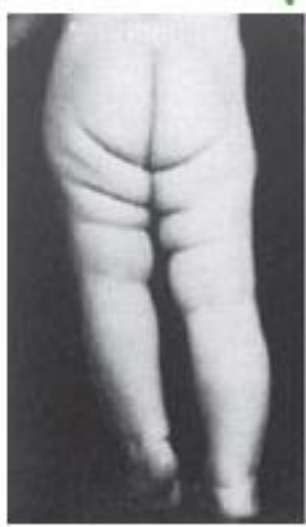

(a)

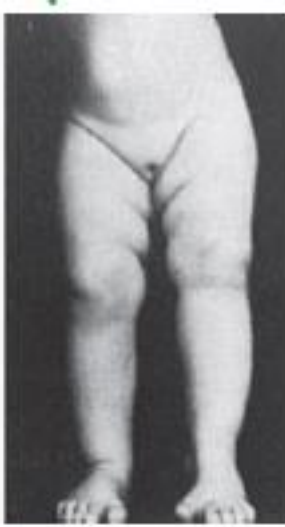(b)

(c)

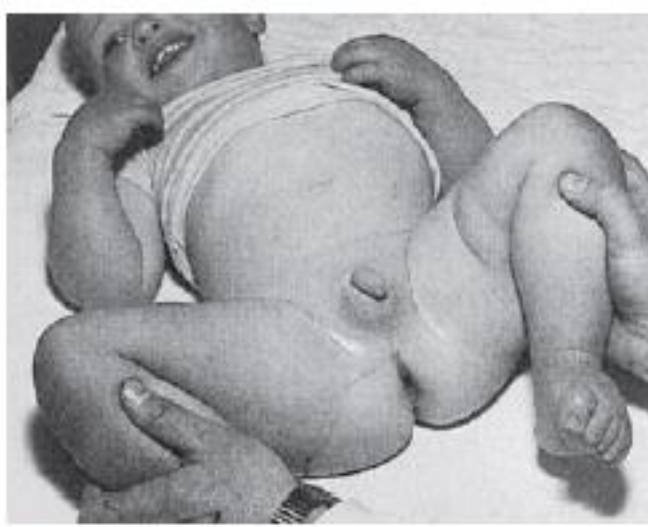**19.1 Trendelenburg's sign** (a) Standing normally on two legs. (b) Standing on the right leg which has a normal hip whose abductor muscles ensure correct weight transference. (c) Standing on the left leg whose hip is faulty, and so abduction cannot be achieved; the pelvis drops on the unsupported side and the shoulder swings over to the left.



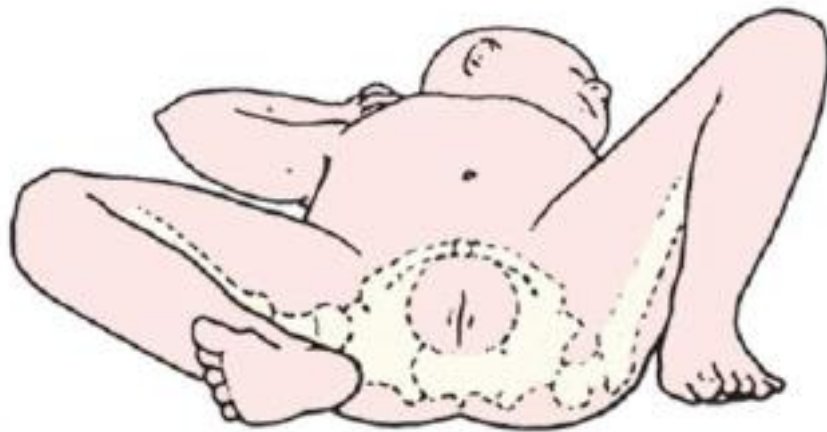(a)



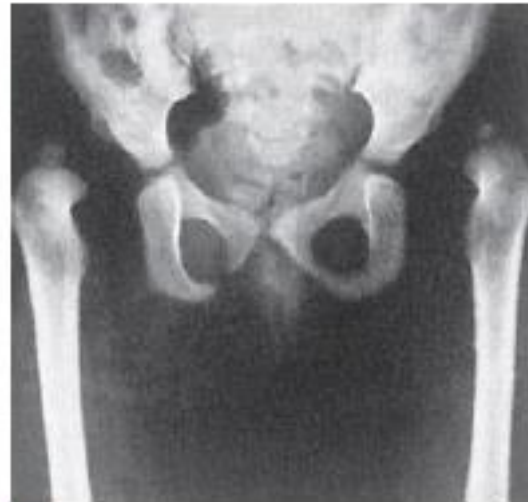(b)



(c)



(d)

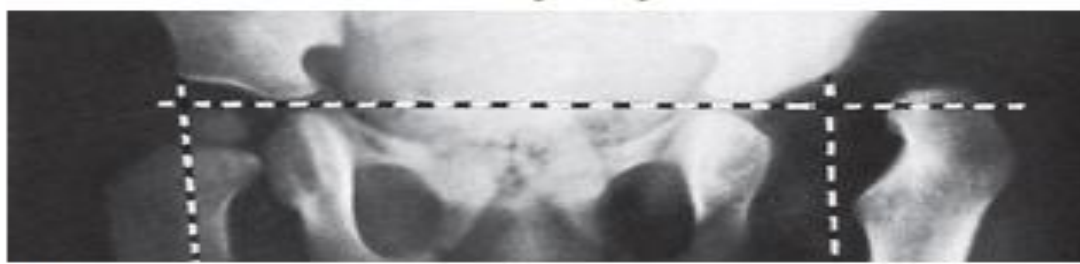


(e)

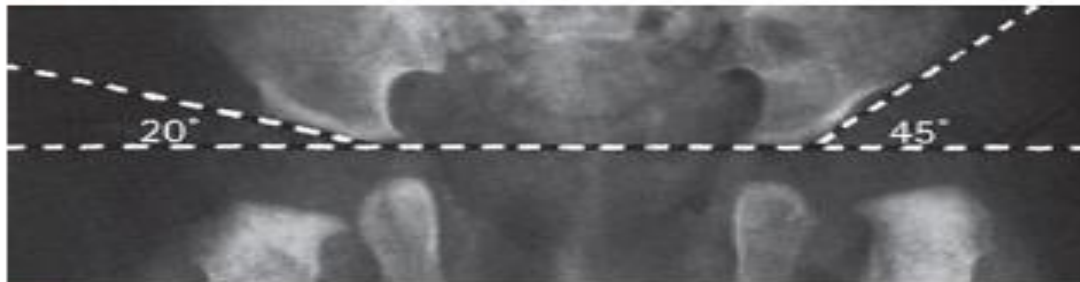
### 19.9 DDH – late signs

(a,b) Unilateral dislocation of the left hip. (c) The left hip does not abduct more than half way, and (d) the drawing shows why – the femoral head is caught up on the rim of the acetabulum. (e) X-ray showing bilateral displacement of the hip.

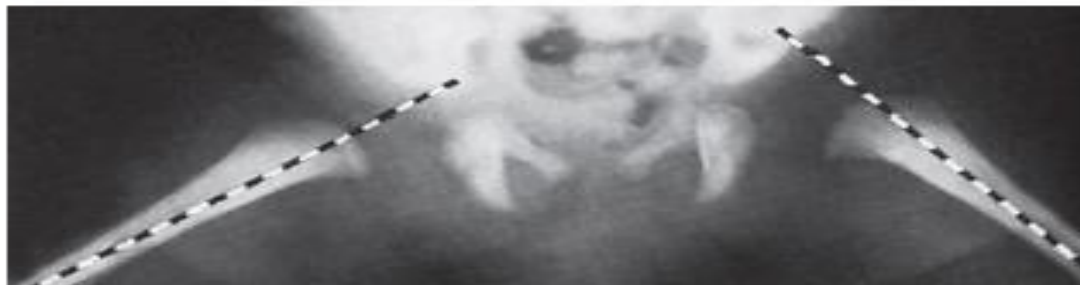




(a)



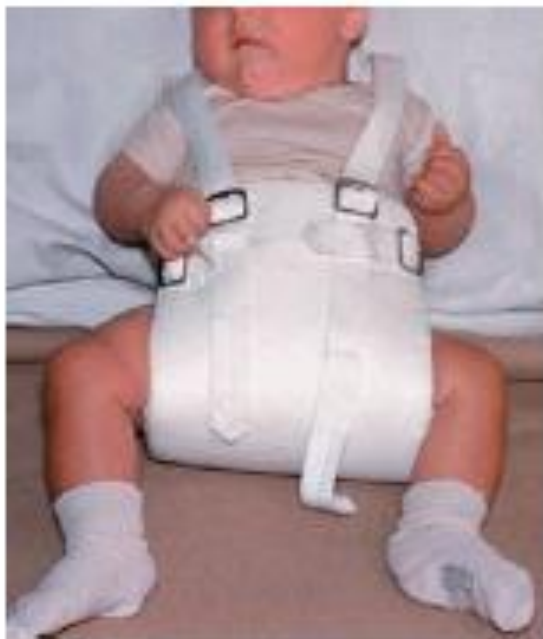(b)



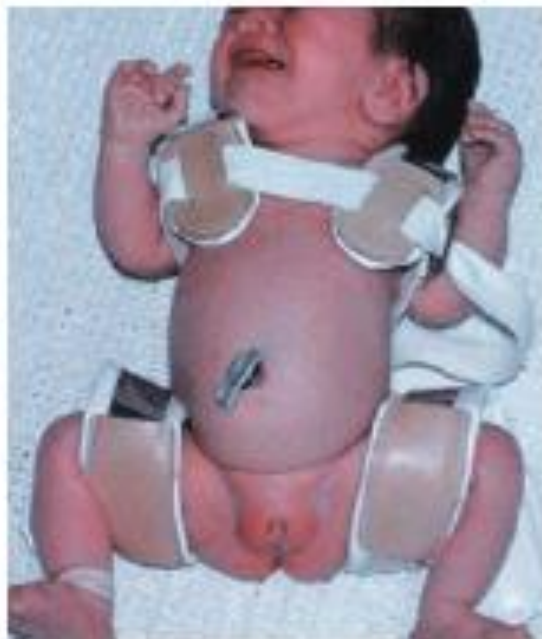(c)

**19.10 DDH – X-rays** (a) The left hip is dislocated, the femoral head is underdeveloped and the acetabular roof slopes upwards much more steeply than on the right side. In this case the features are very obvious but lesser changes can be gauged by geometrical tests. The epiphysis should lie medial to a vertical line which defines the outer edge of the acetabulum (Perkins' line) and below a horizontal line which passes through the triradiate cartilages (Hilgenreiner's line). (b) The acetabular roof angle should not exceed  $30^\circ$ . (c) Von Rosen's lines: with the hips abducted  $45^\circ$  the femoral shafts should point into the acetabula. In each case the left side is shown to be abnormal.

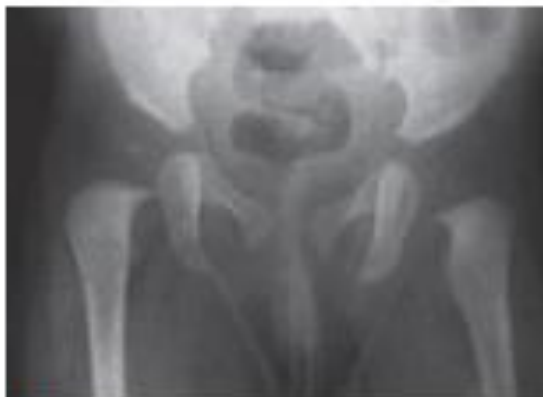



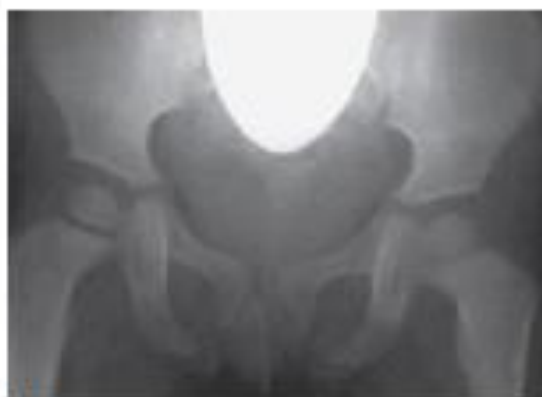(a)



(b)

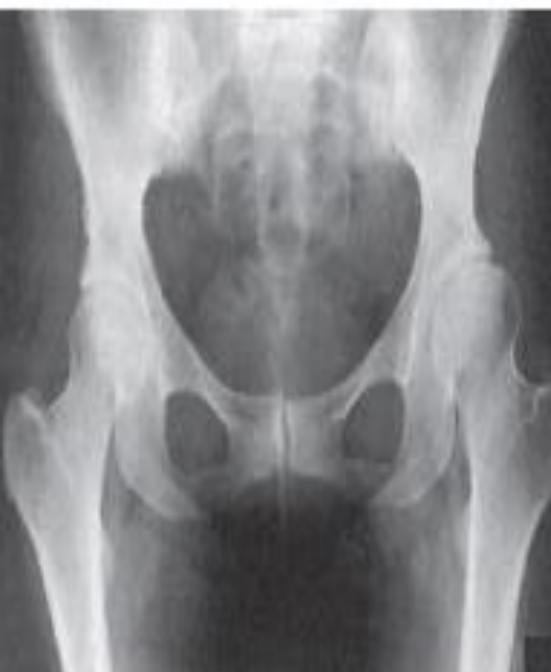

(c)

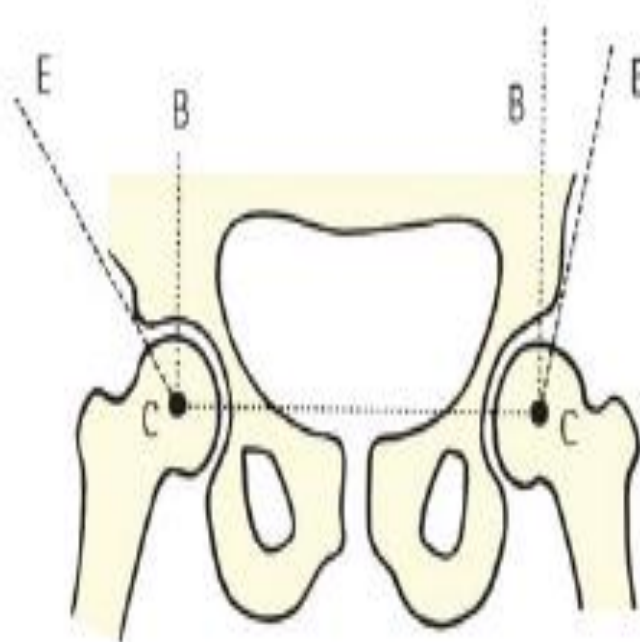


(d)

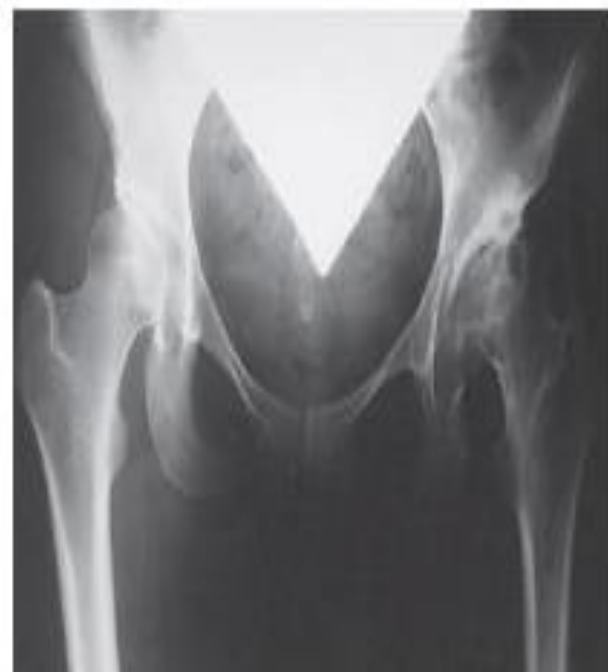**19.11 DDH – early treatment (a,b)** Various types of abduction splint. **(c,d)** X-rays showing result of splintage for DDH of the right hip at 3 months and 18 months.



(a)

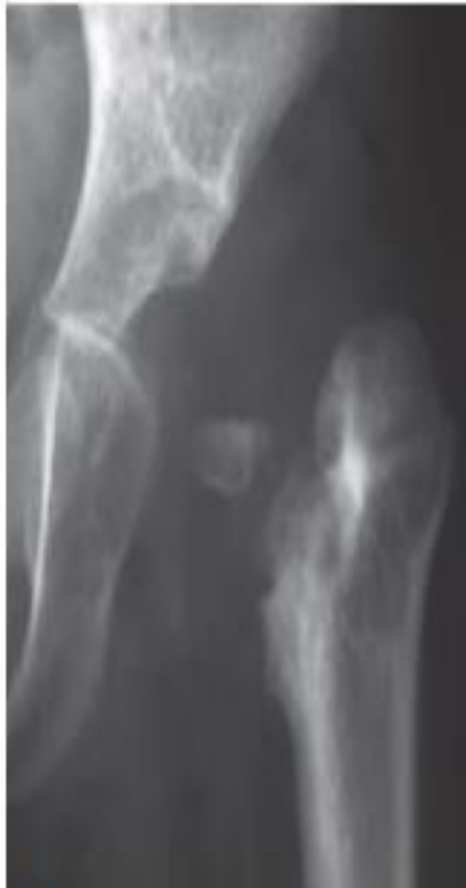

(b)

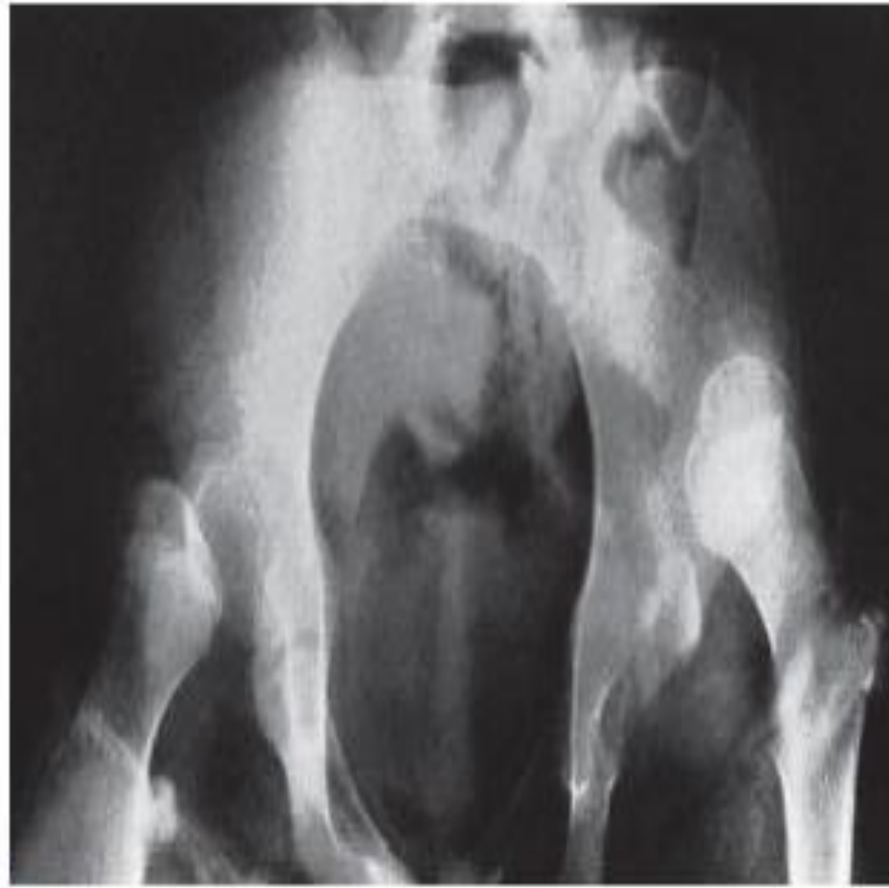

(c)

**19.15 Acetabular dysplasia** (a) X-ray showing a dysplastic left acetabulum. The socket is shallow and the roof sloping, leaving much of the femoral head uncovered. Note that the femoral neck-shaft angle is somewhat valgus on both sides. (b) Measuring Wiberg's centre-edge (CE) angle; the line C-C joins the centre of each femoral head; C-B is perpendicular to this and C-E cuts the superior edge of the acetabulum. The angle BCE should not be less than  $30^\circ$ ; in this case the left hip is abnormal. (c) X-ray of another patient showing acetabular dysplasia on the right side and secondary osteoarthritis in an untreated dysplastic left hip.



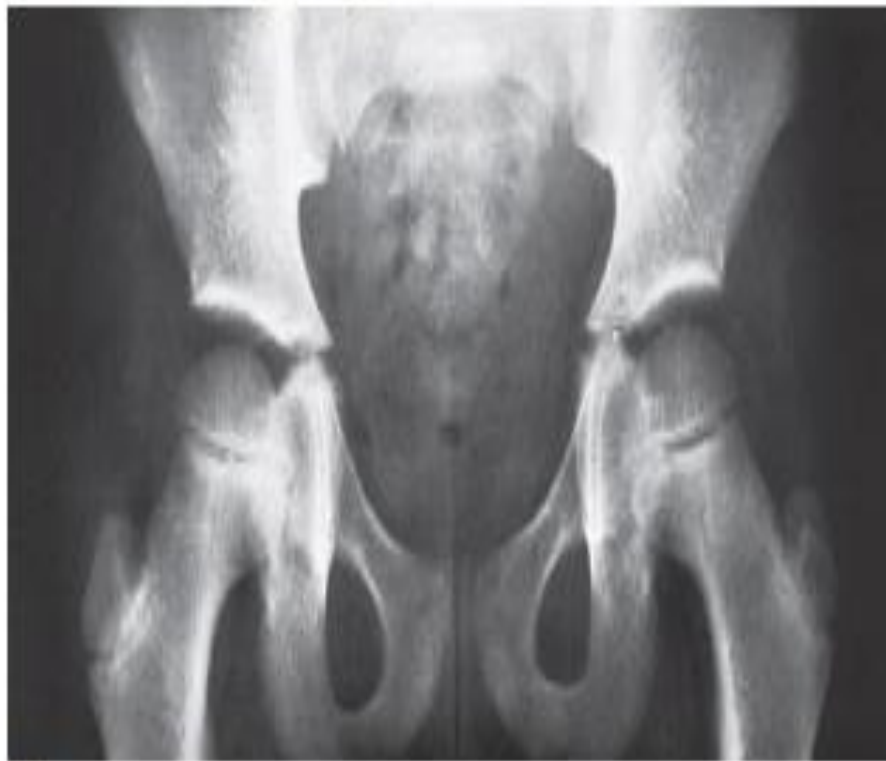(a)



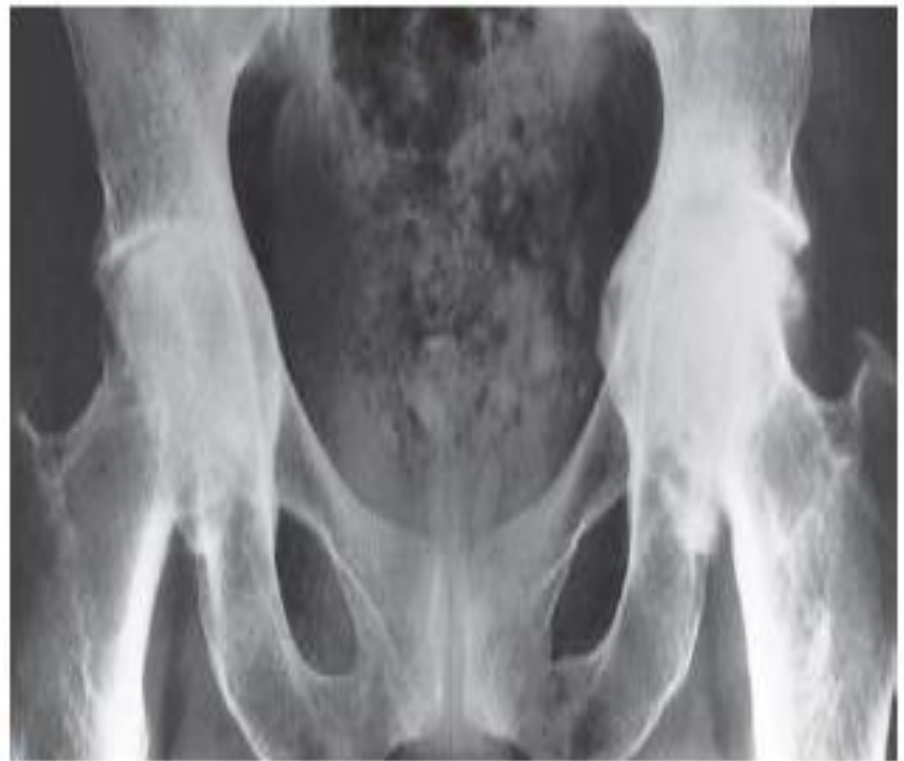(b)

### 19.18 Acquired dislocation in children

(a) Almost complete destruction of the femoral head following neglected septic arthritis. (b) Bilateral dislocation in a child with muscle imbalance due to spina bifida.



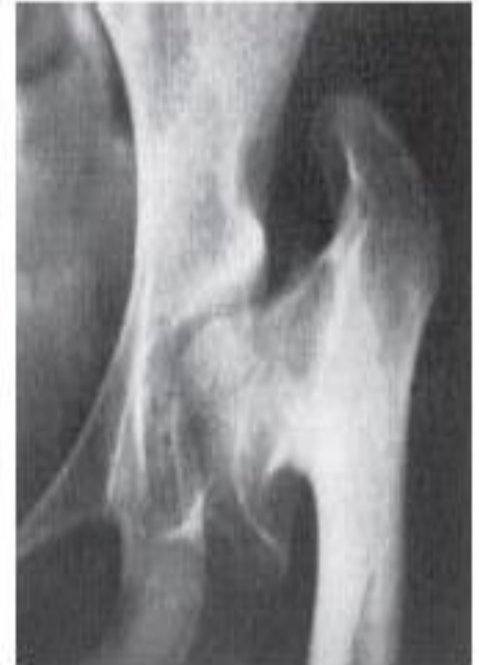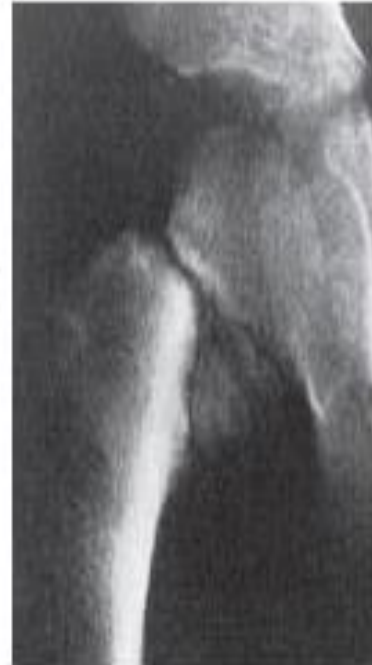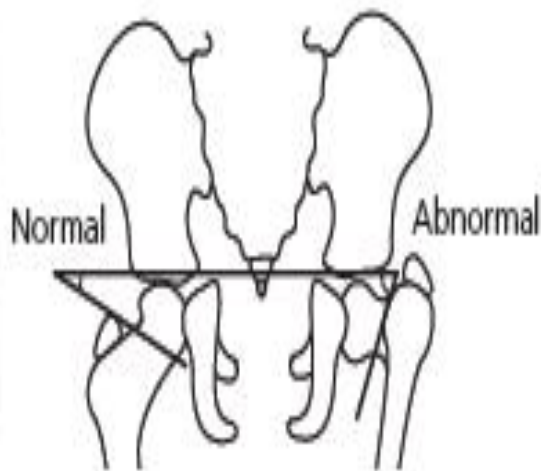
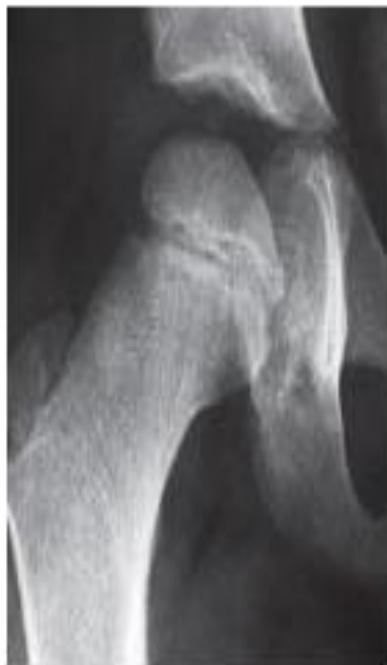(a)



(b)

**19.20 Protrusio acetabuli** (a) The early stage in a child. (b) In this adult with protrusio, degenerative changes have developed in both hips.





(a)

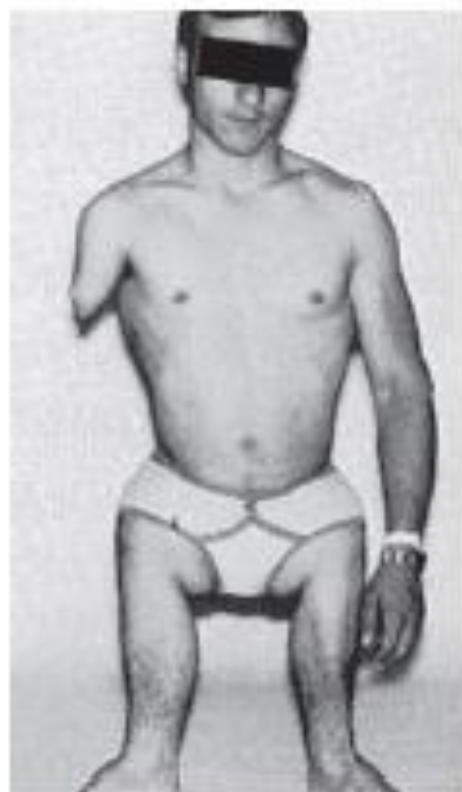(b)

(c)

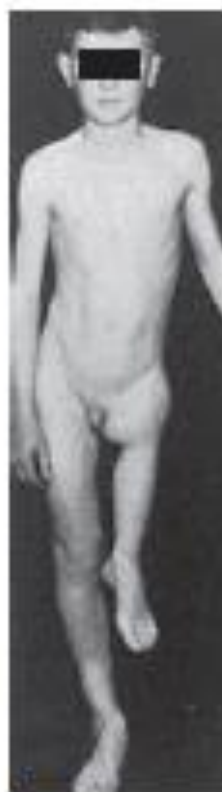(d)

**19.21 Infantile coxa vara** In the normal hip (a) Hilgenreiner's epiphyseal angle is well within the normal range of 30–40°. The measurements are shown in (b). On the opposite side (c) the physis is too vertical: 45–60° calls for careful follow-up and review, and more than 60° is an indication for Pauwels' valgus osteotomy. In a neglected case (d) the trochanteric physis allows further growth but the femoral neck may remain fixed in marked varus.

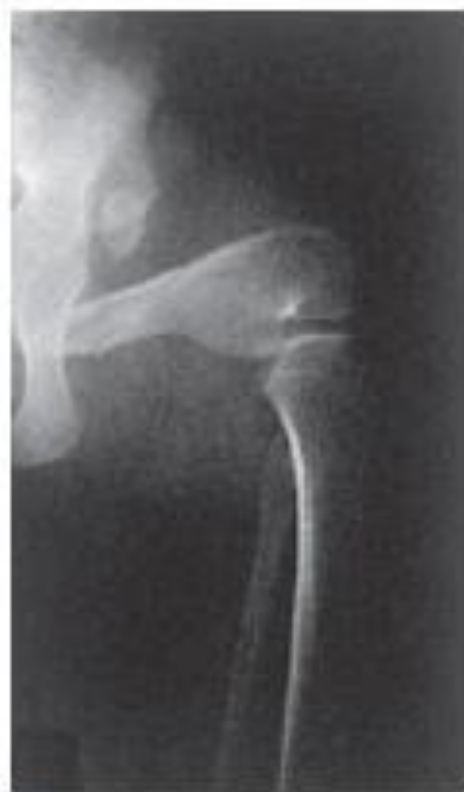



(a)

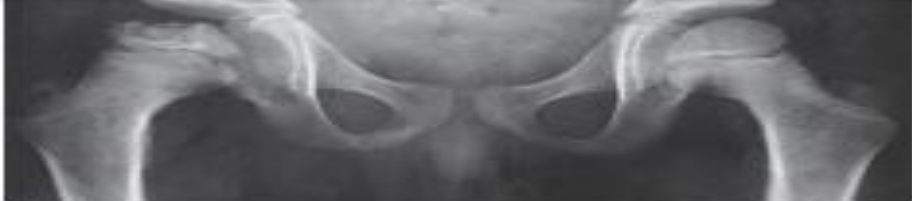

(b)

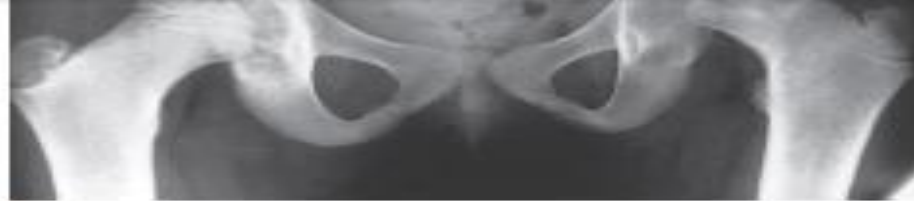

(c)

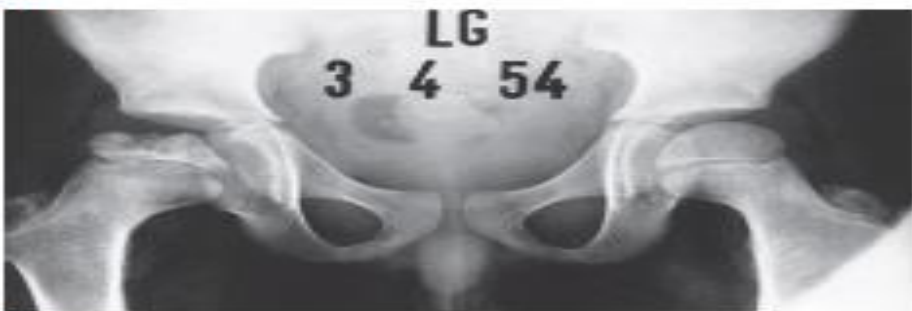**19.24 Proximal femoral dysplasia** (a) This man was born with transverse deficiency of the right arm and bilateral proximal femoral focal deficiency. Although unhappy with his appearance, because the lower limb defects were symmetrical he was able to get about remarkably well. (b) By contrast, this young man with similar but unilateral dysplasia was severely disabled. (c) X-ray showing the proximal femoral deficiency.



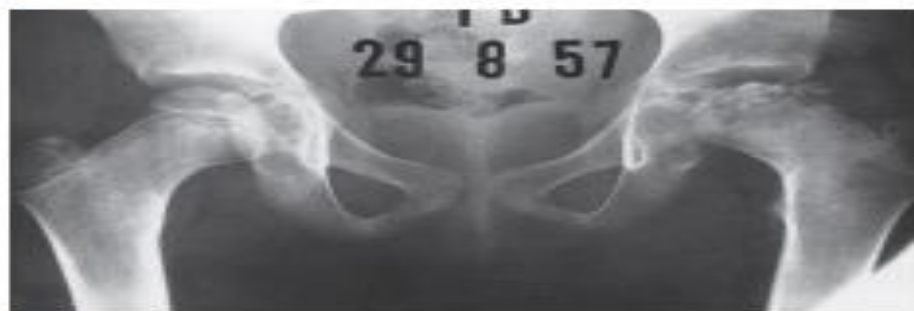(a)



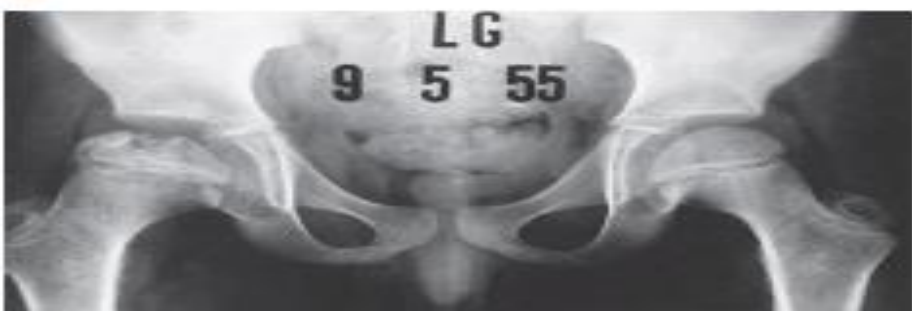
(b)



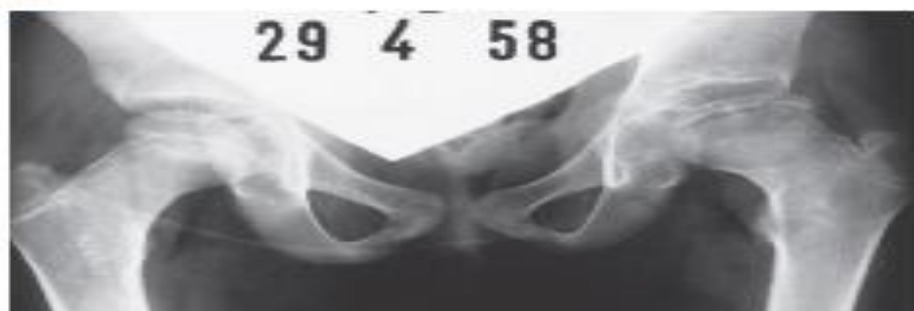(c)



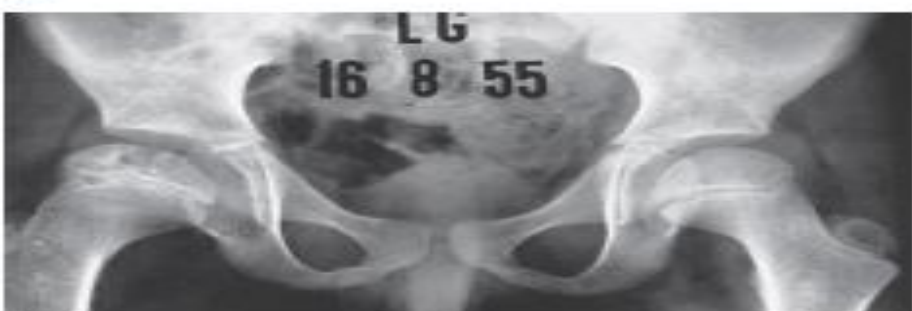(d)



(e)



(f)

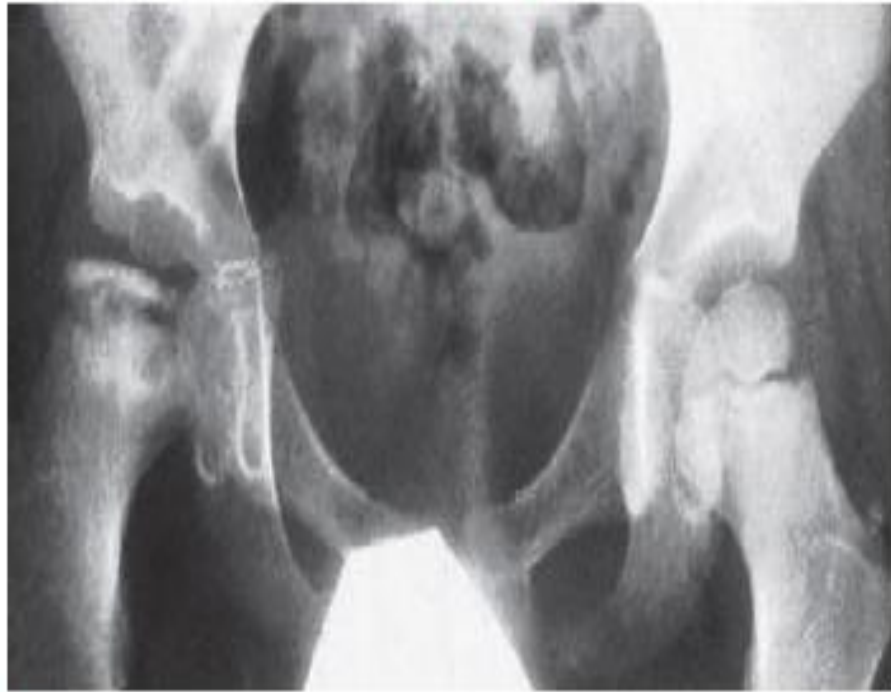

(g)

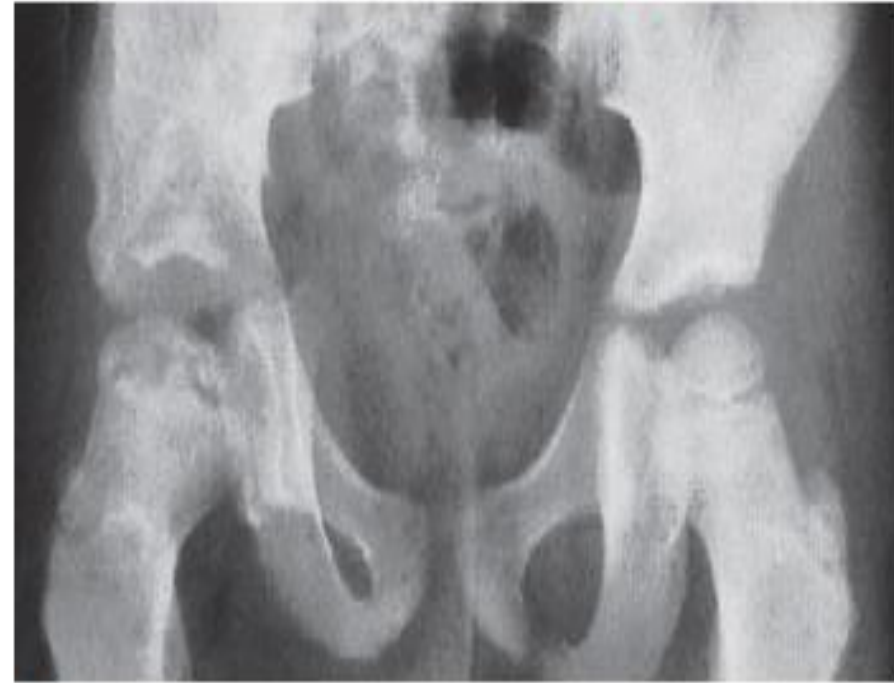

(h)

**19.25 Perthes' disease – Herring classification** The Herring classification is based on the severity of structural disintegration of the lateral pillar of the femoral epiphysis. Column 1 shows the changes in a boy with moderately severe Perthes' disease of the right hip. Although the central part of the epiphyseal ossific centre seems to be 'fragmented', the lateral part remains intact throughout the progress of the disease. This is a favourable feature and serial x-rays show how the femoral head has gradually re-formed. Column 2 shows progressive changes in another boy with severe Perthes' disease of the left hip. The epiphysis is widely involved from the outset, 'fragmentation' extends to the most lateral portion of the epiphysis and there is progressive flattening of the epiphysis resulting in permanent distortion of the femoral head.



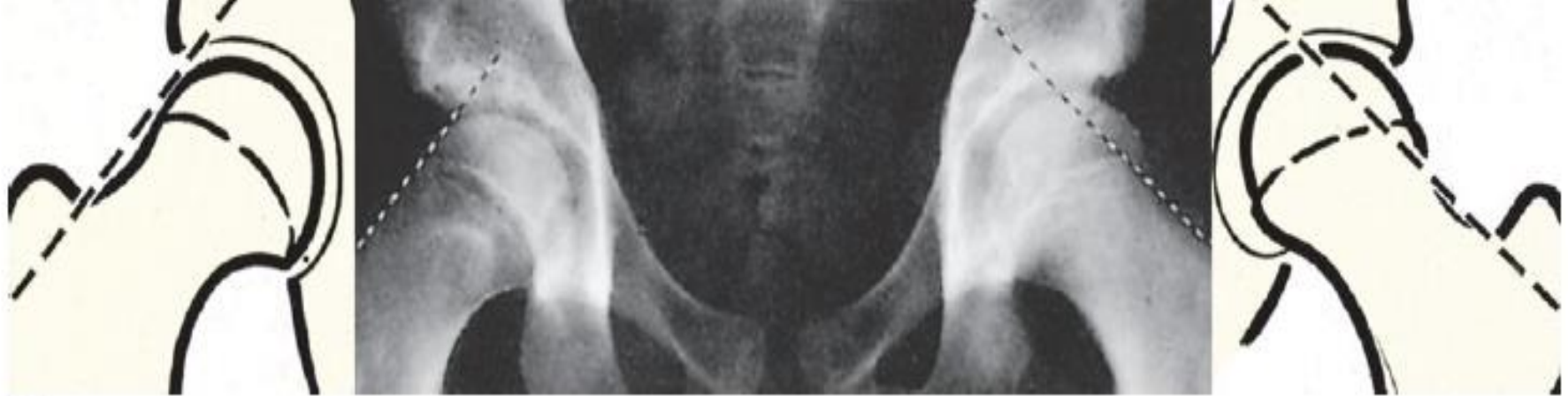(a)



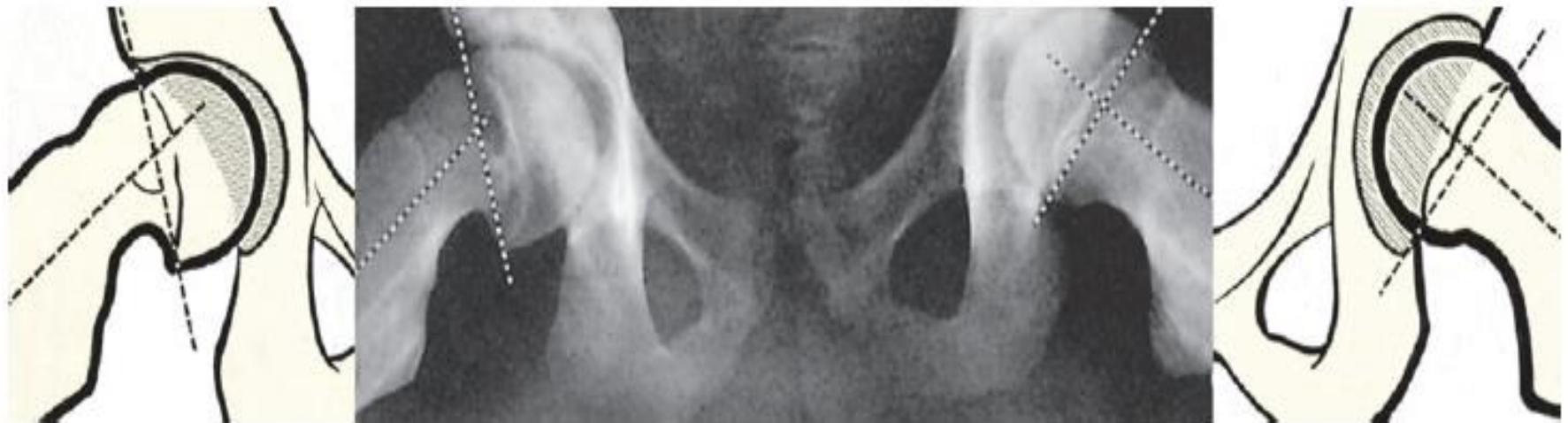(b)

**19.26 Perthes' disease – operative treatment** (a) The x-ray shows advanced Perthes changes and lateral displacement of the right femoral head. (b) Following an innominate osteotomy, the femoral head is much better 'contained' and, although not normal, is developing reasonably well.



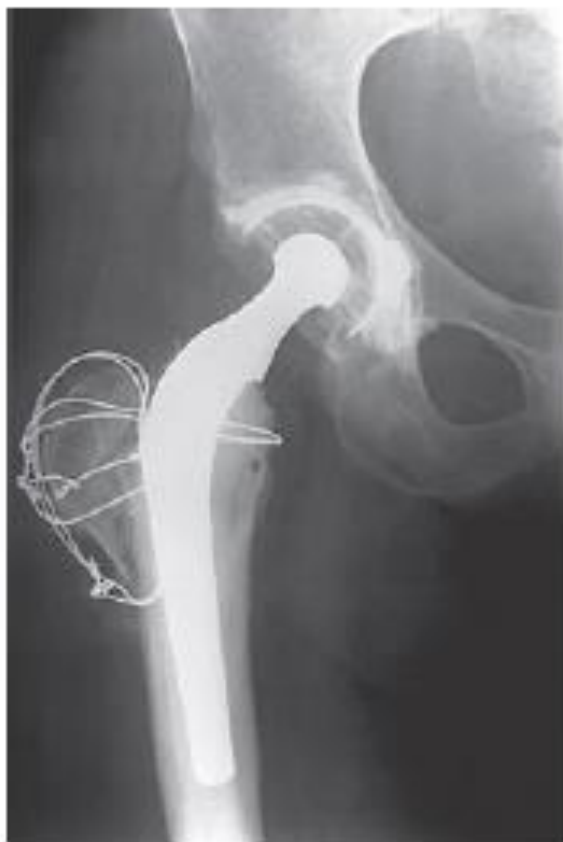

(a)

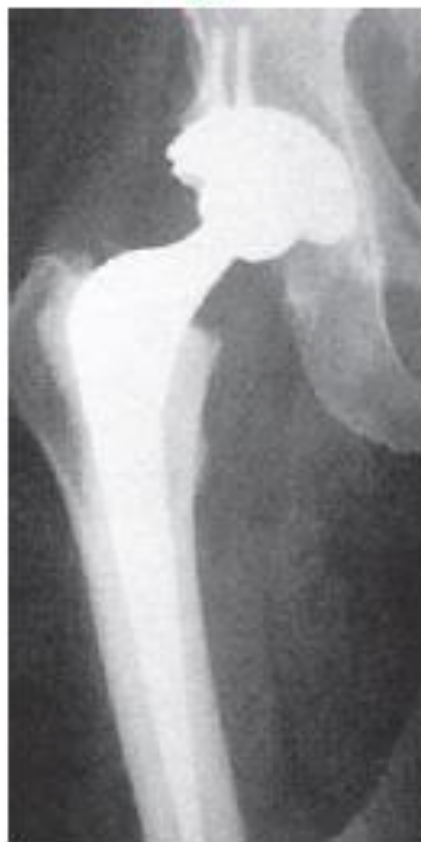

(b)

**19.28 Slipped epiphysis – x-rays** (a) Anteroposterior and (b) lateral views of early slipped epiphysis of the right hip. The upper diagrams show Trethowan's line passing just above the head on the affected side, but cutting through it on the normal side. The lateral view is diagnostically more reliable; even minor degrees of slip can be shown by drawing lines through the base of the epiphysis and up the middle of the femoral neck – if the angle indicated is less than  $90^\circ$ , the epiphysis has slipped posteriorly.



(a)

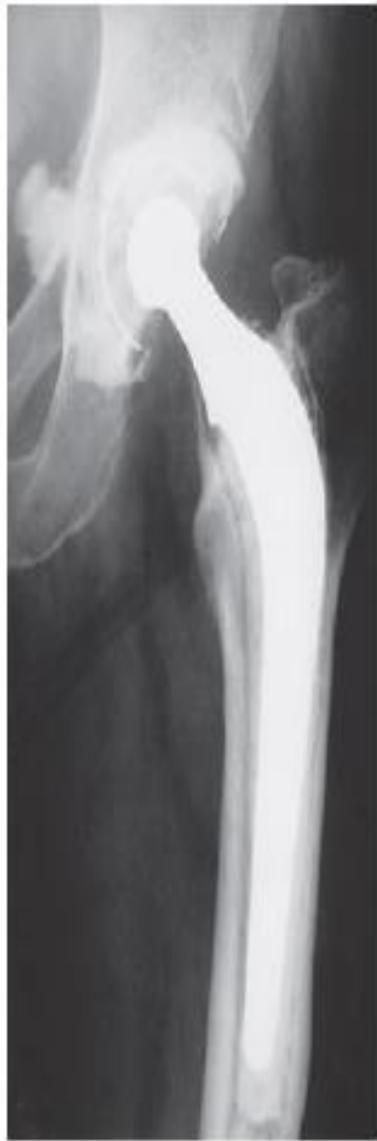

(b)

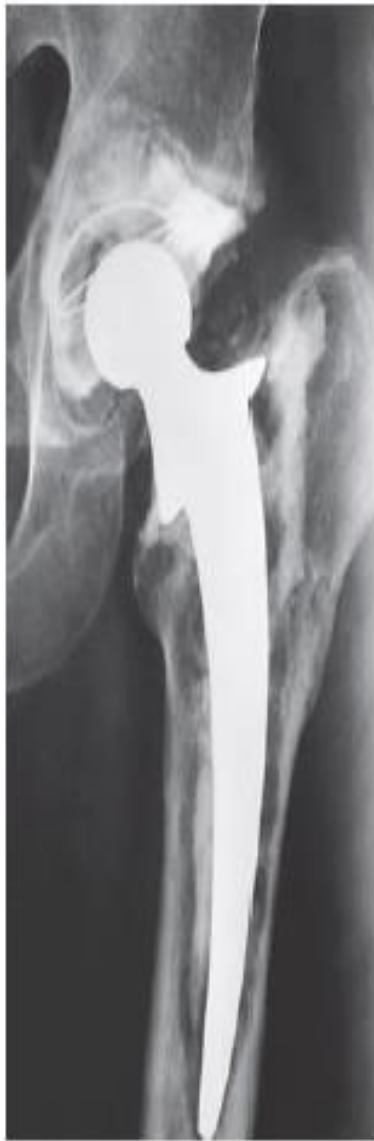**19.55 Total hip replacement** (a) X-ray of a Charnley hip replacement system, forerunner of all the modern methods of total hip replacement. This comprises a collared femoral prosthesis with a fairly wide stem and a polyethylene acetabular cup, both implants fixed with acrylic cement.

(b) X-ray of a cemented Ling femoral prosthesis – collarless with a tapered stem – and an uncemented acetabular cup.

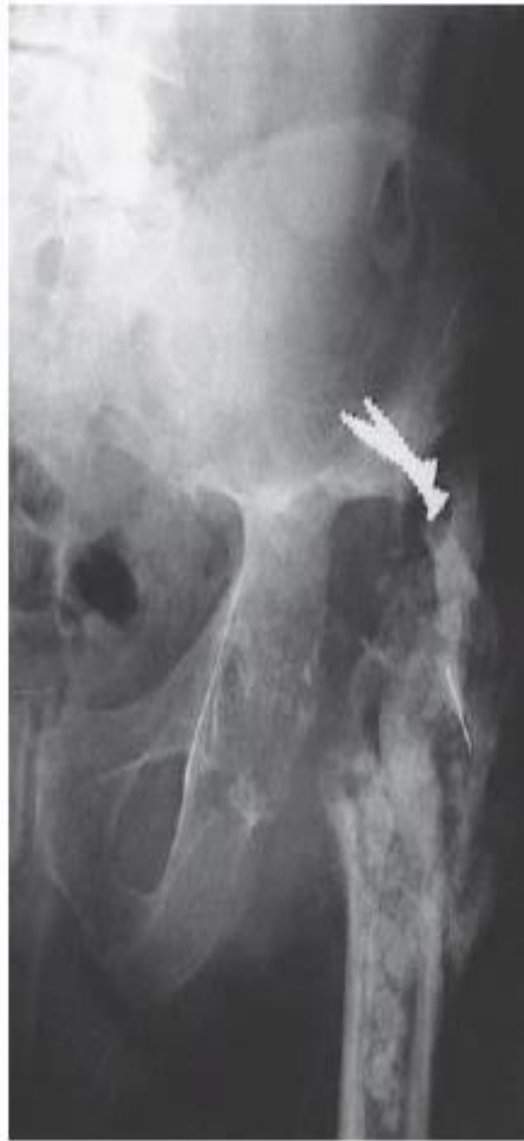



(a)

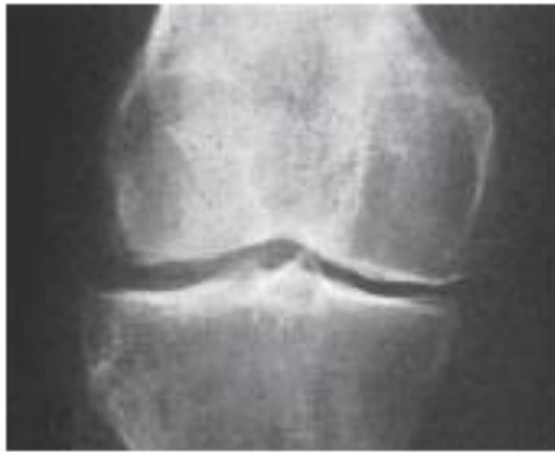

(b)

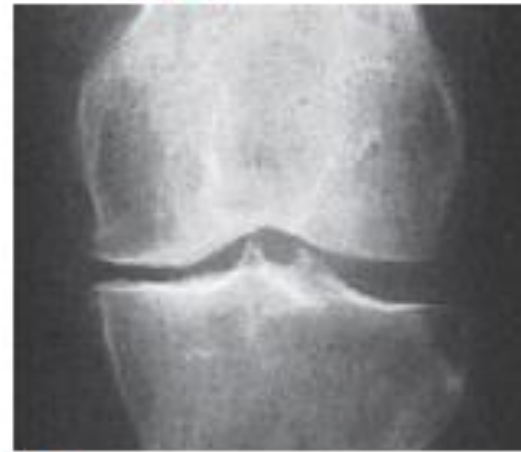

(c)

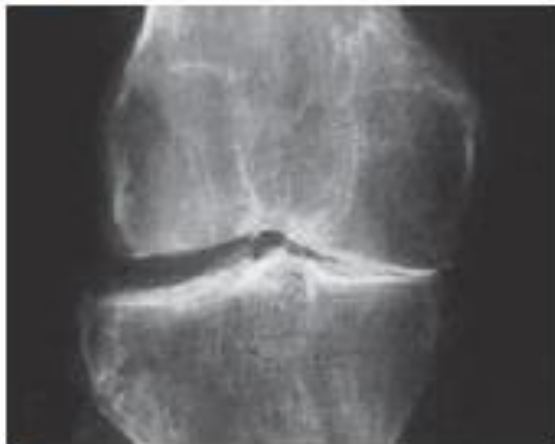
**19.56 Hip replacement – aseptic loosening** (a) Ten years after a hip replacement there is a distinct radiolucent line around this femoral implant as well as resorption of the calcar. (b) A further stage shown in another patient. Aggressive osteolysis. (c) The end of the line. This patient, after four 'revisions', ended up with fragmentation of the proximal femur, massive resorption of the acetabulum and fragments of bone and acrylic cement in the soft tissues. Happily, nowadays, few and far between but the risk is always there.



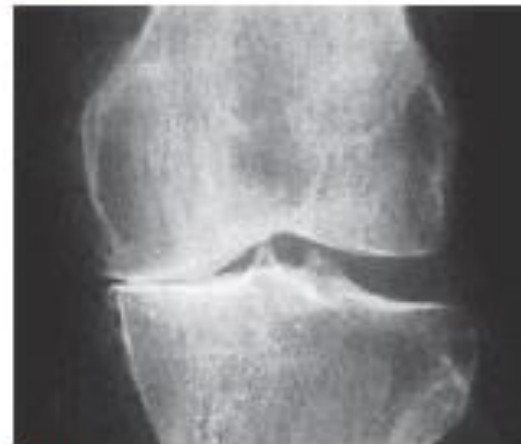(a)



(b)

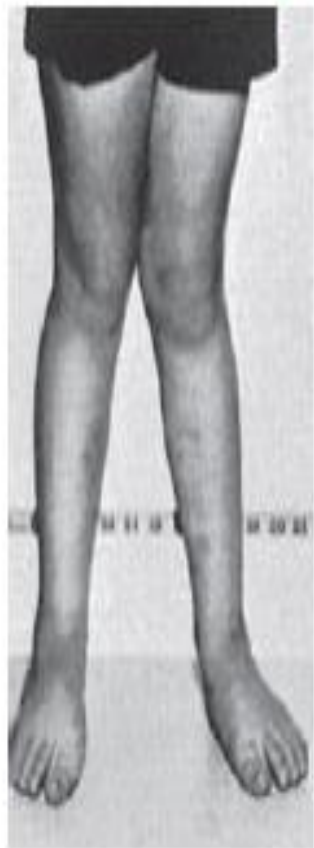


(c)

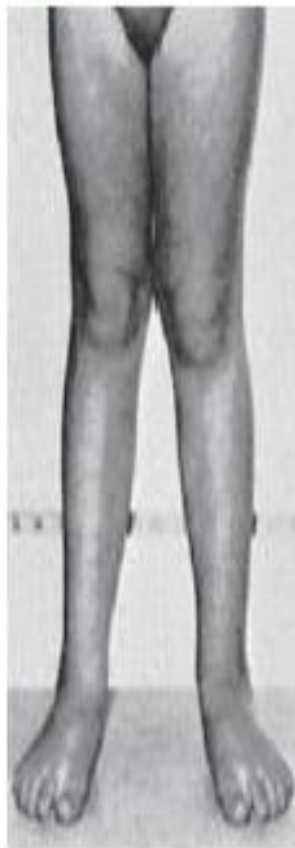

(d)

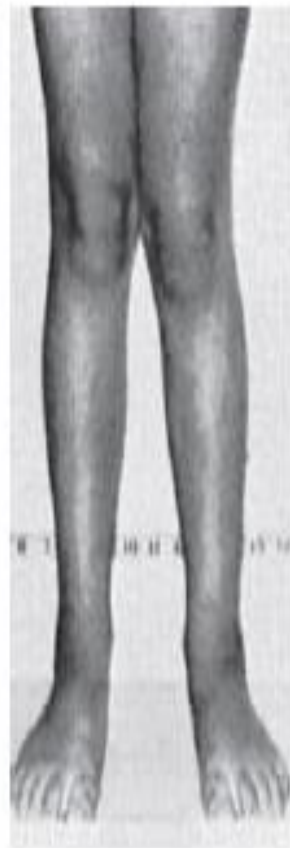
**20.10 X-rays** Anteroposterior views should always be taken with the patient standing. (a,b) X-rays with the patient lying down show only slight narrowing of the medial joint space on each side; but with weightbearing (c,d) it is clear that these changes are much more marked.



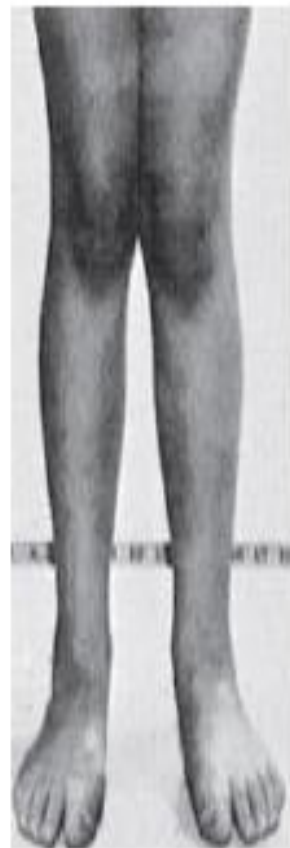(a)



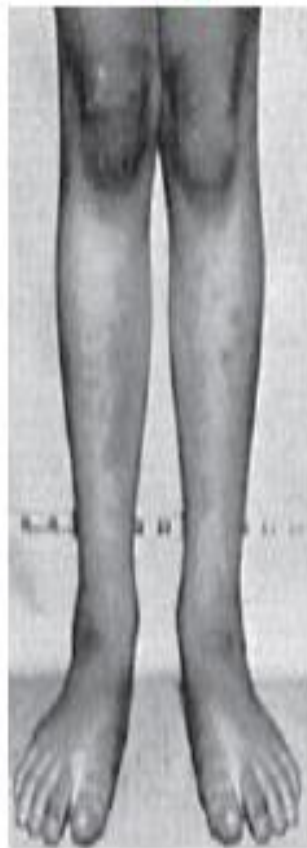(b)



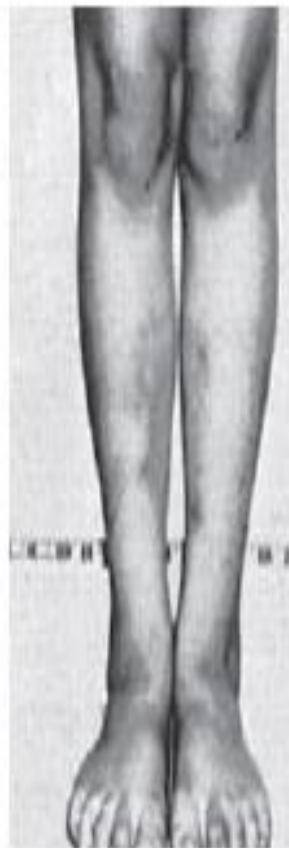(c)



(d)

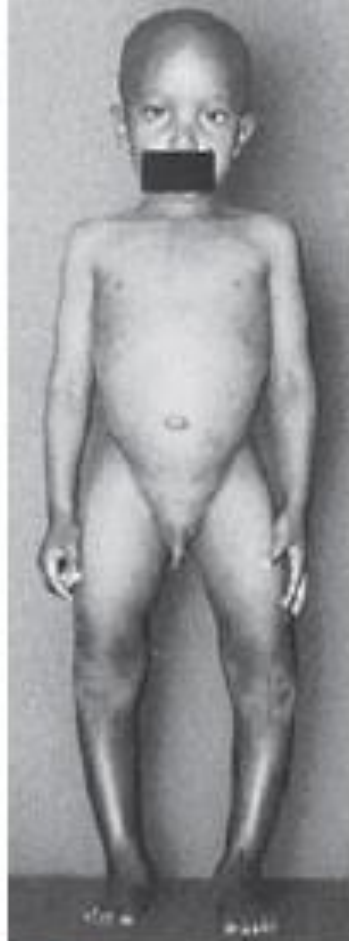

(e)

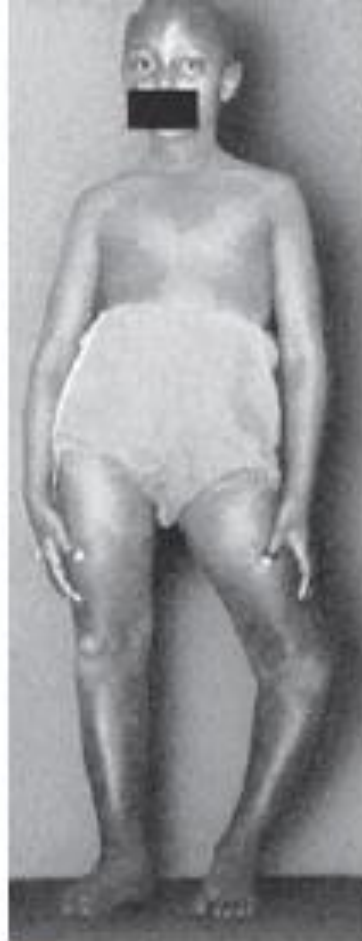

(f)

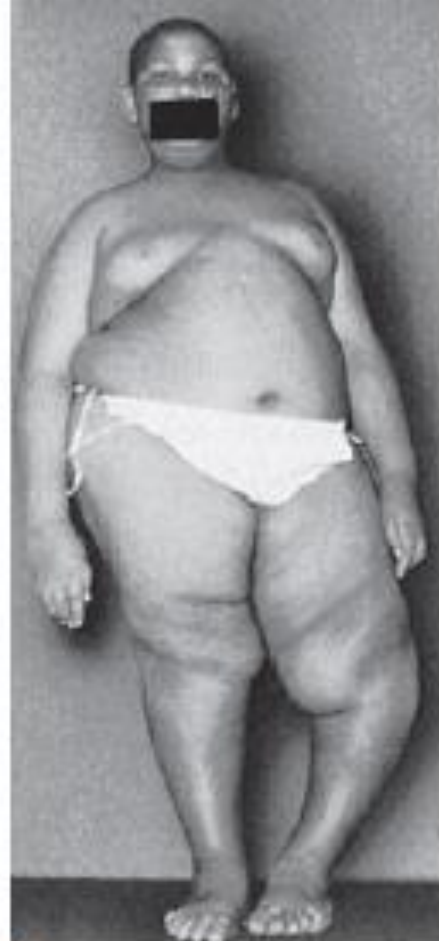**20.13 Physiological genu valgum** 'Knock-knees' in young children usually correct spontaneously. These pictures of the same child were obtained at various ages between 3 and 7 years.



(a)

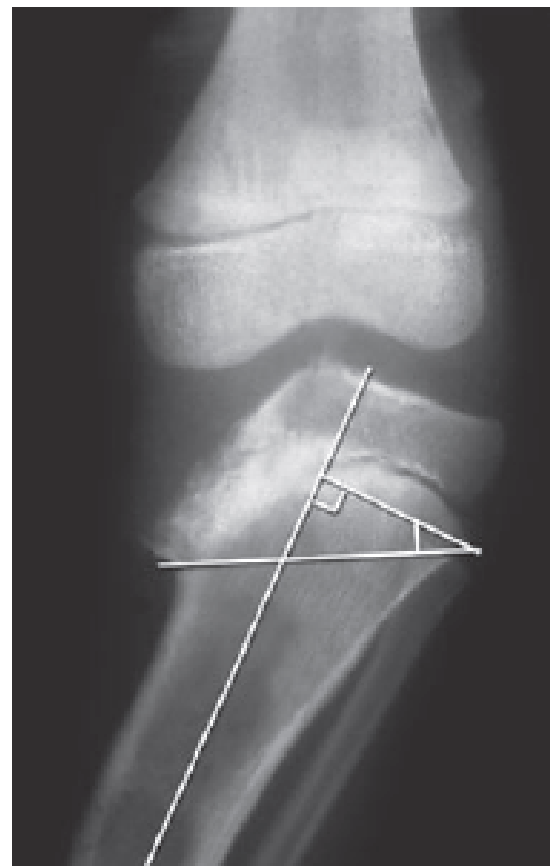
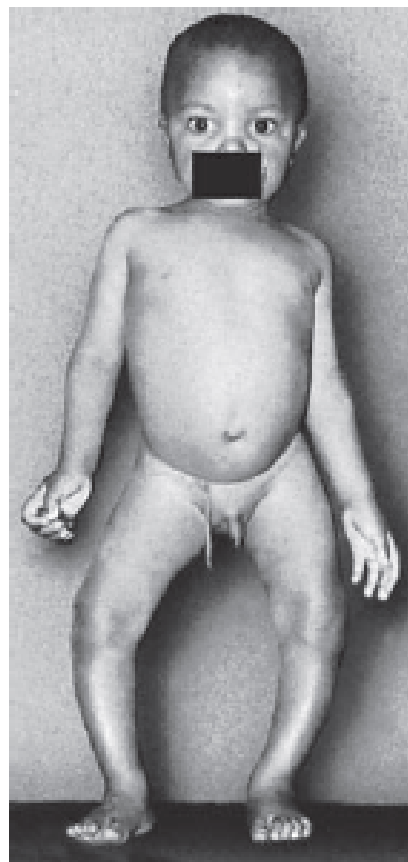

(b)



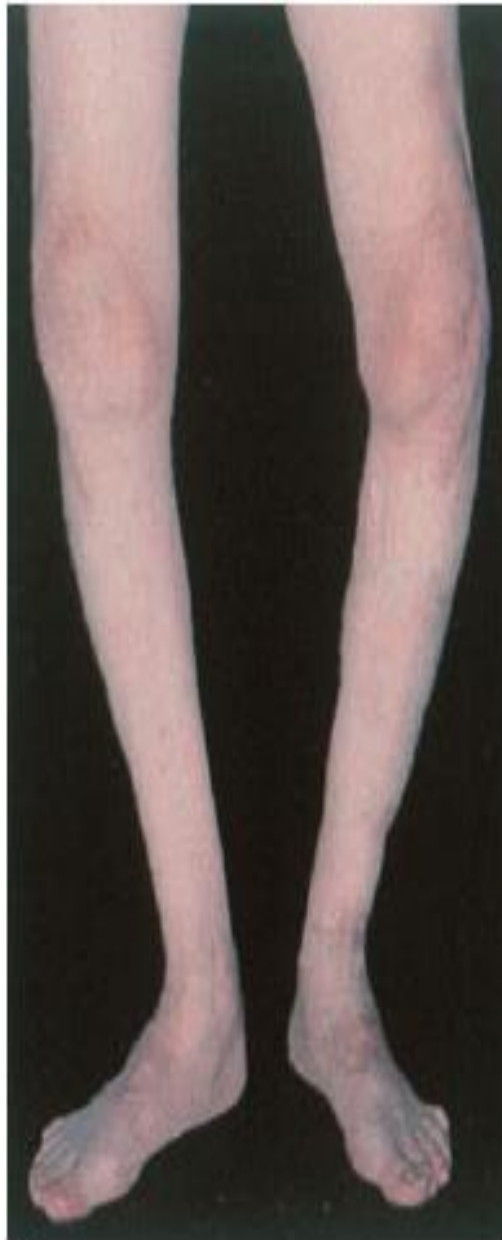(c)

**20.15 Pathological bow legs** (a) Child with healed rickets. (b) Growth deformity following a fracture involving the proximal tibial physis. (c) The deformity here was due to a 'slipped' proximal tibial epiphysis in a child with an endocrine disorder.

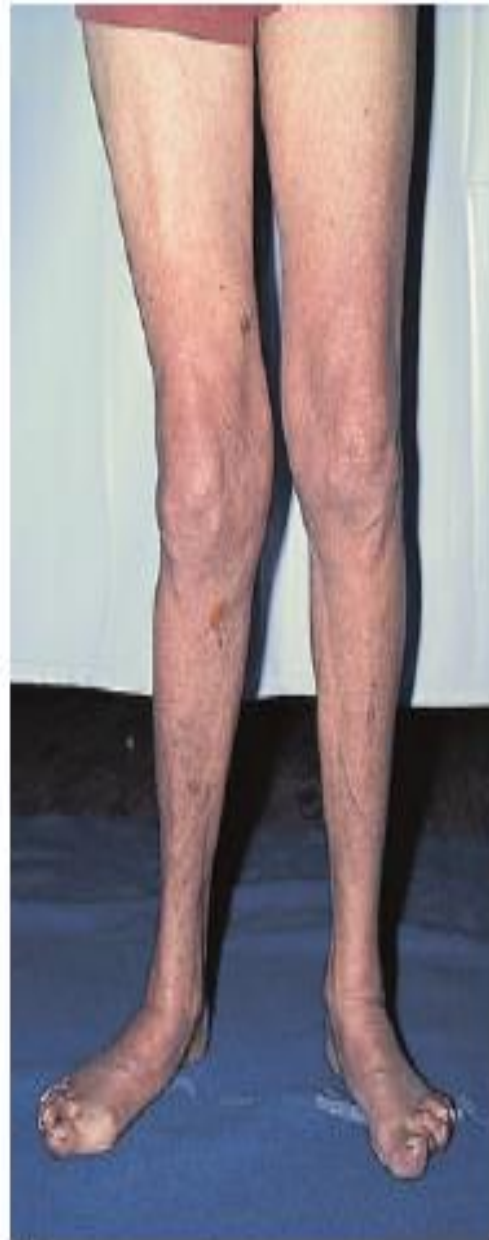

**20.16 Blount's disease** In contrast to the children in Fig. 20.15, this young boy developed progressive bow-legged deformities from the time he started walking. X-rays showed the typical features of Blount's disease: marked distortion of the tibial epiphysis, as if one half of the growth plate (physis) had fused and stopped growing. Changes can be accurately assessed by measuring the *metaphyseal-diaphyseal angle*: a line is drawn perpendicular to the long axis of the tibia and another across the metaphyseal flare as shown on the x-ray; the acute angle formed by these two lines should normally not exceed  $11^\circ$ .

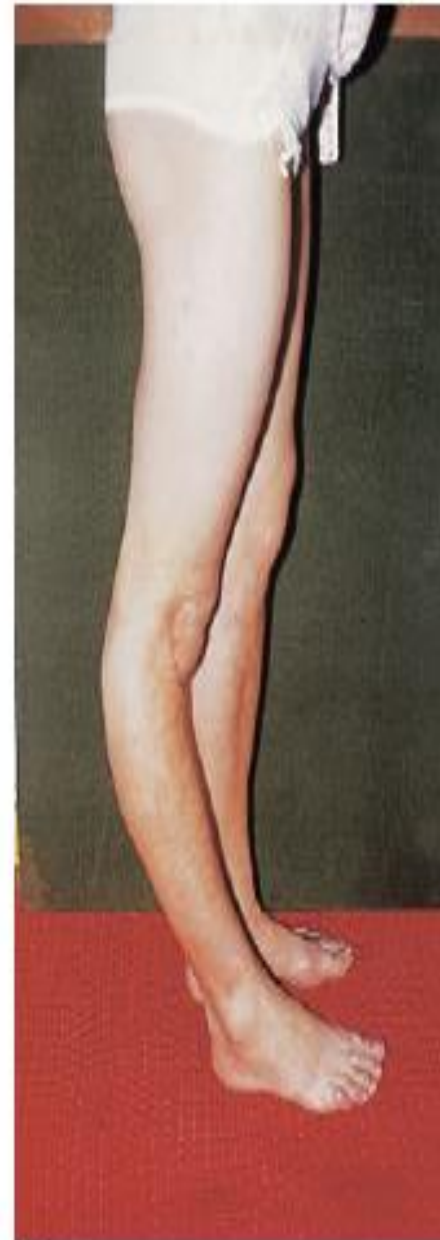



(a)

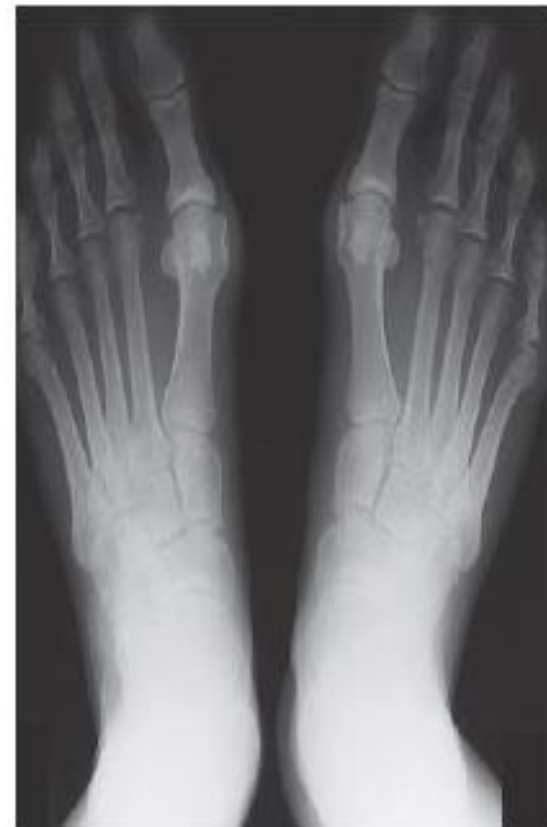
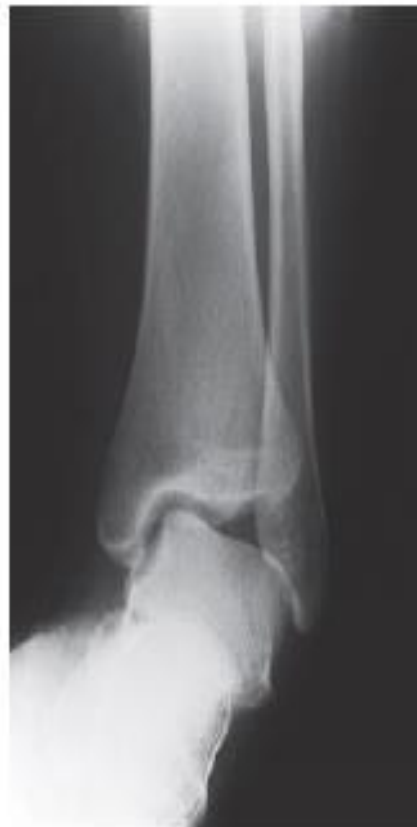
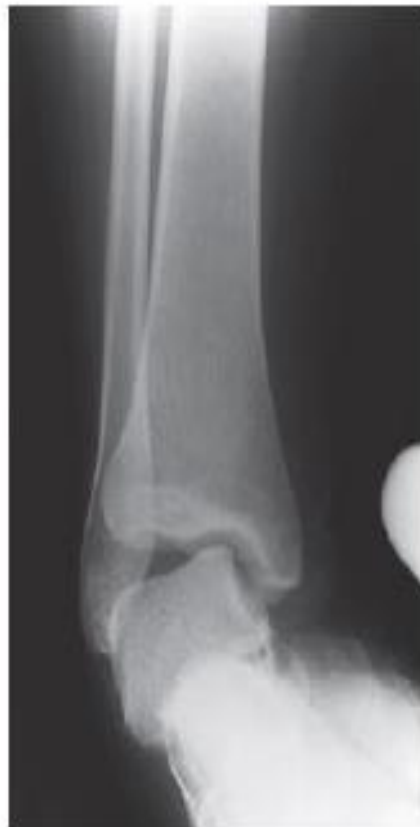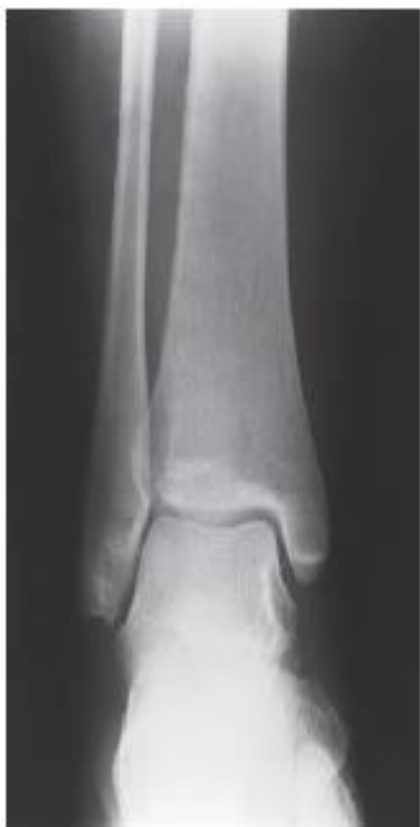(b)



(c)

**20.17 Knee deformities in adults** Genu varum is usually associated with osteoarthritis (a); genu valgum with rheumatoid arthritis (b); and genu recurvatum (c) with severe destructive arthritis (e.g. Charcot's disease) or a flail joint (e.g. post-poliomyelitis).



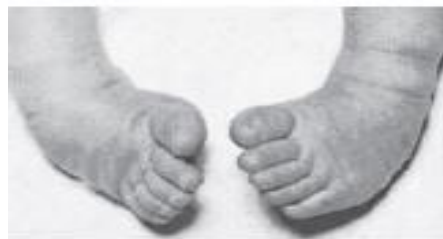(a)

(b)

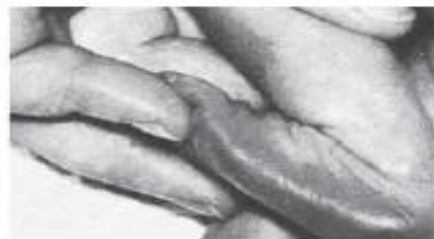(c)

(d)

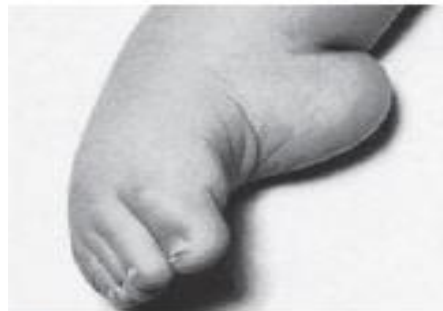**21.5 X-rays** (a) AP view of the ankle in a young woman who complained that after twisting her right ankle it kept giving way in high-heeled shoes. The x-ray looks normal; the articular cartilage width (the 'joint space') is the same at all aspects of the joint. The inversion stress view (b) shows that the talus tilts excessively; always x-ray both ankles for comparison and in this case the left ankle (c) does the same. She has generalized joint hypermobility, not a torn lateral ligament. (d) X-rays of the feet should be taken with the feet flat on the ground.



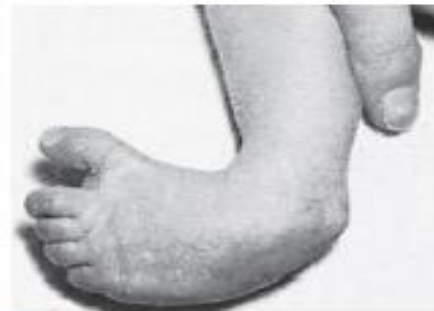(a)



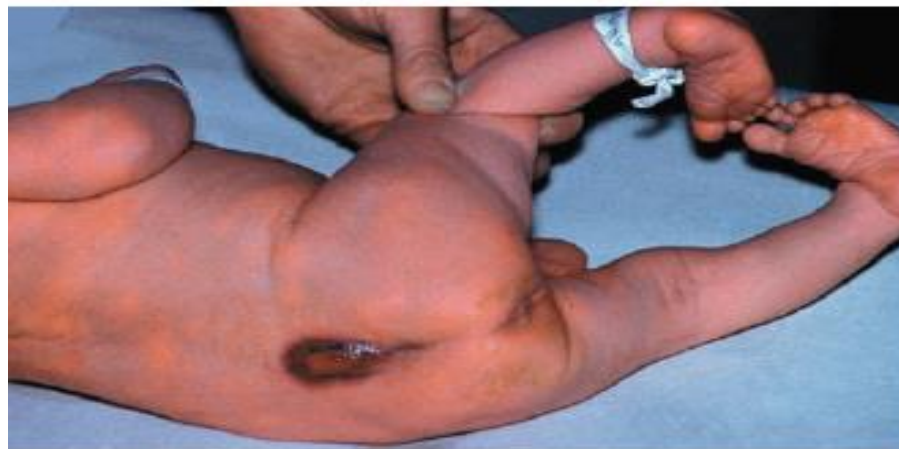(b)



(c)

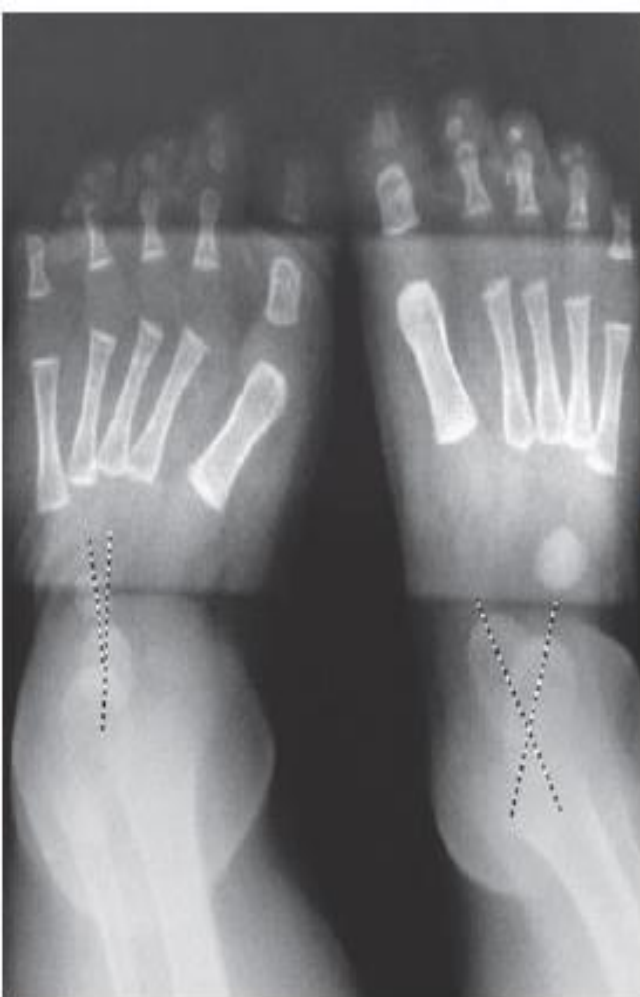

(d)

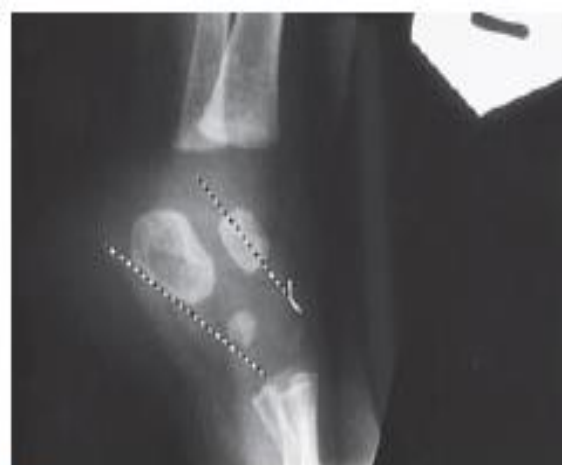

(e)

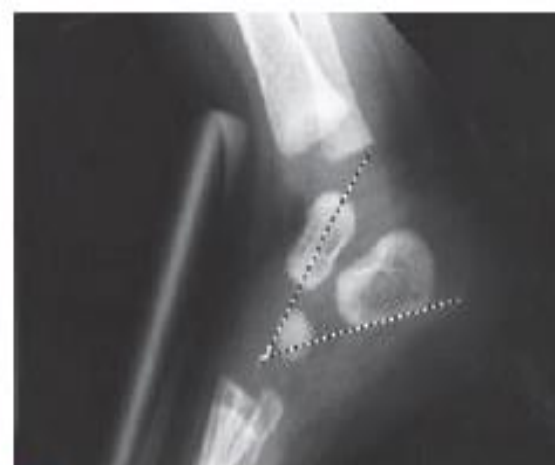**21.6 Talipes equinovarus (club-foot)** (a) True club-foot is a fixed deformity, unlike (b) postural talipes, which is easily correctable by gentle passive movement. (c,d) With true club-foot, the poorly developed heel is higher than the forefoot, which points downwards and inwards (varus). (e) Always examine the hips for congenital dislocation and the back for spina bifida (as in the case shown here).



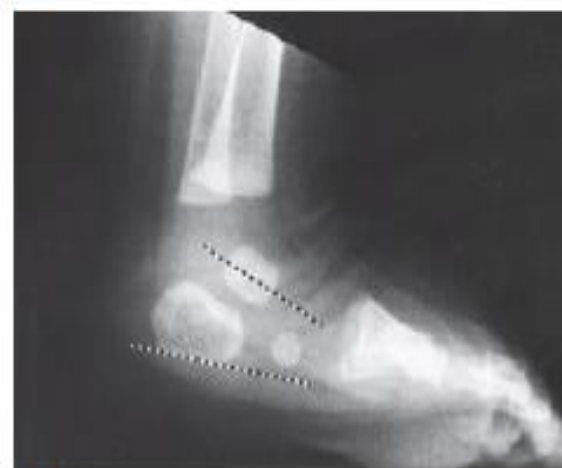(a)



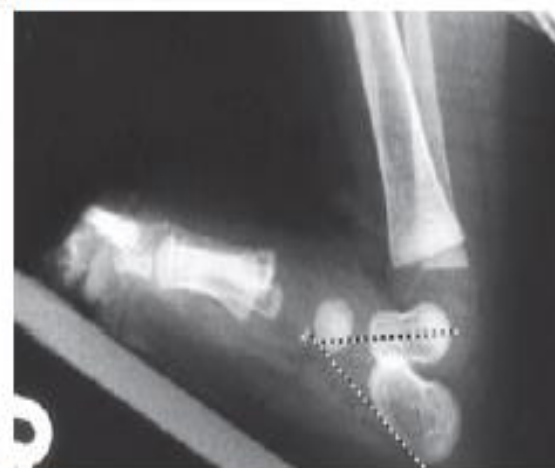(b)



(d)



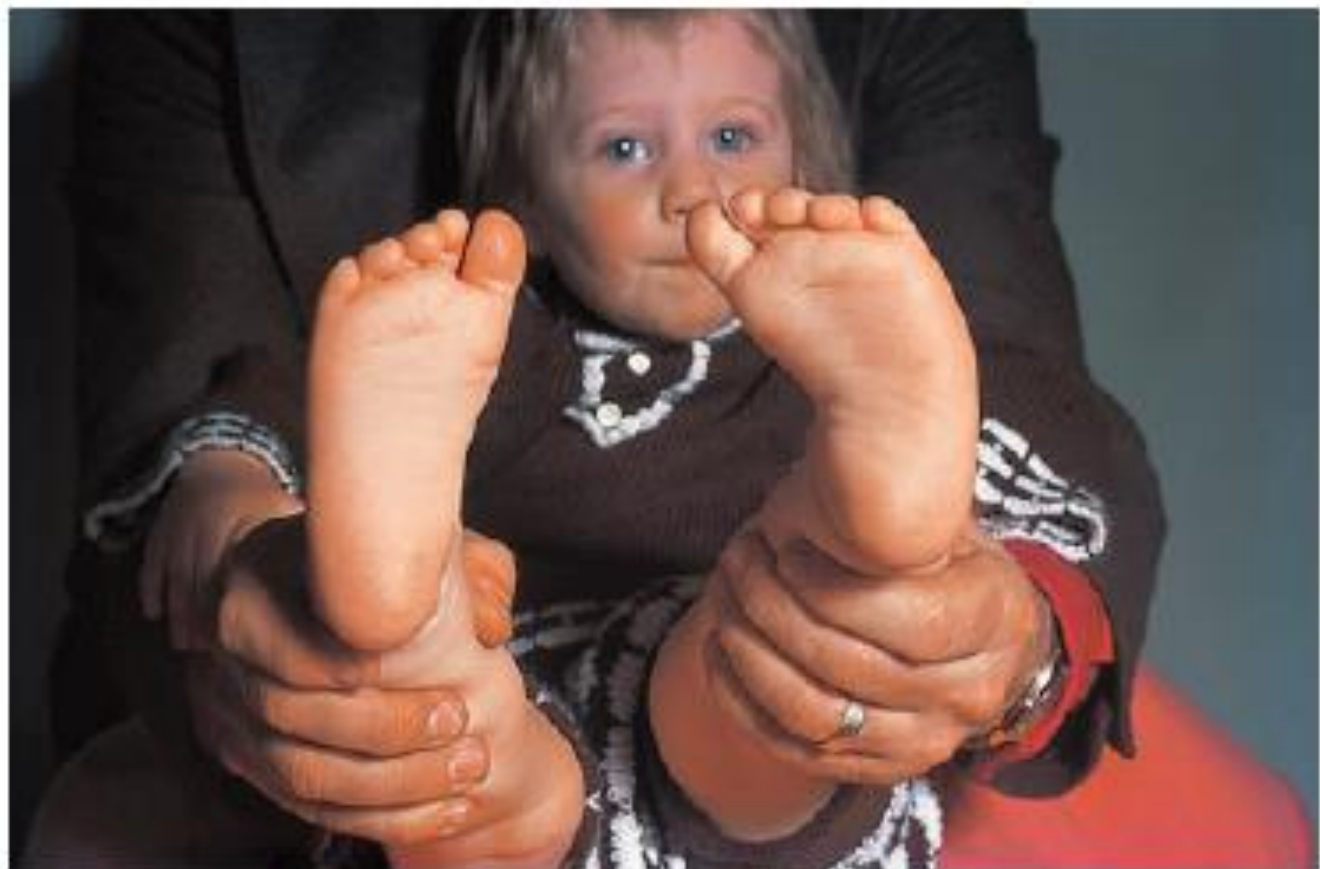(c)



(e)

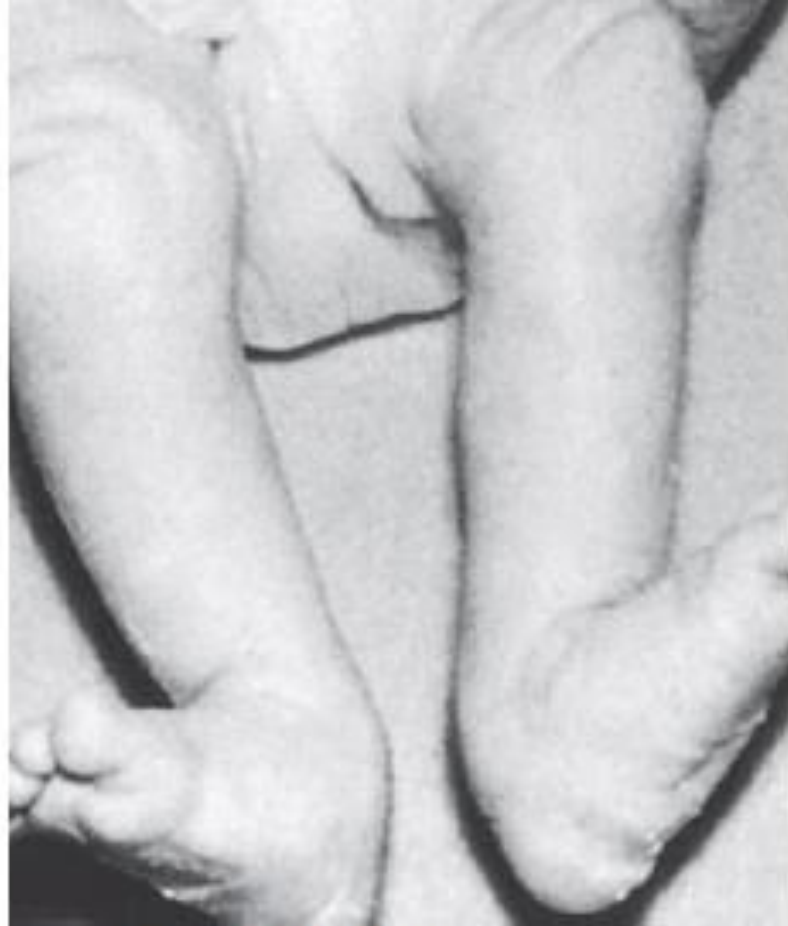**21.7 Talipes equinovarus – x-rays** The left foot is abnormal. In the anteroposterior view (a) the talocalcaneal angle is 5 degrees, compared to 42 degrees on the right. In the lateral views, the left talocalcaneal angle is 10 degrees in plantarflexion (b) and 15 degrees in dorsiflexion (c). In the normal foot the angle is unchanged at 44 degrees, whatever the position of the foot (d,e).



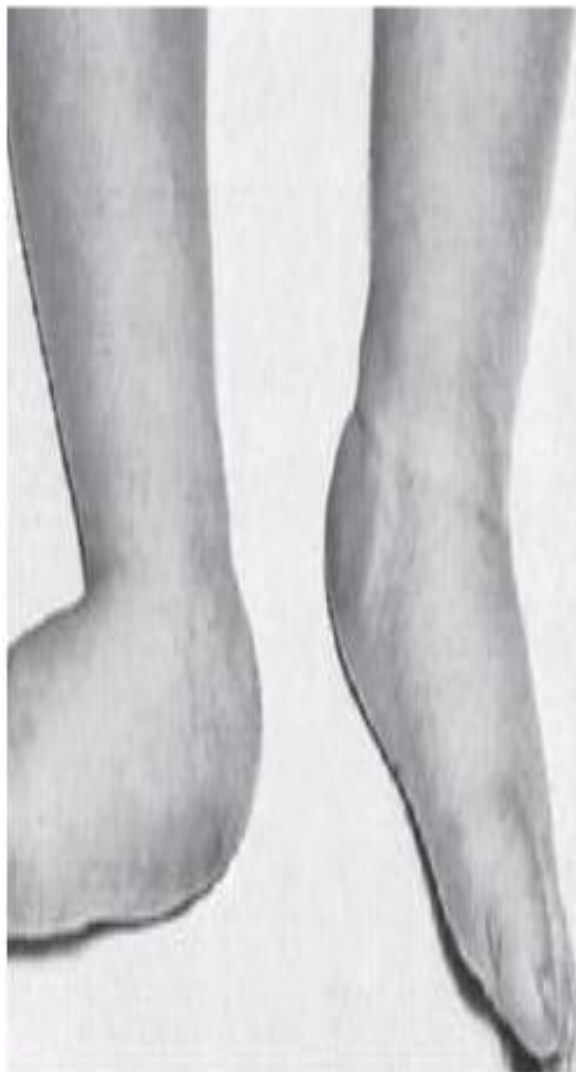


**21.9 Metatarsus adductus** In contrast to club-foot, the deformity here is limited to the forefoot.

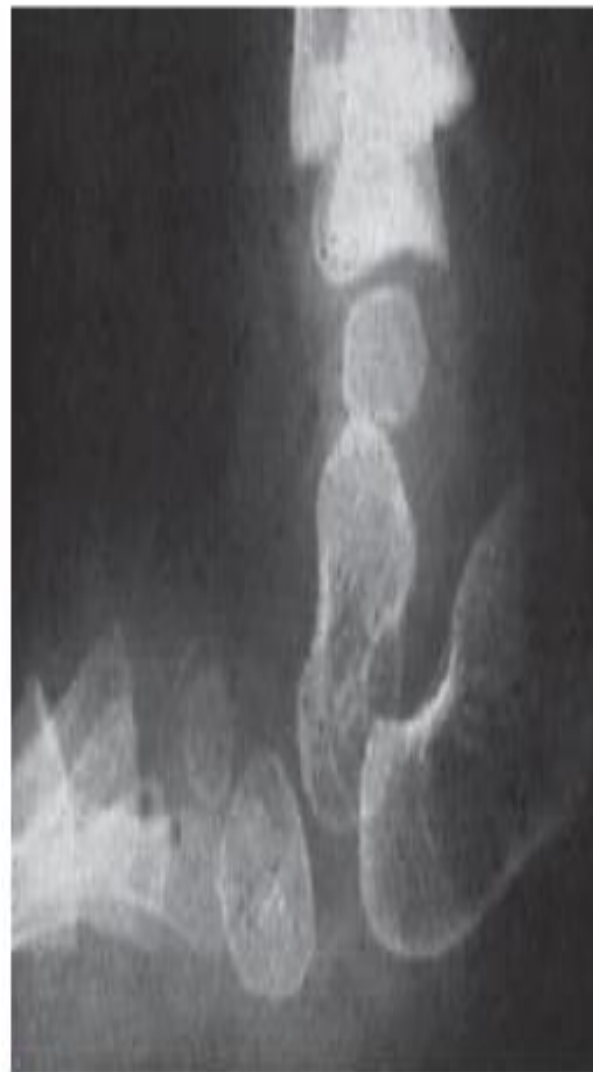



**21.10 Talipes calcaneovalgus** Bilateral calcaneovalgus. This benign 'deformity' can be easily corrected without hurting the baby. Over time it usually corrects spontaneously.



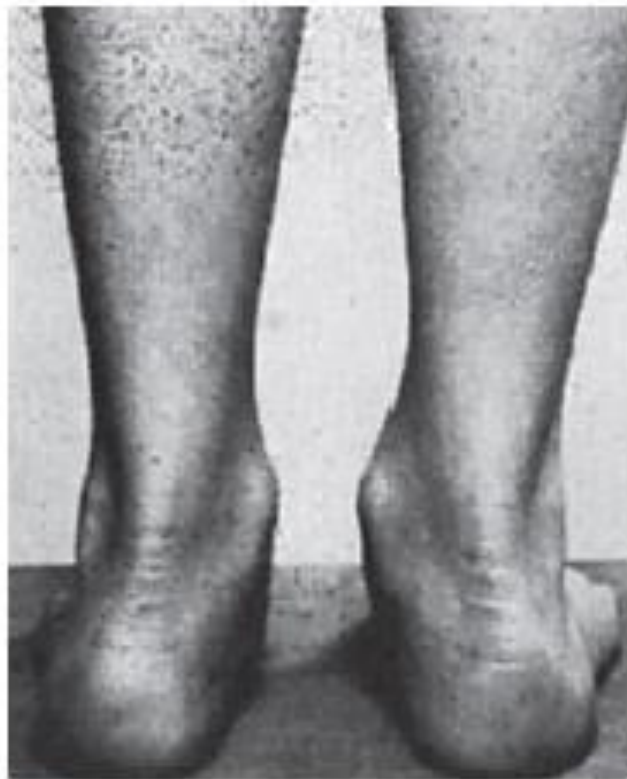(a)



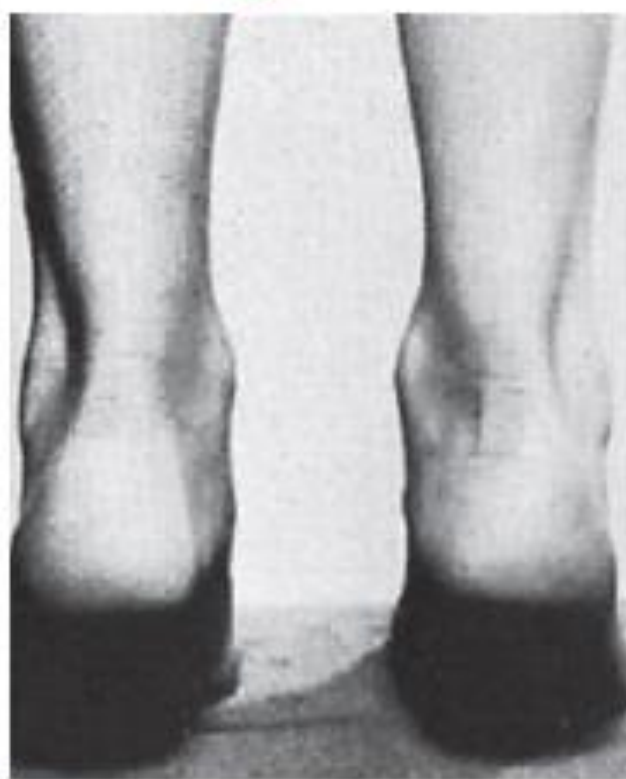(b)

## 21.11 Congenital vertical talus

(a) The infant's foot is in marked valgus and has a rocker-bottom shape. The deformity is rigid and cannot be corrected. (b) X-ray shows the vertical talus pointing downwards towards the sole and the other tarsal bones rotated around the head of the talus.

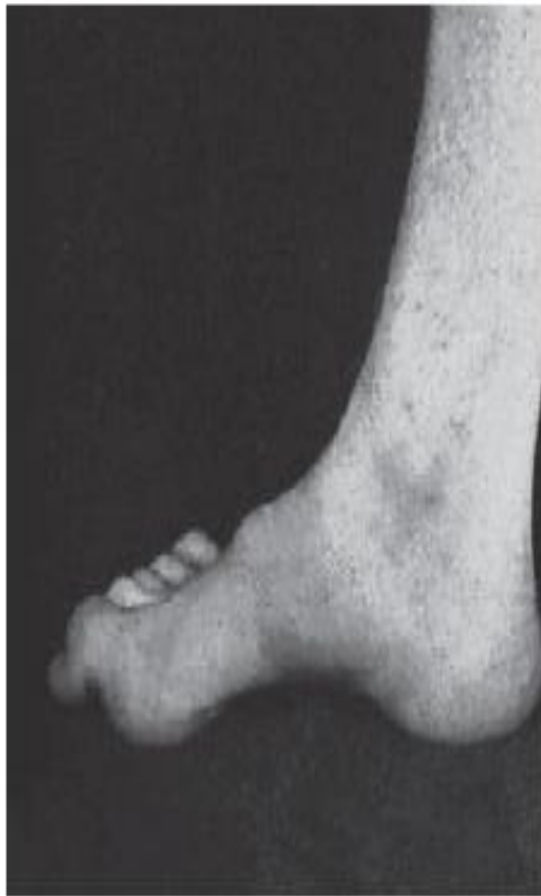

(a)

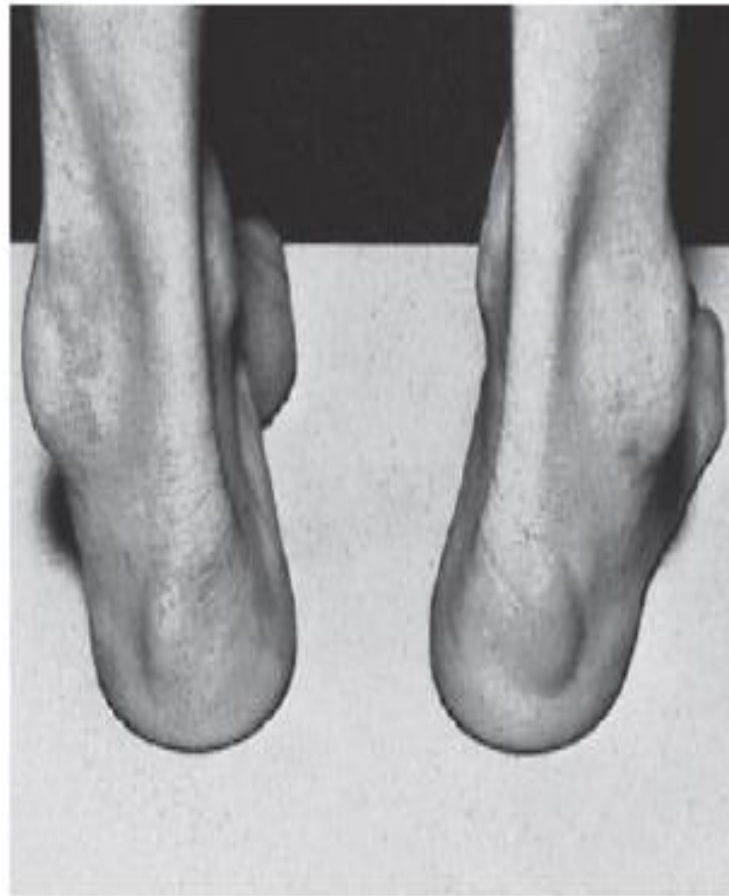


(b)

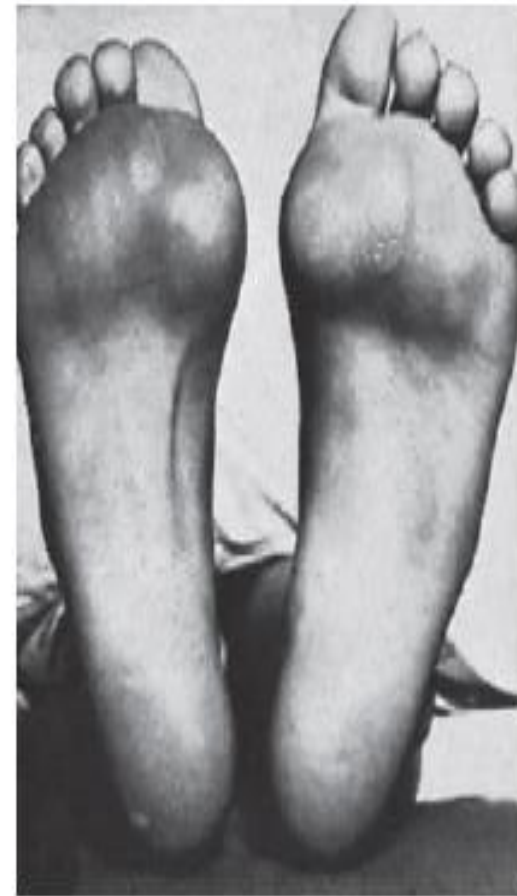**21.12 Mobile flat feet** (a) Standing with the feet flat on the floor, the medial arches appear to have dropped and the heels are in valgus. (b) When the patient goes up on his toes, the medial arches are restored, indicating that these are 'mobile' flat feet. If this does not occur, look carefully for a tarsal coalition.



(a)



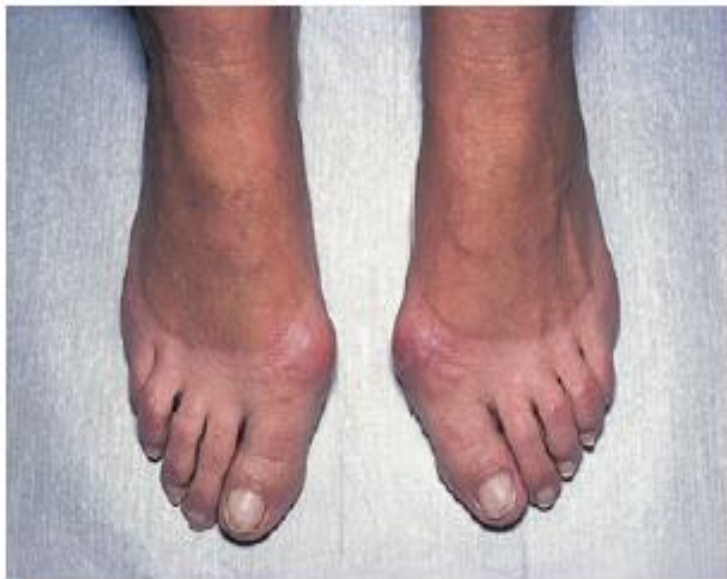(b)



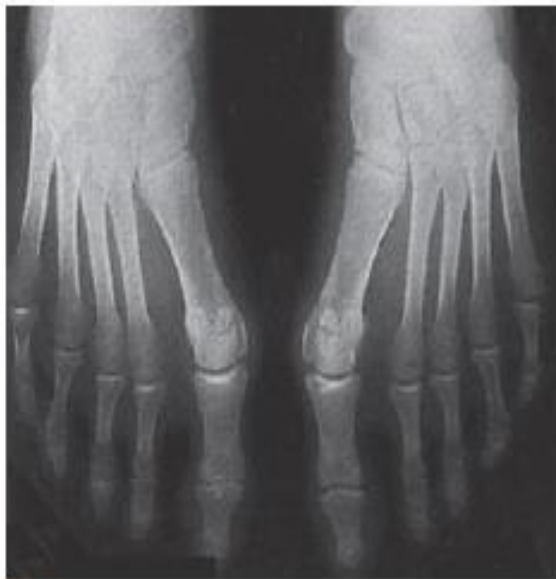(c)

**21.16 Pes cavus and claw-toes** (a) Typical appearance of 'idiopathic' pes cavus. Note the high arch and claw-toes. (b) This is associated with varus heels. (c) Look for callosities under the metatarsal heads.

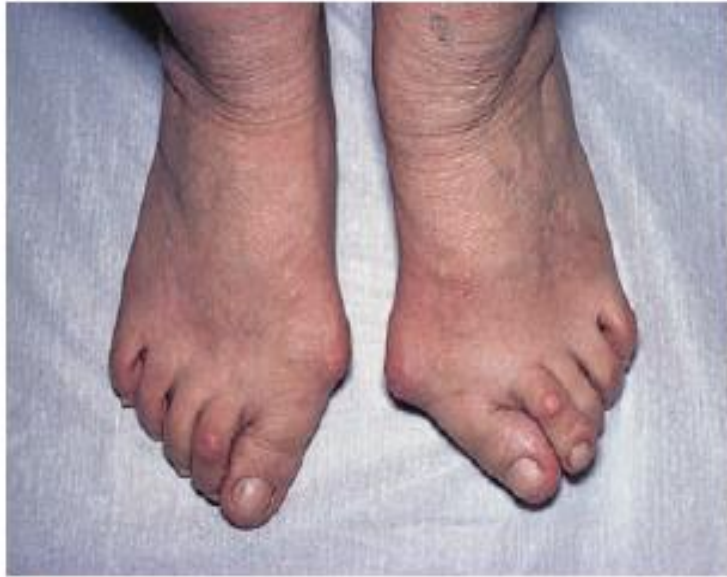



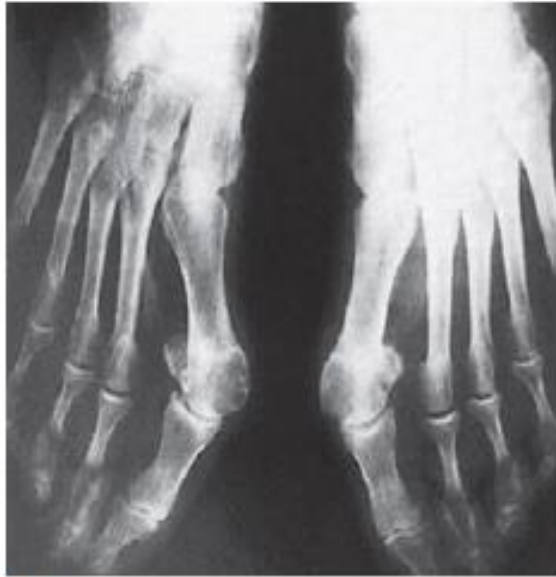(a)



(b)



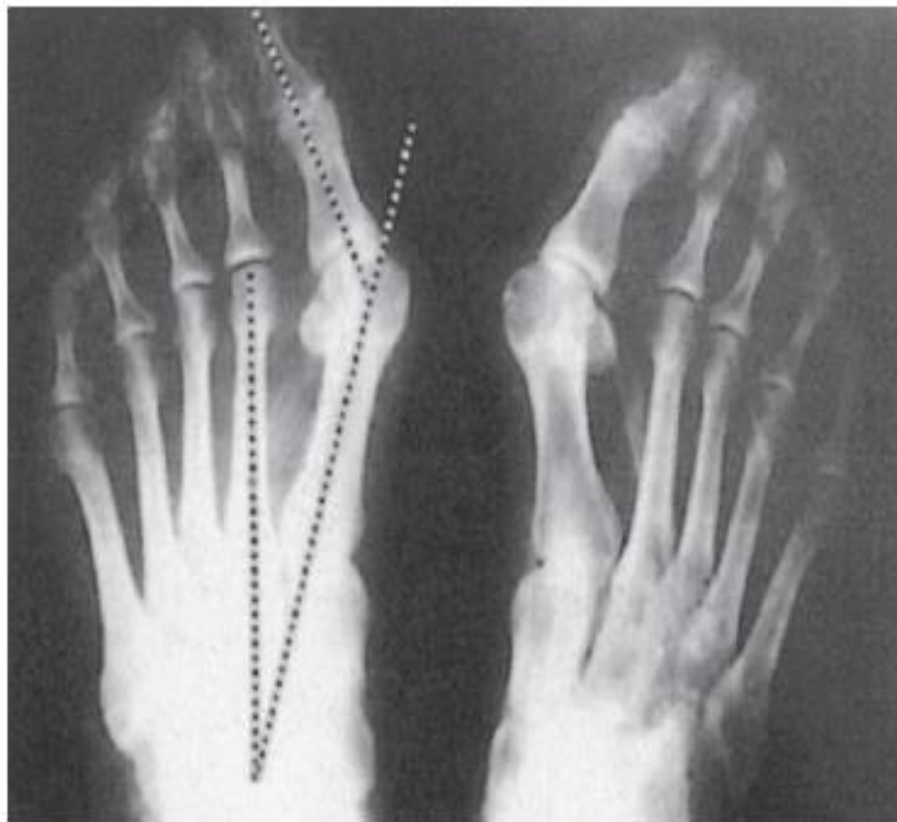
(c)



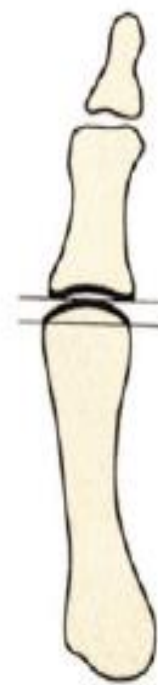
(d)

**21.22 Hallux valgus (a,b)** This girl's feet are well on the way to becoming as deformed as those of her mother (c,d). Hallux valgus is not uncommonly familial. X-rays should be taken with the patient standing to show the true metatarsal and digital angulation.

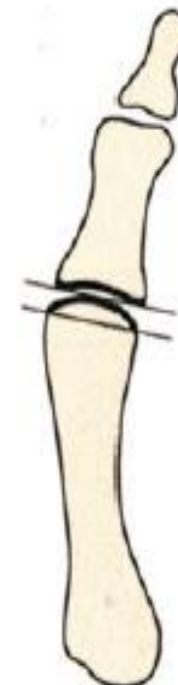



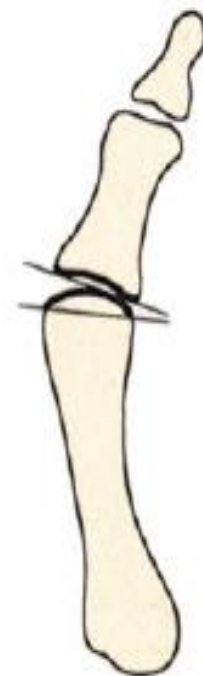(a)



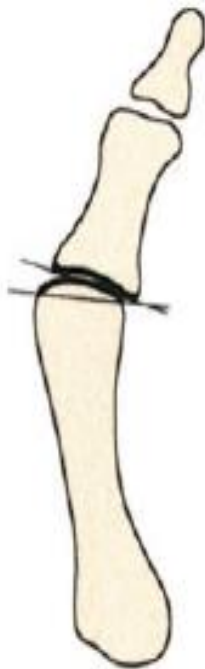(b)



(c)

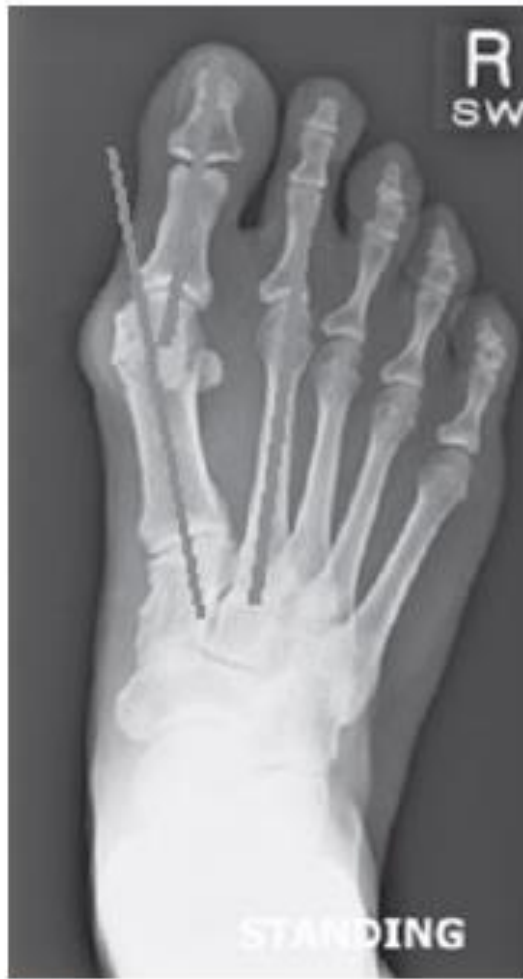

(d)

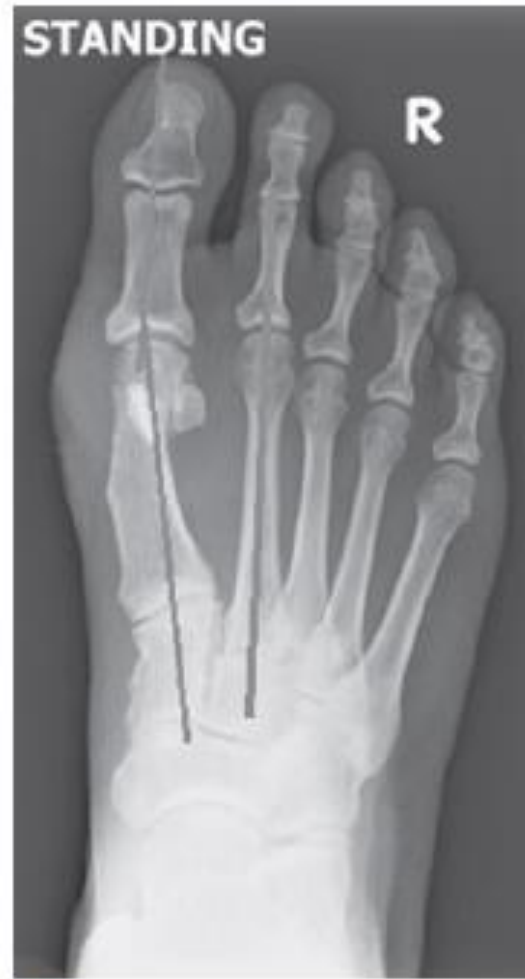

(e)

**21.23 X-rays** (a) The intermetatarsal angle (between the first and second metatarsals) as well as the metatarsophalangeal angle of the hallux are recorded. Piggott (1960) defined three types of hallux valgus, based on the position and tilt of the first MTP articular surfaces: In *normal feet* (b) the articular surfaces are parallel and centred upon each other. In *congruent hallux valgus* (c) the lines across the articular surfaces are still parallel and the joint is centred, but the articular surfaces are set more obliquely to the long axes of their respective bones. In (d) the *deviated type of hallux valgus*, the lines are not parallel and the articular surfaces are not congruent. In the *subluxated type* (e) the surfaces are neither parallel nor centred.

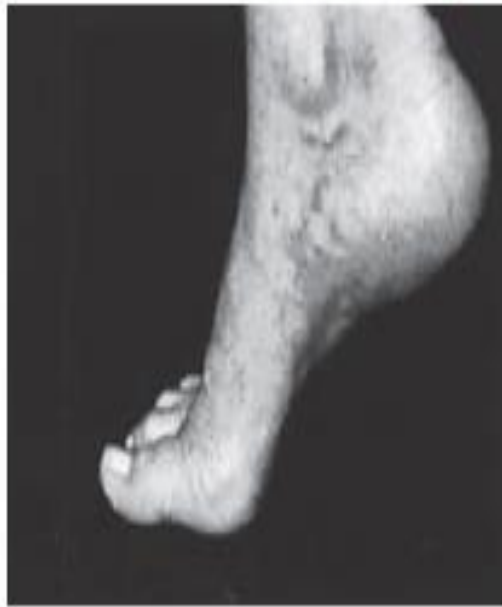

(a)

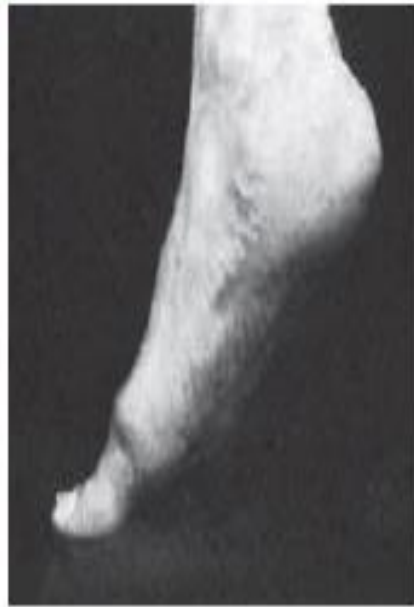

(b)

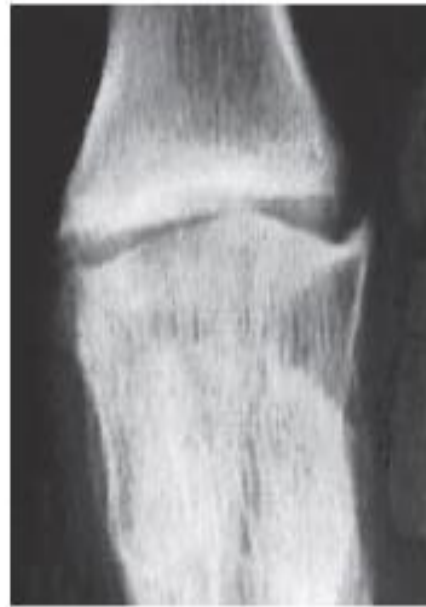**21.25 Hallux valgus – treatment** (a) X-ray before operation. (b) X-ray after distal osteotomy.



(a)

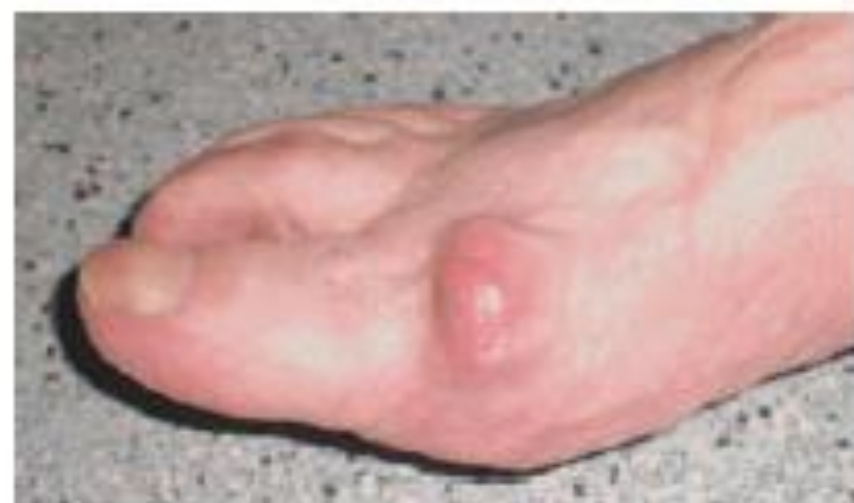

(b)

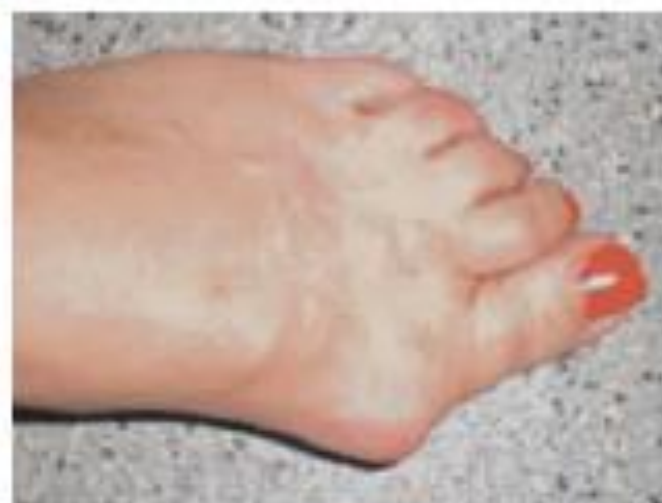

(c)

**21.26 Hallux rigidus** (a) In normal walking, the big toe dorsiflexes (extends) considerably. With rigidus (b), dorsiflexion is limited. (c) The usual cause is OA of the first MTP joint.



(a)

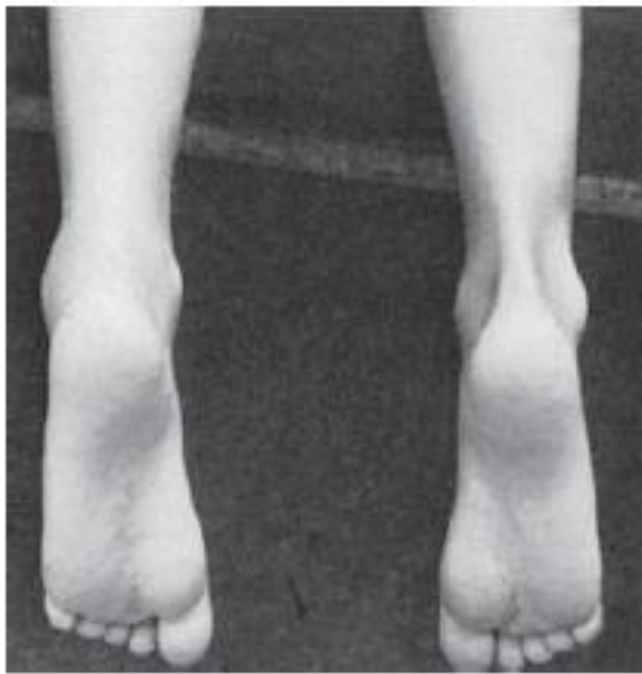

(b)

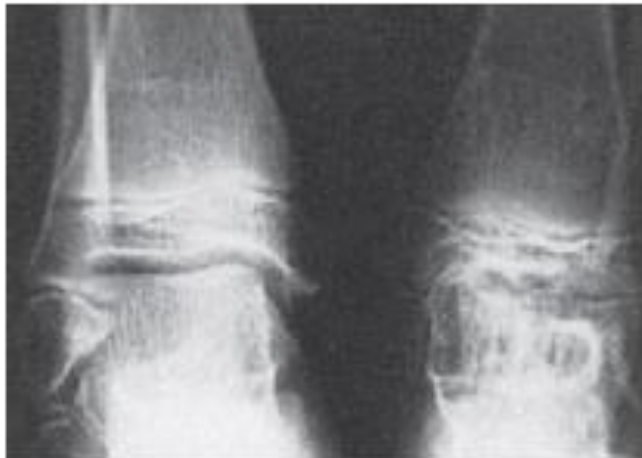**21.27 'Bunions'** Compare the two types of bunion:  
(a) Dorsal bunion in hallux rigidus and (b) medial bunion in hallux valgus.

### 21.29 Tuberculous arthritis of the ankle

(a) The swelling of the left ankle is best seen from behind; (b) shows regional osteoporosis and joint destruction.



(a)

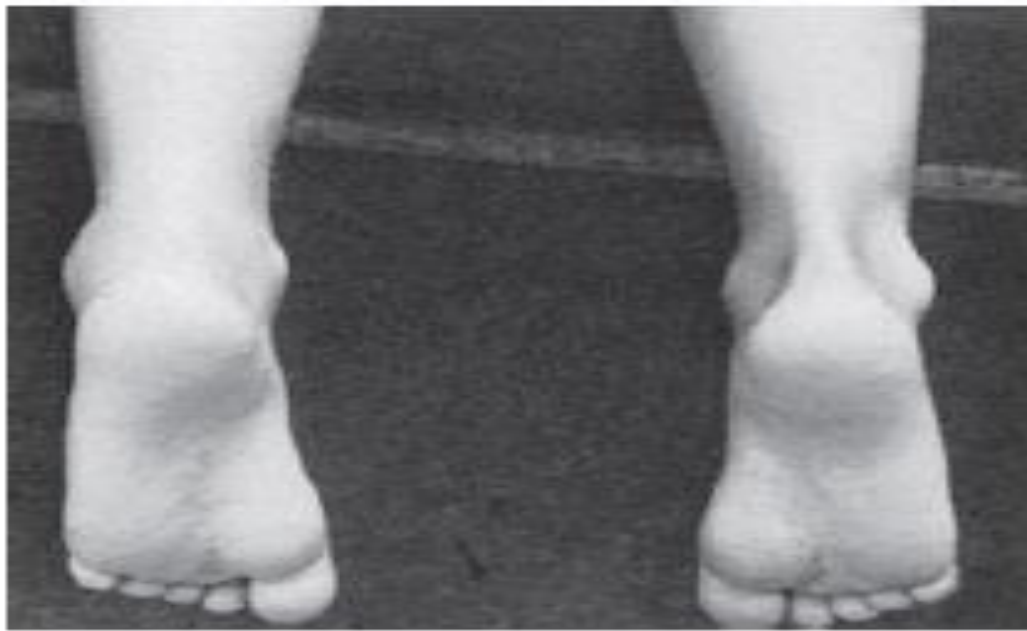

(b)

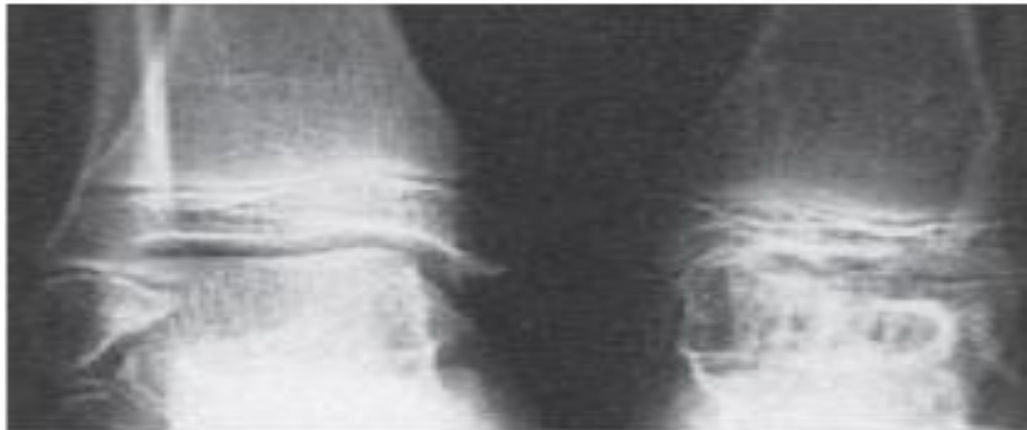

### 21.29 Tuberculous arthritis of the ankle

(a) The swelling of the left ankle is best seen from behind; (b) shows regional osteoporosis and joint destruction.



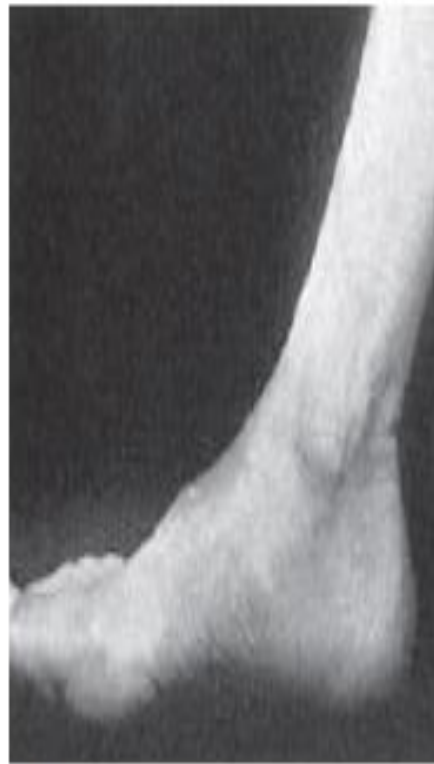(a)



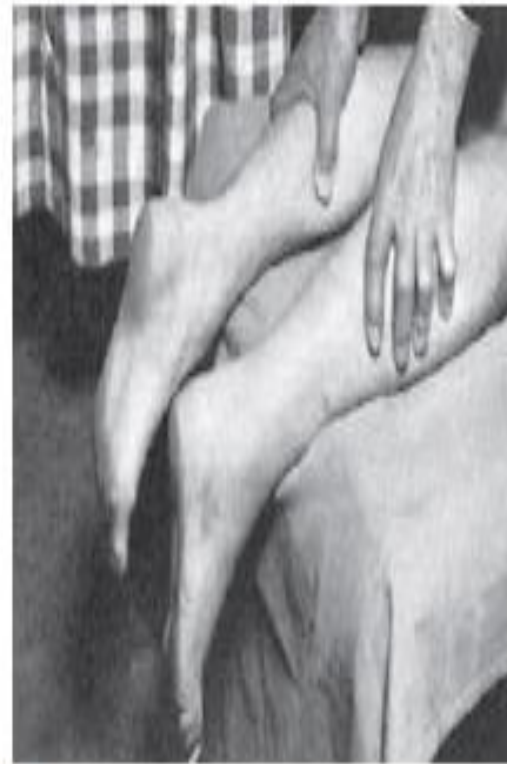(b)



(a)

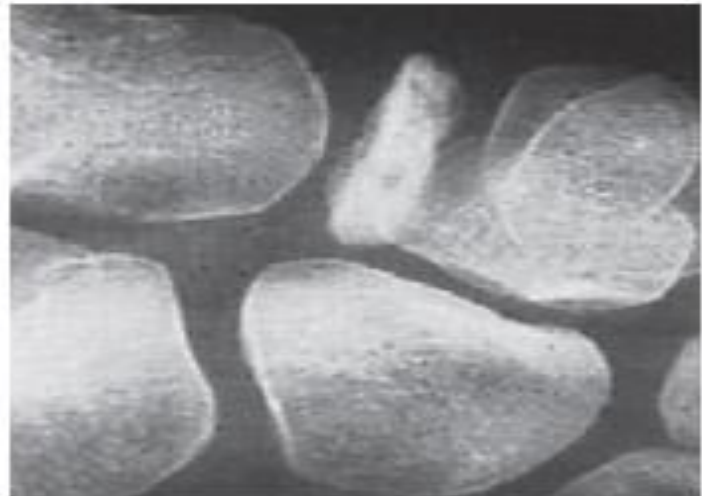


(b)

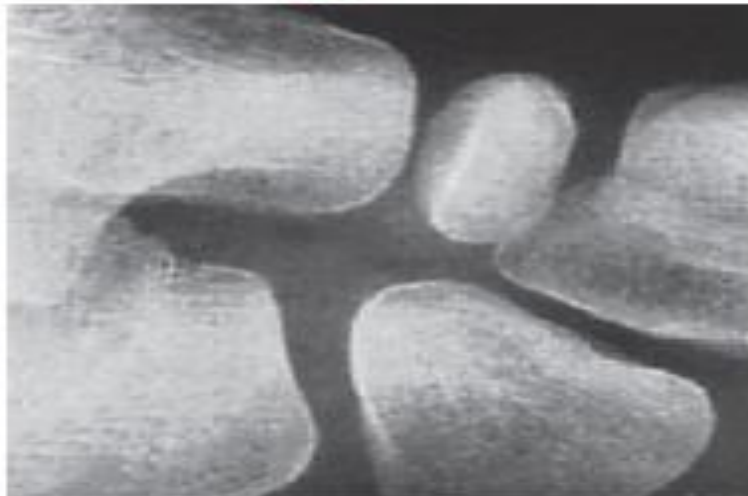


(c)

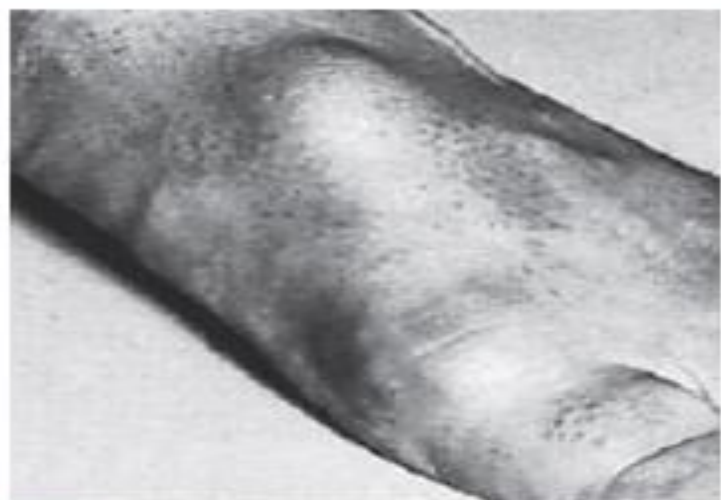**21.36 Tendo Achillis** (a) The soleus may tear at its musculotendinous junction (1), but the tendo Achillis itself ruptures about 5 cm above its insertion (2). (b) The depression seen in this picture at the site of rupture later fills with blood. (c) Simmonds' test: both calves are being squeezed but only the left foot plantarflexes – the right tendon is ruptured.



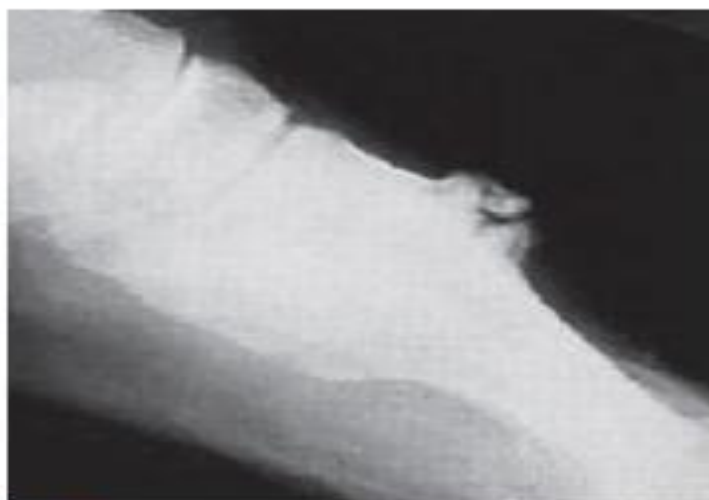
(a)



(b)

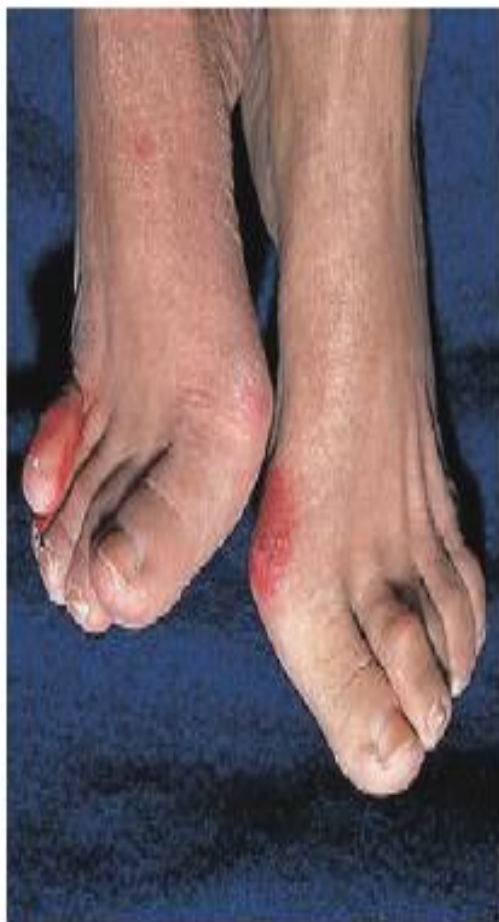

(c)

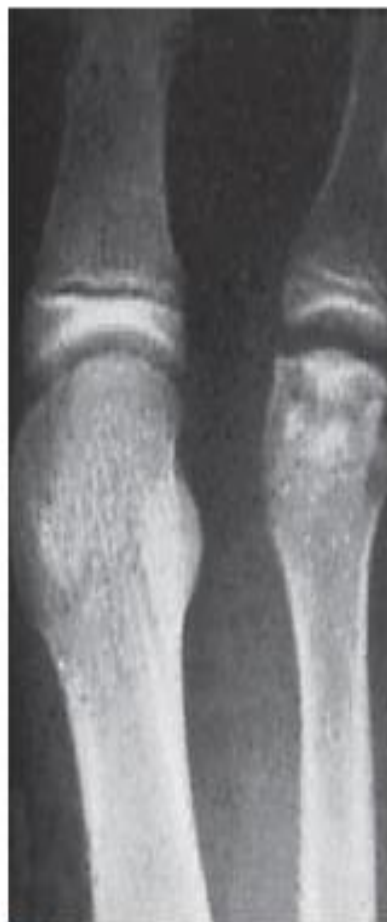

(d)

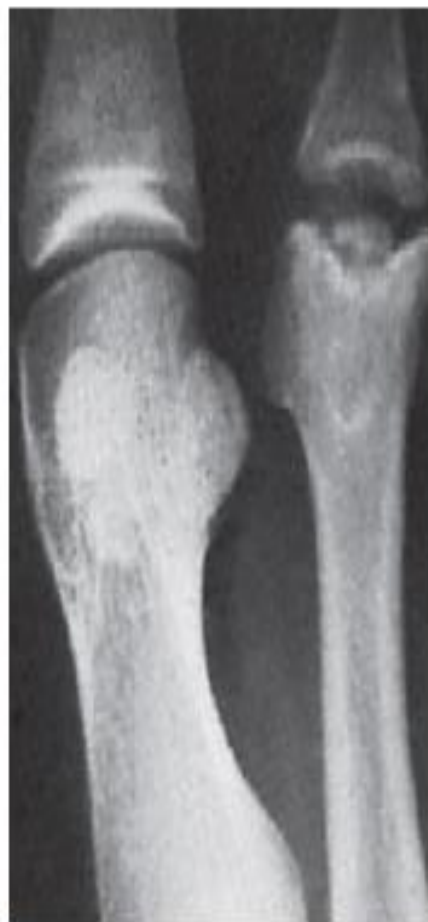**21.39 Pain over the midfoot** (a) Köhler's disease compared with (b) the normal foot. (c,d) The bump on the dorsum of the foot due to OA of the first cuneiform-metatarsal joint



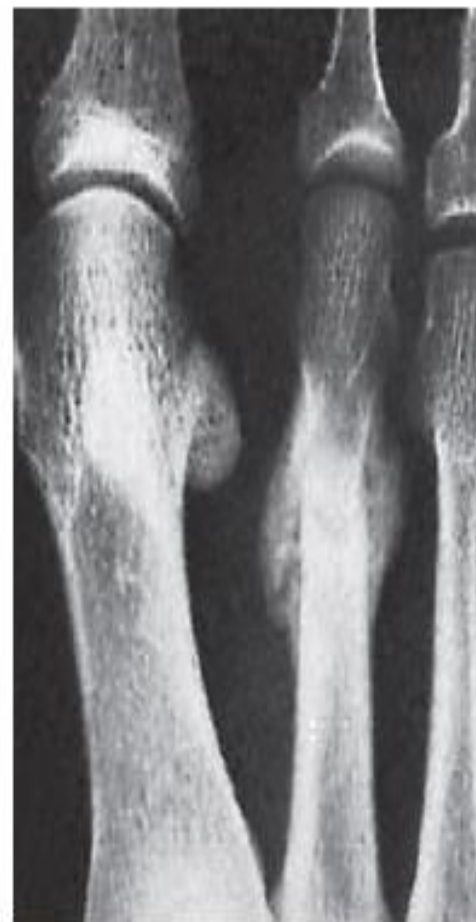(a)



(b)



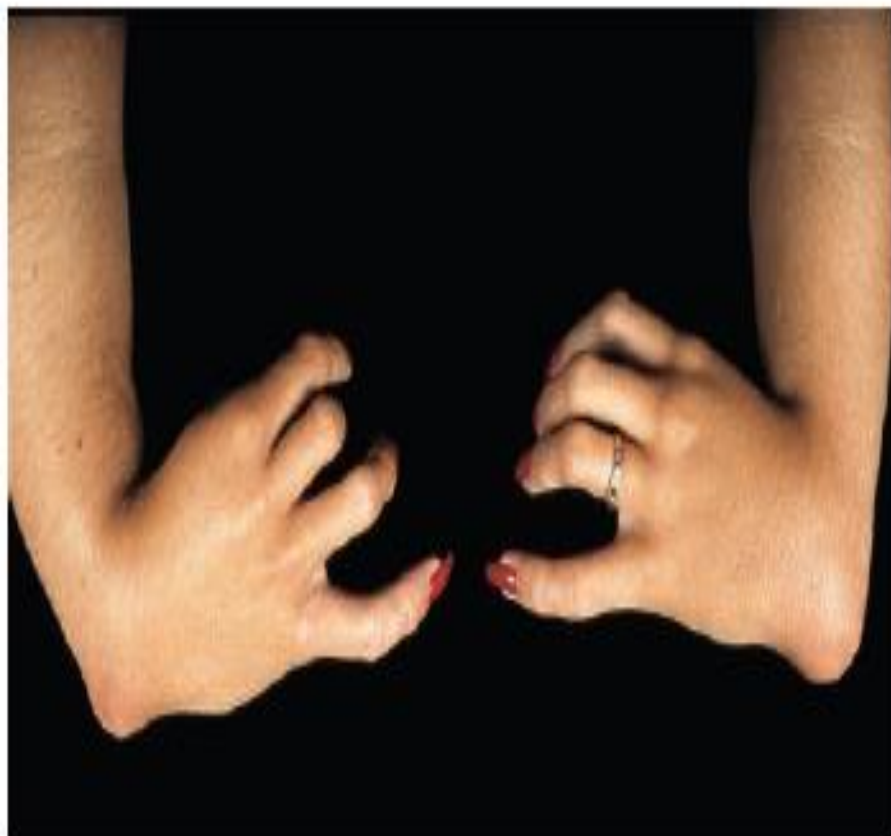(c)



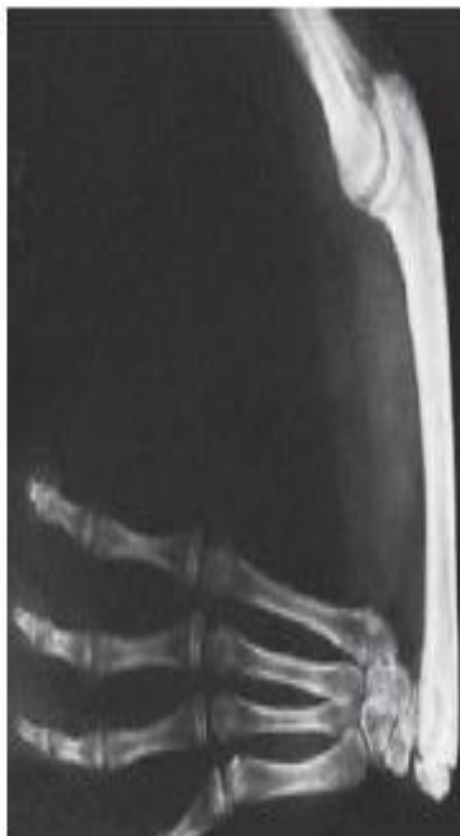(d)

**21.40 Pain in the forefoot** (a) Long-standing deformities such as dropped anterior arches, hallux valgus, hammer-toe, curly toes and overlapping toes (all of which are present in this patient) can cause metatarsalgia. Localized pain and tenderness suggest a more specific cause. (b,c) Stages in the development of Freiberg's disease. (d) Periosteal new-bone formation along the shaft of the second metatarsal, the classic sign of a healing stress fracture.





(a)



(b)

**8.28 Radial dysplasia**  
(a) Bilateral. (b) X-ray showing that the entire radius is absent.