





# **Dermatology HU Past Papers**



**Pulse Batch**



# Dermatology mini-OSCE

**Group A5&A6**



# Q1: Define/Answer the following :

- 1) **Write the name of the cell with the following function:**
  1. Vit. D synthesis → *Keratinocytes*
  2. Melanin production → *melanocyte*
  3. Immunity → *Langerhans cells*
- 2) **Define Bulla** = A raised, circumscribed lesion greater than 0.5 cm that contains serous fluid.
- 3) **List 3 complications of Psoriasis?**
  1. Arthritis    2. Metabolic syndrome    3. IHD
- 4) **4 types of rosacea :**
  1. Ocular    2. Phymatous    3. Papulo-pustular
  4. Erythematotelangiectatic
- 5) **List 2 diseases that cause hypopigmentation?**
  1. Vitiligo    2. Albinism



# Q2 : Male patient with hair loss from all over the body

## 1. What's the diagnosis ?

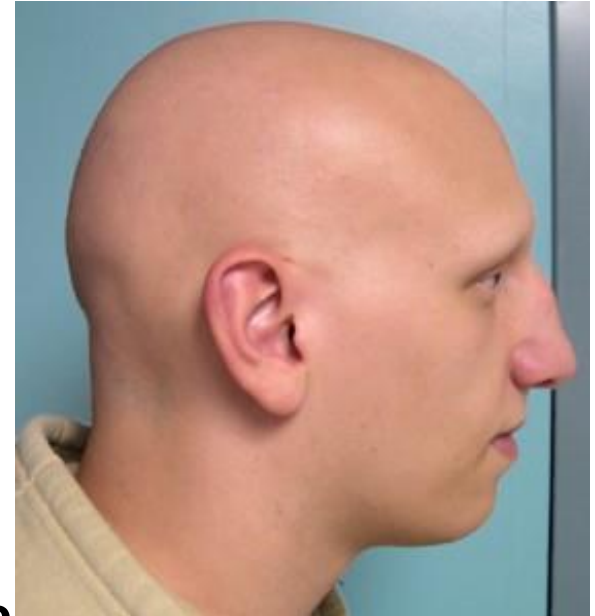**Alopecia universalis**

## 2. Findings on histology ?

**lymphocytes around and in the hair matrix**

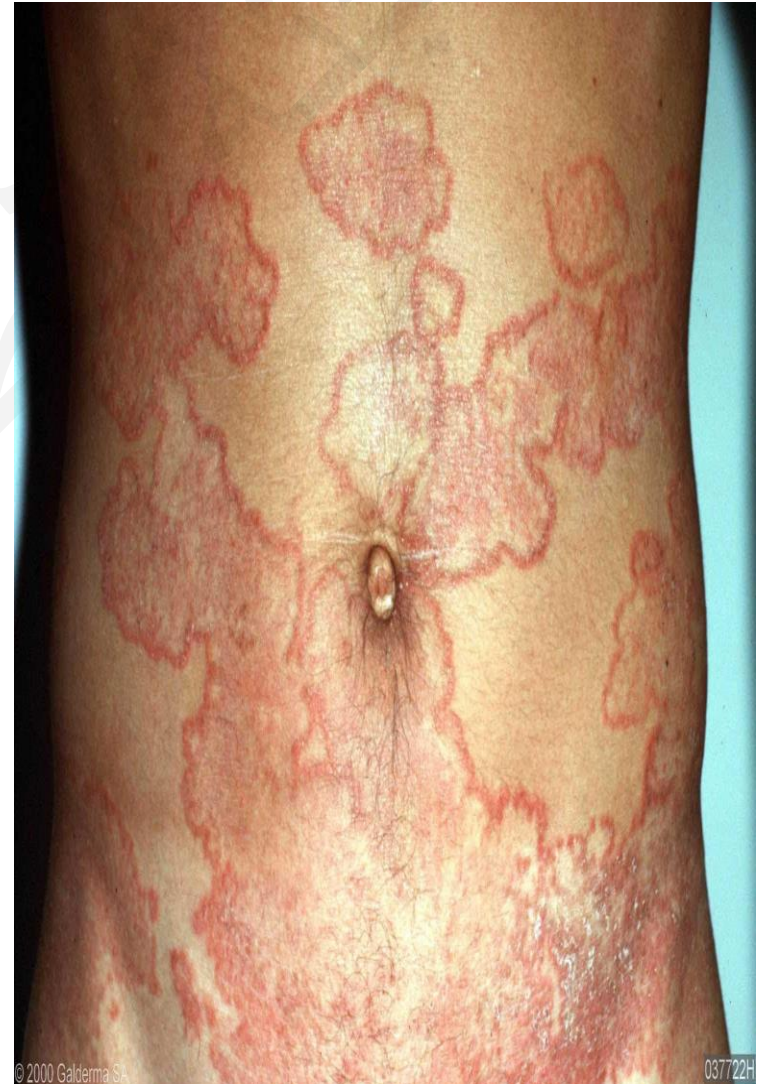## 3. List 2 treatments?

- **Topical corticosteroid**
- **Topical immunotherapy (squaric acid dibutylester (SADBE) and diphencyprone (DPCP))**



# Q3 : Itchy annular lesion on the body

- 1) What's the Diagnosis ?  
Tinea corporis
- 2) What investigations you would want to order?  
skin scraping + koh
- 3) What's your treatment?
  - systemic Terbinafine
  - topical imidazole



# Q4:

## 1. What's the diagnosis?

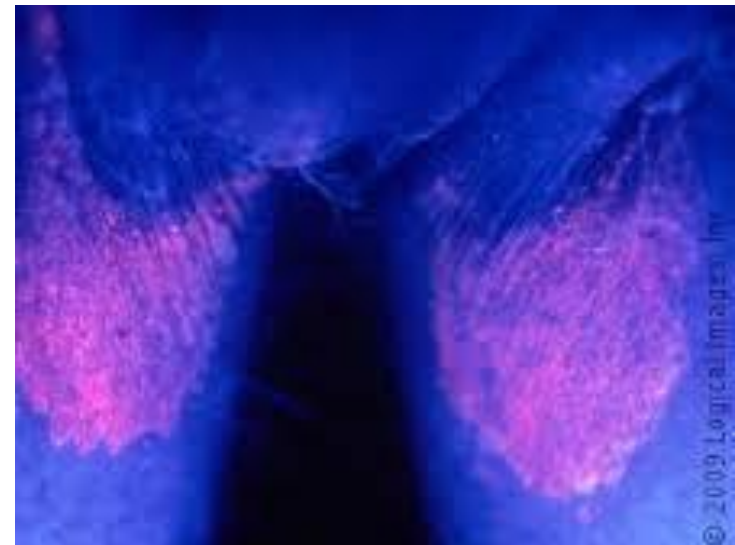
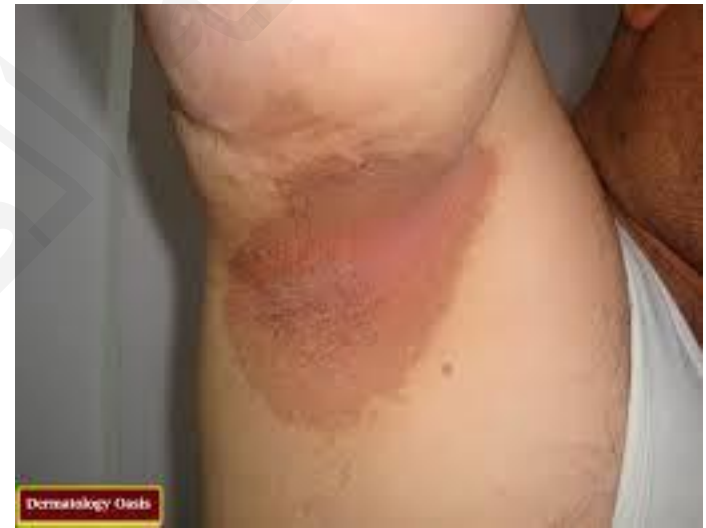Erythrasma

## 2. Name the color on wood's light and the cause?

- coral pink with Wood's light
- porphyrins

## 3. Whats the causative organism?

Diphtheroid

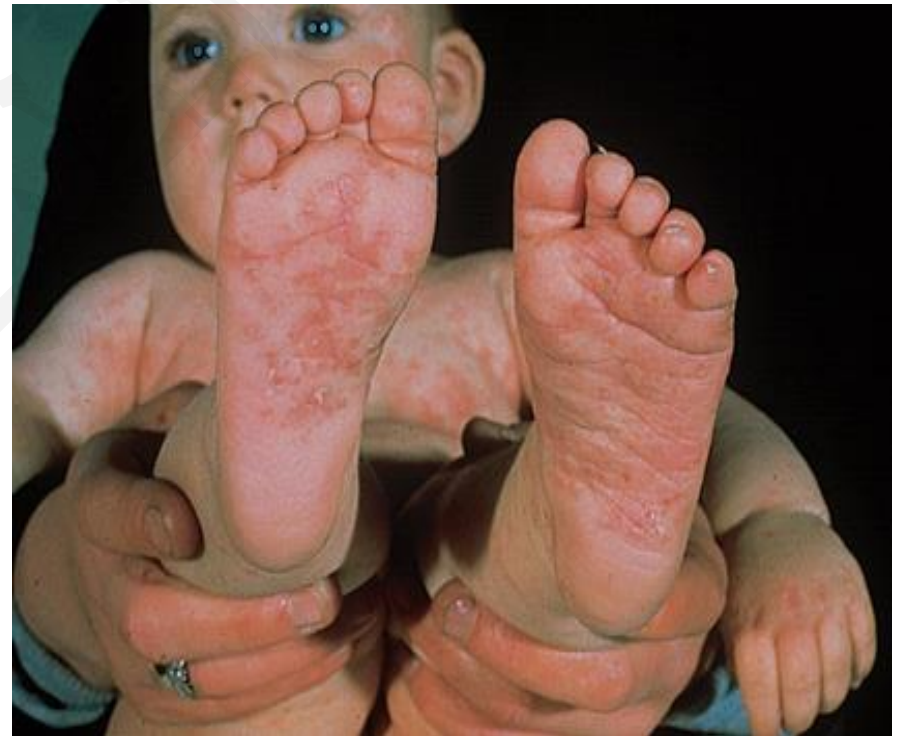

# Q5 : This child came with itch and all of his family members are itchy

**1. Whats the Diagnosis ?**  
Scabies

**2. List 2 treatments?**

- Permethrin
- Malathion





# Q6 : 30 years old itchy

## 1. Describe the lesion?

- Plaque
- ill demarcated
- red in color
- scaly with excoriation
- no specific arrangement
- on the forearm

## 2. Diagnosis ?

atopic eczema (most probably)

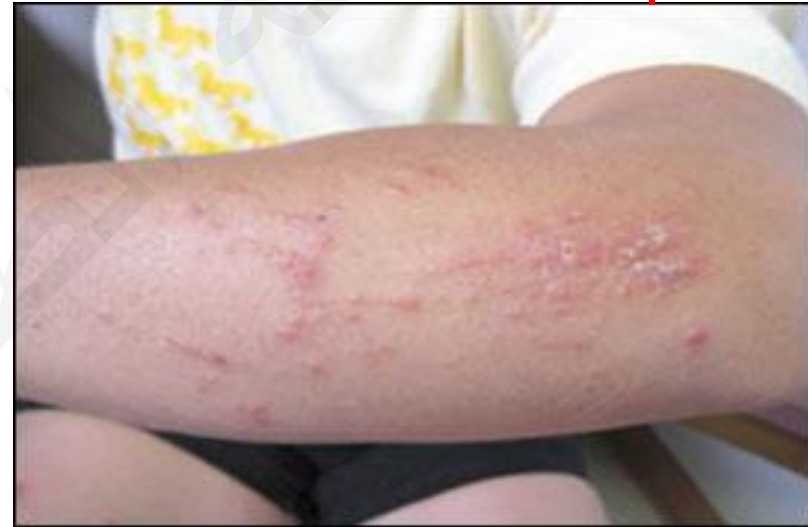## 3. List 3 complications?

- affect sleep/work in adult growth in children
- viral super infection eczema herpeticum
- bacterial superinfection

## 4. List 3 treatment?

- topical steroids
- Tacrolimus
- Ciclosporin

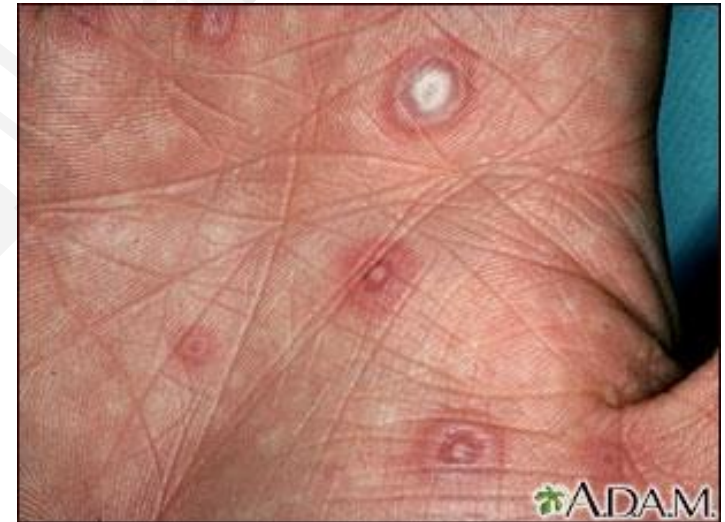Not the same pic!



# Q7: This pt has this rash on his both hands and face

## 1. Describe the lesion?

- annular patches
- red in color
- well demarcated
- not scaly
- (target lesion)
- no specific arrangement
- on the palmar aspect of the hand



## 2. Diagnosis ?

erythema multiforme

## 3. What's the cause of the facial rash?

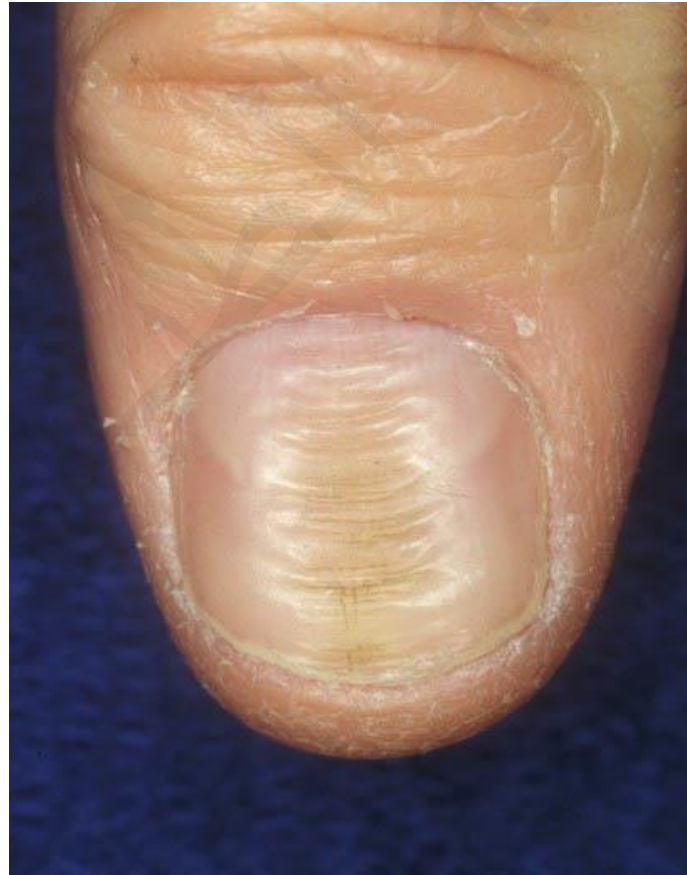Herpes simplex

## 4. What will you see on Diascopy?

Blanchable

## Q8 : Name this finding

- ▶ tic nail dystrophy






# **Pulse Question Team**

## **(Rand Bashir,Aws Amro &Jaafar khalid)**

# Dermatology mini-osce group

## A3+A4

18-4-2017



# Q1

- **1-define erythroderma & mention 1 medical condition it appears in.**

is a generalized redness of skin that may be scaling (exfoliative erythroderma) or smooth.

Seen in : psoriasis,eczema,cutaneous lymphoma,drug allergy.

**2-what is the most common cause of erythema multiforme?** Herpes simplex (in ~50% of cases)

- **3-mention 2 lines of t.t for melasma ?**
- 1- avoid exposure to sunlight and use suitable sun cream.
- 2-bleaching agents like hydroquinone.
  
- **4- what is spongiosis ? Give 1 example ?**
- Edema in the epidermis.
- Seen in acute eczema.
- **5- mention two places for seborrhieic eczema ?**
- Face,scalp,ears,eyebrows..
- Pre-sternal,inter-scapular.
- Intertriginous: groin,armpits.

- **Q2**

- **35 years old woman came to your clinic complaining of hotness in her for 2 years increased in the summer.**

**1-what is your most likely diagnosis ?**

Rosacea

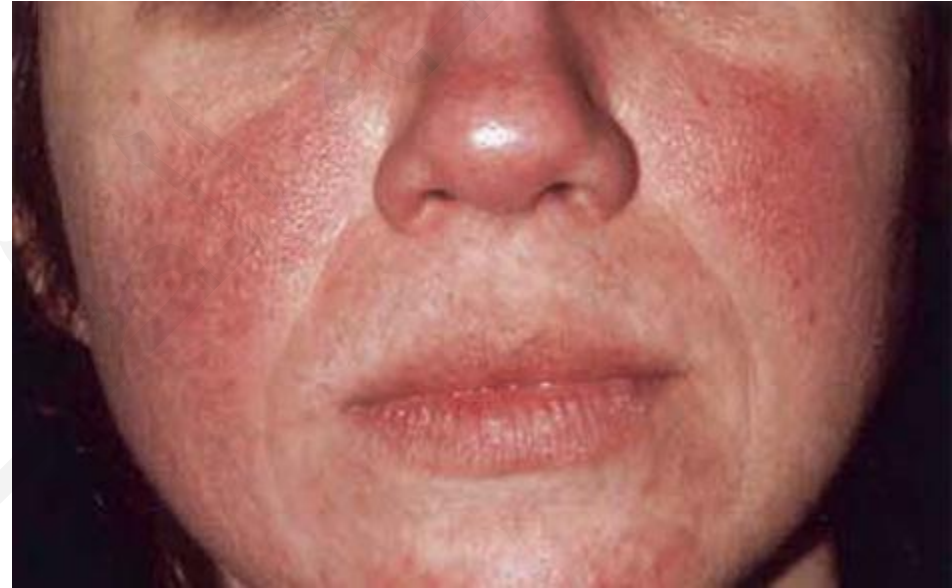**2-mention 1 differential diagnosis ?**

Acne/sunlight photosensitivity

**3-mention 2 systemic treatments.**

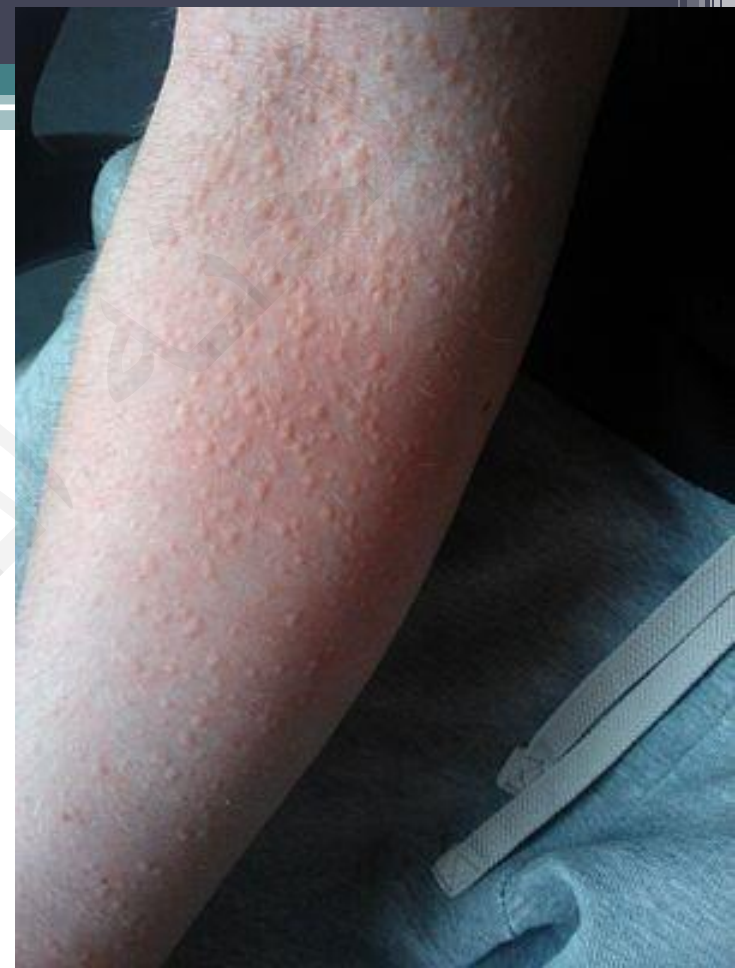1- systemic Abs (tetracyclin) – papulopustular

2- stubborn cases : systemic retinoid (isotretinoin)



# Q3

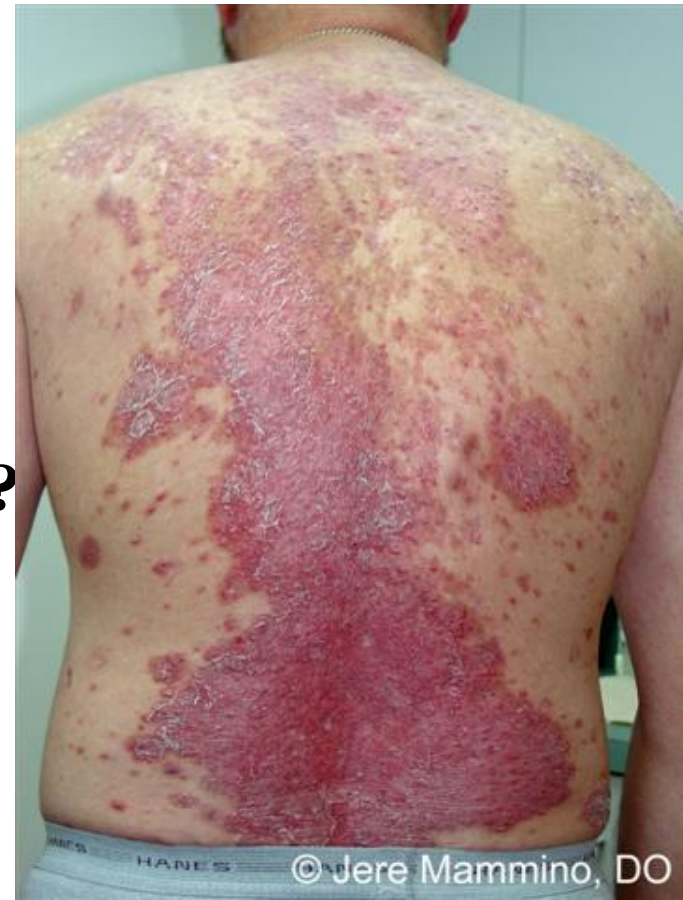- 24 years old male came to your clinic complaining of this rash that appears with sweating and exercise.
- **1-what is your most likely diagnosis ?**
- Cholinergic urticaria(type of physical)
- **2- what is wheal ?**
- Elevated compressable white evanescent area produced by dermal edema,often surrounded by a red axon mediated flare .although usually less than 2 cm in diameter,it can be huge in size.
- **3-what is your first line of treatment ?**
- avoidance of heat, minimizing anxiety,..



# Q4

- A 45 years old male came to your clinic complaining of this mildly itching lesion ,appeared before 2 years .
- **1-describe the lesion ?**
- TSAD..(salmon pink,scaly,well defined plaque..no specific arrangement,distributed in lower back and buttock)
- **2-mention two other sites you can see this lesion in ?**
- Scalp,elbows,knees.
- **3- mention 2 nail signs you can see ?**
- 1- oil drop
- 2- pitting
- 3-subungual hyperkeratosis
- 4-onycholysis

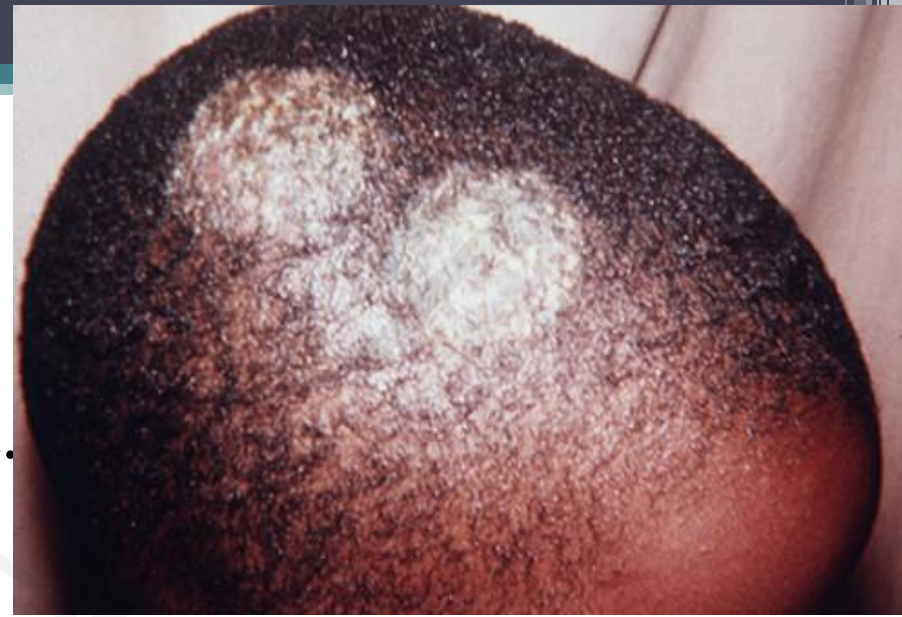The figure in exam was different from this, showing a big plaque in the lower back and buttock.





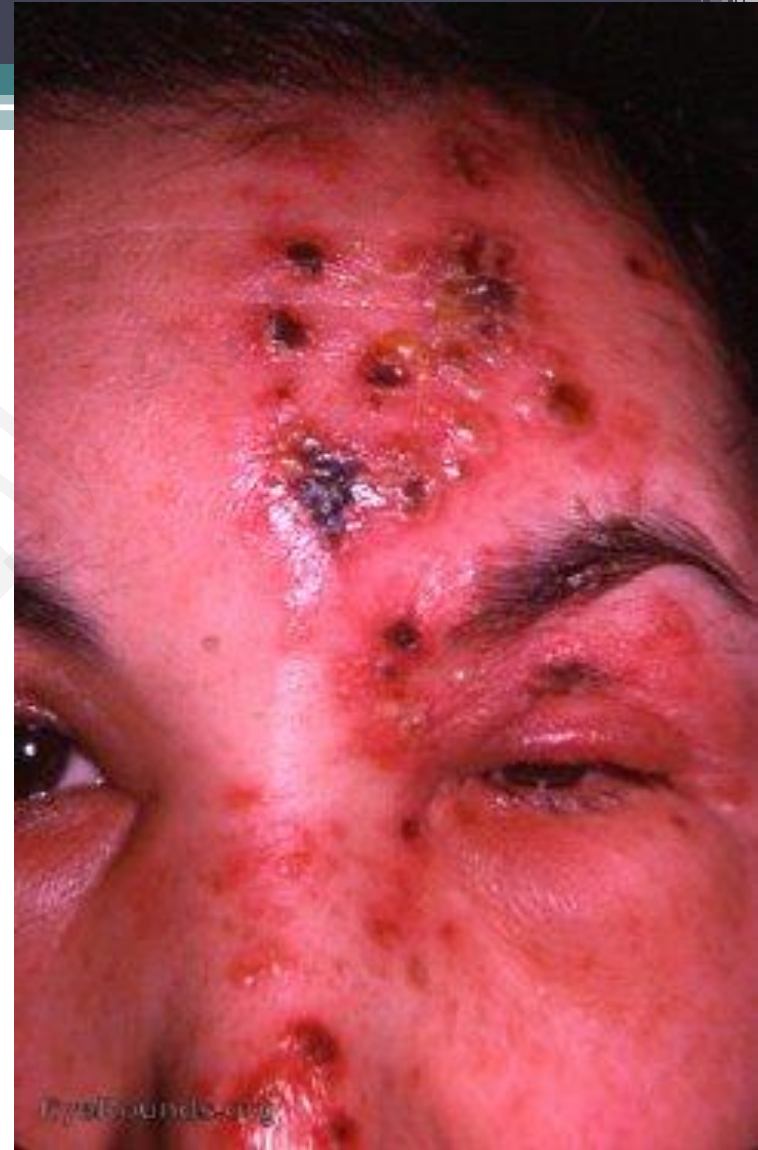# Q5

- This 6 years old boy came to you complaining from this, since 6 weeks. he has a dog at his house.
- **1-what is your diagnosis ?**
- Tinea capitis
- **2- mention 2 bed-side tests you would like to perform ?**
- 1- wood's light → green discoloration of the hair shaft.
- 2-hair plucking sample → KOH shows hyphae and spores.
- **3- what is your treatment ?**
- SYSTEMIC antifungal → griseofulvin
- Topical antifungal → miconazole



# Q6

- **1-what is your most likely diagnosis ?**
- Herpes zoster ophthalmicus
- **2-describe the lesion ?**
- Multiple vesicles ,with non scaly but crusted surfaces(yellow and blackish ),ill defined with erythematous base ,arranged in groups, distributed in the ophthalmic division(forehead,eye lid, tip of the nose "Hutchinson sign"
- **3-what is your first line in the treatment ?**
- Systemic treatment as early as possible (golden 5 days)→aciclovir ,famciclovir ,valaciclovir.
- If late : supportive treatment...



# Q7

- **This figure shows phototherapy Treatment unit.**

**Treatment unit.**


**Mention 4 indications for it's use ?**

- Psoriasis
- eczema
- vitiligo
- Lichen planus



# Pulse questions team-Esraa Damra



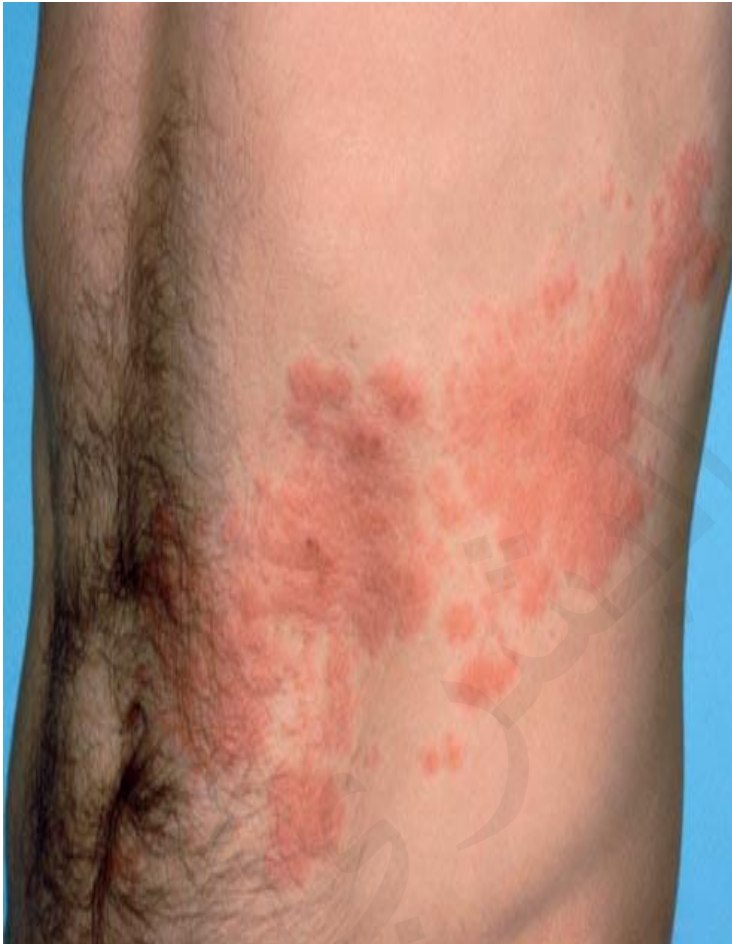

# **Dermatology mini-OSCE**

## **Group A7&A8**



# Question 1



1. Define plaques.
2. Mention 2 types of dendritic cells found in epidermis.
3. Mention the causative microorganism in shingles.

- Q1:

Plaque: small solid elevation of skin, less than 0.5 cm in diameter.

- Q2:

1. Melanocytes
2. Langerhans Cells

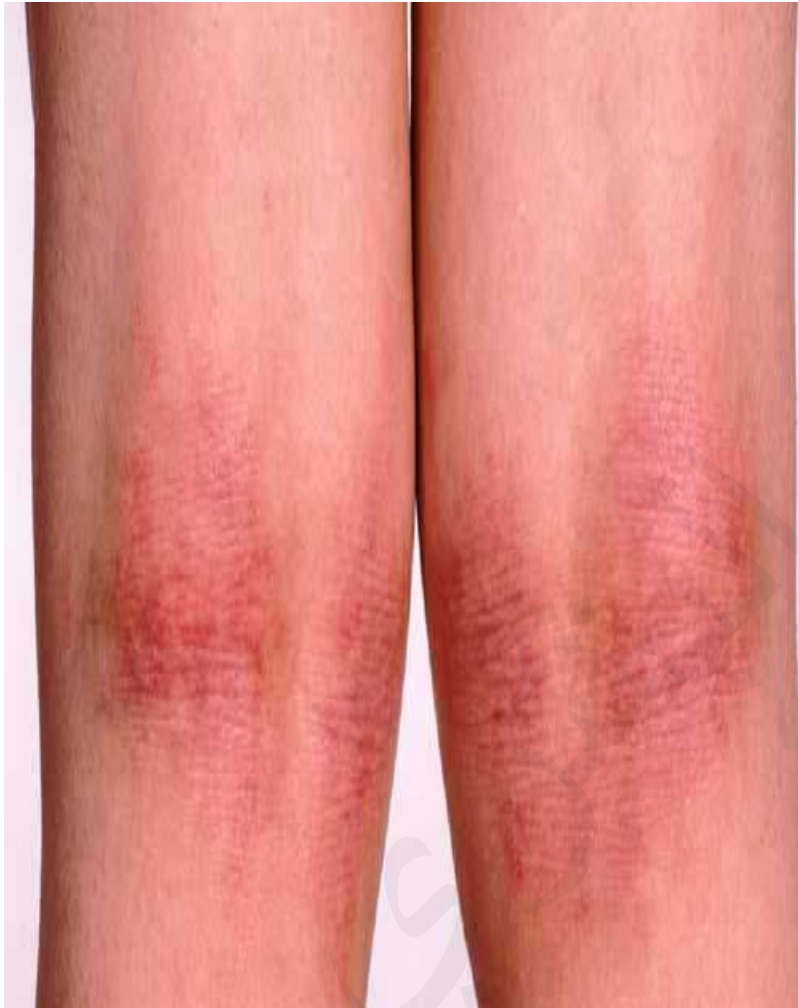- Q3:

Varicella Zoster virus.



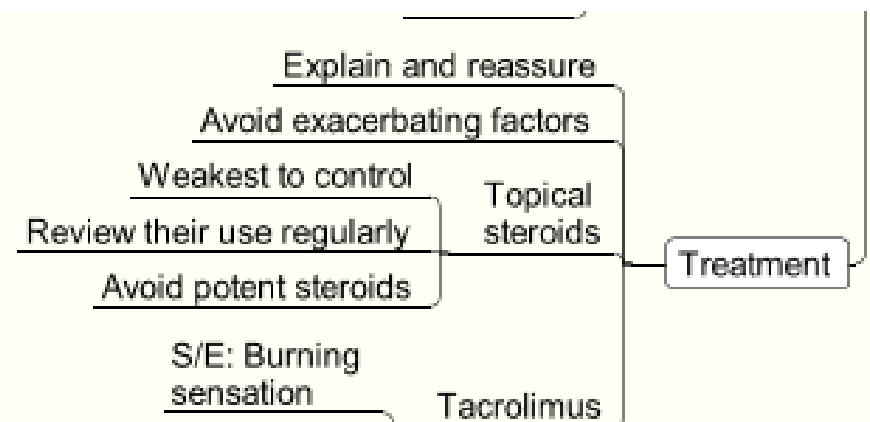
Pic of atopic eczema

## Question 2



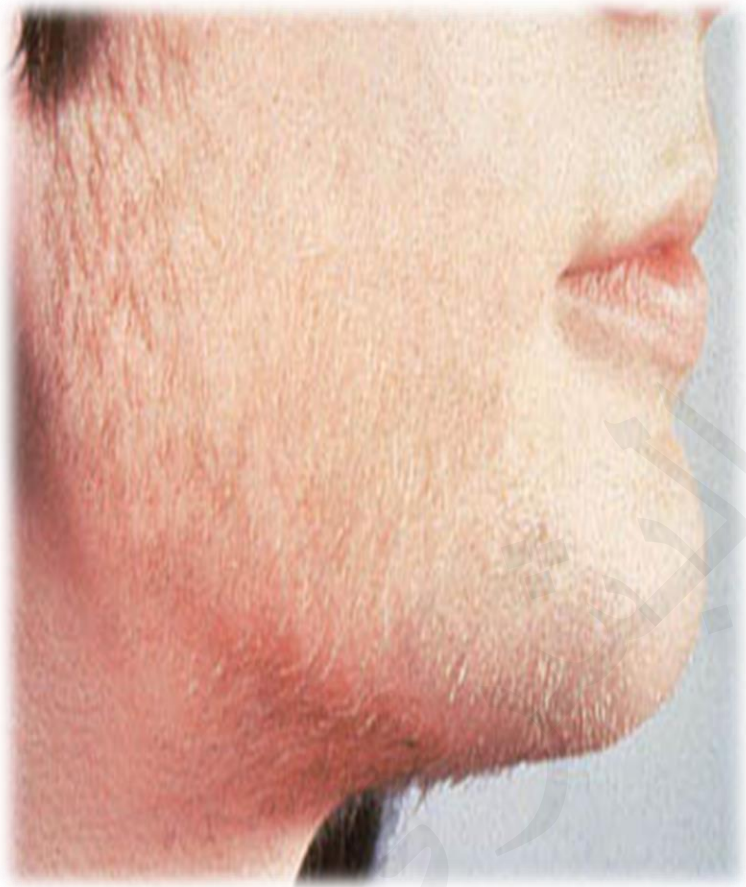1. Describe the lesion seen in the picture
2. Mention the complications of this condition
3. What is the treatment for it?

- Q1:
  1. Type: 1<sup>o</sup>; Plaque. 2<sup>o</sup>; Lichenification.
  2. Shape: Ill defines, red, dry, scaly.
  3. Arrangement: grouped?
  4. Distribution: extensor surface of bilateral forearms.
- Q2:
  1. Bacterial superinfection.
  2. Viral superinfection.
  3. Disturb sleep.
  4. Poor growth.
- Q3:



Pic of PCOS

## Question 3



1. Mention other possible symptoms might be seen in this condition.
2. What are the blood tests you would order?
3. What is the treatment?

- Q1:

1. Acne.
2. Obesity.
3. Androgenetic alopecia.
4. Menstrual irregularities.

- Q2:

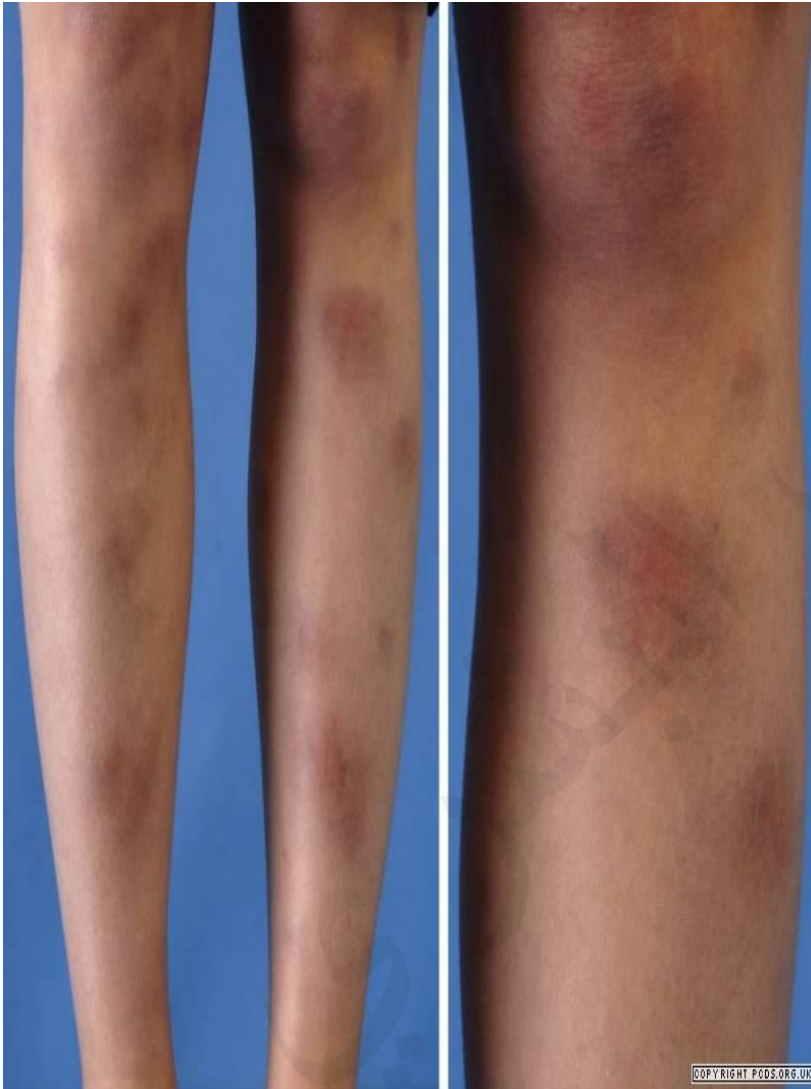
1. Testosterone
2. sex hormone-binding globulin,
3. dehydroepiandrosterone sulphate
4. Androstenedione
5. prolactin.

- Q3:

1. Decrease weight and exercise.
2. Treatment of underlying cause if present.
3. Hair removal physically + plucking should be avoided.
4. Drugs as Ethinylestradiol & Cyproterone acetate or Spironolactone (antiandrogen).
5. Topical therapy with eflornithine
6. Laser.
7. Electrolysis.

Pic of Erythema  
nodosum

# Question 4



1. Describe the lesions seen in the picture.
2. What is the treatment?

- Q1:

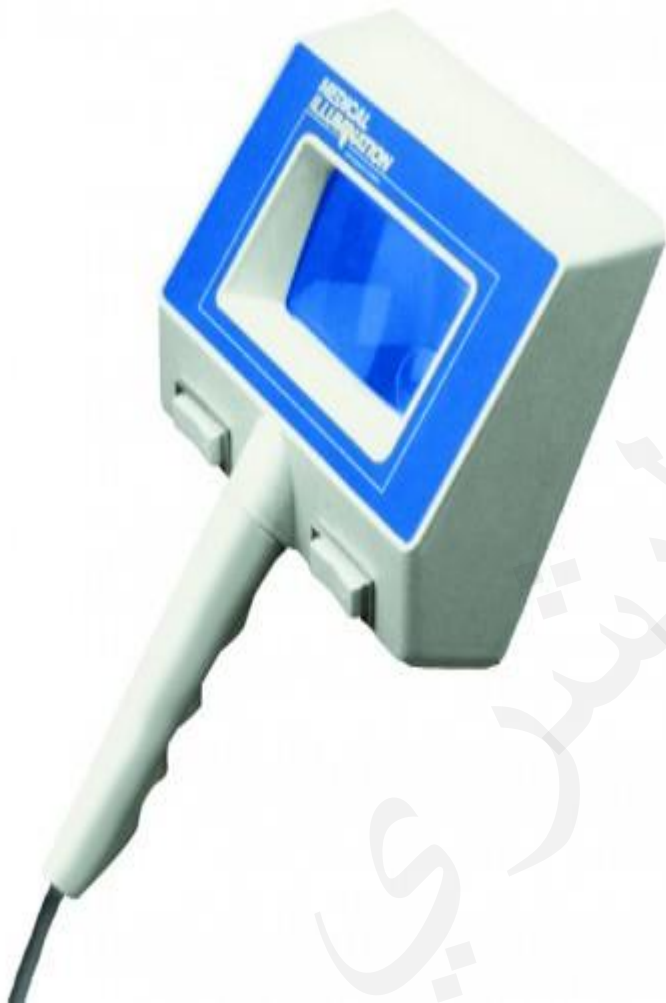1. Type: nodules
2. Shape: ill-defined, red, shiny, not scaly.
3. Arrangement: no specific arrangement.
4. Distribution: bilateral, over the lower limbs

- Q2:

1. Identify and eliminate the cause.
2. Bed rest and leg elevation.
3. NSAIDs,
4. ABx.

Pic of Wood's light

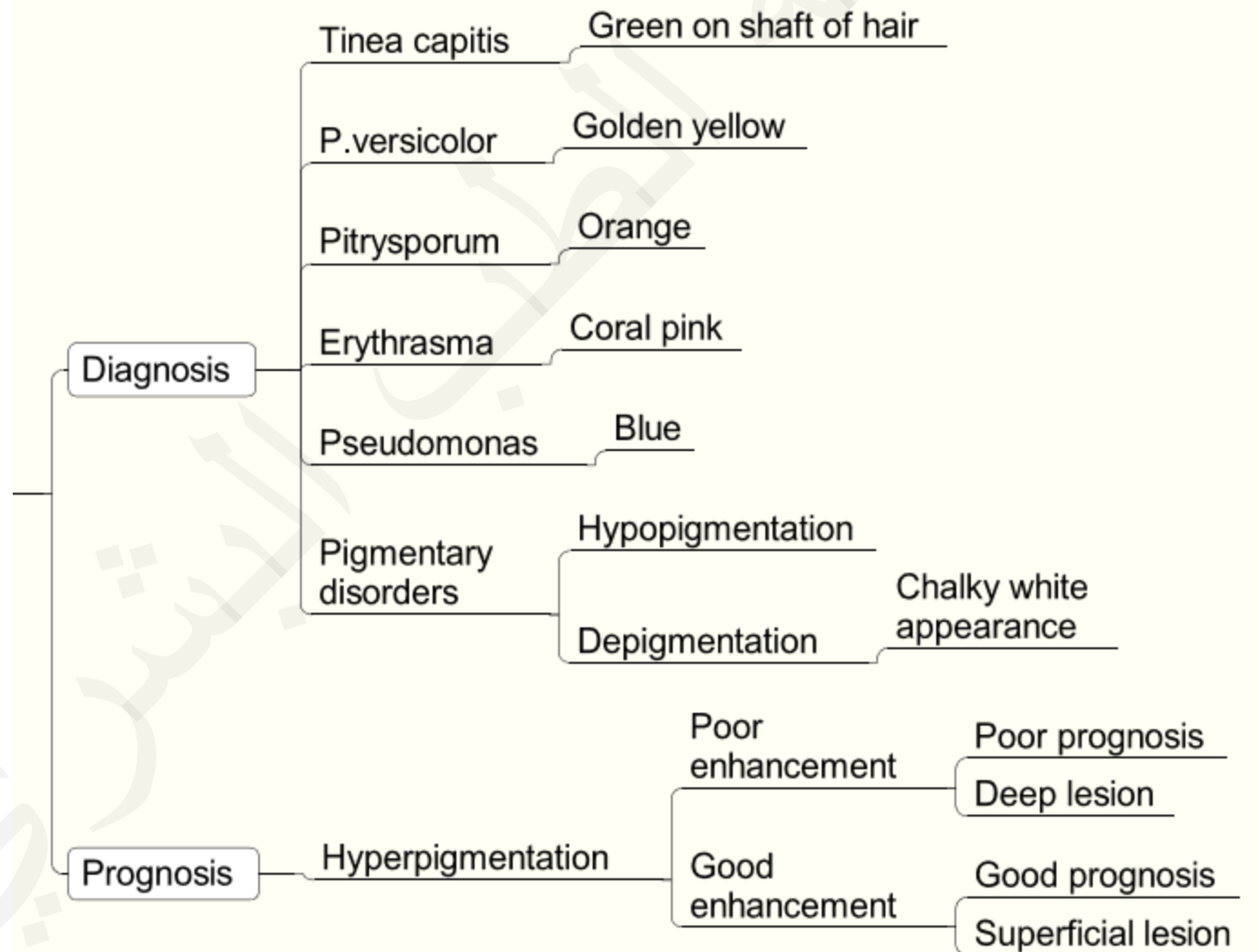
# Question 5



1. Mention the length of light used in this tool.
2. What are the indications for this type of bedside test?
3. What are the possible colors to be seen?

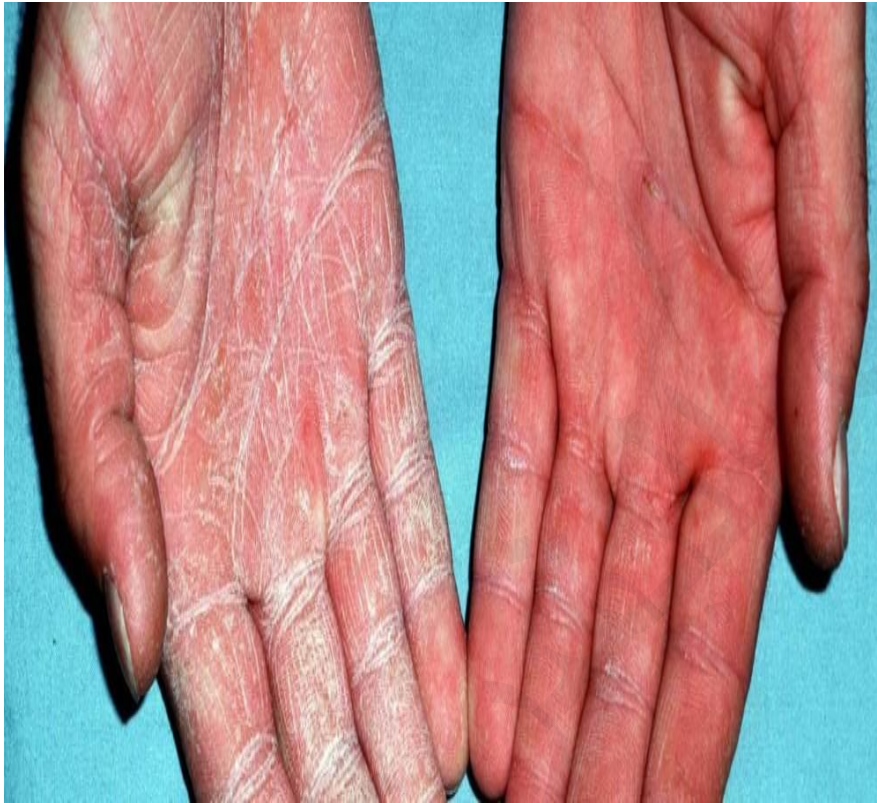

- Q1:  
365 nm.
- Q2+Q3:



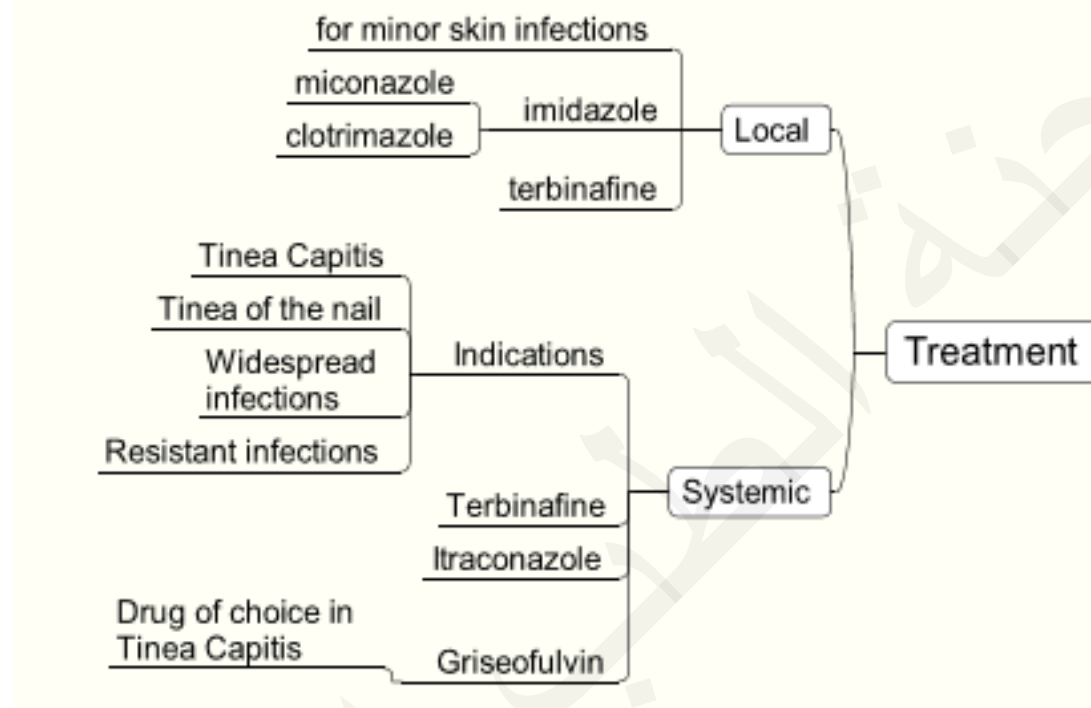
Pic of Tinea manuum

## Question 6



1. What is the treatment?
2. Mention some tests to be ordered.

- Q1:

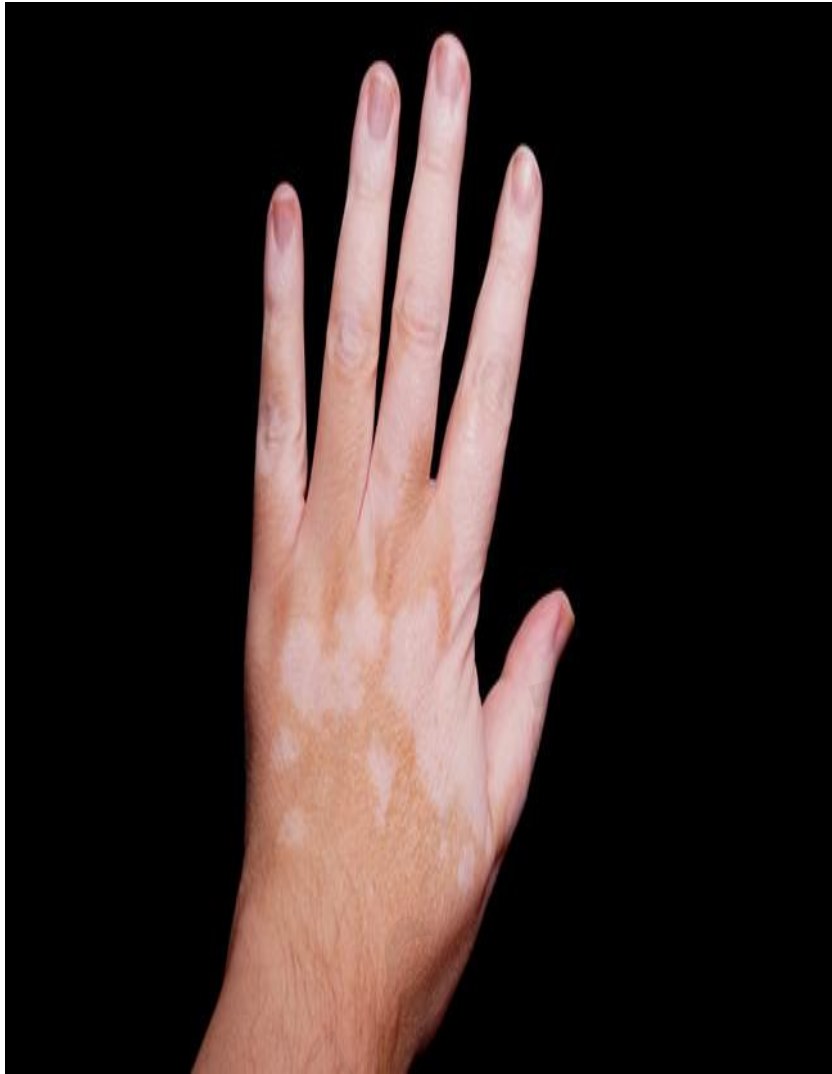

- Q2:

1. skin scraping + KOH.
2. Cultures.

Pic of Vitiligo

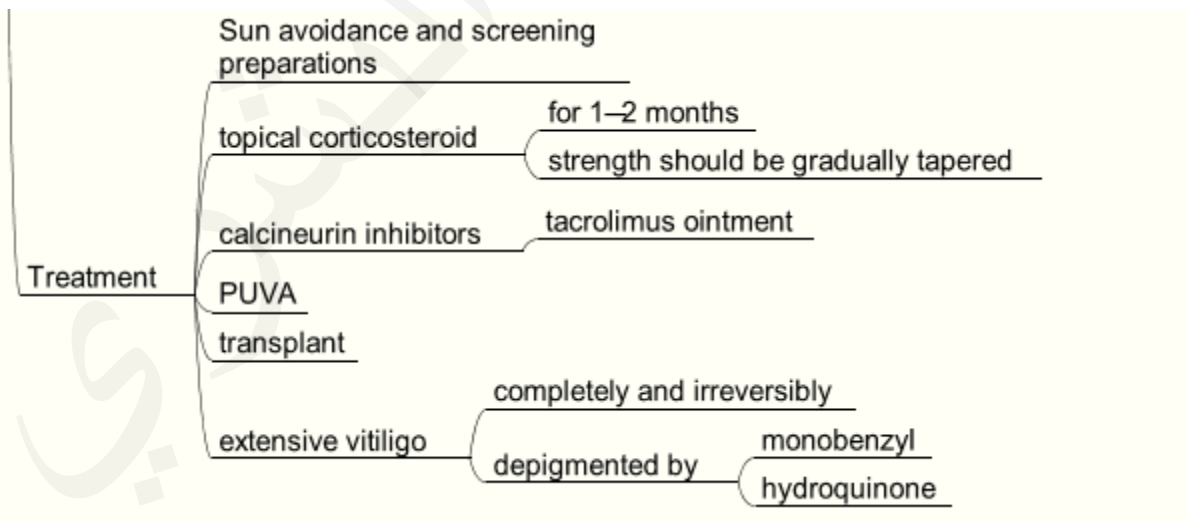
# Question 7



1. Describe the lesions seen in the picture.
2. What are the possible treatments for this disease?

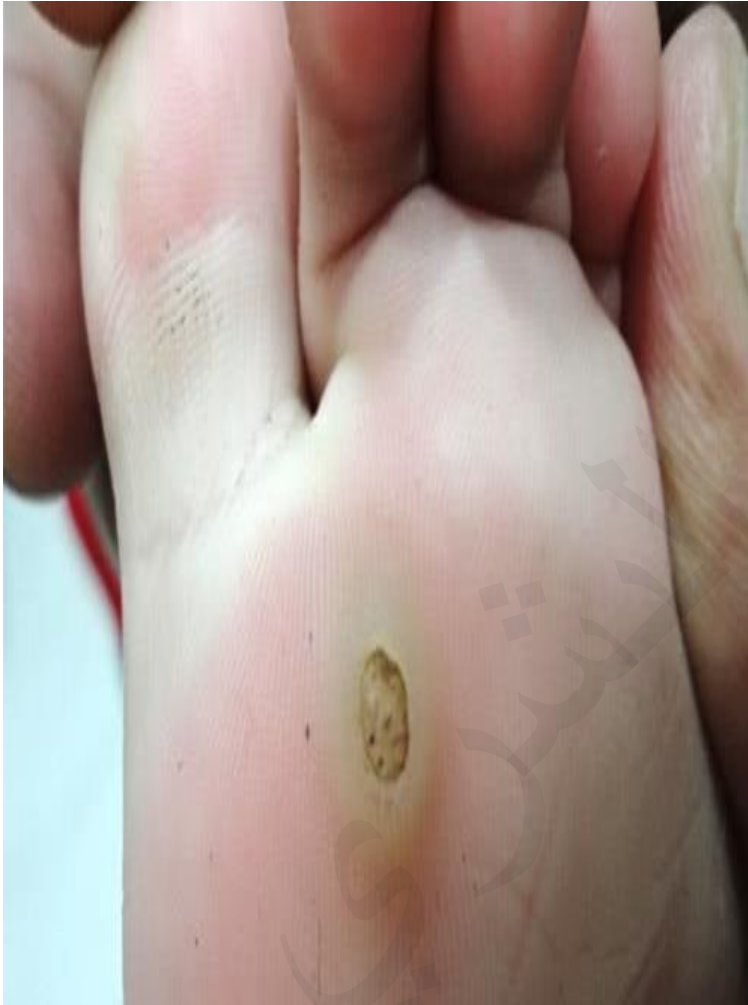- Q1:
  1. Type: Patch
  2. Shape: Sharply defined, hypopigmented, not scaly.
  3. Arrangement: not specific.
  4. Distribution: Symmetrical, over the hand in this pic.

- Q2:



Pic of Planter warts

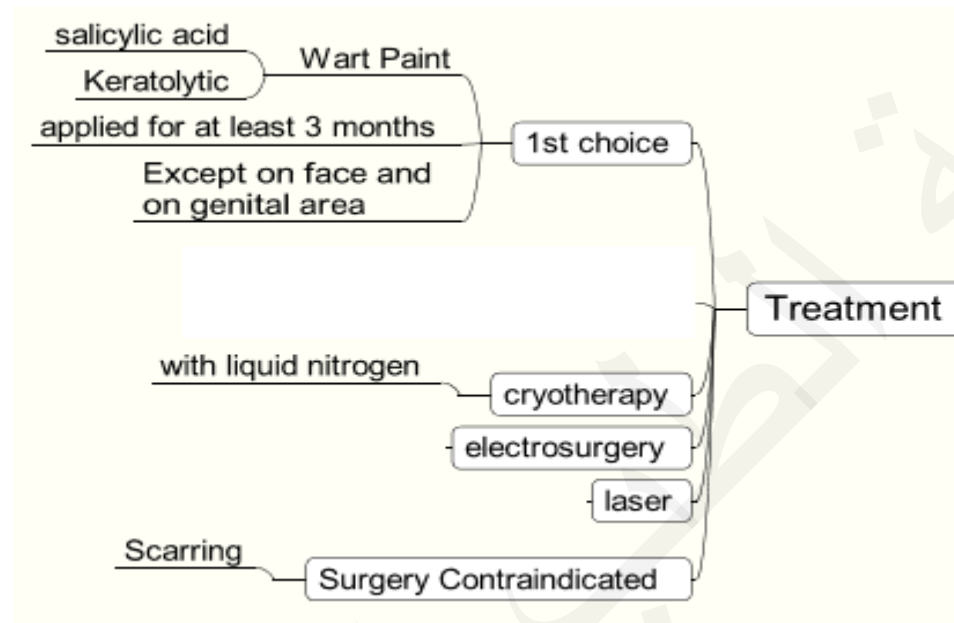
# Question 8



1. What is the treatment for this lesion?
2. Mention of the cause of the black dots?




- Q1:



- Q2:

Because the capillary blood vessels are thrombosed.

# **Pulse Question Team (Ibtihal Bany Mustafa)**



# **Dermatology mini-OSCE**

## **Group A1&A2**

# Question 1

- **Define the followings :**
  1. Burrow.
  2. Tzancks smear.
  3. Mention 3 causes of localized non-scarring alopecia.
  4. Mention 2 underlying causes for erythema nodosum.

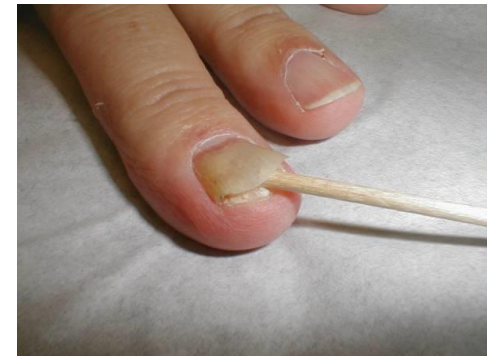
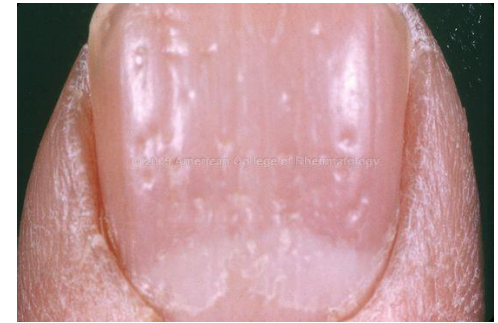## Question 2

- What the most likely Dx?
- Describe these lesions.
- Mention 2 topical treatments.
- Mention 2 autoimmune diseases you expect to find in the patient.
- What do you expect to see on woods light?



# Question 3

- **A 23 year old male patient comes to the office complaining of the following, he's father and brother are diagnosed with psoriasis.**
- What the Dx?
- Mention the finding from the picture.
- Give 1 DDx.
- Mention 2 areas you want to examine in this patient.

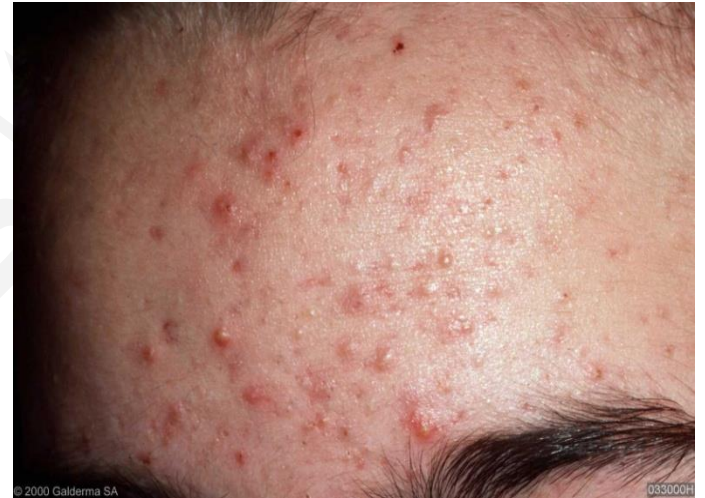



# Question 4

**A young male patient comes complaining of comedons, pustules and papules on his face and upper back.**

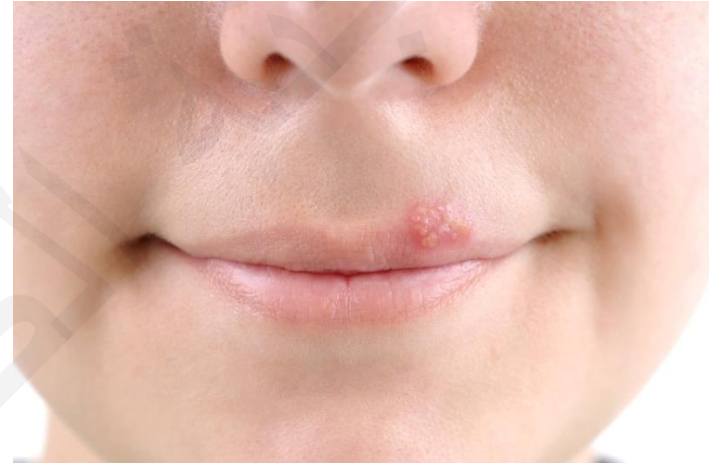- What's the Dx ?
- If the patient had scars, what's the treatment of choice and mention the side effects ?



## Question 5

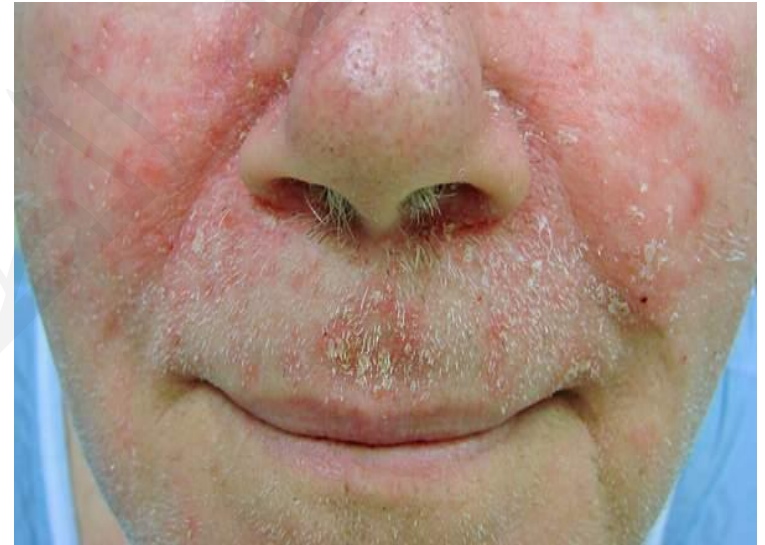**A 12 year old male complains of recurrent attacks of the following.**

- What's the Dx ?
- Describe the lesion ?
- Mention 2 factors that might trigger this condition?



# Question 6

**A 53 year old sexually active male complains of yellow crusted lesions around the mouth, he had this condition for the last 5 years**



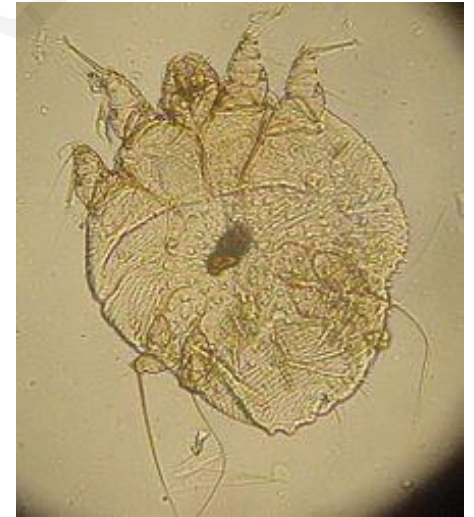
- What's the Dx ?
- Where do expect to find similar lesions ?
- Mention the yeast associated with this condition ?
- If this condition is resistant to all tt's what's the likely cause ?

**The answer to the last question is HIV**


# Question 7

**A man comes to the office and complains of 2 weeks itching that is much worse at night, and 2 family members have the same symptoms**

- Name the causative agent.
- Mention 2 points from the hx that supports your Dx.
- Mention 2 possible treatments.



**Pulse Question Team**  
**(Bader Abbad & Lara Rabah)**



# **Dermatology mini-OSCE**

## **Group B3&B4**



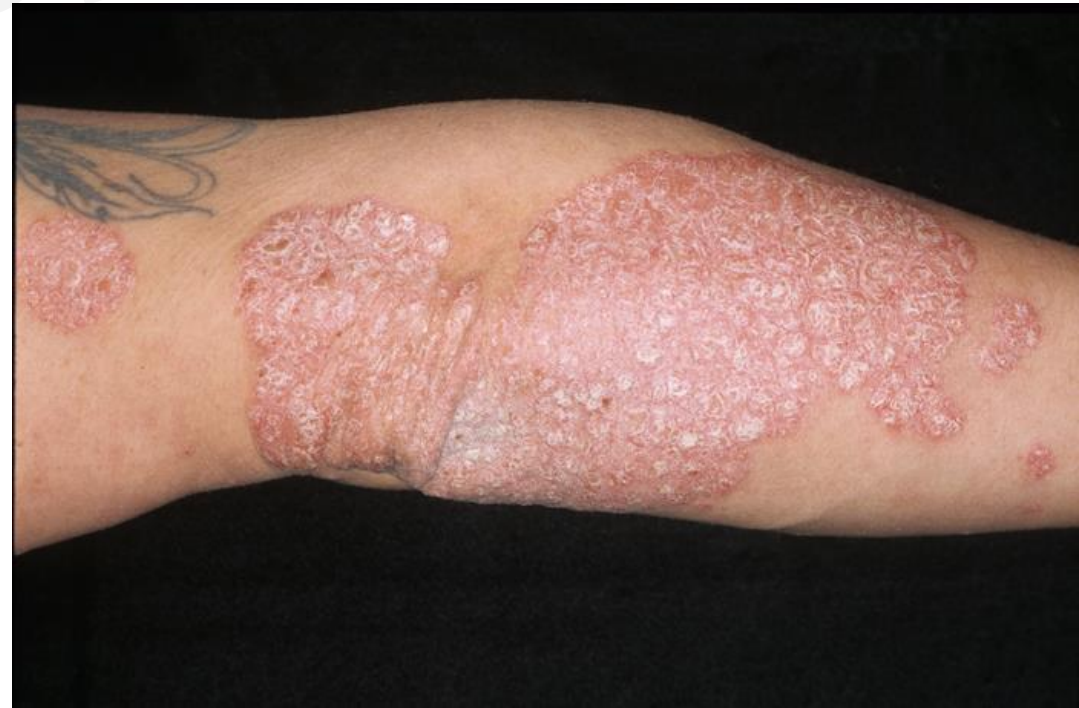# Q1) Define or answer the following:

- Define vesicle and mention two diseases.
- Define wood's light and give two examples.
- Two microorganism cause impetigo.
- Two clinical differences between acne and rosacea.

Q2) Female patient had this disease for 20 years and she has family Hx.

- Describe this lesion.
- Mention 2 triggering factors.
- Mention 2 nail changes related to this disease.
- Mention 2 tropical Tx.

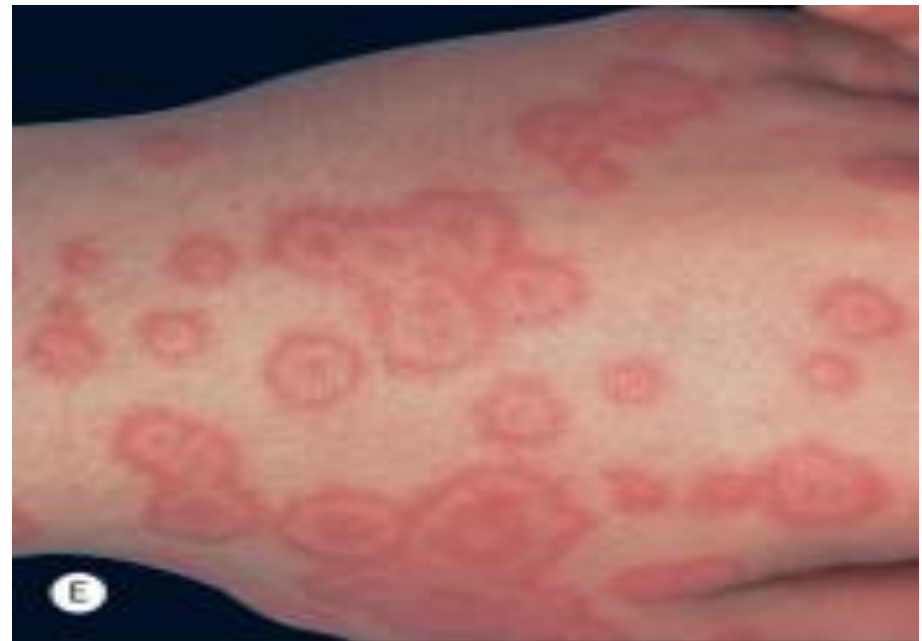((psoriasis))



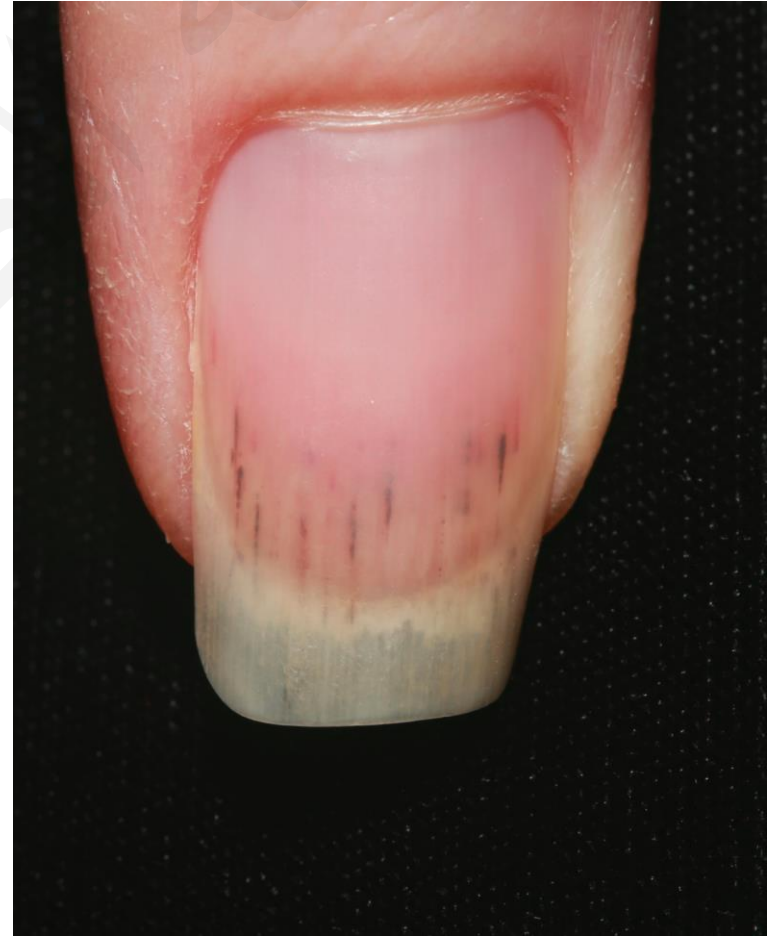Q3) Female patient with this lesion and she has Hx of painful lesions around her lips.

- What is the name of this lesion.
- What is the most likely Dx.
- Mention 2 causes.

((erythema multiform))

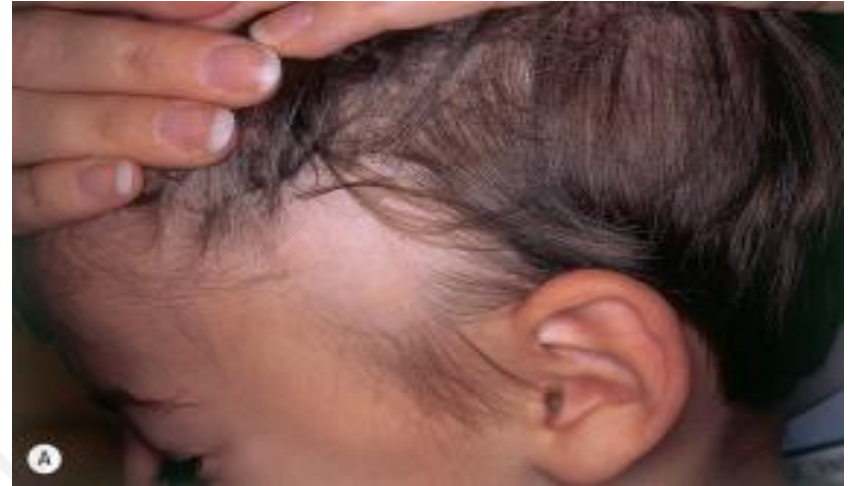

**Q4) Name the sign  
and give two  
causes.**

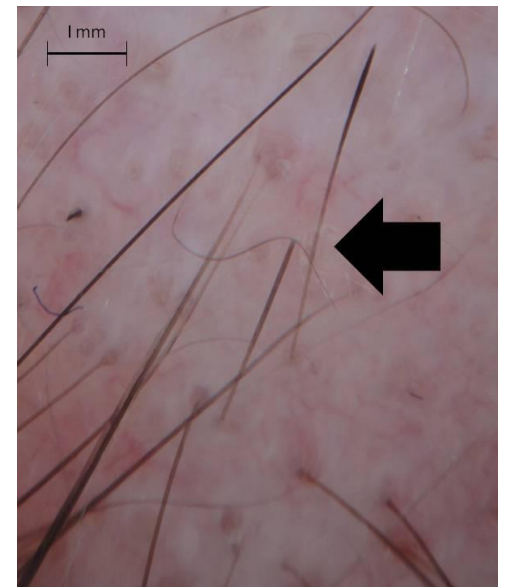


## Q5)

- Most likely Dx?
- DDx?
- What the name of the sign in the 2nd pic?
- 3 lines of Tx.



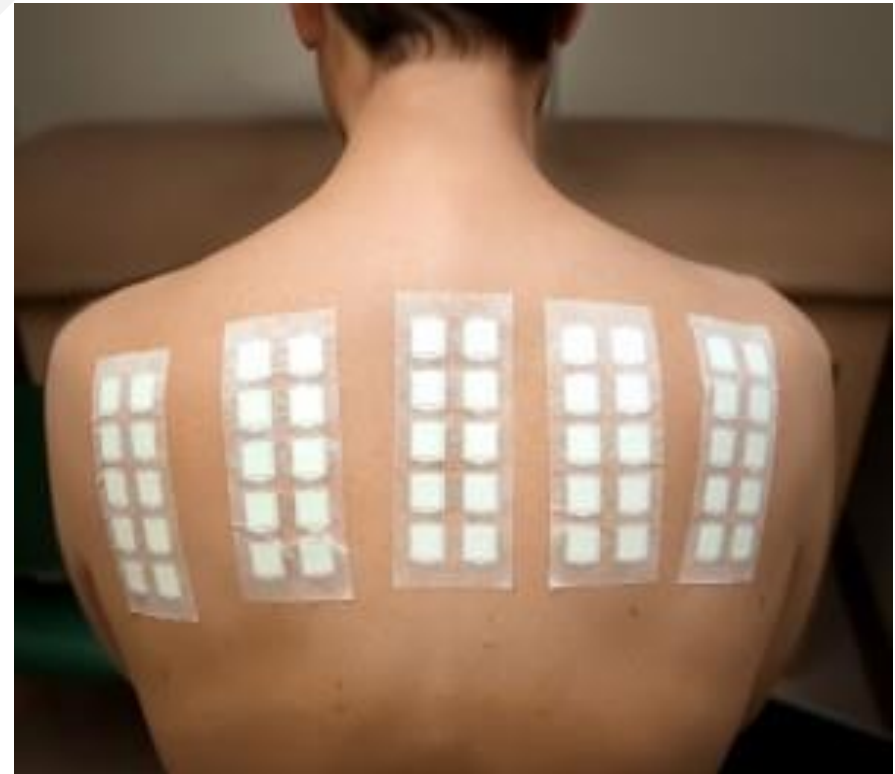((alopecia areata))



## Q6)

- What is the name of this test?
- After how many days you can read the results?
- What disease is Dx with it?

((patch test))

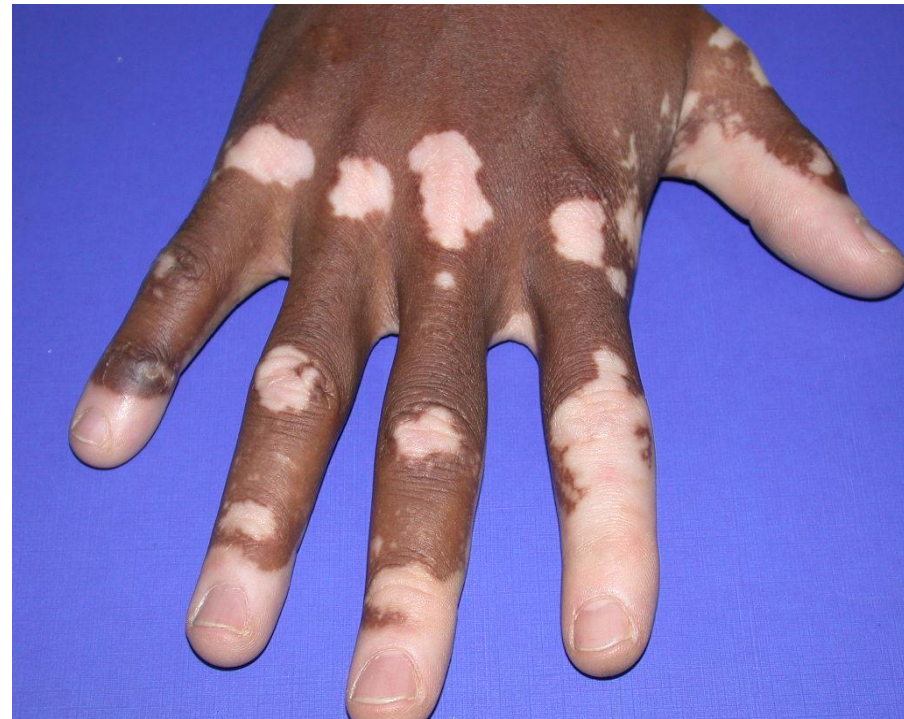



# Q7)

- Describe the lesion.
- What is the most likely Dx?
- Mention 2 blood tests you would order.
- Mention 2 lines of treatment.

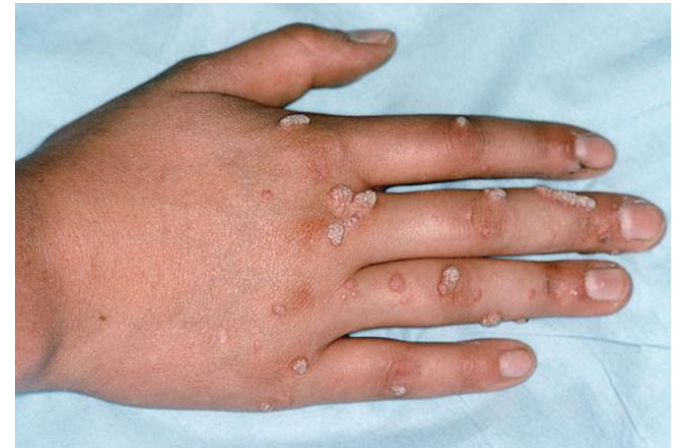((vitilligo))




## Q8)

- What is the diagnosis and what is the type?
- What is the cause?
- Mention 2 lines of Tx.

((common warts))



# **Pulse Question Team (Saif Al-Ghweery)**



# **Dermatology mini-OSCE**

## **Group B7&B8**

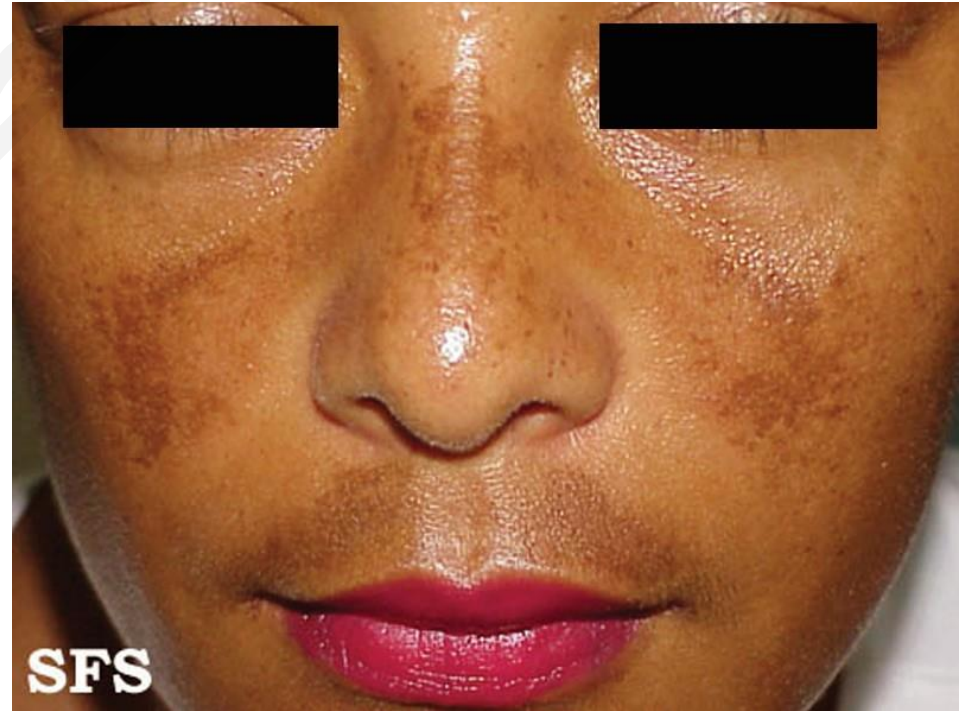# Question #1

- Define Erythroderma and give one example.
- Give 3 causes of onycholysis.
- Give 2 complications of rosacea.
- Name the sites of chronic psoriasis plaques.
- Give 2 treatments of scabies.

## Question #2

- Female pt, after her pregnancy she developed these lesions and she is now on OCP.
- 1) Describe the lesion
  - 2) What is the most suitable diagnosis ?
  - 3) What is the treatment ?

( Melasma )

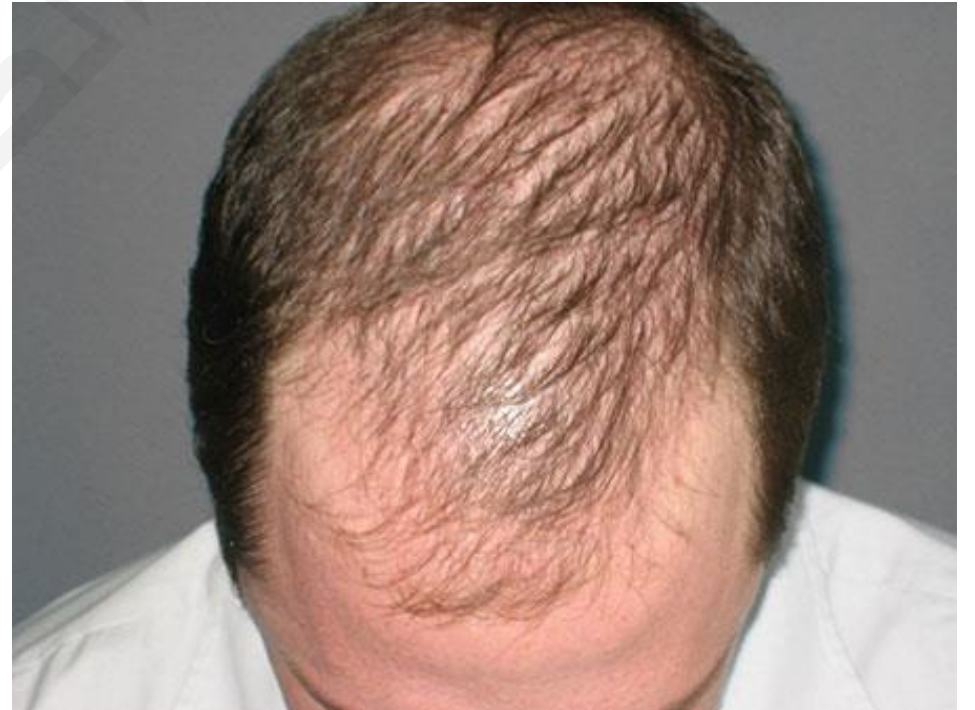



## Question #3

- Old male pt, came to your clinic complaining of hair loss, his brother suffers from the same condition.
- 1) Your diagnosis ?
  - 2) Give to 2 lines of treatment.
  - 3) Give 4 causes of diffuse non scarring alopecia.

( Androgenic Alopecia )





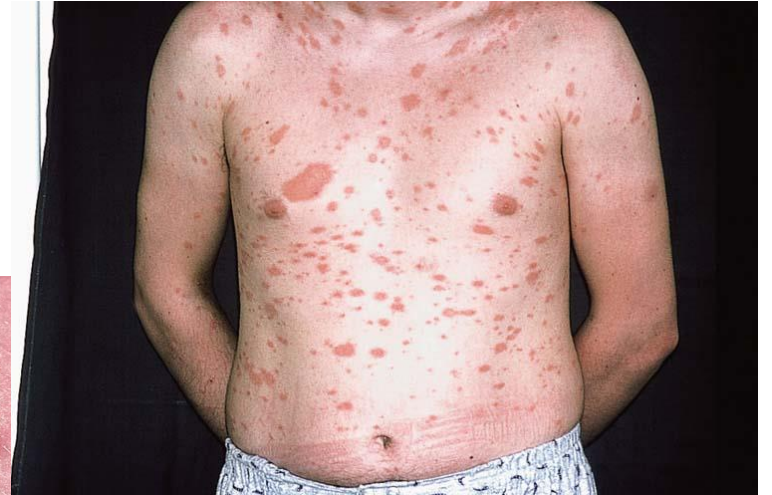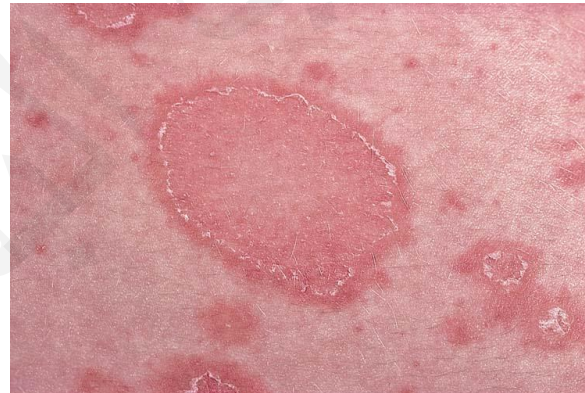## Question #4

- Pt present with wheal skin rash and was diagnosed with urticaria, answer the following:
  - 1) What is the triple response of Lewis ?
  - 2) Give 3 causes of acute urticaria.
  - 3) Name internal organs that are affected by angioedema.
  - 4) If the pt suffered from hypotension and tachycardia, what would your diagnosis be and what would your treatment be ?

# Question #5

• According to the following picture answer the following questions:

- 1) Give 2 differential diagnosis.
- 2) Name 2 drugs that might cause this.
- 3) What is the scale type ?



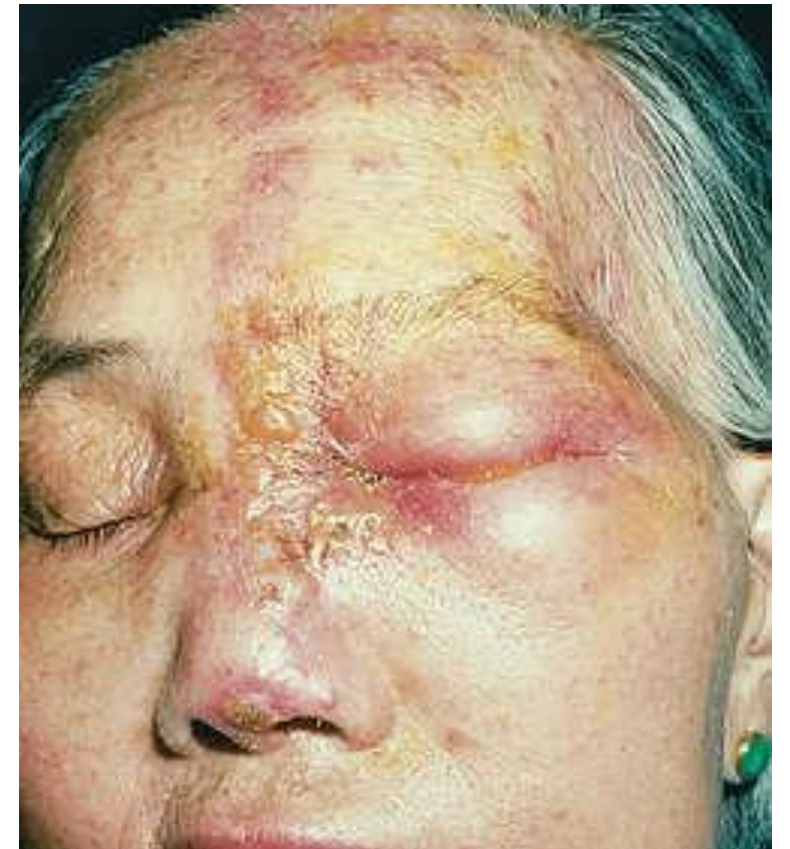( Pityriasis Rosea )

## Question #6

- According to the following picture answer these questions:


- 1) Describe.
- 2) Treatment.
- 3) Name 2 complications.

( Not the exact picture but almost the same )  
( Herpes Zoster )



# **Pulse Question Team**

## **Shaden Almomani**



# **Dermatology mini-OSCE**

## **Group B1&B2**

The pics are either the same or as close as possible to what were at our exam

# Q1

- Define patch
- mention the causative organism in erysipelas –scaled skin syndrome -chicken pox
- Mention 2 types of dendritic cells in epidermis ?

# Q1 Answers

- *Patch* : flat area, more than 0.5 cm in diameter, of altered color or texture.
- Erysipelas: GAS /s.PYOGENES, scaled skin syndrome:S.aureus , chicken pox :varicella zoster virus (VZV)
- Melanocytes,langerhan's cells



## Q2

- Describe the lesion
- Mention one bedside test
- Mention 2 blood tests

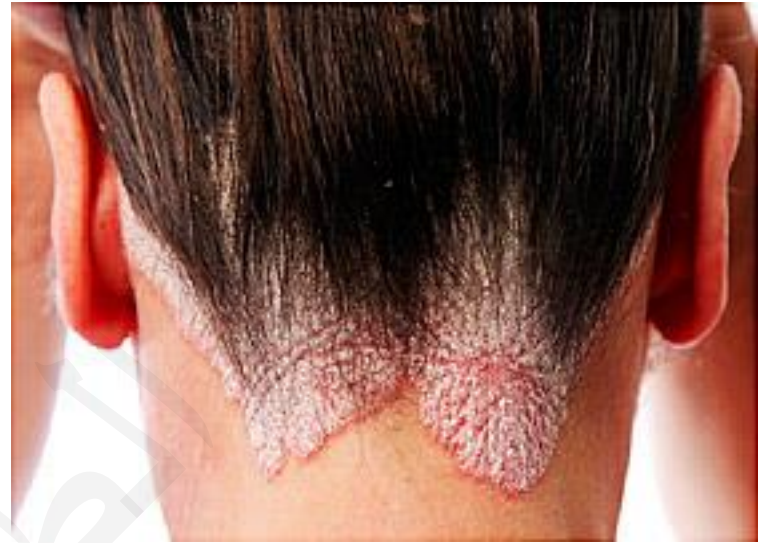

## Q2 answers

- **Type: Patches** ,**Shape: well** defined margin, not scaly, depigmented (white), **distribution:** periorificial +on extensor surfaces/acrofacial
- Wood's light
- TFTs(t3,t4,TSH),fasting blood glucose,b12,...etc (to look for associated autoimmune diseases(thyroid,DM,pernicious anemia,...))

### Q3

They told us its scalp psoriasis



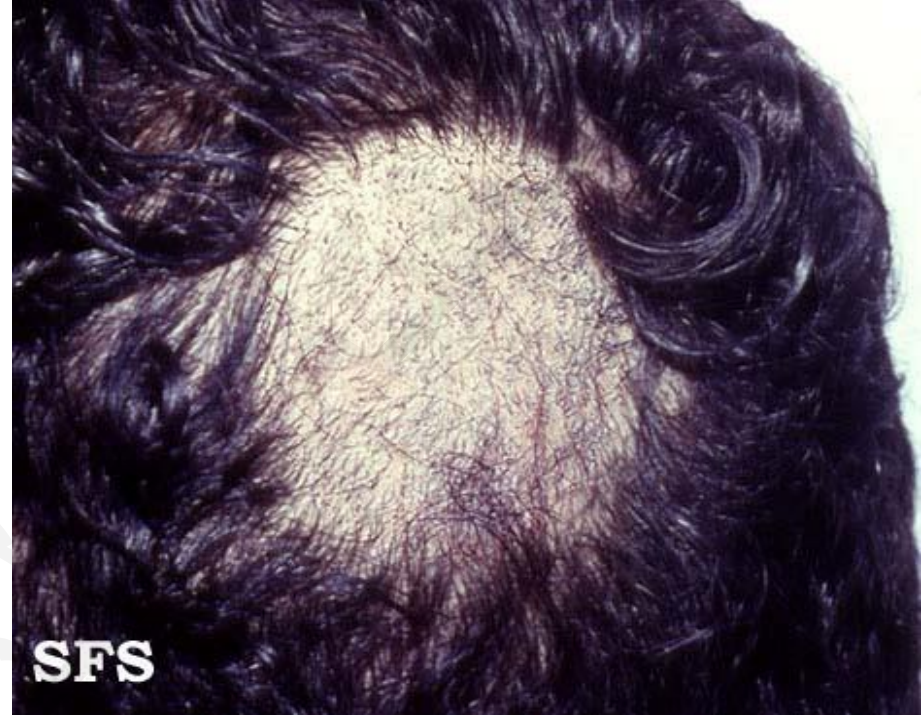- Describe lesion ?
- Mention 4 systemic TX
- If both parents were affected with vitiligo what's the % of their kids involvement
- How to differentiate seborrheic dermatitis and scalp psoriasis

# Q3 answers

- **Type**: plaque ,**shape** :well defined margin, salmon-pink ,silver scale on top of it, overflows beyond hair line ,**distribution** :on scalp
- Acitretin, Methotrexate, Cyclosporine, biologics(e.g Infliximab)
- 41%(hunter 5<sup>th</sup> edition)

Psoriasis	seborrhic dermatitis
lumpy	Less lumpy
Well defined margin	Not will defined
-Overflows beyond hair line -Silver scale	-Doesn't -yellow greasy scale

Q4: Pic of boy with hair loss the boy has a dog



- What is the DX?
- Give 2 DDX ?
- Mention the Tx of choice?

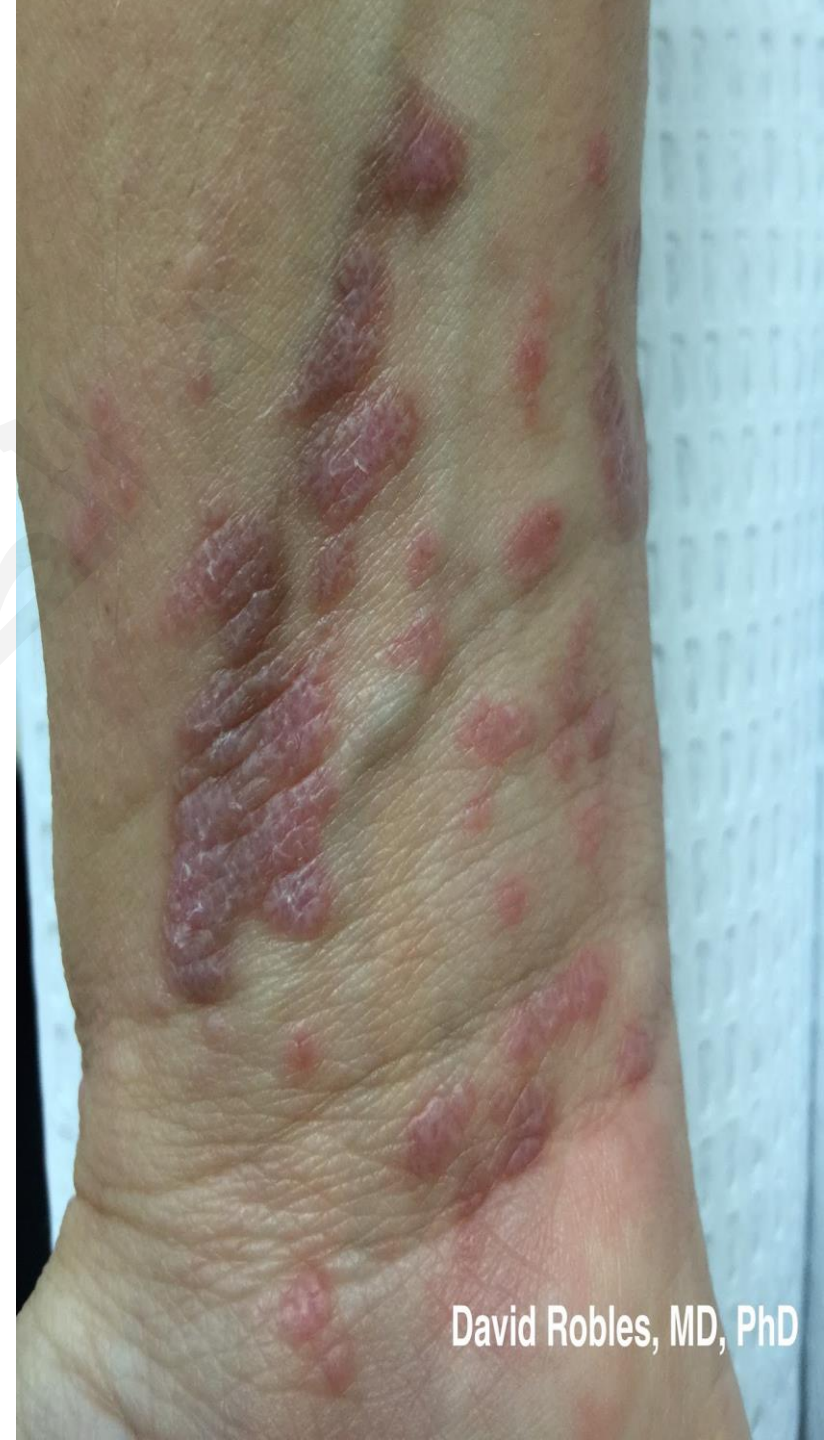# Q4 ANSWERS

- Tinea capites
- Alopecia areata, **Trichotillomania**
- Griseofulvin

## Q5

Purple flat topped  
itchy plaque

- What's your Dx
- 3 lines of Tx
- 3 variants
- 2 Nail changes



David Robles, MD, PhD

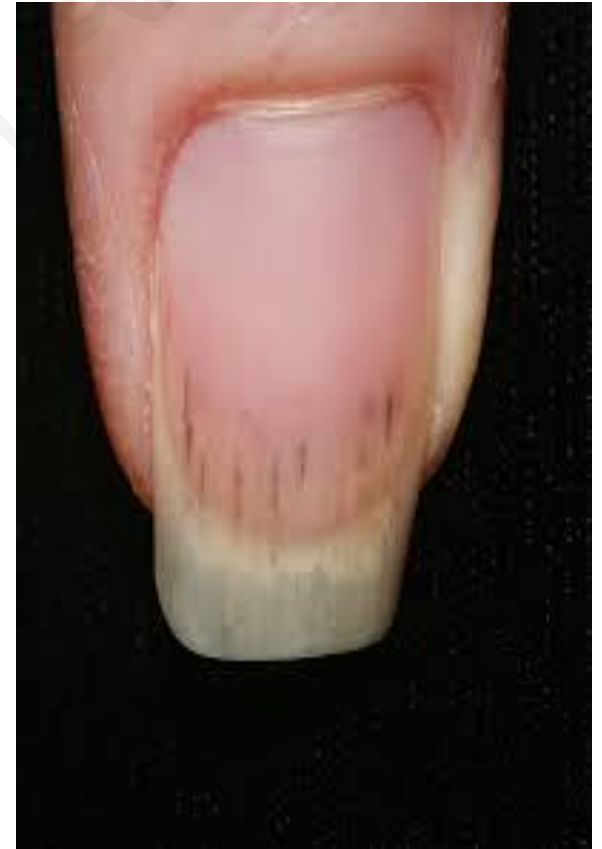

# Q5 answers

- Lichen planus
- topical or intralesional corticosteroids, oral metronidazole , phototherapy
- Atrophic ,hypertrophic, follicular ,...
- Longitudinal ridges +grooves, pterygium

q6

- What's your diagnosis
- Mention 2 causes

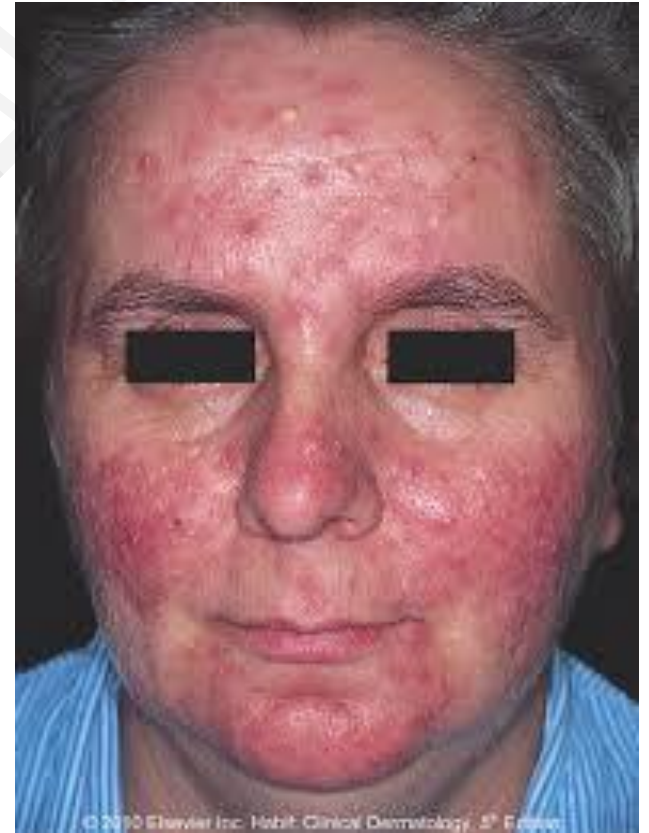

## Q6 answers

- Splinter hemorrhages
- Psoriasis ,trauma,infective endocarditis

## Q7


- Name 1 parasite involved in the disease
- What's your Dx
- Mention 2 complications ?
- Mention 2 topical Tx



## Q7 answers

- *Demodex folliculorum*
- *Rosacea*
- *Phyma ,ocular involvement (e,g keratitis),psychological*
- *Topical metronidazole,azeliac acid*

**Pulse Question Team**  
**(Mosab Shoman & Bayan Al-Ghsoun)**



# **Dermatology mini-OSCE**

## **Group B7&B8**

26-1-2017



## Q1 :

1. Define acantholysis.
2. Mention 3 patterns of cutaneous arrangement.
3. Define “ exclamation mark” of alopecia areata.
4. Give 3 examples of scarring alopecia
5. Mention 3 modes of treatment in vitiligo
6. Mention 3 precipitating factors for herpes simplex

Q2:

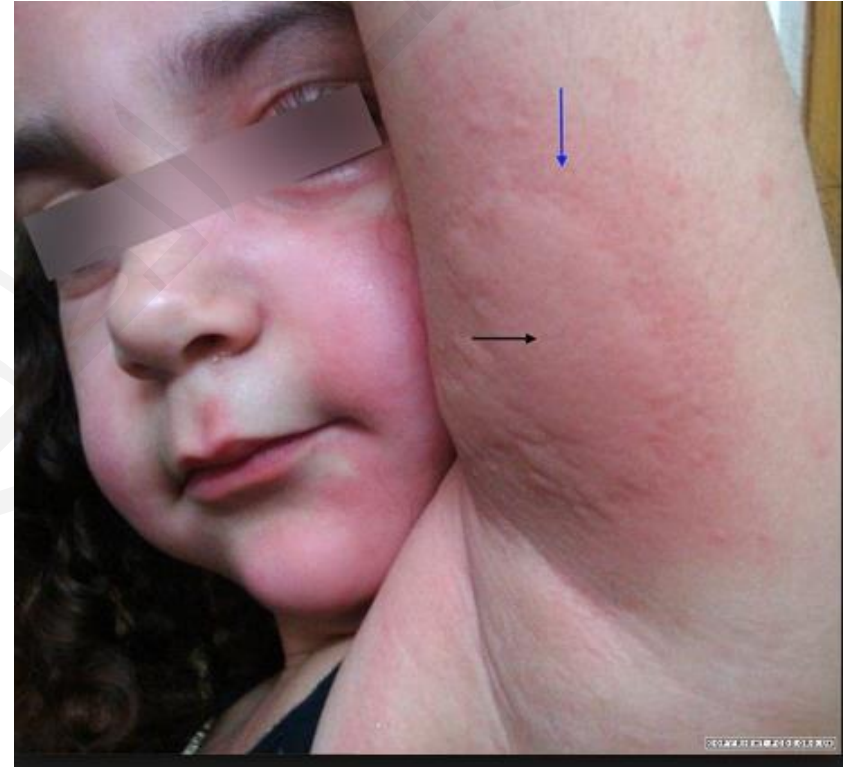This patient developed this rash, individual lesions stayed for less than 24h

1-Describe the rash.

2-What is the diagnosis.

3-What is the main mediator of it in this condition.

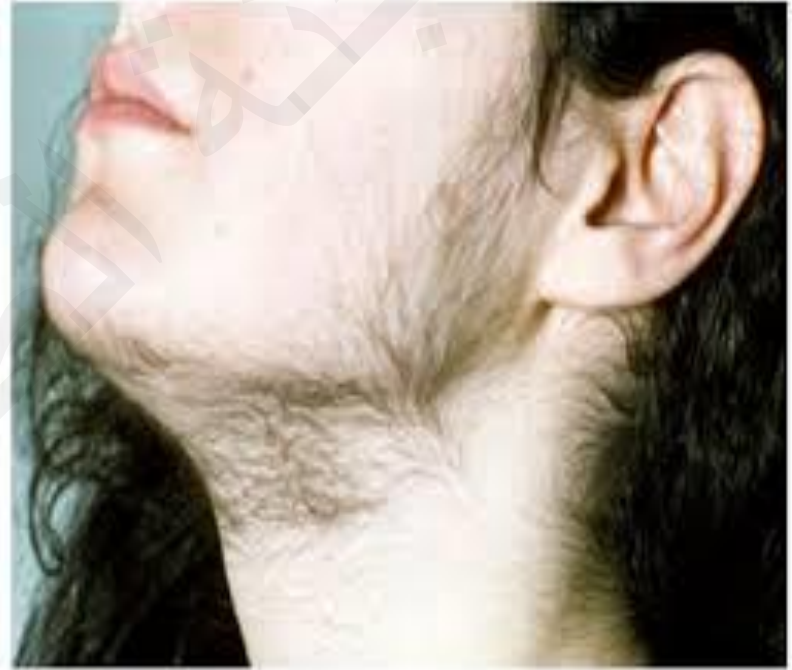4-What is the 1<sup>st</sup> line of treatment.



Q3:

19 years old female patient  
present with hirsutism

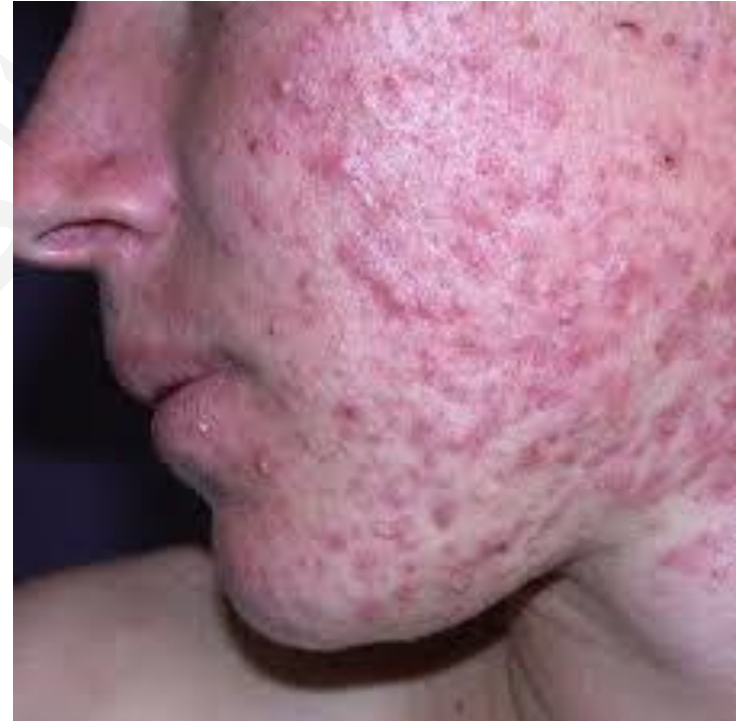1. Define hirsutism.
2. What is what is the most important question to ask in history.
3. If the patient had deepening of voice and clitoromegaly what to suspect ?
4. The main 3 investigations to do.



Q4:

Patient present with pustules, nodules and comedones of the face and shoulders

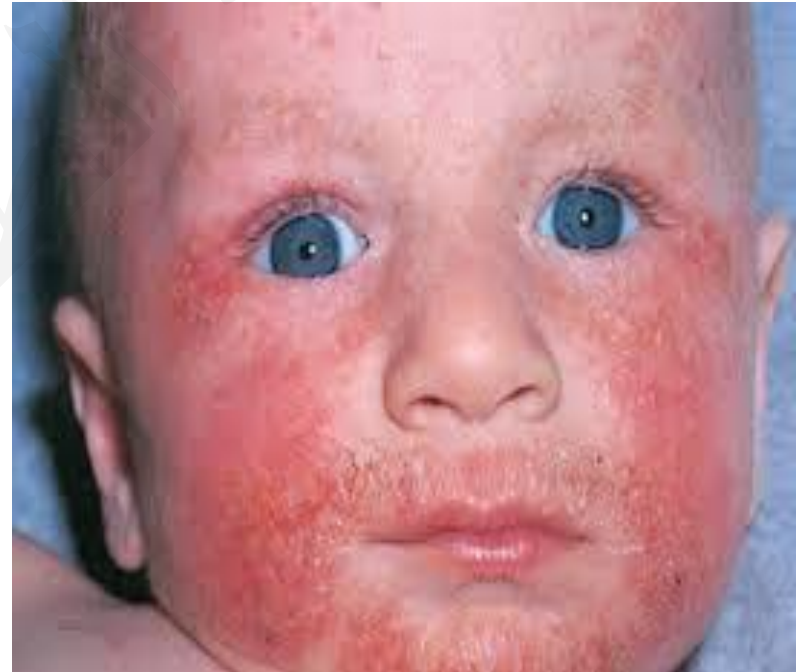1. What is the diagnosis ?
2. 3 complications for this condition.
3. Mention 3 variants
4. 3 lines of systemic treatment.



Q5:

6 months male baby present with this rash for 3 months, his mother has asthma

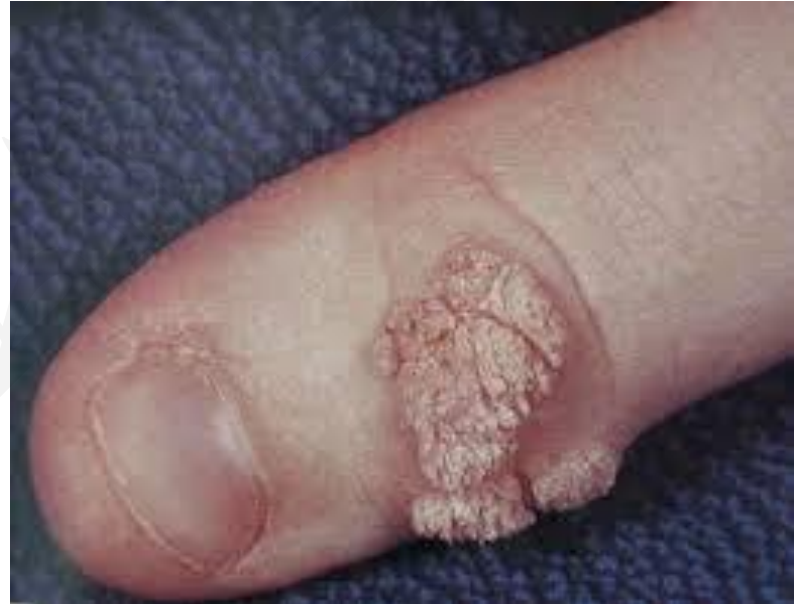1. What is the diagnosis.
2. Name 2 organisms that can cause skin infections in this patient.
3. Where do you expect the rash to be if the condition persisted till childhood
4. Mention 3 topical treatment.



Q6:


Patient present with this elevated solid, asymptomatic condition

1. What is your diagnosis.
2. Describe the rash.
3. Mention 3 variants for this condition.
4. 2 lines of treatments with their duration.



**Pulse Question Team**  
**(Laith Nimer & Shaden Abu Baker)**



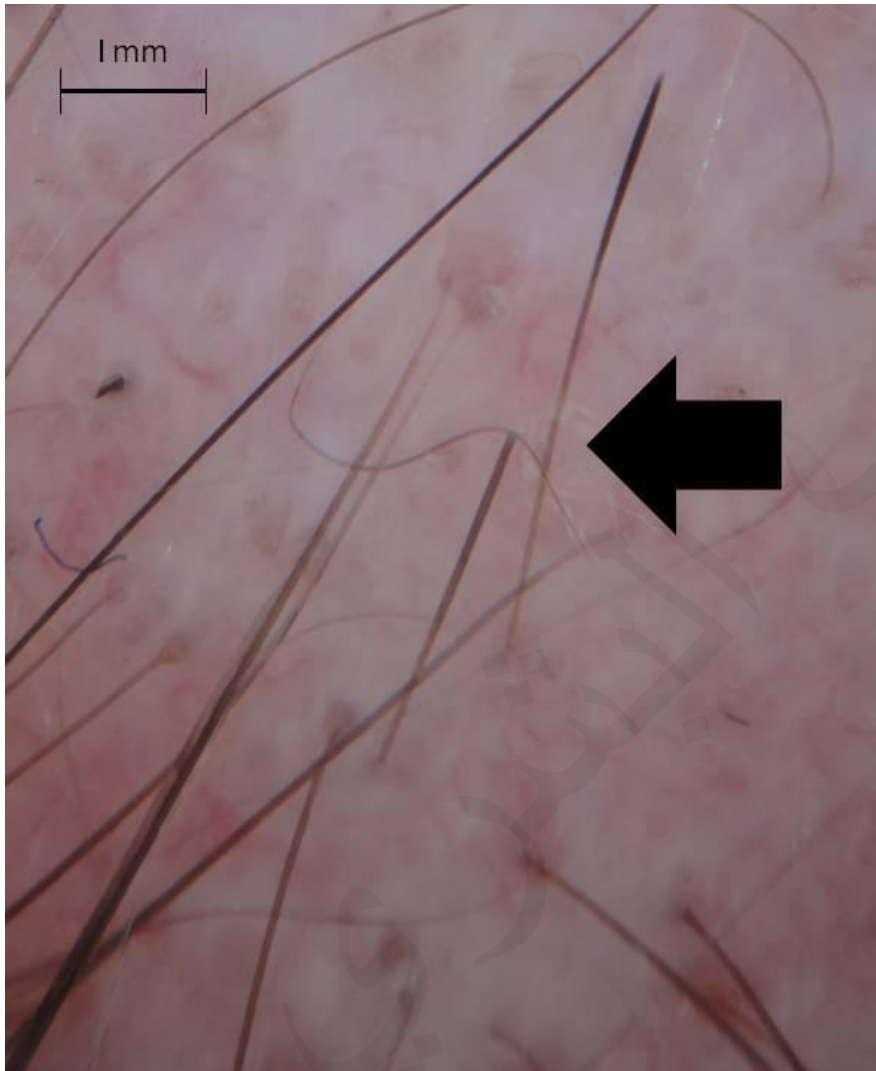


# Dermatology Exam Groups C3+C4

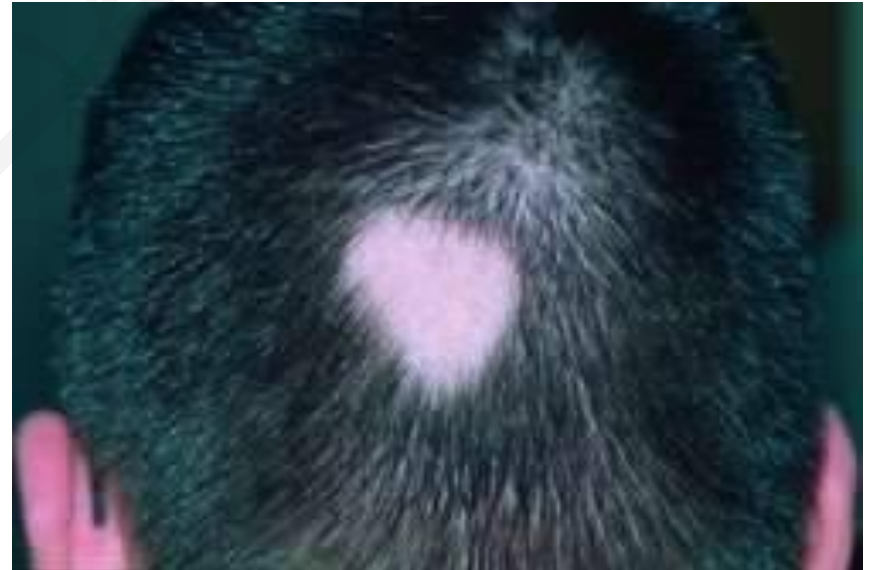22-12-2016

- Define Poikiloderma
- Mention the types of endogenous eczema
- What is the treatment for psoriasis? (with a picture)
- What are the functions of skin?
- Picture of acne and asked for Dx and treatment
- Picture of urticaria and asked for Dx and treatment

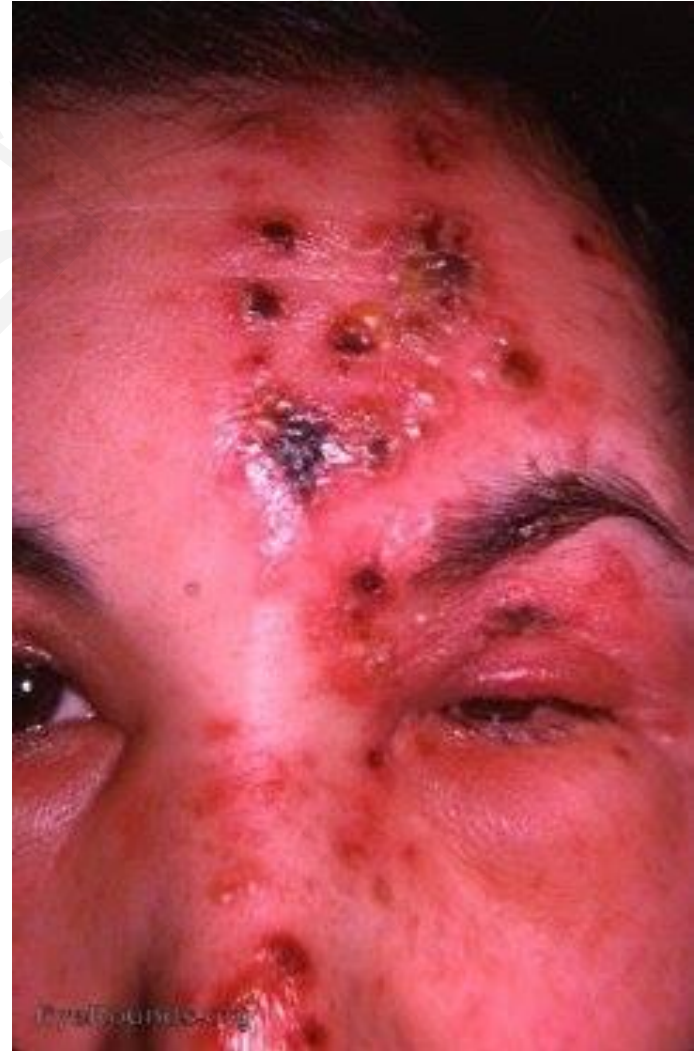Exclamation mark



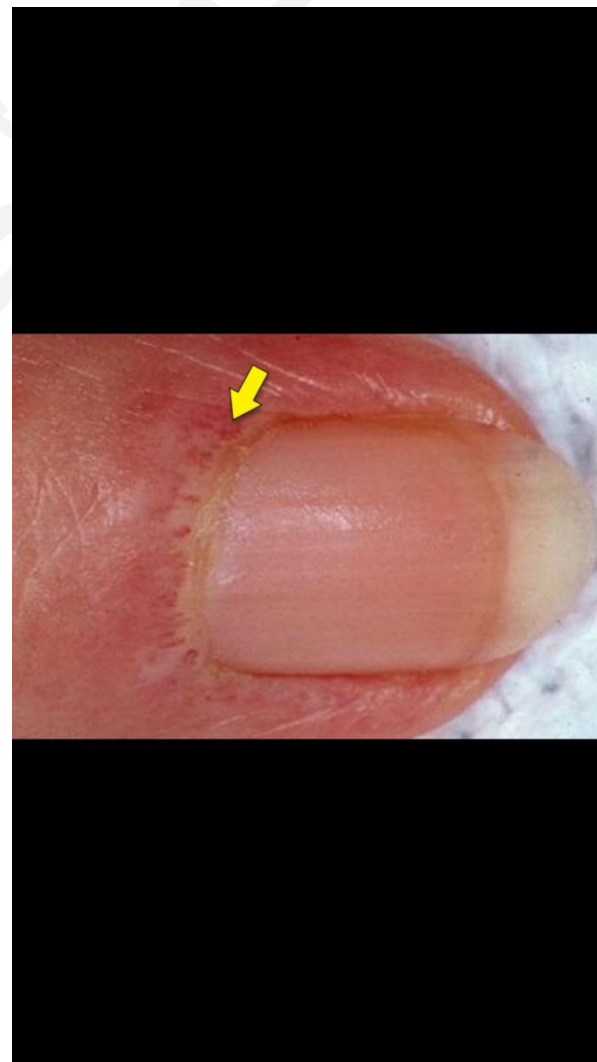Alopecia Areata



Shingles along the  
ophthalmic division of  
trigeminal dermatome  
Causative agent is herpes  
zoster  
(herpes zoster  
ophthalmicus)



## Nail fold Telangiectasia





**Healing Batch**

# Dermatology Exam – Healing Batch

Groups B1 + B2



# Written Questions

1. Adhesion molecules of the epidermis?
2. Criteria of atopic dermatitis major and minor?
3. Define arthroderma? Give 2 examples?
4. Clinical difference between urticaria and erythema multiforme?
5. Mention 2 diseases caused by malassezia (pityrosporum orbiculare)?
6. Case Telogen effluvium? tt?

# Pictures

1. Psoriasis? Definition? Mode of inheritance?
2. Pityriasis Rosea? Type of the scale? causative organism? Prognosis? What is the serology test that you can perform?
3. Piebaldism? What is the mode of inheritance?
4. Herpes zoster ophthalmicus? tt?
5. Pitted keratolysis? Causative organism? tt?

# Dermatology Exam – Healing Batch

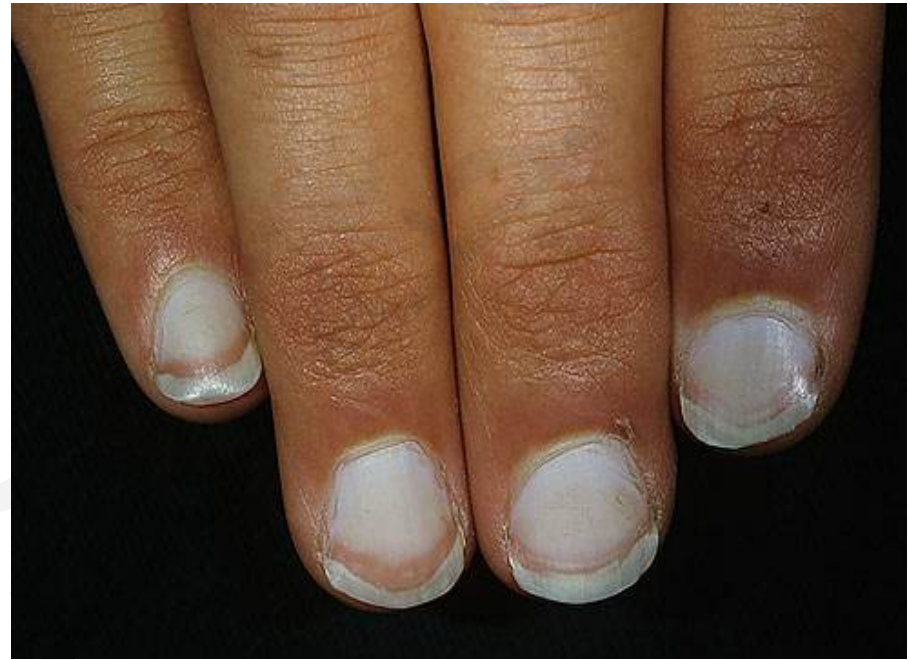## Done by B7+B8

# Q1- written question

- Define the vesicles ,and give 3 diseases u can see in
- Define the offiasis ,and which disease does this sign appear ?
- Mention 4 variant types of lichen planus
- When you see horsutism there are conditions associated with polycystic ovary disease ,mention 3 of them

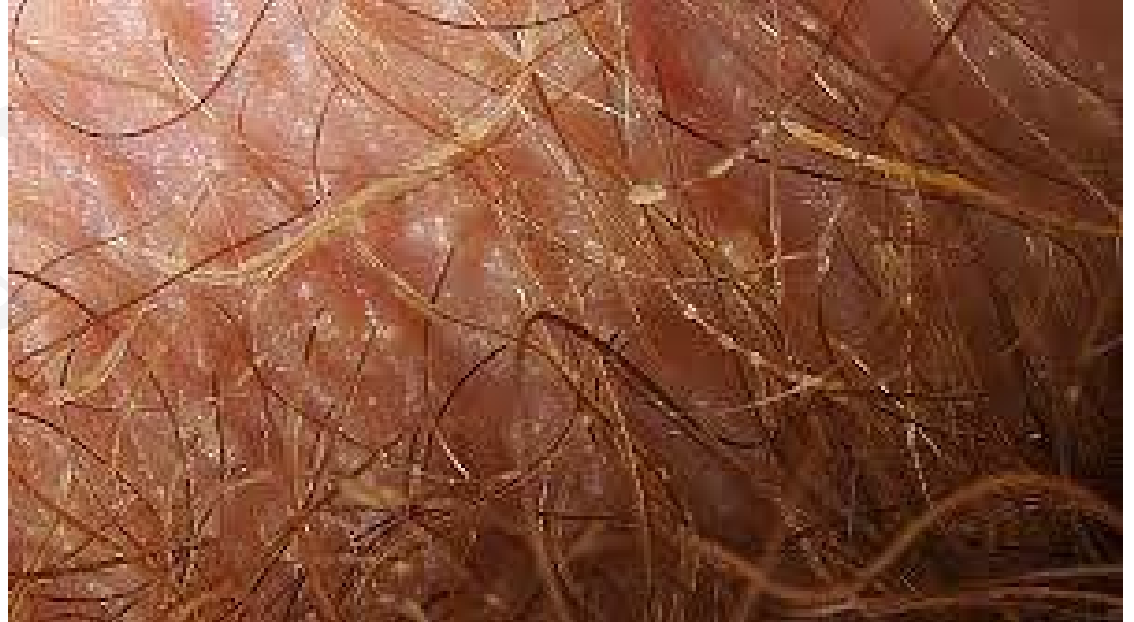## Q2

- What is this?
- In which disease u see?



# Q3

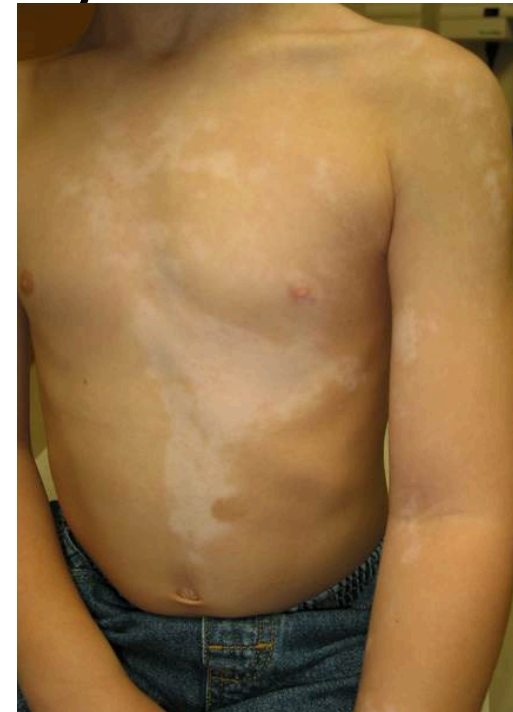- What is this?
- Is it bacterial or fungal infection?
- Give two lines of treatment?



# Q4

- What is this ? Give one investigation and the result?

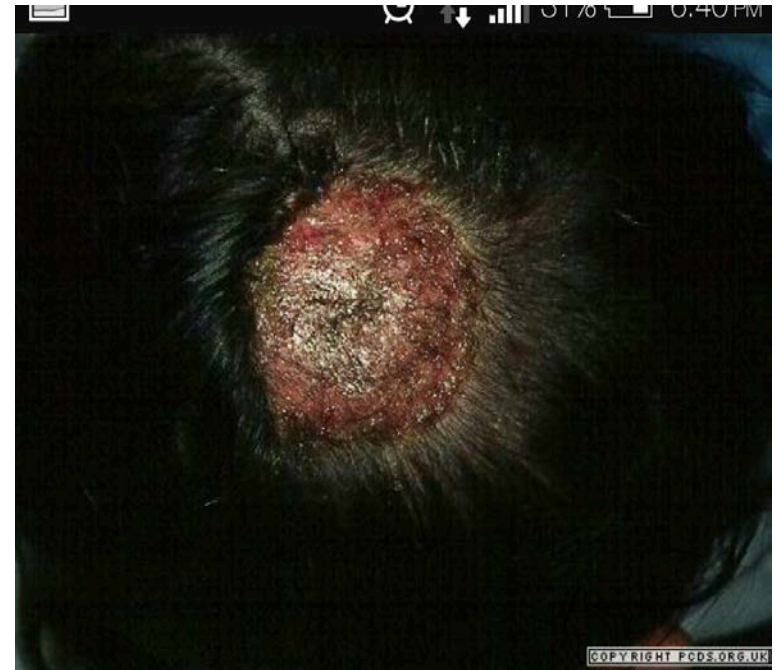which type of (Q about vitiligo that only presents on the lateral trunk and upper thigh)?segmental





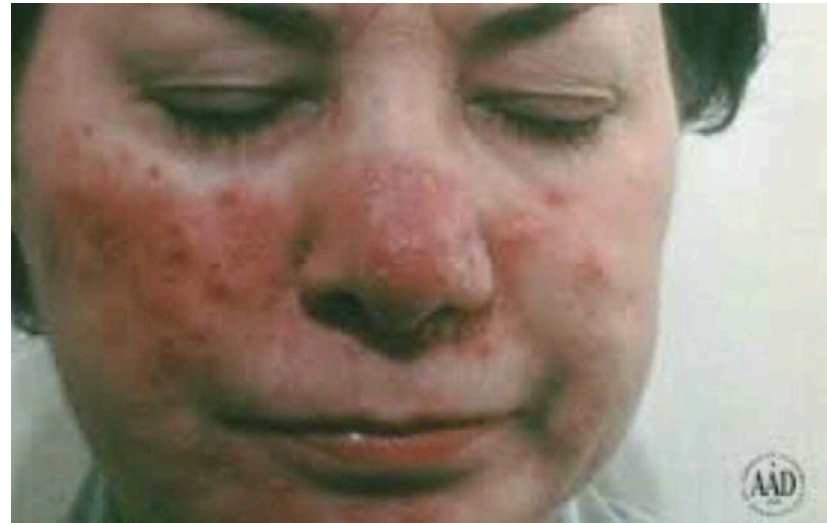# Q5

- Child presented with this lesion : Your Dx another pic ?ask what is it ?KOH Other investigations to confirm?



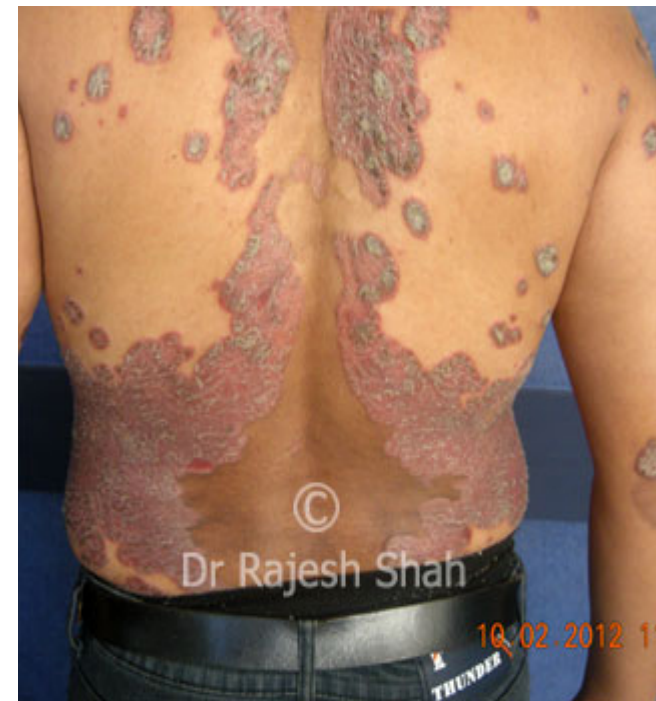## Q6

- Dx :Rosacea Mention three complications
- And name three medications to treat ?



# Q7

- Describe the lesion ?
- What is Dx ?
- Mention 3 complication of this lesion ?



# Dermatology Exam – Healing Batch Groups C5-C6

- -Define auspitz sign and where is it found ?
- Function of DEJ barrier
- Define the characteristics of chronic eczema
- Dx and treatment of androgenic alopecia
- White dermographism with atopic eczema
- Case of scabies with treatment
- Viral warts dx and subtypes
- A case of psoriasis, drugs that exacerbate,
- Case of erythema nodosum, primary lesion, course

# Dermatology Exam – Healing Batch Groups C7 & C8

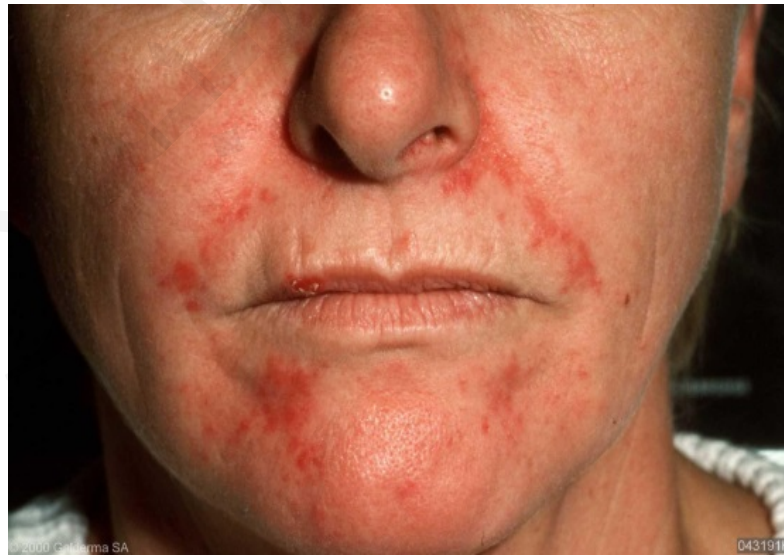# Q1

- 1) define pustule
- 2) mention 4 presentations of acne
- 3) name three fibers in the dermis
- 4) mention three presentations of tinea capities



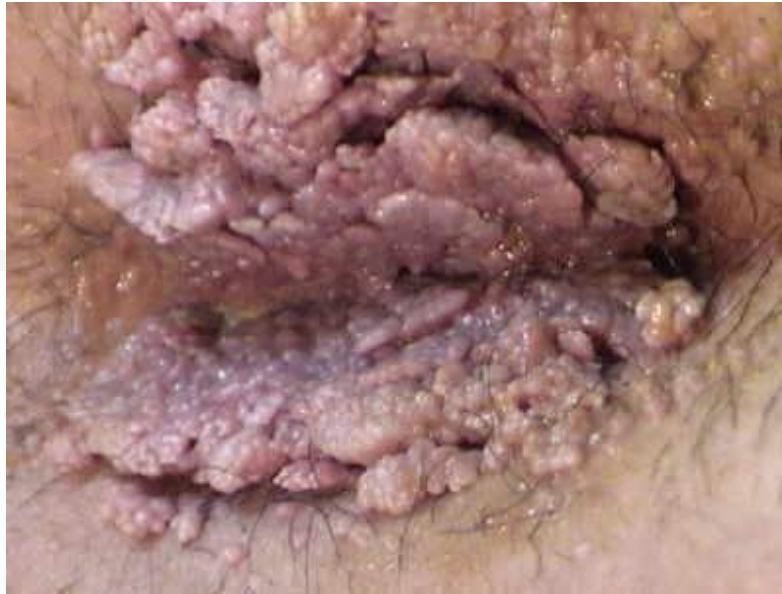Q2: a patient presents with greasy scales on the face

- 1) Dx ? seborrheic eczema
- 2) mention other Three presentations of this condition
- 3) the two most common groups affected



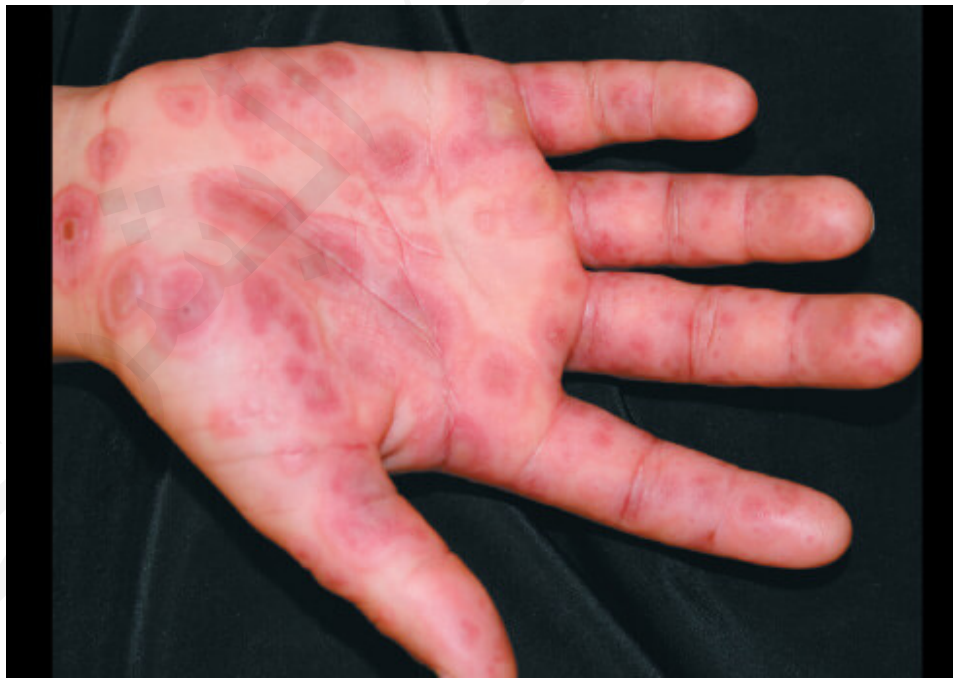Q3: a patient present with this in his anal region

- 1) Dx ? condylomata acuminata
- 2) causative organism and it's serotype
- 3) one DDx
- 4) two topical treatments with side effect for each one



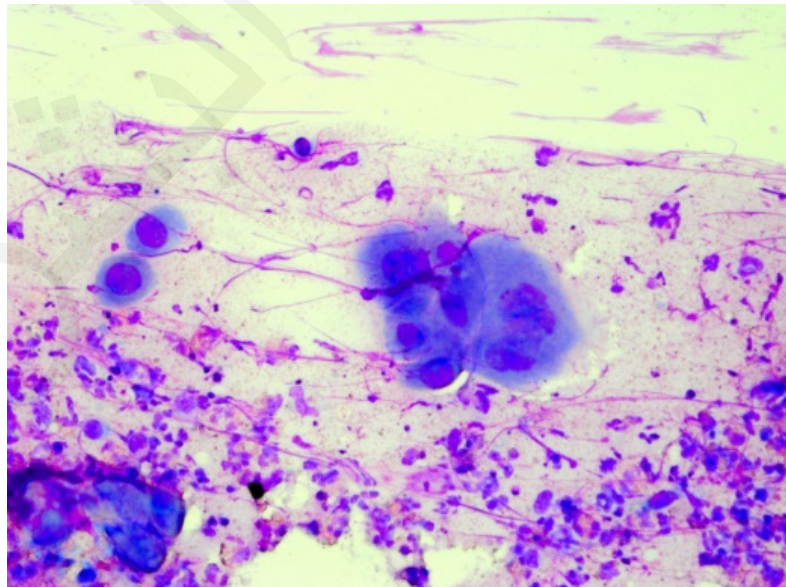
## Q4

- 1) describe the lesion
- 2) diagnosis
- 3) most common cause ?



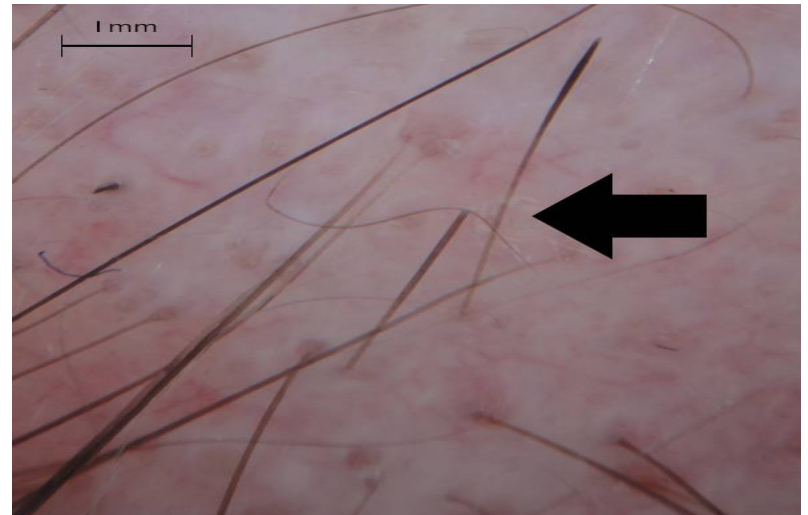
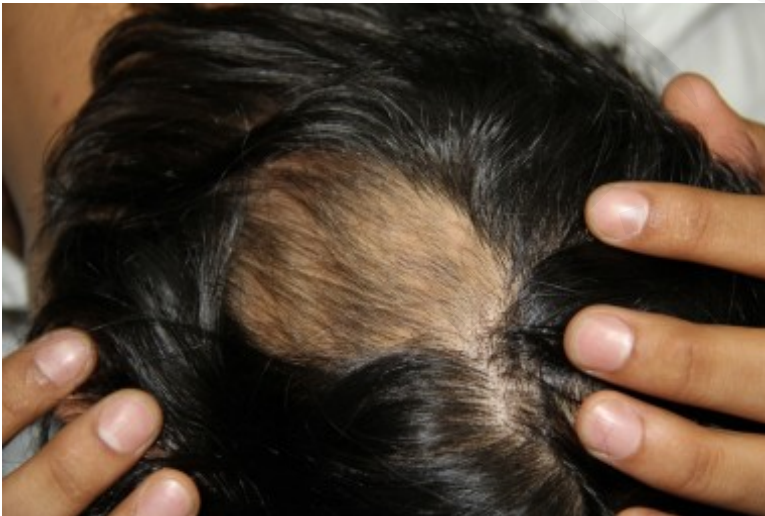Q5: A patient comes with unilateral burning pain and a lesion on his chest ,  
and the following test was done

- 1) Dx ? shingles
- 2) name of the test and findings ?
- 3) other condition we use this test in ?



## Q6: a child comes with this presentation

- 1) Dx ? alopecia areata
- 2) 2 signs you look for to support your diagnosis
- 3) wood's lamp result ?





**Ihsan Batch**

# Dermatology Groups

## B1+B2

Ihsan Batch

10/01/2019

# Q1:

1. Define a comedone.
2. Mention 2 functions of the dermo-epidermal junction (DEJ).
3. Mention 4 causes of non scarring diffuse alopecia.
4. Mention 2 diseases caused by diphtheria.

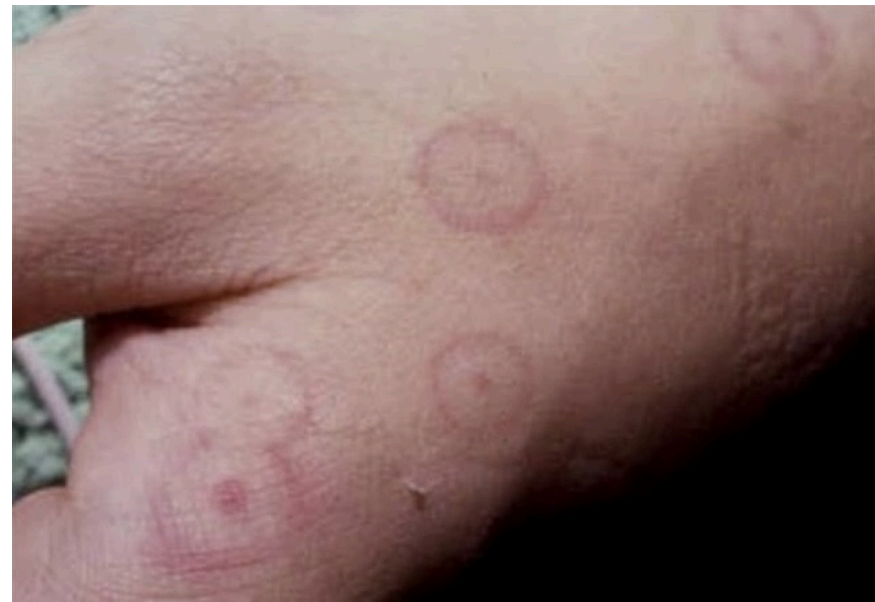

# Answer 1:

1. a plug of greasy keratin wedged in a dilated pilosebaceous orifice.
2. -The structures within the dermo-epidermal junction provide mechanical support.  
-The DEJ encourages the adhesion, growth, differentiation and migration of the overlying basal cells.  
-It acts as a semipermeable filter that regulates the transfer of nutrients and cells from dermis to epidermis.
3. -Androgenic alopecia -Drug induced -Telogen effluvium -Iron deficiency ...etc
4. -Pitted keratolysis -Erythrasma ...etc

Q2: a patient came to you with this lesion for 1 week, he had several similar lesions over the past year.

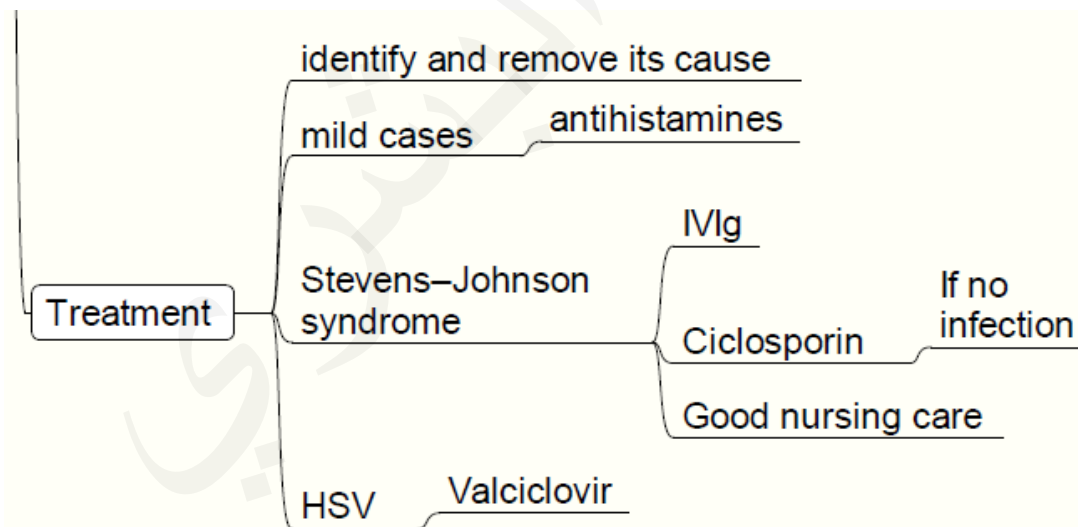
1. What is the diagnosis?
2. Describe this lesion.
3. What is the next step in physical examination?
4. Mention 2 lines of treatment for this case.



## Answer 2:

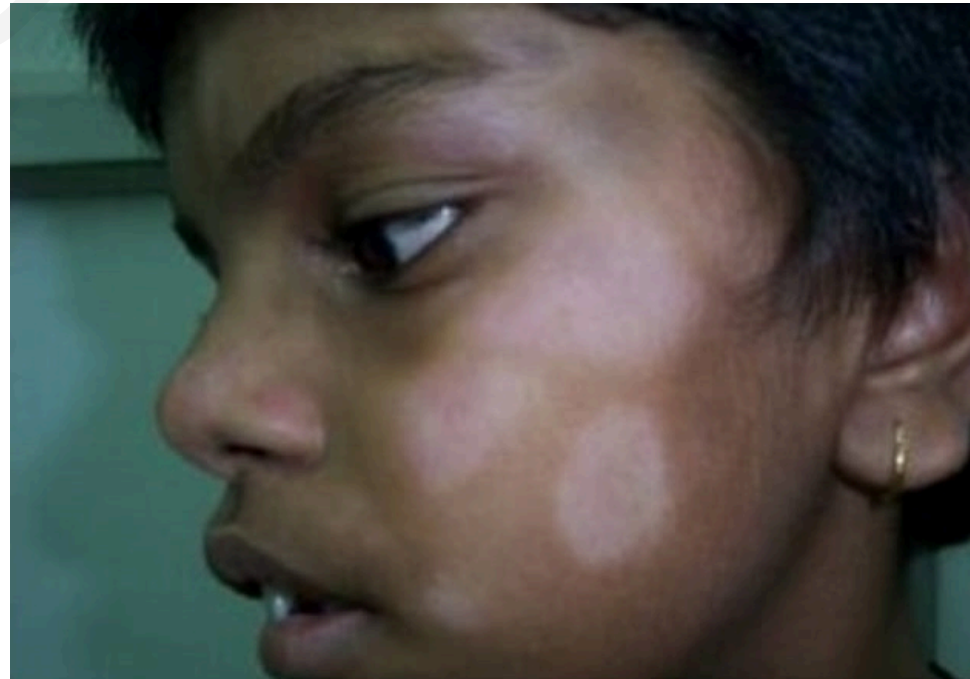1. Erythema multiforme.
2. Multiple target shaped nodules, well defined margin, no clear pattern of arrangement, distributed over the dorsum of the hand ...
3. Diascopy.

4.



Q3: A patient came with this lesion on his face, and he has itching on the flexor surface of his knees

1. What is the diagnosis?
2. Describe this lesion.
3. Mention one differential diagnosis.

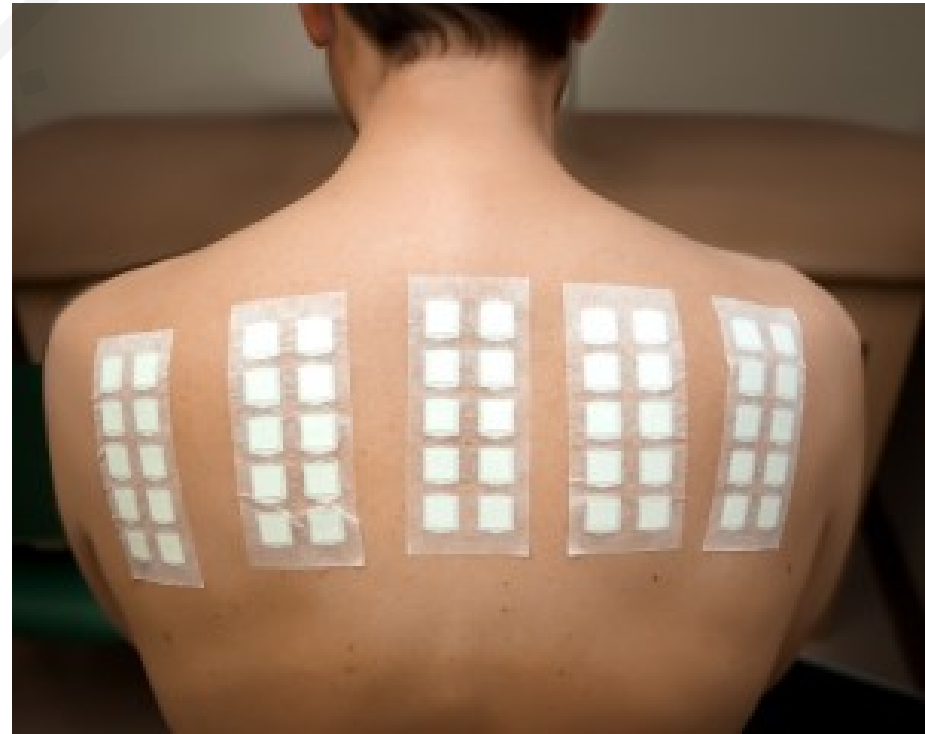

## Answer 3:

1. Pityriasis alba.
2. Multiple patches of hypopigmentation, well defined margin, no clear pattern of arrangement, distributed on the face and cheek.
3. Vitiligo.

# Q4:

1. What is this test?
2. What type of hypersensitivity does it test?
3. When do you read the test?

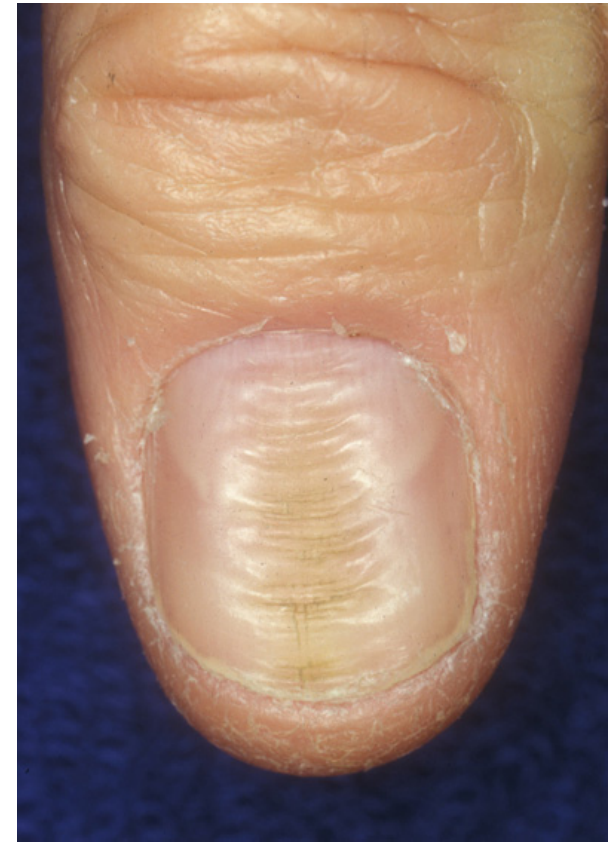

## Answer 4:

1. Patch test.
2. Type 4 hypersensitivity reaction.
3. Between 48-92 hours, on average the first reading is read after 3 days.

Q5:

1. What is the name of this sign?
2. Mention 2 diseases that cause nail pitting.



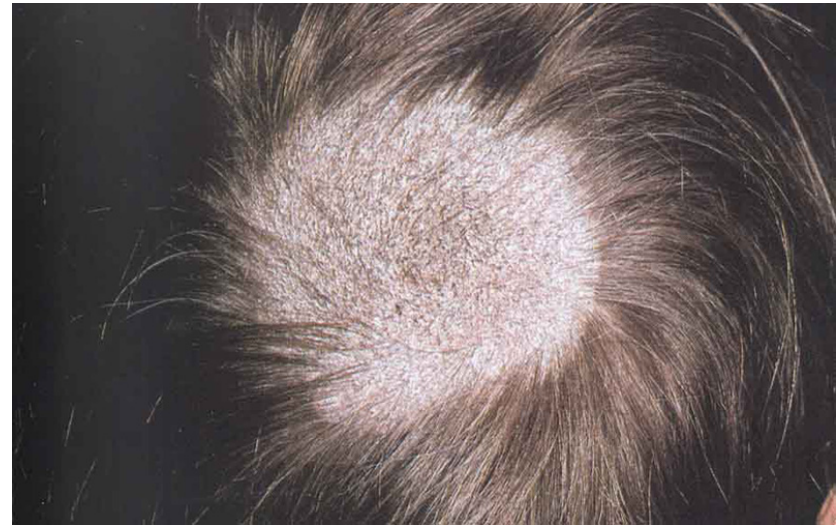

## Answer 5:

- Tic nail dystrophy.
- -Psoriasis -Tinea of the nail

Q6: A patient came to you with this presentation, he has a pet dog

1. What is the most likely diagnosis?
2. Mention 1 differential diagnosis.
3. Mention 2 clinical subtypes for this disease.
4. What is the drug of choice for this case?



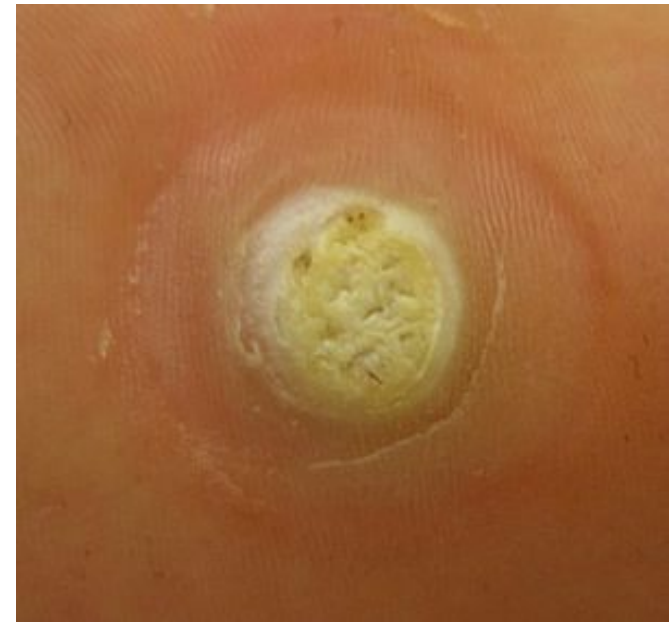## Answer 6:

1. Tinea capitis.
2. Scalp psoriasis (because it is scaly).
3. -Kerion -Favus
4. Griseofulvin

# Q7:

1. Describe this lesion.
2. Mention 3 differences between warts & corns.
3. Mention 2 lines of treatment for this case.
4. Do you recommend surgical excision? And why?

\*\*Not the same picture, in the exam it was clear that the wart is on the foot\*\*



# Answer 7:

1. Single white colored nodule that is scaly, well defined margin, distributed on the sole of the foot.

2.

Corns are concentrated only on the feet.	Warts can appear all over the body.
A corn is related to friction.	A wart is not related to friction.
Skin lines can appear on the corn	Warts are usually smooth and skin lines don't appear on them
A corn doesn't itch or bleed.	A wart can sometimes itch or bleed.

According to  
google

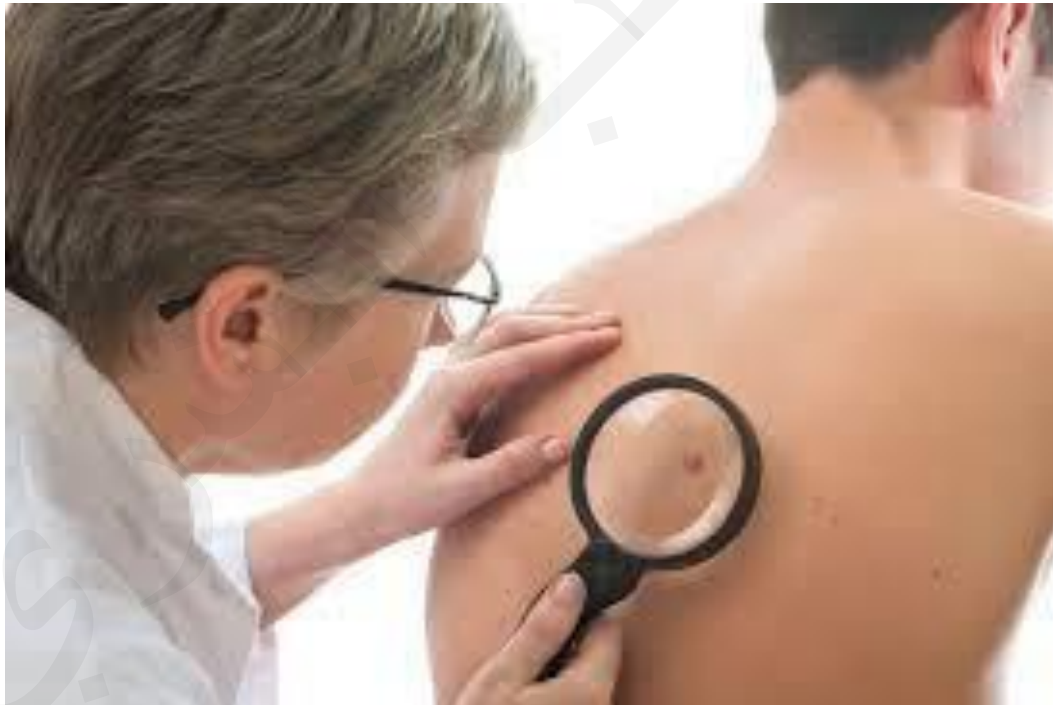3. -Topical salicylic acid or keratolytic -cryotherapy  
...etc
4. Surgical excision isn't recommended as it can lead to permanent scarring.

# Dermatology Mini Osce

## Group C

### Ihsan batch-2020

### 2018



# Dermatology Exam-Ihsan Batch

C1+C2

**THE ANSWERS ARE AFTER EACH QUESTION.**

# Q1

- 1- Define Burrows ,What is the causative organism and mention 2 sites where you can find them?
- 2- A women with hirsutism came to your clinic .. Mention 4 questions you want to ask in history (Relevant history)
- 3- Mention 3 infectious causes of Erythema nodosum.
- 4- Differentiate between urticaria and angioedema according to the (site , color , duration and associated symptoms )



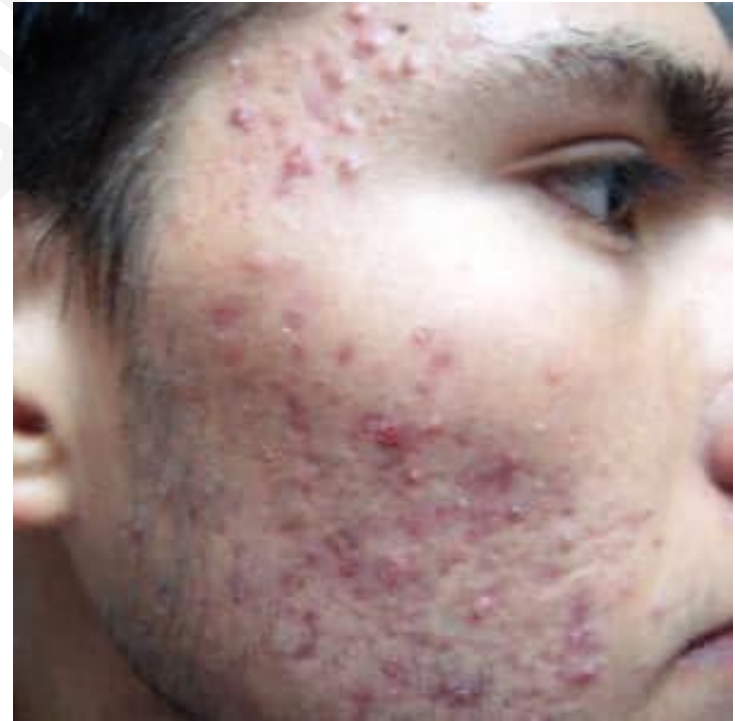# Answers

- 1- linear or curvilinear papule .Caused by Scabies mite /foung in interdigital spaces ,sides of the hand ,and on the flexural aspect of the wrist. Other sites include the nipples and genitals.
- 2- #onset and duration? #Menstrual cycle? #signs of virilization As acne/alopecia/ voice change ...? #Family Hx?
- 3- Strep ,TB , Leprosy , Brucellosis , EBV, Hep B, Mycoplasma
- 4- →

	Urticaria	Angioedema
Site	<ul style="list-style-type: none"> <li>• Anywhere in skin surface</li> <li>• Edema in the dermis</li> </ul>	<ul style="list-style-type: none"> <li>• Mostly occurs at junctions between skin and mucus membranes (peri-orbital/peri-oral)</li> <li>• Edema in subcutaneous tissue</li> </ul>
Color	Bright red /pink	Less red ,less demarcated
Duration	Resolve within 24h	Hours to days “ ..More than 24h” <b>Not sure :3</b>
Associated symptoms	Itching	May be associated with swelling of the tongue and laryngeal mucosa / Mild itching

## Q2

- 1- What is your Dx ?
- 2- Mention 3 subtypes
- 3- Mention 2 complications

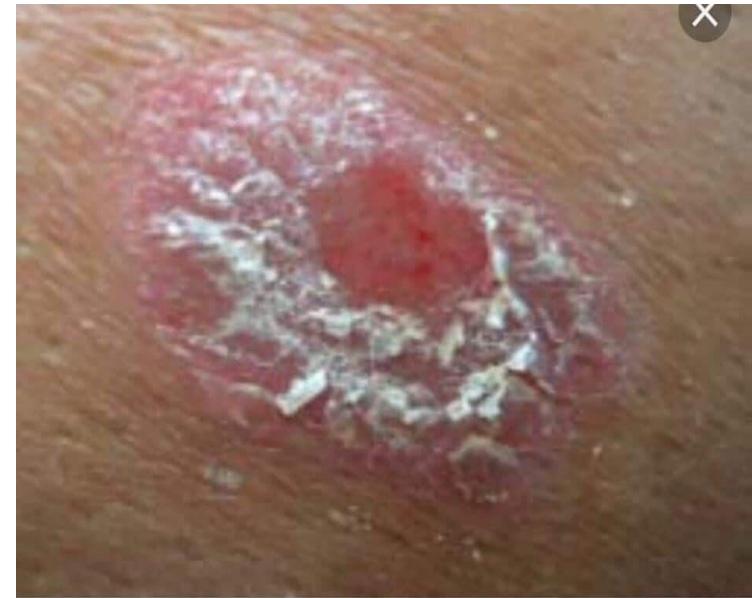
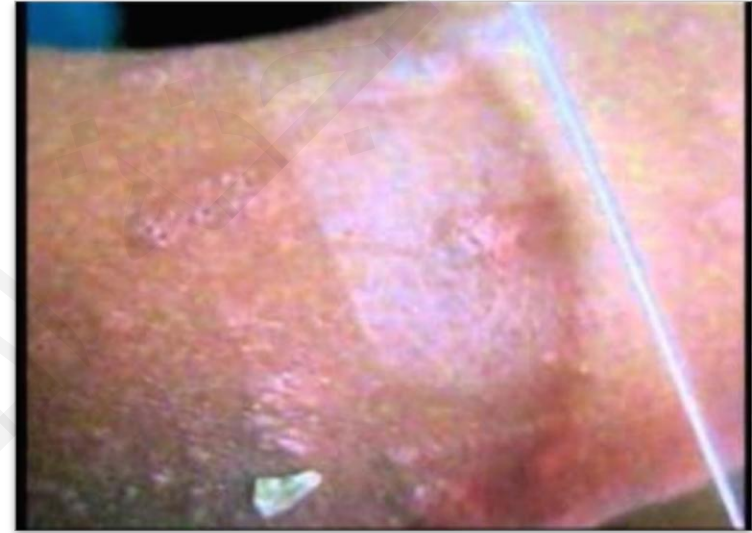
# Answer

- 1- Acne vulgaris
- 2- Neonatal acne/ infantile acne / late onset acne/Excoriated ...etc
- 3- Scars/ Post inflammatory hyperpigmentation / depression ...

# Q3

- This pt presented with this lesion with scales .. The dr scratch it and blood appears as in pic 2...
- 1- Name the sign ?
- 2- In which disease you can see it?
- 3- What is the pathogenesis behind this sign?

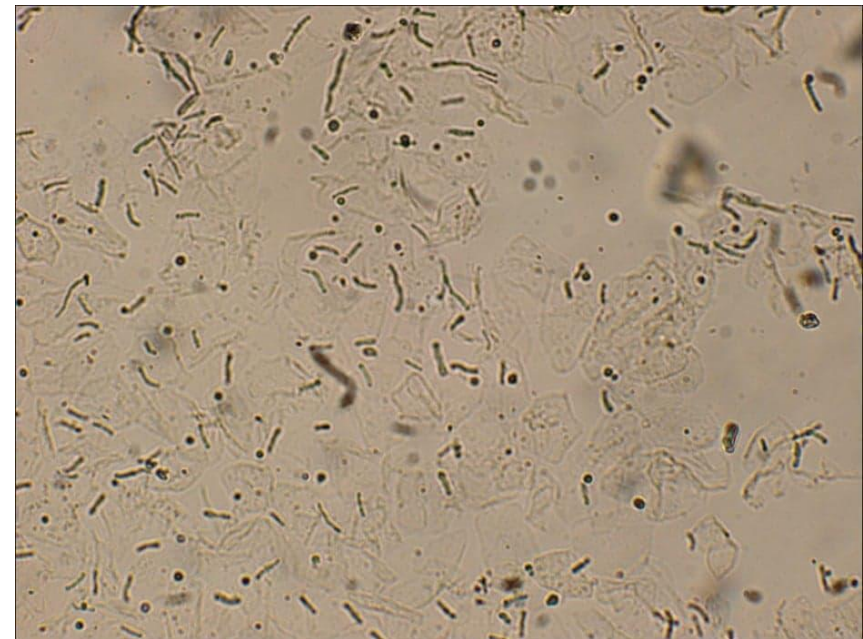
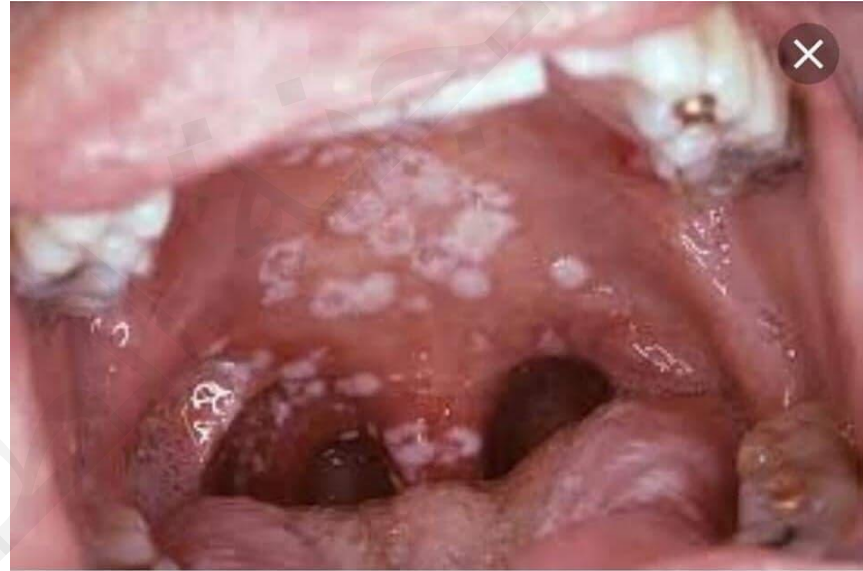

# Answer

- 1- Auspitz sign
- 2- Psoriasis
- 3- there's irregular thickening of the epidermis with thinning over dermal papillae with dilated and tortuous loops of capillaries in dermal papillae ,so when you scratch and remove the scale pinpoint bleeding is seen .

# Q4

- Pt presented with this adherent white plaques..
- 1- What is your diagnosis?
- 2- give other 2 Ddx
- 3- Mention a bed side test



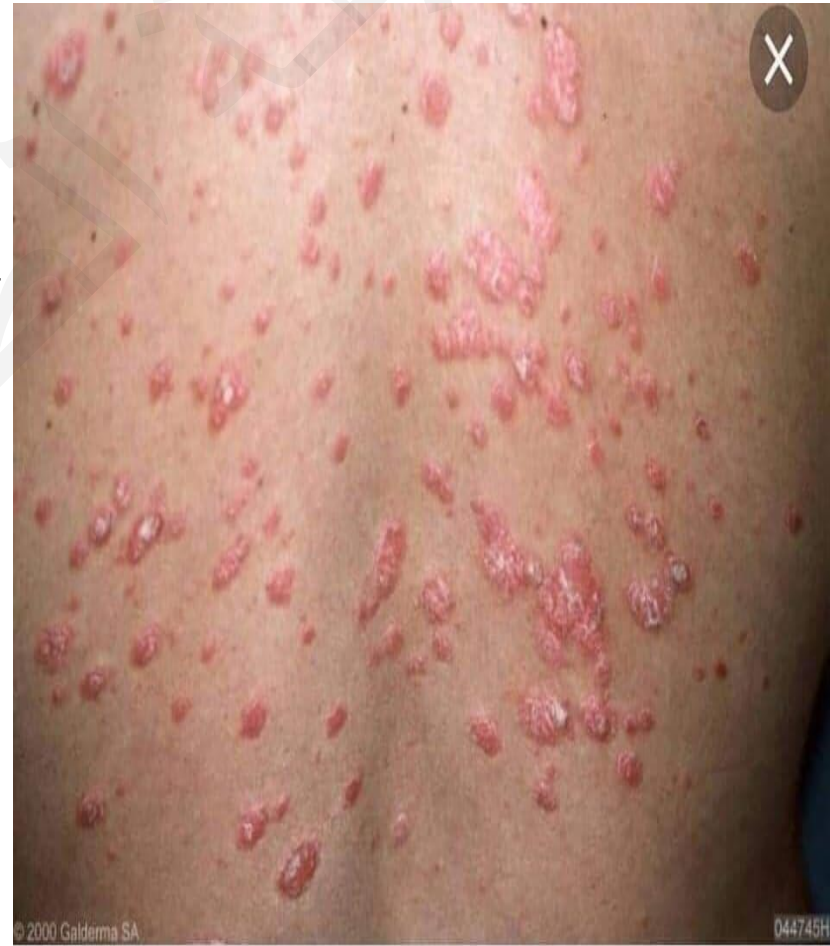# Answer

- 1- Oral candidiasis
- 2- Lichen planus/ Aphthous ulcer / Herpes Simplex virus infection ( From medscape .. I'm not sure what the dr wants)
- 3- KOH



# Q5

- Pt came to your clinic with this presentation after 'strep pharyngitis' infection , also his scalp is involved
- 1- Describe the lesion
- 2- What is the prognosis of this disease
- 3- Mention 2 local ttt

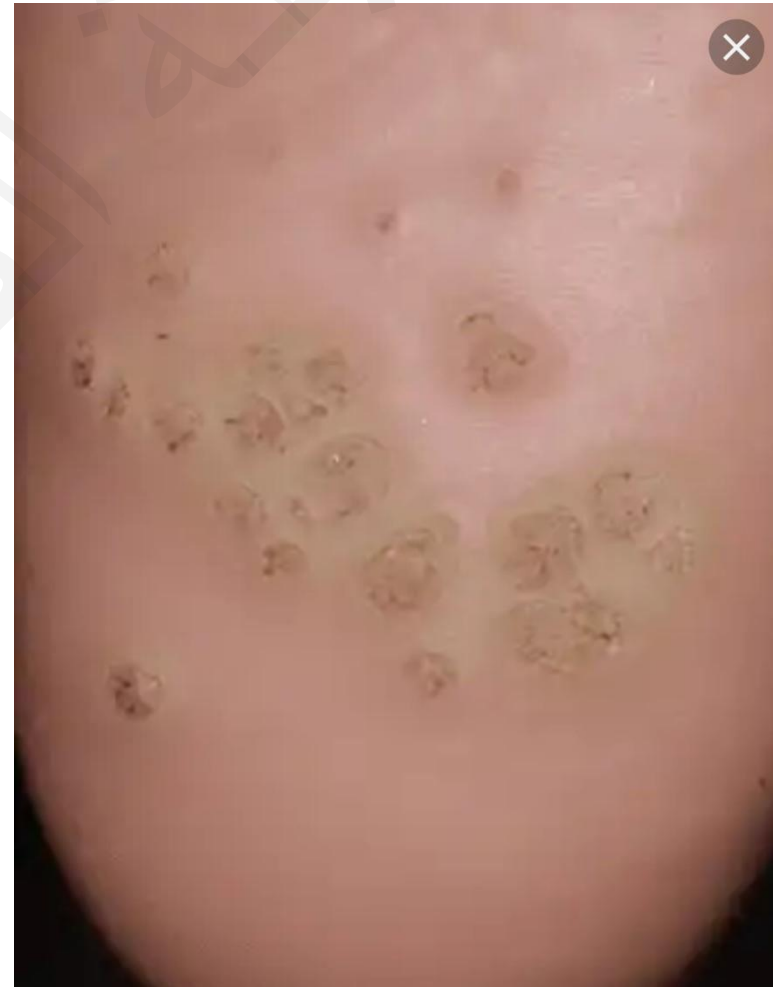

# Answer

- 1- Multiple papules and plaques , red to salmon pink in color with silver scales ,well-demarcated on his back , bilaterally .
- 2- I don't know what the dr really wants but we write the following : The rash clears in few months but plaque psoriasis may develop later on (Good Prognosis!!!)
- 3- Vit D analogues , topical retenoids , coal tar .

## Q6

- Pt presented with these painful lesions
- 1- What is your diagnosis?
- 2- Describe the lesion
- 3- Give one differential diagnosis
- 4- mention 2 lines of Physical management

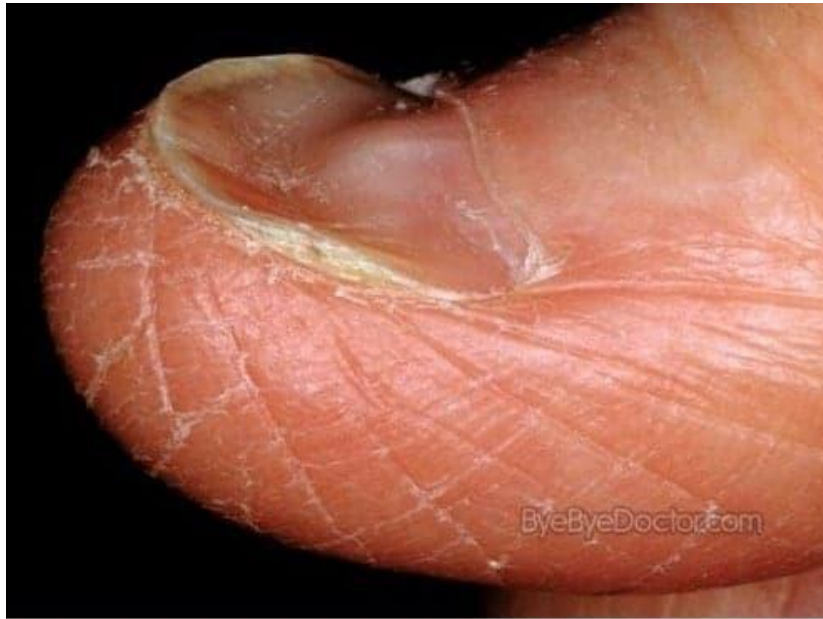


# Answer

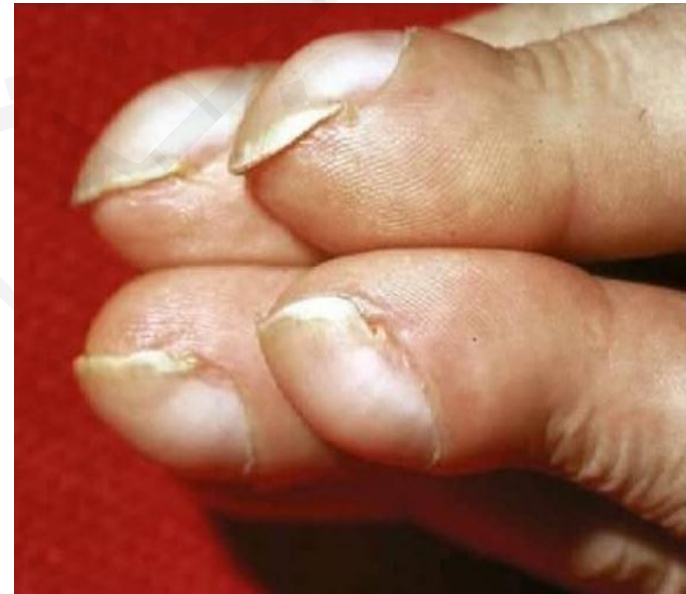- 1- Plantar warts
- 2- Multiple elevated papules ,rough surface (vurrucus) , scaly , brown in color ,well-defined, with dark pinpoint
- 3- Plantar corns
- 4- Cryotherapy /Electrocautary \*Not sure\*

Q7 • What is your spot diagnosis ?

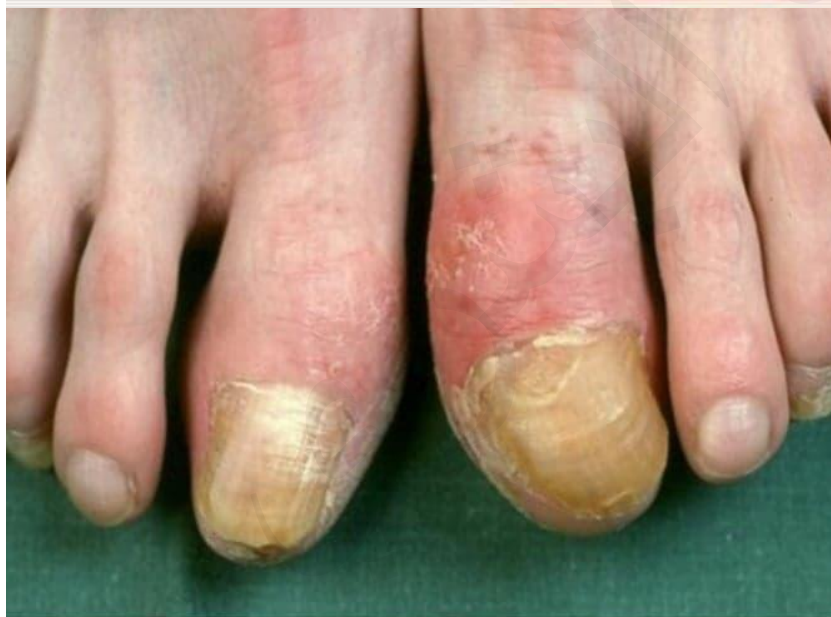A



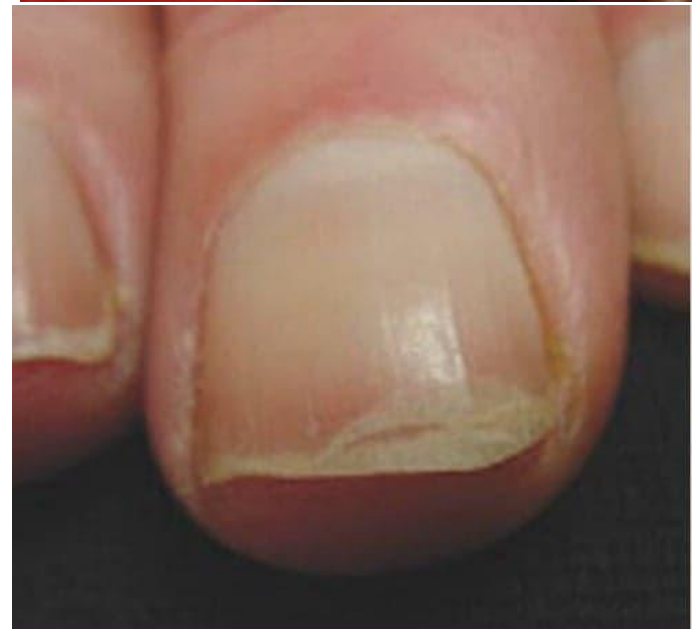B



C



D



# Answer

- A- Koilonychia
- B- Clubbing
- C- Onychogryphosis
- D- lamellar splitting

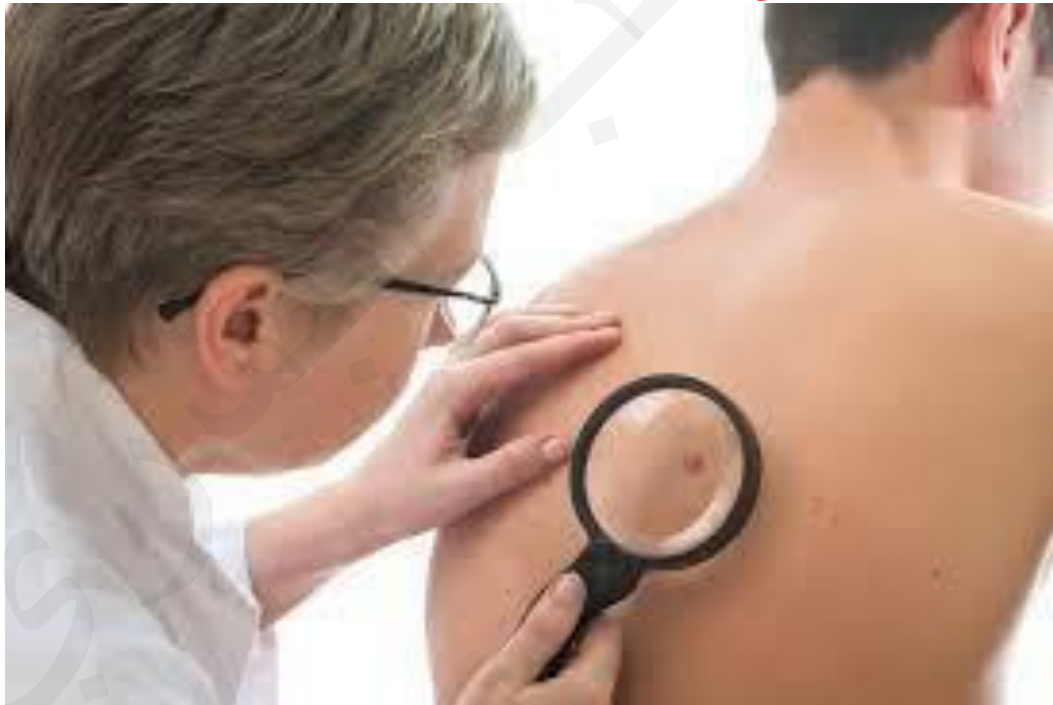# Dermatology Mini Osce

## Groups C7-C8

### Ihsan batch-2020

### 15-11-2018

**THE ANSWERS ARE AFTER EACH QUESTION.**



# Q1- written question

1. Define the vesicle
2. Write three complications of *Seborrhoeic eczema*
3. *Write four questions you ask for patient comes to clinic complain of Rash (Dermatological history)*
4. *Write four endocrine disorders leads to hyperpigmentation*
5. *Write three lines of treatment for pitted keratolysis*



# Answer

1. Vesicle: Is a circumscribed elevation of skin, less than 0.5 cm in diameter and containing fluid.
2. A) Associated with furunculosis  
B) In intertriginous type: superadded Candida infection may occur  
C) Bacterial colonization is common in all types of eczema and overt infection is common in seborrhoic.
3. Duration/site at onset/details of spread/ progression and pattern is it persistent or waxing and waning/precipitating factors/previous similar attacks/symptomatic or not (itching-numbness-pain-fever)/FHx/Medical Hx/ Aggravated and relieving factors ...etc.

# Answer

4. Addison's/Cushing's/pregnancy/Renal Failure.

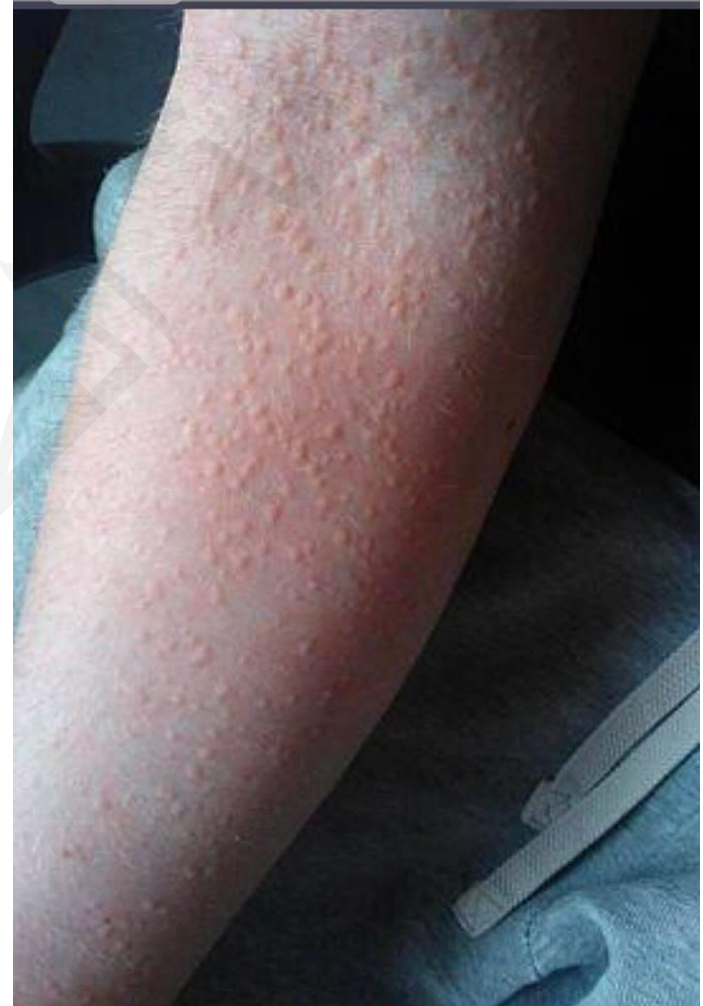5. Keep the foot dry and Occlusive footwear should be replaced by sandals and cotton socks if possible

Fusidic acid or mupirocin ointment is usually effective, and antiperspirants can also help.

# Q2

- 30 years old pt complain of rash for 2 months ,complaining of these lesions appear on trunk and extrimities for 2 hours after excessive exercise, embarrassment ,hot shower

- 1) what's your DX?
- 2) what the pathogenesis of this condition?
- 3) Describe this pic



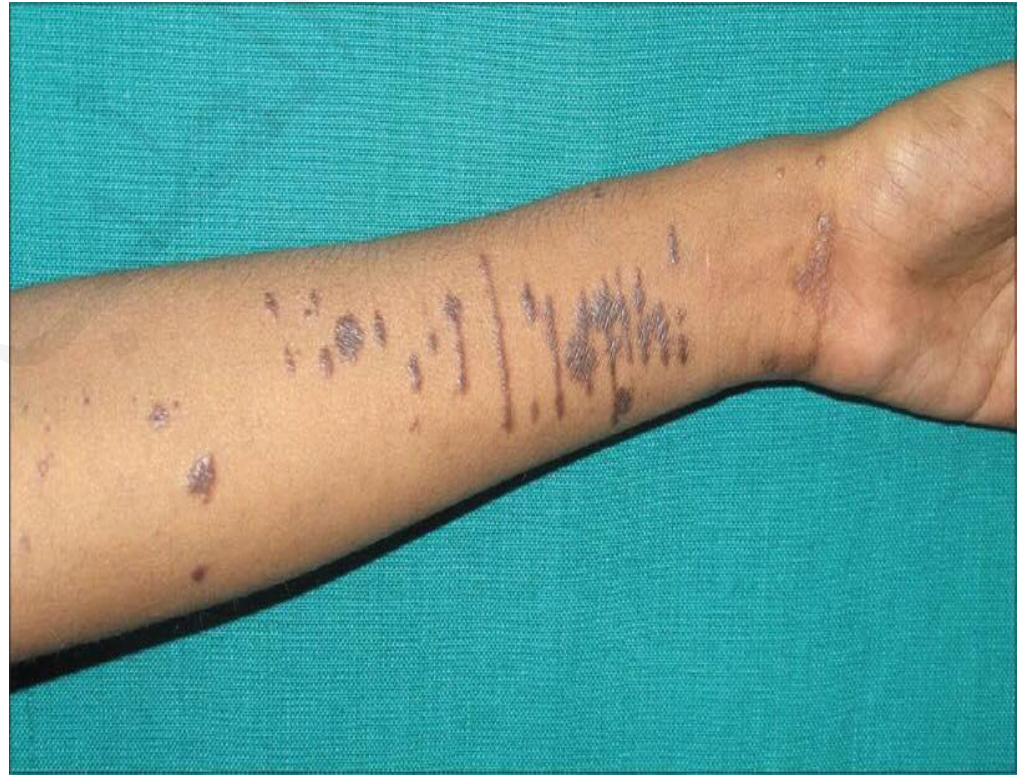# Answer

- 1) Cholinergic urticaria
- 2) Sweating elicits this characteristic response. The vessels overreact to Acetylcholine liberated from sympathetic nerves in skin
- 3) Pink ,itchy, multiple, small 2-5 mm ,transient follicular papules or macules ,blanchable, non-scaly, cover most of the upper extremity skin surface. (Add what you see)

# Q3

Pt complain of itchy flat-topped papule on volar aspect of his hand

1. What is DX?
2. Is it infectious or not?
3. what is the cause of these linear lesions on his hand?



# Answer

- 1) Lichen planus (Kobner phenomenon)
- 2) Non-infectious
- 3) Due to kobner phenomenon -These lesions of the disease appear on the site of scratch, trauma, scars or wounds .

# Q4

1. What is this device ?
2. what the temperature used in this device?
3. write 2 side effects



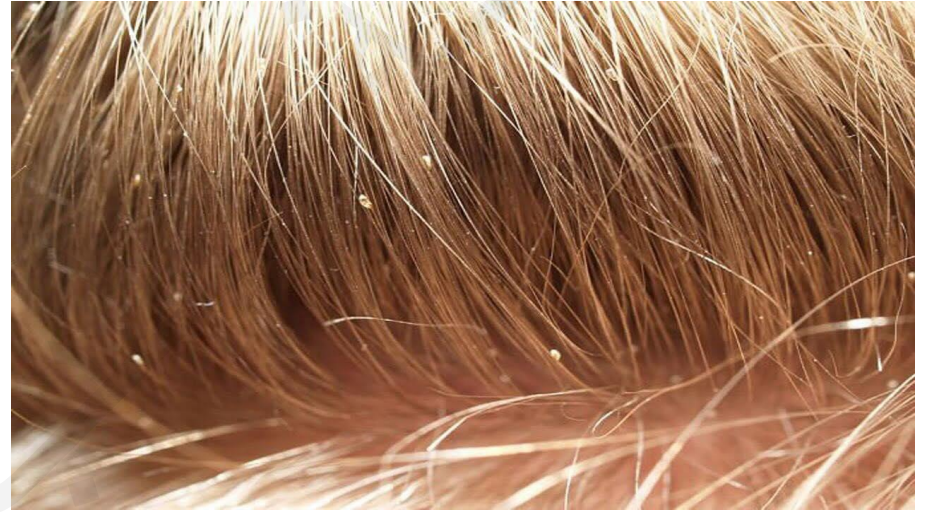# Answer

1. Cryotherapy with liquid nitrogen
2. -196
3. Painful and possible blistering after treatment/ causes hypopigmentation-in deeply pigmented individuals it destroys pigment cells, leaving whiter skin at the sites treated/ when treating warts on fingers → digital nerve damage can follow over-enthusiastic freezing.



# Q5

8 yrs old complaining of itchy scalp for 2 months that become worse at night



1. Your DX ?
2. mention one bedside test
3. mention 2 lines of treatment

# Answer

1. head lice
2. By seeing the live nits firmly stuck to proximal hair shaft –unilateral attachment

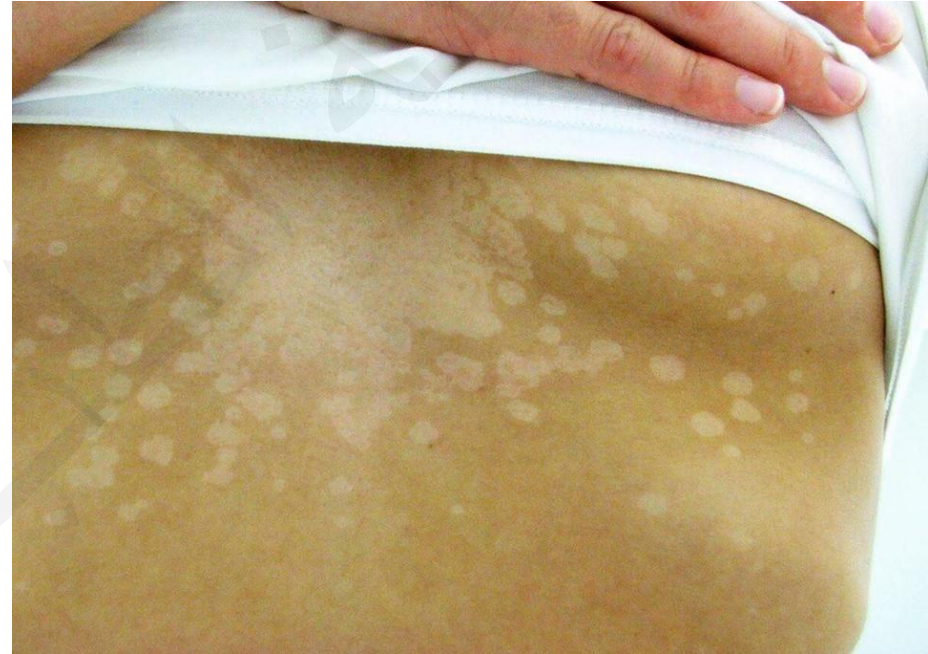And you can examine the nit under the microscope

1. A) Malathion B) Demiticone C) Permethrin

# Q6

Pt come with this picture ,  
complaining of this  
after swimming

1. Describe this picture
2. Your DX?
3. what the cause of  
these lesions
4. 2 lines of treatment

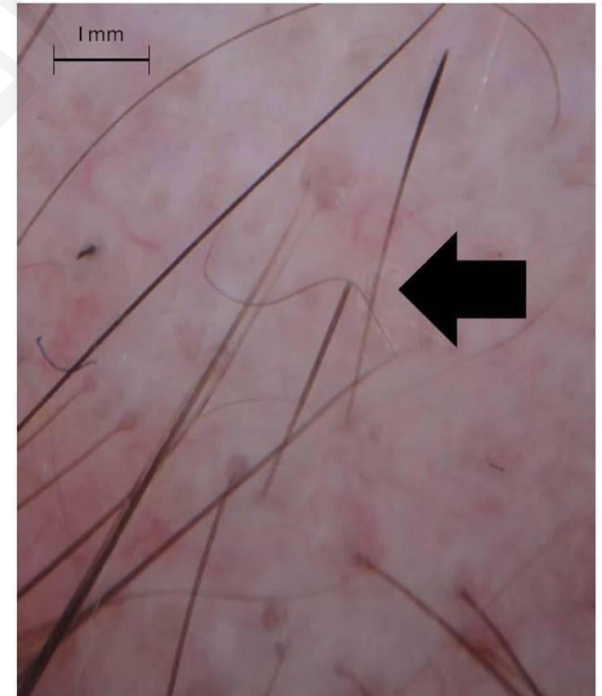


# Answer

1. Depigmented white (paler than the surrounding skin after exposure to sunlight) , well defined macules and patches ,scaly, on the upper trunk
2. Pityriasis versicolor
3. caused by commensal yeasts (*Pityrosporum orbiculare*) - Carboxylic acids released by the organisms inhibit the increase in pigment production by melanocytes that occurs normally after exposure to sunlight
4. Topical imidazol / Selenium sulphide /a shampoo containing ketoconazol.. For widespread : systemic itraconazole.

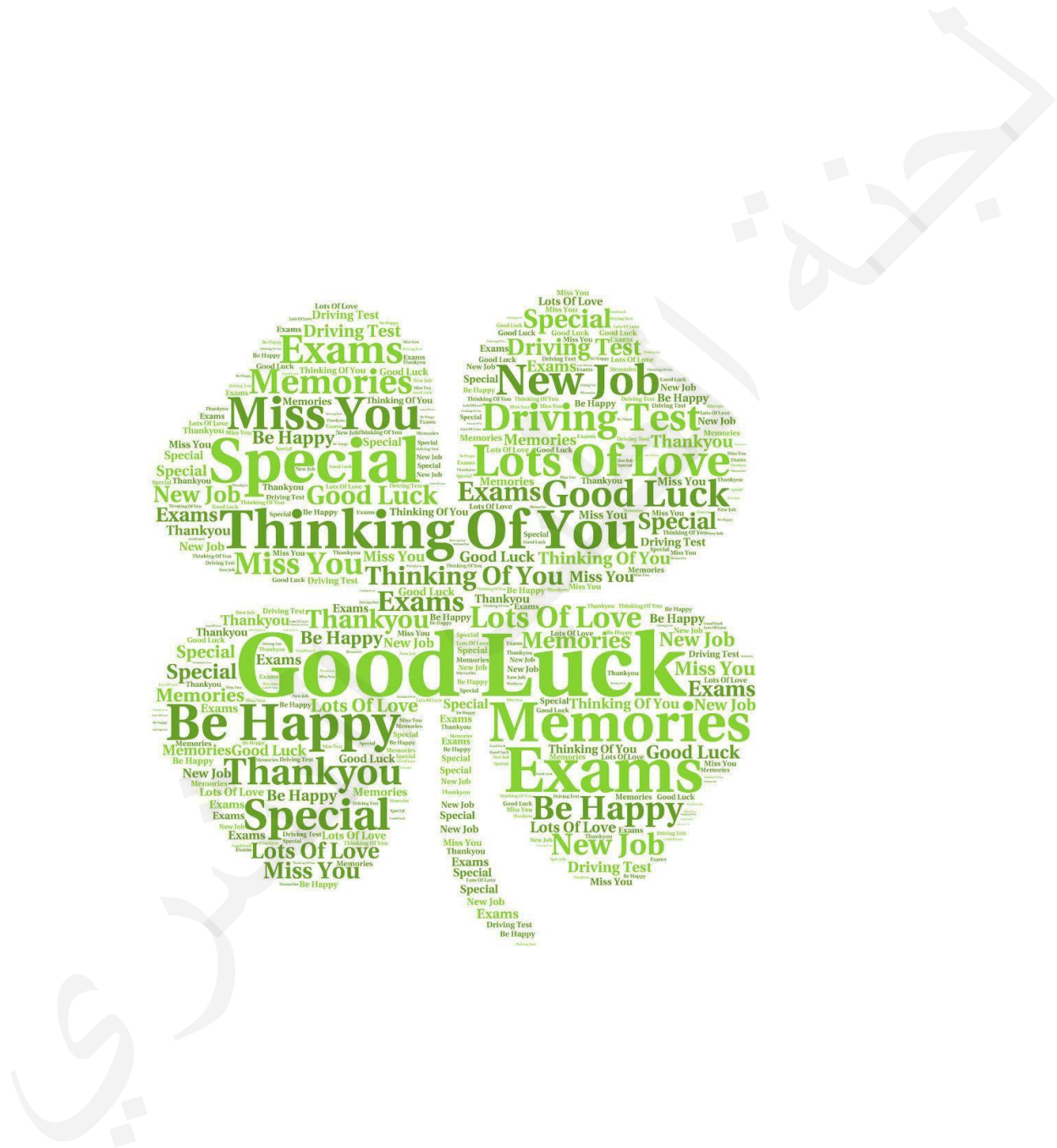# Q7

1. what is the name of this sign showed in this picture ?
2. name the disease seen this sign on?



# Answer

1. Exclamation mark
2. Alopecia areata



# Dermatology Exam



C3 & C4

13 - 12 - 2018

**THE ANSWERS ARE AT THE END**



# The Questions

# Q1



A- Define **crust** ? And mention one disease that can be seen it in?

B- Give **four** clinical differences between urticaria and erythema multiforme?

C- Direct Immunofluorescent test?

D- Mention **four** causes of non scaly alopecia?

## Q2

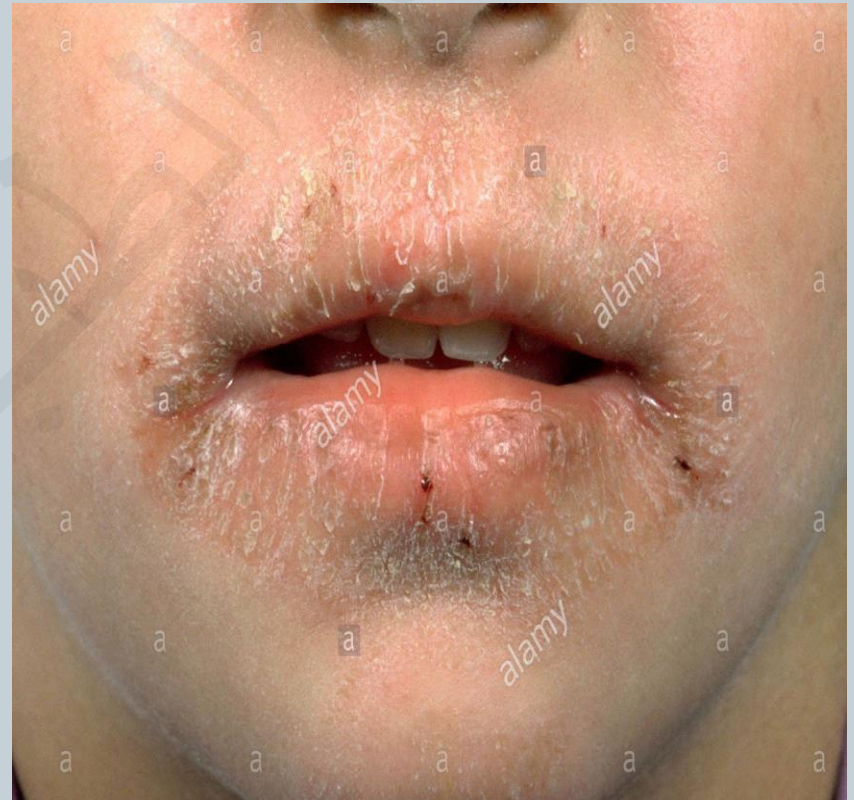

A child with a history of lip licking developed an itching around his lips :

A- What's your diagnoses?

B- Give **one** differential diagnoses?

C- What's the management?



 alamy stock photo

A78PTR  
www.alamy.com

# Q3



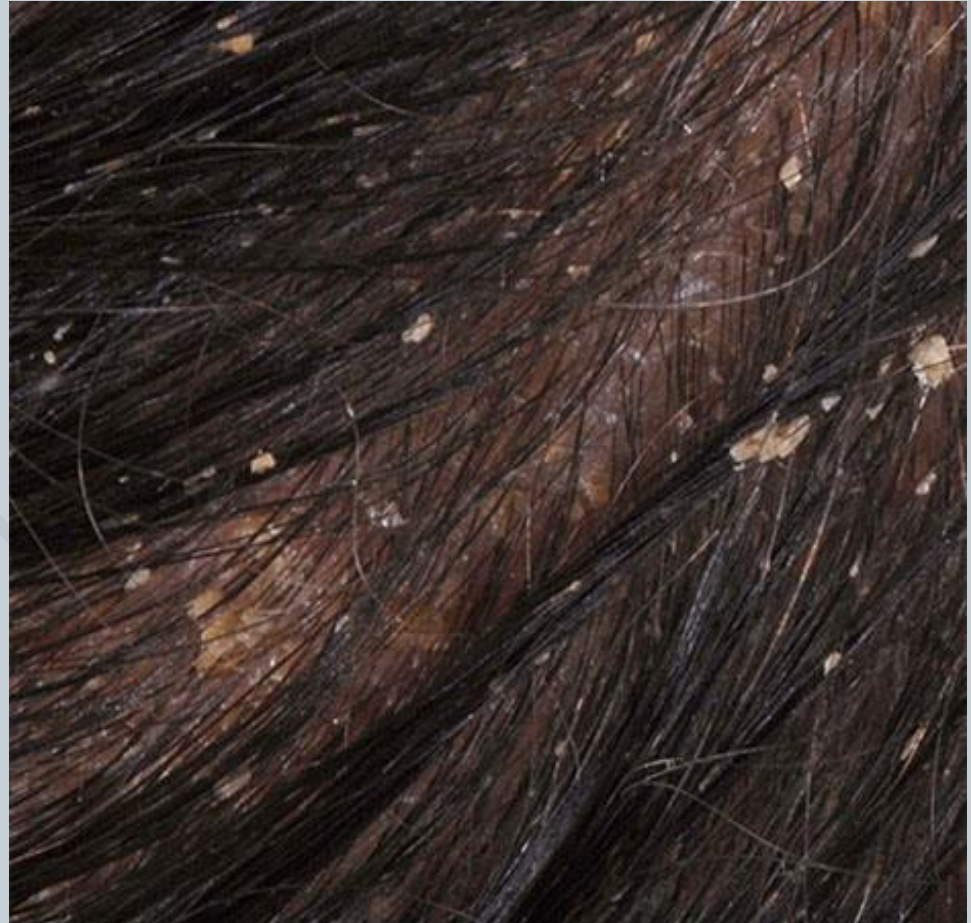This patient complain of this yellowish scales and a rash on his chest :

A- What's your diagnoses?

B- What's the name of the **chest** rash?

C- Give **one** differential diagnoses?

D- Give **2 lines** of treatment?



© MAYO FOUNDATION FOR MEDICAL EDUCATION AND RESEARCH. ALL RIGHTS RESERVED.

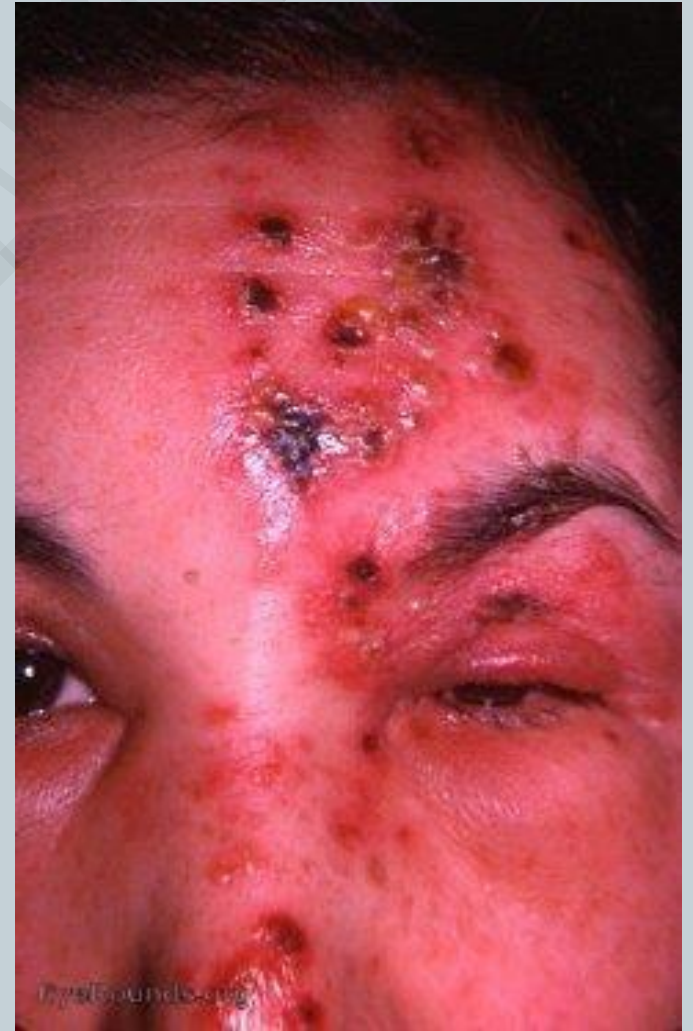# Q4



A- Describe the rash?

B- what's the most **fatal** complication of this condition?

C- What's your management?





# Q5

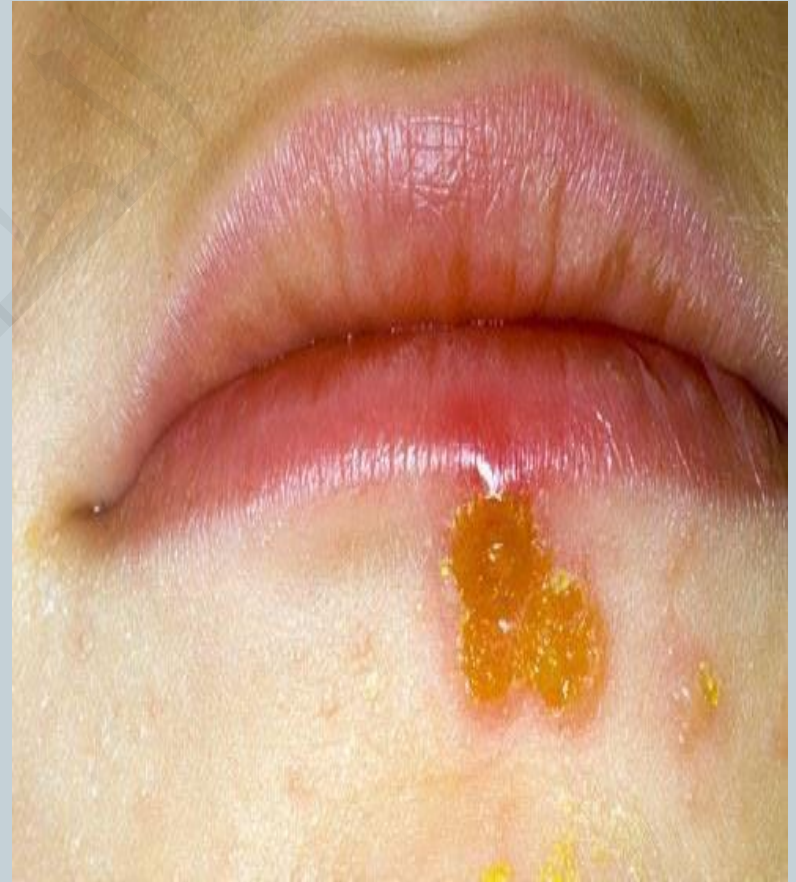

A 5 y/o child developed this lesion :

A- What's your diagnoses?

B- What's the causal **microorganism**?

C- Mention one **topical** treatment?



# Q6

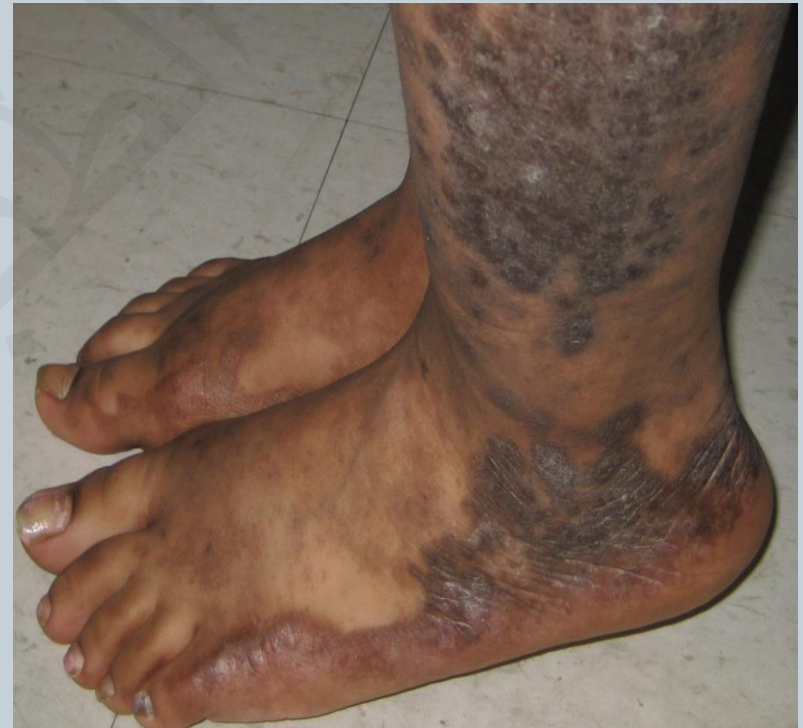

This patient develop a violaceous intensely itchy lesions on his wrists and legs :

A- Describe?

B- Mention **3 nail** abnormalities you can see with this disease?

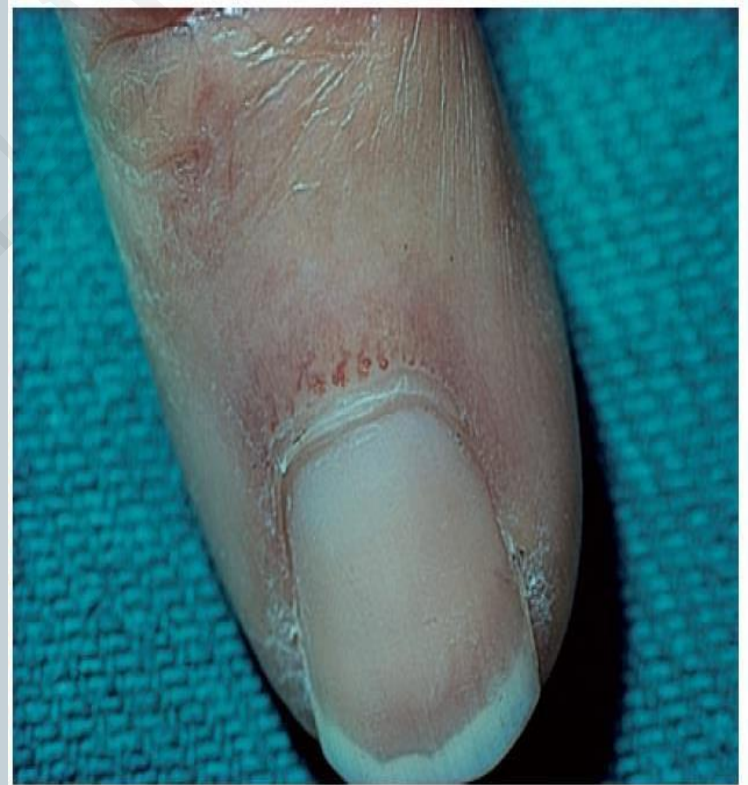C- What's the treatment?



# Q7



□ Name **2 diseases** you can see this abnormality with?

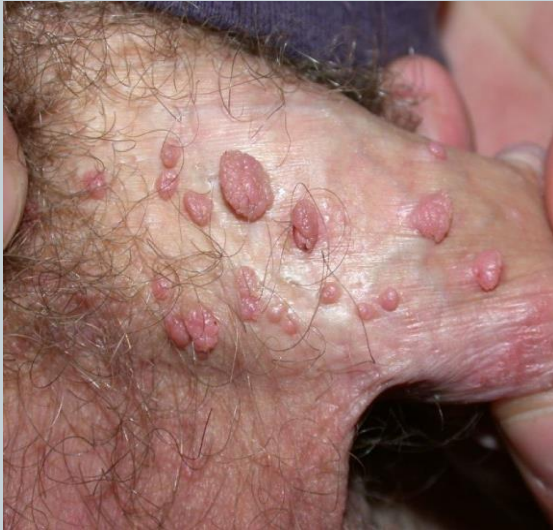



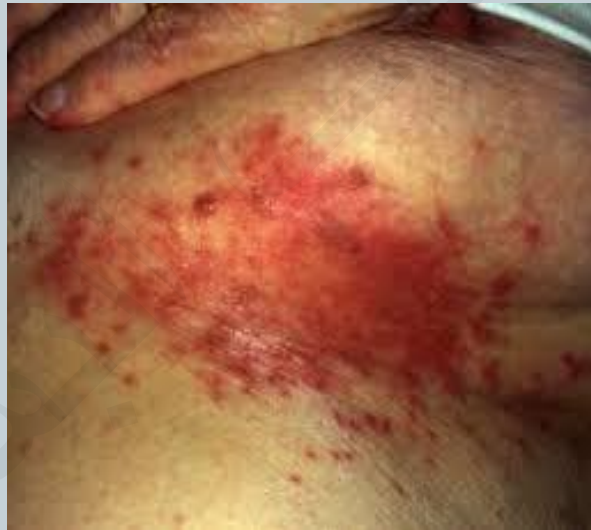# Q8



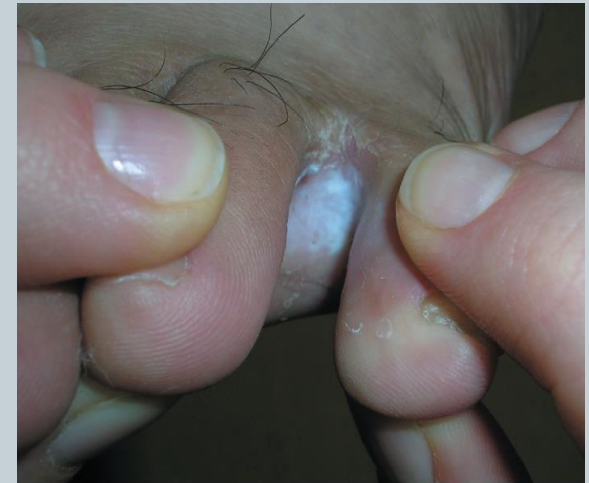□ What's the **TYPE** of the infection in the followings :



A



B



C

Source: Usatine RP, Smith MA, Mayeaux EJ, Chumley HS: The Color Atlas of Family Medicine, Second Edition: www.accessmedicine.com  
Copyright © The McGraw-Hill Companies, Inc. All rights reserved.

# The Answers

# Q1



A- Crust may look like a scale, but is composed of dried blood or tissue fluid that can be seen in Impetigo, Shingles.

B-

TABLE 1.

## Differences between Urticaria Multiforme and Erythema Multiforme

Criteria	Urticaria Multiforme	Erythema Multiforme
Morphology	Annular wheals with central pallor or ecchymosis Duration of wheals <24 hours Often angioedema on face and extremities	Erythematous papules, target lesions Eventually central necrosis or vesicles Duration >7 days
Location	Universal	Palms and soles
Urticarial dermographism	Yes	No
Mucosal involvement	No, eventually mild edema	Eventually erosions
Symptoms	Pruritus	Burning, mild pruritus
Triggers	Infections, medicine, foods	Infections, herpes
Treatment	Antihistamines	Topical steroid ointments, systemic steroids with spread lesions

# Q1 (Cont.)



C- “Direct immunofluorescence Ultraviolet source detects antibodies in a patient’s skin. Here immunoglobulin G (IgG) antibodies are detected by staining with a fluorescent dye attached to antihuman IgG.” .... FROM THE BOOK.

D- Alopecia Areata, Androgenic Alopecia, Traction Alopecia and Ringworm Infections.

## Q2



A- Contact irritant dermatitis.

B- Allergic irritant dermatitis, Atopic eczema.

C- Avoidance, topical steroids and emollients.

# Q3



A- Seborrhoiec eczema

B- Seborrhoeic folliculitis or Malassezia folliculitis

C- Scabies (NOT SURE)

D- Topical Imidazole, Li preparation, Salicylic acid.

# Q4



A- erythema and grouped, sometimes blood-filled, vesicles scattered over a dermatome. The clear vesicles quickly become purulent, and over the space of a few days burst and crust. Scabs usually separate in 2–3 weeks, sometimes leaving depressed depigmented scars.

B- Dunno the exact answer 😊

C- Systemic Antiviral (Aciclovir, Famciclovir, Valaciclovir)

# Q5



A- Impetigo.

B- Staphylococcus Aureus.

C- Fusidic Acid, Neomycin or Bacitracin.



# Q6



A- 5 P's + Scaly and Symmetrical.

B- Pterygium, fine grooves, destruction of the nail bed.

C- Topical steroids, Antihistamines, Oral cyclosporine  
... etc.

Q7



Systemic Lupus Erythromatosus, Sarcoidosis.

# Q8

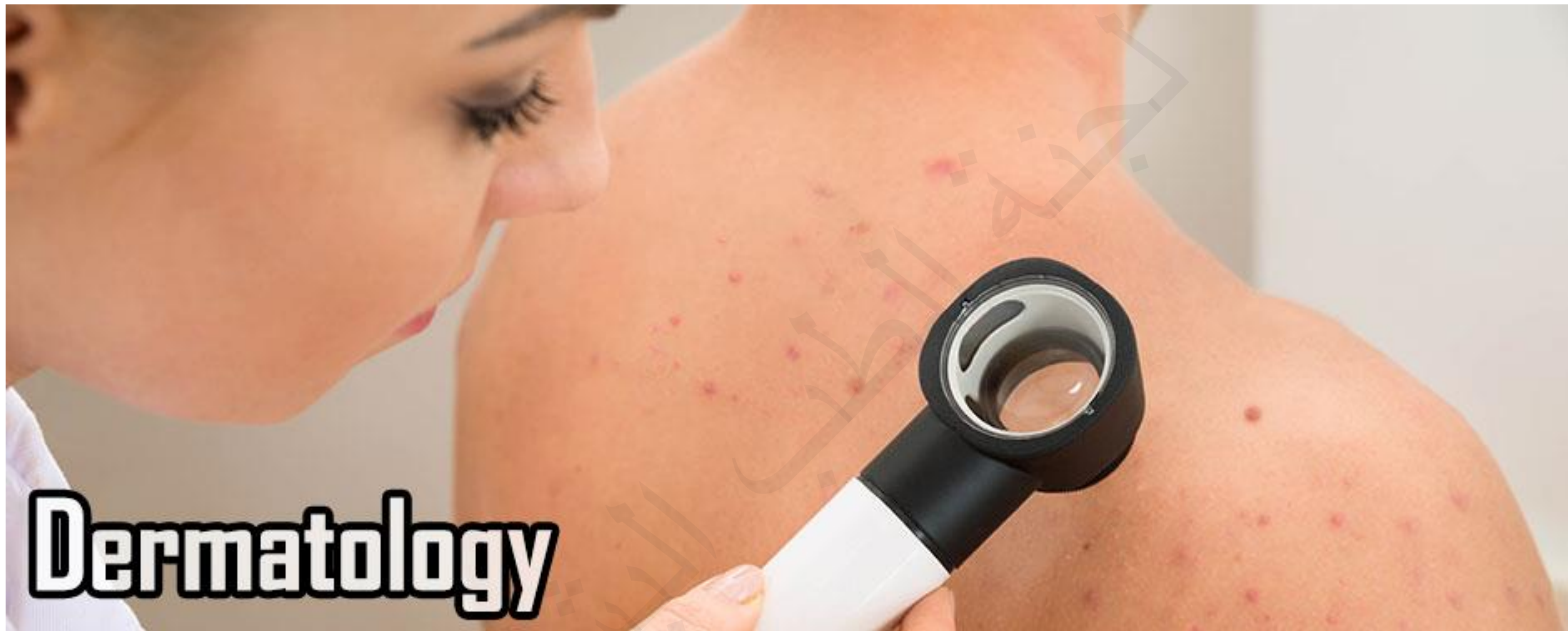

A- Anogenital Warts. (Caused by HPV 6,11,16,18)

B- Candidiasis. (groin)

C- Tinea Pedis (Interdigital Scaling)

Good Luck 😊



Dermatology mini osce- Group D –Ihsan batch 2018

6/9/2018

Question1:

A) Define Koebner phenomenon, and Mention 2 skin disorders can be associated with it?

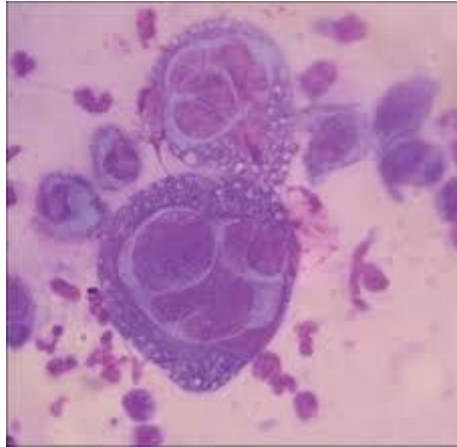
B) Mention 2 skin diseases can be treated with Acitretin?

C) 2 treatment line of chronic Paronychia?

**Question2:**

**Name the tool/ tests that appear in each picture:**

**A)**



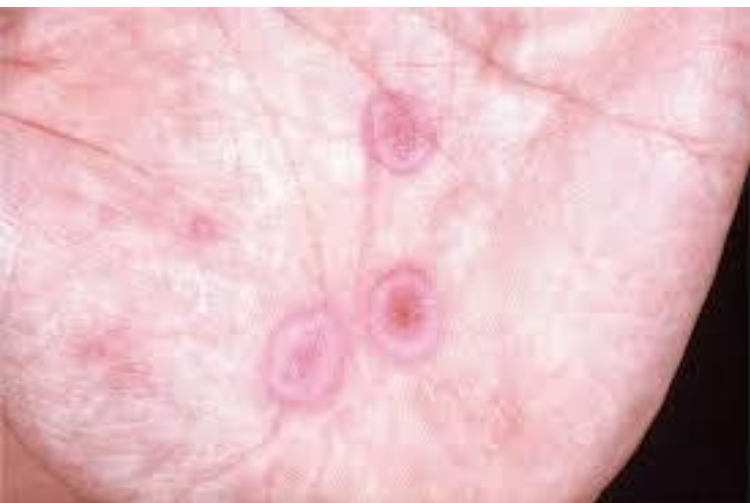**B) Similar pic**



**C)**

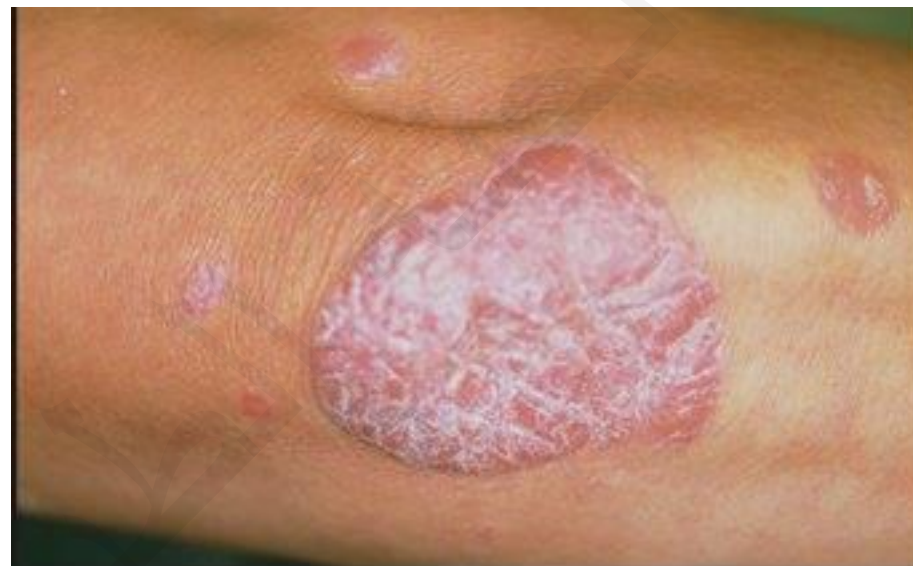

**Question3:**



- 1) What is the name of this lesion?**
- 2) Diagnosis?**
- 3) Write other distribution site of this lesion?**

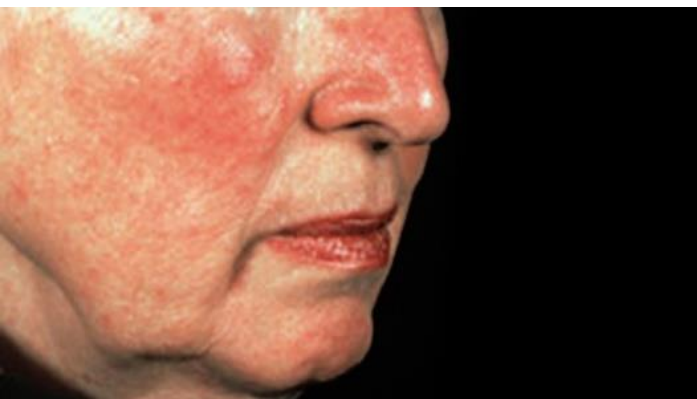**Question4: similar pic**



- 1) Describe the lesion?**
- 2) What is your diagnosis?**
- 3) Mention other sites you will examine also?**



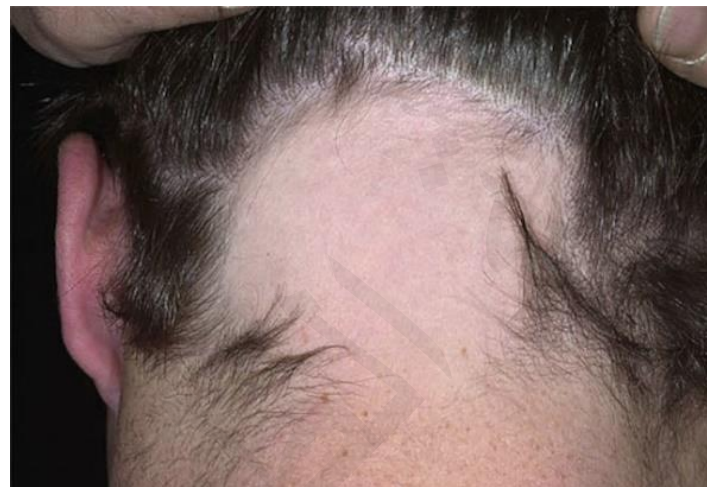**Question5:**



- 1) What is your diagnosis?
- 2) Mention 2 complication of this disease?
- 3) Mention 2 topical treatment can be used?
- 4) if this patient has also a joint pain and pleuritic (pain /effusion)\*\*, what is your next step ?

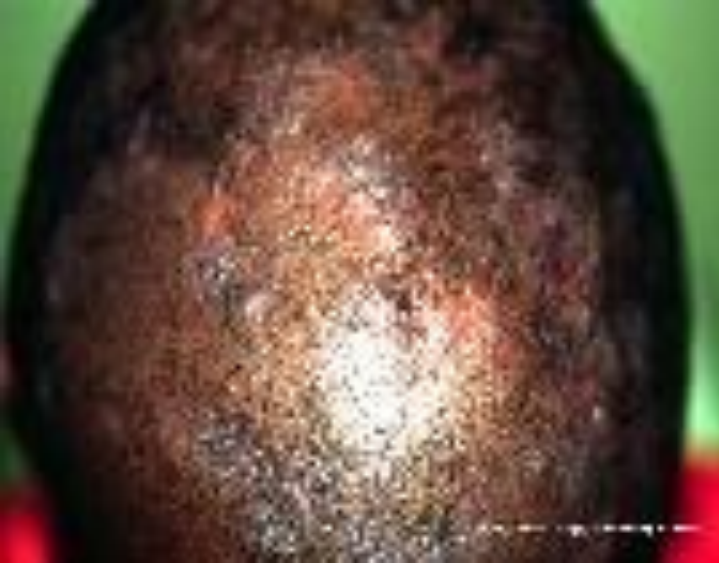**Question 6:**

30 years old patient complain a hair loss within six month :



- 1) Describe the lesion?
- 2) Diagnosis?
- 3) Treatment?
- 4) Good or bad prognosis and why?

### Question 7:



- 1) Diagnosis?
- 2) Treatment?
- 3) Appearance on wood examination?

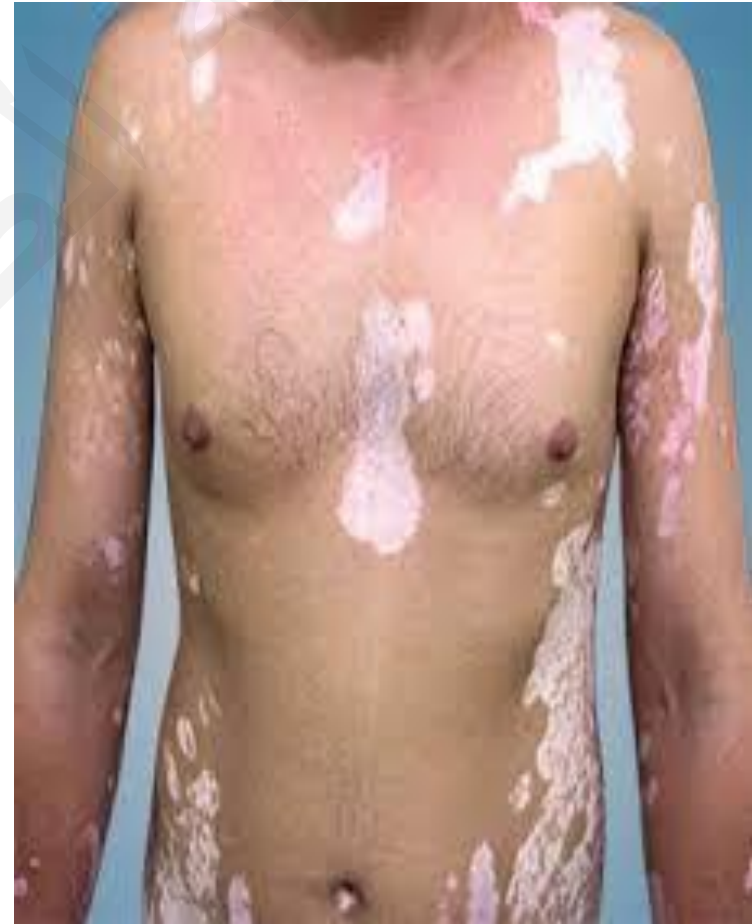D7&D8  
Dermatology miniosce exam  
20/9/2018

Q1:

- 1. Define parakeratosis?
- 2. mention two life long complication of chronic psoriatic plaque ?
- 3. mention two underlying causes of localized hypertrichosis?

Q2:

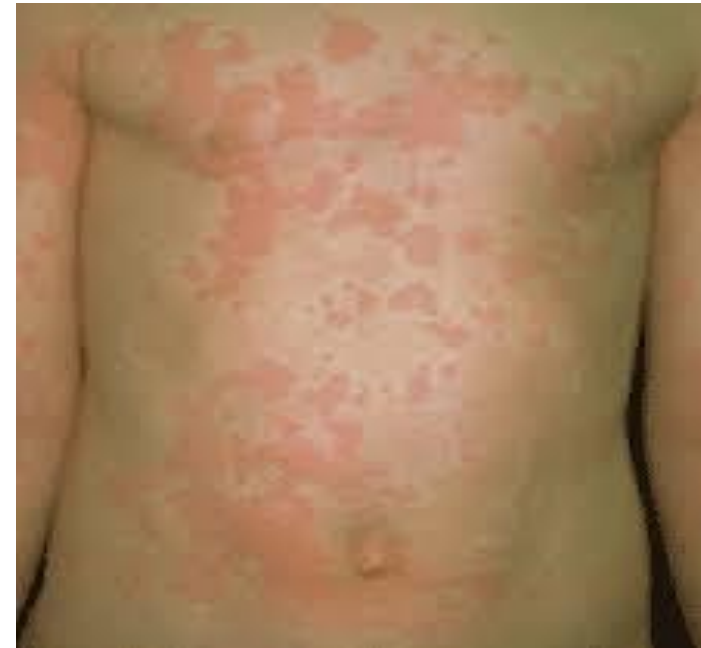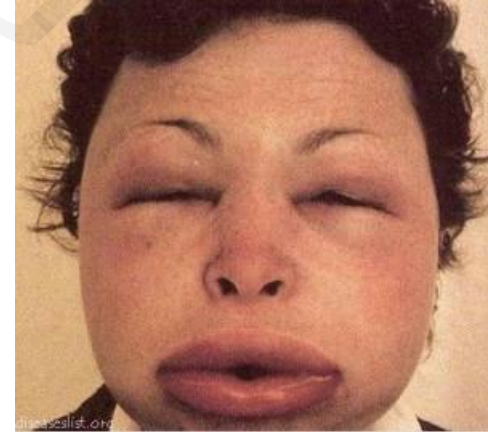- Her mother has hashimoto thyroiditis
1. What is the diagnosis?
  2. Describe
  3. Mention two tests ?
  4. On woods light ,what will appear?



Q3:

- 1.What is the diagnosis?  
2.Describe -the second picture -?

3.If the pt develop loss of consciousness and dyspnea ,what you will do?



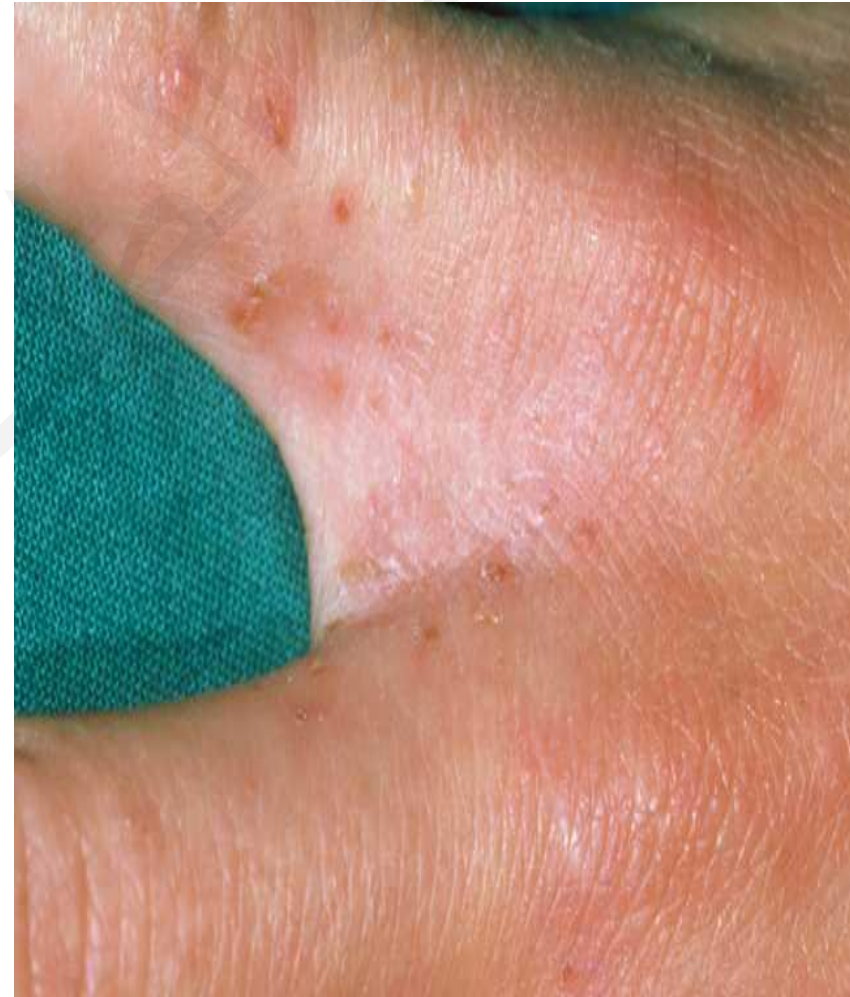# Q4:

- Pt has itchiness that distrub his sleep

1.What is the diagnosis ? 2.What is the pathogenesis of this disease?

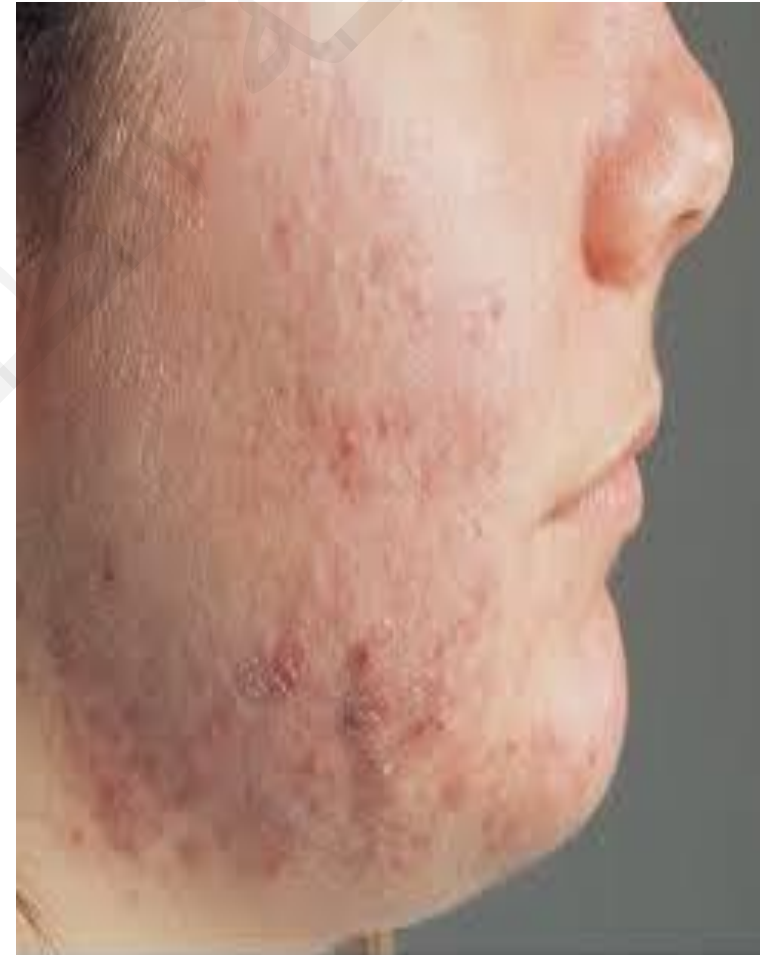3.What is the bedside test to confirm diagnosis?

4.mention 2 lines of treatment for this disease?



# Q5:

- 1.define acne?  
2.Mention two points of the pathogenesis of acne?  
3.What is the treatment of severe acne ?



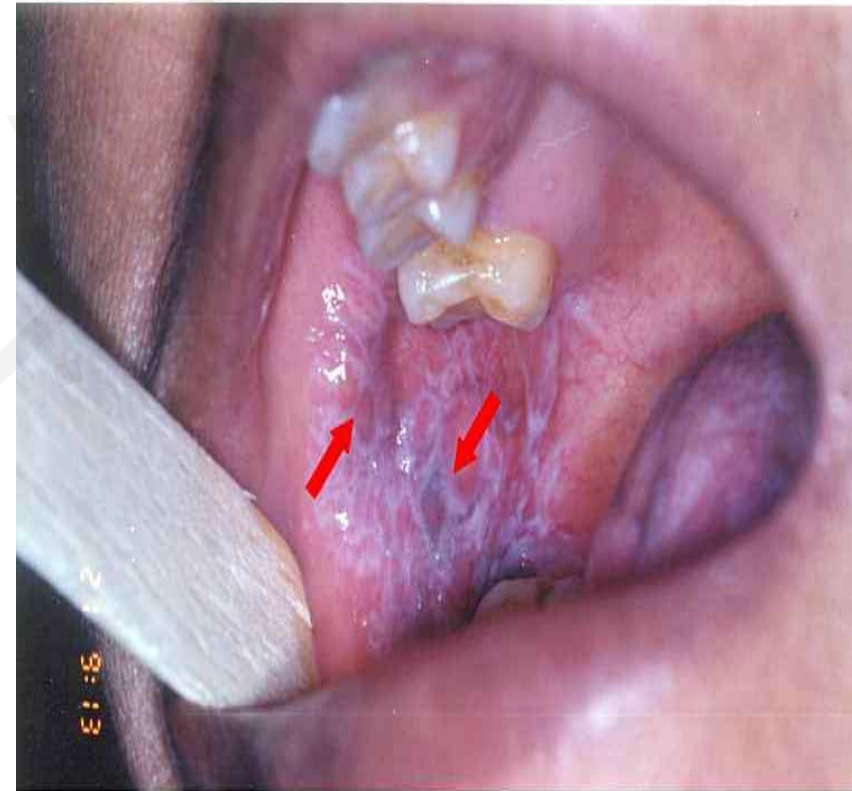
© 2000 Blackwell Science Ltd. All rights reserved.



Q6:

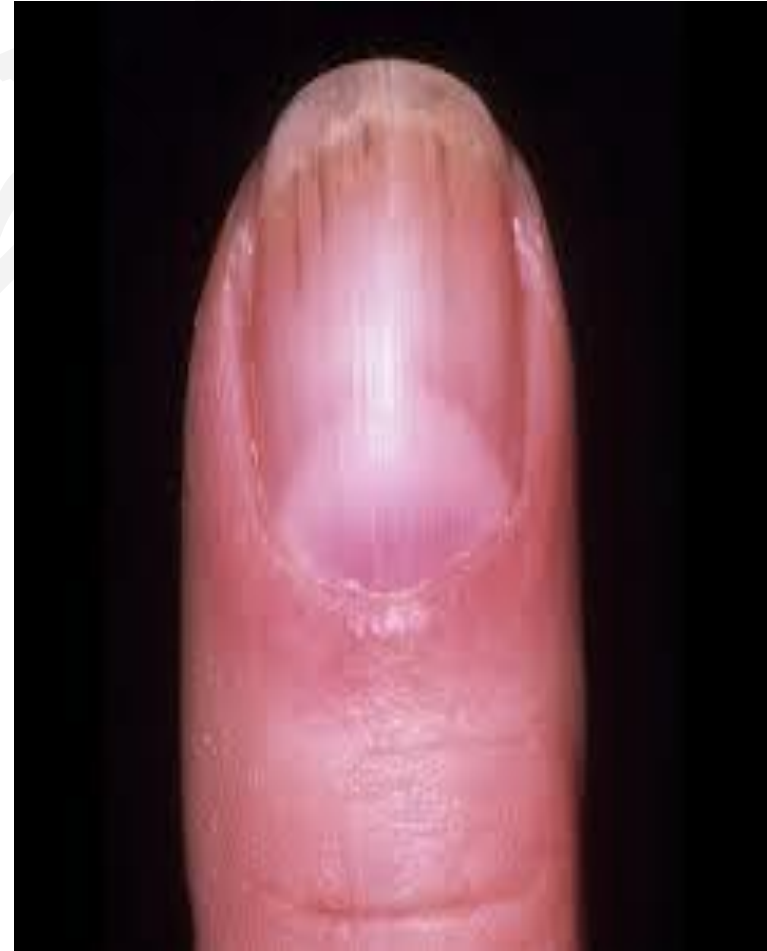- Pt has itchy papule on the his flexiors

1.What is the diagnosis? 2.What is the name of The striae on the buccal mucosa?  
3. Mention two complications of the disease?



Q7:

- 1.What is the name of the lesion?
- 2.Mention 3 conditions it occurs in ?



•

The end 😊  
good luck

By:Haneen khlaifat

18/10/2018 mini osce

Q1) Define Erythroderma, with one disease can cause it.

-mention 3 infectious skin disease diagnosed by wood's light (write the color of each disease on woods light)

Q2:

**1-Describe the lesion?**

annular patches  
red in color  
well demarcated  
not scaly  
(target lesion)  
no specific arrangement  
on the palmar aspect of the hand

**2-What's the cause of the facial rash?**

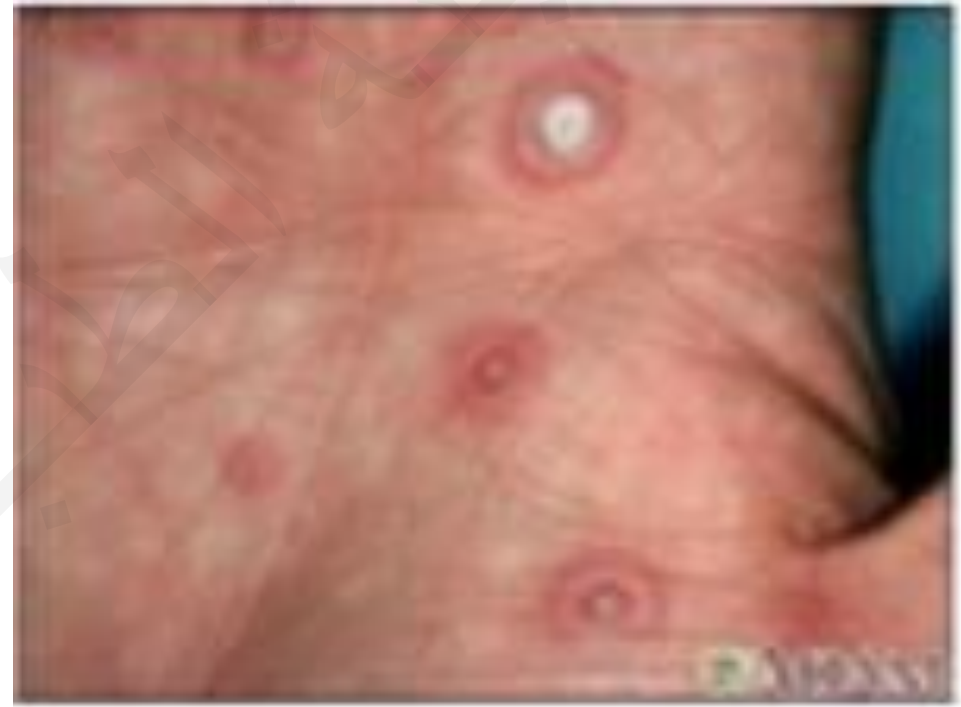erythema multiforme

**3-Diagnosis ?**

Herpes simplex

**4-What will you see on Diascopy?**

Blanchable



Q3)

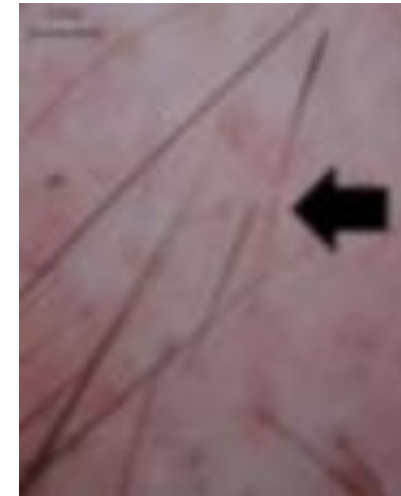
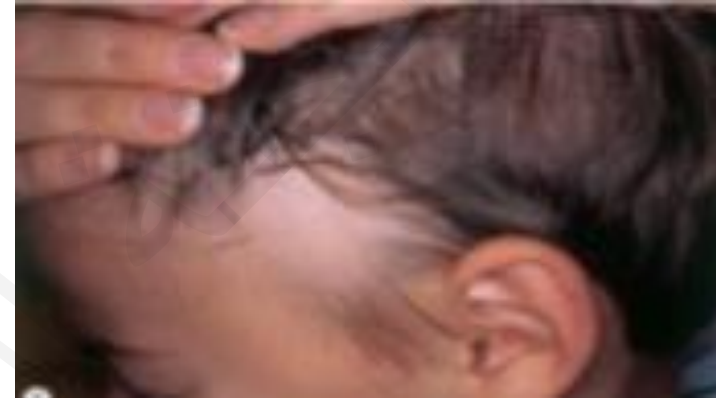Most likely Dx?

DDx?

What the name of the sign in the 2nd pic?

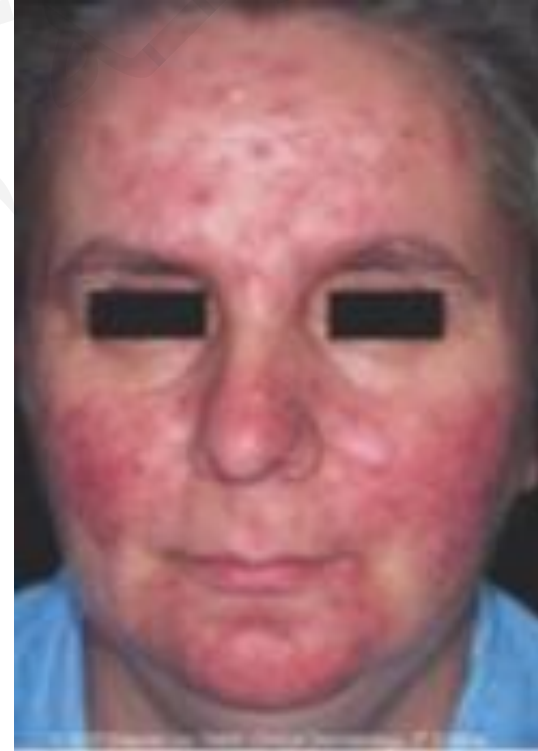3 lines of Tx.

((alopecia areata))



Q4)

- Name 1 parasite involved in the disease
- What's your Dx
- Mention 2 complications ?
- Mention 2 topical Tx



Q5:

6 months male baby present with this rash for 3 months, his mother has asthma

1.What is the diagnosis.

2.Name 2 organisms that can cause skin infections in this patient.

3.Types?

4.Mention 3 topical treatment.





