

1. what is the definition of the following and give example for each

A) Nodule

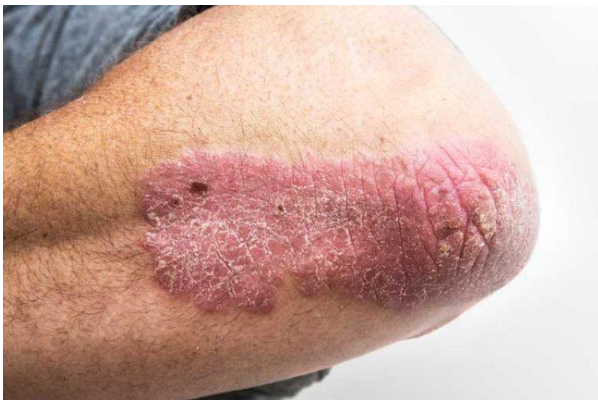B) Erythroderma

C) Macule

D) Scale

E) Atrophy

F) bulla



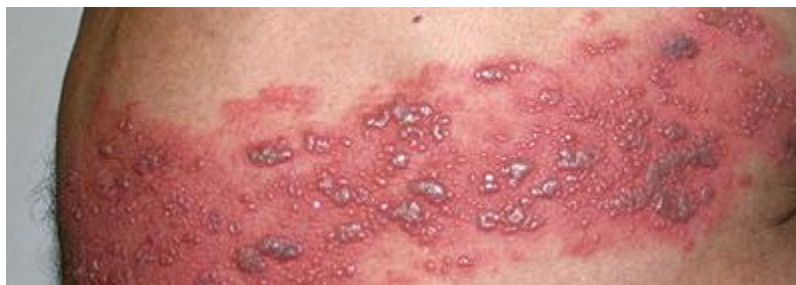2.

A) Describe the lesion

B) Give 2 differential diagnosis

C) Give 2 areas should be checked in this patient ?

D) Give 2 Complications ?

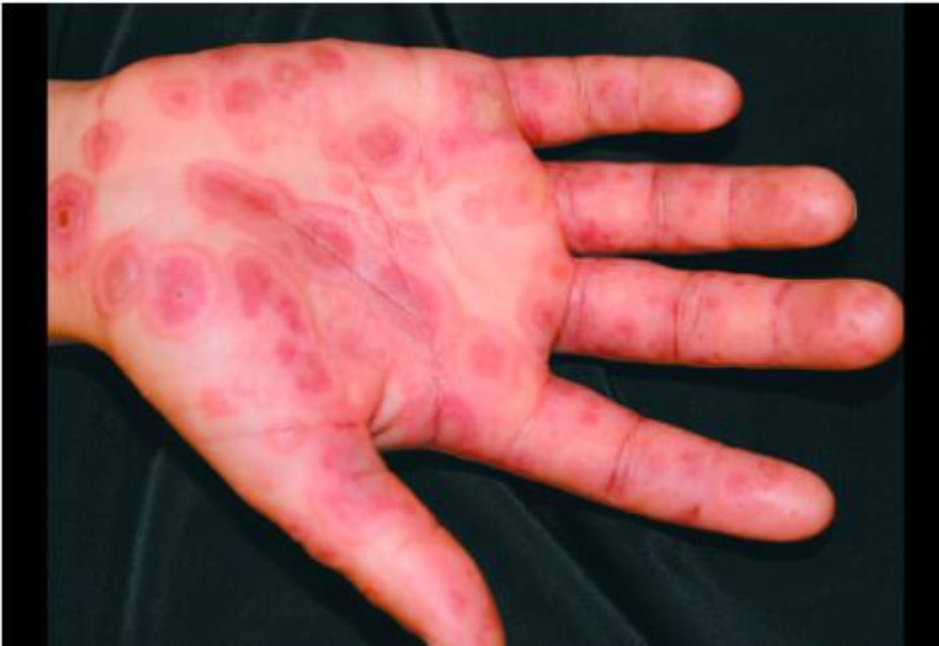

3)

A) give 2 differential diagnosis

B) How can you diagnosis?

C) what is the treatment ?

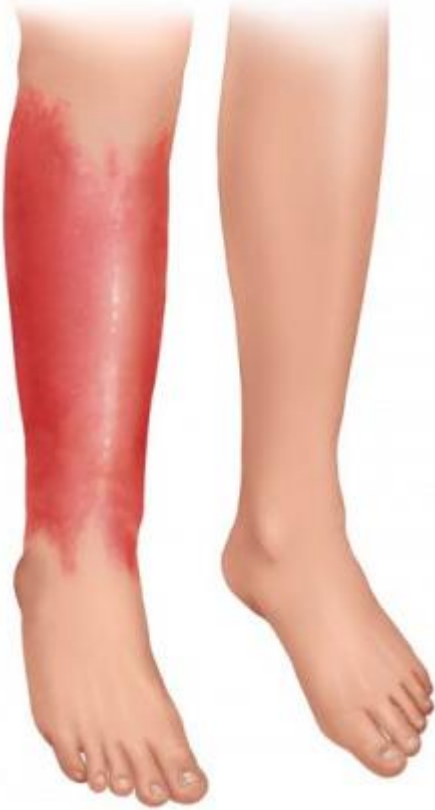

4)

A) Describe the lesion

B) give 2 differential diagnosis

c) what is the most common cause of the disease?



5)

A) Describe the lesion

B) GIVE 2 differential diagnosis

C) What is the treatment ?

Thanks.

# B 7+8 Dermatology exam

1/4/2021

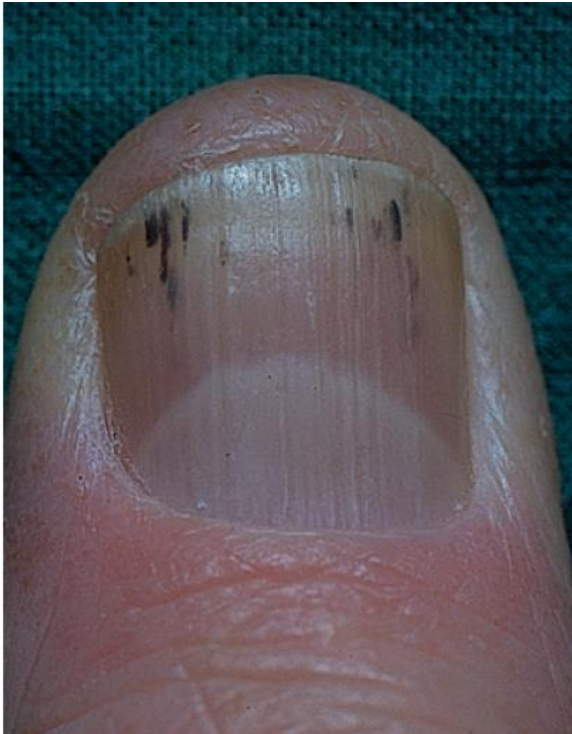Q1- Define the followings and give an example of a disease in which it is found.

1. Excoriation
2. Nodule
3. Lichenification
4. Macule
5. Wheal
6. crust

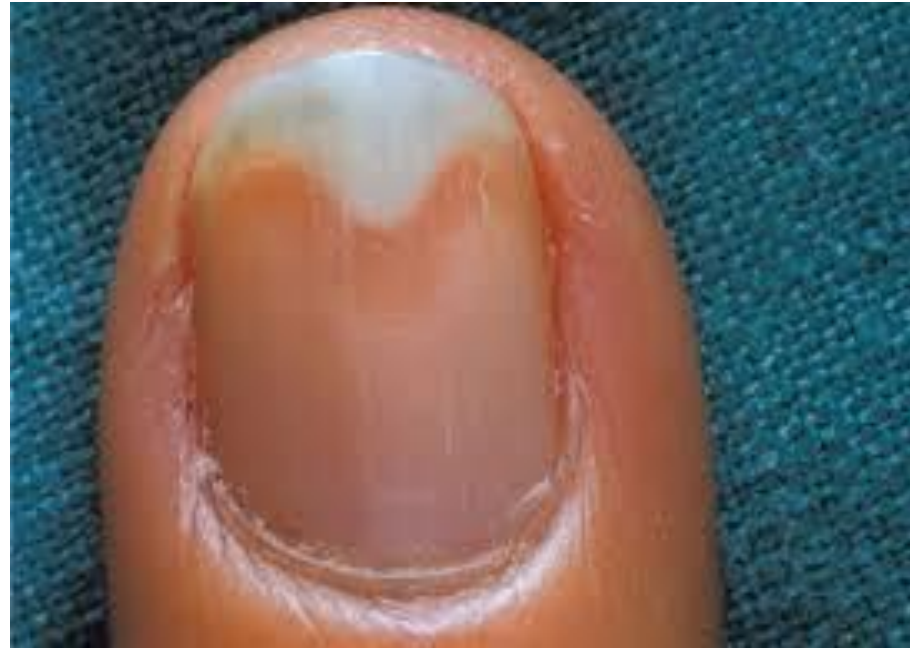## Q2

- What is **the name** of the following nail changes and mention **2 causes** of each sign ?
- A ? B ? C ?

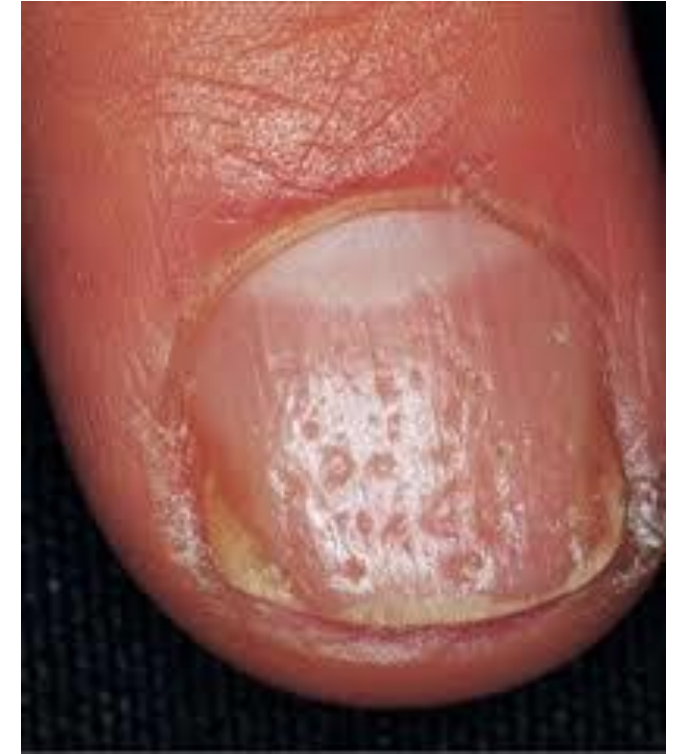A



B

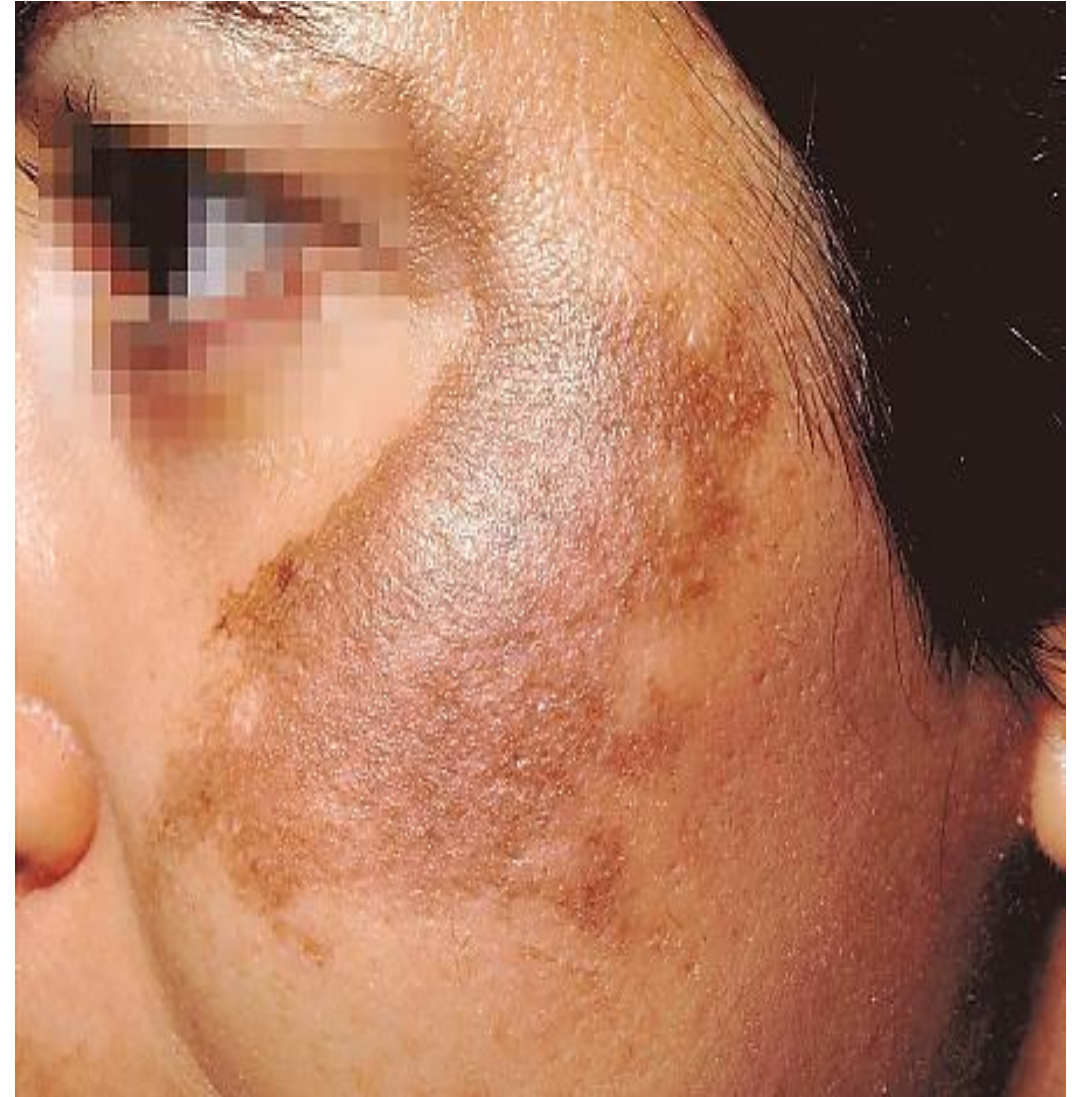

C





- This 35 year old female patient presented with 2 year history of brown macules and patches on her face . It was not preceded by erythema or itching .
- 1. What is the most likely diagnosis ?
- 3. mention **two** causes of this disease ?
- 4. How would you treat this patient?



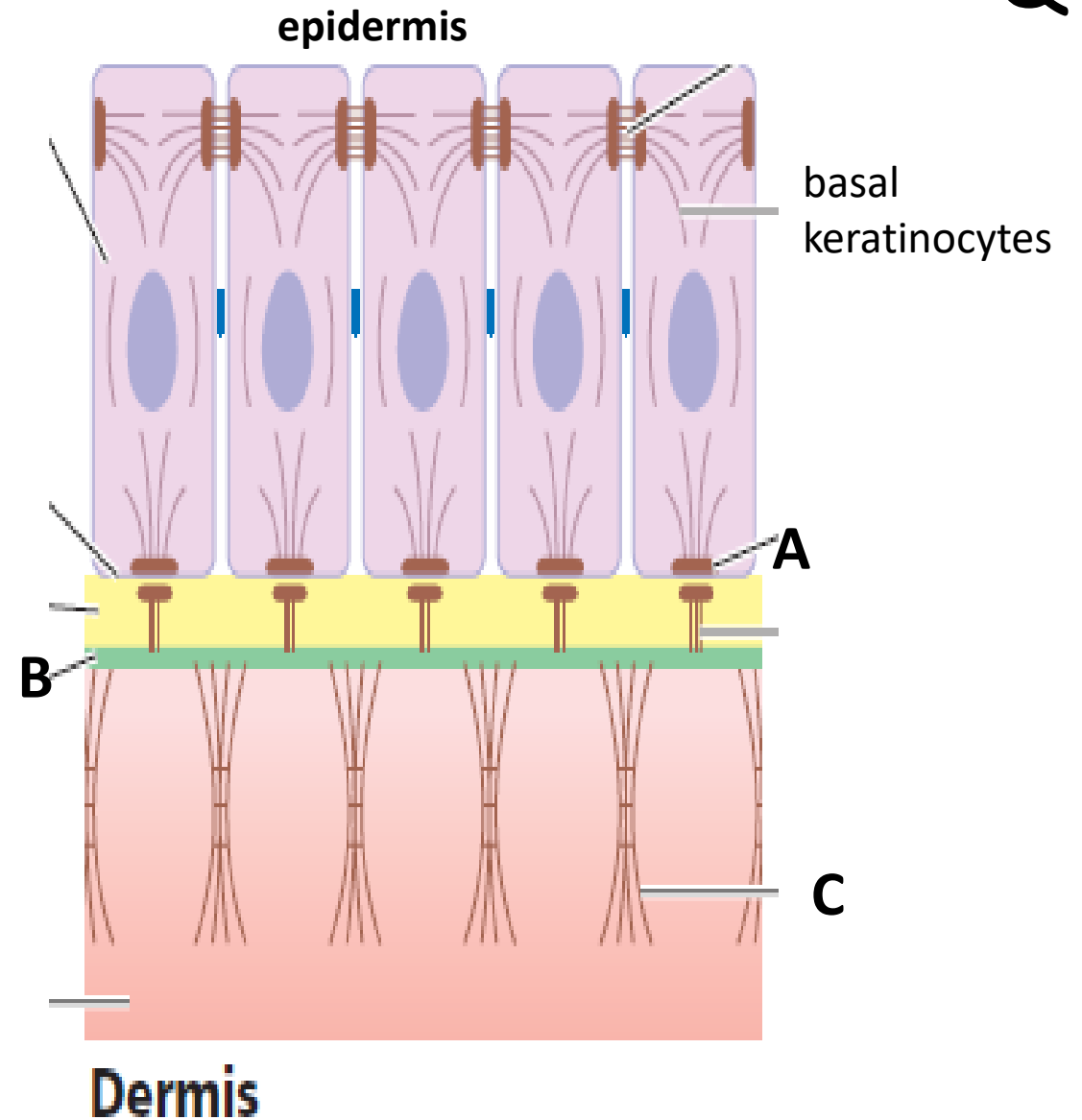
Q4

- Name the following structures ?

- 1. A ?

- 2. B ?

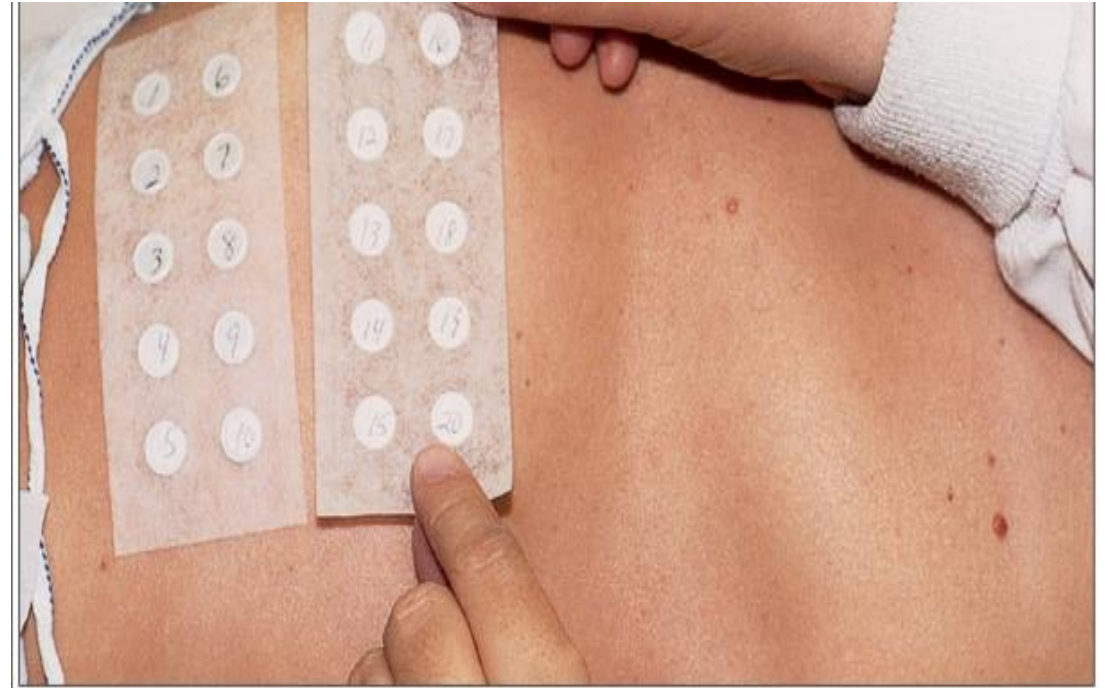
- 3. C ?





# Q5

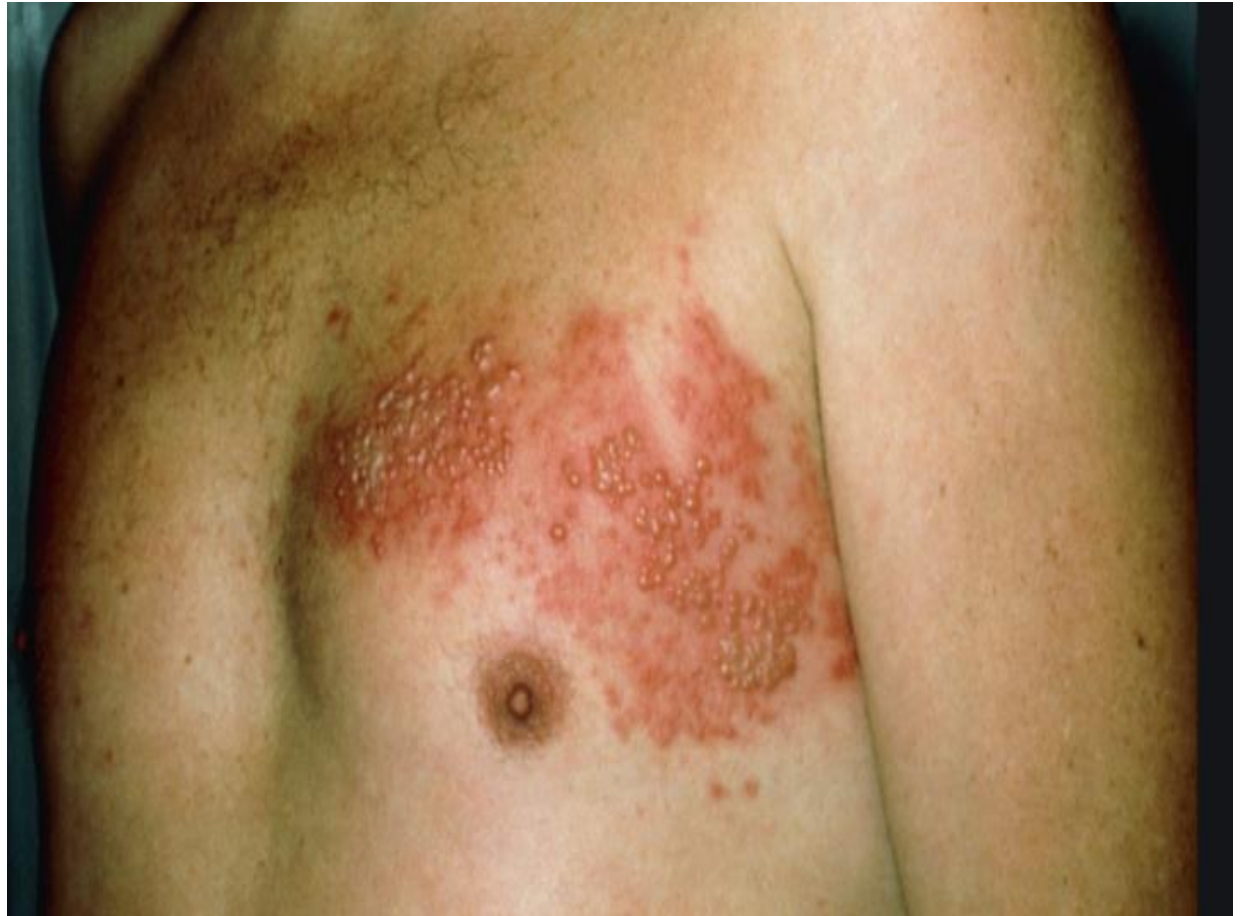1. What is this test?
2. In which disease do we use it?



Q6. This 50 year old diabetic patient, presented with burning pain and vesicles on the chest for 3 days.

- A. What is the most likely diagnosis?
- B. How would you confirm your diagnosis?
- C. Mention 2 differential diagnosis.
- D. How would you treat this patient?

- 



A1 + A2 Derma MiniOSCE Exam

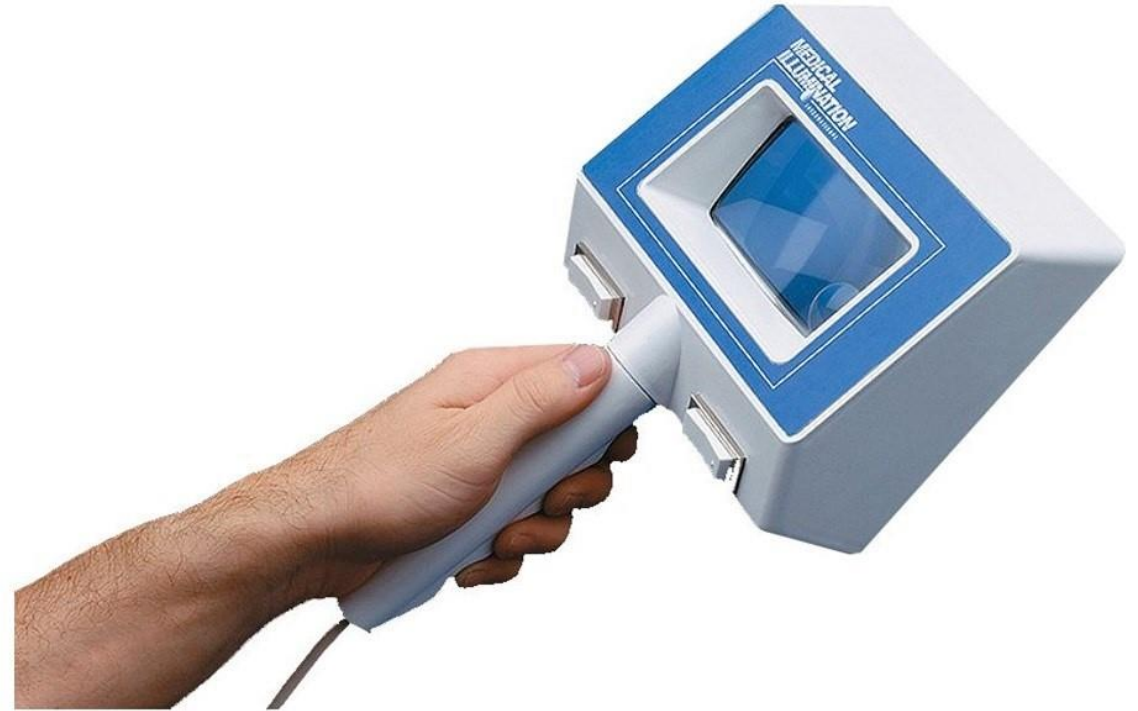Q1: Definition with one example:

- Macule
- petechia
- open comedone
- vesicle
- angioedema
- burrow

(All definitions could be found in Yazan file)

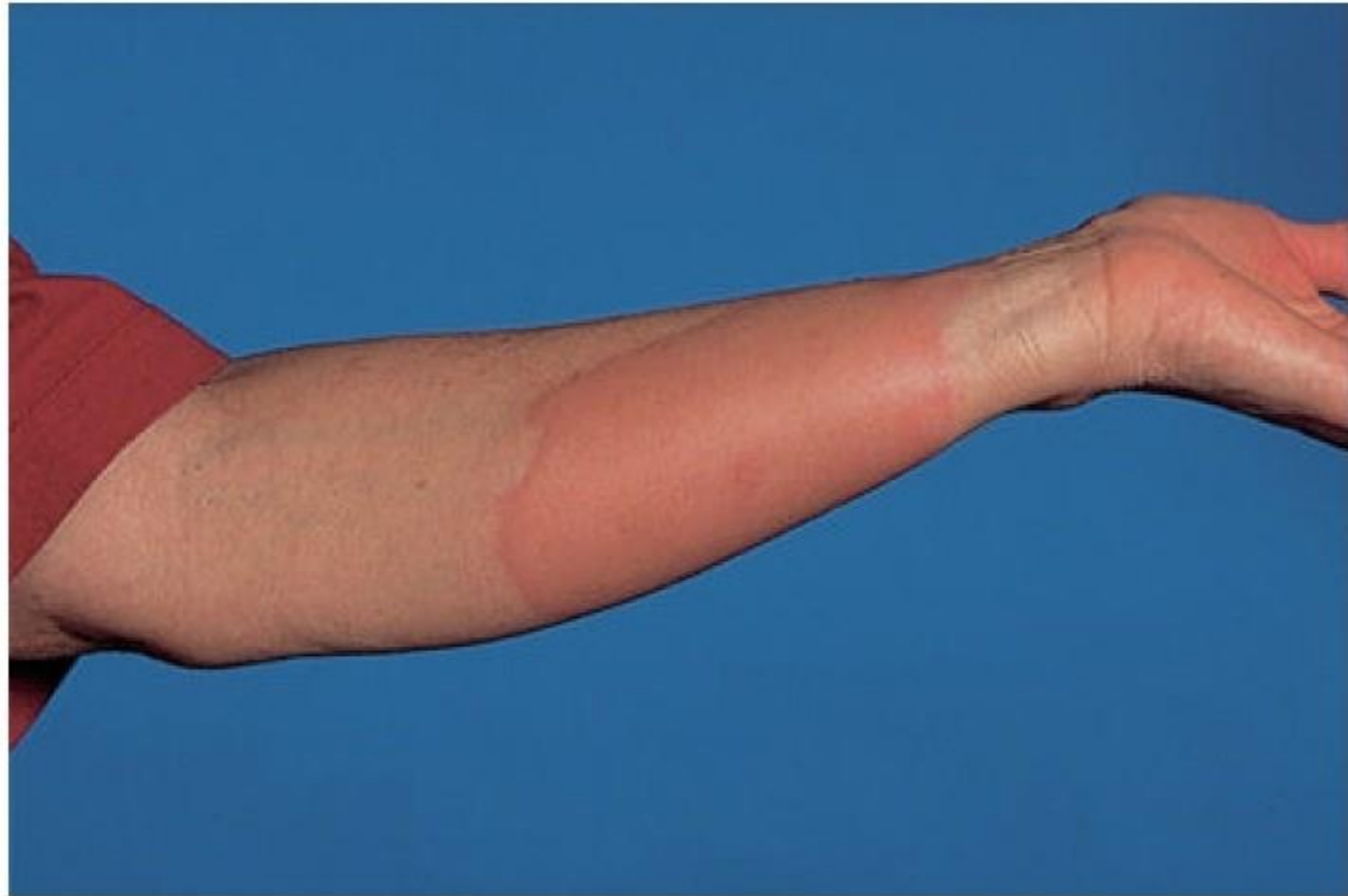
Q2 :

- What is the name of this test : (wood light)
- Mention 2 indications for it



Q3:

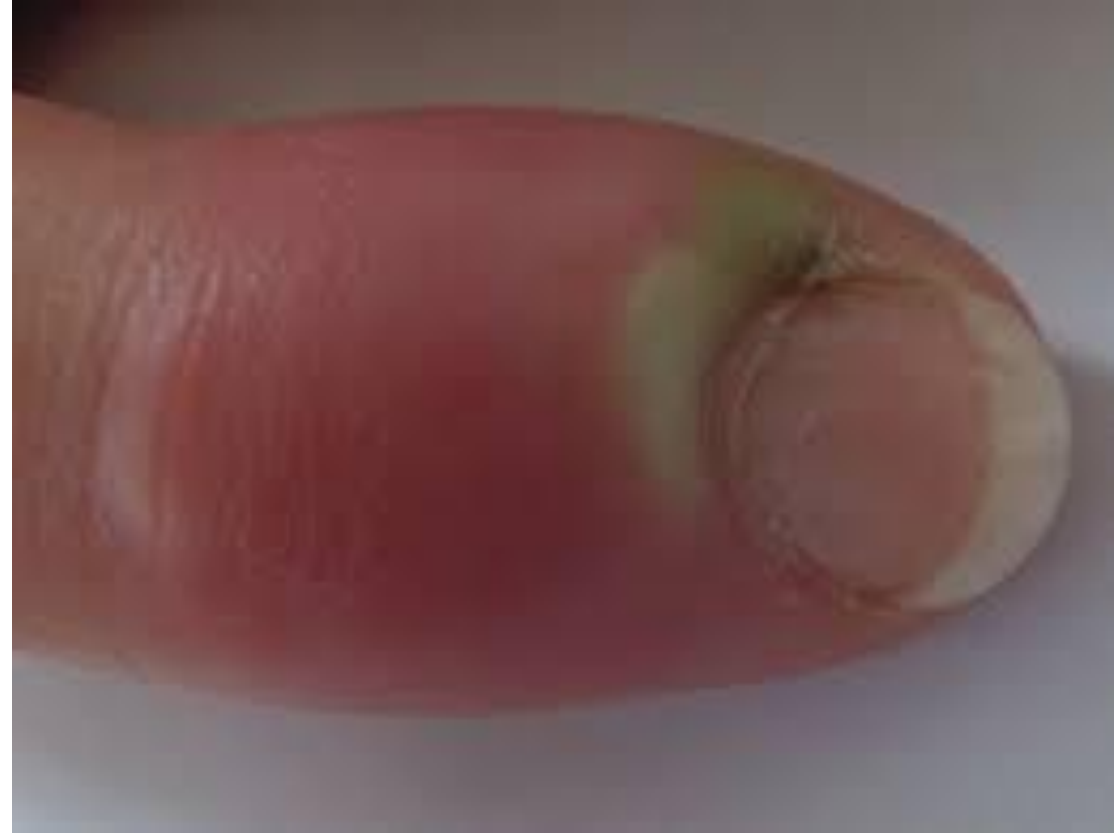- Describe what you see
- 2 ddx : (urticaria, cellulitis)



**Figure 8.7** A massive urticarial reaction to a wasp sting.

Q4:

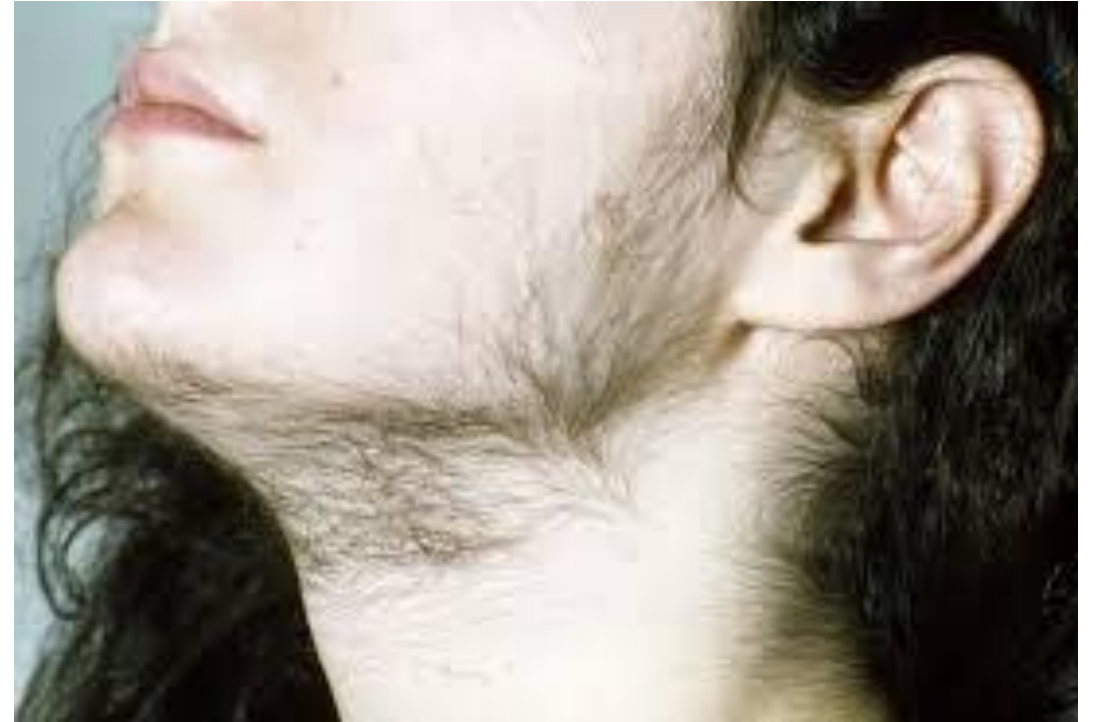- 2 findings : (erythema and swelling, pus collection in the nail fold)
- diagnosis (acute paronychia)
- 1 line of treatment (incision and drainage, ab for staph)





Q5: 20-y old female presented with hair as in picture

- diagnosis : (Hirsutism)
- 2 imp questions in hx : (family hx,menstrual hx)
- 2 physical exam findings : (acne, muscle atrophy, androgenic alopecia)
- 4 lab tests



Q6:

- diagnosis : (seborrheic dermatitis)
- ttt : (topical steroid, imidazole for malacacia)
- mention 2 other areas involved : (groin area, eye brows)
- complications : (malacacia over growth, blepharitis, furunculosis)

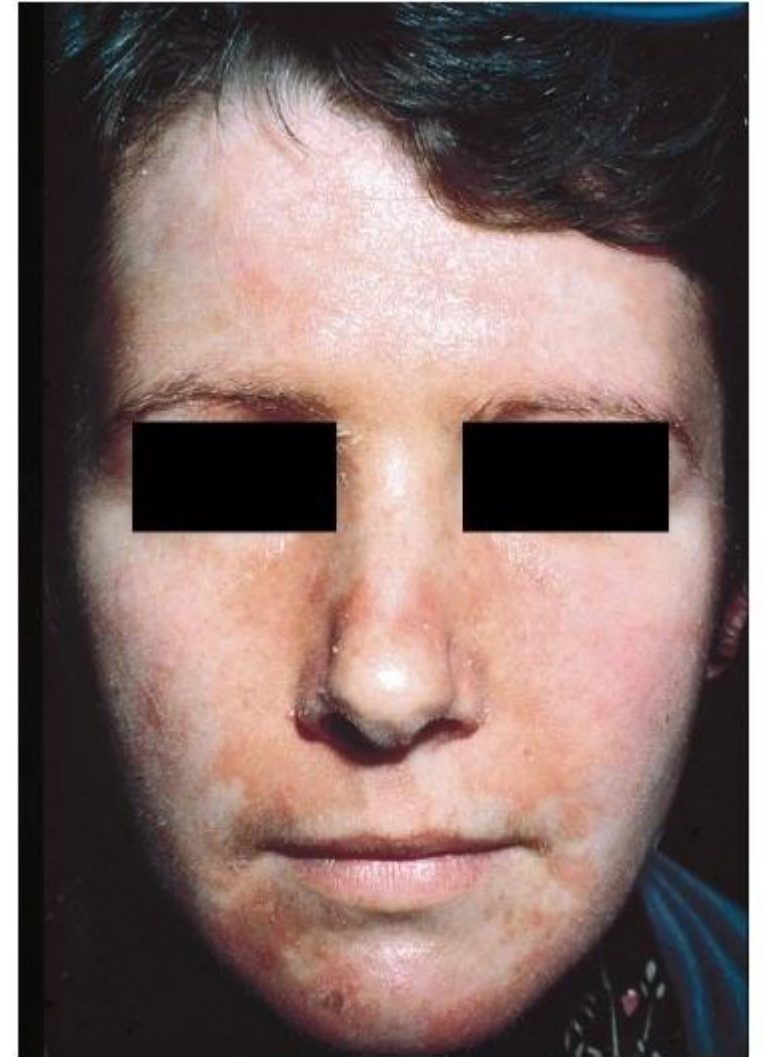


Figure 7.20 Active seborrheic eczema of the face.