



ENT MINI OSCE

Soul batch

B groups

Give 2 indications & 2 complications of tracheostomy tube?

1) A-Mechanical obstruction of the upper airways.

B-Retention of bronchial secretions

C-Protection of tracheobronchial tree in patients at risk of aspiration.

D-Respiratory failure.

E-Elective tracheostomy, e.g. during major head and neck surgery a tracheostomy can provide/improve surgical access and facilitate ventilation.

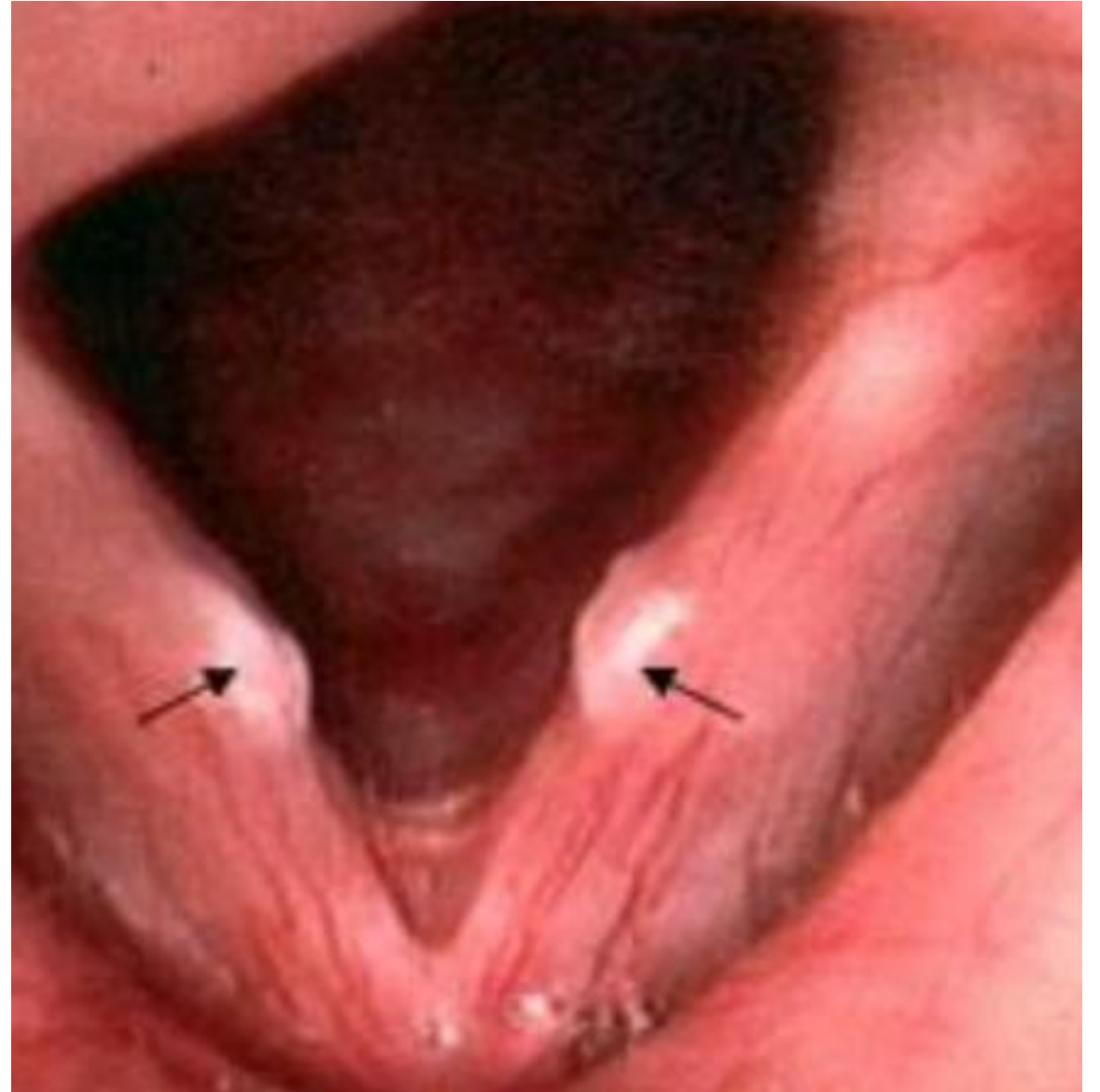
2) Dislodgment, Obstruction, Pneumomediastinum, Pneumothorax, Infection

1)What is the diagnosis?

-Singer's nodule

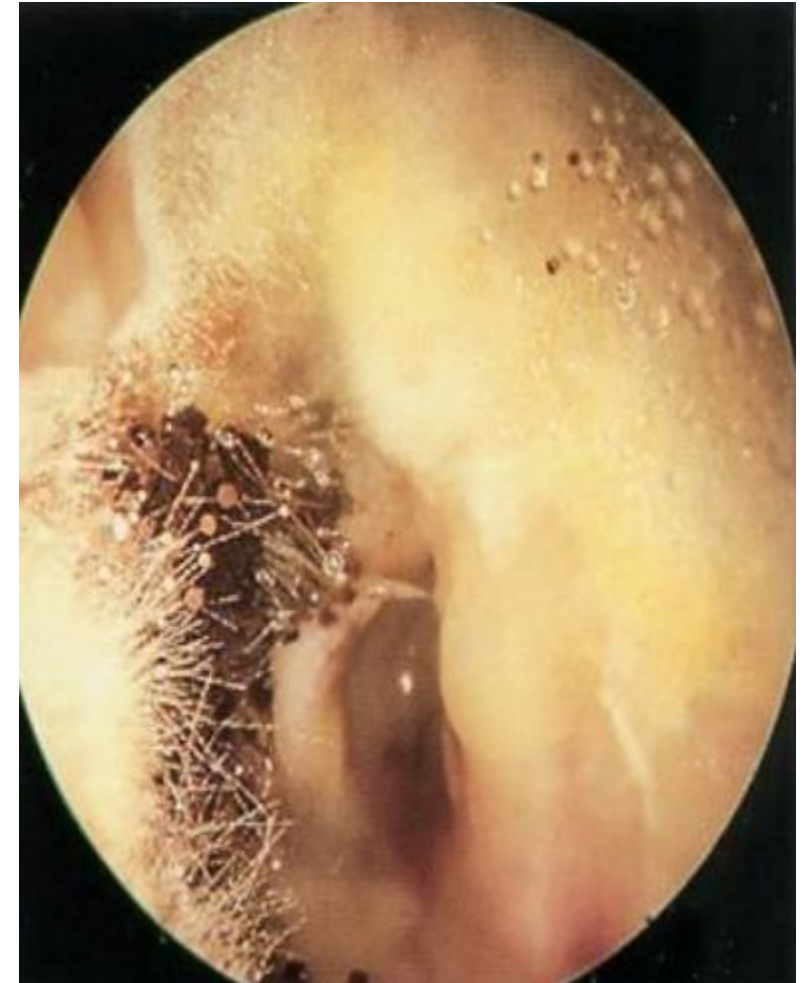One line of management?

-Voice rest / speech therapy



This pt. presented with Hx of ear itchiness.

- What is your diagnosis? -Otomycosis
- Two lines of management?
 - Aural toilet and keep the ear dry
 - Topical antifungals

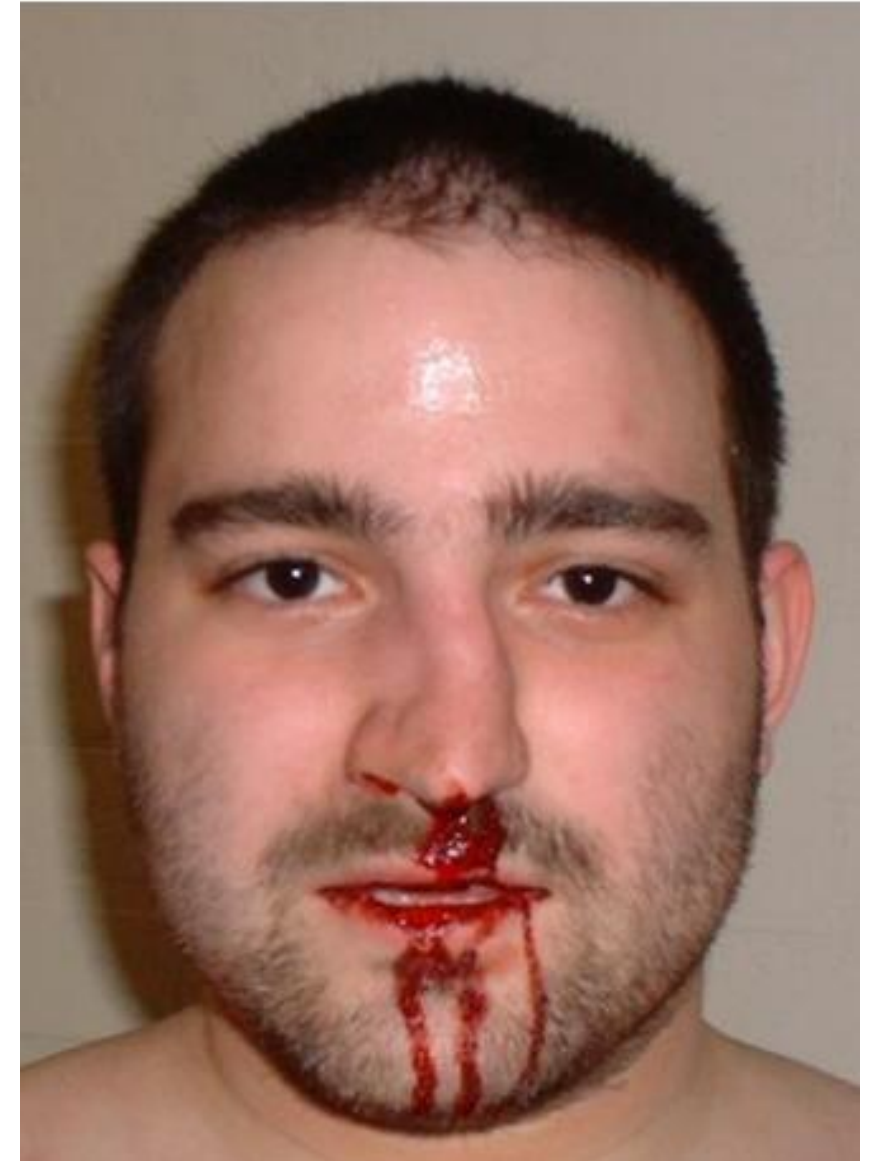

1- What is the first line of management?

Digital compression/Trotter's maneuver

2- Mention a surgery for treatment?

Ligation of the anterior ethmoidal artery



1-Mention two findings.

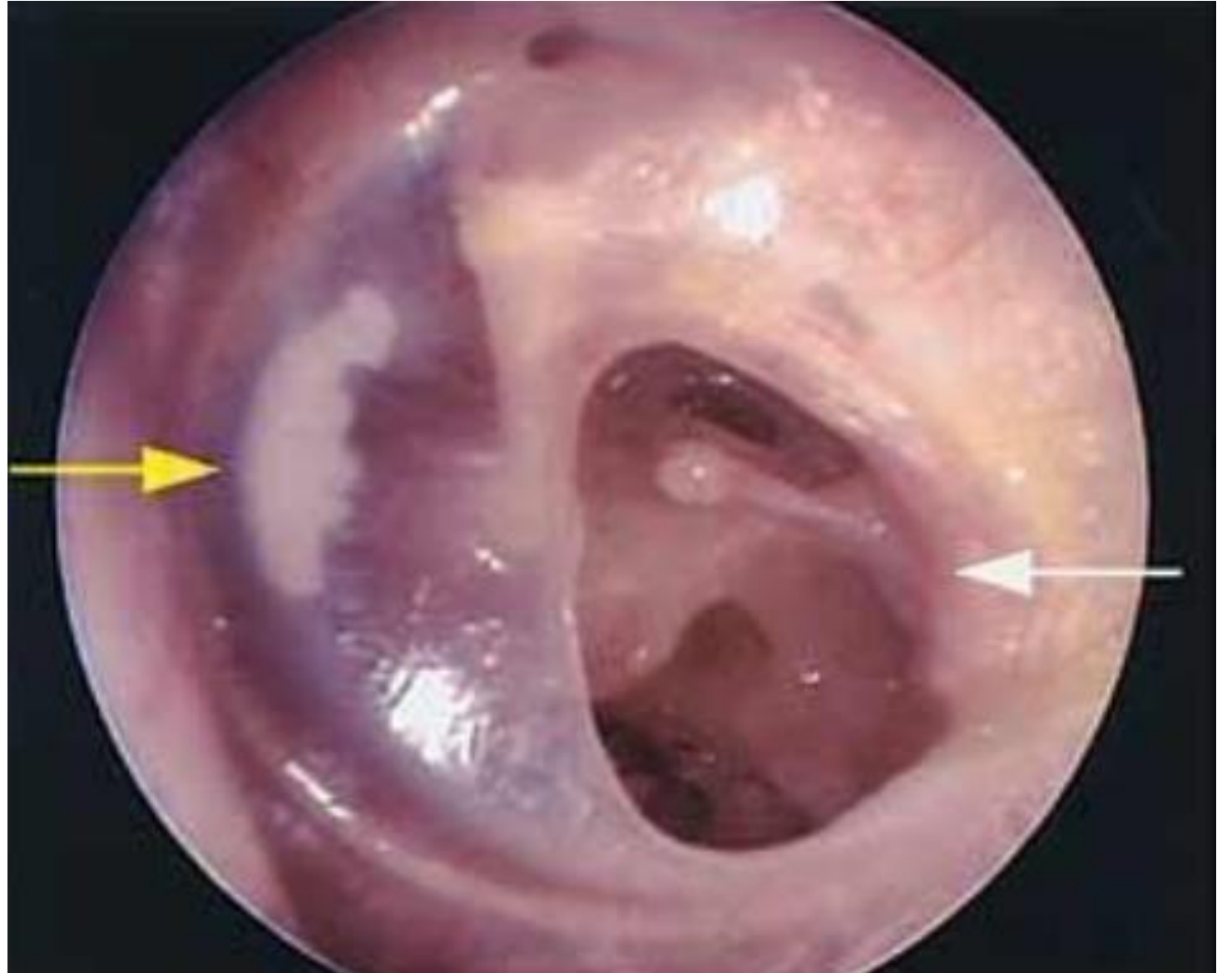-Tympanic membrane perforation

–Myringosclerosis

2- What do you see on tympanometry?

Type B

3-Possible extra cranial complications (same as OM complications)



- Thyroid nodule u/s picture:
- - Mention 2 suspicious findings (from the slides)

A 5 year old is brought to the emergency department by his parents because they saw a white exudate on his throat, he had a tonsillectomy 2 days ago

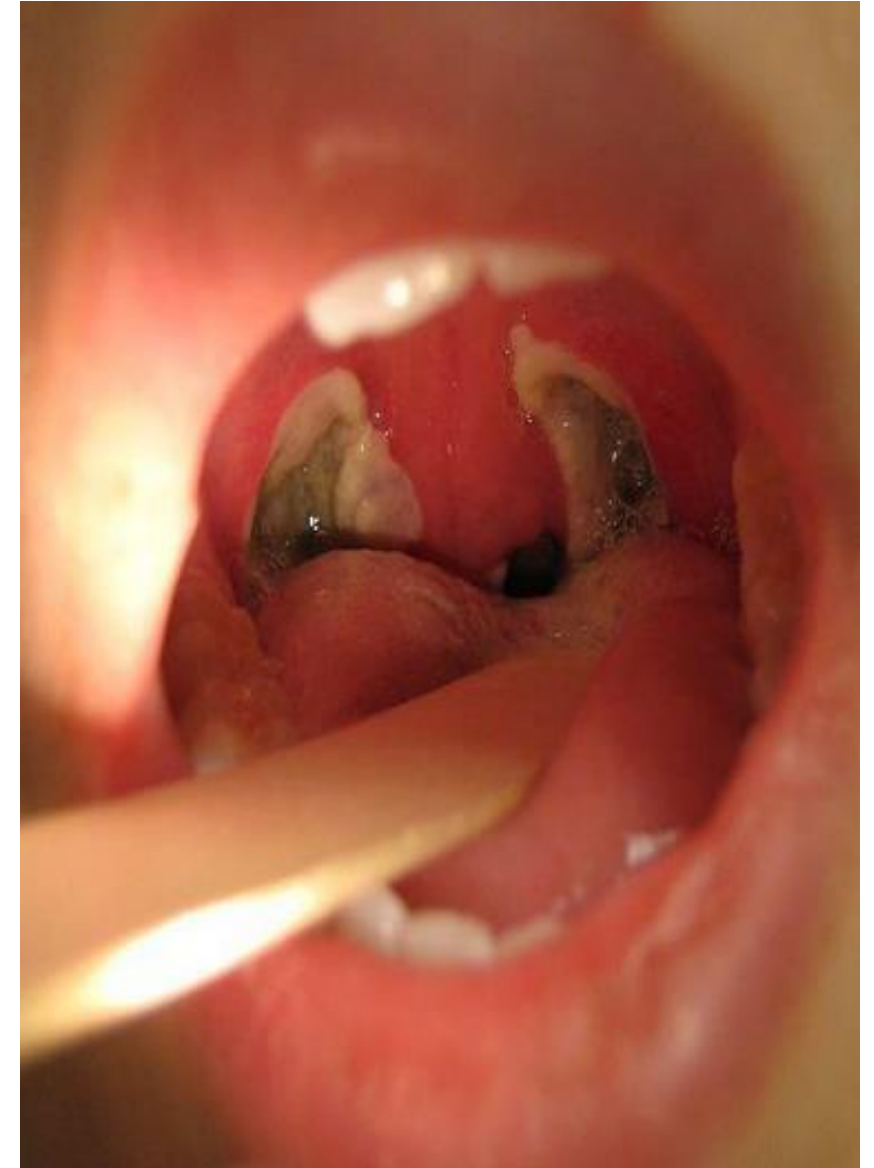1-What is the cause of this?

Normal fibrinoid reaction after tonsillectomy

2-Give 2 indications for tonsillectomy?

A-Recurrent acute tonsillitis

B-Complicated tonsillitis as in febrile convulsion



A 20 year old female patient presented with 10 days duration of yellow nasal discharge

1- What is the diagnosis?

Acute infective rhinosinusitis

2- What is the most likely microorganism?

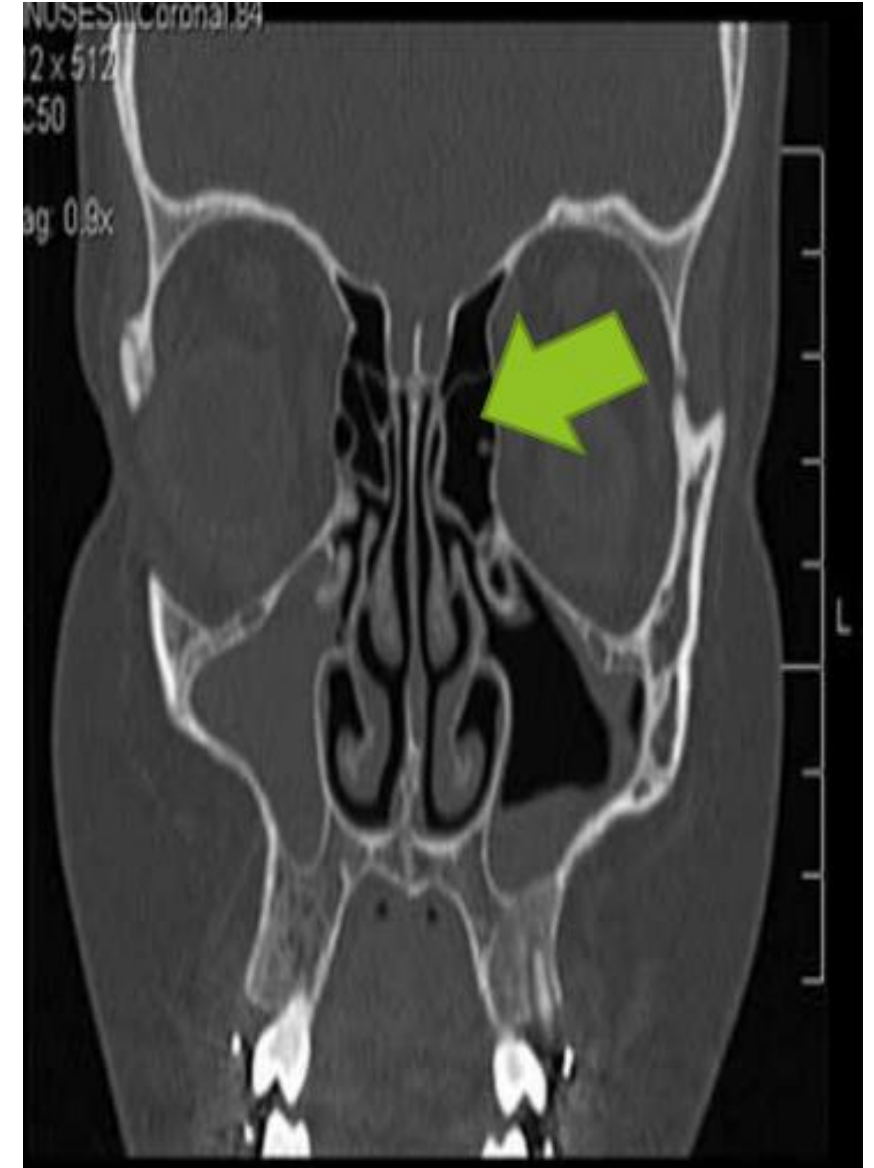Streptococcus pneumonia

3- What is the name of the surgery for refractory cases?

FESS (Functional endoscopic sinus surgery)

4-What is indicated by the arrow?

Left ethmoidal sinus



Thyroid nodule (at the midline and moves with tongue protrusion):

1) ddx: thyroglossal duct cyst

2) Ttt: sistrunk procedure

A child is brought by his worried mother complaining of choking and difficulty breathing

1- what is the diagnosis?

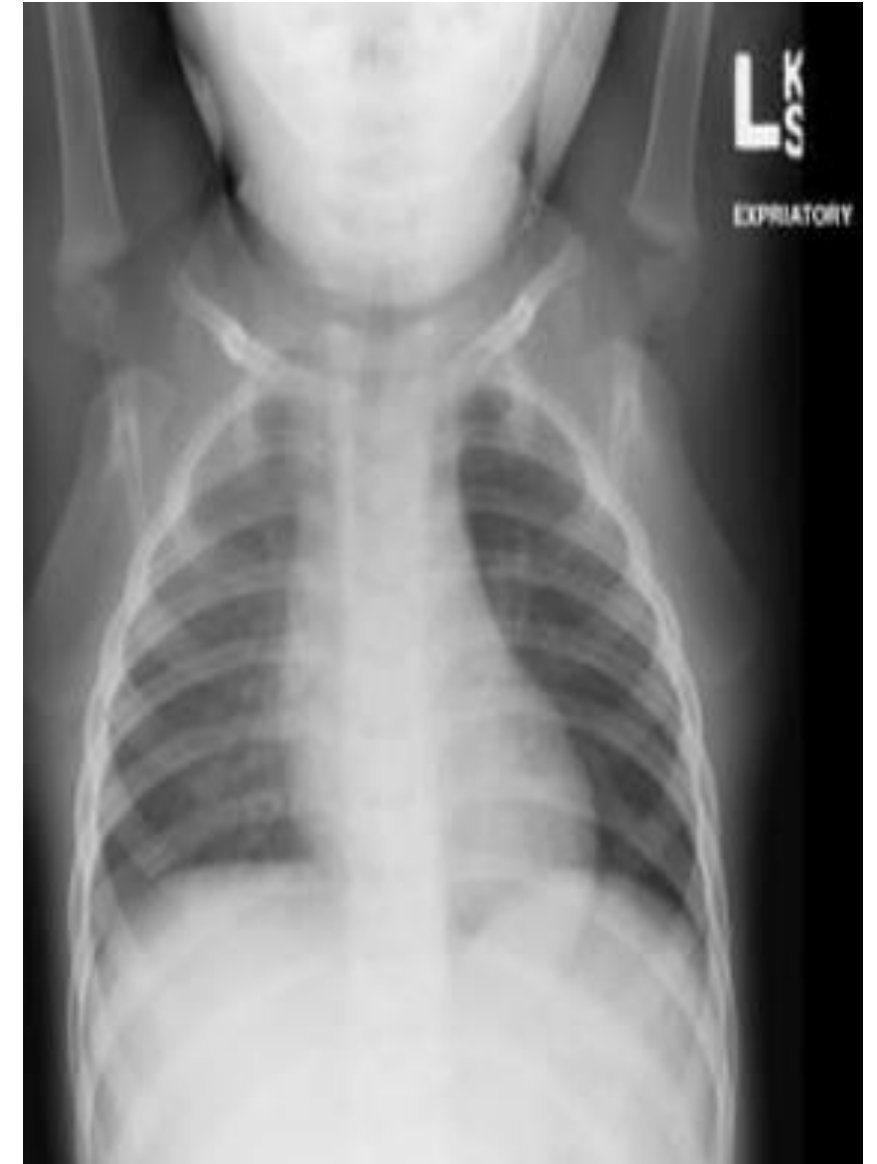Foreign body aspiration

2- what is the first line of management?

Bronchoscopy

3- Mention 2 complications if left untreated.

Pneumonia, lung collapse



A pt with thyroid enlargement had a FNA that showed little follicular cells of undetermined significance.

1. what is the Bethesda score? Bethesda 3

2. What is your management? Lobectomy

1. What's your diagnosis?

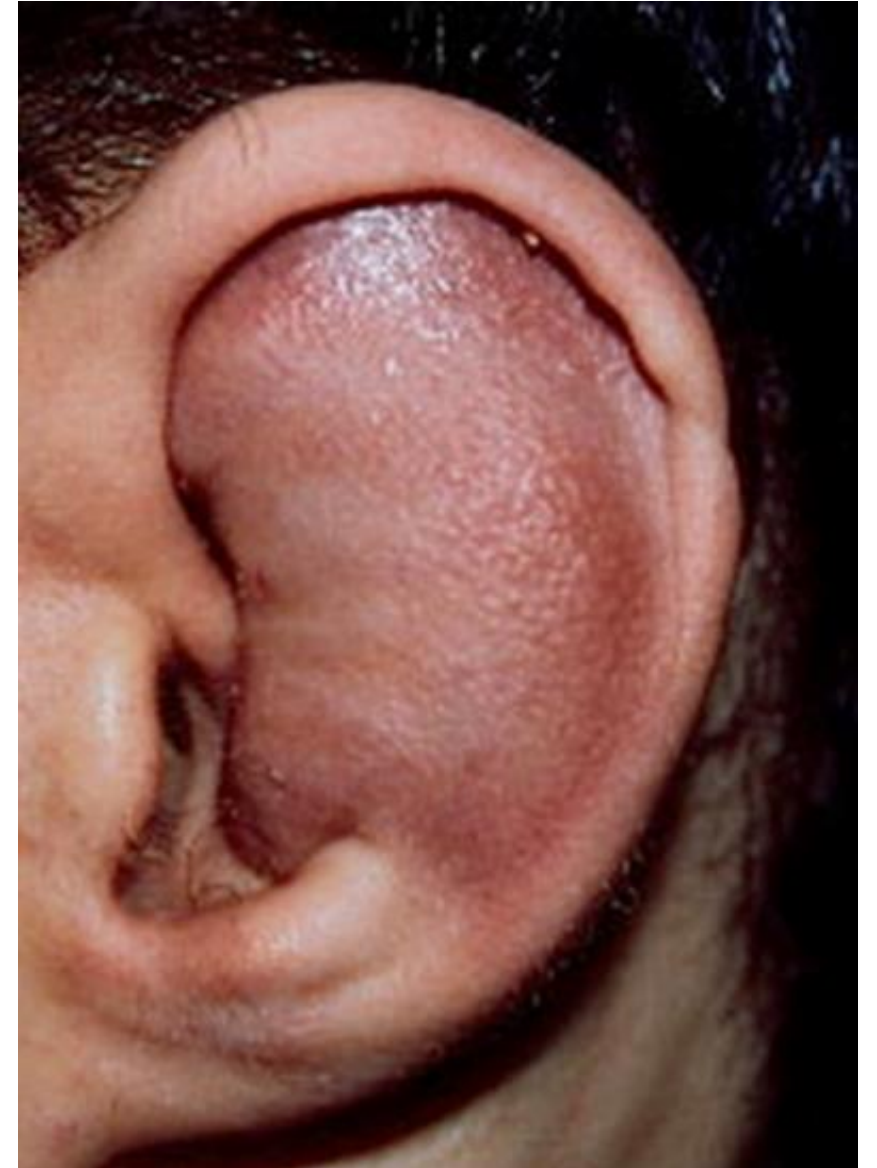Auricular hematoma

2. Mention 1 way for treating it.

Incision and drainage

3. Mention 1 complication if left untreated?

Cauliflower ear



A 4 year old child presented with history of hearing loss and aural fullness of 5 month duration in both ears.an otoscope showed the following

1) What is the diagnosis?

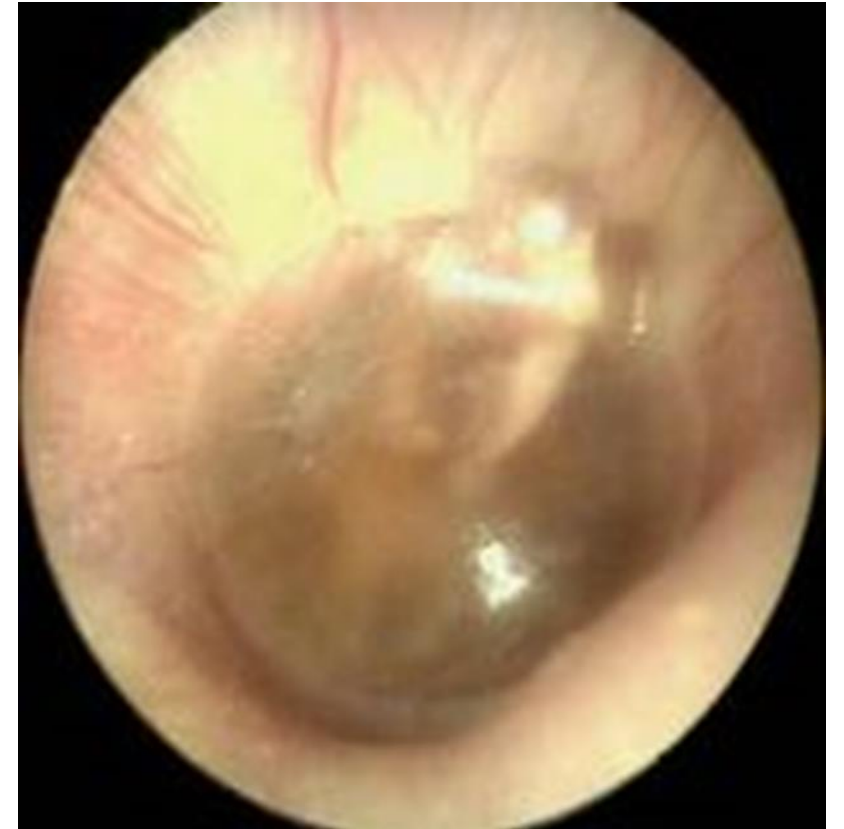Otitis media with effusion

2)type of tympanometry?

Type B

3)What is the main line of treatment?

Myringotomy and grommet tube insertion



A patient presented with headache and nasal discharge for a week

1-What is your Dx?

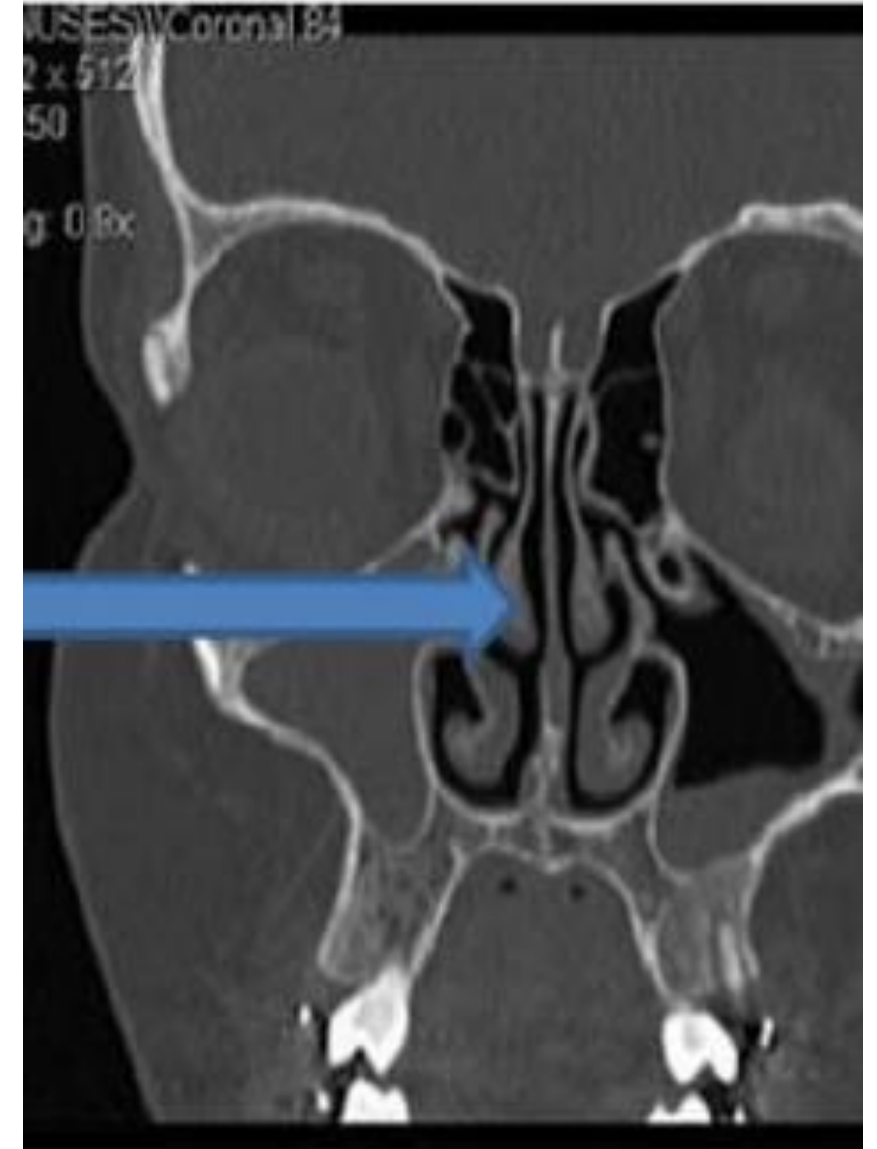Acute infective rhinosinusitis

2-What is the structure on the arrow?

Right middle turbinate

3-If the case is refractory to medications what is the second line?

FESS

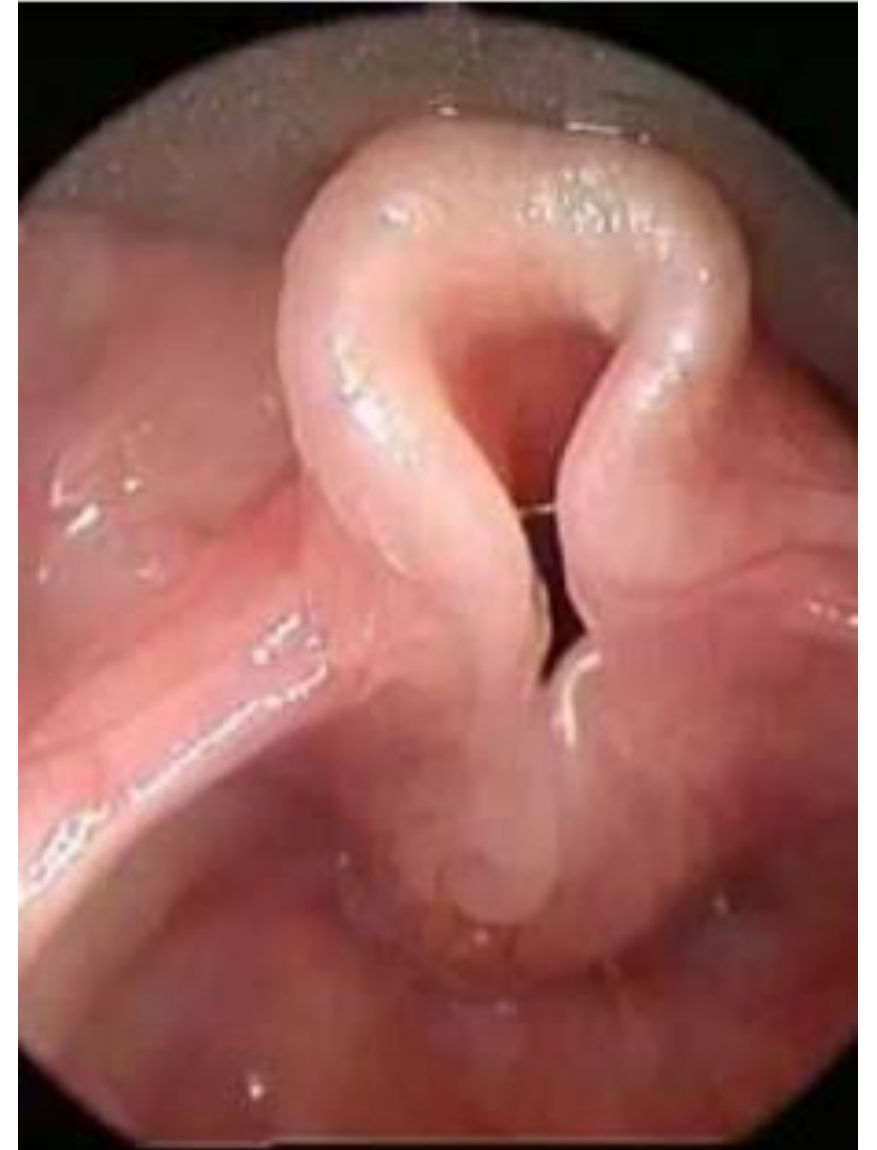

1-What is the diagnosis?

Laryngomalacia

2-What is the sign in the pic?

Omega sign



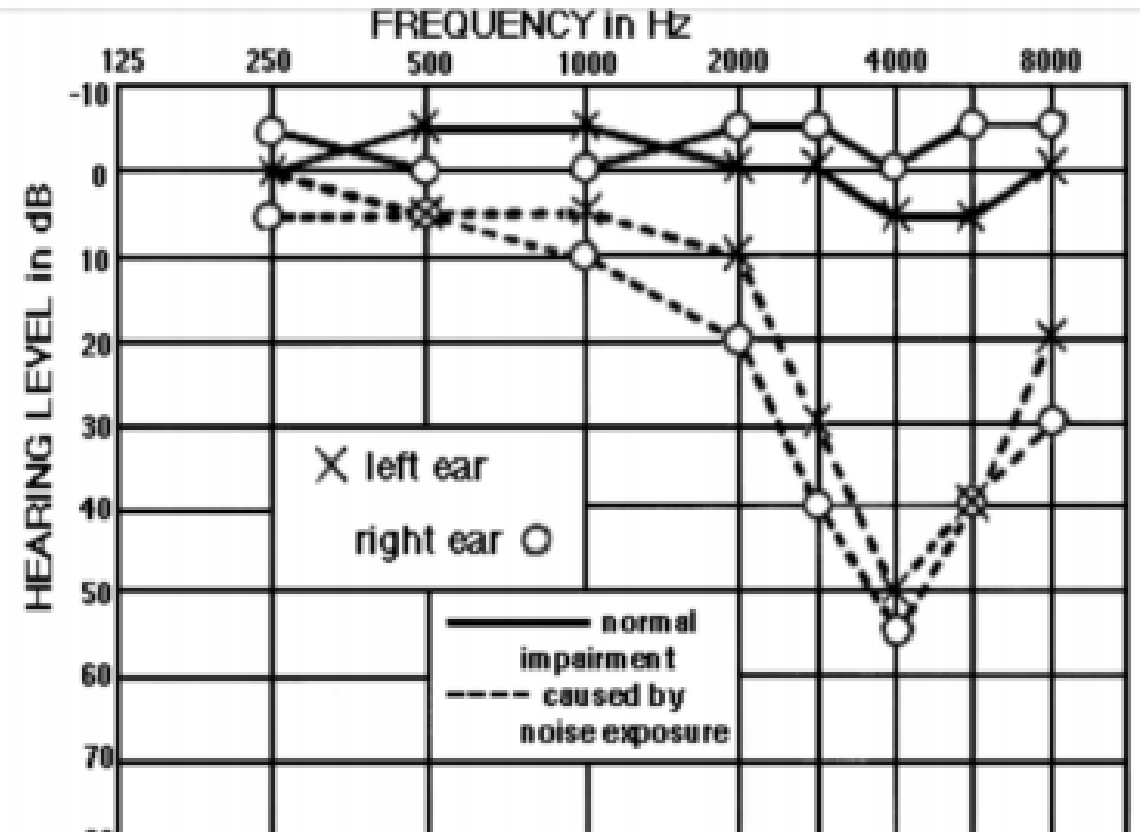
1)What is the first thing to do if you found an insect in pt ear?

Kill with alcohol

2)What complication can it cause?

Tympanic membrane perforation

- Male 60 years old with progressive bilateral hearing loss, with this PTA First line of management?
- Hearing aids



A patient complaining of a neck mass for 3 months duration.

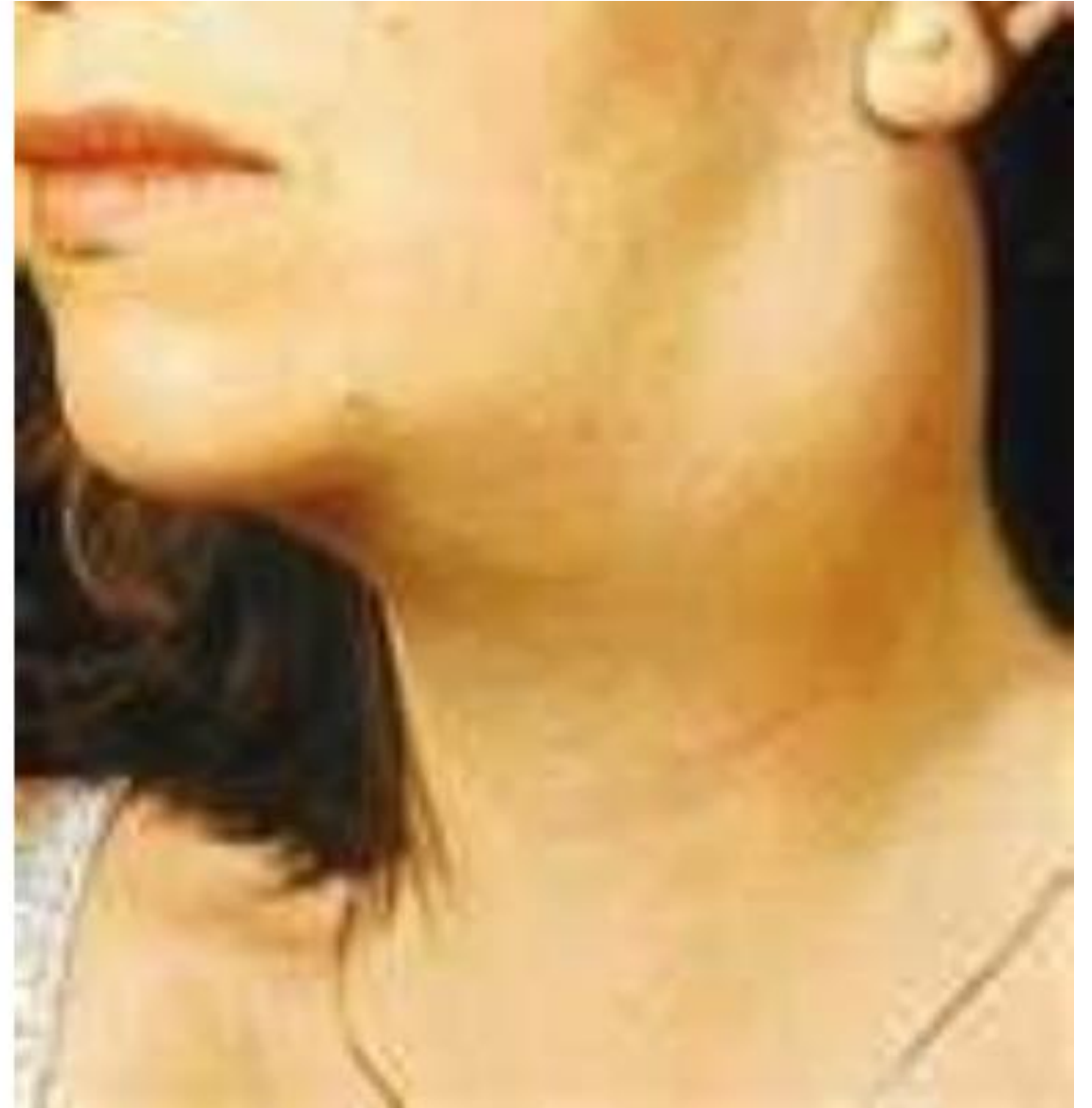1- Mention 2 differential diagnoses?

branchial cyst

Lymphoma

2- Best next step in management?

FNA



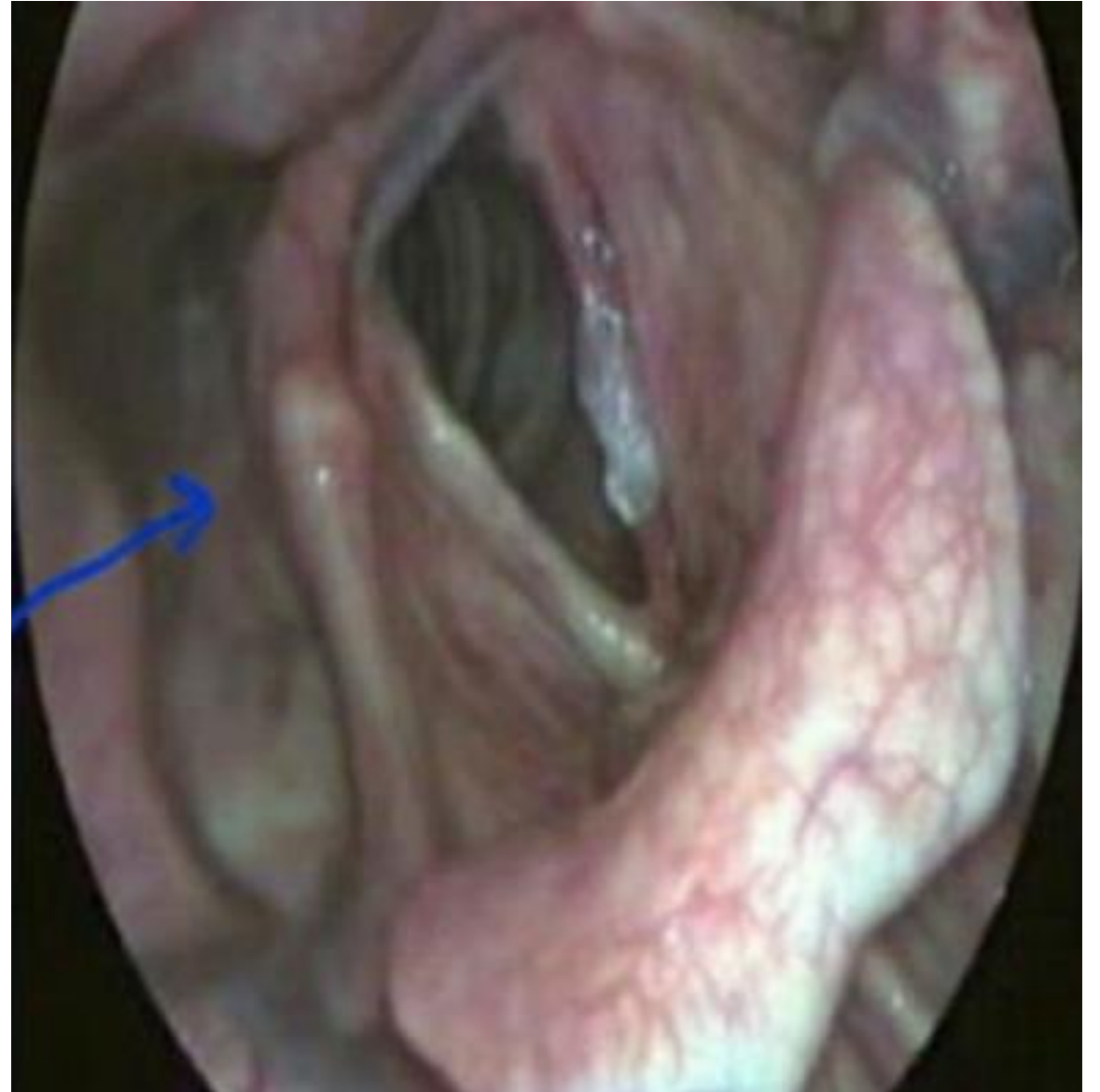A 55 year old male smoker, is complaining of dysphonia. His initial work up suggests malignancy

1- What is the most common subtype?

Squamous cell carcinoma

2- What is the name of the area the arrow is point at?

Right piriform fossa



1-What is your diagnosis?

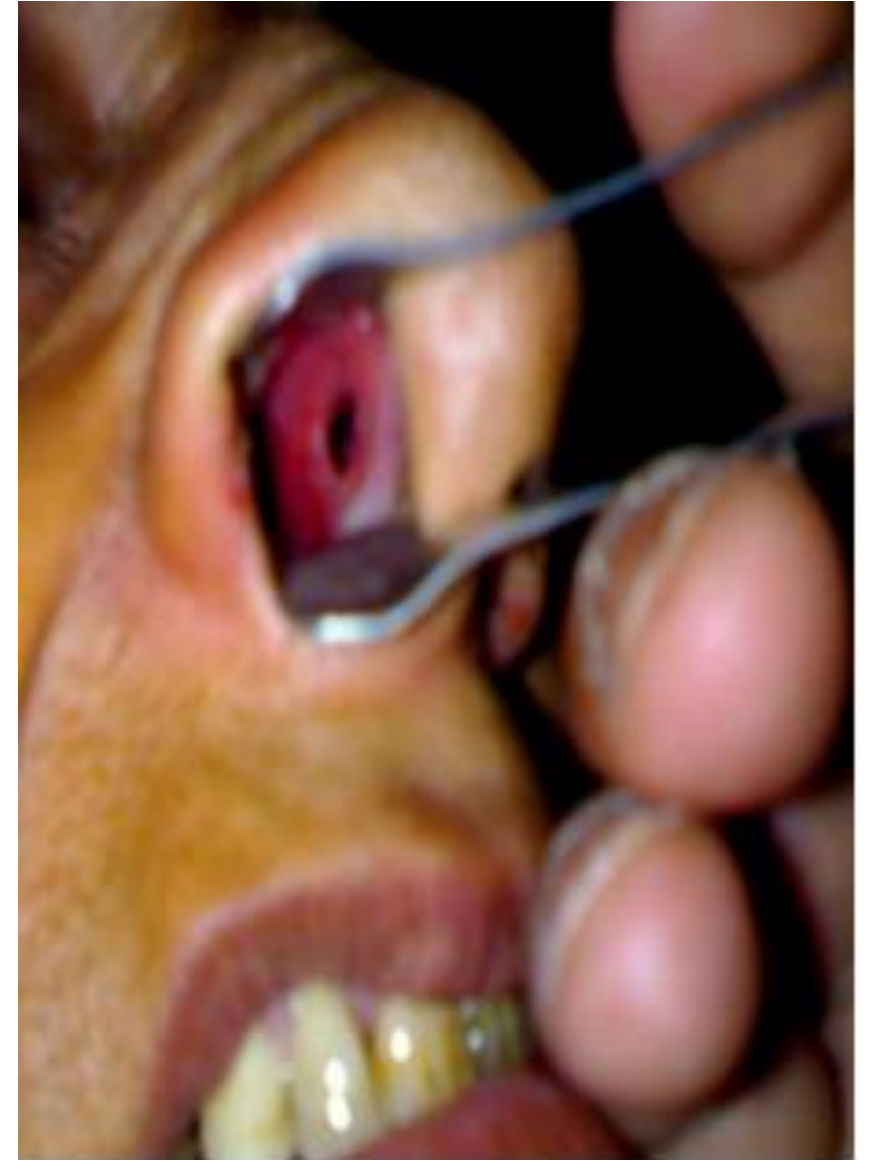-Nasal septum perforation

2-Give two non-iatrogenic causes.

-Foreign body

-Warfarin

-Cocaine sniffing



1)Most causative bacterial organism?

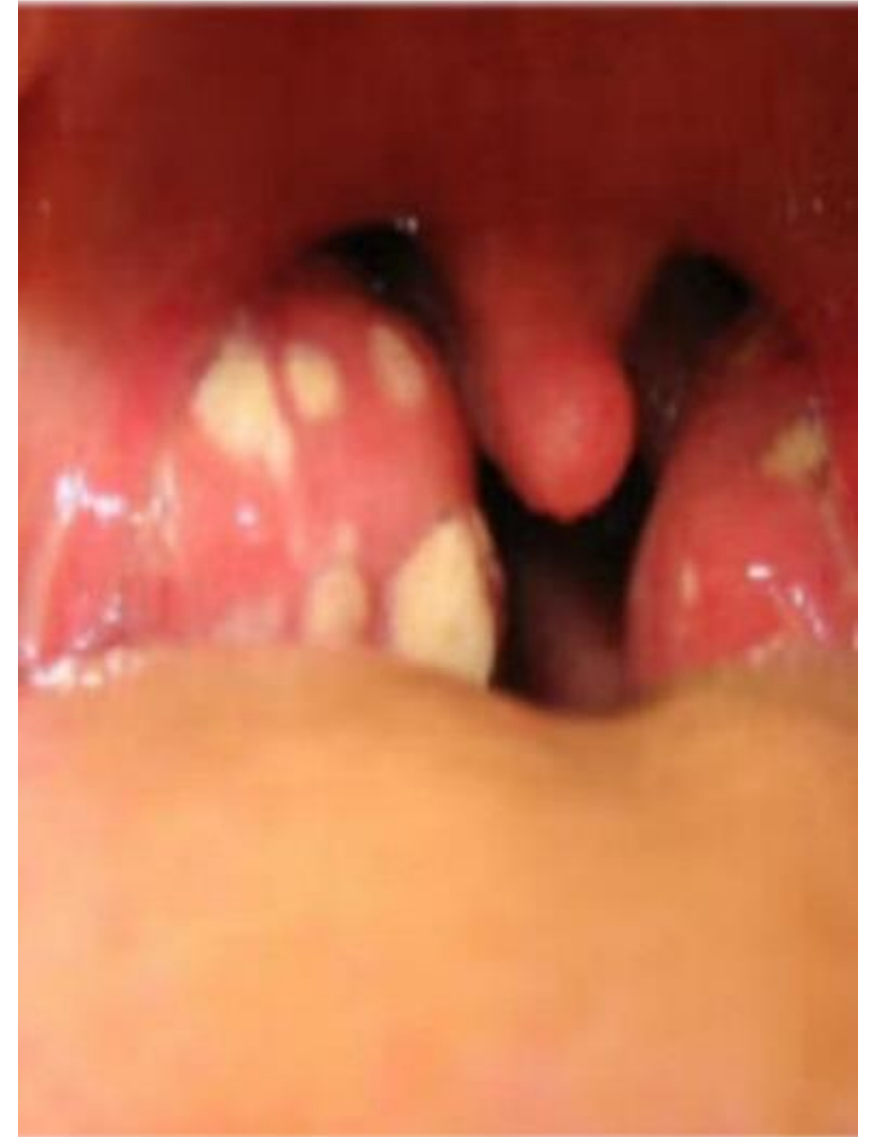
Strep pyogens

2)Causes of tonsillectomy?

Reccurnet infections

Quinsy

malignancy



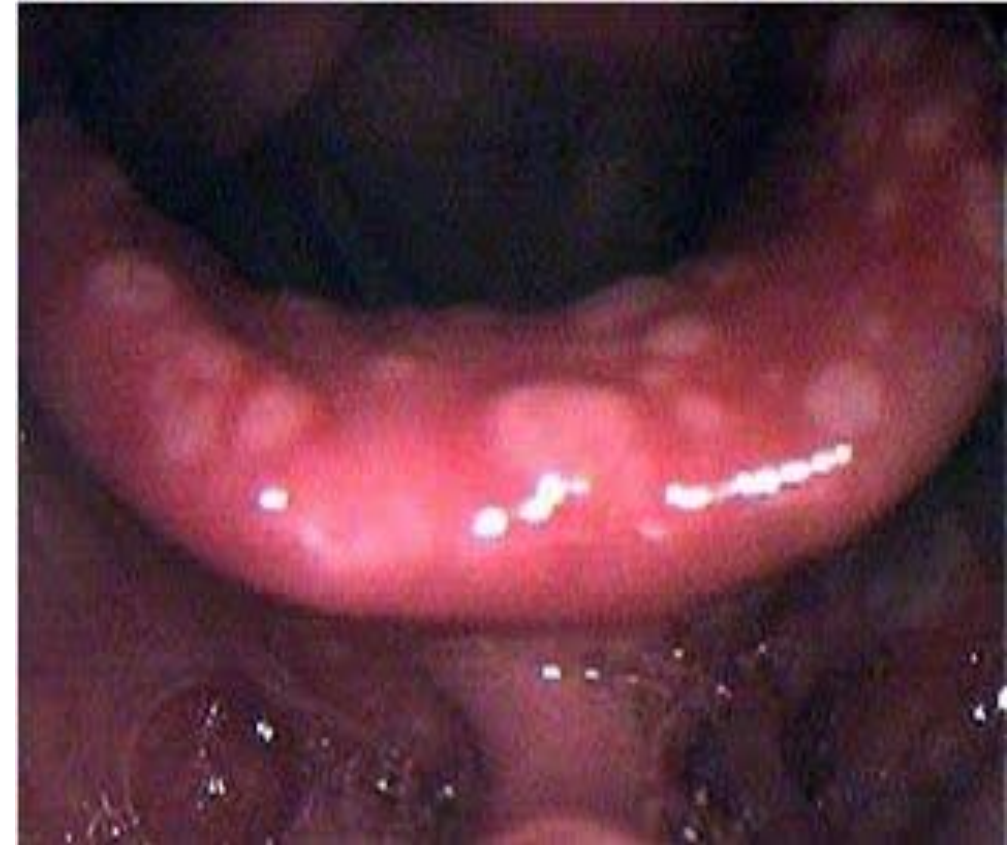A 7 year old child presented to the ER with stridor and toxic appearance and fever with difficulty in breathing

- What is the most common cause for it ?

H.influenza type B

best way to secure the air way?

Endotracheal intubation

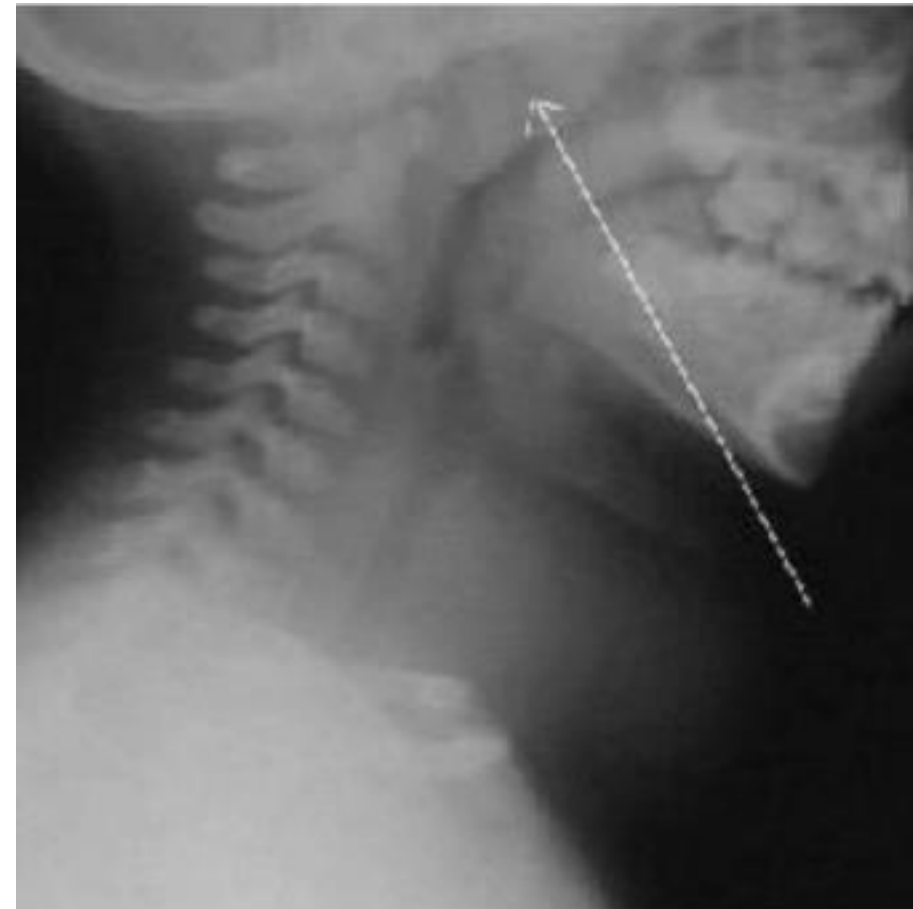

1- What is your diagnosis?

Adenoid hypertrophy

2- Mention two contraindications
for adenoidectomy ?

Cleft palate, acute infection, bleeding tendency

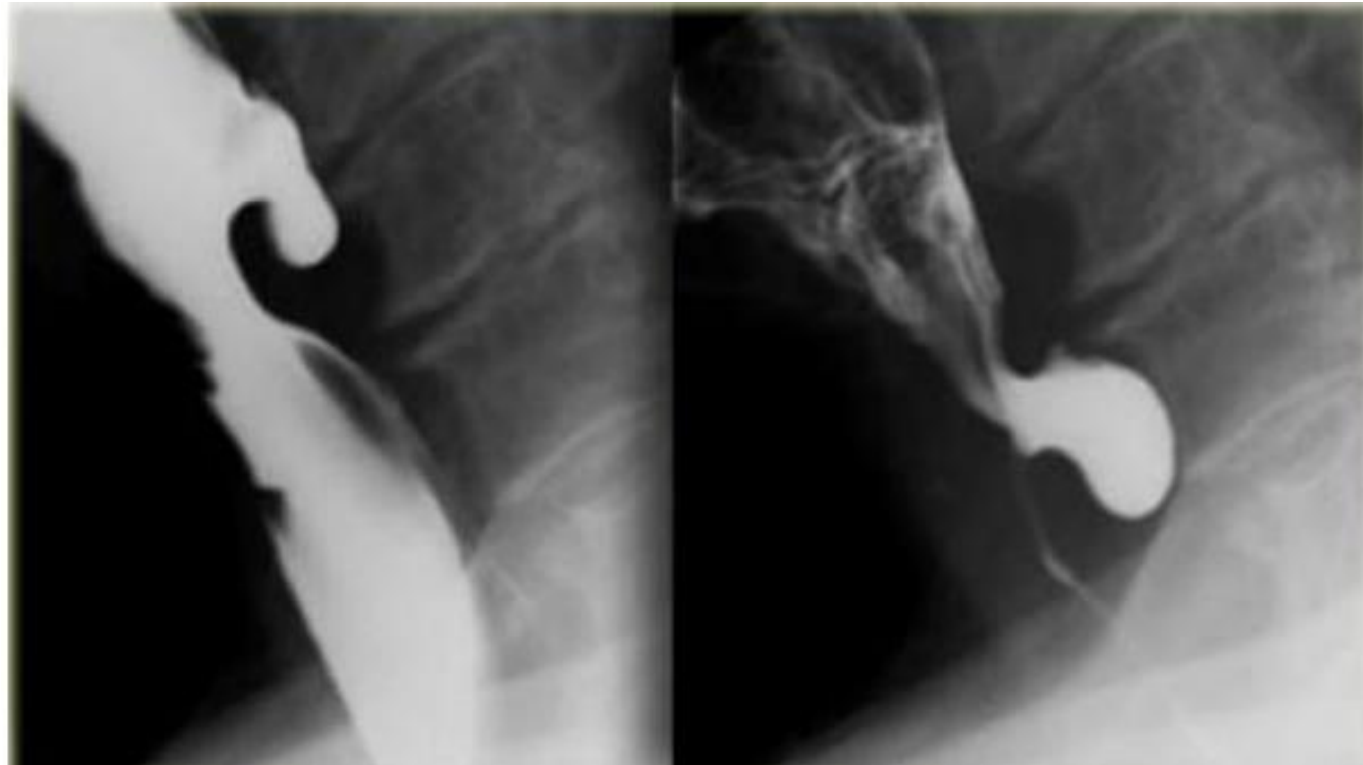

Chocking and cyanosis while eating in a restaurant..

- Best maneuver?
 - Heimlich maneuver
- Next step in this situation?
 - Cricothyroidotomy

Dysphagia, regurgitation

- Diagnosis?
 - Zenker's diverticulum
- Anatomical site?
 - Killian triangle



A patient presented with history of recurrent attacks of vertigo that continues for seconds with moving the head, Dix-hallpike positive

- **What is the next Step?**
 - Epley's manoeuvre
- **Finding in the Dix-hallpike maneuver?**
 - Nystagmus



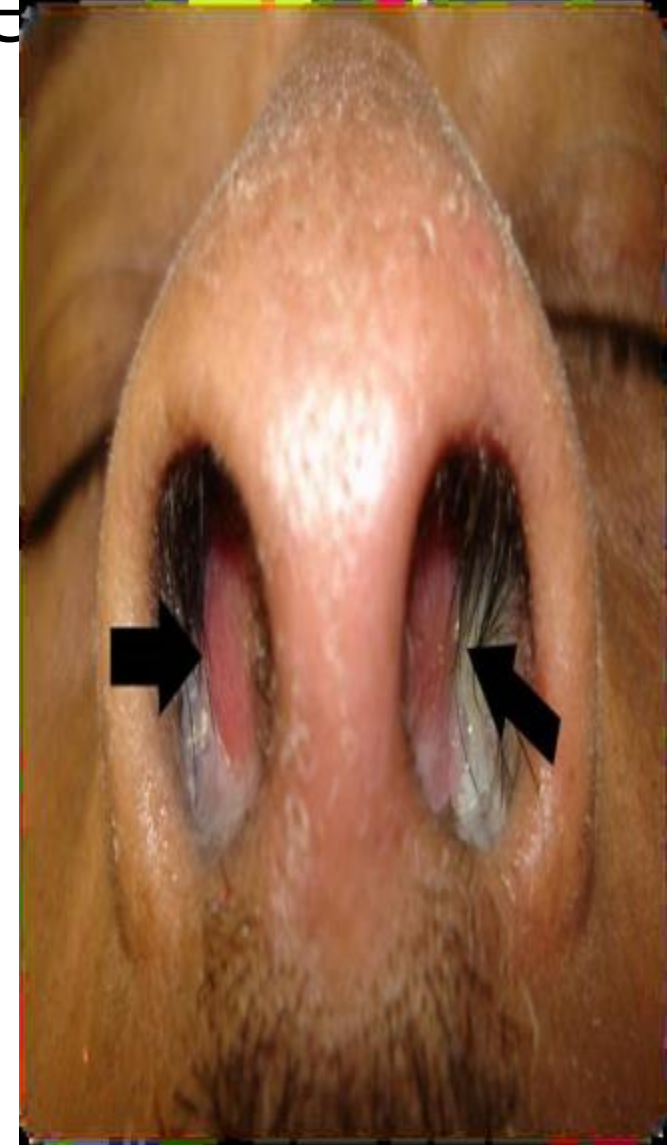Patient came to you after history of trauma yesterday complaining of this picture

- **What is your diagnosis?**

- Septal Hematoma

- **2 complications?**

- Abscess -Perforation



Name 5 prognostic factors for thyroid tumors

- MACIS

Mets

Age

Completeness of resection

Invasion

size

A female undergoes thyroidectomy

- What are the complications of HRT?

Write the thyroid and parathyroid complications

What is the origin of inferior thyroid artery?

ENT

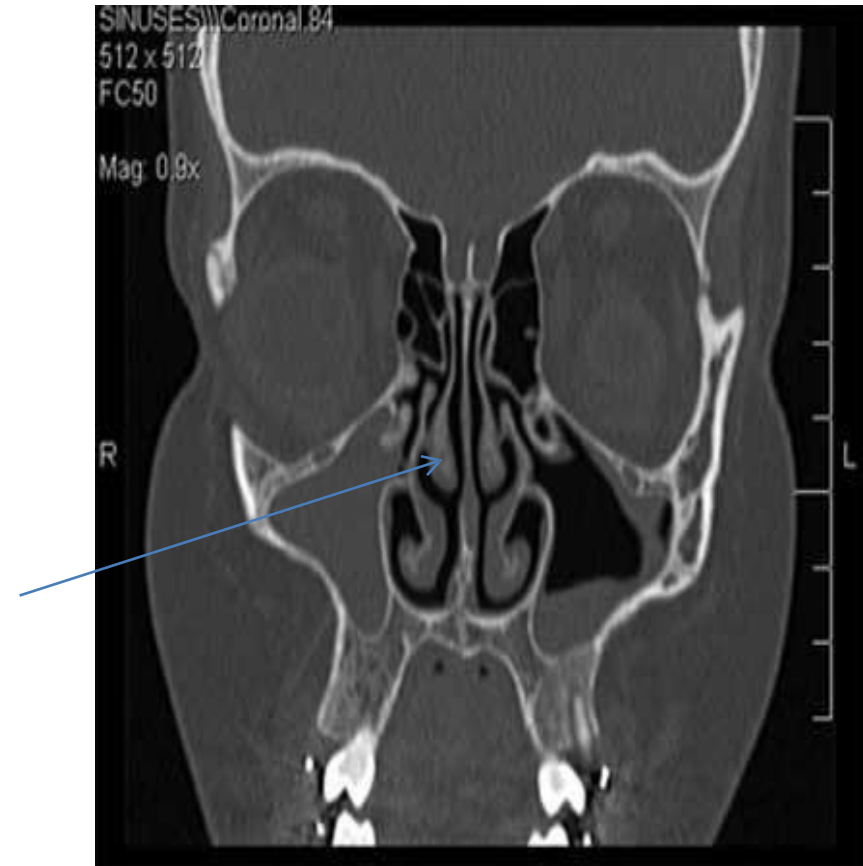
GroupA5/A6

Q1.

1Diagnosis?
Acute infective
rhinosinusitis.

2Name the structure?
Right middle turbinate.

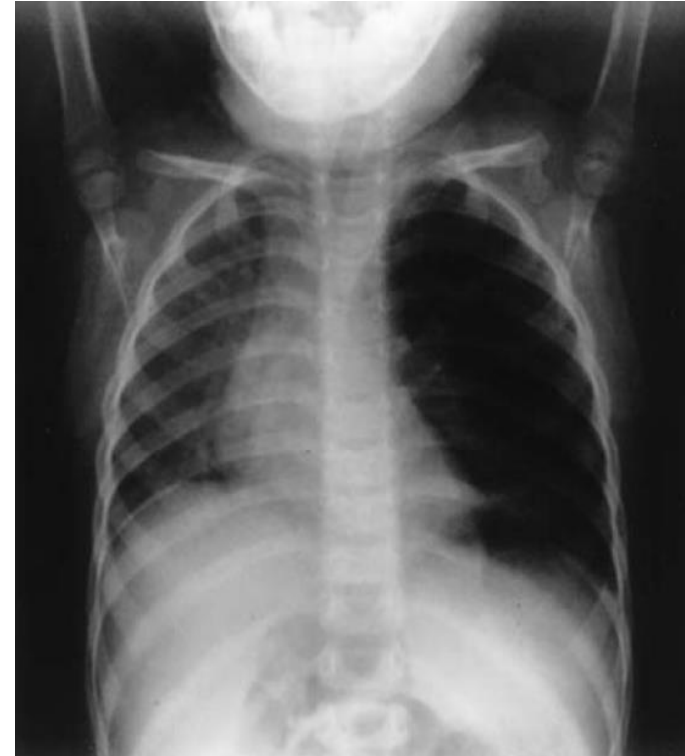3Two intracranial
complications?
Epidural abscess, Meningitis.



Q2.

1Diagnosis?
Foreign body
inhalation.

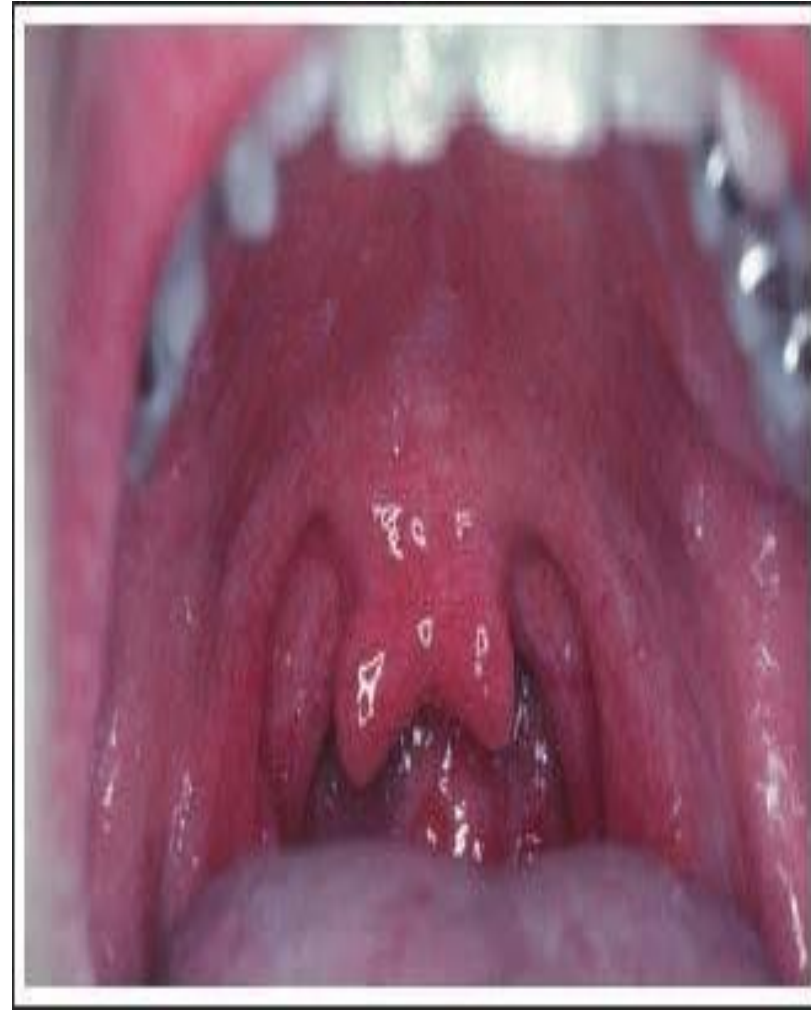2Management?
Bronchoscopy.



Q3.

1Two indications for tonsillectomy?
Recurrent acute tonsillitis, complications..

2Significance of the pathology in the picture?
Associated with submucous cleft palate.



Q4.

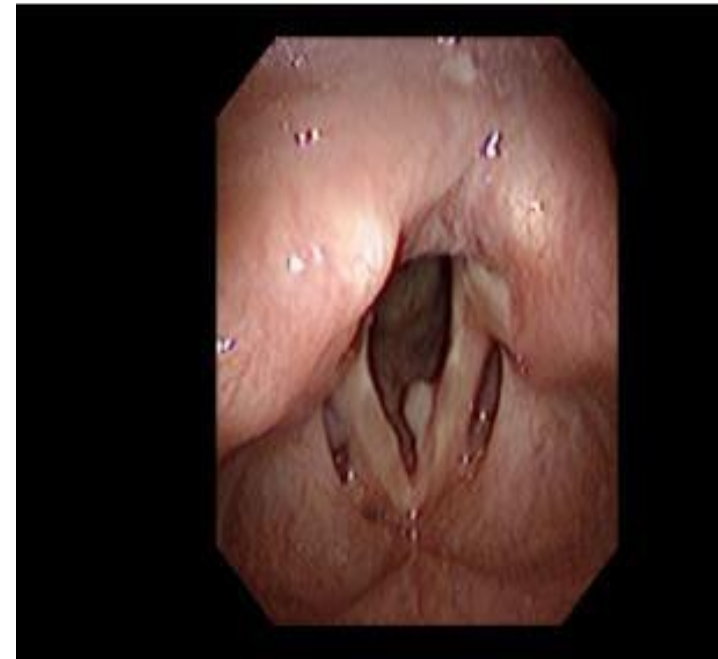
The pt is teacher and has hoarseness of voice..

1Diagnosis?

Singer's nodule.

2One line of management?

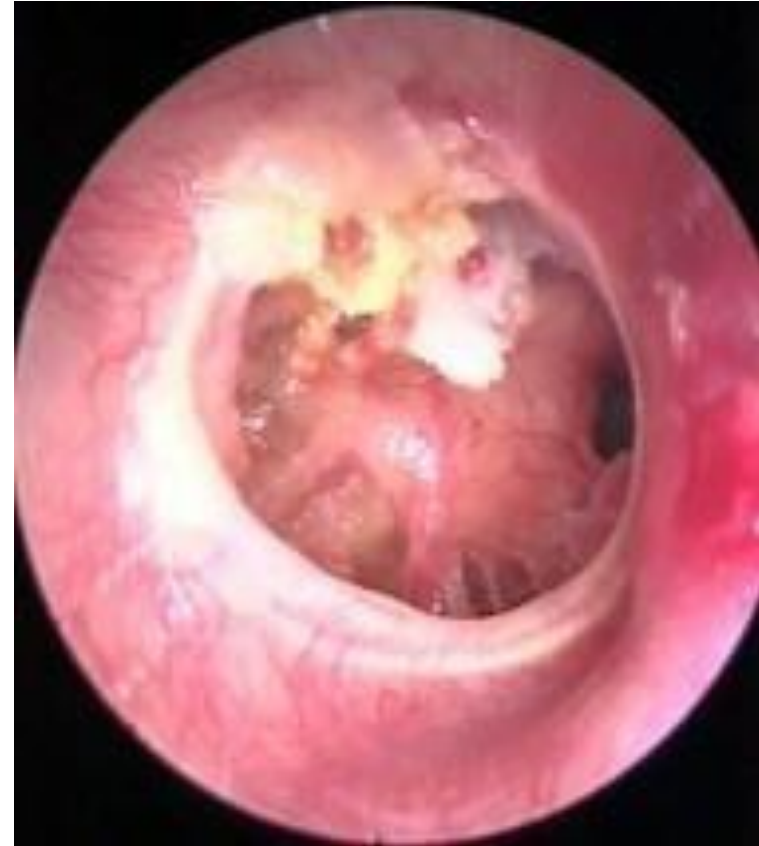Voice rest.



Q5.

1 Diagnosis?
chronic suppurative otitis
media with
cholesteatoma.

2 Tympanometry?
Type B.

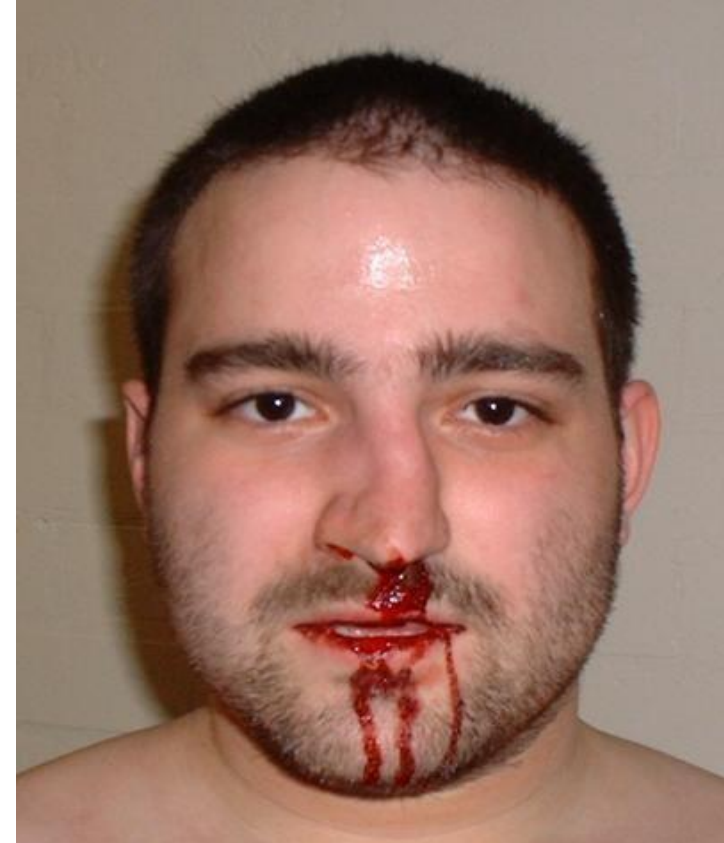

Q6.

1 Management?
Trotter's maneuver.

2 Two local causes?
Trauma, Septal perforation.

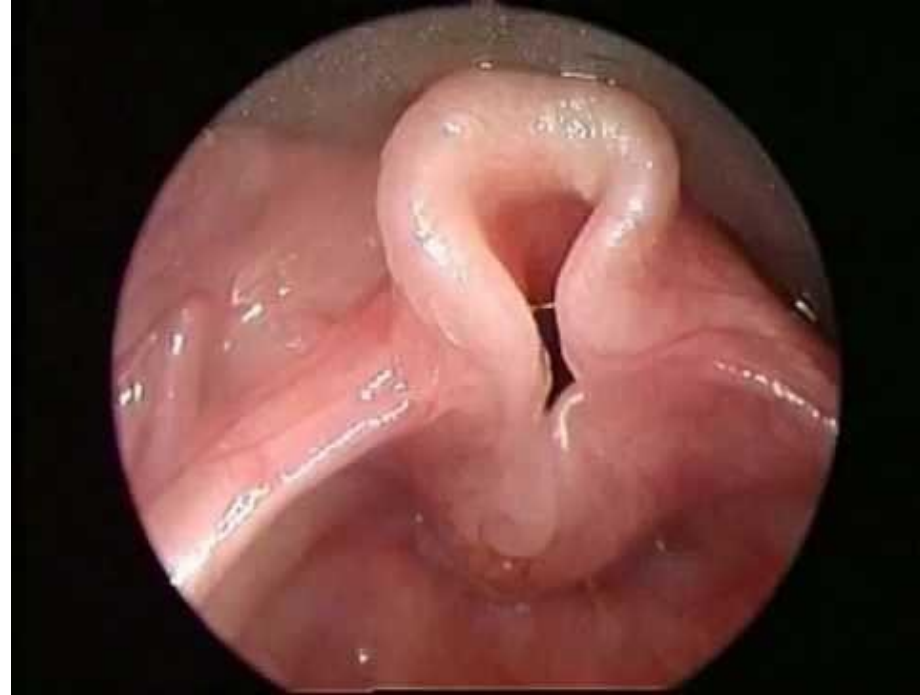3 Surgery?
Ligation of the anterior
ethmoidal artery.



Q7.

1Diagnosis?
Laryngomalacia.

2Sign?
Omega sign.

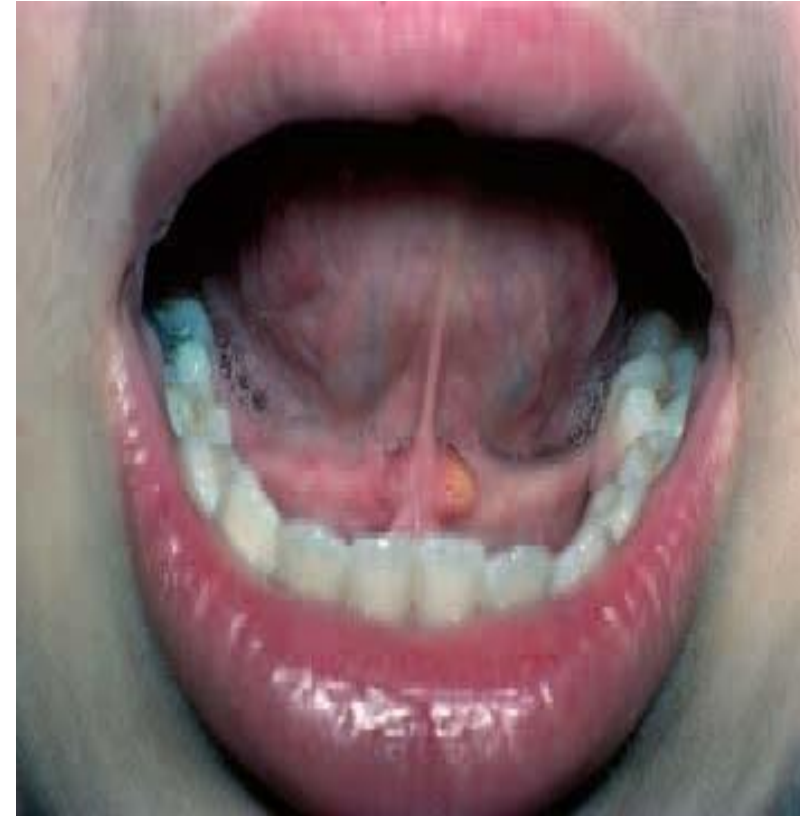

Q8.

1 Diagnosis?
Left submandibular
sialolithiasis.

2 Imaging study?
Sialogram.

3 Stenson's duct opening?
Opposite to upper second
molar tooth.



Q9.

A progressive bilateral hearing loss in old age with PTA of the pt:

- 1 Diagnosis? Presbycusis.
- 2 Management? Hearing aids.
- 3- Rinne test? Positive.

Q10.

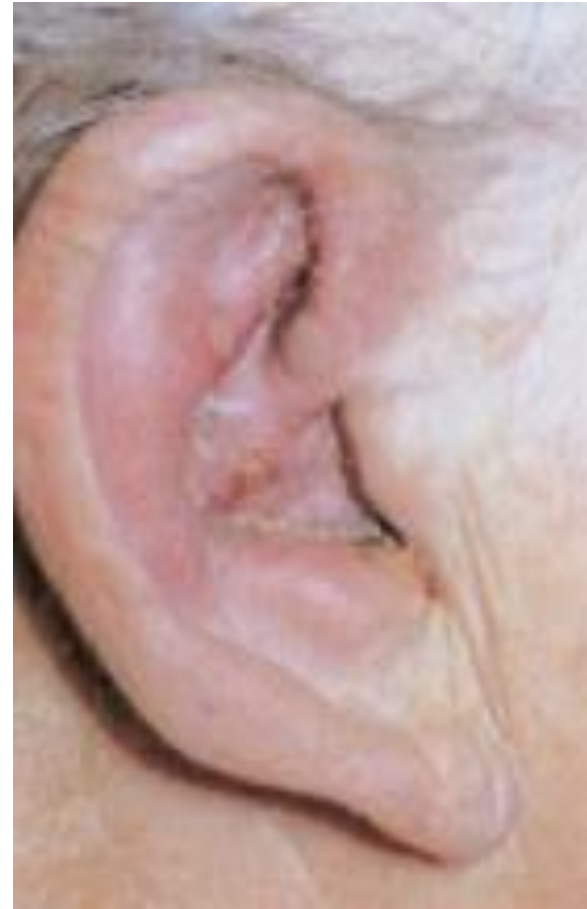Vesicles around the ear..

1- Diagnosis?

Herpes zoster oticus.

2- One complication?

Facial nerve palsy.



Q11.

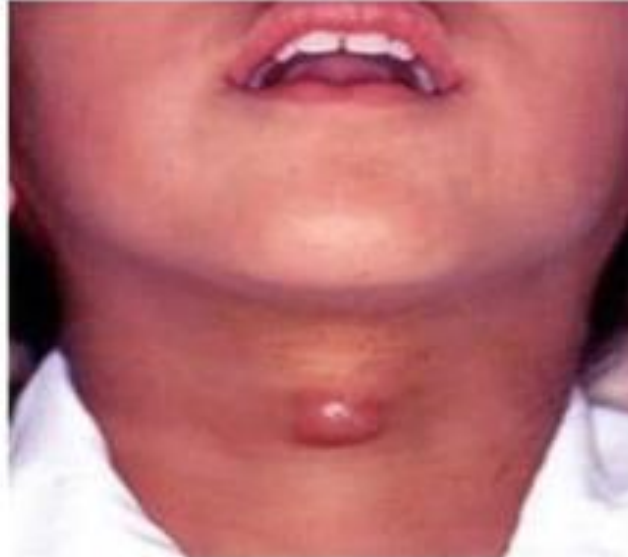Two features of Papillary Cancer?

- 1 Nuclear grooves.
- 2 Psammoma bodies.

5.

Q6

- Mention 3 differential Diagnosis?
- What is your next Investigation?



What is the Dx if this mass moves upon tongue protrusion and swallowing:

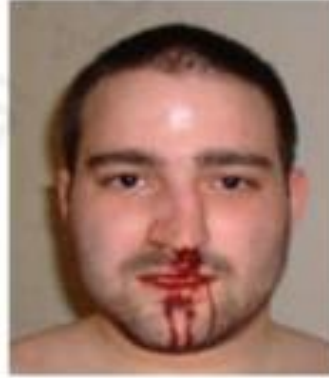Thyroglossal duct cyst

Surgery: Sistrunk surgery

What is the first line of management? Trotter's maneuver

Mention 2 of the non-traumatic causes? HTN, osler weber rendu syndrome (HHT)

Mention a surgery for ttt? Ligation of the anterior ethmoidal artery / carotid artery ligation



3.

Q9: After examining a patient you see this picture:

Mention 2 signs you see:

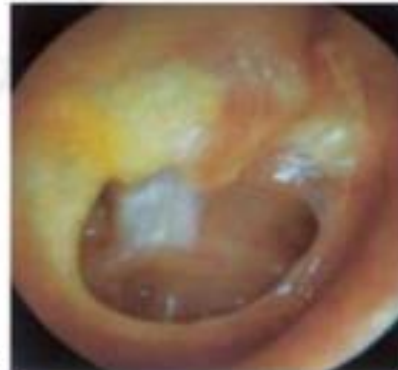- Tympanosclerosis
- Tympanic membrane perforation

Which Type of Tympanometry:

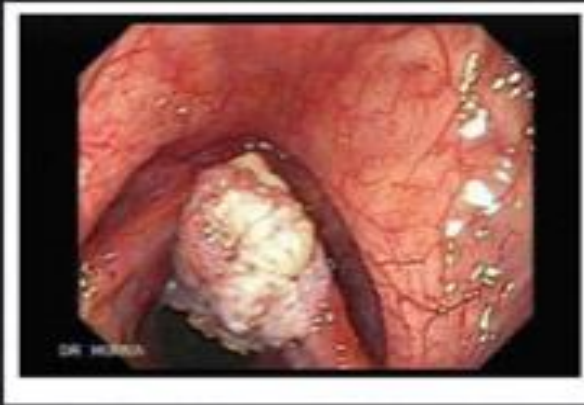- Type B

What is the result of Rennie test:

- Negative



6.



What is the work of diagnosis (question was written this way): laryngeal carcinoma

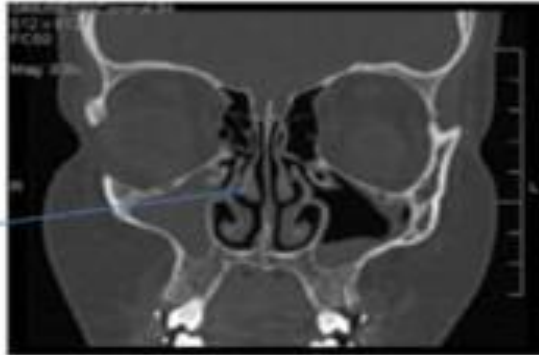
There was an arrow to name: Epiglottis

7. Histopathology of medullary thyroid cancer and question saying (Amyloidosis)

What is Dx?

What hormone shall we follow up?

Calcitonin

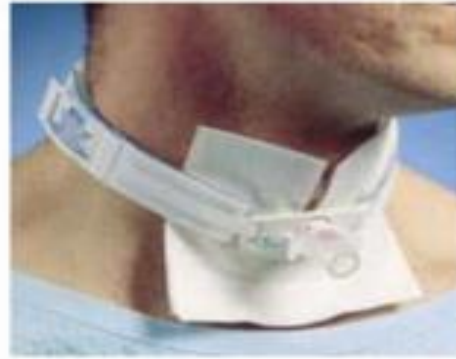

- What is the diagnosis ? acute rhinosinusitis
- Mention 2 Intra cranial complications?
Epidural abscess , brain abscess
- name the structure that the arrow points to?
Right middle turbinate

What is Dx: The case was chronic rhinosinusitis (due to duration 5 months)

2 Risk factors: immunodeficiency, smoking, allergy...

The arrow was on the (LEFT inferior turbinate)



- What is this instrument?
- Mention two uses.
- Mention one complication.

Give two indications: upper airway obstruction

Elective surgery... etc

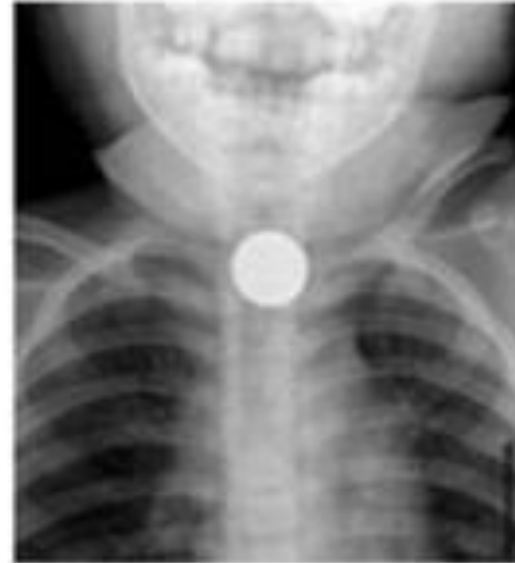Once contraindication: pediatrics

On which tracheal ring is it performed?

2nd

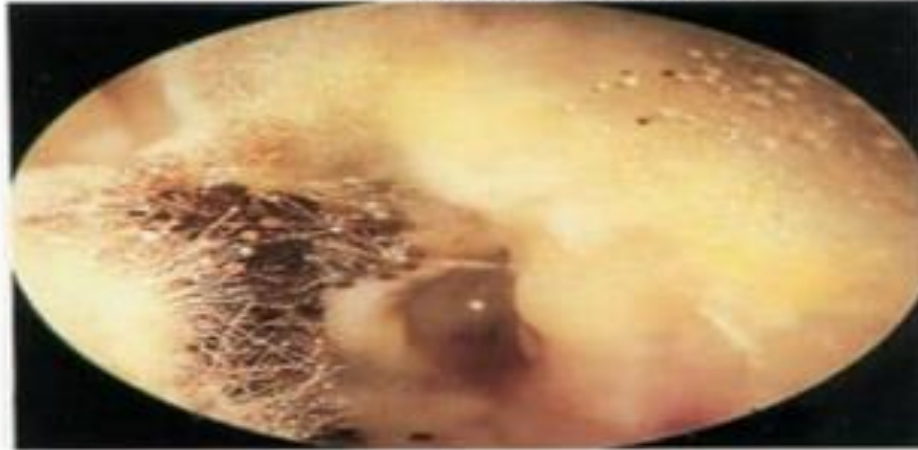
9.

- Q3) A history of a child presented with choking and dysphagia.
 - Where is the impaction
 - What is the treatment?
 - What is the most common site of foreign body entrapment in esophagus?



Dx: Foreign body (coin) ingestion
Management: esophageoscopy

Q4) A patient with a history of
pruritus...



- - Diagnosis . aspergillus otomycosis
- Mention 2 lines of treatment

Aural toilet. Topical antifungal

What is Dx: Otomycosis (Fungal infection
of the ear)

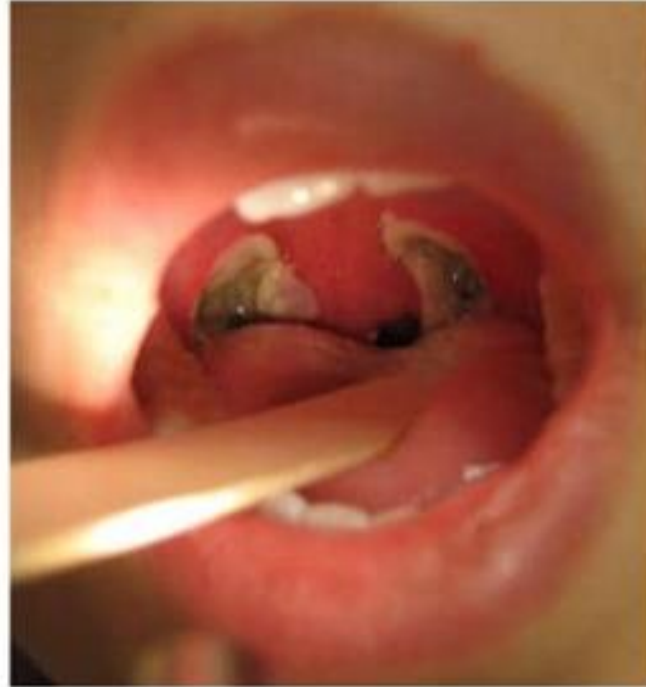2 Lines of management

8.

Q8:

This patient had tonsillectomy before one week:

- What are you seeing
- Give 2 indications for tonsillectomy
- give 2 complications of tonsillectomy



What is this?

In eagle syndrome what is the CN affected? Glossopharyngeal nerve

Adult risk factor for sleep apnea? Obesity

Q:

In Gradenigo's syndrome : What is the nerve that affected in the syndrome other than the trigeminal nerve?

Answer : Abducent nerve